

# Development of Graft-Versus-Host Reaction in Various Target Organs After Small Intestine Transplantation

E. Deltz, H. K. Müller-Hermelink, K. Ulrichs, A. Thiede, and W. Müller-Ruchholtz

**T**HE first attempts at clinical small intestine transplantation had very poor results.<sup>1</sup> One of the presumed reasons is that the role of graft-versus-host reaction (GVHR) induced by the small bowel graft is not yet fully evaluated. How far GVHR-induced lesions (GVHRIL) become apparent and if they are based on lymphoid tissue restricted GVHR or an extralymphatic GVHR, too, is disputed.<sup>2</sup> Transplantation of small intestine in the rat provides a useful model that allows answers to the following questions: (1) Does the quantity of grafted lymphatic tissue influence the strength of GVHR and the survival of the recipients? (2) What is the morphological correlation of GVHR in the graft? (3) Which lymphoid and nonlymphoid organs of the recipient are involved in GVHR, thus becoming target organs of GVHR? (4) Do the characteristics of GVHR show a specific time course?

## MATERIALS AND METHODS

Total or half small intestine was transplanted heterotopically.<sup>3</sup> Portal vein and an aortic cuff of the graft were anastomosed to the inferior vena cava and the abdominal aorta of the recipient. The oral end of the graft was closed, its distal end anastomosed to the terminal ileum of the recipient. Half (group 1,  $n = 15$ ) and total (group 2,  $n = 31$ ) small bowel of F344 rats was transplanted to (F344  $\times$  CAP)  $F_1$  hybrids and half (group 3,  $n = 30$ ) and total (group 4,  $n = 26$ ) small intestine of BN rats was grafted into (BN  $\times$  LEW) $F_1$  hybrid recipients. In addition, a syngeneic control group ( $n = 28$ ) was performed. The clinical features of the recipients after transplantation have been correlated with histomorphologic investigations of the graft as well as with the lymphatic tissues and small bowel of the recipient.

## RESULTS

### *Mortality Rates*

After syngeneic transplantation, there was no mortality until 120 days after operation. In the semiallogeneic groups, mortality with the clinical appearance of wasting disease was

found to be dependent on the quantity of grafted tissue. The animals developing GVHR disease showed progressive weight loss and heavy inflammatory alterations of the integument. Autopsy revealed striking diminution of adipose tissue. The recipients' intestines appeared transparent and puffed up with gas. Comparison of survival times (Fig. 1) shows that the strength of GVHR is closely correlated to the quantity of lymphatic tissue grafted.

### *Histologic Appearance of the Graft*

No morphological alterations of the mesenteric lymph nodes of the syngeneic grafts were found between days 15–25 after transplantation. During the same period, strong expression of GVHR can be found within the mesenteric lymph nodes of a semiallogeneic graft. The histologic picture shows immunoblasts and proliferation of epitheloid cells in the paracortical area (Fig. 2). All layers of the bowel wall of the graft, including mucosal epithelium, showed no morphological alterations.

### *GVHRIL in Recipients' Organs*

Compared with syngeneic controls, peripheral lymph nodes and spleen showed marked proliferation of immunocompetent cells with partial destruction of normal histologic architecture. The mucosal surface of the recipients' small bowels showed severe erosive enteritis

---

*From the Department of General Surgery, Department of Pathology, and Department of Immunology, University of Kiel, Kiel, Federal Republic of Germany.*

*Supported in part by Deutsche Forschungsgemeinschaft SFB 111.*

*Reprint requests should be addressed to Dr. E. Deltz, Department of Surgery, University of Kiel, 2300 Kiel, Hospitalstrasse 40, Federal Republic of Germany.*

© 1981 by Grune & Stratton, Inc.

0041-1345/81/1301-0291\$01.00/0

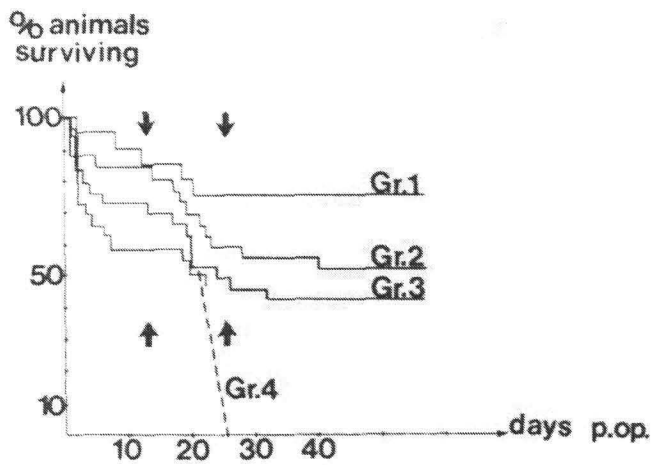


Fig. 1. Survival times of recipients of semiallogeneic small bowel grafts after development of GVHR.

with loss of the villi. The lamina propria was infiltrated by numerous immunoblasts and activated lymphoid cells.

#### Time Course of GVHRIL

All alterations showed a typical time dependence with maximum expression between days 15 and 25 after transplantation, followed by regression and fibrosis of lymphatic tissues.

#### CONCLUSIONS

The GVHRIL following transplantation of small intestine are different from those found after bone marrow transplantation or spleen cell injections<sup>4,5</sup> in that they show a remarkable, significant prevalence of lesions within the intestinal mucosa. These findings are consistent with the observation that intestinal lymphocytes newly formed in mesenteric lymph nodes predominantly home in on the intestine again.<sup>6</sup> The degree of histologic alteration within different tissues indicates that the graft and the host may survive the lesions of the lymphatic tissues, whereas the severe intestinal lesions following GVHR may

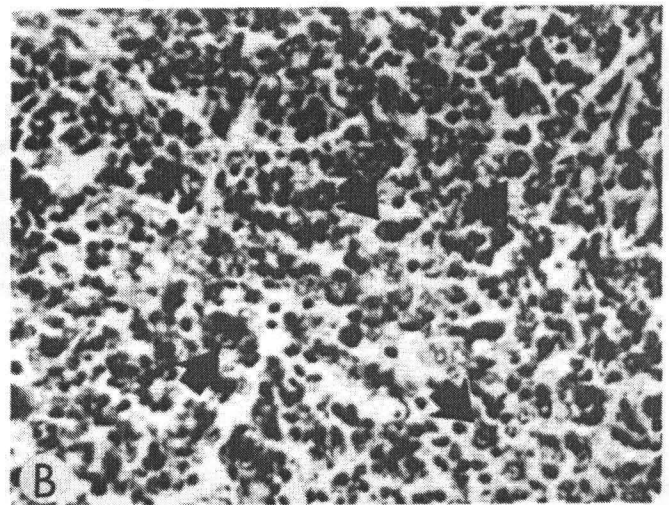
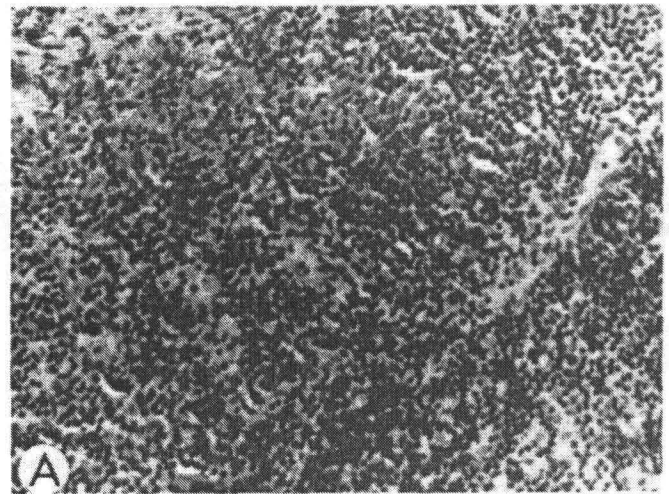


Fig. 2. Histologic picture of a mesenteric lymph node of the small bowel graft. (A) Syngeneic graft with normal appearance of the lymph node (day 15). (B) Immunologic stimulation in GVHR. The paracortical area contains numerous immunoblasts (arrows).

easily cause death of the recipient. With regard to clinical small bowel transplantation two statements can be made: (1) GVHRIL play a significant role in small bowel transplantation. (2) To minimize their biologic importance, a selective elimination of the graft's lymph nodes by irradiation or surgical resection should be considered in view of the remarkable difference between GVHRIL in lymph nodes and in the graft's intestinal wall itself.

#### REFERENCES

1. Stauffer UG: *Z Kinderchir* 22:241-248, 1977
2. Monchik GJ, Russell PS: *Surgery* 70:693-702, 1971
3. Thiede A, Deltz E: *Langenbecks Arch Chir* 346:119-127, 1978
4. Simonsen M: *Progr Allergy* 6:349-467, 1962
5. Elkins WL: *Transplant Proc* 10:15-17, 1978
6. Pabst R, Trepel F: *Immunobiology* 154:347-348, 1978