



Case report

Anomalous bilateral contribution of extensor pollicis longus and muscle fusion of the first compartment of the wrist



Rodrigo César Rosa^{a,*}, Kennedy Martinez de Oliveira^b, Jorge Alfredo Léo^c,
Bruno Adriano Borges Elias^c, Paulo Ricardo dos Santos^a,
Hildemberg Agostinho Rocha de Santiago^d

^a Department of Structural Biology, Universidade Federal do Triângulo Mineiro, Uberaba, MG, Brazil

^b Department of Anatomy, Universidade Federal de Juiz de Fora, Governador Valadares, MG, Brazil

^c School of Medicine, Universidade de Uberaba, Uberaba, MG, Brazil

^d Department of Biomechanics, Medicine and Rehabilitation of the Locomotor Apparatus, Faculdade de Medicina de Ribeirão Preto, Universidade de São Paulo, Ribeirão Preto, SP, Brazil

ARTICLE INFO

Article history:

Received 5 April 2015

Accepted 30 April 2015

Available online 26 February 2016

Keywords:

Wrist

Tendons

Muscle

ABSTRACT

Knowledge of the anatomical variations of the muscles of the first dorsal compartments of the wrist is clinically relevant to De Quervain's tenosynovitis and to reconstructive surgeries. In the literature, there are many reports of the presence of multiple insertion tendons in the first dorsal compartment of the wrist, but few reports describe occurrences of fusion and muscle contributions. This case report describes an anomalous bilateral contribution of the extensor pollicis longus. This anomalous contribution was found through a slender auxiliary tendon that crossed laterally under the extensor retinaculum, entered the first dorsal compartment of the wrist and merged with the tendon of the extensor pollicis brevis muscle. In the same cadaver in which this contribution was present, there was atypical muscle fusion of the abductor pollicis longus muscle and extensor pollicis brevis muscle. In conclusion, anomalous bilateral contribution of the extensor pollicis longus muscle and atypical muscle fusion, concomitant with a variant insertion pattern, are the highlight of this case report. Furthermore, it is concluded that additional tendons may be effectively used in reconstructive surgeries, but that there is a need for knowledge of the possible numerical and positional variations of these tendons, with a view to making more effective surgical plans.

© 2016 Sociedade Brasileira de Ortopedia e Traumatologia. Published by Elsevier Editora Ltda. All rights reserved.

* Corresponding autor.

E-mail: rodrigocesarosa@gmail.com (R.C. Rosa).

<http://dx.doi.org/10.1016/j.rboe.2016.02.008>

2255-4971/© 2016 Sociedade Brasileira de Ortopedia e Traumatologia. Published by Elsevier Editora Ltda. All rights reserved.

Anômala contribuição bilateral do extensor longo do polegar e fusão dos músculos do primeiro compartimento dorsal do punho

R E S U M O

Palavras-chave:

Punho
Tendões
Músculo

O conhecimento das variações anatômicas dos músculos do primeiro compartimento dorsal do punho é clinicamente relevante na tenossinovite de De Quervain e nas cirurgias reconstrutivas. Na literatura encontram-se inúmeros relatos da presença de múltiplos tendões de inserção no primeiro compartimento dorsal do punho, mas são poucos os relatos que descrevem a ocorrência de fusão e de contribuições musculares. Este relato de caso descreve uma contribuição anômala bilateral do extensor longo do polegar. A anômala contribuição foi encontrada por um tendão auxiliar delgado que cruzou lateralmente sob o retináculo dos extensores, entrou no primeiro compartimento dorsal do punho e fundiu-se com o tendão do músculo extensor curto do polegar. No mesmo cadáver foi encontrada a presença dessa contribuição e uma fusão muscular atípica do músculo abductor longo do polegar (APL) com o extensor curto do polegar (EPB). Em conclusão, a anômala contribuição bilateral do músculo extensor longo do polegar e a fusão muscular atípica, concomitante com um padrão de inserção variante, é o destaque deste relato de caso. Ainda, conclui que os tendões adicionais podem ser efetivamente usados nas cirurgias reconstrutivas e alerta sobre a necessidade de conhecimento das possíveis variações numéricas e posicionais desses tendões, com vistas a planejamentos cirúrgicos mais eficazes.

© 2016 Sociedade Brasileira de Ortopedia e Traumatologia. Publicado por Elsevier Editora Ltda. Todos os direitos reservados.

Introduction

The tendons of the abductor pollicis longus (APL) muscle and extensor pollicis brevis (EPB) muscle are located in the first dorsal compartment of the wrist. The APL originates in the proximal region of the dorsal surface of the radius, ulna and interosseous membrane, and it follows an inferolateral path and becomes superficial in the distal region of the forearm. There, it divides into two portions, which are inserted in the base of the first metacarpal and the base of the trapezium. The EPB originates in the distal region of the dorsal surface of the radius and the adjacent interosseous membrane and inserts in the base of the proximal phalanx of the thumb.¹

De Quervain's syndrome is characterized by pain in the region of the styloid process of the radius, coming from stenosing tenosynovitis of the tendons of the APL and EPB, in the region of the first dorsal compartment of the wrist. Variations in the number, length, thickness and insertion pattern of the tendons have been well described in the literature and have an important role in comprehension of the etiology of De Quervain's stenosing tenosynovitis.² Therefore, knowledge of the anatomical variations of the muscles of this region is important for surgeons during reconstructive surgery.³ This case report had the objective of presenting an occurrence of a fused muscle belly of the first dorsal compartment of the wrist and the presence of an anomalous contribution from the extensor pollicis longus muscle with the extensor pollicis brevis muscle.

Case report

During an investigation on occurrences of abnormal muscle fusions of the first dorsal compartment of the wrist, an

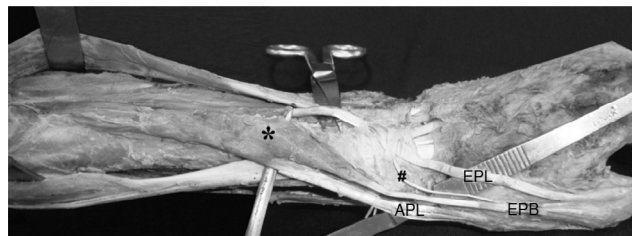


Fig. 1 – Photo showing the left forearm in pronated position. * denotes fused muscle belly of the abductor pollicis longus and extensor pollicis brevis. EPL, extensor pollicis longus; EPB, extensor pollicis brevis; #, auxiliary tendon; APL, abductor pollicis longus.

anomalous bilateral contribution from the extensor pollicis longus muscle was found (Fig. 1). There was an unusual bilateral contribution from a slender auxiliary tendon that crossed laterally under the extensor retinaculum, entered the first dorsal compartment of the wrist and merged with the tendon of the extensor pollicis brevis muscle. In the same cadaver in which this contribution was present, there was anomalous muscle fusion of the APL and EPB (Figs. 1 and 2).

Morphological characteristics such as length and width were described by using the reference points of the standard muscle origin and insertion. Anthropometric measurements were made by positioning a string passively on the tendons and muscle bellies, and the dimensions were confirmed by means of universal digital calipers (Mitutoyo®), with precision of 0.05 mm. The measurement technique was carried out by the same evaluator, who made three consecutive measurements. The mean of the values obtained was used.

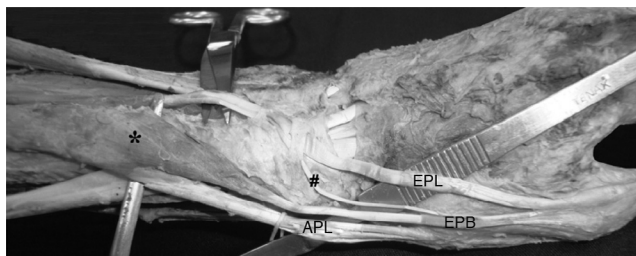


Fig. 2 – Photo showing details of the anomalous muscles of the first dorsal compartment of the wrist and the auxiliary tendon of the extensor pollicis longus muscle. * denotes fused muscle belly of the abductor pollicis longus and extensor pollicis brevis. EPL, extensor pollicis longus; EPB, extensor pollicis brevis; #, auxiliary tendon; APL, abductor pollicis longus.

The right APL was 11.5 cm in length and 2.7 cm in width. The ulnar origin (ulnar head) was located 20.5 cm from the insertion (base of the first metacarpal). The distance between the radial origin (radial head) and its insertion (base of the first metacarpal) was 18.2 cm. The right APL had a single tendon of approximately 9 cm in length and it had two insertion fascicles: one to the abductor pollicis brevis (APB) muscle and the other to the opponens pollicis (OP) muscle.

The left APL was 15.7 cm in length and 2.5 cm in width. The ulnar origin (ulnar head) was located 20 cm from the insertion (base of the first metacarpal). The distance from the radial origin (radial head) and the insertion (base of the first metacarpal) was 17.5 cm. The tendon of the left APL had three branches: intermediate tendon (I), lateral tendon (L) and medial tendon (M) (Fig. 3).

Tendon I was 7.5 cm in length, while tendons M and L were 7 cm. Tendons M and I were inserted in the base of the first metacarpal, while tendon L presented three insertion fascicles: APB, OP and the anteromedial region of the base of the first metacarpal. Both of the EPB muscles received anomalous donation from the EPL, through a slender auxiliary tendon of mean length 9.2 cm, which crossed obliquely and laterally under the extensor retinaculum, entered the first dorsal compartment of the wrist and merged with the tendon of the EPB.

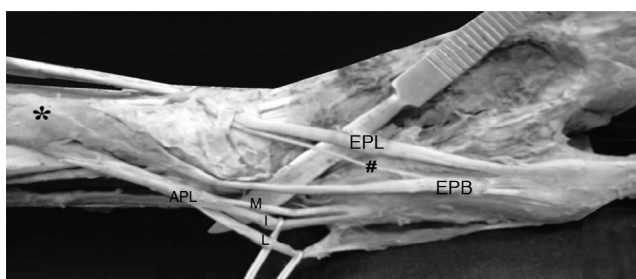


Fig. 3 – Photo showing details of the insertion tendons of the abductor pollicis longus of the left arm. * denotes fused muscle belly of the abductor pollicis longus and extensor pollicis brevis. EPL, extensor pollicis longus; EPB, extensor pollicis brevis; #, auxiliary tendon; APL, abductor pollicis longus; M, medial tendon; I, intermediary tendon; L, lateral tendon of the fused muscle belly.

The right EPB was 7.2 cm in length and 1.2 cm in width. Its radial origin was located 14.5 cm from the insertion. It was inserted at the level of the extensor aponeurosis of the metacarpophalangeal joint of the thumb. However, the left EPB was 8.5 cm in length and 1.1 cm in width, and its radial origin was located 17 cm from the insertion.

The innervation of the fused bellies was, as usual, through the posterior interosseous nerve. No neurovascular variation was observed in the region of the wrist and hand.

Discussion

There are several reports on multiple insertion tendons of the APL in the literature. These are presented as an atavism,^{4,5} with reports of three,² four,⁶ five,⁷ seven and nine insertion tendons.^{8,9}

The presence of supernumerary tendons of the APL is of great clinical importance, particularly during reconstructive surgery.⁹ Accessory tendons of the APL can be used for tendon transfer, tendon translocation and interposition arthroplasty.⁹⁻¹²

Prior knowledge of the existence and importance of these accessory tendons may be useful in surgical procedures,¹³ in view of their use as replacements for the extensor pollicis longus (EPL) and in reconstructions of the first dorsal compartment of the wrist.^{14,15} However, the possibility that the auxiliary extensor tendon might contribute toward the action of the extensor pollicis brevis muscle is very interesting and unexpected. There are no reports of this in the literature.

According to the literature, the presence of two or more tendons of the APL is observed in 94% of the cases. The EPL presents two tendons in 3% of these cases.¹⁶ The presence of multiple tendons represents a type of atavism. It is generally reported in primates such as chimpanzees, gorillas and gibbons. These anomalous tendons in humans are of anthropological and phylogenetic importance, given that their presence constitutes a reminiscence of ancestral forms of muscle insertion.^{2,3,6,8,17}

From a phylogenetic point of view, the APL and EPB are known to develop through differentiation from a common muscle mass. Complete separation of the EPB is only observed in humans. Reports of its absence or of fusion with the EPL have only rarely been described in the literature.⁵ However, further studies are needed in order to elucidate the factors relating to fusion of the APL and EPB. The incidence of doubling of the EPB is unclear, given that the rates reported in different studies have been 1%, 2% and 8.3%.⁴ However, multiple tendons may constitute a reminiscence of the pattern of fetal tendon development.⁶

The most important clinical condition involving anomalies of the APL and EPB is De Quervain's syndrome. This condition arises due to thickening and inflammation of the tendons of the APL and EPB and results in pain and edema in the first dorsal compartment of the wrist. The pain becomes exacerbated during movements of the thumb, which makes the tendons more liable to degenerative processes and lesions.¹⁶ Surgical release of the tendons inside the dorsal compartment of the wrist is a curative measure for De Quervain's syndrome.¹⁸ Thus, deeper knowledge of the possibilities for tendon

anomalies is needed before undertaking any reconstruction or in planning for surgical correction of tendinopathy.

In conclusion, the anomalous bilateral contribution of the EPL and atypical fusion of the APL and EPB, concomitantly with a variant insertion pattern, are the highlight of this case report. Furthermore, it is concluded that additional tendons may be effectively used in reconstructive surgeries, but that there is a need for knowledge of the possible numerical and positional variations of these tendons, with a view to making more effective surgical plans.

Conflicts of interest

The authors declare that there were no conflicts of interest.

Acknowledgements

We are grateful for the support provided by technicians at the Anatomy Laboratory: Romes, Marcelo, Neuza and Wanderson (Thon).

REFERENCES

1. Standing S, Ellis H, Healy JC, Johnson D, William A. *Gray's anatomy: the anatomical basis of medicine and surgery*. 39th ed. New York: Churchill Livingstone; 2005.
2. Bergman RA, Thompsom SA, Affifi AK, Saadeh FA. *Compendium of human anatomic variation: catalog, atlas and world literature*. Baltimore and Munich: Urban & Schwarzenberg; 1988.
3. Lacey T 2nd, Goldstein LA, Tobin CE. Anatomical and clinical study of the variations in the insertions of the abductor pollicis longus tendon, associated with stenosing tendovaginitis. *J Bone Joint Surg Am*. 1951;33(2):347-50.
4. Joshi SS, Joshi SD. Applied significance of variations of first extensor compartment of wrist. *J Anat Soc India*. 2002;51(2):159-61.
5. Dhuria R, Mehta V, Suri RK, Rath G. Anomalous composition of musculature of the first dorsal fibro-osseous compartment of the wrist. *Singapore Med J*. 2012;53(6):e133-5.
6. Mehta V, Arora J, Suri RK, Rath G. A rare quadruplicate arrangement of abductor pollicis longus tendons: anatomical and clinical relevance. *Clinics (Sao Paulo)*. 2009;64(2):153-5.
7. Schmidt HM, Lahl J. Studies on the tendinous compartments of the extensor muscles on the back of the human hand and their tendon sheaths. I. *Gegenbaurs Morphol Jahrb*. 1988;134(2):155-73.
8. Melling M, Wilde J, Schnallinger M, Schweighart W, Panholzer M. Supernumerary tendons of the abductor pollicis. *Acta Anat (Basel)*. 1996;155(4):291-4.
9. Mansur DI, Krishnamurthy A, Nayak SR, Kumar GC, Rajalakshmi R, D'costa S, et al. Multiple tendons of abductor pollicis longus. *Int J Anat Var*. 2010;3(1):25-6.
10. Akan M, Giderogu K, Cakir B. Multiple tendons of the abductor pollicis longus muscle. *Hand Surg*. 2002;7(2):289-91.
11. Nayak SR, Krishnamurthy A, Pai MM, Prabhu LV, Ramanathan LA, Ganesh Kumar C, et al. Multiple variations of the extensor tendons of the forearm. *Rom J Morphol Embryol*. 2008;49(1):97-100.
12. Cerqueira PC, Silveira D, Silva AT, Franco AG, Gama HVP, Sales MC, et al. Anomalous origin of the Abductor Pollicis Longus (APL): clinical and surgical applications. *J Morphol Sci*. 2013;30(3):152-5.
13. Dos Remédios C, Chapnikoff D, Wavreille G, Chantelot C, Migaud H, Fontaine C. The abductor pollicis longus: relation between innervation, muscle bellies and number of tendinous slips. *Surg Radiol Anat*. 2005;27(3):243-8.
14. Sehirlir US, Cavdar S, Yüksel M. Bilateral variations of the abductor pollicis longus. *Ann Plast Surg*. 2001;47(5):582-3.
15. Sarikcioglu L, Yildirim FB. Bilateral abductor pollicis longus muscle variation. Case report and review of the literature. *Morphologie*. 2004;88(282):160-3.
16. Minamikawa Y, Peimer CA, Cox WL, De Sherwin FS. Quervain's syndrome: surgical and anatomical studies of the fibroosseous canal. *Orthopedics*. 1991;14(5):545-9.
17. Paul S, Das S. Variant abductor pollicis longus muscle: a case report. *Acta Med (Hradec Kralove)*. 2007;50(3):213-5.
18. Chambriard C, Couto P, Osório L, Rehsfeldt LCL, Menegassi Z. A reoperação na tenossinovite de De Quervain. *Rev Bras Ortop*. 1998;33(2):128-30.