



ELSEVIER

Behavioural Brain Research 97 (1998) 69–78

**BEHAVIOURAL
BRAIN
RESEARCH**

Research report

Encoding and retrieval in declarative learning: a positron emission tomography study

U. Halsband ^{a,*}, B.J. Krause ^{b,c}, D. Schmidt ^{b,c}, H. Herzog ^c, L. Tellmann ^c,
H.-W. Müller-Gärtner ^{b,c}

^a Department of Neurology, Heinrich-Heine-University Hospital, Düsseldorf, Germany

^b Department of Nuclear Medicine, Heinrich-Heine-University Hospital, Düsseldorf, Germany

^c Institute of Medicine, Research Center Jülich, Jülich, Germany

Received 1 August 1997; received in revised form 3 February 1998; accepted 3 February 1998

Abstract

We present neuroanatomical correlates of encoding and retrieval in an episodic memory task using visually presented highly imaginable word-pair associates. A total of 13 right-handed normal male volunteers took part in the study. Each subject underwent six ¹⁵O-butanol PET scans. On each of the six trials the memory task began 30 s before the injection of a bolus of ¹⁵O-butanol. The subjects had to learn and retrieve 12 word pairs (highly imaginable words, not semantically related, hard associations). The presentation of nonsense words served as a reference condition. Recall accuracy after 2–4 presentations was $66.1\% \pm 21.1$ correct during the PET measurement so that scanning during the retrieval of word pair associates was appropriate to capture the brain activity associated with retrieval. The results obtained support the hypothesis of the presence of an asymmetric network consisting of distributed brain structures subserving associative memory. We show left dorsolateral prefrontal activation during the encoding of visually presented word pair associates, whereas retrieval led to bilateral frontal activation. Furthermore, the importance of the precuneus in the retrieval of highly imaginable word-pair associates using visual imagery as a mnemonic strategy is demonstrated. © 1998 Elsevier Science B.V. All rights reserved.

Keywords: Episodic memory; Positron emission tomography; Prefrontal; Cortex; Precuneus; Associative learning

1. Introduction

Memory processes can be subdivided with respect to both contents and time. In the time domain, short-term memory and working memory are dissociated from long-term memory processes [2,58]. The essential criterion for a distinction between the two is their temporal persistence, length of time may be seconds to minutes in working and short-term memory and up to years in

long-term memory; substantial support for this dichotomy has come from studies of amnesic patients [13,62].

Classification of memory must also take into account differences and similarities on the kinds of information that memory contains. A number of different classification schemes of memory have been described [30,61,62,70,71,82,83]. Although the terminology used by different investigators may vary, there seems to be considerable agreement as to the main concept behind a dichotomy of a declarative (explicit) versus procedural (implicit) memory system. The concept of two distinct memory systems arose from the observation that even severely amnesic patients can learn new motor skills

* Corresponding author. Present address. Institute for Medical Psychology and Behavioural Neurobiology, Eberhard-Karls-University of Tübingen, Gartenstraße 29, D-72074 Tübingen, Germany. Tel.: +49 7071 2974222; fax: +49 7071 295956.

[3,12,44,55,65]. Declarative memory includes specific information about time and space relating to the recall of personal events in the subject's life (episodic memory) as well as general knowledge of the world, i.e. semantic knowledge of facts that the subject has come to categorize as concepts or abstractions (semantic memory) [61,70,79]. Declarative memory requires the conscious recollection of events and facts, in contrast, procedural or implicit memory is inferred from the effect that practice has on behaviour independent of cognition [27,61,71]. The procedural system comprises the learning of motor skills, rules and conditioning of simple stimulus-response connections, i.e. instances where information that has been previously learned can be expressed only through performance. It is, therefore, not surprising to find that different brain areas have been implicated in procedural and declarative learning tasks [16,27].

Short-term memory registers and retains information in a highly accessible form and allows for a lingering impression of the individual's present environment beyond the duration of the physical presence of the stimulus information emanating from the environment [71]. Previous investigations delineated widespread brain systems in verbal episodic memory including the medial temporal lobe system [4,12,44,55], the thalamic structures [14,26,77], the precuneus (Brodmann area 7) [16,17], the prefrontal cortex [4,16,17,21,23,24,26] and the retrosplenial area of the cingulate gyrus [52,76].

Only a few studies on episodic memory have addressed the question of whether the brain systems involved during encoding and retrieval processes are dissociable. Recent findings from functional imaging studies have provided evidence for a memory encoding/retrieval asymmetry (HERA model) [16,17,31,40,60,64,72,73]. Despite the use of markedly differing tasks, modalities (e.g. verbal-visual versus verbal-auditory) and conditions, an important finding of these studies was of a left prefrontal activation during episodic encoding and a right prefrontal activation predominating at retrieval.

In the present study, the functional anatomy of a verbal episodic memory task was examined during either the encoding or retrieval of visually presented paired word associates. Learning a paired association between A and B involves; (1) that representations A and B are stored as elements and (2) that A is conditionally tied or connected to B so that some kind of associate bond is formed. The aim was to specifically disentangle encoding and retrieval in this episodic memory task. Regional cerebral blood flow (rCBF) was measured using positron emission tomography (PET) in 13 normal subjects with ^{15}O -butanol during encoding and retrieval phases. A reference task was employed in which, during scanning, subjects were presented with nonsense words and required to read them aloud.

In contrast to earlier studies [4,16,17,60] paired associates that were related were not included, such as lamp and bulb. But instead 'hard' word associations were used, i.e. word pairs that are unrelated, for example candle and street. This was done in order to increase the mnemonic demands. A similar distinction between easy and hard word associations was made by Wechsler [81] in his associative learning task, Subtest VII, of the Wechsler Memory Scale.

A high factor of imagery of the word pair associates was chosen because previous functional imaging studies using PET indicate that imaginability of paired associates affects the activity in the precuneus [16,17,60] and it is known that the use of imagery provides a valuable strategy for efficient episodic memory retrieval [26,64,73]. It was predicted that the precuneus would be significantly activated by the recall of the imaginable pairs of words used in the present investigation.

2. Material and methods

2.1. Subjects

A total of 13 right-handed male volunteers (mean age 26.6 ± 3.4 years) with no history of neurological or psychiatric illness took part in the study which was approved by the ethical committee and federal authorities. All subjects gave informed, written consent for participation in the study. Each subject underwent six PET scans within a single session and a magnetic resonance imaging scan on a different day.

2.2. Positron emission computed tomography scanning

Scans of rCBF were obtained for each subject using a GE PC4096 Plus scanner which provides 15 transverse sections through the brain spaced 6.5 mm apart (center to center). The physical characteristics of this scanner have been described previously [51]. Transmission scans performed with a ^{68}Ga rotating line source were used for measured attenuation correction. A laser positioning system helped to obtain images parallel to a line 27 mm above the canthomeatal line. Emission scans were recorded after the intravenous bolus administration of 1500 MBq ^{15}O -butanol (half-life 123 s). Emission data were acquired in list mode for 3 min post-injection starting with the injection of ^{15}O -butanol. The list mode data was framed into a single frame of 40 s starting at the entry of the tracer into the brain comprising all 15 image planes [28]. Using filtered backprojection, the reconstructed image resolution was about 9 mm (full width half maximum). The activity images were not further quantified and were regarded as estimates of rCBF.

2.3. Paired word association learning

A visual verbal episodic memory task was used. Subjects were visually presented word pairs. Study words were two-syllable German words that were between four and nine letters in length and of moderate frequency. The word pairs were unrelated and, therefore, difficult to associate. Word pairs (with the second word under the first to avoid lateralization effects) were presented on a 17" computer monitor placed in a distance of about 70 cm from the eyes (Font: Times New Roman, size: 72 points). The letters were white on a black screen and centered. In the reference condition, nonsensewords (two-syllable pseudowords that obey German spelling rules) were used.

In a pre-study all subjects underwent testing of memory performance with the visual verbal memory task. Subjects were presented 12 word pairs. Afterwards they were asked to retrieve the corresponding word pair associate after having been randomly presented the first of the two words of each word pair. The subject's individual performance was evaluated by repeating the storage and retrieval task for the number of times the volunteer needed to successfully retrieve about 80% of the randomly presented word pairs.

Using a new set of 12 word pairs, six PET measurements were performed for each volunteer. On each of the six trials the cognition task began approximately 30 s before the injection of a bolus of *O*-15-butanol. During the first scan (storage) subjects were presented 12 word pairs visually and had to read them aloud (presentation rate: 4 s word pair presentation, 1 s interval). Between scan 1 (1st storage) and scan 2 (1st retrieval) the same word pair associates were presented in random order one to three times according to the number of encoding repetitions needed to retrieve an average of 80% of the word pair associates as evaluated by pre-study memory performance testing. During scan 2 the first words of the pair associates were visually presented (presentation rate: 4 s first word of a word pair, 1 s interval). The subjects had to read the first word of a word pair aloud and to add the corresponding associated word aloud, too. During scan 3 (reference condition) the volunteer saw nonsense-words which he had to read aloud (presentation rate: 4 s nonsense-word, 1 s interval). Scans 4 through 6 were repetitions of scan 1 through 3 with only one more encoding of the same word pairs during scan 4 and the second retrieval during scan 5. Only the data from scan 1 through 3 were included in this analysis.

2.4. Data analysis

Image analysis was performed using the statistical parametric mapping (SPM) software [18,19]. Image analysis was performed on a SPARC 20 workstation (Sun Microsystems). Calculations were performed in

Matlab (MatLab version 4.2c).

Each reconstructed ¹⁵O-butanol scan was realigned and reoriented along the bi-commissural line using a PET template into a standard stereotactic space [67]. In the standard space 1 voxel represents 2 × 2 × 4 mm in the *x*, *y* and *z* dimensions, respectively [18]. A Gaussian filter with a full width half maximum (15 mm) was applied to smooth each image to compensate for inter-subject differences and to suppress high frequency noise in the images. Differences in global activity within and between subjects were removed by the analysis of covariance (ANCOVA) on a pixel by pixel basis with global counts as covariate and regional activity across subjects for each task, as inter and intra-subject differences in global activity may obscure regional alterations in activity following cognitive stimulation. For each pixel in stereotactic space the ANCOVA generated a condition-specific, adjusted mean rCBF value (normalized to 50 ml/100 ml per min⁻¹) and an associated adjusted error variance. The ANCOVA allowed comparison of the means across two conditions (encoding/retrieval of word pair associates and reference condition) using *t*-statistics. The resulting map of *t*-values constituted a statistical parametric map (SPM_t) [19]. Pixels were identified as significantly activated if they passed the high threshold of *Z* = 3.09 and at least belonged to a cluster of 50 activated pixels.

3. Results

3.1. Memory performance

The pre-study training period resulted in a high overall recognition performance (85.9% ± 19.0). During the PET measurement recall after 24 presentations (depending on individual subject's performance) was 66.1% ± 21.1 correct so that scanning during the first retrieval of word pair associates was sufficient to capture the brain activity associated with retrieval. Post-hoc questioning of the subjects in this study indicated that most had used imagery when recalling the items in the episodic memory task.

3.2. Changes in rCBF

This study design allowed the assessment of differences in regional brain activity (measured as rCBF) between the encoding/retrieval and the reference task, representing relative increases or decreases in rCBF.

3.2.1. Encoding of word pairs compared with reference task

Increases in rCBF (Fig. 1). During encoding of word pairs, significant increases in rCBF were observed in primary visual and visual integration areas (Brodmann

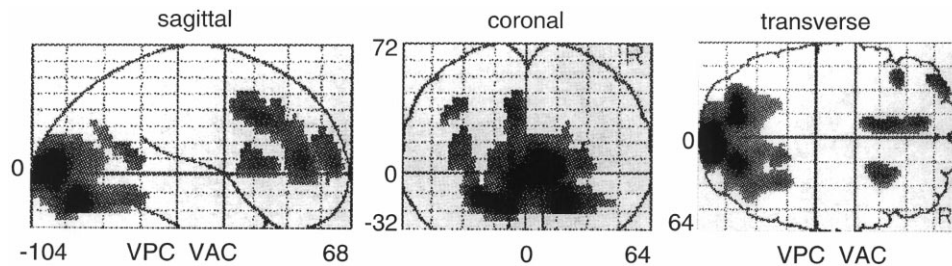


Fig. 1. Comparison of adjusted mean regional cerebral flow (rCBF) in thirteen subjects between encoding word pairs and reference. Spatial distributions of significant voxels are shown as integrated projections along sagittal, coronal and transverse views of the brain. (R, right)

areas 17/18, $Z = 5.72$), the anterior cingulate (BA 32/24, $Z = 3.95$), in the left dorsolateral prefrontal cortex (Brodmann areas 9/10, $Z = 3.43/3.32$) and the right frontal lobe (BA45, $Z = 3.61$) (Table 1).

Decreases in rCBF. Decreases of rCBF were observed in the left ($Z = 4.89$) and right ($Z = 5.09$) BA 44, the left middle and superior temporal gyri (Brodmann areas 21/22/41/42, $Z = 4.11$) and the right anterior cingulate (BA24, $Z = 4.64$).

3.2.2. Retrieval of word pair associates compared with reference task

Increases in rCBF (Fig. 2). Significant increases in blood flow comparing the retrieval of word pair associates to the reference condition were seen in the left ($Z = 4.88$) and the right ($Z = 4.54$) precuneus (Brodmann area 7), the visual integration area BA19 ($Z = 4.24$), in the cerebellum ($Z = 4.56$), right ($Z = 3.86$) and left ($Z = 4.02$) prefrontal cortex and the anterior cingulate (BA 32, $Z = 3.29$) (Table 1).

Decreases in rCBF. Significant reduction in rCBF was seen bilaterally in the left ($Z = 5.89$) and right ($Z = 4.11$) middle and superior temporal gyri (Brodmann areas 21/22/41/42).

4. Discussion

The main finding of the present study is a functional distinction of an asymmetric network of brain structures subserving encoding and retrieval of visually presented paired word associates. During episodic memory encoding, an activation in the left prefrontal structures was observed and by contrast, during retrieval of word pair associates a bilateral prefrontal activation. Furthermore, the importance of the precuneus in the recall of highly imaginable word pair associates using visual imagery as a mnemonic strategy was demonstrated.

4.1. Anatomical and functional correlates of observed changes in rCBF

4.1.1. Dorsolateral prefrontal cortex

The present findings of prefrontal activity in the

storage and retrieval of declarative information are in agreement with existing data from animals and humans [5,21,23,25,64,72,73] and with neuropsychological studies of brain damaged patients [37,38,53,80]. Taken together, the results of the studies point to a crucial role of prefrontal cortex in episodic memory.

A major finding from previous functional imaging studies is the evidence for a hemispheric prefrontal memory encoding/retrieval neuronal representation. Despite the use of markedly differing tasks, modalities (e.g. visual, aural, olfactory) and conditions (verbal and non-verbal) episodic encoding involved a left prefrontal activation; in contrast, retrieval was associated with an exclusively right or right greater than left activation in the prefrontal cortex [16,17,20,22,26,31,32,45,46,60,64,72,73].

In this present study, results showed significant left prefrontal activation during encoding and a bilateral, predominantly right activation during episodic memory retrieval of word pair associates. In agreement with previous studies which reported an exclusively left prefrontal activation associated with episodic memory encoding [20,26,31,45,46,84,60] the present results also indicate left prefrontal activity during verbal encoding.

The present findings are consistent with previous reports showing bilateral activation during retrieval [5,26,32,64,72,73]. In the study by Buckner et al. [5] subjects were presented with a series of words a few minutes before scanning. Thereafter, they were shown three-letter word stems and required to complete these in order to form the same words they had seen earlier. Results showed a predominantly right prefrontal activation, but also a left prefrontal activation in association with the declarative recall condition when compared to a baseline condition. The prefrontal regions comprised the right anterior prefrontal cortex (Brodmann area 10), three regions in the right dorsolateral prefrontal cortex (Brodmann areas 8 and 9) and one region in the left dorsolateral prefrontal cortex (Brodmann area 8). Interestingly, prefrontal activation was not found during a procedural priming task which did not require conscious recall of the words studied earlier. Kapur et al. [32] reported a predominantly right but also left prefrontal activation in a verbal memory

Table 1

The stereotactic coordinates of maximal activations and inhibitions for encoding (a) and retrieval (b) of word pairs

(a) Encoding of word pairs compared to reference condition

Increases in rCBF

Stereotactic coordinate

x	y	z	Z value	BA	Region	rCBF change (%)	Cluster size
10	-96	4	5.72	17/18	Occipital cortex, left and right	6.2	3161
-8	10	36	3.95	32/24	Frontal (medial) anterior cingulate, left	4.5	463
-36	54	12	3.43	10	Frontal (lateral), left	4.9	122
-36	28	36	3.32	9	Frontal (lateral), left	4.0	51
26	14	8	3.61	45	Frontal (lateral), right	4.3	181

Decreases in rCBF

-36	-6	16	4.89	44	Frontal (lateral), left	6.5	1547
46	2	20	5.09	44	Frontal (lateral), right	4.9	2242
50	-42	-6	4.11	21, 22, 41, 42	Middle and superior temporal gyri, right	5.3	
14	-6	40	4.64	24	Frontal (medial) anteriorcingulate, right	6.0	969

(b) Retrieval of word-pair associates compared to reference condition

Increases in

rCBF

-10	-74	32	4.88	7	Precuneus, left	5.2	2968
12	-64	-20	4.56		Cerebellum	5.5	
16	-74	28	4.54	7	Precuneus, right	4.5	
0	-60	4	4.24	19	Occipital cortex	3.9	
-10	42	4	4.02	10	Frontal (lateral), left	4.8	995
20	46	0	3.86	10	Frontal (lateral), right	4.9	
4	34	20	3.29	32	Frontal (medial) anterior cingulate, right	3.3	

Decreases in rCBF

-40	-4	4	5.79	21, 22, 41, 42	Middle end superior temporal gyri, left	6.0	3305
44	-6	4	4.11	21, 22, 41, 42	Middle and superior temporal gyri, right	4.0	598

Co-ordinates are according to the atlas of Talairach and Tournoux [67], areas are named after Brodmann (BA).

The pixels show levels of significance above a threshold of $P < 0.001$ (omnibus).

retrieval task. The authors concluded that the activation of the prefrontal cortex was related to the attempt to retrieve the mnemonic information and not to their successful retrieval of the stored information. In keeping in line with this interpretation, neuropsychological findings suggest that the prefrontal structures are involved in the temporal organization [21,47], strategic processing [38] and the organization of search and selective attention [48,59]—functions compatible with an interpretation of retrieval attempt as put forward by Kapur et al. [32]. Most recently, Rees et al. [48] examined the attentional modulation of cortical activity by varying the rate of visual stimuli in object categorization tasks according to single and conjoined features. The subjects were requested to categorize serially presented single visual targets by individual features (color

or orientation) or the conjunction of color and orientation at four different rates of presentation during a series of PET regional cerebral blood flow scans. The results indicate an activation of prefrontal cortex that was elicited by the subject's attention to conjoined as compared with single features. This activation was independent of the stimulus presentation.

4.1.2. Precuneus

Significant increases in rCBF occurred in the left and right precuneus during retrieval of word pair associates. Fiez et al. [15] failed to find an activation in the inferior parietal cortex during the maintenance of a verbal information task. Subjects were instructed to retain five related words, unrelated words or pseudowords for the duration of a 40 s PET scan. In contrast to the present

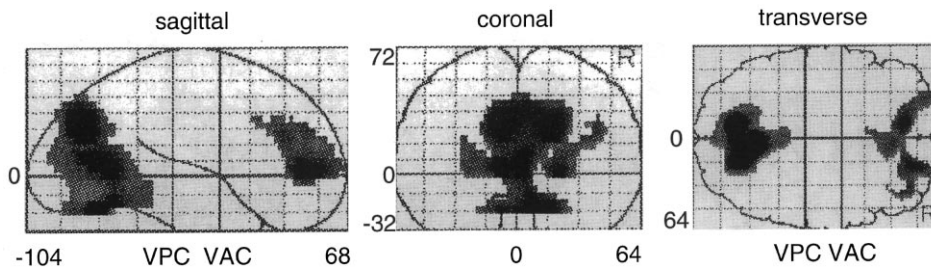


Fig. 2. Comparison of adjusted mean regional cerebral flow (rCBF) in thirteen subjects between retrieving word pair associates and reference. Spatial distributions of significant voxels are shown as integrated projections along sagittal, coronal and transverse views of the brain. (R, right)

study, in the design of Fiez et al. [15] the encoding and retrieval of information was minimized. These findings support the hypothesis that inferior parietal cortex plays a specific role in aspects of stimulus encoding and retrieval whereas it does not appear to be generally involved in phonological processing.

It has been shown in studies with auditory stimulus presentation that imaginability of paired associates affects the activity in the precuneus [16,17]. In this present design, word-pair associates that were highly imaginable were chosen and presented visually. The use of mnemonic devices that involve a high degree of imaginability is an effective strategy in the storage and retrieval of associative memory tasks; this has been called 'imaginal memory' [43]. It is known that the use of visual imagery in connecting arbitrary events can dramatically improve performance [42]. There is evidence from regional cerebral blood flow studies using PET that the precuneus in the medial parietal cortex is crucially involved in associating highly imaginable events [16,17,60]. These present findings are in agreement with the results of Fletcher et al. [16,17] and Shallice et al. [60] who reported a significant activation of the right precuneus during the retrieval of auditorily presented word-pair associates. Interestingly, the activation in the precuneus was most pronounced in those retrieval tasks which require a high degree of imagery associated with the recall condition. In terms of this interpretation further studies are needed to clarify the exact nature of the imaginability factors in memory control.

4.1.3. Temporal cortex

There is neuropsychological evidence for the importance of the temporal lobe structures in memory function [3,12,36,44,65]. Earlier, the whole medial-temporal region has been implicated to be crucially involved in declarative or explicit memory functioning. But most recently functional magnetic resonance imaging (fMRI) has been successfully applied in disentangling the functional role of separate areas in the temporal lobe system during encoding and retrieval of declarative information. Gabrieli et al. [22] reported significant activation in the medial temporal lobe system with fMRI. Their

results indicate that within the temporal lobe system, separate components are active during encoding and retrieval of visually presented scenes and words. During the encoding task, subjects were shown color pictures of indoor and outdoor scenes and line drawings; they were instructed to remember the pictures for a later memory test. In one condition, novel pictures were presented for the first time, in another condition, familiar scenes were shown repeatedly. During the retrieval task, subjects saw words in two conditions; (i) most of the words were the names of previously presented drawings, (ii) most of the words were the names of other drawings which were not shown earlier. Results indicate activations in posterior sections focused in the parahippocampal cortex during the encoding task that were greater for novel than for repeated visual scenes. In contrast, retrieval tasks yielded increased signals for successfully remembered information in an anterior medial temporal lobe region that were centered in the subiculum.

In this present study, a relative reduction of cortical activity in superior temporal and peri-auditory regions during encoding and retrieval was reported. Deactivation in the left temporal lobe was more prominent and is in agreement with other findings showing reduction of rCBF [26,72]. The activity decrease in superior temporal and peri-auditory regions are in line with the assumed involvement of these regions in auditory perception and in language comprehension. Some of these decreases may reflect auditory priming. Because of the subjects prior exposure to the words, neural computational requirements for identification and comprehension of these sentences were diminished in comparison with new sentences. Thus, blood flow decreases in bilateral temporal regions may partially mark neuronal substrates of auditory priming. The relative reduction in this area reflects a decrease in rCBF in the encoding/retrieval condition over the reference condition. Relative reductions of rCBF in these regions have been observed during verbal fluency tasks [78]. These verbal fluency findings with PET can be modeled by a set of regions for word generation in which the efficient production of intrinsically generated word lists was associated with a reduction of neuronal activity of primary auditory areas.

4.1.4. Hippocampal region

Hippocampal functioning has been strongly associated with novelty detection [34,54,66]. Taken together, the results of studies using PET, fMRI and event-related potentials, indicate that especially the right and the more posterior hippocampal and parahippocampal structures are engaged in responding to novel events. Furthermore, it has been argued that the hippocampus plays a more crucial role in memory encoding and consolidation than in retrieval [35,63]. However, there is a considerable degree of confusion about the central question of whether task-associated activation in the hippocampal region and in the temporal lobe structures can be detected by PET. The present study did not show any temporal lobe or hippocampal activation associated with either the encoding or retrieval conditions. This is in agreement with the studies by Fletcher et al. [16,17] and by Grasby et al. [26] who failed to find an activation in these regions. In a series of declarative and procedural learning experiments Buckner et al. [5] failed to show activation in the medial temporal lobe, though in one experiment (declarative memory retrieval) the authors observed an activation in the right hippocampal/parahippocampal region.

Several reasons could account for the failure of a hippocampal and/or temporal activation in the current study; (1) the failure may reflect continual activity in these regions such that a cognitive subtraction technique would show no relative increase in activity during the memory task [16,17], (2) memory-task associated activations may be of a magnitude outside the sensitivity of PET [50]. The presence of the activation of certain cell assemblies may be associated with a decreased activity in other, contiguous cell populations, so that on the basis of the limited spatial and even poorer temporal resolution provided by PET, there is no detectable relative change in overall activity. (1) In contrast, other authors reported an activation in the hippocampal/parahippocampal region [32,39,41,49, 54,64]. Nyberg et al. [39] reported that retrieval performance of individual subjects is correlated with changes in blood flow in the hippocampal regions. (2) Most recently, Tulving and Markowitsch [74] analyzed some crucial evidence available on the cortical regions that are differentially active in encoding and retrieval by pooling data from different studies together in a meta-analysis. The authors came to the conclusion that brain regions more active during encoding than retrieval included bilateral temporal lobes, left fusiform gyrus extending to the perirhinal cortex, right parahippocampal gyrus and bilateral entorhinal cortex. In contrast, the brain regions more active during the retrieval than during encoding included the right frontal lobe, anterior cingulate cortex, thalamus, brainstem and precuneus/cuneus.

Other authors reported a right medial temporal lobe activation in tasks without obvious declarative memory components [11,57].

It is important to remember that what is measured in human brain imaging experiments using PET is not neural activity but local hemodynamic changes. Even with fMRI which provides better resolution than PET, one is still dealing with signals that have latencies of 4 to 8 s and a spatial resolution of about 2 mm [75]. Taken together, there is at present a large degree of uncertainty over the central question in which tasks hippocampal and/or temporal lobe activation can be measured by PET and if present, whether the blood flow changes are actually causally related to declarative memory performance or other subprocesses, such as attention [68] and emotion [7,8].

4.1.5. Interhemispheric activations

A significant finding of the present investigation is that bilateral activity patterns are observed during retrieval phases with predominance for activity in the non-dominant hemisphere in the prefrontal structures and the precuneus. These findings are in agreement with neuroanatomical results which show a high degree of interconnectivity between the two hemispheres. Innocenti [29], Selemon and Goldman-Rakic [56] have reported dense interhemispheric connections of the prefrontal cortex with its homotopic counterpart. Cavada [9] and Goldman Rakic [10] examined the cortico-cortical and cortico-subcortical connections of four cytoarchitectonic subdivisions of the posterior parietal cortex in rhesus monkeys. The results indicate that each parietal subdivision is heavily interconnected with areas of the contralateral hemisphere, including both the homotopic cortex and widespread heterotopic areas. The contralateral labeling was remarkable for its extent: each area was found to be interconnected with as many areas of the contralateral hemisphere as within the ipsilateral one. The location and the density of the contralateral labeling followed that in the ipsilateral hemisphere, though less intensively [9,10].

It was shown that the dorsolateral prefrontal cortex is interconnected with more than a dozen of the same areas with which the posterior parietal cortex is connected; common cortical targets of the dorsolateral prefrontal and posterior parietal cortices are depicted in the orbitofrontal cortex, premotor areas, the supplementary motor areas, the frontal eye-fields, the anterior and posterior cingulate cortices, the fronto-parietal operculum, the insula, the superior temporal sulcus, the medial parietal cortex, the parahippocampal and pre-subicular cortices, the caudomedial lobule and the medial prestriate cortex [56]. In addition, both the dorsolateral prefrontal cortex and the parietal cortex share many subcortical targets in the claustrum, amygdala, thalamus, striatum, superior colliculus and pon-

tine reticular formation [56]. Other evidence indicates that many of the areas connected with the parietal and prefrontal cortices receive input from cell clusters within the medial pulvinar thalamus [1,6,33,85].

The present findings are in agreement with the view that interhemispheric interactions play a decisive role in the encoding and retrieval of declarative information. One may argue that within the parietal and prefrontal cortices each subdivision should be considered as part of an expanded cortico-cortical and corticosubcortical network, whose functional characteristics are determined by the specific nodal points of the network, whereby the components of each network are usually strongly interconnected [9,10].

Interhemispheric communication also plays a crucial role in procedural memory. In a previous study it was reported that interhemispheric communications are of key importance in motor learning and intermanual transfer of training [69]. The results obtained from this study indicate that it is the dorsolateral prefrontal cortex, an area which has dense interhemispheric connections with its homotopic counterpart [29,56] in which changes in neural activity and intermanual training transfer of trajectory learning were related. Taken together, the findings from this study are in line with the view that interhemispheric interactions play a crucial role in both, declarative and procedural learning tasks.

Acknowledgements

We wish to thank J. Shah for his useful comments in preparing the manuscript.

References

- [1] Asanuma C, Andersen RA, Cowan WM. The thalamic relations of the caudal inferior parietal lobule and the lateral prefrontal cortex in monkeys: divergent cortical projections from cell clusters in the medial pulvinar nucleus. *J Comp Neurol* 1985;241:357–81.
- [2] Baddeley AD. *Human Memory: Theory and Practice*. Boston: Allyn and Bacon, 1990.
- [3] Blakemore C. *Mechanics of the Mind*. Cambridge: Cambridge University Press, 1977.
- [4] Blaxton TA, Bookheimer SY, Zeffiro TA, Figliozzi CM, Gaillard WD, Theodore WH. Functional mapping of human memory using PET: comparisons of conceptual and perceptual tasks. *Can J Exp Psychol* 1996;50(1):42–56.
- [5] Buckner RL, Peterson SE, Ojemann JG, Miezin FM, Squire LR, Raichle ME. Functional anatomical studies of explicit and implicit memory retrieval tasks. *J Neurosci* 1995;15(1):12–29.
- [6] Burton H, Jones EG. The posterior thalamic region and its cortical projection in New World and Old World monkeys. *J Comp Neurol* 1976;168(2):249–301.
- [7] Cahill L, Babinsky R, Markowitsch HJ, McGaugh JL. Involvement of the amygdaloid complex in emotional memory. *Nature* 1995;377:295–6.
- [8] Cahill L, Haier RJ, Fallon J, Alkire MT, Tang C, Keator D, Wu J, McGaugh JL. Amygdala activity at encoding correlated with long-term, free recall of emotional information. *Proc Natl Acad Sci USA* 1996;93:8016–21.
- [9] Cavada C, Goldman-Rakic PS. Posterior parietal cortex in rhesus monkey: I. Parcellation of areas based on distinctive limbic and sensory corticocortical connections. *J Comp Neurol* 1989;287:393–421.
- [10] Cavada C, Goldman-Rakic PS. Posterior parietal cortex in rhesus monkey: II. evidence for segregated corticocortical networks linking sensory and limbic areas with the frontal lobe. *J Comp Neurol* 1989;287:422–45.
- [11] Corbetta M, Miezin FM, Dobmeyer S, Shulman GL, Petersen SE. Selective and divided attention during visual discrimination of shape, color and speed: functional anatomy by positron emission tomography. *J Neurosci* 1991;11:2383–404.
- [12] Corkin S. Acquisition of motor skills after bilateral medial temporal lobe excision. *Neuropsychologia* 1968;6:255–65.
- [13] Corkin S. Lasting consequences of bilateral medial temporal lobectomy: clinical course and experimental findings in H.M. *Semin Neurol* 1984;4:249–59.
- [14] Fazio F, Perani D, Gilardi MC, et al. Metabolic impairment in human amnesia: a PET study of memory networks. *J Cereb Blood Flow Metab* 1992;12:353–8.
- [15] Fiez JA, Ralfe EA, Balota DA, Schwarz JP, Raichle ME, Petersen SE. A positron emission tomography study of the short-term maintenance of verbal information. *J Neurosci* 1996;16(2):808–22.
- [16] Fletcher PC, Dolan RJ, Frith CD. The functional anatomy of memory. *Experientia* 1995;51:197–207.
- [17] Fletcher PC, Frith CD, Grasby PM, Shallice T, Frackowiak RSJ, Dolan RJ. Brain systems for encoding and retrieval of auditory verbal memory: an in vivo study in humans. *Brain* 1995;118:401–16.
- [18] Friston KJ, Ashburner J, Frith CD, Poline J-B, Heather JD, Frackowiak RSJ. Spatial registration and normalization of images. *Hum Brain Mapp* 1995;2:165–89.
- [19] Friston KJ, Holmes AP, Worsley KJ, Poline J-B, Frith CD, Frackowiak RSJ. Statistical parametric mapping in functional imaging: a general linear approach. *Hum Brain Mapp* 1995;2:189–210.
- [20] Frith CD, Friston KJ, Liddle PF, Frackowiak RSJ. A PET study of word finding. *Neuropsychologia* 1991;29:1137–48.
- [21] Fuster JM. *Memory in the Cerebral Cortex*. Cambridge, MA: MIT Press, 1995.
- [22] Gabrieli JDE, Brewer JB, Desmond JE, Glover GH. Separate neural bases of two fundamental memory processes in the human medial temporal lobe. *Science* 1997;276:264–6.
- [23] Goldman-Rakic PS. Circuitry of primate prefrontal cortex and regulation of behaviour by representational memory. In: Mountcastle VB, editor. *Handbook of Physiology*, vol. 5. Bethesda, MD: American Physiological Society, 1987:373–417.
- [24] Goldman-Rakic PS, Friedman HR. The circuitry of working memory revealed by anatomy and metabolic imaging. In: Levin HS, Eisenberg HM, Benton AL, editors. *Frontal Lobe Function and Dysfunction*. Oxford: Oxford University Press, 1991:72–91.
- [25] Goldman-Rakic PS. The anatomy of dopamine in monkey and human prefrontal cortex. *J Neural Transm Suppl* 1992;36:163–77.
- [26] Grasby PM, Frith CD, Friston KJ, Bench C, Frackowiak RSJ, Dolan RJ. Functional mapping of brain areas implicated in auditory-verbal memory function. *Brain* 1993;116:1–20.
- [27] Halsband U, Freund H-J. Premotor cortex and conditional motor learning in man. *Brain* 1990;113:207–22.
- [28] Herzog H, Seitz RJ, Tellmann L, et al. Quantitation of regional cerebral blood flow with O-15-butanol and positron emission tomography in humans. *J Cereb Blood Flow Metab* 1996;16:645–9.

- [29] Innocenti GM. Some new trends in the study of the corpus callosum. *Behav Brain Res* 1994;64:1–8.
- [30] Johnson NF, Carnot MJ. On time differences in searching for letters in words and nonwords: do they emerge during the initial encoding on the subsequent scan? *Mem Cogn* 1990;18:3139.
- [31] Kapur S, Craik FIM, Tulving E, Wilson A, Houle S. Neuroanatomical correlates of encoding in episodic memory: levels of processing effort. *Proc Natl Acad Sci USA* 1994;91:2008–11.
- [32] Kapur S, Craik FIM, Jones C, Brown GM, Houle S, Tulving E. Functional role of the prefrontal cortex in retrieval of memories: a PET study. *Neuro Rep* 1995;6:1880–4.
- [33] Kievit J, Kuypers HG. Organization of the thalamo-cortical connections to the frontal lobe in the rhesus monkey. *Exp Brain Res* 1977;29(34):299–322.
- [34] Knight RT. Contribution of human hippocampal region to novelty detection. *Nature* 1996;383:256–9.
- [35] Kroll NE, Knight RT, Metcalfe J, Wolf ES, Tulving E. Cohesion failure as a source of memory illusions. *J Mem Lang* 1996;3:176–96.
- [36] Milner B. Brain mechanisms suggested by studies of temporal lobes. In: Darley FL, editor. *Brain mechanisms Underlying Speech and Language*. New York: Grune and Stratton, 1967.
- [37] Milner B, Petrides M, Schmidt ML. Frontal lobes and the temporal organization of memory. *Hum Neurobiol* 1985;4:137–42.
- [38] Moscovitch M. Memory and working-with-memory: a component process model based on modules and central systems. *J Cognit Neurosci* 1992;4:257–67.
- [39] Nyberg L, McIntosh AR, Houle S, Nilsson LG, Tulving E. Activation of medial temporal structures during episodic memory retrieval. *Nature* 1996;380:715–7.
- [40] Nyberg L, Cabeza R, Tulving E. PET studies of encoding and retrieval: the HERA model. *Psychon Bull Rev* 1996;3(2):135–48.
- [41] Owen AM, Milner B, Petrides M, Evans AC. Memory for object features versus memory for object location: a positron emission tomography study of encoding and retrieval processes. *Proc Natl Acad Sci USA* 1996;93:9212–7.
- [42] Paivio A, Yuille JC, Smythe PC. Stimulus and response abstractness, imagery and meaningfulness and reported mediators in paired-associate learning. *Can J Psychol* 1966;20:362–77.
- [43] Paulesu E, Frith CD, Frackowiak RSJ. The neural correlates of the verbal component of memory. *Nature* 1993;362:342–5.
- [44] Penfield W, Milner B. Memory deficit produced by bilateral lesions in the hippocampal zone. *Arch Neurol Psychiat* 1958;79:475–97.
- [45] Petersen SE, Fox PT, Posner MI, Mintun M, Raichle ME. Positron emission tomographic studies of the cortical anatomy of single-word processing. *Nature* 1988;331:585–9.
- [46] Petersen SE, Fox PT, Snyder AZ, Raichle ME. Activation of extrastriate and frontal cortical areas by visual words and word-like stimuli. *Science* 1990;249:1041–4.
- [47] Petrides M. Frontal lobes and memory. In: Boller F, Grafman J, editors. *Handbook of Neuropsychology*, vol. 3. Amsterdam: Elsevier, 1989:75–90.
- [48] Rees G, Frackowiak RSJ, Frith C. Two modulatory effects of attention that mediate object categorization in human cortex. *Science* 1997;275:835–8.
- [49] Roland PE, Gulyas B. Visual memory, visual imagery and visual recognition of large field patterns by the human brain: functional anatomy by positron emission tomography. *Cereb Cortex* 1995;5:79–93.
- [50] Rolls ET, Treves A. The relative advantage of sparse versus distributed encoding for associative neuronal networks in the brain. *Network* 1990;1:53–6.
- [51] Rota Kops E, Herzog H, Schmid A, Holte S, Feinendegen L. Performance characteristics of an eight-ring whole body PET scanner. *J Comp Ass Tomogr* 1990;14(3):437–45.
- [52] Rudge P, Warrington EK. Selective impairment of memory and visual perception in splenic tumours. *Brain* 1991;114:249–360.
- [53] Schacter DL. Memory, amnesia and frontal lobe dysfunction. *Psychobiology* 1987;15:21–36.
- [54] Schacter DL, Alpert NM, Savage CR, Rauch SL, Albert MS. Conscious recollection and the human hippocampal formation: evidence from positron emission tomography. *Proc Natl Acad Sci USA* 1996;93:321–5.
- [55] Scoville WB, Milner B. Loss of recent memory after bilateral hippocampal lesions. *J Neurol Neurosurg Psychiatry* 1957;20:11–21.
- [56] Selemon LD, Goldman-Rakic PS. Common cortical and subcortical targets of the dorsolateral prefrontal and posterior parietal cortices in the rhesus monkey: evidence for a distributed neural network subserving spatially guided behaviour. *J Neurosci* 1988;8(11):4049–68.
- [57] Sergent J, Ohta S, MacDonald B. Functional neuroanatomy of face and object processing. *Brain* 1992;115:15–36.
- [58] Shallice T, Warrington EK. Independent functioning of verbal memory stores: a neuropsychological study. *Q J Exp Psychol* 1970;22:261–73.
- [59] Shallice T. *From Neuropsychology to Mental Structure*. Cambridge: Cambridge University Press, 1988.
- [60] Shallice T, Fletcher P, Frith CD, Grasby P, Frackowiak RSJ, Dolan RJ. Brain regions associated with acquisition and retrieval of verbal episodic memory. *Nature* 1994;368:633–5.
- [61] Squire LR. Mechanisms of memory. *Science* 1986;232:1612–9.
- [62] Squire LR. *Memory and Brain*. New York: Oxford University Press, 1987.
- [63] Squire LR, Zola-Morgan. The medial temporal lobe memory system. *Science*, 1991;253:1380–1386
- [64] Squire LR, Ojeman JG, Miezin FM, Peterson SE, Videen TO, Raichle ME. Activation of the hippocampus in normal humans: a functional anatomical study of memory. *Proc Natl Acad Sci USA* 1992;89:1837–41.
- [65] Starr A, Philipps L. Verbal and motor memory in the amnesic syndrome. *Neuropsychologia* 1970;8:75–88.
- [66] Stern CE, Corkin S, Gonzales RG, et al. The hippocampal formation participates in novel picture encoding: evidence from functional magnetic resonance imaging. *Proc Natl Acad Sci USA* 1996;93:8660–5.
- [67] Talairach J, Tournoux P. *Co-planar stereotaxic atlas of the human brain. 3-Dimensional Proportional System: An Approach to Cerebral Imaging*. Stuttgart: Thieme, 1988.
- [68] Tesche CD, Karhu J, Tissari SO. Non-invasive detection of neuronal population activity in human hippocampus. *Cogn Brain Res* 1996;4:3947.
- [69] Thut G, Halsband U, Roelcke U, Nienhusmeier M, Missimer J, Maguire RP, Regard M, Landis T, Leenders KL. Intermanual transfer of training: blood flow correlates in the human brain. *Behav Brain Res* 1997;89:129–34.
- [70] Tulving E. Multiple memory systems and consciousness. *Hum Neurobiol* 1987;6:67.
- [71] Tulving E. Concepts of human memory. In: Squire L, Lynch G, Weinberger NM, McGaugh JL, editors. *Memory: Organization and Locus of Change*. New York: Oxford University Press, 1991:3–32.
- [72] Tulving E, Kapur S, Markowitsch HJ, Craik FIM, Habib R, Houle S. Neuroanatomical correlates of retrieval in episodic memory: auditory sentence recognition. *Proc Natl Acad Sci USA* 1994;91:2012–5.
- [73] Tulving E, Kapur S, Craik FIM, Markowitsch HJ, Houle S. Hemispheric encoding/retrieval asymmetry in episodic memory: positron emission tomography findings. *Proc Natl Acad Sci USA* 1994;91:2016–20.
- [74] Tulving E, Markowitsch HJ. Memory beyond the hippocampus. *Curr Opin Neurobiol* 1997;7:209–16.

- [75] Ungerleider LG. Functional brain imaging studies of cortical mechanisms for memory. *Science* 1995;270:769–75.
- [76] Valenstein E, Bowers D, Verfaellie M, Heilman KM, Day A, Watson RT. Retrosplenial amnesia. *Brain* 1987;110:1631–46.
- [77] von Cramon DY, Hebel N, Schuri U. A contribution to the anatomical basis of thalamic amnesia. *Brain* 1985;108:993–1008.
- [78] Warkentin S, Nilsson A, Risberg J, Karlson S. Absence of frontal lobe activation in schizophrenia. *J Cereb Blood Flow Metab* 1989;9:354.
- [79] Warrington EK. The selective impairment of semantic memory. *Q J Exp Psychol* 1975;27:635–57.
- [80] Warrington EK, Weiskrantz L. Amnesia: a disconnection syndrome? *Neuropsychologica* 1982;20:233–49.
- [81] Wechsler D. A standardized memory scale for clinical use. *J Psychol* 1945;19:87–95.
- [82] Weiskrantz L. Neuroanatomy of memory and amnesia: a case for multiple memory systems. *Hum Neurobiol* 1987;6:93–105.
- [83] Weiskrantz L. Problems of learning and memory: one or multiple memory systems? *Philos Trans R Soc Lond (Biol)* 1990;329:99–108.
- [84] Wise R, Chollet F, Hadar U, Friston K, Hoffner E, Frackowiak RJS. Distribution of cortical neural networks involved in word comprehension and word retrieval. *Brain* 1991;114:1803–17.
- [85] Yetarian EH, Pandya DN. Corticothalamic connection of the posterior parietal cortex in the rhesus monkey. *J Comp Neurol* 1985;237:408–26.