

CASE REPORT

Strongyloides stercoralis: a rare and severe presentation in a pregnant woman

Antonio Beltrán Rosel¹, Isabel Sanjoaquin Conde², Ana Pérez Muñoz³, Purificación Mateo Alcalá³, Carlo B. Marta⁴, Alvaro Irigoyen von Sierakowski⁵

¹Department of Microbiology, Lozano Blesa University Hospital. Zaragoza, Spain;

²Department of Infectious Diseases, Lozano Blesa University Hospital. Zaragoza, Spain;

³Department of Obstetrics and Gynecology, Lozano Blesa University Hospital. Zaragoza, Spain;

⁴Department of Pathology, Lozano Blesa University Hospital. Zaragoza, Spain;

⁵Department of Family and Community Medicine, Corralejo Health Center, Las Palmas, Spain

SUMMARY

Strongyloides stercoralis is a parasitic nematode with a worldwide distribution. It can go from an asymptomatic infection to a life-threatening hyperinfection syndrome. Here, we report a case of intestinal obstruction due to *S. stercoralis* in a pregnant woman. This condition, as well as severe strongyloidiasis in pregnant women, is seldomly reported. In this case, Human T-lymphotropic Virus 1 (HTLV-1) coinfection was confirmed, a well-known risk factor for a more severe presentation of strongyloidiasis. We suggest that HTLV status should be screened in every severe *S. stercoralis* infection, or when, despite a correct treatment, a relapse is observed.

Received April 9, 2019

Accepted November 9, 2019

CASE REPORT

A 23-year-old primigravid Colombian woman in her 21st week of pregnancy presented with acute abdominal pain and oral intolerance. She had arrived to Spain two months before, worked as a saleswoman, and did not report any contact with toxic substances.

At admission, she showed a poor general condition, weight loss (BMI 16), dehydration, low-grade fever, and diffuse abdominal pain with tenderness. Laboratory tests showed an elevated white cell count (16×10^9 cells/L), hemoglobin of 11.3 g/dL, normal eosinophil count, and an elevated C-reactive protein. Abdominal ultrasound revealed no pathological findings. Stool and blood cultures were negative. Due to the worsening clinical situation and constant weight loss, a nasogastric tube was inserted.

Further laboratory findings showed a positive fecal occult blood test, and negative serology tests for *Toxoplasma gondii*, Rubella, Measles, EBV, Syphilis, HIV, and hepatitis. These findings led to the performance of an oral endoscopy, which showed ulcers with mild spontaneous bleeding in the second half of the duodenum and progressive narrowing of the lumen. The histopathological examination of the duodenal biopsy revealed larvae compatible with a parasitic infection: there was presence of several stages of the worm embedded in mucosal crypts (Figure 1). Additional findings included villous flattening, crypt hyperplasia,

and an inflammatory reaction consisting of lymphocytes, plasma cells, and eosinophils.

A stool examination (formalin-ethyl acetate technique) revealed both Charcot-Leyden crystals and a huge number of rhabditoid (but not filariform) larvae of *Strongyloides stercoralis*. Unusually, eggs were also detected (Figure 2). Despite the parasite burden, the eosinophil count remained within normal limits, so we decided to check the HTLV status. After a positive Enzyme-Linked Immunosorbent Assay (ELISA) screening test, an HTLV-I infection was confirmed by Line Immunoassay (LIA).

Therapy with oral ivermectin was initiated with a dose of 200 µg/kg/day for two days, with resolution of the digestive symptoms and resumed oral tolerance. Another fecal sample was submitted just prior to delivery and, again, a very high load of rhabditoid larvae was detected, which led to the prescription of another course of ivermectin. Finally, the patient underwent a normal vaginal birth and, a month later both mother and child were parasite-free (tested by PCR).

DISCUSSION

The patient presented with intestinal obstruction due to *S. stercoralis*. This condition, as well as severe strongyloidiasis in pregnant women, is seldom reported.

This parasite has a complex life cycle consisting of a free-living and a parasitic cycle. In both cycles, the parasite reaches the intestinal tract, where the adult female lives and reproduces. The larvae can either be passed in the stool or cause autoinfection. *S. stercoralis* is known to be one of the only two helminths with this ability, where the infective larvae can penetrate the mucosa or the perianal skin and reach any other tissue (Page *et al.*, 2018).

Key words:

Strongyloides stercoralis, Strongyloidiasis, Pregnancy, HTLV, Intestinal obstruction.

Corresponding author:

Antonio Beltrán Rosel

E-mail: abeltranros@salud.aragon.es

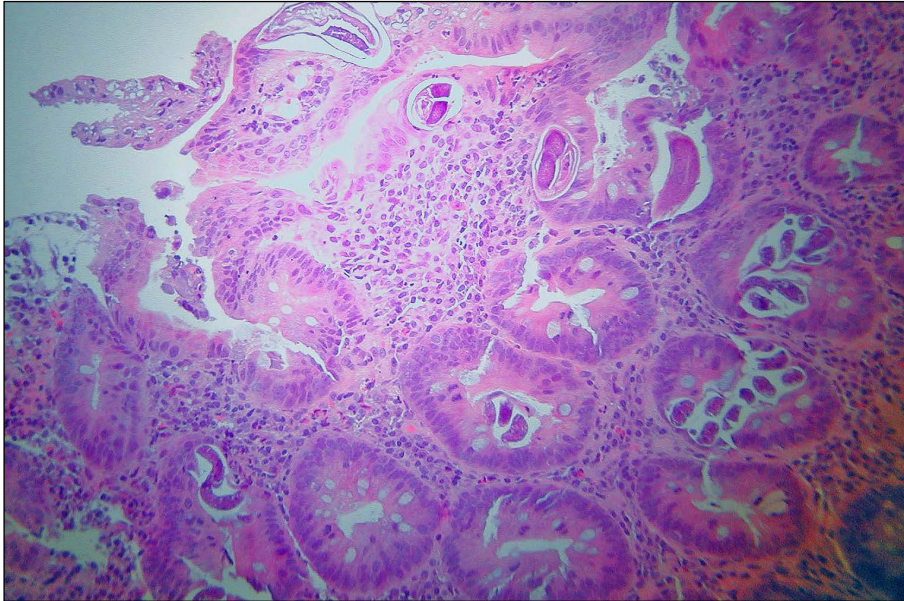


Figure 1 - Histological section of duodenum showing three adult females and numerous larvae.

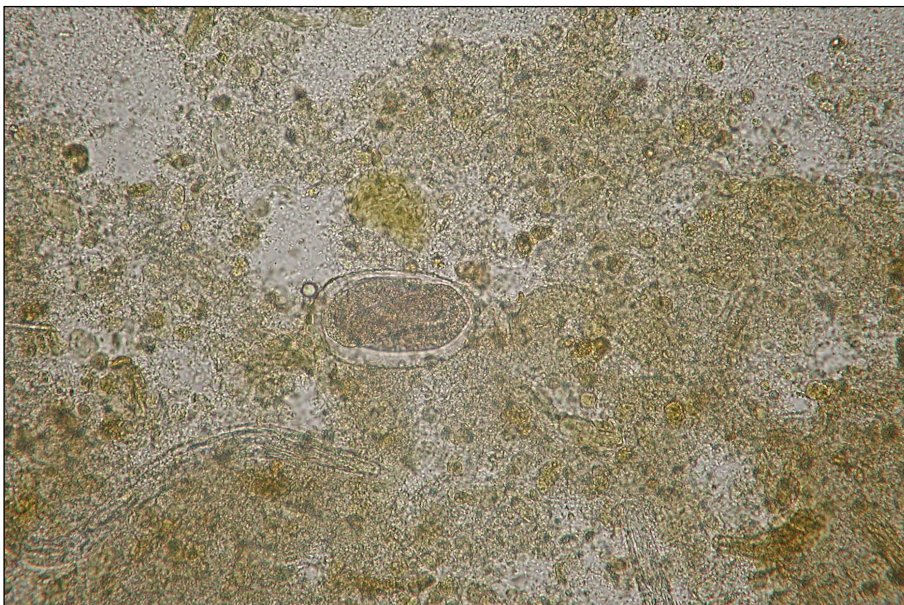


Figure 2 - Microscopy image of a well-developed larva inside an egg.

Strongyloidiasis is endemic in tropical and subtropical regions but can also be found in non-endemic areas due to increases in travelling and migration (Montes *et al.*, 2010). In some cases, the infection can evolve to a hyperinfection syndrome due to an increase in the larvae burden in the traditional reproductive route (skin, gut, and lungs), or can cause a disseminated infection (when larvae are found outside this route, e.g., heart, liver, central nervous system). The risk of suffering from this severe form of the illness is increased in immunosuppressed patients, such as those under corticosteroid treatment or with positive HIV or HTLV-I status (Schär *et al.*, 2013).

In our case, the histopathological results of the biopsies pointed to the final diagnosis. Finding a prominent eosinophilic infiltrate and Charcot-Leyden crystals should prompt a search for parasitic infestation. The small intes-

tine is the most commonly affected site, but in rare cases the stomach and colon can also be involved (Montgomery and Voltaggio, 2012).

Previously, Malézieux-Picard (2017) reported a similar case in a pregnant woman (Malézieux-Picard *et al.*, 2017). Nevertheless, pregnancy alone does not seem to be the major cause, since only very few reports of intestinal obstruction due to *S. stercoralis* in pregnant women have been published and pregnancy has not been described as a risk factor for severe strongyloidiasis. Thus, we speculate that the underlying HTLV infection was the only trigger in our case. Indeed, the clinical condition of our patient dramatically improved once the anthelmintic therapy began.

Oral ivermectin remains the treatment of choice for strongyloidiasis (Nutman, 2017). In case of oral intolerance, malabsorption syndromes or in worsening clinical situ-

ations, the possibility of using ivermectin either through the rectal or subcutaneous route has been described (Tarr *et al.*, 2003).

HTLV-1 infection is a well-known risk factor for a more severe presentation of strongyloidiasis, including disseminated infections and intestinal obstruction (Toledo *et al.*, 2015). HTLV-1 decreases the Th2 type of immune response (Toledo *et al.*, 2015). This explains both the increase in prevalence and the severity of strongyloidiasis in these patients. Mother to child is one of the most important routes for HTLV transmission, thus, breastfeeding should be avoided (Carneiro-Proietti *et al.*, 2014).

In this way, strongyloidiasis helped us expose an underlying viral infection. We suggest that HTLV status should be screened in every severe *S. stercoralis* infection or when, despite a correct treatment, a relapse is observed.

Acknowledgements

This work was financed by Gobierno de Aragon (Spain) (Research Reference Team Water and Environmental Health T51_17R) and co-financed by Feder 2014-2020 "Building Europe from Aragon.

References

- Carneiro-Proietti A.B.F., Amaranto-Damasio MS., Leal-Horiguchi C.F., Bastos R.H.C., Seabra-Freitas G., et al. (2014). Mother-to-Child Transmission of Human T-Cell Lymphotropic Viruses-1/2: What We Know, and What Are the Gaps in Understanding and Preventing This Route of Infection. *J Pediatric Infect Dis Soc.* **3**, S24-S29.
- Malézieux-Picard A., Saint-Paul M.C., Dellamonica J., Courjon J., Tieulié N., et al. (2017). Severe intestinal obstruction due to *Strongyloides stercoralis* in a pregnant woman. *Med Mal Infect.* **47**, 429-431.
- Montes M., Sawhney C., Barros N. (2010). *Strongyloides stercoralis*: there but not seen. *Curr Opin Infect Dis.* **23**, 500-504.
- Montgomery E., Voltaggio L. (2012). Chapter 3. In: Biopsy interpretation of the gastrointestinal tract mucosa. 2nd edition. Philadelphia, PA: Wolters Kluwer/Lippincott Williams & Wilkins. p. 123.
- Nutman T.B. (2017). Human infection with *Strongyloides stercoralis* and other related *Strongyloides* species. *Parasitology.* **144**, 263-273.
- Page W., Judd J.A., Bradbury R.S. (2018). The Unique Life Cycle of *Strongyloides stercoralis* and Implications for Public Health Action. *Trop Med Infect Dis.* **3**, 53.
- Schär F., Trostorf U., Giardina F., Khieu V., Muth S., et al. (2013). *Strongyloides stercoralis*: global distribution and risk factors. *PLoS Negl Trop Dis.* **7**, e2288.
- Tarr P.E., Miele P.S., Peregoy K.S., Smith M.A., Neva F.A., et al. (2003). Case report: Rectal administration of ivermectin to a patient with *Strongyloides hyperinfection syndrome*. *Am J Trop Med Hyg.* **68**, 453-455.
- Toledo R., Muñoz-Antoli C., Esteban J.G. (2015). Strongyloidiasis with emphasis on human infections and its different clinical forms. *Adv Parasitol.* **88**, 165-241.