



Turun yliopisto
University of Turku

Katriina Applegate and Taina Rönkkö

International Student's Survival Guide to Clinical Practice

Second Cycle Degree Thesis

University of Turku

Faculty of Medicine

Institute of Dentistry

Autumn term 2020

Subject: Restorative Dentistry and Cariology

Thesis supervisor: Prof. Arzu Tezvergil-Mutluay

Credit points: 20

The originality of this thesis has been checked in accordance with the University of Turku quality assurance system using the Turnitin OriginalityCheck service.

Table of Contents

1. Introduction	1
2. Clinical Training and Service in TYKS (Turku University Hospital) and in the Medical Imaging Centre of Southwest Finland	1
2.1 Clinical Training	1
2.2 Service in TYKS	2
2.3 Service in the Medical Imaging Centre of Southwest Finland	2
2.4 Goals	2
2.5 Absence During Clinical Training	3
2.6 Clinical Tutor	3
3 Dental Students' Teaching Clinic	3
3.1 Clinic Map	4
3.2 Rooms and Equipment	5
3.3 Teaching Staff	7
4 Computer Programmes	7
4.1 WinHit	8
4.1.1 Registering of Clinical Procedures	9
4.1.2 Estimate of Cost	10
4.2 IRJA	10
4.3 Booking a Teacher	12
4.4 X-Ray Programmes: Romexis and CareStream	12
4.5 Webropol Feedback	13
4.6 Pegasos	13
4.7 Calling a Patient, Appointment Booking and Patient Instructions	13
4.8 Examination, Re-evaluation, Final Evaluation	13
4.9 Hygiene Guidelines at the Clinic	14
4.10 Ergonomics	16
5 Dental Examination and Treatment Plan	17
5.1 Extraoral Examination	20
5.1.1 TMD Examination	20
5.1.1.1 Masticatory Muscles	20
5.1.1.2 Temporomandibular Joints	21
5.1.1.3 Centric Relation (CR) and Intercuspal Position (ICP)	21
5.1.1.4 Movements of the Lower Jaw	21
5.2 Intraoral Examination	22
5.2.1 Masticatory Muscles	22
5.2.2 Mucous Membranes, Tongue and Bone Overgrowth	22
5.2.3 Dentition	23

5.2.3.1 Detecting Caries and Its Risk Assessment	23
5.2.3.2 Developmental Disorders in Dentition	24
5.2.4 Periodontium	24
5.2.4.1 Depth of Gingival Pockets, Gingival Recession and Bleeding Gingiva	24
5.2.4.2 CPI	27
5.2.4.3 Classifications of Furcation Lesions and Tooth Mobility	27
5.2.4.4 Aetiology and Diagnosis of Periodontitis	28
5.2.4.5 Treatment Plan for Periodontitis and Its Prognosis	30
5.2.5 Occlusion in Childhood and Adolescence and Evaluating the Need for Orthodontics	31
5.2.5.1 Eruption of Deciduous Teeth	32
5.2.5.2 Eruption of Permanent Teeth	32
5.2.5.3 Screening Chart for Orthodontics	33
5.2.6 Prosthetics	34
5.2.6.1 Removable Protheses	34
5.2.6.2 Fixed Protheses	36
5.3.1 Radiology	39
5.3.1.1 BW and Periapical Imaging	39
5.3.1.2 Panoramic Imaging	42
5.3.1.3 X-Ray Reporting	43
5.3.2 Saliva Tests	43
6 Home Care of the Patient	44
6.1 <i>Instructions for Patients' Home Care</i>	44
6.2 <i>Informing Patients of the Dangers of Smoking</i>	44
6.3 <i>Periodontal Treatment</i>	45
6.3.1 Treatment of Gingivitis.....	45
6.3.2 Anti-Infective Treatment of Periodontitis	45
6.3.3 Re-Evaluation, Epicrisis and Periodontal Risk Assessment.....	45
6.3.3.1 How to Take a Microbial Sample from a Gingival Pocket.....	46
6.3.3.2 Antibiotics in Periodontal Treatment	48
6.3.4 Periodontal Surgery	49
6.3.4.1 Gingival Curettage.....	50
6.3.4.2 Gingivoplasty ECA30	52
6.3.4.3 Gingivectomy ECA35	53
6.3.4.3.1 Use of the Electric Knife	54
6.3.4.4 Flap Surgery ECA50 or ECA55	55
6.3.4.5 Operative Report	57
6.3.4.5. Periodontal Dressing.....	57
6.4 <i>Restorative Treatment</i>	58
6.4.1 Arrest of Caries Lesions.....	58

6.4.1.1 Sealants.....	60
6.4.1.2 Fluoride.....	60
6.4.2 Restorative Treatment of Caries –Shallow to Moderate Lesions	61
6.4.2.1 Treating Deep Caries	61
6.4.2.1.2 Perforation	64
6.4.2.2. Matrices	66
6.4.3 Composite Resin Bonding and Repair	67
6.4.3.1 Temporary Filling Materials	68
6.4.3.1.1 Riva Self Cure	68
6.4.3.1.2 IRM Caps	69
6.4.3.1.3 Cavit, Cavit W and Cavit G.....	69
6.5 <i>Root Canal Treatment</i>	70
6.5.1 Indications.....	70
6.5.2 Root Canal Morphology	70
6.5.3 Stages of Treatment	72
6.5.4 Instruments.....	72
6.5.5 Opening and Expanding Root Canals	73
6.5.6 Canal Filling	75
6.5.7 Preparing a Permanent Filling on Top of Root Filling	76
6.5.8 Mechanical Root Canal Preparation with ProTaper	76
6.5.9 Removal of Old Root Canal Filling	77
6.6 <i>Oral Surgery</i>	78
6.6.1 Tooth Extraction.....	78
6.6.1.1 Indications.....	78
6.6.1.2 Contraindications.....	79
6.6.1.3 Instruments.....	80
6.6.1.3.1 Luxator and Elevator Types.....	80
6.6.1.4 Tooth Separation in Extraction.....	81
6.6.1.5 Post-Operative Instructions	84
6.6.1.6 Post-Operative Symptoms and Complications	84
6.6.1.6.1 Post-Operative Bleeding	84
6.6.1.6.2 Alveolitis	85
6.6.2 Biopsy and Suturation.....	86
6.6.2.1 Biopsy.....	86
6.6.2.2 Suturation	87
6.7 <i>Local Anaesthetics and How to Choose Them</i>	90
6.7.1 Allergy to Anaesthetic Agents.....	90
6.7.2 Topical Anaesthesia.....	91
6.7.3 Active Ingredients in Local Anaesthetics and Their Maximum Dosages.....	91

6.8 Most Commonly Used Medication in Dentistry	92
6.8.1 Pain – Non-Steroidal Anti-Inflammatory Drugs	92
6.8.2 TMD Pain.....	93
6.8.3 Antibiotics	94
6.8.3.1 Single Dose Prophylaxis	94
6.8.3.2 Continuous Prophylaxis and Treatment of Infections	95
6.8.4 Lichen Ruber Planus.....	96
6.8.5 Painful and Recurrent Aphthous Ulcer	97
6.8.6 Oral Fungal Infection.....	97
6.8.7 Herpes.....	98
6.8.8 Patients at High Bleeding Risk.....	98
6.8.9 Acute Chest Pain	98
6.9 Most Commonly Used Medicines and Their Effect on Dental Treatment.....	99
6.9.1 Warfarin (Marevan)	99
6.9.2 Aminobisphosphonate (Fosamax)	99
6.9.3 Insulin Therapy or Oral Medication of Diabetes	100
6.9.4 Inhaled Corticosteroids (Aerobek, Rhinocort, Flixotide, Flixonase)	100
6.9.5 Anti-Hypertensive and Cardiac Insufficiency Medication (Diuretics, Calcium Channel Blockers, ACE Inhibitors)	100
6.10 Risk Patients.....	101
6.10.1 Cardiovascular Diseases.....	101
6.10.1.1 Cardiac Insufficiency	101
6.10.1.2 Hypertension	102
6.10.1.3 Increased Risk of Bleeding	102
6.10.2 Diabetes.....	102
6.10.3 Patients with Artificial Joints.....	103
6.10.4 Rheumatic Diseases	103
6.10.5 Head and Neck Cancers	104
6.10.6 Pregnancy	104
6.10.7 Asthma and Respiratory Disorders	104
6.10.8 Inflammatory Bowel Diseases.....	104
6.10.9 Liver Diseases.....	105
6.10.10 Renal Insufficiency	105
6.10.11 Organ Transplants	105
6.11 First Aid and Resuscitation.....	106
6.11.1 Serious Allergic Reactions.....	106
6.11.2 Sudden Cardiac Symptoms in Dental Practice	106
6.11.3 Hypoglycaemic Shock	107
6.11.4 Seizures.....	107
6.11.5 Foreign Objects in Respiratory Tract or Oesophagus	108

6.11.6 Shortness of Breath	108
6.11.7 Loss of Consciousness.....	108
6.11.8 Angina Pectoris	108
6.11.9 Cerebral Blood Flow Disorders.....	109
6.11.10 Anaesthetic Toxicity	109
6.11.11 Cardiopulmonary Resuscitation	109
7 ICD-10/Nomesco Classification – Mouth	111
8 Most Common TMD ICD-10 Diagnoses.....	115
9 Dental Terminology Finnish–English	116
10 Useful Links	117
11 Sources.....	118
12 Appendices	123
12.1 <i>Instructions</i>	123
12.1.1 Fillings	123
12.1.1.1 Dentin Conditioner	123
12.1.1.2 Riva Self Cure	124
12.1.1.3 Filtek Z250 (3M Espe)	124
12.1.1.4 ViscoStat, Astringedent&Astringedent X	126
12.1.1.5 Calcimol LC.....	126
12.1.2 Hypersensitive Teeth.....	127
12.1.2.1 Bifluorid 5	127
12.1.2.2 Duraphat® 22,6 mgF-/ml	127
12.2 <i>Special Healthcare – Oral and Maxillofacial Surgery</i>	128

1. Introduction

The purpose of this guide is to offer basic information to an undergraduate exchange student in dentistry regarding the clinical work and practices at the University of Turku including the Turku University Hospital (TYKS) and the teaching clinic of the city of Turku at Dentalia. This guide is based on Piia Uusitalo's and Katariina Havukainen's degree thesis *Kandin selviytymisopas klinikkaan* written originally in Finnish to help Finnish dental students get accustomed to teaching clinic's practices. The English version has been updated and modified according to new clinic practices in e.g. aseptics, periodontology and cariology.

In this guide you will find practical information on what you need to know when you begin clinical work in the teaching clinic. It is meant as a handy PDF guide where you can check and verify procedures and practical things during your clinical training. The aim is to make your transition to the clinic easier and more enjoyable.

2. Clinical Training and Service in TYKS (Turku University Hospital) and in the Medical Imaging Centre of Southwest Finland

2.1 Clinical Training

Clinical dental training takes place in the Institute of Dentistry (Dentalia) of the University of Turku. The teaching clinic of Turku University Hospital is located on the 2nd floor. The undergraduate teaching clinic of the city of Turku is located at the 3rd floor. Emergency dental care for Turku residents is provided in Dentalia on the ground floor (1st floor).

Undergraduate students start the clinical training at the beginning of the 3rd year and continue until the end of their 5th year. The clinic at the University of Turku is a part of the municipal dental organisation which means students are responsible for treating all their patients from start to finish. Before being assigned their first patients, students must fulfil specified requirements of theoretical knowledge. During their first term in clinical training, undergraduate students are allowed to conduct examinations on young adults, provide counselling on nutrition and smoking cessation, perform complete periodontal examinations and give basic periodontal therapy and apply fluoride varnishes. After completing their competence exams on respective fields, students are also allowed to continue with direct restorative treatments, tooth extractions and prosthodontic or endodontic treatments. Any extra equipment such as electric

toothbrushes or tooth gap brushes are found in the front part of the clinic. Patient leaflets are found on the wall next to the office.

Part of the clinical training includes participation in other clinical services. Shifts in TYKS (Turku University Hospital) and in the Medical Imaging Centre of Southwest Finland are either marked in WinHIT or you will receive information about them before your shifts. Therefore, patients should not be booked in these time slots.

2.2 Service in TYKS

Students will take part in oral and maxillofacial surgery polyclinical services. This includes one week in TYKS Oral and Maxillofacial Clinic that is located on the 2nd floor in Dentalia.

Students will also have four days of emergency dental care service.

2.3 Service in the Medical Imaging Centre of Southwest Finland

Radiology service is done as part of patient treatment. Students take part in their own patients' radiological examinations and have radiological shifts in the Medical Imaging Centre of Southwest Finland for one week. This is located on the 2nd floor in Dentalia. Patient will require a referral from a dentist prior to any radiological examinations. Medical Imaging Centre of Southwest Finland performs panoramic examinations and cone beam CT scans.

A patient receiving all-inclusive treatment will require an up-to-date panoramic film, preferably no more than 5 years old.

2.4 Goals

The goal for (Finnish) students is to show during the clinical training period that they have the skills, knowledge and attitudes required for independent dental work and that their skills, knowledge and attitudes match the levels of their European colleagues.

To achieve these goals students are given specific guidelines and a list of procedures that need to be completed before their time in clinical training is over.

2.5 Absence During Clinical Training

Clinical training is part of mandatory studies. In case of sickness, phone early in the morning or send a text message the previous evening (tel: 044 907 3617) in order to cancel patient appointments.

2.6 Clinical Tutor

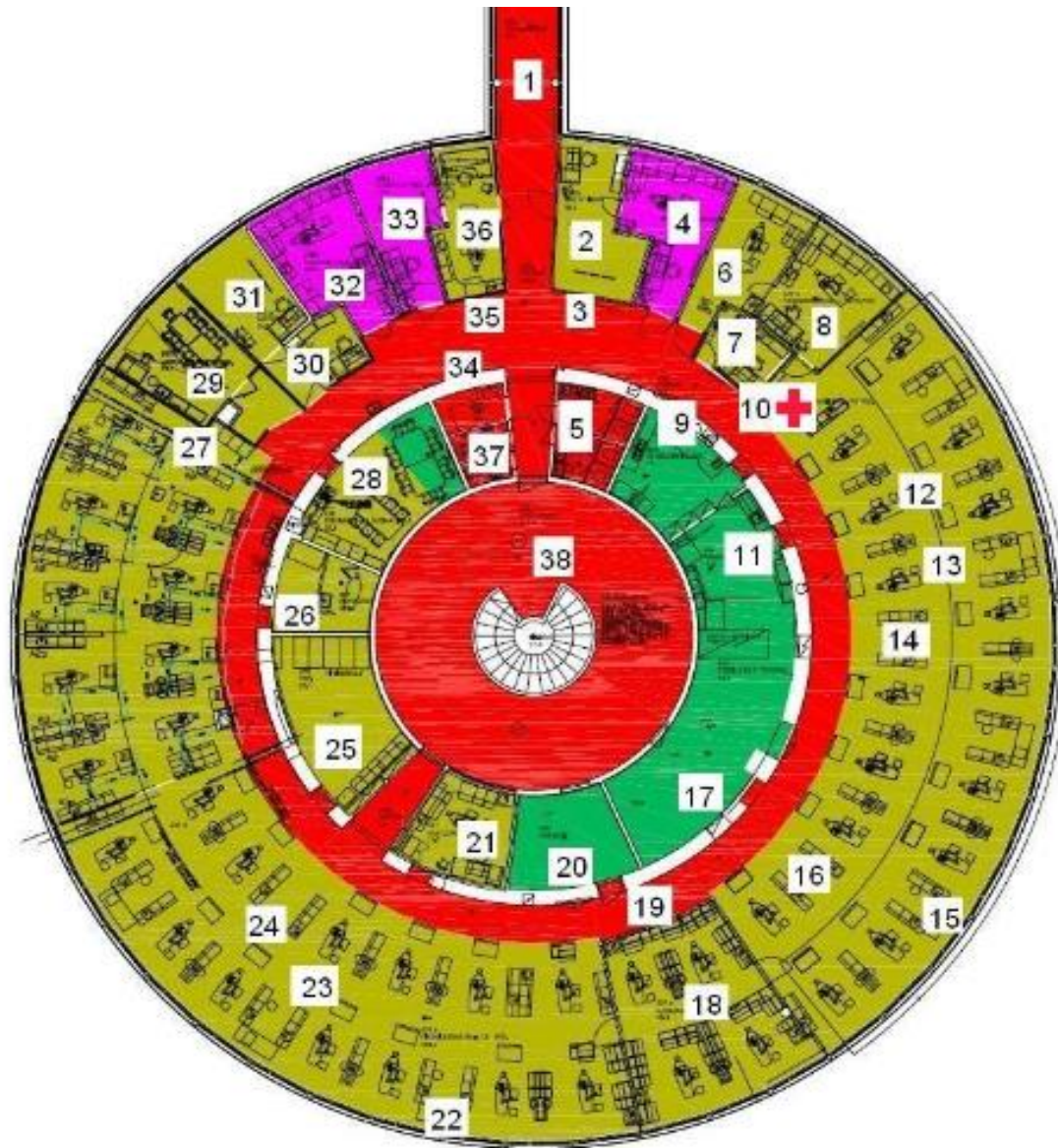
Each third-year student is assigned a clinical tutor, who is responsible for following the clinical work and competencies of the students and provide assistance and guidance when needed until they graduate.

3 Dental Students' Teaching Clinic

The teaching clinic is part of municipal oral healthcare services. Every inhabitant of Turku and anyone who has chosen Turku as their place of health care has the right to these services.

The number for the office in the teaching clinic is **02 269 0611** and the address is Lemminkäisenkatu 2, 3rd floor. The phone number for the office on the 2nd floor is **02 266 60618**. The phone number for the surgical procedure room is **02 266 0612**. Please note that these phone numbers are for staff use only and should not be given to patients.

3.1 Clinic Map



Picture 1. Clinic layout.

1. Glass corridor
2. Instruction nurses' lobby
3. Computers on the corridor. Those on the left are connected to the university's internet.
4. Clinicteachers' room

5. Patient toilets
6. Periodontology room
7. Office, where you will find safety instructions for different equipment and phones. Outside the office on the wall are forms, instructions and leaflets for patients.
8. Orthodontist's room
9. Instrument maintenance, sluice
10. Prosthetics 1 cupboard, includes first aid
11. Instrument maintenance packing
12. Front hall
13. Front hall drill trolley
14. Front hall passage for necessities and equipment
15. Scanner
16. Drill passage and trolley
17. Instrument maintenance, clean side
18. Endo room
19. Nametags
20. Instrument maintenance
21. Oral hygienist's room
22. Fridge
23. Back hall
24. Back hall's necessities and equipment passage
25. Storage and x-ray room
26. X-ray room
27. Prosthetics 2 cupboard
28. Staff room
29. Senior dentists' room
30. Teachers' room, here you will find the students folders and pigeonholes for different classes
31. Teachers' room
32. University room

33. Teachers' room
34. Cast model cupboard and mail cupboard
35. Cast model cupboard
36. Oral hygienist's room
37. Staff toilets
38. Waiting area

3.2 Rooms and Equipment

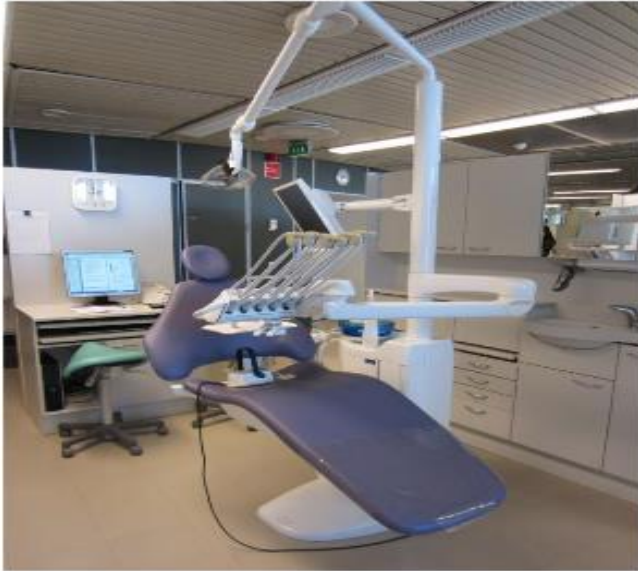The undergraduate dental clinic has 43 dental care units. Units 1-16 are in the so-called front hall and units 17-37 are in the back hall. To book a unit you need to fill in a reservation form in Moodle-IRJA before your clinical shift.

Some units have X-ray, and some have ultrasound. Two of the units (18 and 19) are left-handed. Some of the units are dedicated mostly for those doing prosthetic work (4, 6, 8, 10, 12, 14). Six units are reserved for emergency dental treatment procedures (7, 9, 11, 13, 15, 16).

For root canal treatments, there are four especially equipped treatment units in the endo room. Endo room is in the middle separated from normal units by walls.

If you've been issued a clinic card with your name and picture, take it from the card holder on the wall at the beginning of the shift and attach it on your unit.

The X-ray rooms are situated on the 2nd floor (see map, numbers 25 and 26). The bigger room is used for all local patients with a referral, the smaller storage room is only for teaching clinic's patients. On the walls are instructions on how to develop digital X-ray images, or you can ask a dental assistant for help. In the X-ray rooms you can take periapical or bitewing images, and they are used for all units except the ones that have their own X-ray tubes.



Picture 2. Dental treatment unit in a cleaned position C.

3.3 Teaching Staff

Clinical supervision is the responsibility of integrated multidisciplinary teams of faculty members and clinical teachers. There are approximately 35 clinical teachers working in the undergraduate teaching clinic, as well as dental assistants, administrators and instrument maintenance staff.

4 Computer Programmes

The following programmes are used at the teaching clinic: Terve-verkko, WinHIT, Moodle-IRJA, Romexis, Carestream, Webropol and Pegasos.

To sign into the computers, you need a user ID and password. To access WinHIT, a separate user account is needed. You will receive the username and password for this account once you have signed a confidentiality contract with the clinic.

4.1 WinHIT

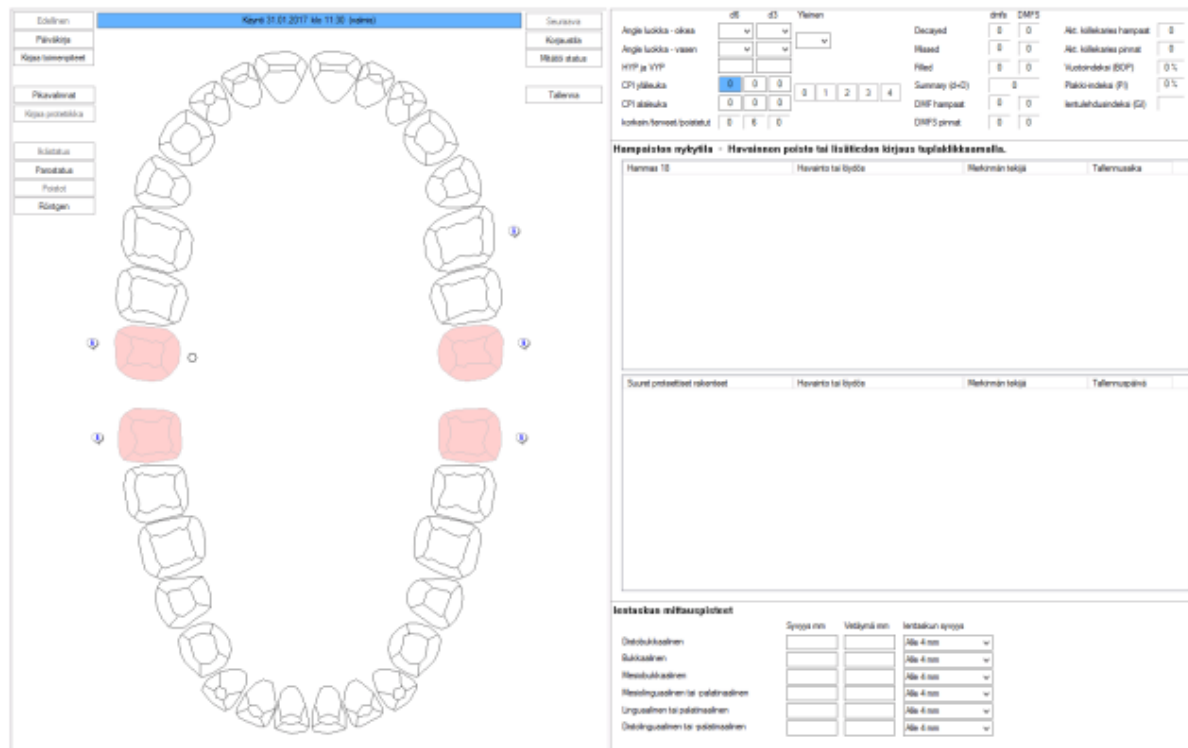
WinHIT is a dental patient register used by the city of Turku. The manual for WinHIT can be found in <http://www.innet.fi/kayttooppaat.html>. This is in Finnish, however, so it is advisable to ask a dental assistant, fellow student or a teacher for a quick tutorial.

Prior to receiving dental treatment, patients' details, such as addresses and telephone numbers, must be checked. Remember to ask for a permission from patients to send text message reminders about their future appointments.

Patient history must include any possible illnesses, medications, allergies and anything else that might affect treatment.

The screenshot displays the WinHIT software interface. On the left is a navigation tree with categories like 'Asiakastiedot', 'Hoitoajat', 'Status', 'Parodontologinen status', 'Anamnesisi', 'Hoitokertomus', 'Toimenpidehistoria', 'Tekstiviestit (sopimus)', 'Yhteydenotot ja tietojen luovutus', 'Yleisterveysthuolto', 'Riskitiedot', 'Lääkityslista', and 'Laboratoriotulokset'. The main area shows patient details for 'Opetuslääkäri' in room 'Opetus 11' at 'Kandi 164'. Below this is a calendar for 'Syyskuu 2014' with a grid showing dates and appointment times. The right sidebar shows a list of appointments for 'hml kand. *kandi 164 - Tiistai 09.09.2014', including 'Toimisto OPETUS 11 12:30 - 12:45' and 'Klininen OPETUS 11 12:45 - 15:30'. At the bottom, there are options for 'Yhteydenotoviesti', 'Saapunut viesti', and 'Lähetetty viesti', along with a table for sending messages.

Picture 3. Starting page in WinHIT. Source: http://www.innet.fi/help/wp-content/uploads/2017/08/20170503_WinHIT_statuksen_kasikirja.pdf



Picture 4. Status page on WinHIT. Source: http://www.innet.fi/help/wp-content/uploads/2017/08/20170503_WinHIT_statusen_kasikirja.pdf

Päiväkirja = reservation calendar, Kirjaa toimenpiteet = register procedures, Pikavalinnat = shortcuts (for examination findings, e.g. caries, composite restoration), Parodontologia = periodontology, Röntgen = x-ray (Romexis).

On the status page, there are two dental charts. Findings are documented tooth by tooth on the dentition on the left and details on e.g. restoration types and occlusion can be seen on the right side. The explanations for symbols can be seen by placing mouse pointer on a symbol and right-clicking.

4.1.1 Registering of Clinical Procedures

Once the patient appointment is finished all procedures need to be registered in "Kirjaa toimenpiteet". Click on the right mouse button and choose "Lisää toimenpide" (add procedure). Remember to record all necessary information. Teacher then accepts and signs off the procedures and establishes the reason for the appointment (ICD-10 code).

4.1.2 Estimate of Cost

An evaluation of total cost is made for patients who receive all-inclusive treatment. It is easy to print out from WinHIT.

Koodi	Toimenpide	Hamm	Hinta
Kayn	Käyntimaksu		10,20 €
SAA03	Suun laaja tutkimus		29,30 €
SFA20	Kahden pinnan yhdistelmämuovit	16	29,30 €
SFA10	Yhden pinnan yhdistelmämuovita	17	14,70 €
WX110	Infiltraatiopuudutus	17	6,60 €
EB1SA	Hammasaröntgen, Bite-Wing	17	6,60 €
EB1SA	Hammasaröntgen, Bite-Wing	17	6,60 €
WZC00	Kok.tutkimukseen liitt. hoitos	17	0,00 €
	Yhteensä		103,30 €

Picture 5. Estimate of cost.

4.2 IRJA

IRJA is the teaching clinic's specially designed electric desktop which monitors students' clinical progress and procedures. IRJA also has message boards for the communication at the clinic, as well as clinical treatment guides. You can use IRJA to access numerous instructions, and it also has video material and booking calendars for units and clinic's teachers. You can access IRJA through Moodle: <http://moodle.utu.fi>.



turku SOSIAALI- JA TERVEYSTOIMI med.UTU.fi
TURUN YLIOPISTO
UNIVERSITY OF TURKU

IRJA
Opetushammashoitolan sähköinen työpöytä

Moodle on oppimisalusta eli virtuaalinen oppimisympäristö (VLE).

OPETTAJA PAIKALLE
HOITAJA PAIKALLE

Opettajien varauskirja

-  KLINISTEN OPETTAJIEN VARAUSKALENTERI
-  SHG -varaukset D5/D6
-  KARIOLOGIA LOPPUTARKASTUS (2013)
-  PARODONTOLOGIA LOPPUTARKASTUS (SL 2013)
-  PROTETIIKKA SUUNNITTELU JA LOPPUTARKASTUS (SL 2013)
-  OP-suunnitteluseminaari (SL 2013)
-  PURENTAFYSIOLOGIA LOPPUTARKASTUS (SL 2013)
-  ENDODONTIAN VARAUKSET

Valmis

Inter

Picture 6. IRJA. Calendar for booking a teacher.

Requests for dental assistants and teachers are made by adding a new conversation message in IRJA. In the topic section write unit number and the reason for which you are requesting a teacher. You can ask for a specific teacher by writing their name in the topic. In the message section write your own student number. When requesting for a dental assistant you do not need to write a reason.

If you are doing a procedure for the first time, it is best to mention it in the topic section so the teacher can be prepared. Assistants are always available to help you, and they are especially important in recording a dental examination and during the bonding procedures of restorative treatments.

Olet kirjautunut nimellä Piia Uusitalo. (Kirjaudu ulos)

Tämä alue tyhjeneään klo 12.00-12.30 välisenä aikana sekä klo 16.00 jälkeen.

▼ Uusi kysymyksesi

Aihe*

Viesti*

Pöytä: p

Tilaus ⓘ Tilauksia ei sallita

Picture 7. An example of a request for a teacher.

4.3 Booking a Teacher

Use IRJA/Opettajien varauskirja to book a teacher e.g. for examinations, re-evaluations, final evaluations, periodontological surgeries or prosthetic treatments. Mark down your student number and name, patient's initials and the reason for the appointment.

4.4 X-Ray Programmes: Romexis and Carestream

Romexis is an X-ray imaging programme used in the clinic. It can be opened in WinHIT from the status of the patient (Röntgen). Carestream is for dental cone beam CT.

4.5 Webropol Feedback

Teachers give feedback on students' work, skills and progress through Webropol. Students can access the feedback through IRJA/Hoitoharjoittelun arviointi/Arviointi (henkilökohtainen).

4.6 Pegasos

The city of Turku uses Pegasos patient information system. Its aim is to enhance and improve the quality of care as well as to ensure that patients receive required treatments within an acceptable time period. The information system includes multiple functions such as appointment booking, contact information, advice and electronic medical history.

4.7 Calling a Patient, Appointment Booking and Patient Instructions

Dentists can refer patients to Dentalia. The dental office assistant gives the first appointment to a patient or sends a message to a student in WinHit, after which the student books the first appointment. From this point on, the student handles subsequent appointments.

Oral home care information leaflets for patients are found by the office in a shelving unit. Instructions include nutrition, tooth extraction etc.

4.8 Examination, Re-Evaluation, Final Evaluation

The first appointment booked for a patient who receives all-inclusive care and treatment is an initial oral examination. This is conducted by the student. During the same appointment, use WinHIT to book a second appointment for the patient for a teacher's examination. Remember to book a teacher in IRJA. The student must be present at this appointment. This allows for the student to have a provisional treatment plan ready, and possible changes can be made after teacher's examination. A recent panoramic film and possible BW and intraoral images must be ready at the teacher's examination.

Re-evaluation of the basic periodontal treatment is done 4–6 weeks after anti-infective treatment has ended. The patient will have a new periodontological examination, a medical summary is written, and a new appointment time is booked with a teacher through IRJA.

For the final check-up, treatment must be completed (at least for the area concerned) and a medical summary written. For the examination, a specialist teacher in that field is booked via IRJA.

4.9 Hygiene Guidelines at the Clinic

Teaching clinic and simulation lab work outfits are provided by the city of Turku or the university hospital. All clothes are located at the basement (K-floor) of Dentalia, and for entry one must have an access key. Before entering the clinic, change into clinic clothes (light blue shirt and white trousers) at the changing room located at the basement. From the elevator turn left and immediately right to the laundry room. Return your clothes to the laundry baskets after use every week or when they are dirty. Wear your own socks and clean indoor shoes.

Rings, watches and other accessories need to be removed and long hair needs to be tied back during patient work. Wearing perfume or nail varnish is not allowed.

Hygiene guidelines should be given special attention. It is important to develop a routine for aseptic procedures. After a while they will become automatic and eventually take less time.

Always wash hands at the beginning of your shift. Apply hand sanitiser when you come to or leave the unit. Do not leave the unit with face mask on. Always wear gloves and a mask when working with a patient, but remember to not touch keyboard, hair etc.

Proper order of hygienic procedure:

- 1. Wash hands.***
- 2. Apply hand sanitiser.***
- 3. Put face mask and loupes on.***
- 4. Apply hand sanitiser.***
- 5. Put on gloves.***

A video on hygienic requirements is found on the link below:

<http://www.stal.fi/viestinta/julkaisut/-ja-videot/aseptiikkavideo/>

Procedures in the treatment unit before the first patient of the day:

- Wash hands, apply hand sanitiser and vinyl gloves.

- Moisten the cleaning tissues with surface disinfectant (Desiol).
- Wipe the lamp handle, instrument mat, hand pieces and tubings, tray table.
- Put wiped hand pieces, multifunctional syringe and the ultrasound device for a rinse in the water system (2 beeps).
- Wipe table surfaces and the X-ray device.
- Wipe instruments that have been rinsed in the water system.
- Wipe patient chair.
- Wipe suction tubes and suck water in from the tap for a moment.
- Put gloves into the trash bin and apply hand sanitiser.
- Pick up clean instruments from sterile hatch.
- Lay out basic instrument tray, suction tip, cotton rolls, cellulose swabs, patient cloth, cup for rubbish and clean protective glasses for patient.

Procedures to be done between patients:

- Put drill heads in a metal cup.
- Put cotton rolls, wedges, cellulose swabs and suction tips in a trash bin.
- Put instruments into their own cassettes (e.g. probe, tweezers and gingival pocket measurer).
- Put all sharp instruments to a sharps bin (anaesthetics needles, root canal needles etc.) and ampoules in their own medicinal waste can.
- Take the patient tray to the dirty hatch in the instrument maintenance.
- Apply hand sanitiser and change vinyl gloves.
- Moisten the cleaning clothes with surface disinfectant (Desiol).
- Wipe the lamp handle, instrument mat, hand pieces and tubings, tray table.
- Set the wiped hand pieces, multifunctional syringe and ultrasound device into the water system for a rinse (1 beep).
- Wipe table surfaces, cupboard handlebars, keyboard, table and the X-ray device, instruments of the water system, patient chair, suction tip and tubes (suck water into the tubes when necessary).
- Wipe/wash patient's protective glasses and the protective light curing shield.
- Put gloves into the trash bin and apply hand disinfectant.
- Get clean instruments from the sterile hatch.

- Lay out the following items: basic instrument tray, suction tip, patient cloth, cup for rubbish and clean protective glasses for patient.

Final tidying-up at the end of a day:

- Take the cleaned tray, drill cup and suction instrument's detachable pieces to the dirty hatch in the instrument maintenance area.
- Put away vinyl gloves and apply hand disinfectant.
- Follow the cleaning procedures as described for in-between patient cleaning, followed by water systems rinse (2 beeps).
- Take a yellow jug from the vanity cabinet. Fill the jug with ½ capfuls of Orotol and 1 litre of water (up to the line).
- Attach the suction tubes to the nozzles on the jug's lid.
- Remove the suction tubes immediately once the solution is finished.
- Leave the cleaned micromotor sleeve on the instrument tray.
- Set the chair in position C.
- Set the pedal on the chair over a paper towel.
- Switch off the device and turn off the tap.

Instrument maintenance is located on the 3rd floor in Dentalia (see map, nr 9).

4.10 Ergonomics

Ergonomics is of paramount importance to a dentist. It should be given special attention from the beginning.

Most dental treatment procedures are conducted from a seated position. As the dentist is sitting, the position of the back should be almost identical to a standing position. This allows the vertebrae to line up in a manner that distributes pressure equally.

Teaching clinic has saddle chairs and chairs with backrests. The slope of a traditional chair's seating part should be 5–15 degrees. The height of the chair should allow a minimum of a 90-degree slope for the body and the thighs. As for the saddle chair, the optimal seating position is reached by increasing the slope between the body and thighs to 130 degrees. This allows the back to arch in an optimal way.

When the work is conducted by leaning forward, the direction of the thighs should be tipped downward.

Students will receive loupes that are attached to protective glasses and adjusted individually. Loupes enable dentists to work more ergonomically.

When using power suction, a turbine bur or an ultrasound device, the level of noise is about 65 dB. Noise can become a stress factor. Therefore, using ear protectors is recommended.

5 Dental Examination and Treatment Plan

Patient/Potilas:	Date/Päivämäärä:
General health/Yleisterveys:	
Anamnesis/previous dental care history/self-care: Anamneesi/aik. hammashoitohistoria/omahoito:	
Soft tissue/Pehmytkudokset:	
Occlusion/Purenta:	
Periodontium/Parodontium:	
Dentition/Hampaisto:	
X-ray/ptg/bw/periapical imaging: Rtg/ptg/bw/periapikaalikuvat:	
Etiology/Etiologia:	
Prognosis/Proгноosi:	
Treatment plan/Hoitosuunnitelma:	

Chart 1. General information for medical record.

	Patient history/Anamneesi
Date of examination/ Alkutarkastuksen pvm	
Patient name/potilaan nimi	
Social security no./ Henkilötunnus	
Student/Kandi	
Teacher/Opettaja	
Reason for seeking treatment/ Hoitoon hakeutumisen syy	
Hopes for treatment/ Toiveet hoidon suhteen	
Patient with dental fear/ Pelkopotilas	Yes/no Kyllä/ei
Healthy/Terve	Yes/no Kyllä/ei
Diseases/Sairaudet	
Medications/Lääkitykset	
Allergies/Allergiat	
Need for antibiotic prophylaxis/ Ab-profylaksian tarve	Yes/no Kyllä/ei
Previous dental treatment/ Aikaisempi hammashoito	Examination (tarkastus)/filling (paikkaus)/rootcanal (juurihoito)/ extraction (poisto)/orthodontics (oikominen)/prosthetics (protetiikka)
Home care/ Kotihoito	Manual brush (manuaaliharja)/electric brush (sähköharja) Morning & evening (aamuinilloin)/once a day (kerranpäivässä) Dental floss (hammaslanka)/dental brush (hammasväliharja) /toothpick (hammastikku) Morning&evening (aamuinilloin)/once a day (kerranpäivässä) Fluoride toothpaste (fluorihammastahna)
Diet/Ruokavalio	Regular/snacking Säännöllinen/napostelu
Sweets/crisps Makeiset/sipsit	Does not eat/once a week/twice a week/daily Ei syö/kerran viikossa/2 kertaa viikossa/päivittäin
Sugar in coffee Kahvisokerin käyttö	Yes/no Kyllä/ei

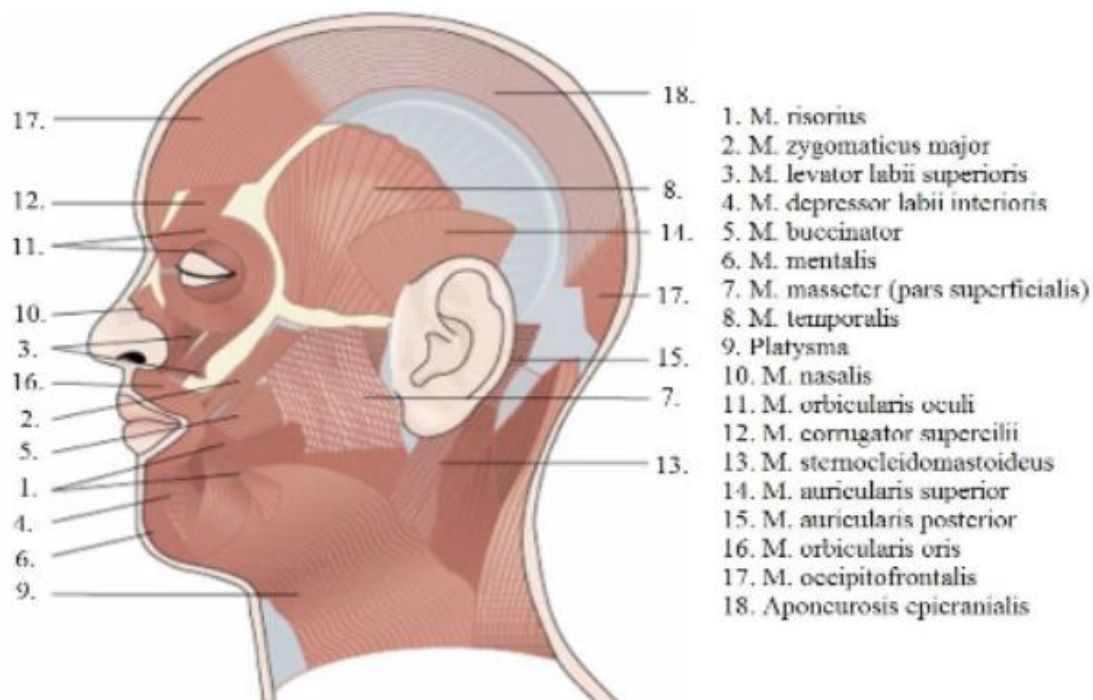
Drinks/frequency Juomat/frekvenssi	Water/milk (vesi/maito) Juice/soda/sport drinks/alcohol (mehu/virvoitusjuomat/urheilujuomat/alkoholi)
Xylitol/Ksylitoli	Chewing gum/pastille quantity: Purukumi/pastilli määrä:
Smoking/snuff Tupakointi/nuuska	Yes/no Kyllä/ei
Other/muuta	
	Status extraoralis
Masticatory muscles	Sore on palpation: yes/no, where:
Temporomandibular joint	Clicking: yes/no, which one: Pain: yes/no
Deviations	
Lymph nodes	Enlarged: yes/no, where:
CR-ICP	No glide/glide
	Status intraoralis
Mucous membranes and tongue	Healthy appearance
Torus	Yes/no, where:
Occlusion	Right: AI, AII, AIII/K Left: AI, AII, AIII/K
Overjet/mm	
Overbite/mm	
Max opening/mm	
Length of lateral movement	Right mm from midline Left mm from midline
Midline	In line/mandibula midline mm right/left
Laterotrusion right	Canine guidance/group contact
Mediotrusion right	No contacts/contacts:
Laterotrusion left	Canine guidance/group contact
Mediotrusion left	No contact/contacts:
Malocclusion	
Dentition	Good condition/many fillings/too few/residual teeth/deciduous/I turnover/II turnover/complete
Prosthetics	
Periodontium	
Most common diagnoses	

Chart 2. Things to consider during an examination.

5.1 Extraoral Examination

5.1.1 TMD Examination

External examination includes palpating the masticatory muscles, temporomandibular joints and lymph nodes of the neck. The mandible's trajectory must also be measured, and any deviations recorded. Finally, the difference between centric relation and intercuspals position is assessed. Please note that for actual TMJ patients this is done more thoroughly according to an internationally standardised protocol DC-TMD Diagnostic Criteria for Temporomandibular Disorders.



Picture 8. Muscles of the head and the neck. Source: Therapia Odontologica.

5.1.1.1 Masticatory Muscles

The superficial part of m. masseter is palpated from the angle of the jaw and the deeper part under the zygomatic arch with a force of 1 kg.

M. temporalis is palpated anteriorly from the temple and posteriorly above and behind the ear with a force of 1 kg.

M. pterygoideus medialis is palpated underneath the angle of the jaw with a force of 0.5 kg.

M. digastricus is palpated behind the angle of the jaw with a force of 0.5 kg.

5.1.1.2 Temporomandibular Joints

Temporomandibular joints are examined by palpating with a soft grip of 0.5 kg force laterally in front of the ear and dorsally from the outer auditory canal when the patient's mouth is closed and maximally open. At the same time the presence of any joint sounds is examined.

5.1.1.3 Centric Relation (CR) and Intercuspal Position (ICP)

Set the patient to a lying down or half seated position. Advise the patient to lift their jaw upward. Take a firm grip of the patient's jaw with both hands. Ask the patient to swallow and relax the lower jaw. A mental picture of the jaw dropping to the floor may be helpful. Tap the patient's teeth together. Centric relation is the farthest back position where the teeth of the lower and upper jaws can still touch each other. Many people's CR and ICP may differ by 3 mm and still be acceptable.

5.1.1.4 Movements of the Lower Jaw

The maximal opening should be at least 40 mm. This should include overbite. Protrusion and lateral movements should be at least 7 mm, including overjet. Measurements are done from the incisal tops of dd. 11 and 41.

As for the lower jaw's opening movement, pay attention to whether the opening movement is straight or deviating. Deviation always takes place towards the affected temporomandibular joint.

In articulation movements laterotrusion should have canine guidance or a group contact. In mediotrusion there should be no contacts. Protrusion should rest equally on the incisors.

For a patient with full prosthetics, laterotrusion on the working side should have a group contact. Mediotrusion contact on the non-working side is necessary to prevent prostheses from moving.

5.2 Intraoral Examination

Examination begins with examining the intraoral masticatory muscles, mucous membrane and the tongue. Document possible changes such as tight frenula, gingival overgrowths, linea alba and bone overgrowth. These could interfere with possible prosthetic treatment. Also palpate the floor of the mouth, sulci and apical areas.

5.2.1 Masticatory Muscles

Masticatory muscles are palpated inside the mouth using max 0.5 kg force. The anterior part of m. masseter is palpated with a thumb inside the mouth.

The attachment point of m. temporalis to processus coronoideus is palpated inside the mouth along the anterior part of ramus mandibularis.

M. pterygoideus lateralis is palpated behind maxilla's sulcus and upwards.

5.2.2 Mucous Membranes, Tongue and Bone Overgrowth

Mucous membranes of all patients must be examined, even if a patient is only presenting with a cracked tooth. Any changes are documented in the treatment plan and followed up. **Any changes that do not disappear in 2–3 weeks once all possible irritating factors have been removed require a biopsy.**

Mucous membranes of patients in all-encompassing treatment are checked along with any procedures preferably at least once a year even if there have been no changes. Special attention should be given to the sides and the root of the tongue.

A video for examining mucous membranes is found on the link below:

<http://www.kaypahoito.fi/web/kh/suositukset/naytaartikkeli/tunnus/nix01836>

5.2.3 Dentition

When examining a patient's dentition, pay attention to the following factors: absence of teeth, excessive number of teeth, changes in enamel, development problems, erosion, abrasion, abfraction and attrition.

5.2.3.1 Detecting Caries and Its Risk Assessment

It is vital to be able to distinguish between a caries lesion that has been inactive and is not progressing, a caries lesion that is progressing and needs to be arrested and caries lesion that needs to be restored. The surface of the tooth must be dried so that it is possible to detect early changes. If the dentition is relatively intact with few fillings, fibre optic light may be useful in detecting caries. When using fibre optic light, all other sources of light must be switched off so a possible caries lesion can be seen. Caries appears as a dark shadow in dentine.

An inactive caries lesion appears shiny and often dark and hard on the surface of the tooth. A progressing, early caries lesion in enamel appears chalky and feels rough on probing. Changes are covered by plaque and edges are not exact.

Active caries lesions are typical in erupting/recently erupted teeth in children with active caries. Inactive lesions can be seen on teeth that have erupted some time ago in children and young people who are not at a high caries risk.

Status symbol	Explanation	Extra definition on a young person*
CI	Caries in enamel	Improved home care
CIA	1) Active caries lesion only in enamel. 2) Active caries lesion in dentine, can be arrested.	Treatment to stop progression
CII	Caries progressed to dentine	Treatment to stop progression
CII	Caries progressed to pulp	Treatment to stop progression

Chart 3. How to document level of progression and activity to WinHIT.

*Risk assessment's extra definition is documented in YHV (timeline for maintenance treatment) section for children/young people.

5.2.3.2 Developmental Disorders in Dentition

A developmental disorder can manifest as a colour change or as a deformity on the surface of the tooth and is caused by genetic and/or environmental factors. An excessive intake of fluoride during a developmental stage is a common reason for the colour change of enamel. Other reasons for developmental disorders are coeliac disease, rachitis (known as rickets), malfunctioning of liver, kidneys, thyroid or parathyroid malfunction, as well as radio and cytostatic therapy.

Furthermore, some drugs such as tetracycline and chemicals such as dioxin can disturb the normal development of a tooth. If a deciduous tooth grows inwardly due to a trauma or infection, this can damage the development of the permanent tooth. Developmental disorders of the teeth are often related to different syndromes.

5.2.4 Periodontium

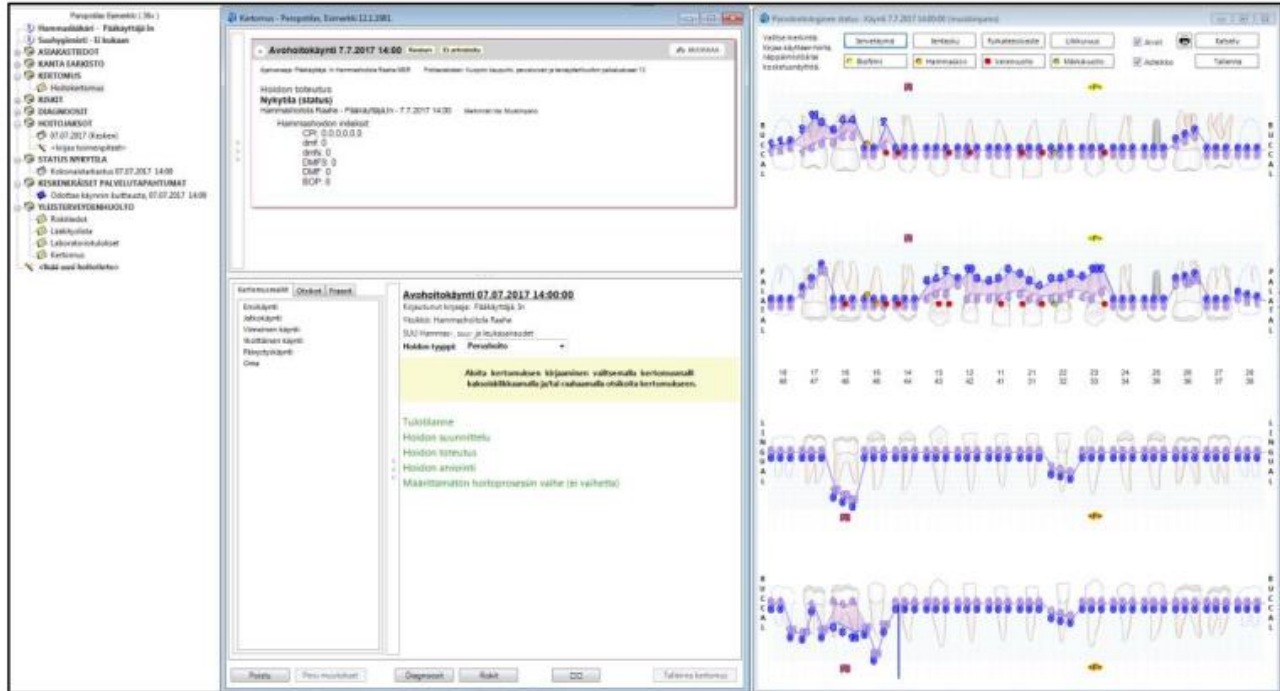
During the examination, each patient also receives a periodontal examination. The findings are recorded in WinHIT. This examination includes measuring the depth of gingival pockets, gingival recession, gingival bleeding and their locations, furcation lesions and mobile teeth. The examination is done on all teeth.

5.2.4.1 Depth of Gingival Pockets, Gingival Recession and Bleeding Gingiva

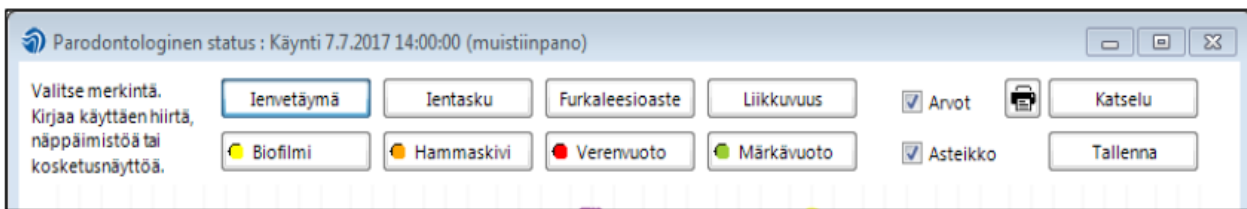
A complete periodontal examination (pocket depths, BOP, tooth plaque, dental calculus, gingival recessions, furcations and tooth mobilities) should be made for all patients starting in the 8th grade of upper comprehensive school. Findings are documented on six surfaces of the tooth: buccal, distobuccal, mesiobuccal, palatinal/lingual, distopalatinal/distolingual and mesiopalatinal/mesiolingual. When measuring depths of gingival pockets, remember the axial orientation of a measuring instrument.

While measuring the depths of gingival pockets also record any gingival bleeding. Bleeding on probing or BOP % is the number of bleeding surfaces divided by the number of all the surfaces x 100. Possible suppuration is documented separately.

Periodontal status is registered by clicking the function buttons (e.g. bleeding) or by dragging with mouse pointer (e.g. gingival pockets) in the status view.



Picture 9. Periodontal status in WinHIT. Source: http://www.innet.fi/help/wp-content/uploads/2017/08/20170707_WinHIT_parodontologinen_status.pdf



Picture 10. Function buttons in WinHIT. Source: http://www.innet.fi/help/wp-content/uploads/2017/08/20170707_WinHIT_parodontologinen_status.pdf

Ienvetäymä = Gingival recession

Ientasku = Gingival pocket

Furkaatioleesioaste = Grade of furcation lesion

Liikkuvuus = Mobility

Biofilmi = Biofilm

Hammaskivi = Calculus

Verenvuoto = Gingival bleeding

Märkävuoto = Suppuration

Furcation lesion stages are recorded from I to IV:

Grade I: Incipient lesion. Suprabony pocket and slight bone loss in the furcation area.

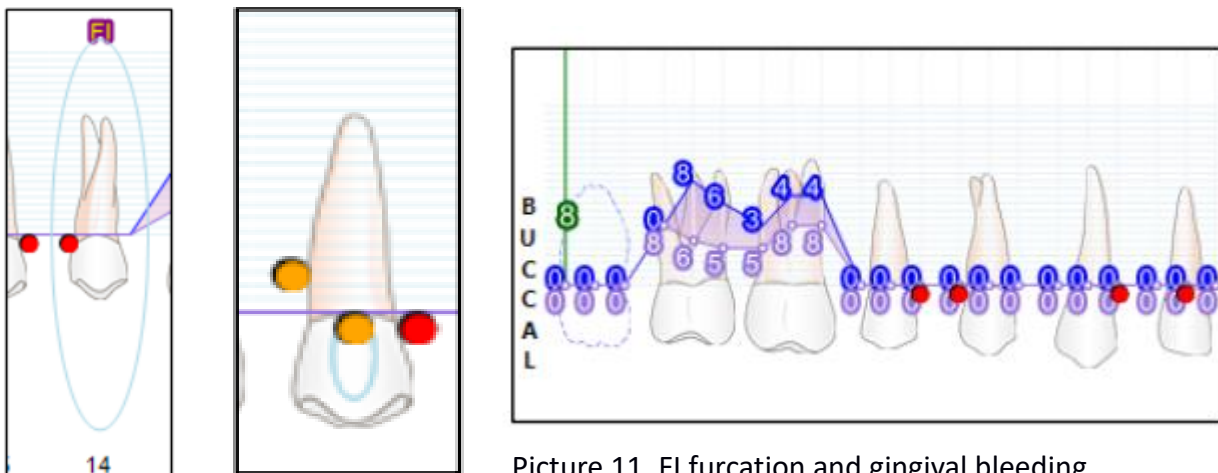
Grade II: Loss of interradicular bone and pocket formation but a portion of the alveolar bone and periodontal ligament remain intact.

Grade III: Through-and-through lesion.

Grade IV: Through-and-through lesion with gingival recession, leading to a clearly visible furcation area.

There are two options for recording tooth mobility. Functional mobility (<F>) is caused by occlusion, passive mobility (<P>) is mobility without occlusion related causes.

Calculus can be recorded either as supragingival or subgingival.



Picture 11. FI furcation and gingival bleeding.

Picture 12. Subgingival and supragingival calculus with gingival bleeding.

Picture 13. Suppuration, gingival recession and pockets with gingival bleeding.

Source: http://www.innet.fi/help/wp-content/uploads/2017/08/20170707_WinHIT_parodontologinen_status.pdf

5.2.4.2 CPI

The CPI index (community periodontal index) can be used for evaluating the need of treatment. The CPI index is documented from three areas according to the worst tooth in the jaw sextant.

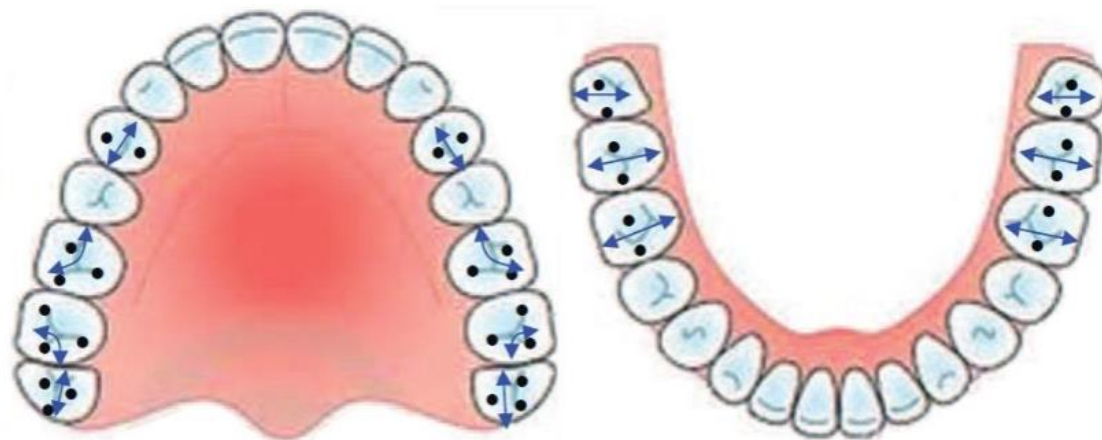CPI index indicators are gingival bleeding, calculus and deepened gingival pockets. The WHO gingival pocket measuring instrument has a 0.5 mm ball tip, where the black zone is between 3.5–5.5 mm.

Periodontal status	CPI
Healthy, no need for treatment	0
Gingival bleeding	1
Calculus, no pockets	2
Pocket(s) 4–5 mm	3
Pocket(s) > 6 mm	4
Not registered (< 3 teeth)	x

Chart 4. CPI.

5.2.4.3 Classifications of Furcation Lesions and Tooth Mobility

For a tooth with multiple roots, furcation is the part where roots separate. Periodontitis that has spread to the furcation area is called a furcation lesion. Molars and maxillary first premolars are examined to determine the class of a furcation. The lesion is documented in the status, and classes and surfaces are separately documented in the patient record. The presence of a furcation lesion considerably worsens the prognosis.



Picture 14. Furcations. Source: Carranza's Clinical Periodontology 11th ed.

Furcation lesions are divided into four categories of severity based on horizontal tissue loss.

Furcation can be felt with a probe, horizontal tissue loss < 3 mm	I
Horizontal tissue loss > 4 mm	II
Horizontal tissue loss penetrates through furcation	III
Horizontal tissue loss penetrates through furcation and furcation roof is exposed	IV

Chart 5. Furcation categories.

Mobility of teeth is examined for example with the handle of a mirror as the tooth is supported from the other side.

< 1 mm horizontally	1st degree
> 1 mm horizontally	2nd degree

Chart 6. Tooth mobility.

5.2.4.4 Aetiology and Diagnosis of Periodontitis

Periodontitis is a chronic disease in which at least two teeth that are not adjacent have a gingival pocket depth of 4 mm or more and tissue loss of 2 mm and or more.

In local periodontitis, less than 30 % of teeth are exposed to the disease. In generalised periodontitis exposure is over 30 %. In the mild form of periodontitis tissue loss is up to 3 mm. In moderate disease tissue loss is in between 3–4 mm and in its severe form tissue loss is 4 mm or more.

General health and periodontitis influence each other. For example, type I diabetes and immunosuppressive diseases predispose to periodontitis. Many medications, such as those used to treat immunosuppression, hypertension and epilepsy, influence gingiva. For example, these can lead to gingival hyperplasia.

The duration and amount of smoking affects the severity of periodontitis, the degree of tissue loss and the outcome of the treatment.

Periodontitis is not a hereditary disease but the tendency to have periodontitis is hereditary.

Periodontitis also occurs in children and young people, so this must be taken into consideration when treating them.

According to the new 2019 periodontitis classification system, individual staging and grading for each patient should facilitate the identification, treatment and prevention of the disease in the future.

Staging a periodontitis patient refers to the severity and extent of destroyed and damaged tissues of a

patient. Staging also includes assessment of treatment, factors that affect its complexity and outcome in the long term.

Grading a periodontitis patient refers to the assessment of future risk of periodontitis progression and therapeutic responsiveness. Assessment must include systemic diseases' impact on tissue healing and enable systemic monitoring in co-operation with medical doctors.

Periodontitis stage		Stage I	Stage II	Stage III	Stage IV
Severity	Interdental CAL at site of greatest loss	1 to 2 mm	3 to 4 mm	≥5 mm	≥5 mm
	Radiographic bone loss	Coronal third (<15%)	Coronal third (15% to 33%)	Extending to middle or apical third of the root	Extending to middle or apical third of the root
	Tooth loss	No tooth loss due to periodontitis		Tooth loss due to periodontitis of ≤4 teeth	Tooth loss due to periodontitis of ≥5 teeth
Complexity	Local	Maximum probing depth ≤4 mm	Maximum probing depth ≤5 mm	In addition to stage II complexity: Probing depth ≥6 mm	In addition to stage III complexity: Need for complex rehabilitation due to:
		Mostly horizontal bone loss	Mostly horizontal bone loss	Vertical bone loss ≥3 mm Furcation involvement Class II or III Moderate ridge defect	Masticatory dysfunction Secondary occlusal trauma (tooth mobility degree ≥2) Severe ridge defect Bite collapse, drifting, flaring Less than 20 remaining teeth (10 opposing pairs)
Extent and distribution	Add to stage as descriptor	For each stage, describe extent as localized (<30% of teeth involved), generalized, or molar/incisor pattern			

Picture 15. Staging a Periodontitis Patient.

<https://onlinelibrary.wiley.com/doi/epdf/10.1111/jcpe.12945>

Periodontitis grade		Grade A: Slow rate of progression	Grade B: Moderate rate of progression	Grade C: Rapid rate of progression	
Primary criteria	Direct evidence of progression	Longitudinal data (radiographic bone loss or CAL)	Evidence of no loss over 5 years	<2 mm over 5 years	≥2 mm over 5 years
	Indirect evidence of progression	% bone loss/age	<0.25	0.25 to 1.0	>1.0
		Case phenotype	Heavy biofilm deposits with low levels of destruction	Destruction commensurate with biofilm deposits	Destruction exceeds expectation given biofilm deposits; specific clinical patterns suggestive of periods of rapid progression and/or early onset disease (e.g., molar/incisor pattern; lack of expected response to standard bacterial control therapies)
Grade modifiers	Risk factors	Smoking	Non-smoker	Smoker <10 cigarettes/day	Smoker ≥10 cigarettes/day
		Diabetes	Normoglycemic / no diagnosis of diabetes	HbA1c <7.0% in patients with diabetes	HbA1c ≥7.0% in patients with diabetes
Risk of systemic impact of periodontitis ^a	Inflammatory burden	High sensitivity CRP (hsCRP)	<1 mg/L	1 to 3 mg/L	>3 mg/L
Biomarkers	Indicators of CAL/bone loss	Saliva, gingival crevicular fluid, serum	?	?	?

Picture 16. Grading a Periodontitis Patient.

<https://onlinelibrary.wiley.com/doi/epdf/10.1111/jcpe.12945>

5.2.4.5 Treatment Plan for Periodontitis and Its Prognosis

The treatment plan includes the following: patient’s good oral care, patient’s motivation to care for their teeth, removal of calculus, removal of retentive factors such as excessive filling materials, optimizing contacts of restorations, follow up on patients’ home care and motivation as well as continued treatment to maintain good oral health.

Prognosis must be taken into consideration when making a treatment plan, and ICD-10 codes are determined for anti-infective treatment. ICD codes are based on gingival pocket depths and the extent of treatment (see attachment: ICD-10 codes).

Good prognosis	Controlling etiological factors and adequately supporting periodontological tissues enable relatively easy maintenance for the patient and clinician.
Fair prognosis	Approx. 25 % attachment loss, FII (location and depth of lesion allow maintenance if the patient is motivated).
Questionable prognosis	50 % attachment loss, FII (location and depth of lesion enable maintenance, but it is more difficult).
Poor prognosis	> 50 % attachment loss, bad crown and root ratio, shape of the root is bad, FII (location and depth of lesion make cleansing more difficult) or FIII; 3rd degree mobility; root concavity.
Hopeless prognosis	Inadequate attachment to maintain health, comfort and function.

Chart 7. Prognosis of periodontitis.

Good/fair prognosis: An extensive periodontal treatment and maintenance treatment will bring a good result. Future loss of periodontal tissue is unlikely.

Questionable prognosis: Factors that influence the status of the tooth locally and/or systematically may or may not be controlled. If these factors can be controlled the status of the attachment tissue can be stabilised with extensive periodontal treatment. If these factors cannot be controlled, subsequent loss of periodontal tissue is likely.

Poor prognosis: Local and systematic factors cannot be controlled. Extensive periodontal treatment and maintenance treatment will most likely not prevent loss of attachment tissue.

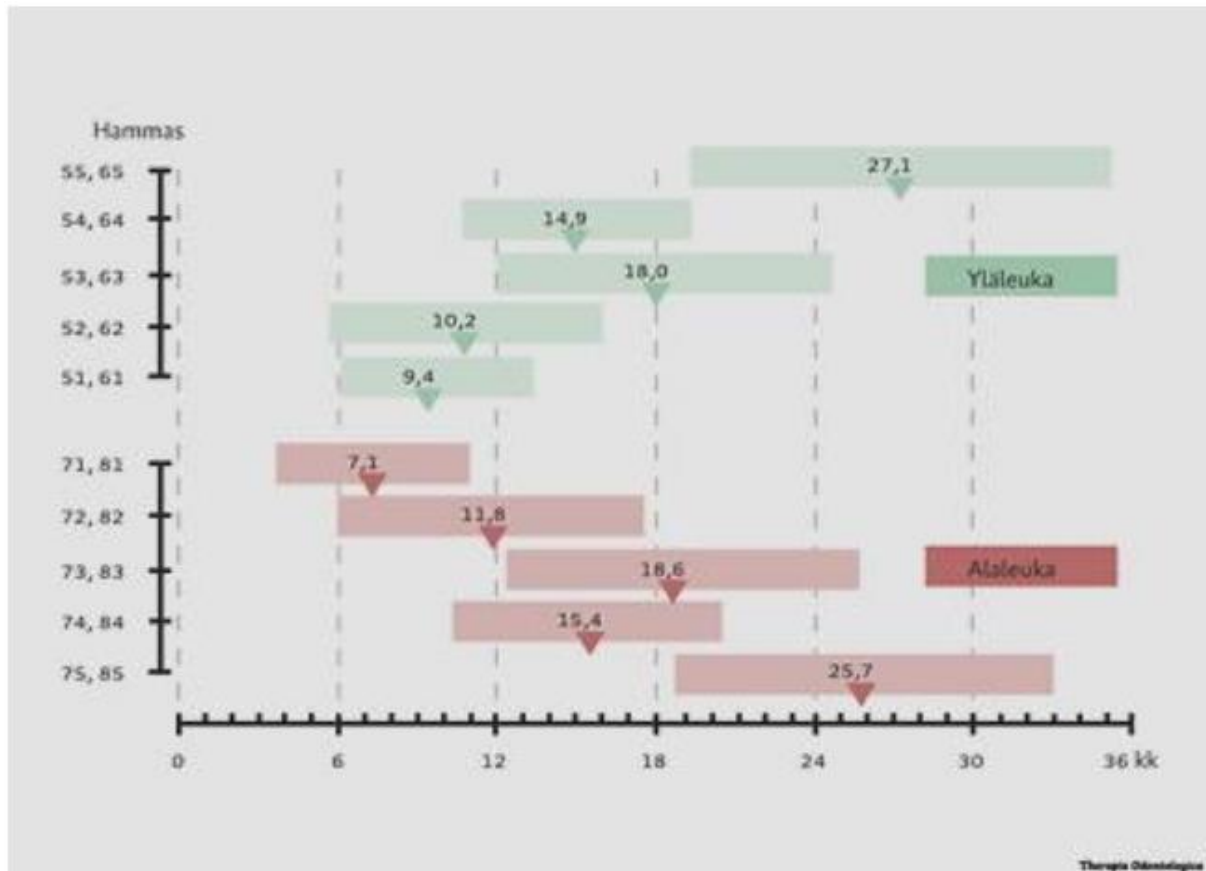
Hopeless prognosis: Tooth must be extracted.

5.2.5 Occlusion in Childhood and Adolescence and Evaluating the Need for Orthodontics

In examining children and the adolescent, it is vital to pay special attention to the stage of their dental eruption sequence and also to the need for orthodontics.

5.2.5.1 Eruption of Deciduous Teeth


The first deciduous tooth usually erupts at the age of six months. All deciduous teeth should erupt by the age of three years.



Picture 17. Order of eruption for deciduous teeth, average age of eruption and standard deviation (± 2 SD) in Finnish children – including both girls and boys. Hammas – tooth, kk – months. Source: Therapia Odontologica.

5.2.5.2 Eruption of Permanent Teeth

Permanent first molars and first and second incisors erupt at the age of 6–8 years. This is called the first turnover. Eruption starts in the mandible. The second turnover follows with eruption of the canines in the mandible and first premolars in the maxilla. After this the rest of the teeth erupt. Second molars are last to erupt at the age of 12 years. The wisdom teeth erupt at around the age of 18–20 years.



Picture 18. Order of eruption for permanent teeth, average age of eruption and standard deviation (± 3 SD) in Finnish boys (green intact line) and in girls (red intermittent line). Source: Therapia Odontologica.

5.2.5.3 Screening Chart for Orthodontics

The chart below can be used to evaluate the need for orthodontics. In the underlined cases an orthodontist must be consulted.

Turn over stage	Deciduous	I	II	Finished
Molar relation	AIII	AI	K	All
Overjet	< 1 mm	1.5 mm	> 6 mm (d. 11 mesial border)	> 6 mm (d. 11 mesial border)
Overbite	Open bite (< 0 mm)	Tooth contact	Gingival contact (d. 11 mesial border)	
Width relations	Crossbite	Normal	Scissor bite	
Dental arches	Tight	Space normal	Wide diastema	Abnormal positioning
Eruption	Abnormal (6 months) → panoramic film	Abnormal (6 months) → panoramic film	Normal	Hypo/hyperdontia
Upper canine palpation 8–12 yrs	n/a	Palpable	Not palpable → panoramic film	Right and left side difference → panoramic film

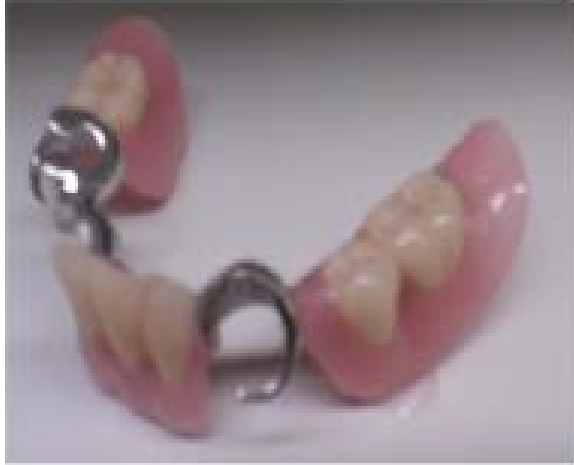Chart 8. Orthodontic treatment screening chart. Source: specialised dentist Susanna Karsila.

5.2.6 Prosthetics

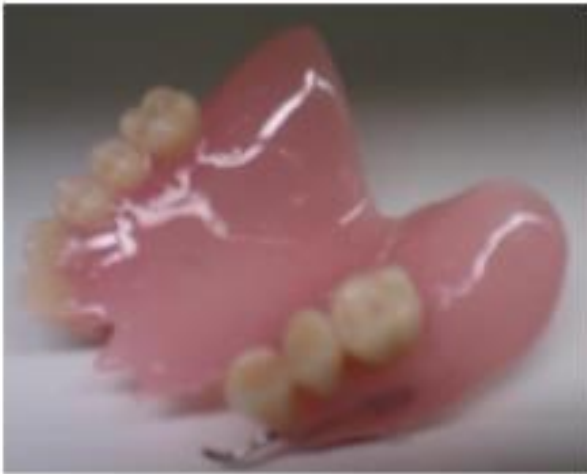During the early stages of clinical training your patient may need prosthetics. Therefore, it is necessary to be familiar with different types of prosthetics. The need for prostheses is taken into consideration when planning treatment after the initial examination.

5.2.6.1 Removable Prostheses

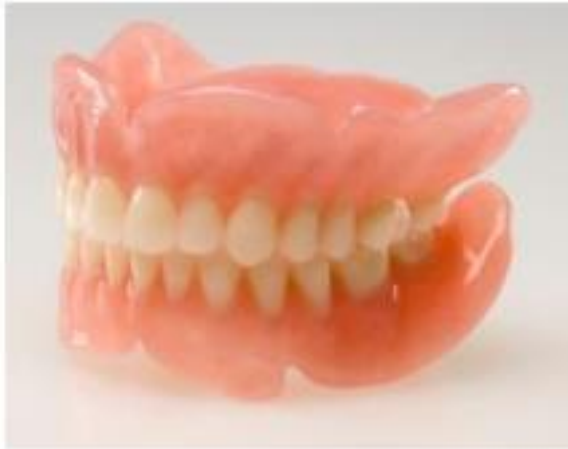The most common removable prostheses are partial clasp prostheses, acrylic partial prostheses and complete prostheses.



Picture 19. Partial clasp prosthesis. Source: Piia Uusitalo.



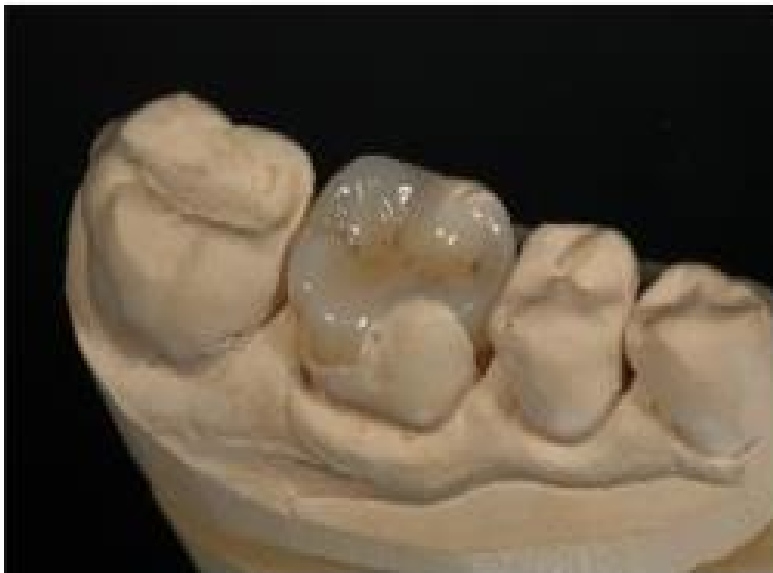Picture 20. Acrylic partial prosthesis. Source: Piia Uusitalo.



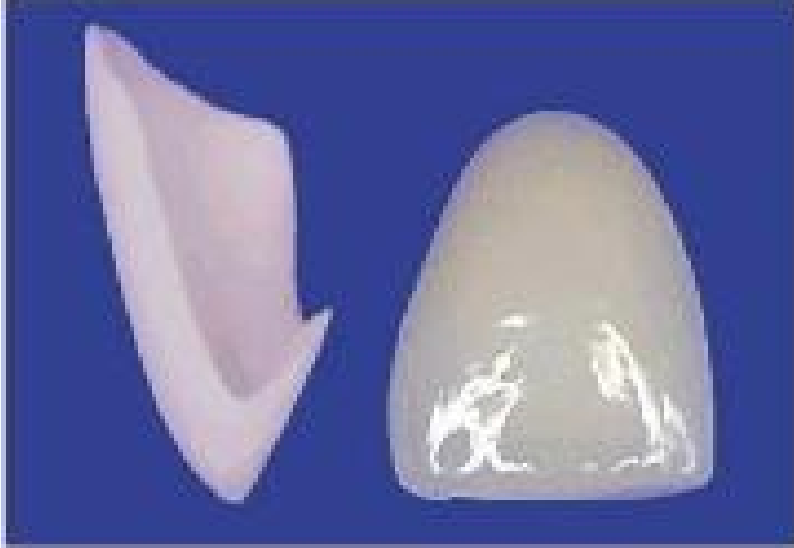Picture 21. Complete prostheses. Source: <http://dundasdentureclinic.com/full-dentures-2/>.

5.2.6.2 Fixed Prostheses

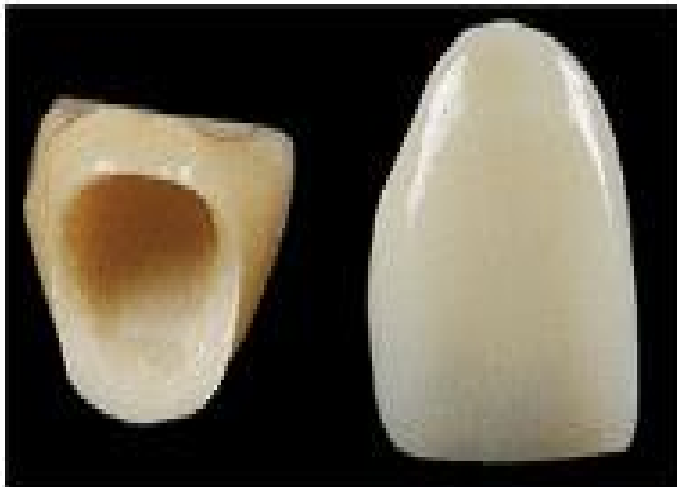The most common fixed prostheses are partial crowns, porcelain laminate veneers, porcelain crowns, implant crowns, bridges and implants.



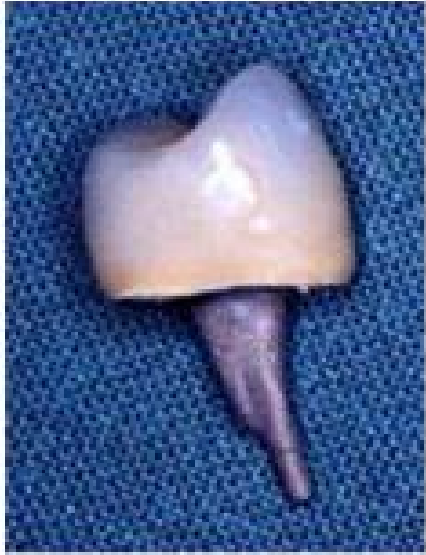Picture 22. Partial crown. Source: <http://www.lindent.fi/sivut/tuotteet>.



Picture 23. Porcelain laminate veneers. Source: <http://www.lindent.fi/sivut/tuotteet>.



Picture 24. Porcelain crown. Source: <http://www.dentalimplant-abroad.co.uk/dental-crowns-abroad.php>.



Picture 25. Post crown. Source: lectures by Johanna Tanner.



Picture 26. Bridge with one replaced tooth. Source: <http://www.lindent.fi/sivut/tuotteet>.



Picture 27. Implant. Source: <http://www.aivankuinluonnollisethampaant.fi/fi-FI/fi-FI/Tietoja-hammasimplanteista/Hammasimplantin-osat150813>.

5.3 Supplementary Examinations

5.3.1 Radiology

As needed, Bite Wing (BW), periapical, panorama or CBCT imaging can be taken.

There needs to be a clear indication for every x-ray. A teacher needs to approve every x-ray before they are arranged. All x-rays need to be recorded in the x-ray room in the department of radiology on the 2nd floor in Dentalia. The report needs to be approved by the teacher in charge of the department.

In most cases x-rays are not carried out on pregnant patients.

5.3.1.1 BW and Periapical Imaging

BW imaging is indicated where there is a need for more detailed caries diagnostics. For example, in cases of approximal caries.

Periapical imaging is used in planning and executing root canal treatment and for more detailed information on panoramic imaging.

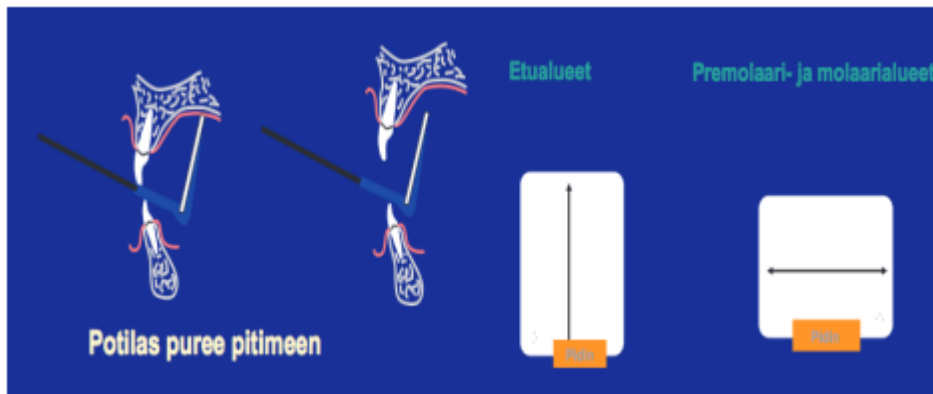
Images can be taken in the X-ray room or in the endo/on-call units (7, 9, 11, 13, 15, 16, Endo 1–4).

Film discs and disc holders are found in the X-ray room and endo cabinets. The film disc should be placed into the protective plastic cover immediately (black against black) which is then put into the disc holder (text against text).



Picture 28. BW and anterior and posterior periapical disc holders. In a position for sector 1 imaging.

Technique:



Picture 29. Patient bites holder. Incisor area. Premolar and molar areas.

1. Patient sits back straightened and neck supported.
2. Remove any detachable prosthetics and metals around the area of interest such as piercings and glasses.
3. Occlusal surfaces should be parallel to the floor.
4. Place thyroid collar to protect the thyroid.

5. Place X-ray tube near head.
6. Insert film in the mouth:
 - Ask patient to bite the film holder.
 - Film disc needs to be parallel with the long axis of the tooth.
 - In periapical image, the tooth and 2–3 mm of the surrounding tissue needs to be seen.
 - In BW image, upper and lower teeth's marginal border needs to be seen (as well as canines' distal surface and the mesial surface of the tooth that is most distal).
 - If the film holder's rod is not in line with the occlusal plane, the film needs to be moved closer to midline (sometimes as far as in the middle palate).
7. X-ray beam needs to be perpendicular to the long axis of the tooth and as close to the patient as possible. Ensure that patient is biting teeth together. Now ask the patient to not to move.
8. From the X-ray control device choose correct imaging value for the right tooth. Take an X-ray by pressing the button until you hear a beep (stand behind the wall in the X-ray room).
9. Sign in to WinHIT: Asiakas (patient)/röntgen. Romexis programme opens (patients name can be seen in upper right-hand corner).
10. Press 2D in the left-hand corner, then press "Uusi tutkimus", in the comment section write for an example d. 46 root canal treatment.
11. Choose TWAIN Capture/Vista Scan -kuvaus. Wait for the scanning window to open and for a "Device ready" text to appear. Now scanning is booked for you. X-ray room has its own scanning device and endo/on-call units scanning device is located between units 15 and 17. If "Couldn't connect" text appears it means another student booked the device. Wait a moment and then try again.
12. Once "Device ready" text appears set the cassette that holds the film discs into cassette passage. You can drop the cassette when 3 green lights are on.



Picture 30. Film and cassette.

13. After scanning images appear in the preview window. You can turn the image by pressing "Orientation". Mark all the teeth seen in the BW in the dental chart. In a periapical image mark only the tooth that is of interest. Press "OK". If you press "Peruuta" (cancel) images will disappear!
14. In the end press "Sulje" in the scanning window. This frees the scanning device to be used by another student.
15. Wait for the scanner to spit out film discs. Assemble cassette and return film discs. Hold film discs only from the edges.

5.3.1.2 Panoramic Imaging

For every adult patient receiving all-inclusive treatment there needs to be an up-to-date panoramic image. The panoramic image can be a maximum of 5 years old. The panoramic image is used to plan and execute treatment. Always check in WinHIT whether the patient has an up-to-date panoramic image.

Panoramic images taken in the Imaging Centre of Southwest Finland will appear in Carestream. But it is possible there is an older image in Romexis.

1. A referral is needed for every panoramic image.
2. Patient will book the appointment themselves from clinic's office.
3. In the x-ray room patient is informed how the imaging is done. Patient is asked to remove any detachable prosthetics, glasses and jewellery.
4. New end piece is changed into the biting stick. Patient is asked to stand straight, hold on to the handlebars and bite biting stick. Patient's head is positioned correctly with the help of the lights.
 - Head is straight horizontally and vertically.
 - Middle light is in the middle of the patient's face.
 - Another light is in between dd. 22–23.
5. Patient is then asked to lift tongue to roof of the mouth and to hold it there for approximately 7 seconds.
6. X-ray assistant and everyone else in the room will go behind protective cover. Image is then taken.

5.3.1.3 X-Ray Reporting

X-ray report:

- Compares the clinical findings to the x-ray findings. It should include the indication for taking the image.
- Compares images to possibly earlier images.
- Viewing of x-ray images and reporting takes place in the radiology/x-ray room on the 2nd floor in Dentalia – all x-ray images need to be reported in the WinHIT's x-ray page.

5.3.2 Saliva Tests

Among the adult population, reduced salivation (hyposalivation) is common. Subjective dry mouth sensation experienced by the patient is called xerostomia and objectively measured low saliva secretion is called hyposalivation. Secretion rate of 0.7ml/min for paraffin-stimulated saliva and 0.1ml/min resting saliva are generally considered threshold values of hyposalivation. In Finland, the most frequently used Streptococcus mutans and Lactobacillus saliva test manufacturing has stopped. However, measurement of resting saliva and stimulated saliva could easily be performed. The collecting circumstances should be standardized and the collection time for the stimulated saliva is 5 min and for resting saliva is 10 min.

Before saliva tests, the patients should not eat or drink or have a chewing gum for at least one hour. For collecting the saliva, the patient should seat bend forward, and be warned not to swallow any saliva accumulating in the mouth. You can provide a gauge glass or a disposable cup for saliva collection. Patient will be draining the saliva to the cup for 10 min.

After collecting the resting saliva, you can collect stimulated saliva. Patient will chew a paraffin chewing piece for 1 min. During the paraffin chewing the saliva accumulated in the mouth could be swallowed. After that, the patient will continue to paraffin chewing, and the saliva accumulated in the oral cavity is drained 1-3 times/minute into a gauge glass or disposable cup.

After collecting the saliva, the time of the test, and the amount of resting and stimulated saliva ml/min should be written clearly. While measuring the saliva amount, use the liquid surface as a reference, not the foamy part of the saliva.

6 Home Care of the Patient

In the beginning of the treatment patients should be informed that each appointment can take two hours or more. Delays are also possible. It is also good to warn patients about the lack of parking spaces around Dentalia.

In the dental practice clinic students should conduct themselves appropriately. Students should behave in a friendly manner towards staff and patients. Inappropriate behaviour from the patient is not tolerated. If such a situation arises contact the teacher. In certain cases, a patient may be required to attend elsewhere.

The following chapter will cover treatment of attachment tissue disease, the main principles of preparative caries treatment, root canal treatment and stages of tooth extraction.

6.1 Instructions for Patients' Home Care

As needed, patients should receive personal home care guidance. Any guidance that is given should be clearly documented in the patient record. Demonstrate correct brushing and flossing techniques in front of a mirror and allow the patient to practice under supervision. Give advice on suitable oral care products. Inform the patient about a tooth friendly diet, the use of xylitol products and of the importance of using fluoride toothpaste. The aim is to motivate the patient to efficient home care and inform them of the importance of good oral health. If appropriate, also explain about the dangers of smoking. Any anti-infective treatment should commence/be completed within the first 2–4 weeks.

6.2 Informing Patients of the Dangers of Smoking

It is the responsibility of the student to discuss smoking and give information on its negative effects on oral health. There are leaflets about smoking at the clinic.

Healthcare centres in Turku run a smoking cessation programme. It is aimed at residents of Turku who are over 18 years old and is free to attend. To take part in the programme, patients need to contact their local health centres.

6.3 Periodontal Treatment

6.3.1 Treatment of Gingivitis

In caring for gingivitis, patient motivation and home care guidance play a key role. It is important to show the patient their problem spots (usually lingual surfaces, molars distal surfaces and marginal gingiva). Calculus is removed carefully as well as possible excessive filling materials. Poor contacts need to be corrected. Once home care is more effective, the results need to be followed up. It is important also to give positive feedback to the patient when they are succeeding. Subsequent treatment and the interval between re-call appointments is decided according to individual needs.

6.3.2 Anti-Infective Treatment of Periodontitis

Treatment begins with providing information to the patient and providing guidance on home care. This is followed by removal of calculus, removal of excessive filling material and removal of caries along the gingival margin. The aim is to motivate the patient to a higher standard of home care. The results of improved home care need to be followed up. After all the calculus is removed in the subgingival area, a follow up appointment is given in 4–6 weeks to assess the treatment and results.

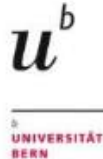
6.3.3 Re-Evaluation, Epicrisis and Periodontal Risk Assessment

A re-evaluation of the patient's treatment is carried out 4–6 weeks after anti-infective treatment has ended. Prior to this the student will conduct a new periodontological examination and will book an appointment time with a teacher via Moodle. During this re-evaluation, the response to the treatment is evaluated, the need for further treatment is determined and where appropriate there is the opportunity to contemplate reasons why the response to the received treatment was inadequate. If needed, microbial samples can be taken from the periodontal pocket and antimicrobial medication prescribed.

During the re-evaluation, a medical case summary is written about the patient. The medical case summary briefly explains the patient's initial condition, summarises the treatment received and describes caries and periodontal statuses. Also, the need for further treatment is described, as well as the prognosis and any factors that will influence the prognosis. If there is no need for ongoing

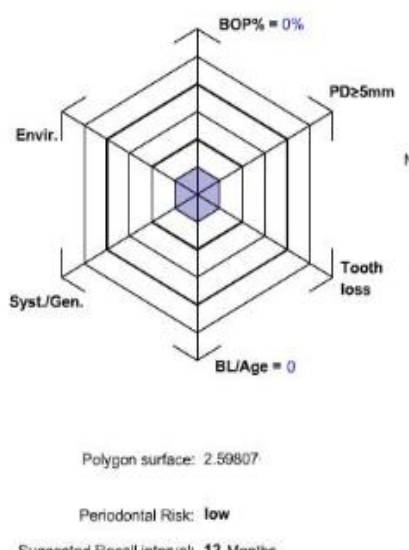
treatment, a maintenance treatment interval is determined using the Periodontal Risk Assessment (PRA) chart:

Department of Periodontology
Periodontal Risk Assessment



UNIVERSITÄT
BERN

Patient Last Name First Date



Polygon surface: 2.59807

Periodontal Risk: **low**

Suggested Recall interval: **12** Months

Age:

Number of teeth and implants: (1 - 32)

Number of sites per tooth / implant: 2 4 6

Number of BOP-pos. sites: of 64

Number of sites with PPD ≥ 5mm:

Number of missing teeth:

% Alveolar bone loss (estimated in % or 10% per 1mm): %

Syst./Gen.: Yes No

Envir.: Non smoker (NS)
 Former smoker (FS)
 Occasional smoker (OS)
 Smoker (S)
 Heavy smoker (HS)

Picture 31. Periodontal Risk Assessment (PRA) chart. Source: <http://www.perio-tools.com/pr/en/>.

6.3.3.1 How to Take a Microbial Sample from a Gingival Pocket

A gingival pocket sample can be taken during clinical practice when specialised dentists in periodontology or oral pathology (Leimola-Virtanen, Raunio, Varrela, Tuominen, Willberg) are present.

ALWAYS ASK A TEACHING CLINIC ASSISTANT FOR AN INVOICE PERMISSION.

Immuno Diagnostics, which analyses bacteria, uses the invoicing form to charge the city of Turku (i.e. the patient does not pay!). The form is put into an envelope with the sample and the order form.

Sampling equipment and instructions are found in the same cabinet as saliva tests. Take the

equipment (Immuno Diagnostics micro-IDent® (a blue plastic case), printed instructions, Immuno Diagnostics manual and a brown, padded pouch) for sending the sample.

Tell the patient why the microbiological sample is taken, justify the need and the advantages, and also the price of the microbiological sample.

The sample is taken with a teacher's help or in teacher's supervision.

Sampling instructions, information and research results about microbiological sampling and the general guidelines for the interpretation of results are in the instruction hand-out and in the manual.

1. Always take the pooled bacterial sample of five periodontopathogens. A pooled sample means that the samples that have been taken from individual teeth and gingival pockets are put to the same conveyor pipe.
2. Dry the sample area of saliva with an air spray. Put the small saliva ejector in the mouth. Remove the visible supragingival plaque with a curette from the sample area. Isolate the area with cotton rolls.
3. Put one sterile paper stud from the package into the gingival pocket at a time and let the stud soak for at least 10 seconds so that the bacteria will have time to be absorbed into the stud. Avoid saliva contamination!
4. Put the paper stud immediately to the conveyor pipe.
5. Finally, put the test tube into a blue plastic case finally and the case to a brown envelope together with an order form and an invoice permit.
6. Fill the order form carefully (see the filling instructions from the model form):

- Sending dentist: Turun kaupungin hyvinvointitoimiala

Suun terveydenhuolto

Opetushammashoitola

Lemminkäisenkatu 2, 20520 Turku

Puh. 266 06 11

- Information about the patient.
- Select the sample type: indication of 5 periodontal bacteria.
- Fill other questions of the form carefully.
- Cross out "Valitse laskutuslupa" and "Nimi" and write LASKUTUSLUPAKAAVAKE.
- Reporting of results: write POSTITSE LÄHETTÄJÄN OSOITTEESEEN.

Record the procedures in the patient's file, WinHIT, microbiological sample SBA00, in the explanation text "Ientaskunäyte" and teeth. Invoice normally, the invoice goes home to the patient.

Sample results will come by post to the sending teacher. Go through the results with the teacher and copy the sample results into the patient's file in WINHIT section "Hoitosuunnitelma".

6.3.3.2 Antibiotics in Periodontal Treatment

- Always take a microbial sample before prescribing antibiotic medication.
- If home care is satisfactory, oral hygiene is good and the microbe sample has excessive amounts of A. actinomycetemcomitans or P. gingivalis, a course of antibiotics may be indicated.
- Antibiotics are commenced on the same day as the mechanical removal of calculus.

Metronidazole (Flagyl®) 400 mg x 3, 5–7 days

- Primary microbe medication, especially if the sample has *T. denticola*, *T. forsythia* or *P. gingivalis*.
- Not during first trimester of pregnancy or during breastfeeding.
- No concurrent alcohol or disulfiram (Antabus) use.
- Not to be used if patient is on any of the following: warfarin, carbamazepine, lithium, cyclosporine, amiodarone or if they have neurological malfunction.

Metronidazole 400 mg + Amoxicillin 500 mg x 3, 5–7 days

- Especially good if the sample has a profuse growth of *A. actinomycetemcomitans* bacteria.
- Not suitable if the patient is allergic to penicillin.
- See above for more.

Doxycycline 100–150 mg x 1 (first dose x 2), 5–7 days

- In case of penicillin allergy and profuse growth of *A. actinomycetemcomitans* in the sample.
- Not suitable during pregnancy, for children or for patients with liver disease.
- Avoid sun exposure.

6.3.4 Periodontal Surgery

Indications:

- Persistent gingival pockets found on re-evaluation. The prognosis can be improved with periodontal surgery.
- Surgery would enable cleansing of difficult teeth surface (for example furcations, vertical bone pockets, concave root surfaces).
- Removal of granulation tissue.
- In lower molars showing progression from III class furcations to IV furcations. This is for patients with good home care.

Contraindications:

- Severe concomitant disease (for example leukaemia).
- Myocardial infarction in preceding 6 months.
- Excessive smoking.
- Inadequate home care.
- Acute infection such as influenza, abscess in the mouth, herpes.
- Labile diabetes.
- Radiotherapy.
- Hopeless teeth.
 - Loss of bone tissue more than 2/3.
 - Upper molars with class III furcations unless the treatment procedure includes the removal of one root.

Relative contraindications:

- Smoking.
- Pregnancy (necessary procedures are possible during the 2nd trimester).

Preparing for the procedure:

- Start planning for the procedure by evaluating the patient's suitability and general health. Consider the need for a prophylactic antibiotic.
- Inform the patient during the previous appointment of the procedure's purpose, method and subsequent post-operative treatment.

6.3.4.1 Gingival Curettage

Scraping involves scraping the surface of the gingiva while simultaneously removing calculus.

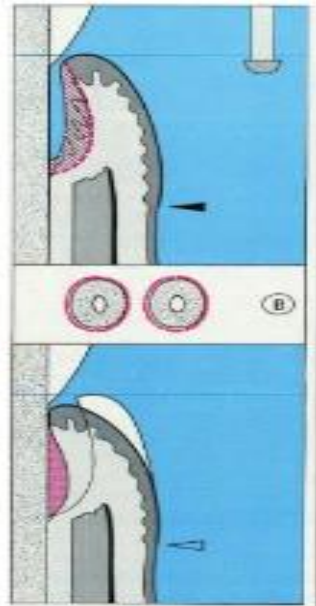
Curettage can only be considered in cases where primary treatment methods are not appropriate!

Indications:

- Single mid-deep pockets on easy surfaces, on already operated pockets and on recurring pockets.

Contraindications:

- Bone pockets on all sides, furcations, fibrotic gingiva, acute abscesses.



Picture 32. Curettage. Source: Carranza's Clinical Periodontology, 11th ed.

Technique:

1. One-minute chlorhexidine (CHX) rinse.
2. Local anaesthesia and isolating the area with cotton rolls.
3. Removal of calculus in supragingival area with ultrasound and hand instruments.
4. Removal of granulation tissue with traditional instruments or with McCall or Syntette instruments.
5. Rinse the gingival pocket with normal saline and then apply pressure (stitching or surgical paste may also be indicated).
6. Home care instructions:
 - No hot food to be consumed on day of procedure.
 - No brushing allowed around the operated area.

- (After one week, removal of paste and stiches and cleansing of the area with a swab moistened in CHX.)
- 7. Two weeks later paste cleansing and going over home care as well as possible new home care instruments (tightening gingiva with a toothpick).

6.3.4.2 Gingivoplasty ECA30

Gingivoplasty is defined as shaping of the gingiva on a small scale by removal of a small piece of gingiva with a disposable knife (or an electric knife) in order to remove hyperplastic gingiva or to make way for a filling.

Indications:

- Hyperplastic gingiva, loose papilla, or to enable application of a filling into a deep cavity.

Contraindications:

- Tightly attached gingiva, all attached gingiva may not be removed!
- If the cavity's margin is under 3 mm from marginal bone. Instead of gingivoplasty, a crown lengthening operation is carried out.
- An electric knife is not suitable for patients fitted with pacemakers.

Instructions:

1. Get the instruments required. A disposable knife (with blade number 15) is found in every unit.
2. One-minute CHX rinse.
3. Anaesthetise the area as well as interdental papilla within the area to minimise bleeding.
4. Mark the incision line with a periodontal probe, paying attention that all the attached gingiva must not be removed.
5. When using a disposable knife, cut in a 45-degree angle along the surgery line (if an electric knife is used see the instructions under gingivectomy).
6. Remove any visible calculus.
7. Post-operative instructions for the patient:

- a. Inform the patient that the operated area can be sore for few days.
 - b. Avoid brushing the area for a week. Rinse with CHX for one minute twice a day for a duration of one week.
8. Document the gingivoplasty in the treatment report.
- For example: D. 46 p:36. To ensure a good filling a hyperplastic gingiva was shaped with an electric knife.

6.3.4.3 Gingivectomy ECA35

Gingivectomy is defined as the removal of gingival tissue with a knife. Please note that an electric knife is not suitable for a patient with a pacemaker.

Indications:

- Fibrotic gingival hypertrophy (idiopathic or induced by drugs).
- Supra-alveolar gingival pockets.
- If a flap surgery is not possible due to smoking or poor oral hygiene, a gingivectomy may lower the gingival pockets. This might however raise concern over aesthetics.

Contraindications:

- Tightly attached gingiva, all attached gingiva may not be removed!
- An electric knife is not suitable in patients fitted with pacemakers.
- Inflammatory gingival hypertrophy.
- Progressing loss of attachment if marginal bone > 4 mm from cementoenamel junction.
- Infra-alveolar gingival pockets, vertical changes in the bone.

Instructions:

1. Get the instruments required. A disposable knife (with blade number 15) is found in every unit, a gingivectomy knife (Kirkland) and papilla knife (Orban) are found in the periodontology room.

2. One-minute CHX rinse.
3. Anaesthetise the area as well as interdental papilla within the area to minimise bleeding.
4. Mark the incision line with a periodontal probe, paying attention that not all the attached gingiva is removed.
5. Removal of gingival collar for example with a curette.
6. The marginal gingival boarder is shaped and thinned as needed to its physiological shape with so called secondary incisions.
7. Remove any appearing calculus and retained plaque.
8. (If needed, use surgical paste. See CoePak instructions.)
9. Post-operative instructions:
 - a. Inform the patient that the operated area can be sore for a few days.
 - b. Avoid brushing the area for a week. Rinse with CHX for one minute twice a day for a duration of one week.
 - c. Reinforce the importance of good self-care during healing.
10. (Removal of periodontal dressing after one week and paste cleansing with fine paste.)
11. Document gingivectomy in the treatment report.

6.3.4.3.1 Use of the Electric Knife

1. The electric knife is found in the nurse's passage.
2. Choose an electrode for the knife:
 - For removal of gingiva, a long loop electrode is most suited or a straight knife.
 - For approximal gaps, a straight electrode is usually most suitable.
 - To control bleeding use a coagulant-ball electrode. If there is difficulty in reaching the area, use an electrode for a straight knife.
3. Turn on the electric knife (green light will switch on).
4. Set the earthing disc on the patient's bare chest.
5. Set the power to cut and coag mode (coag is to stop bleeding).

6. Turn on the electrode by pressing the foot pedal prior to taking the electrode to the tissue (have the power on in the electrode only during treatment).
7. Pull the electrode in a 45-degree angle along the incision line, parallel with the tissue being removed. Cut the tissue in thin layers using a smooth, fast and brushing like motion. Usually it is easiest to cut with a straight electrode and finish off with a loop electrode. BEWARE of touching the surface of a tooth or bone!
8. Suppress bleeding for 1 s. Usually bleeding stops within one or two touches.
9. Let the tissue cool down for 10–15 seconds prior to cutting or suppressing bleeding again.
10. A curette can be helpful in detaching the gingiva.
11. Once the procedure is over, detach the electrode from the tissue, release the foot pedal and remove the earthing disc.

6.3.4.4 Flap Surgery ECA50 or ECA55

An appointment for flap surgery is booked in IRJA with a dentist that has specialised in periodontology (Gürsoy, Leimola-Virtanen, Varrela). Surgery is conducted in a periodontology room in sterile conditions. The student partakes in the surgery in the role of a nurse and writes the surgery report.

Ensure that there is a periapical or vertical BW image of the area.

The patient should be well informed about the procedure during a previous visit.

- Patient may need a sick leave note for work.
- Possible swelling/gingiva retreat/pain in the neck of a tooth.
- CHX may cause colouring, use paste in aesthetically important areas.

Indications:

- After thorough mechanical treatment, gingival pockets remain deep > 6 mm and are hard to cleanse.
- Patient must have good oral home care (BOP/VPI < 20 %).

Contraindications:

- General surgical contraindications, bad prognosis of a tooth, inadequate self-care, pregnancy and acute infection such as influenza or herpes.

Instructions:

1. Local anaesthesia.
2. CHX rinse for 1 minute.
3. Primary, secondary and horizontal incisions (Bard Parker/Blakey/Orban).
4. Lift flap with periosteal elevator and triple bend excavator.
5. Observe exposed area: bone loss and shape, surface of the root, enamel pearls etc.
6. Remove granulation tissue with McCall/Syntette Curette, excavator and/or with tissue scissors.
7. Remove calculus, possible furcation modelling, grind enamel pearls, rinse with saline.
8. (Possible remodelling of bone pockets and chemically treating surface of the root.)
9. Finish flap's inner surface with tissue scissors. Press flap to its place, suture with reabsorbing monofilament thread (Dafilon 5-0/6-0 or Salfi 5-0).
10. If needed, use periodontal dressing CoePak.
11. Post-operative instructions verbally and in writing.
 - No hot food, alcohol, cigarettes or exercise within the same day.
 - Cold compress will reduce swelling.
 - For one week avoid hard food and heavy chewing around the operated area.
 - No brushing around the operated area. However, meticulous brushing everywhere else.
 - CHX rinse after brushing 2 times per day over 2 weeks.
 - Highlight the importance of patient's own good oral care in the healing process.
 - If needed, non-inflammatory painkillers e.g. for 3 weeks, NO acetylsalicylic acid as it increases risk of bleeding.
12. Change periodontal dressing after 1 week.
13. Removal of stitches and periodontal dressing after 2 weeks. Instructions post-operatively: soft brush, gently cleaning in between teeth, and if needed, CHX rinse for one more week.
14. Control in 2-3 weeks.
15. First maintenance appointment in 1-2 months.

6.3.4.5 Operative Report

Operative report is written by the student on the day of the surgery. The report needs to be approved by a teacher before transferring it to WinHIT.

Describe in detail the course of incisions and bone loss.

6.3.4.5. Periodontal Dressing








Use of COE PAK: Use vinyl or nitrile gloves, not latex!

1. The Coe-Pak pack is mixed well with a spatula (for 30–45 s, usually mixed by a nurse, spatula needs to be cleansed after).
2. After mixing wait a while for the dressing to set. Once it starts to warm up take a little bit of Vaseline in your fingers (makes it easier to handle) and shape dressing into a “sausage” approximately 1 cm per tooth.
3. Press the dressing over the treatment area for protection. Do not put dressing over moving mucous membrane. The dressing should not interfere with occlusion. You can use a moistened swab or/and a McCall 17/18 curette to set the dressing.
4. It takes about 30 minutes for the dressing to set after which the patient can eat.
 - Periodontal dressing is changed one week after the procedure and removed after a further 2 weeks.
5. A syntette or curette can be used to assist in the removal. Be careful not to touch soft tissues.

6.4 Restorative Treatment

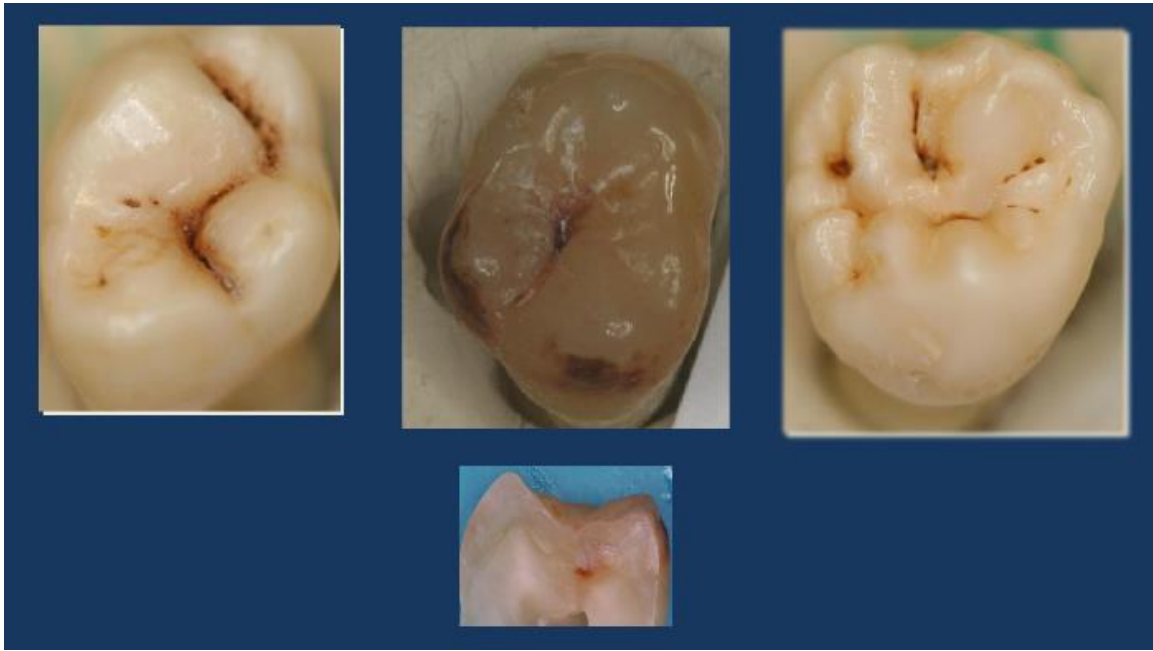
6.4.1 Arrest of Caries Lesions

When treating a patient with caries lesions, the International Caries Detection and Assessment System (ICDAS) categorises lesions from 0 to 6.

0	1	2	3	4	5	6
<u>Sound tooth surface</u>	<u>Lesion appears after 5 secs drying</u>	<u>Visual changes in enamel</u>	<u>Localised enamel breakdown</u>	<u>Underlying dentine shadow</u>	<u>Distinct cavity</u>	<u>Large cavity (more than half of surface area)</u>
						
<u>Sound tooth surface</u>	<u>Lesion in the outermost part of enamel</u>	<u>Lesion in cemento-enamel junction</u>	<u>Lesion in mid one-third of dentine</u>	<u>Lesion in mid one-third of dentine</u>	<u>Lesion in inner one-third of dentine</u>	<u>Lesion in inner one-third of dentine</u>

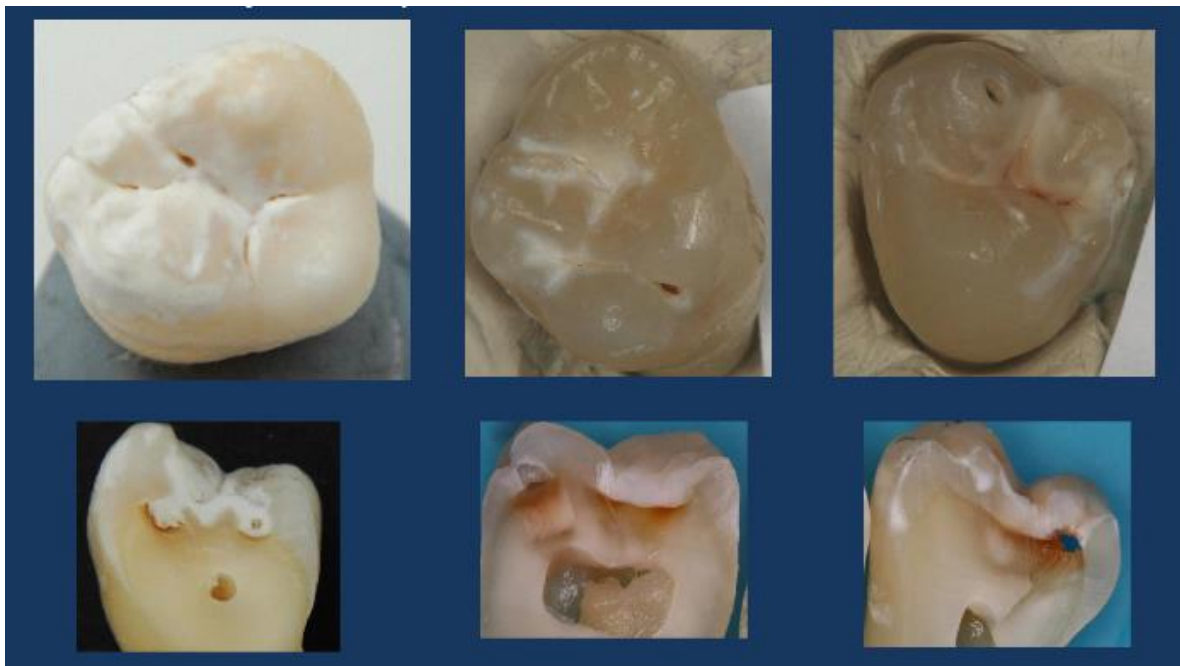Picture 33. ICDAS stages 0–6. Source: Käypä hoito caries treatment guidelines.

Inactive or slowly progressing caries appears as clearly defined lesions that are often dark, hard, smooth and shiny.



Picture 34. Inactive or slowly progressing caries lesions. Source: Käypä hoito caries treatment guidelines.

An active, progressing caries lesion has ill-defined edges and a soft and rough surface with a chalky and matt appearance.



Picture 35. Active caries lesions. Source: Käypä hoito caries treatment guidelines.

Good oral hygiene, low sugar diet, sealants and fluoride all play a key role in arresting a caries lesion. The number of microbes in the oral cavity can be temporarily reduced using chlorhexidine products if needed.

6.4.1.1 Sealants

Indications for using sealants includes a previous deciduous caries, deep fissures in a caries risk patient, and an enamel caries on an occlusal surface which does not yet reach dentine.

Contraindications are poor co-operation, dentine caries and a tooth that is showing symptoms. In the clinic acrylic and glass ionomer sealants are used.

Instructions on how to use ClinPro Sealant acrylic sealant:

1. Pumice cleaning.
2. Etch the enamel with phosphoric acid, wash and dry.
3. Isolate the tooth, for example with cotton rolls.
4. Apply sealant.
5. Light cure.
6. Remove excess with a flame bur, check occlusion and polish with a polishing cup.
7. Apply protective lacquer.

6.4.1.2 Fluoride

Fluoride in moderate dosages protects enamel and prevents formation of cavities by acting as a protective cover over the enamel. Toothpaste is the most important source of fluoride. Teeth need to be brushed twice a day, for a minimum of 2 minutes at a time.

The most important fluoride product used to arrest caries in the practice is varnish. However, it is only allowed to be used a maximum of four times per year.

6.4.2 Restorative Treatment of Caries –Shallow to Moderate Lesions

The shallow or moderate lesions are those which are not reaching inner 1/3 or ¼ of dentin, and there is no risk for pulp exposure. The management strategy of the caries lesions is based on the symptoms, diagnosis, risk assessment and treatment planning. The guiding principles for carious tissue removal are:

To preserve the dental hard tissues

To preserve the pulpal health and avoid pulp exposure

To achieve a good peripheral seal on sound tooth structure.

Therefore:

The caries access should be limited to the defect and should be made just large enough to sufficiently visualize and instrument the carious tooth structure. The access cavity in enamel is prepared with a diamond bur. The peripheral dentine that has caries is removed with a round bur and/or excavator (pulpal walls).

The caries lesion should be first removed peripherally to **hard dentin** to have a 1-1.5 mm sound peripheral tooth structure.

After that moving centrally from hard peripheral region, it is acceptable to leave discoloured caries affected dentin that is **firm** to a hand excavator.

Student needs to show the teacher a cavity, matrix and a finished filling. The teacher will document the different approved stages on a paper attached to the unit wall. A finished filling is documented in the patient file in WinHIT. The student will have codes ready for the teacher to sign them.

6.4.2.1 Treating Deep Caries

When caries extends to pulpal 1/3 or ¼ of dentin and there is a risk of pulpal exposure, these lesions are classified as deep (advanced) caries lesions. The deep caries management options include:

Selective removal to soft dentin

After the cavity access, the caries lesion should be removed peripherally to **hard enamel/dentin** to have a 1-1.5 mm sound peripheral tooth structure to allow a tight seal and placement of a durable restoration.

At the pulpal wall **soft carious tissue** is left over the pulp to avoid exposure and stress to the pulp. Selective removal to soft dentine reduced the risk of pulp exposure compared to nonselective removal to hard or firm dentin.

The final restoration is done at the same appointment using an etch and rinse adhesive and composite restoration.

Stepwise removal

Stepwise excavation is a method of managing deep/advanced dentinal caries lesions to reduce the risk of pulpal exposure by removing the caries in separate appointments with 6 month or longer intervals.

Indications: Deep carious lesion in permanent teeth likely to result in pulp exposure.

Vital pulp, pulpal test (+), no evidence of irreversible pulpitis.

No history of spontaneous or prolonged pain.

Radiographically over $\frac{3}{4}$ through dentin, and no periapical lesions.

Not responsive to percussion.

Patient will cooperate and will come for the follow up.

First stage selective removal to soft dentin

Use rubber dam isolation.

Periphery of the cavity should be at the hard dentin with a clean DEJ providing a 1-1.5 mm wide zone of sound/hard dentin.

At the pulpal wall **soft carious tissue** is left over the pulp to avoid accidental pulp exposure during the second visit.

A layer of Dycal or Pink FUJI Triage as the inner layer directly over the soft dentin to avoid any pulp exposure during the second visit.

After dentin conditioner (polyacrylic acid) treatment, the cavity is restored with a glass ionomer fuji XI OR Fuji IILC IS for functional and aesthetic purposes.

Second stage selective removal to firm dentin 6-12 months later

Confirm the vitality.

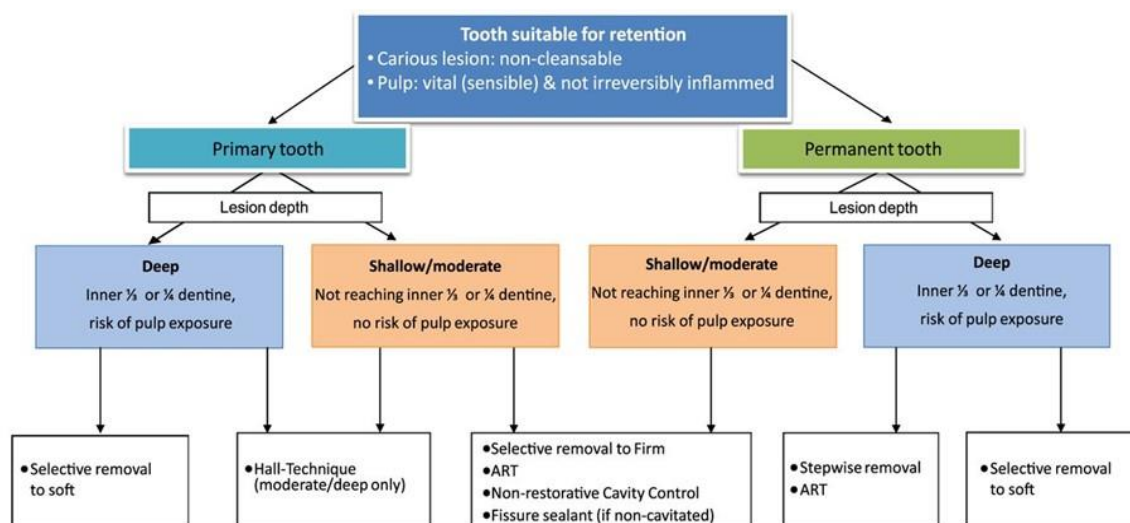
Evaluate the symptoms.

Remove provisional restoration carefully to avoid and accidental pulp exposure.

Selective removal to firm dentin.

Place final restoration as indicated with appropriate material.

Figure. Decision making for noncleansable carious lesions in retainable teeth with vital pulps.



F. Schwendicke et al. ADR 2016;28:58-67



Copyright © by International & American Associations for Dental Research

Picture 36. Carious lesion guidelines for caries removal.

The definitions of dentin hardness (Innes et al., ADR, 2016):

Soft Dentine: Soft dentine will deform when a hard instrument is pressed onto it can be easily scooped up using a sharp excavator with a little force.

Leathery Dentine: Leathery dentine does not deform when an instrument is pressed onto it but can still be easily lifted without much force being required.

Firm dentine is physically resistant to hand excavation, and some pressure needs to be exerted through an instrument to lift it.

Hard Dentine: A pushing force is needed to be used with a hard instrument to engage the dentine, and only a sharp cutting edge or a bur will lift the dentine. A scratch sound can be heard when a probe is taken across the dentine.

6.4.2.1.2 Perforation

If by accident the pulpal wall is perforated ensure that the tooth is isolated from saliva. Remove a possible blood clot from the cavity with an excavator. Suppress bleeding by applying pressure to the bleeding site softly with a cotton ball that has been moistened with sodium hypochlorite or Klorhexol. Apply calcium hydroxide (Ultracal, Biokalkki) onto the pulpal wound and dry with a sterile cotton ball. Cover the perforated area with an isolating liner (Calsimol LC/Dycal/Vitrebond) and make a temporary/permanent filling. Alternatively, MTA or Biodentine can be used. In that case an isolating solvent is not necessary.

6.4.2.1.2.1 MTA and Biodentine

MTA (Mineral trioxide aggregate):

MTA is an endodontic cement, that hardens in a moist environment.

Indications:

1. Pulpal, furcal and root perforation
2. Pulpotomy
3. Apexification when treating reabsorption in open rooted teeth
4. Root filling material retrogradely

Instructions:

1. Isolate the area with rubber dam.
2. Remove caries (good to ensure with an indicator).
3. Disinfect the area with Klorhexol. In case of perforation, suppress bleeding (with clear calcium hydroxide or Klorhexol).

4. Nurse can mix MTA and put it in an applicator. Mix an MTA powder bag and one ampule of sterile water. If it is too sticky, 1–2 drops of sterile water can be added.
5. Apply MTA onto the area and seal it tightly by pressing it gently with the other end of the instrument over the perforated area and over surrounding dentine. The layer of MTA should be 1,5–3 mm on the perforation area. The working time for MTA is 5 minutes. The overall setting time for MTA is 4–6 hrs. It is not possible to restore the tooth permanently until the overall setting time is over. Please note that the working time and the overall setting time vary between products.
6. Temporary filling.
7. If the tooth presents no symptoms, a permanent filling can be applied in 4–6 months. The MTA can be left at the bottom of the cavity.

Biodentine:

Biodentine is another tricalcium silicate-based material. It can be used for direct capping. However important to remember whether it was caused by deep caries or accidental perforation. If the perforation was caused by deep caries, the chances of success are under 50 %. In this case, the patient must be informed that it is possible that the tooth may require root canal treatment in the future.

Indications:

1. Step by step excavation and direct capping.
2. Replacing dentine in a deep cavity.
3. Under inlay/onlay filling to replace dentine.
4. Can be left as a direct temporary filling to replace enamel.

Instructions:

1. Remove caries (good to ensure with indicator).
2. In case of perforation for the suppression of bleeding use sodium hypochloride or Klorhexol.
3. Mixing and setting time is altogether 6 mins. The nurse will mix Biodentine.
4. Set Biodentine in place.
5. The overall working time for Biodentine is 12 mins. Therefore, Biodentine must dry at least 6 mins.

6. Biodentine can function as a temporary filling or on top of IRM/Fuji LC or as a permanent filling.

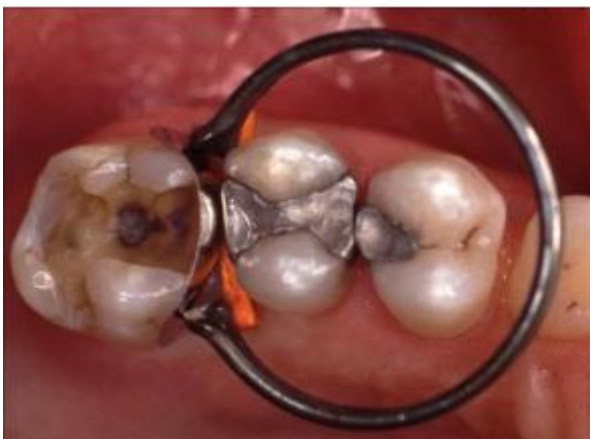After the perforation has been sealed the tooth is followed up for 4–6 months. If the tooth presents no symptoms, Biodentine can be left to replace the dentine. The missing enamel is replaced with a composite filling which is bonded on top of dentine and Biodentine.

6.4.2.2. Matrices

Matrices make it possible to apply a large filling on a tooth.

Preparing an approximal filling using a kidney shaped matrix ensures a good contact to the teeth. See picture 37.

The clamp is set either distally, where it least obscures visibility, or mesially. The wedge needs to go deep enough between the teeth so that it does not hinder the filling's anatomical shape.



Picture 37. Kidney shaped matrix. Source: I. Ostela.

In small class II fillings, where only one approximal space is opened, the kidney matrix is used as a primary option. A straight matrix band can be used in fillings that are on free surfaces where the anatomical shape of the filling is not as crucial. Straight matrix bands are a little thinner than shaped matrix bands, and therefore, fit better through a tight approximal space.

A shaped matrix band is the primary choice in large class II fillings or when both approximal spaces are opened.

A class five U-matrix can be used in fillings for cavities in subgingival areas. A retraction cord can also be used.

6.4.3 Composite Resin Bonding and Repair

An example of a bonding composite resin filling:

1. Etch the enamel and dentine (UltraEtch).
 - Enamel 15–60 s.
 - Dentine 15 s.
 - Beware of over-etching!
2. Thoroughly wash and carefully dry.
3. Carefully mix primer (ALL BOND Primer A+B) 1:1. Apply 5 layers onto the dentine and enamel.
4. Dry thoroughly 5–6 s (surface of the tooth needs to be shiny).
5. Apply a thin layer of resin (D/E Resin) onto the dentine and enamel, air boost lightly.
6. Light cure 20 s.
7. Apply flow composite (TetricEvoFlow) onto the base of the cavity, onto the borders of the matrix and onto sharp edges (max 0.5 mm layer).
8. Light cure 20 s.
9. Apply composite resin (Filtek Z250), max 2 mm layers.
10. Light cure 40 s.
11. Remove excess material. Large amounts can be removed with a turbine and excess scaler. Finish off the filling with a flame and round diamond burs, a raptor and sandpaper strip. Finally, check occlusion and polish with a polishing cup.

In restorative caries treatment the whole composite filling does not necessarily have to be removed if it is in a good condition. It is important that the shape of the cavity increases retention (teddy bear ears).

1. Roughen old composite resin filling with a diamond.
2. Etch enamel and composite resin filling.

3. Rinse and dry.
4. Mix Primer A and B and apply 2 layers onto the tooth.
5. Dry carefully 5–6 s.
6. Apply a thin layer dentine/enamel adhesive onto the tooth.
7. Light cure 20 s.
8. Apply composite resin filling in small amounts at a time.
9. Finish off.

6.4.3.1 Temporary Filling Materials

Temporary fillings are used when there is not enough time to make a permanent one or it is too early to make a permanent filling for example in cases of unfinished root canal treatments or symptomatic teeth. Filling material alternatives are IRM, Riva and Cavit. Instructions on how to use IRM, Riva and Cavit are found in the attachments.

6.4.3.1.1 Riva Self Cure

Glass ionomer fillings are used in deciduous teeth, in fillings for marginal gingiva and under composite fillings. Biologically it is a good material, but due to its brittle nature and wearing it is not suitable for large 1 surface fillings.

Instructions on how to use Riva Self Cure glass ionomer:

1. Clean and isolate tooth.
2. If pulp protection is needed, apply calcium hydroxide.
3. Mix capsule for 10 seconds.
4. Extrude Riva Self Cure into the cavity, being careful not to trap air under the restoration.
5. Apply resin coating to all exposed surfaces of restoration.
6. Let harden for 6 minutes from start of mixing.

6.4.3.1.2 IRM Caps

IRM is a reinforced zinc-oxide eugenol composite. Eugenol has an antimicrobial effect, but its main function is for pain relief. It soothes pulp even through dentine. It also inhibits hardening of composite resin.

Instructions on how to use IRM:

Hold the capsule in an upright position. Twist the cork so the membrane separating the powder and liquid is broken. The capsule is now activated and set in a mixer. Set a mixing time of 6 s (the longer it is in the mixer, looser it will become). Remove the cork. IRM has the consistency of bubble gum and it is hard to handle. Apply IRM in one lump to the cavity with a carver. Apply pressure with a moistened cotton ball towards the edges of the cavity so that the filling will become compact. Shape the filling with a carver. Ensure that the filling is not inadequate nor sticking out. Ask the patient to bite teeth together before it dries so it will set better in occlusion. IRM hardens in 5 minutes due to moisture and warmth in the mouth. IRM should not be used as a filling in the corners of teeth.

Please note, not to be used for patients with eugenol or acrylate resin allergy.

6.4.3.1.3 Cavit, Cavit W and Cavit G

Cavit, Cavit W and Cavit G are temporary filling materials that harden on their own due to moistness in the mouth. Hardening starts when the surface of the filling is moistened. Cavit is the hardest and Cavit G the weakest.

Areas of use:

Cavit is for temporary use on occlusal surfaces, Cavit W is for endodontic treatment and Cavit G is for temporary inlay fillings.

Instructions on how to use:

Apply with an instrument into a moist cavity. It hardens in a few minutes. Avoid chewing for the next 2 hours. Close the lid immediately after use as it is sensitive to moisture.

6.5 Root Canal Treatment

The aim of root canal treatment is to treat and prevent infection. Canals are cleansed, disinfected and filled with root canal fillings. Root canal fillings function as a barrier to the periapical area and prevent bacteria from colonising the root canal. In root canal treatment, special attention must be given to aseptic technique.

6.5.1 Indications

The most common reason for root canal treatment is caries. The presence of bacteria causes inflammation/infection in the pulp and eventually necrosis. Sometimes a healthy pulp may need to be treated for example to obtain extra retention.

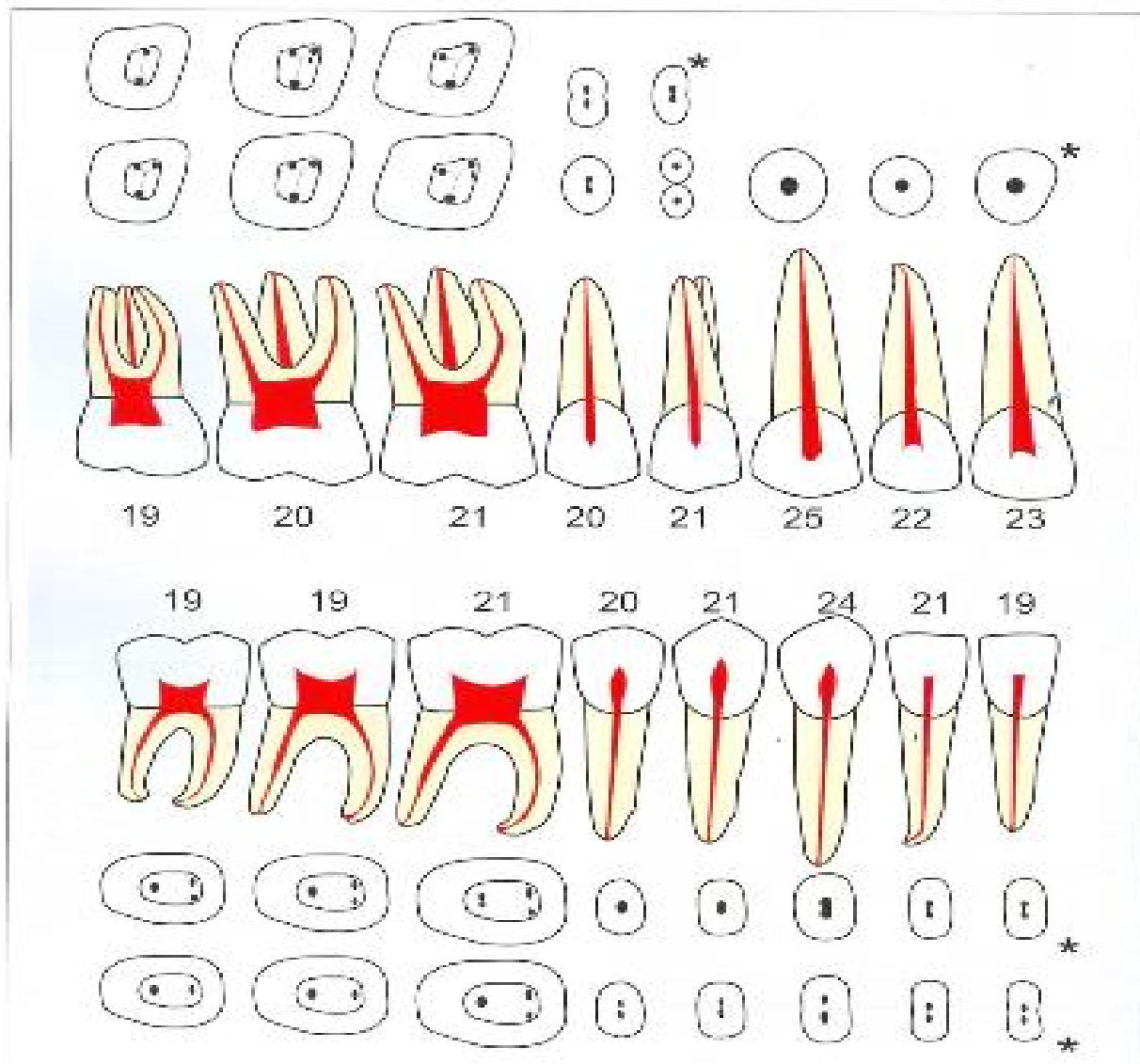
Diagnosis and ICD codes for a tooth in need of root canal treatment:

1. Reversible pulpitis (beginning of infection, hyperaemia) K04.00
2. Irreversible pulpitis K04.0
3. Necrotic pulp K04.1
4. Acute apical periodontitis K04.4
5. Chronic apical periodontitis K04.5
6. Periapical abscess without fistula K04.7
7. Periapical abscess with fistula K04.6

The diagnosis must be documented in patient's treatment plan and root canal card.

6.5.2 Root Canal Morphology

In the picture below is a summary of permanent teeth's root canal morphology, average preparation lengths in intact teeth and most common locations for the root canal openings. It is important to remember, however, that there are numerous variations, and, for example, lengths of canals are only approximations.



* Mesiobuccal corner

Picture 38. Root canal morphology. Source: Haapasalo, Kotiranta, Sirén, Haapasalo, Endal. Käytännönjuurihoito, 2nd ed., 2009.

6.5.3 Stages of Treatment

1. Consent for root canal treatment.
2. Patient history, clinical examination (do not anaesthetise before this, and remember to measure gingival pockets), X-ray to show the situation before treatment.
3. Inform the patient and obtain consent.
4. As the treatment progresses, fill in the root canal treatment card and ask the clinical teacher to approve and sign it.
5. If the tooth has a fistula, conduct fistulography (press guttapercha to fistula and take an X-ray).

6.5.4 Instruments

Drills:






Endo Z		For evening out cavum walls, tip does not cut.
Gates Glidden		
Long neck		For finding and drilling open blocked canals.
Largo		
Lentulo		For taking medications into canals, green hand piece, please note rotates clockwise.

Chart 9. Drills used in root canal treatment. Lentulo for medication.

Files:










<p>#8-15</p> 	<p>Steel K files</p>	<p>Can bend</p>	
<p>#20 Number at the end is the colour of the handle</p>	<p>Steel K flexofiles In the future, instead of flexofile a NiTi-K file</p>	<p>Can bend</p>	
<p>#25-60</p>	<p>NiTi-K files</p>	<p>Cannot bend</p>	
<p>#25-30</p> 	<p>Steel H files</p>	<p>Can bend</p>	
	<p>Steel reamer/ opener</p>	<p>Can bend</p>	
	<p>Finger spreader</p>	<p>n/a</p>	

Chart 9. TYHL dental needle set, reamer and spreader.

6.5.5 Opening and Expanding Root Canals

1. Recall the morphology of tooth.
2. Anaesthetise tooth if needed.
3. Remove caries and plaque.
4. Renew poor fillings.
5. Cut the cusps of premolars and molars if needed.

6. Pierce through enamel with turbine.
7. Open cavum with round bur (mid-length, final layers without water cooling, avoid saliva contamination).
8. Find the location of root canals (use explorer and fibre optic light).
9. Isolate tooth with Kofferdam, if needed, it can be made more compact with Putty compacting liquid or Cavit.
10. Wipe unit.
11. Disinfect working area with Klorhexol and take out root canal treatment tray.
12. The lid functions as an assisting tray and the base as a patient tray. Only sterile items can be placed on it.
13. Completion of cavum preparation, ensure direct access to canals (finishing off walls with Endo-Z bur).
14. Rinse debris away with 2,5 % Canasol (NaOCl) – do not rinse with pressure, remember thorough suction!
15. Measure the lengths of canals with an apex measuring instrument. Remember that the canal needs to be as moist as the patient's lip. From the result subtract 1 mm to receive the working length.
16. Confirm the working length with an X-ray of the root canal file and document the reference point. Capital letters are cusps and small letters canals.
17. X- ray of the root canal file can be repeated if the need for repair is more than 2 mm.
18. Chemomechanical cleaning of canals (ensure that there is Canasol in the canal all the time, clean the needles frequently and check condition. Only take measured instruments to the canal. Finally rinse canal in the following order: NaOCl, EDTA (1 min.), chlorhexidine (5 min.).
19. Spray medication (calcium hydroxide) to the canal (Ultracal XS).
20. Make a compact temporary filling, for example layer of Cavit underneath and on top of IRM. Ensure that the filling is not sticking out! No IRM filling on corners of teeth.
21. Book next appointment in 1–4 weeks' time.

6.5.6 Canal Filling

1. Remove temporary filling with a diamond or a hard metal bur while using water cooling.
2. Once there are a few millimetres of temporary filling left set the Cofferdam in place and continue working in an aseptic manner.
3. Mid cleaning.
4. Wipe working area with Klorhexol.
5. Remove Cavit with an excavator from the base.
6. Make sure that no little pieces of IRM end up blocking a canal.
7. Remove medication (Rinse with plenty of water all the time, between rinsing use small needles along working lengths to ensure medication does not gather in the canal), finally rinse canal in the following order: NaOCl, EDTA, (1 min.), chlorhexidine (5 min.).
8. After EDTA do not use Calasept. If there is a need to rinse use chlorhexidine only.
9. Dry canal with paper points.
10. After this apply new medication if needed, or root filling.
11. Choose master point (remember tug-back) and disinfect with chlorhexidine (also remember to disinfect sealer points and dry them on top of cellulose swab).
12. Take a master point image.
13. Fill any other possible canals with paper points.
14. Mix sealer (in teaching clinic AH Plus) and dip master point, set it in a canal and rotate it, so any possible air bubbles will leave.
15. Press master point laterally against the wall of the canal.
16. Take spreader 2-3 mm away from tip of apex and press master point towards apex for 10 s.
17. Twist spreader a half turn anti-clockwise and pull spreader out.
18. Dip sealer points in sealer and work in the same manner as with master point.
19. Every now and then cut gutta percha points with a hot excavator to increase visibility.
20. When no more sealer points fit in the canal and spreader does not go deeper than 2 mm, cut the final GP-points and compress with vertically dull root canal spreader (täppäin).
21. **Ensure that no gutta percha or sealer remain in the cavum.**

22. While the Cofferdam is still in place take an X-ray of root canal and evaluate the quality of the filling.

23. Make a tight temporary filling (for the sealer to set it takes 24 hrs); underneath Cavit, on top of IRM or glass ionomer and check occlusion.

24. Follow up in 6–12 months.

6.5.7 Preparing a Permanent Filling on Top of Root Filling

Remove the temporary filling with a bur. Remove Cavit that is at the base with an excavator and remove filling from the canal 1-2 mm. Apply a 2 mm layer of coloured composite (for example PermaFlo Purple) onto the mouths of the canals (not on cavum) to make a possible retreatment of root canals easier.

6.5.8 Mechanical Root Canal Preparation with ProTaper

In the teaching facility ProTaper is used to mechanically prepare root canals. The endo hand piece is used in preparation. Remember to check that the condition of the needle is impeccable. Establish the working length with #10 or #15 K files. Make a sliding path up to a size #20 with hand needles and then start the mechanical preparation. **The bur needs to be on when introduced into the root canal and it should be used at maximum speed.** Remember, that only measured instruments can be taken into the canal.

Usually, preparation with three instruments is sufficient (S1, S2 and F1) unless the apical part is wide. Take S needles to the canal with a low pressure and with F needles make a quick in-and-out motion. Cleanse the needles frequently on a needle pillow and check their condition. During the preparation, the root canal must be irrigated with sodium hypochlorite. Finally, rinse with EDTA and Klorhexol as in a manual preparation. If a needle gets stuck in a canal, change the course of rotation or detach the needle by hand by rotating it anti-clockwise.

The root canal is then dried and filled with paper points that match the finishing needles and with gutta percha. In a very curved canal use hand needles to prepare and finish the root canal.

ProTaper files:




Sx		<ul style="list-style-type: none"> - For widening the opening of the canal. - Sx file replaces Gates-Glidden bur. - Shorter than other ProTaper burs.
S1 S2		<ul style="list-style-type: none"> - Shaping files. - Use in brush like stroke. - Go to the working length with S1 needle (visit canal 2–7 times). - Top of the needle must not catch canals walls. - Visit canal 1–2 times with S2 needle, then move on to F1 finishing needle.
F1 F2 F3 F4 F5		<ul style="list-style-type: none"> - Finishing files. - In-and-out motion (no brushing strokes!). - Needle can stay in the apex max 1 s. - Take needle 1–2 times into canal. - When needed, use other F needles. - Do not use F3–F5 files in very curvy canals. - Ensure preparation of the apex with hand needle. - F1 → #20 - F2 → #25 - F3 → #30 - F4 → #35 - F5 → #40 - When NiTi needle is a tight fit in the working length, canal is ready to be filled.

Chart 11. Root canal's mechanical preparation with ProTaper.

6.5.9 Removal of Old Root Canal Filling

Use the endo hand piece when mechanically removing an old root filling. Prepare without water cooling. First drill so that the root filling becomes visible and soften it with a probe. If needed, use chloroform (toxic!) to assist. It permeates through rubberdam. It can be applied on top of the root filling in a small cotton ball or with a Pipen pipette. Guttasolv can also be used (contains eucalyptol).

Enter the filling with, for example, a #25 reamer. Cleanse needles often, check their condition and irrigate the canal continuously with sodium hypochlorite.

D files:




D1		<ul style="list-style-type: none"> - 16 mm, diameter 30, taper 0.09. - For cleansing coronal one-third - Use upward, in brush like motion. - Cutting tip (only to be used in a straight part of canal).
D2		<ul style="list-style-type: none"> - 18 mm, diameter 25, taper 0.08. -For cleansing mid one-third
D3		<ul style="list-style-type: none"> - 22 mm, diameter 20, taper 0.07. - For cleansing apical one-third.

Chart 12. Mechanical removal of old root filling.

Dentine is not prepared with incisions. If there is material/step in the canal after cleaning with D3, use a stiff C+ File steel file. The file has a cutting tip. In more challenging canals prepare the apical one-third by hand. Ensure the cleaning was successful with an X-ray. Any remnants of sealer are best removed with Klorhexol. After cleaning establish the working length and complete the canal as usual.

6.6 Oral Surgery

6.6.1 Tooth Extraction

For tooth extraction, get a permission from the clinical teacher. Extractions are registered in a personal extraction log, in which the student also evaluates the degree of difficulty of the extraction. The need for antibiotic prophylaxis must be assessed separately for each patient. Procedures can usually be performed on patients with relative contraindication by using antibiotic prophylaxis.

6.6.1.1 Indications

The most common reason for tooth extraction is caries. Other common indications for extraction are periodontic, prosthetic and stomatognathic causes. Orthodontic causes, (e.g. tightness), other endemic reasons (e.g. hyperdontia), medical reasons (removal of focus of infection) or socioeconomic causes may also lead to removal of a tooth.

6.6.1.2 Contraindications

Local factors:

- Acute infection, such as herpes, not an odontogenic abscess.
- Irradiated area → permanent contraindication.
- Tumours.
- Anatomic risk factors.

Relative contraindications:

Consider with a teacher whether a procedure can be performed with antibiotic prophylaxis:

- Heart diseases.
- Anticoagulant or immunosuppressive medication.
- Liver and kidney diseases.
- Diabetes, hyperthyroidism, pregnancy.
- Previous difficult extractions, infection risk, or haemorrhage risk.
- Patient doesn't give permission or after-treatment cannot be given properly.
- Student's skills and/or knowledge are inadequate.
 - Primarily, agree on a suitable time for extraction with an oral and maxillofacial surgeon in the clinic. If that is not possible, refer the patient to the Oral and Maxillofacial Unit on the 2nd floor of Dentalia.
 - You may attend/help in the extraction.

Clinical signs of a difficult extraction are weak crown, dense surrounding bone, trouble reaching extraction area (limited mouth-opening), tightness in extraction area, elderly patient, root canal treatment. Radiological signs are diverging/narrow/long/multiple/curved roots, inner or outer resorption of root, hypercementosis, dense surrounding bone or low amount of spongy bone, horizontal root fracture.

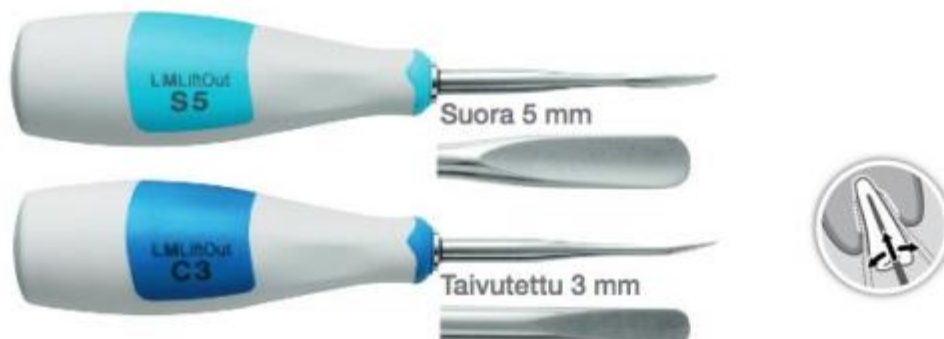6.6.1.3 Instruments

Instruments needed for extraction:

- Dental tray.
- Excavator in a pouch.
- Sterile packet of swabs.
- Anaesthetic syringe and needle.
- After-treatment instructions (from the office outer wall).
- Corsodyl mouthwash (from nurses' vestibule).
- Suitable elevators and/or extracting forceps (from nurses' vestibule).

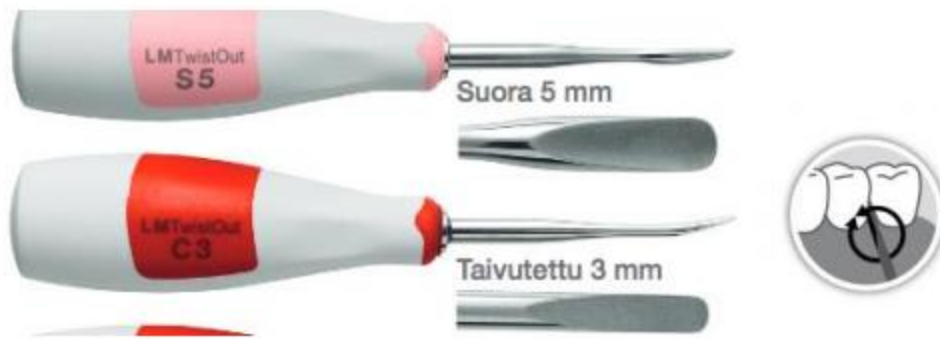6.6.1.3.1 Luxator and Elevator Types

Luxator only for axial use, not for horizontal leveraging (LM elevators that have blue and white handles).



Picture 39. Example of a luxator. Source: LM catalogue – LM-Instruments Oy 2014.

Elevator, suitable for tooth extraction in cases where you need force and horizontal leveraging (LM elevators that have red and white handles).



Picture 40. Example of an elevator. Source: LM catalogue – LM-Instruments Oy 2014.

6.6.1.4 Tooth Separation in Extraction

Tooth separation is recommended especially for molars with difficult roots (e.g. curved roots).

Instruments needed for separation:

- In addition to other extraction instruments, a fissure bur for the separation of teeth.

A Lindemann, Zekrya, turbine or long round bur for the cutting off a crown and separation of roots. Burs are in the endo cabinet.

- Separation must be done with a red contra-angle, not with a turbine (works on compressed air that can end up in tissues).

Separation must be considered case-by-case for all teeth.

Some general principles for separation:

1. Cut off the crown with a bur and possibly with the help of an elevator approximately 3 mm above the edge of the jawbone.
2. Examine the furcation spot with a periodontal probe.
3. Make sure you see the area well and can estimate the position of the alveolar crest in respect to the tooth before you begin to separate roots from each other.
4. Split the tooth between roots with a fissure bur.

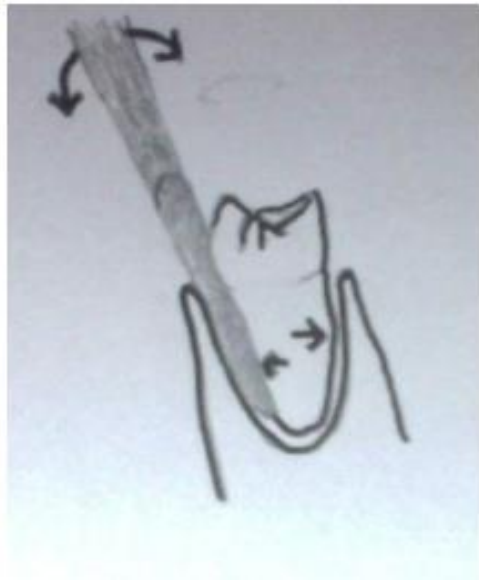5. Separate roots with an elevator.
6. Remove roots with an elevator or with forceps.

Technique for extractions:

1. Inform the patient.
2. Corsodyl mouthwash 1 min.
3. Local anaesthesia.
4. Removal of ligamentum circulare with an excavator or carver.
5. If possible, use an elevator to loosen the tooth.
 - a. Concave side against the tooth.
 - b. Axial leveraging aka luxation: luxator's apex into the periodontal space vertically (picture 38). NB: Finger rest!
 - Alveolar socket is widened with a small back-and-forth rotary motion.
 - c. Horizontal leveraging aka elevation: elevator's apex perpendicularly and approximately below contact area (picture 39), moderate force, finger rest on bone. NB: The tooth must have enough space to rise, mind the adjacent teeth!
6. Position of the forceps: tips levelled apically as parallelly as possible. First the side that is harder to see, do not pinch gingiva!
7. Loosening of the tooth, first to the side of a lesser resistance, more force little by little. The aim is to slowly stretch the alveolar bone.
 - Rotation (one rooted teeth): tooth is rotated around its vertical axis.
 - Luxation: tooth is moved along its buccolingual/palatinal axis.
8. Removal of tooth.
9. Check that the root/roots is/are intact.
10. If needed, trim and clean gingiva and alveolar bone, suture.
11. Gauze for 15–20 minutes until bleeding stops.
12. After-treatment instructions orally and in writing.
- (13. Possible antimicrobial medication.)

NB:

- Use your free hand to palpate the alveolar bone of the tooth about to be extracted.
- Patient's head and lower jaw must be well supported when the tooth is being luxated.
- Cover soft tissues and be careful not to damage adjacent and opposite teeth.
- Consider separating teeth when extracting molars (see below).



Picture 41. Luxation. Source: Hupp JR, Ellis E, Tucker MR. Contemporary Oral and Maxillofacial Surgery, 5th ed. Mosby: Elsevier.



Picture 42. Elevation. Source: Hupp JR, Ellis E, Tucker MR. Contemporary Oral and Maxillofacial Surgery, 5th ed. Mosby: Elsevier.

6.6.1.5 Post-Operative Instructions

- No eating, drinking, or smoking for 2 hrs after the extraction.
 - Soft, cool food on extraction day.
 - Avoid intensive strain 1–2 days after the extraction.
 - Adequate analgesia.
 - Cold compress on extraction day.
 - Avoid touching the extraction socket.
- (- CHX mouthwash twice a day for about a week starting from the day after extraction.)

6.6.1.6 Post-Operative Symptoms and Complications

6.6.1.6.1 Post-Operative Bleeding

- Extraction socket's compression with a sterile gauze for 5–10 minutes, the patient bites a gauze for 20–30 minutes.
- If bleeding persists the following can be used:
 - cauterization or ligaturing of the arteries.
 - reabsorbable local haemostasis such as Surgicel or Spongostan. However, this poses a risk for infection so it must be followed by a course of antibiotics.
 - suturing

To prevent post-treatment bleeding atraumatic extraction technique is vital. If the above local methods do not stop the bleeding medical intervention can be used.

- If needed, gentle rinsing with Caprilon (solution for injection, 100 mg/ml) for 1–2 minutes.
 - Ask a dental nurse to fetch Caprilon from periodontology's storage room.
 - Caprilon is packed in ampules of 5 ml and is mixed with a same amount of water.
- If needed, prescribe Caprilon (5 amp./package) for home use every 4 hours as before.
- A bleeding extraction socket can also be sutured and tamponated with Surgicel Absorbable Hemostat to promote blood clotting.

- Ask a dental nurse to fetch Surgicel from periodontological storage room.
- Surgicel must be of adequate size for it to stop the bleeding but at the same time also small enough to prevent foreign body reactions.
- **NB! Surgicel is always a foreign body and neurotoxic, thus it can cause additional pain in the extraction socket. The more there is Surgicel in the socket, the longer it takes to dissolve, and therefore pain and infection risk last longer.**

6.6.1.6.2 Alveolitis

The main goal of treatment is to alleviate pain, which includes painkillers, removal of blood, and the cleaning of the extraction socket from debris under local anaesthesia.

Symptoms:

- Intense pain for 2–4 days after (mandibular) tooth extraction.
- Clinically a bare extraction socket, no clotted blood but a grey, necrotic mass.
- Foul taste/smell, extraction socket is extremely tender to the touch.
- Etiology unknown.

Treatment:

1. Local anaesthesia.
2. Clean the extraction socket from debris and removal of blood with an excavator. Pay attention to anatomy when excavating (the bottom of maxillary sinus, nervus mandibularis).
3. Rinse with a generous amount of saline. Saline can be found in the so-called eye wash cabinet.
4. Chlumsky solution tamponade in the extraction socket. A gauze is moistened with Chlumsky, which disinfects and alleviates pain. Chlumsky solution and gauzes are in periodontology's storage room, ask a dental nurse to fetch them.
5. Depending on the situation, either ask the patient to remove the Chlumsky tampon on the next day or book a new appointment for removal.
6. Painkillers.
7. Antibiotics only when patient has symptoms.

6.6.2 Biopsy and Sutation

6.6.2.1 Biopsy

A biopsy (a tissue sample) is indicated when there is a need to diagnose a tissue change or eliminate the possibility of mouth cancer.

Changes that don't disappear in 2–3 weeks after the removal of irritating factors require a biopsy. If you suspect a malign change, a biopsy must be taken immediately, or the patient must be referred to the Department of Oral and Maxillofacial Diseases at TYKS.

If uncertain, consult specialised dentists (Willberg, Leimola-Virtanen, Rautava (TYKS), Rytönen).

Biopsy Procedure:

- Pay attention to general surgical contraindications and the need for antibiotic prophylaxis.
- Go to the so-called eye wash cabinet and take a 10 % formalin bottle, PAD referral (histopathologic examination), biopsy/suture set, sterile cotton wool, suture equipment, surgical suction tip, and anaesthetic equipment.
- The so-called IF specimen for an immunofluorescence examination is put in a small amount of saline/water (not formalin), and it is taken to a laboratory right away.

In case you take more than one specimen, put each of them in a different bottle.

Tissue sample procedure:

1. Before the procedure, patient rinses mouth with CHX mouth wash.
2. Numb the skin by infiltrating anaesthetic next to the tissue specimen area, not on the area itself.
3. Incision biopsy is performed on the most representative tissue change so that necrotic areas are avoided. If the tissue sample is of an ulcer or a blister, the specimen must also have some of the tissue surrounding the ulcer or blister. If the diameter of the change is approximately 1 cm or smaller, it can be removed completely by doing an excisional biopsy. For the biopsy, you can use either a scalpel or a punch (diameter 6/8 mm) depending on the biopsy area or your own preferences.
4. Catch the sample with tissue forceps, avoid excessive pressure, and detach the bottom of the lesion with a surgical knife.

5. Put the tissue specimen in a sample tube with patient's personal details.
6. Suture the wound.
7. Give the patient oral and written instructions after the surgical procedure.
8. On the PAD referral, write down the name and contact information of the person who cut the sample, patient's general information and the most essential anamnestic findings, the quality of the change and clinical findings, and the clinical diagnosis of the tissue change. If needed, attach a copy of the x-ray and/or clinical picture to the referral.
9. The sample bottle and PAD referral are taken to the shipping room of the histological laboratory on the 3rd floor (room number 317).
10. The final diagnosis is based on the PAD results that are sent to the clinic's teachers' lounge under the name of the teacher whose name was on the referral.
11. PAD results (not the entire medical report) are registered in the medical record along with a treatment plan, for example follow-ups of the changed tissue area once a year at a dentist's appointment. The patient is informed of the examination results either at an appointment or by phone. Malign findings or further treatments that require discussion are always told to the patient in person at an appointment.

6.6.2.2 Suture

Suture holds clotted blood in the socket and facilitates recovery when there is free, moving mucous membrane around the extraction socket. It also lessens post-operational pain and prevents food from getting in the wound.

Indications:

- Abundant post-operational bleeding.
- Surgical extraction or rupture of soft tissue during extraction.
- Flap surgery.
- (- Biopsy.)

Instruments are in the eye wash cabinet:

- Package of thread and needle.
 - 3/8 circle is the most common, 1/2 for narrow places.

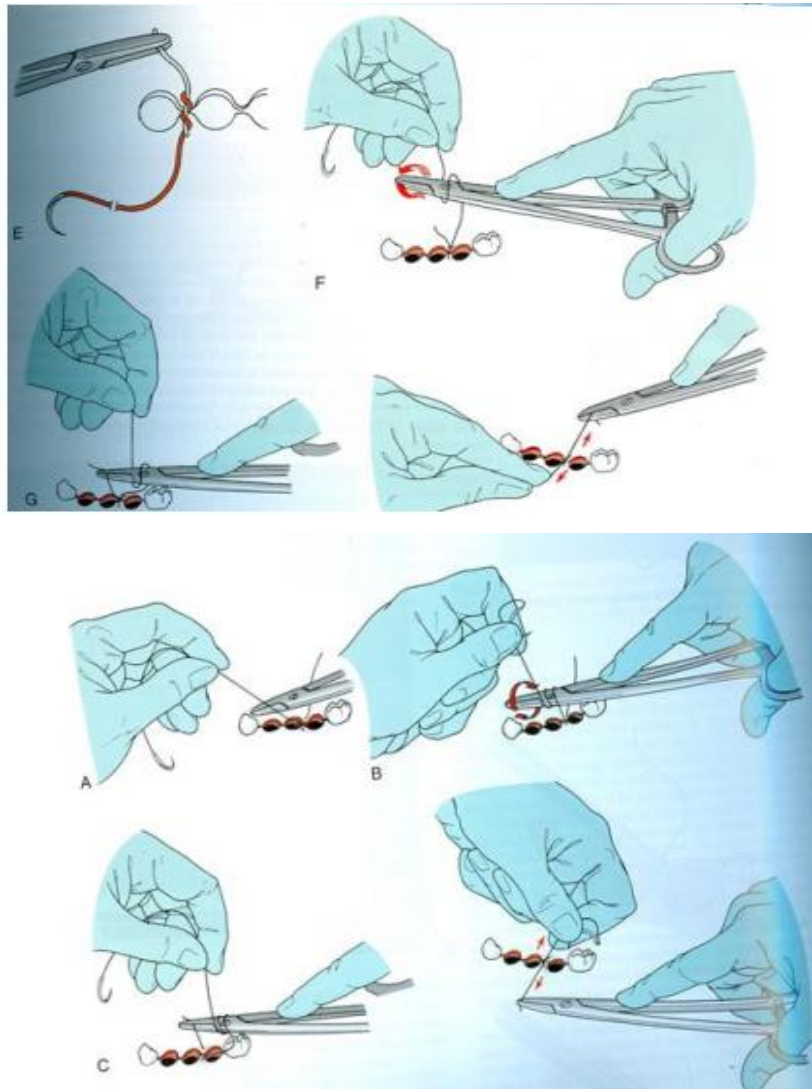
- Thread gauge 3.0 or 4.0.
 - Absorbable/non-absorbable.
- Needle holder.
- Stitch scissors.
- Tissue forceps.

Suturation technique:

1. Clamp the thread with a needle holder and stick it perpendicularly through the tissue approximately 3 mm from the free edge. Stitches start from the side with movable tissues (usually buccal/labial side).
2. Clamp the needle again and pull it through the other side of the wound (often lingual/palatinal side) 3 mm from the edge.
3. Tighten carefully so that the thread doesn't perforate the tissue: the suture is supposed to bring tissues closer.
4. Attach the edges of the wound to each other accurately but without tension, do not stretch the edges too much.
5. Don't make the knot on top of the wound or anywhere in the wounded area.



Picture 43. Mattress stitch. Source: Hupp JR, Ellis E, Tucker MR. Contemporary Oral and Maxillofacial Surgery, 5th edition. Mosby: Elsevier.



Pictures 44 and 45. Making a knot. Source: Hupp JR, Ellis E, Tucker MR. Contemporary Oral and Maxillofacial Surgery, 5th edition. Mosby: Elsevier.

Instrument tie:

1. The thread is pulled through the tissue so that there is an end of about 2 cm.
2. The long head of the thread is spun twice clockwise around the tip of a needle holder that is held horizontally.
3. Grasp the short end with the needle holder.
4. Pull the ends of the thread and release the thread from the needle holder.
5. The long end of the thread is spun once counterclockwise.
6. Grasp the short end with the needle holder and pull to tighten the knot.

7. Release the end of the thread and repeat phases 2–4.
8. Cut the thread ends with stitch scissors, leave 5 mm.

Removing stitches:

- Absorbable stitches need not always be removed, non-absorbable stitches are removed from mucous membrane in 1–2 weeks.
- The stitch is cut with stitch scissors and the thread is pulled toward the wound.

6.7 Local Anaesthetics and How to Choose Them

The choice of anaesthetic is based on the patient's general health, medication, age, the estimated length of the procedure, and the need of haemostasis. Contraindications are patient refusal of local anaesthesia, allergy to an anaesthetic agent, and coagulation defects.

Articaine (Ubistesin, Ultracain, Septocain) is suitable for most. However, for children under 4 years of age the primary choice is lidocaine (Xylocain Adrenalin), articaine is not recommended. Additionally, articaine is not recommended if the patient has angle-closure glaucoma, hyperthyroidism or sulphite allergy. In these cases, prilocaine (Citanest) is a better choice, and for patients with severe bronchial asthma the best anaesthetic is Xylocain.

All anaesthetics are transferred across the placenta. In normal doses anaesthetics do not have negative effects on the foetus. Articaine need not be avoided unless the mother is on her last trimester when it can cause contractions. The recommended anaesthetic is **articaine**. Anaesthetics are passed into mother's milk only in small amounts, there is **no evidence about negative effects** on infants.

As for the elderly, consider general health and multiple medications. Due to their slower metabolism, smaller amounts of anaesthetics are more potent than in younger patients.

The name and amount of the anaesthetic agent must be written down in the medical record.

6.7.1 Allergy to Anaesthetic Agents

Allergies to anaesthetics are exceedingly rare. Less than 1 % of all complications are due to allergies. In addition to anaesthetics, also latex and additives can contain allergens (e.g. sodium metabisulfite, Xylocain, Ultracain). Ultracain and Citanest ampules don't contain latex.

6.7.2 Topical Anaesthesia

Topical anaesthetics must be included in the combined dose of all anaesthetics used and they must be written in the medical record. This is especially important when patients are small children.

For topical anaesthesia, the teaching clinic has Xylocain 5 % gel. It must be applied on dry mucous membrane for maximum efficacy. Wait for 3–5 minutes. Also, topical anaesthetics must be entered in medical records.

6.7.3 Active Ingredients in Local Anaesthetics and Their Maximum Dosages

Below are the active compounds used in anaesthetic agents and maximum doses for adults and children alike.

Product	Active ingredients	Maximum dosage
Xylocain Dental Adrenalin → children	lidocaine hydrochloride 20 mg/ml + epinephrine hydroxy tartrate 12.5 µg/ml	adults 10 ml = 5.5 amp. children (20 kg) 4.4 mg/kg = < 2.5 amp.
Ultracain D-Suprarenin Septocaine Ubistesin	articaine hydrochloride 40 mg/l + epinephrine hydrochloride or epinephrine tartrate 5 µg/ml	Adults 12.5 ml = 7 amp. children (20 kg) 5.0 mg/kg = 1.5 amp.
Septocaine Forte Ubistesin Forte	articaine hydrochloride 40 mg/ml + epinephrine hydrochloride or epinephrine tartrate 10 µg/ml	adults 12 ml = 7 amp. children (20 kg) 7 mg/kg = 2 amp.
Citanest Octapressin (Scandonest)	prilocaine hydrochloride 30 mg/ml + felypressin 0.54 µg/ml (no preservatives) mepivacaine hydrochloride 30 mg/ml	adults 10 ml = 5.5 amp. children (20 kg) 6.0 mg/kg = 2 amp.
Xylocaine 5 %, cream	lidocaine 50 mg/ml, cream	5 g (15 cm of cream from the tube) which corresponds to 250 mg of lidocaine

Chart 13. Active compounds in anaesthetics and their maximum dosages.

6.8 Most Commonly Used Medication in Dentistry

Medication is primarily checked from Duodecim's medication database:

http://www.terveysportti.fi.ezproxy.utu.fi:2048/terveysportti/dlr_laake.koti

When you prescribe medication together with a teacher, remember to give patients clear instructions on how and for how long to take the medication and motivate them to take medication by telling how it affects recovery.

If the patient has a liver or kidney disease, it may be necessary to reduce the dosage frequency or cut unit dose.

E-prescriptions are the only method to prescribe medication. They are saved in a central database called Reseptikeskus (Prescription Centre), maintained by Kela (The Social Insurance Institute of Finland). The national Reseptikeskus has all e-prescriptions and their dispensing entries from pharmacies. Based on the information in Reseptikeskus, prescriptions can be filled by any pharmacy. E-prescriptions and their entry information are saved into Reseptikeskus for 30 months or 2.5 years. After that they are transferred to another central database called Reseptiarkisto (Prescription Archive).

Patients can view their prescription data on Omakanta online service.

6.8.1 Pain – Non-Steroidal Anti-Inflammatory Drugs

Ibuprofen (Burana, Ibumax) 400–800 mg x 1–3

Diclophenac (Voltaren Rapid) 25 mg 1–2 tab. x 3

- Inflammation, pain and fever.
- Contraindications: children, asthmatics, patients with risk of bleeding (Marevan, clopidogrel, ASA, SSRIs, helicobacter infection or glucocorticoid treatment).
- Not for long term usage (use anamnesis to find out if the patient takes other NSAIDs!).
- Must be taken with plenty of water.

Paracetamol (Paratabs, Panadol, Parasetamol, Paracabs, Paramax) 500 mg x 1–2 tab. x 1–3

- Children 4–8 yrs ½ tab X 1–3, 9–16 yrs 1 tab x 1–3.

- Pain and fever, also reduces swelling.
- Children, asthmatics, expectant and nursing mothers, and patients with risk of bleeding.
- For alcoholics, patients with liver and kidney disease or on epilepsy medication with caution.
- Suitable for warfarin users but it is recommended not to exceed the daily dose of 2 g (may add to the risk of haemorrhage).

Codein and paracetamol (Panacod) 1–2 tab. x 1–4

- For slightly more intense pain and when NSAIDs are contraindicated.
- Codeine is a weak opioid.
- Not with alcohol, driving not recommended.
- May exacerbate asthma symptoms and cause nausea.
- See: paracetamol.

Tramadol (Tramal) 50–100 mg x 3–4

- For moderate pain.
- May cause nausea.
- Tramadol is a moderate opioid, increases effects of serotonin, note interactions if the patient has similarly affecting medications, e.g. SSRIs.
- Alcohol increases effects, driving not recommended, interactions with MAO inhibitors and other antidepressants.
- Suitable for most asthmatics that cannot take NSAIDs.

6.8.2 TMD Pain

Tizanidine (Sirdalud) 2 mg + NSAID (Voltaren Retard) 100 mg 5 x day

- For facial and masticatory muscle pain, tizanidine relaxes.
- Driving not recommended, no sedatives, not with ciprofloxacin (antibiotic) or fluvoxamine (antidepressant).
- For patients taking antihypertensives with caution (exacerbates antihypertensive effects).

6.8.3 Antibiotics

6.8.3.1 Single Dose Prophylaxis

- 1 h before a surgical operation or subgingival deputation.
- Patients that have had endocarditis, have an artificial heart valve, a valvular disorder, congenital heart disease, < 6 months old endoprosthesis, or an endoprosthesis older than 6 months combined with immunosuppressive or rheumatoid arthritis medication, or more than one endoprosthesis.
- Endocarditis prophylaxis must be also be given to patients who use intravenous drugs.

Amoxicillin (Amorion, Amoxin) 2 g

- For children 50 mg/kg.
- Not for patients with mononucleosis.
- Suitable for expectant mothers.

Cephalexin (Kefexin, Kefalex) 1,5 g

- For children 50 mg/kg.
- In case of a penicillin allergy.
- May cause diarrhoea.

Clindamycin (Dalacin) 600 mg

- For children 20 mg/kg.
- In case of a penicillin allergy.
- May cause diarrhoea.
- Note that several bacteria have clindamycin resistance and it may not always help.

+ Metronidazole (Flagyl) 400 mg

- For children 15 mg/kg.

- If moderate predisposition for infections.
- Dental infections are combined with another antibiotic because dental infections are always mixed infections and antibiotics are only effective against anaerobes.
- Not during the first trimester of pregnancy or breastfeeding.
- Not with alcohol (disulfiram-like effects (Antabus)).
- Medicinal contraindications: warfarin, carbamazepine, lithium, cyclosporine, amiodarone, or neurological disorder.

6.8.3.2 Continuous Prophylaxis and Treatment of Infections

Indications:

- To prevent wound infections e.g. after tooth extraction in addition to a single dose prophylaxis 3–5 days after the procedure in risk patients (diabetes, cancer, alcoholism, immunosuppression, bisphosphonates, or glucocorticoids).
- Dental infection with generalised symptoms.
- Preferably with bacteria samples especially if the infection does not heal in good time.

V-penicillin (V-pen) 1 million IU x 3–4

- For children 66 mg/kg x 3.
- Suitable for expectant and nursing mothers.
- During methotrexate with caution (rheumatic arthritis, psoriasis, cancer).
- At the earliest 2 hrs after eating.

+ metronidazole (Flagyl) 400 mg x 3 in case of an infection

- For children 15 mg/kg x 3.

Amoxicillin (Amorion, Amoxin) 500 mg x 3 + metronidazole (Flagyl) 400 mg x 3

- In case of a moderate infection risk (labile diabetes, progressive liver or kidney disease, immunosuppression, < 6 months old prosthesis or < 12 months old mouth infection).
- For children amoxicillin 40 mg/kg + metronidazole 22.5 mg/kg x 3.

Cephalexin (Kefexin, Kefalex) 500 mg x 3

- In case of a penicillin allergy.
- In case of an infection + metronidazole 400 mg x 3.
- For children cephalexin 50–100 mg/kg + metronidazole 22.5 mg/kg x 3.

Clindamycin (Dalacin) 300 mg x 4

- For children 20 mg/kg x 4 days.
- In case of a penicillin allergy.
- May cause diarrhoea.
- Note that several bacteria have clindamycin resistance and it may not always help.

6.8.4 Lichen Ruber Planus

- Must have histological confirmation and diagnosis before symptomatic treatment.
- Normally asymptomatic lichen does not require medication.
- Possible fungal and other infections must be treated and irritating factors eliminated before starting cortisone.
- Contraindications: acute infections (a fungal infection must be treated before a steroid treatment).
- Note that cortisone medication blocks natural cortisone production so there must be at least one medication-free week; in other words, after the initial period at least one break per month.

Betamethasone cream (Bemetson)

- Applied thinly on skin 1–2 times/day for 7–10 days.

Desonide cream (Apolar)

- Applied thinly on skin 1–3 times/day for 7–10 days.

6.8.5 Painful and Recurrent Aphthous Ulcer

- When necessary, corticosteroids for local pain.
- Must have histological confirmation and diagnosis before treatment.
- Possible fungal and other infections must be treated before medication.
- Contraindications: acute infections (fungal infection must be treated before a steroid treatment).

Nasacort 55 microg/dos, 30 dos

- When necessary, 2 x spray/day on oral mucosa.

6.8.6 Oral Fungal Infection

Anti-fungal medicines have several possible interactions with other medicines. Before starting an anti-fungal medication, eliminate predisposing factors such as poor oral hygiene, ill-fitting dental prostheses and their use, and possible diabetes-related elevated blood sugar levels.

Nystatin 100,000 IU/ml, 1 ml x 4, 4–6 weeks

- Topical oral suspension, applied on oral mucosa.
- Primary choice.
- A well tolerated medicine for all from babies to the elderly, for expectant and nursing mothers.

Amphotericin B (tablets) 10 mg x 4, 4–6 weeks

- Tablet treatment has very little effect on oral fungal infections, so the advisable type of medicine is topical (see nystatin).
- For those with dry mouth with a small amount of water.
- Not for expectant and nursing mothers, also check other possible interactions.

6.8.7 Herpes

- Herpes is contagious and the patient is treated only if the ailment is acute.
- Do not treat a patient who does not have a blister plaster (ask the dental nurse to get one).
- Safety goggles are mandatory for both the patient and medical staff! Ocular herpes is extremely painful!

Aciclovir (AciclovirHexal) 200 mg tab. x 5 for 5 days

- May cause nausea.

6.8.8 Patients at High Bleeding Risk

Tranexamic acid (Caprilon tablet/suspension, Cyclokapron tablet) 500 mg 1–3 tab. x 2–3 days

- Mouth wash is made of injection suspension (5 x 5 ml ampule). 5 ml Caprilon suspension + 5 ml water. Gentle rinsing of mouth for 2 minutes every 4 hours.
- For patients at high bleeding risk for treatment and prevention of bleeding.
- For renal insufficiency patients with caution.
- Stored in the eye wash cabinet.

6.8.9 Acute Chest Pain

Nitro 0,5 mg x 1 tab. under the tongue

Nitrolingual 1–2 puffs on the tongue

- Maximum dose 3 tablets every 5 minutes or 3 puffs in 15 minutes. If symptoms persist, send the patient to hospital emergency room.
- Alleviates acute chest pain and ischemia, the patient must be sitting.
- Not for patients who have taken erectile dysfunction medicine (Viagra, Cialis, Levitra and other PD5 inhibitors) within the last 24 hours (increases the risk for fatal drop in blood pressure).

6.9 Most Commonly Used Medicines and Their Effect on Dental Treatment

If anamnesis has medicines that are unknown to you, search it from Duodecim's Lääketietokanta. Many medications affect mucous membranes, decrease salivation, and can additionally have unwanted interactions with other drugs.

Duodecim's Lääketietokanta:

http://www.terveysportti.fi.ezproxy.utu.fi:2048/terveysportti/dlr_laake.koti

6.9.1 Warfarin (Marevan)

- Before procedures that cause bleeding: surgical and subgingival debridement require a recent (< 24 h) INR value and it must be < 2.8.
- **Do not alter the medication without consulting the patient's doctor for further instructions.**
- **Please note that a patient with an artificial heart valve needs Marevan and it should not be stopped. A dentist is always responsible for the instructions they give to their patient despite consultation!**
- If INR value is > 2.8, consult the patient's doctor and discuss a lower dosage of Marevan. See the patient again after about 1 week, a new INR value is checked < 24 h before the appointment.
- Paracetamol for pain, NSAIDs increase the risk of haemorrhage.
- No miconazole nor metronidazole (may increase the risk of haemorrhage).
- No carbamazepine (may decrease the effect of warfarin).
- The most important factors in controlling the bleeding during an extraction are an atraumatic technique, cold, compression, Surgicel/Spongostan, and sutures. Tranexamic acid only when nothing else helps.
- Course of antibiotics after extraction (no metronidazole).

6.9.2 Aminobisphosphonate (Fosamax)

- May cause osteonecrosis especially in case of cancer.
- Bad oral hygiene and periodontal and dental diseases increase the occurrence of complications.

- Dental treatment should be foreseeable. Bisphosphonate medication is started only 1 month after a surgical procedure because an extraction can cause osteonecrosis.
- Also, an irritating prosthesis can cause osteonecrosis.
- Traditional, non-invasive and conservative dental treatment is of utmost importance, as well as an infection-free patient.
- **In case of invasive treatments, always consult the Oral and Maxillofacial Unit.**

6.9.3 Insulin Therapy or Oral Medication of Diabetes

- Note that the patient may become hypoglycaemic during a treatment.
- If needed, ask a teaching clinic nurse for a rapidly assimilating sugary snack.
- **Consider a prolonged prophylaxis after extractions. Not always necessary if blood sugar balance is normal.**

6.9.4 Inhaled Corticosteroids (Aerobek, Rhinocort, Flixotide, Flixonase)

- Predisposition to oral fungal infections, tongue ulcers, infections, and caries.
- Delayed wound healing.
- If the patient inhales medicine, recommend them to rinse mouth with water every time afterwards.

6.9.5 Anti-Hypertensive and Cardiac Insufficiency Medication (Diuretics, Calcium Channel Blockers, ACE Inhibitors)

- Primary choice is paracetamol, NSAIDs can weaken the effect of antihypertensive and cardiac insufficiency medication.
- Can decrease salivation and cause mouth ulcers.

6.10 Risk Patients

Prepare for problems beforehand. In the anamnesis, write down the patient's diseases and drugs and their dosages, and investigate possible drug interactions.

6.10.1 Cardiovascular Diseases

Interview the patient about their health. Ask about anaesthetic allergies and inquire if they are afraid of dental treatment and how they stand physical strain (e.g. walking up the stairs).

If needed, consult the patient's doctor. If necessary, give anti-anxiety premedication (e.g. midazolam). Need for antibiotic prophylaxis must be checked from Käypähoito (<http://www.kaypahoito.fi/web/kh/suosituksset>) and endocarditis prophylaxis from Terveysportti (<http://www.terveysportti.fi>).

Arrhythmia patients do not tolerate well pain/stress, and their local anaesthetics should have as little adrenaline as possible. The most common type of arrhythmia is atrial fibrillation and its medication is Marevan. Dental treatment should optimally be done in a half-sitting position and with additional oxygen if needed. Stop procedure when necessary, and call 112 if the patient goes unconscious, check pulse and send the patient to an emergency room.

For a year after a heart attack, stroke, or drug eluting balloon angioplasty, only emergency procedures are acceptable. In case treatments are necessary, consult the Oral and Maxillofacial Unit and the patient's doctor.

6.10.1.1 Cardiac Insufficiency

Cardiac insufficiency decreases the patient's ability to cope with stress/strain. Symptoms may include shortness of breath, fatigue, and swollen feet. Medication includes ACE inhibitors and diuretics.

6.10.1.2 Hypertension

Hypertension may induce acute cerebral haemorrhage or in the long-term cardiac insufficiency. Patients with hypertension must avoid sudden shifts of position. A good haemostasis is essential during treatment. If the condition is severe, dental procedures are prohibited. Patient with untreated/unbalanced hypertension require a careful administration of adrenaline.

6.10.1.3 Increased Risk of Bleeding

Increased risk of bleeding is caused by defective blood coagulation. Drugs that increase the risk of haemorrhage are, among others, heparin, warfarin, dabigatran*, rivaroxaban*, apixaban*, ASA, dipyridamole, clopidogrel, prasugrel*, ticagrelor*, NSAIDs, and SSRIs. Also, certain medicines, e.g. fungus, increase the risk for haemorrhage when combined with Marevan. The risk for haemorrhage in the elderly in respect to aspirin is equal to warfarin. All anticoagulants have a narrow therapeutic window.

- Before procedures, consult the Oral and Maxillofacial Unit about these five anticoagulants. At this point, there is no reliable information about the new anticoagulants in dental health care. In the two latter cases (prasugrel, ticagrelor), the patient is most likely not treatable anyway.

Increased risk of haemorrhage may also be caused by e.g. alcoholism that has damaged the liver.

6.10.2 Diabetes

Diabetes does not in itself cause any oral symptoms or diseases. Nevertheless, diabetics have more often oral infections, and they aggravate more quickly and heal slower. This happens especially when the condition is new or before diabetes treatment has begun or if sugar levels are abnormal in type 1 diabetes.

Remember to check long-term glycated haemoglobin (HbA1c) value. It should be less than 7 %. If it is 10 % or more, the risk of infection is greater than normal. Also, a prolonged periodontal infection can

have a negative effect on diabetes. Periodontal diseases may also increase the risk of cardiovascular diseases, which in diabetics is already remarkably heightened.

Diabetics do not tolerate long fasting and hypoglycaemia should be considered by e.g. having juice or other drink/food that raises blood sugar levels quickly.

Local anaesthetics should have a low adrenaline content.

6.10.3 Patients with Artificial Joints

It is important to treat mouth and teeth before foreign body operations because they can cause infections elsewhere. Procedures that can cause bacteraemia should be avoided for 6 months after the operation when intimal thickening is incomplete. If an invasive operation is necessary, it requires an antibiotic prophylaxis and a consultation from the Oral and Maxillofacial Unit.

A continuous treatment of oral infections is important also after the insertion of an artificial joint. Foreign bodies weaken the immune reactions near them, and a considerably smaller number of microbes is required for the onset of an infection than in healthy tissues. Oral bacteria also adhere easily to prosthetics. Check the requirements for an antibiotic prophylaxis from Käypähoito if the patient has an artificial joint.

6.10.4 Rheumatic Diseases

Rheumatic diseases are autoimmune/connective tissue diseases with an unknown aetiology that are more common in women than in men. Inflammatory rheumatic diseases weaken the body's immune reactions, and oral and dental diseases seem to have a negative effect on the course of inflammatory rheumatic illnesses.

Anti-rheumatic drugs increase the patient's proneness to infections and have a great impact on the treatment and recovery of the patient. Do not hesitate to consult a rheumatologist before all invasive procedures. Anti-rheumatic side effects include e.g. irritation of mucosa, ulcers, lichenoid changes, feeling of dry mouth, diminished flow of saliva, gingival overgrowth, and stomatitis/fungus infection.

Due to dry mouth, rheumatic patients have abnormally high amounts of *Streptococcus mutans*, *Lactobacillus*, and yeast fungus, which predisposes to caries and oral fungal infections. They are also at a higher risk for periodontal diseases.

6.10.5 Head and Neck Cancers

Radiotherapy increases the risk for osteonecrosis. If the patient has received radiotherapy in the head and neck region, check the radiation dose. > 60 Gy is a permanent contraindication for tooth extractions by general dentists and extractions must be operated in special dental care clinics. Before extractions, do not hesitate to consult the Oral and Maxillofacial Unit or another surgery unit.

6.10.6 Pregnancy

During pregnancy, avoid unnecessary surgical procedures that can be postponed. The second trimester is most suitable for procedures. Do not use Citanest for anaesthetics and only take x-rays that you absolutely need. If needed, treatment should optimally be done in a half-sitting position.

6.10.7 Asthma and Respiratory Disorders

Do not treat a patient with fever. Also cough and cold may hinder the treatment and are an infection risk.

If an asthma patient is on a systemic corticosteroid course, always consult the patient's doctor. Oral fungal infections are more common in asthma patients.

6.10.8 Inflammatory Bowel Diseases

NSAIDs can aggravate inflammatory bowel diseases or start an acute phase so use caution when prescribing them. The safest is to ask the patient how NSAIDs have worked before. Also, broad

spectrum antibiotics can aggravate intestinal symptoms, but necessary antimicrobial medication is not contraindicated.

6.10.9 Liver Diseases

Liver transplant patients are at a heightened bleeding and infection risk. Antibiotics prophylaxis is needed if the risk for hyperaemia is high (e.g. depuration). If cyclosporine has caused gingival hyperplasia, it must be treated.

The choice of analgesics is challenging for patients with a liver disease because there are no good options. ASA increases the risk for bleeding, paracetamol slows down metabolism, NSAIDs increase the risk for bleeding and have an influence on kidney functions, and opioids increase the half-life of medications. Of utmost importance is to pay attention to analgesic dosages.

Tramadol is the safest option, although not without risks. Take into consideration all other drugs the patient is using.

6.10.10 Renal Insufficiency

When a patient has renal insufficiency, check the suitability of medication and the need for antibiotic prophylaxis. <http://www.terveysportti.fi/terveysportti/renbase.koti>

6.10.11 Organ Transplants

Foci of infection must be treated before a transplant operation, the patient must be informed of possible oral and dental problems, and the oral side effects of the transplantation must be prevented. Transplant patients must have an antibiotic prophylaxis when the procedure perforates the mucous membrane. Always consult the patient's doctor first. Organ transplants often cause xerostomia, which predisposes the patient to many oral and dental diseases. Anti-rejection medication increases the risk for infections.

6.11 First Aid and Resuscitation

Sometimes it is necessary to resuscitate e.g. because of a serious allergic reaction. Check, if the patient is lifeless or not. Test if the patient can be revived by shaking. If not, call for help.

6.11.1 Serious Allergic Reactions

The quicker the symptoms, the more serious the reaction. The first aid procedure is same for both anaphylactic and anaphylactoid reactions: adrenaline (Epipen, Prote 1 cabinet) injected 0.3 mg deep in muscle. Allergic reactions can be caused by certain drugs (e.g. penicillin, anaesthetics). Adrenaline dosing should be moderate, preferably several small doses at a time. Other medicines for allergic symptoms are corticosteroids, antihistamines, and asthma inhalers.

6.11.2 Sudden Cardiac Symptoms in Dental Practice

Adrenaline used in anaesthetics can predispose to extrasystoles. Individual extrasystoles are rarely dangerous. If the sensation is over quickly, you may continue. If arrhythmia begins abruptly, interrupt the procedure and send the patient to accident and emergency.

Patients with coronary disease usually have nitroglycerin that can be used to treat chest pain. If the pain passes quickly, continue the procedure. If the patient does not have a diagnosed coronary disease, stop the procedure. An attack begins suddenly and lasts more than 20 minutes. The pain is centred around midline and radiates on a large area. It may include nausea, shortness of breath, sweating, and a shock. Other, non-coronary heart disease related, reasons for such pain are an abrupt onset of symptoms and sharp or stinging pain in a small area.

A medical procedure as the trigger of an attack is quite rare. Shortness of breath is not most often heart related, e.g. asthma, panic attack or COPD.

A loss of consciousness should always be considered heart related until proven otherwise. Stop the procedure, place the patient in a lying position, lift legs up, and pay attention to breathing. If needed, send the patient to follow-up treatment.

A sudden chest pain is usually a sign of ischemia in the heart. Call 112, keep the patient calm, and place them in a lying position.

The teaching clinic's defibrillator can be found in the Prote 1 cabinet.

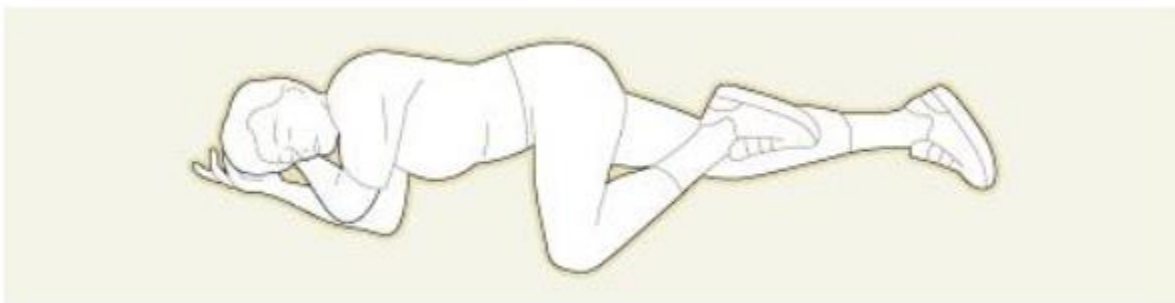
Electric knives and blood vessel cauterisation are contraindicated in patients with pacemakers.

6.11.3 Hypoglycaemic Shock

Symptoms of hypoglycaemic shock are sweaty and clammy skin, superficial breathing, rapid pulse, and unconsciousness. Give the patient honey or e.g. sugary juice, for an unconscious patient 1 mg glucagon i.m.

6.11.4 Seizures

Make sure the patient does not hurt themselves. Seizures usually lead to a loss of consciousness and falling. The seizure typically lasts 1–2 minutes after which they often feel sleepy. Turn the patient into a lateral lying position and call 112 if the seizure lasts more than 5 minutes or is recurrent. If the patient does not start breathing, begin cardiopulmonary resuscitation (CPR).



Picture 46. Lateral position.

Source: http://www.ebm-guidelines.com/dtk/syd/avaa?p_artikkeli=syk00016120813

6.11.5 Foreign Objects in Respiratory Tract or Oesophagus

If there is a foreign object in the patient's respiratory tract and they cannot cough, talk, or breathe and they begin to turn blue, it is vital to act quickly. If the patient is conscious, tell them to cough. If this does not help or cannot be done, hit the patient between shoulder blades 5 times with the palm of your hand while the patient is in a stooping position.

Heimlich manoeuvre: use your fist to push quickly between the patient's sternum and navel and repeat 5 times if necessary.

If these are inadequate, call 112 and send someone to get help from the Oral and Maxillofacial Unit (2nd floor).

6.11.6 Shortness of Breath

In dental care, patients frequently have shortness of breath, but usually it is not heart related. If necessary, give the patient supplementary oxygen.

6.11.7 Loss of Consciousness

If the patient loses their consciousness, shake them and talk to them. Place them in a lying position and lift their legs up, loosen tight clothes and make sure they get fresh air. Fainting is common especially for the young. Patients with a cardiovascular disease are always sent to an emergency unit, those with no cardiovascular history are sent home. Always stop the treatment. A benign loss of consciousness passes within a couple minutes.

6.11.8 Angina Pectoris

Angina pectoris is a heart related sensation of squeezing chest pain. Referred pain may occur on neck, shoulders, mandibula, and left arm. Prophylaxis includes supplemental oxygen (5 ml/min) and nitroglycerin for treatment.

6.11.9 Cerebral Blood Flow Disorders

Cerebral blood flow disorders may be temporary (transient ischemic attack, TIA) or permanent. Temporary attack abates within 24 hours, usually after an hour. In these cases, almost 1 in 10 has a cerebral stroke within a week since the symptoms began, and therefore TIA requires imminent examination and treatment (emergency care).

6.11.10 Anaesthetic Toxicity

Anaesthetic toxicity is a rare condition, and it is always prevented by aspirating before injecting the anaesthetic and by following the instructions for maximum dosages. The symptoms of intoxication are usually caused by intravenous injections. Initial symptoms include tinnitus and metallic taste in mouth. Bupivacaine is considerably more toxic than lidocaine.

If the symptoms are mild, stop injecting, calm the patient, give them supplemental oxygen, and follow the situation. In severe cases, e.g. loss of consciousness and muscle cramps, call 112.

6.11.11 Cardiopulmonary Resuscitation

Open the respiratory tract. Keep track of the patient's respiration (max. 10 s), see if the chest is moving, feel the air flow from mouth with the back of your hand, listen to the air flow. If the patient is not breathing, start CPR with a compression to ventilation ratio of 30:2. Continue until the ambulance team says to stop. Press the mid-sternum (for the adolescent the lower part of sternum, depth 1/3 of sternum). Compressions are piston-like, the chest must also rise. Ventilate for about 1 second. Remember to pay attention to the movement of chest during ventilation. Ask for a defibrillator that is attached to the patients, but do not stop pressing unless the machine so instructs. Defibrillator is used when the patient has ventricular fibrillation and pulseless ventricular tachycardia.

With children (under 13 years old) and in cases of asphyxiation the cardiac arrest is usually caused by ischemia, and CPR begins with 5 ventilations followed by 1 minute of basic resuscitation after which you may call 112.

6.12 Needle Stick Injury or Other Perforation Accidents

Procedure after a perforation accident:

1. Rinse the wound with plenty of water and then with A12T solution. Eyes and mouth are rinsed only with water.
2. Inform the patient about the puncture and check if the patient has any diseases.
3. Write down the information on the medical record.
4. Ask the patient to go to their health centre for blood sample examinations HBV, HCV, and HIV antibodies.
5. Contact FSHS (Finnish Student Health Service) tel. 046 710 1050 (8.00–14.30) or TYKS (Turku University Hospital) tel. 02 313 8800 (outside YTHS appointment times or when the patient is HBV/HCV/HIV positive).
6. A zero sample is taken from the exposed person (the student).
7. An HBV antibody test can be taken if necessary.
8. Fill in the notice of accident form (ask from a teaching nurse).
9. Find out the patient's laboratory results.

When an HIV contagion is suspected after a puncture, prophylaxis should preferably begin within 2 hours, at the latest after 48 hours of the accident. If there is no information on the patient's HIV status, an emergency HIV antibody test is recommended and possibly prophylaxis as well. HIV antibody control test is taken 4–6 months after the accident.

In case of a suspected HBV contagion, the exposed is given either hyperimmunoglobulin (pref. within 24 h) and/or a series of HBV vaccinations (within a week), or in case of an antibody positive patient there is no need for further tests.

If the patient is HCV positive, the exposed is tested for S-HCV-AbG and P-ALAT 2, 4, and 6 months after the accident.

7 ICD-10/Nomesco Classification – Mouth

E Teeth, Jaws, Mouth and Pharynx

EB Teeth

EB_ Diagnostic radiology of teeth

EB1AA Intraoral tooth X-ray examination

EB1AI Panorama tomography of teeth and jaws or similar X-ray examination
(1 quadrant)

EB1BI Double panorama tomography of teeth and jaws or similar X-ray
examination

EB1CA Tooth X-ray additional picture

EB1CI Panorama tomography of teeth and jaws or similar X-ray examination
(3–4 quadrants)

EB1HA Panorama tomography of teeth and jaws or similar X-ray
examination

EB1JA Double panorama tomography of teeth and jaws or similar X-ray
examination

EB1MA Cephalometry with X-ray

EB1SA Bite-Wing

EBA Extraction and partial excision of tooth

EBA00 Extraction of tooth

EBA05 Complicated extraction of tooth

EBA10 Surgical removal of tooth

EBA12 Complicated surgical removal of tooth

EBA15 Extraction of large number of teeth

EBA20 Hemisection of tooth

EBA30 Excision of root of tooth

EBA40 Excision of apex of root of tooth

EBA45 Excision of apex of root of a tooth with several radices

EBA99 Other extraction or partial excision of tooth

S Non-surgical procedures of mouth and teeth

SA Examination of mouth and teeth

SAA Examination and treatment plan of mouth and teeth made by a dentist

- SAA01 Simple examination of mouth
- SAA02 Basic examination of mouth
- SAA03 Extended examination of mouth
- SAA04 Special investigation of mouth

SC Promotion of oral health care

- SCA Preventive dental health treatment
 - SCA01 Simple analysis and advice of nutrition with regard to dentistry
 - SCA02 Analysis and advice of nutrition with regard to dentistry
 - SCA03 Extended analysis and advice of nutrition with regard to dentistry

SCE Fissure closure of teeth

- SCE00 Fissure closure of tooth

SD Treatment of periodontological diseases

SDA Periodontological therapy

- SDA01 Simple periodontological therapy

Easy periodontal patients, CPI = 1–2

- SDA02 Periodontological therapy

Easy periodontal patients, CPI = 1–2

- SDA03 Demanding periodontological therapy

Patient has several 4 mm gingival pockets and dental calculus throughout,
CPI=3

After treatment register SCA03*2 (anti-infective treatment of maxilla and mandibula)

- SDA04 Very demanding periodontological therapy

Patient has a lot of etiological factors (smoking, surplus filling etc.), CPI = 3

After treatment register SCA04*2

- SDA05 Very demanding and lengthy periodontological therapy

Difficult periodontal patients, CPI = 4

- SDA10 Periodontological therapy, complicated disease

- SDA11 Periodontological therapy, complicated, extended and demanding

SF Fillings

SFA Direct filling

- SFA00 Small filling

- SFA10 Filling on one surface of tooth

- SFA20 Filling on two surfaces of tooth

- SFA30 Filling on three or more surfaces of tooth

SFB Indirect filling

SFC Support procedures of dental filling

- SFC00 Pillar of fillings material
- SFC01 Adjuvant procedure of filling therapy
- SFC92 Other demanding adjuvant procedure of filling therapy

SG Endodontics

SGA Root channel opening and dilatation

- SGA01 Tooth opening as first aid
- SGA02 Opening and dilatation of root channel of tooth
- SGA03 Demanding opening and dilatation of root channel of tooth
- SGA04 Very demanding opening and dilatation of root channel of tooth
- SGA05 Very demanding and lengthy opening and dilatation of root channel of tooth
- SGA06 Removal of foreign body from root channel of tooth
- SGA07 Removal of foreign body from root channel of tooth, demanding

SGB Root channel filling

- SGB00 Partial removal of tooth pulp
- SGB10 Filling of root of tooth with one root channel
- SGB20 Filling of root of tooth with 2 root channels
- SGB30 Other demanding filling of root channel of tooth

SGC Other interventions on root of tooth

- SGC00 Local medication of root channels of tooth
- SGC10 Covering tooth pulp
- SGC20 Correction of root channel perforation or inside resorption through root channel of tooth
- SGC30 Correction of root channel perforation or inside resorption through root channel of tooth, demanding
- SGC40 Restauration of tooth for root therapy
- SGC50 Closure of open top of root of tooth

SH Stomatognathic physiology

SHA Stomatognathic health care visit

SHB Mouth guard

SPF Reparative procedures of teeth prosthesis

- SPF00 Reparation of teeth prosthesis
- SPF10 Demanding reparation of teeth prosthesis
- SPF20 Temporary soling for filling
- SPF30 Soling for prosthesis

SX Other treatment procedures of mouth and teeth

- SXA10 Epithelial biopsy of mouth
- SXA20 Local application of medicine to mouth
- SXB00 Removal of sutures from oral mucosa
- SXB10 Removal of attachments and rails from mouth

W Other procedures and procedures acting on several organ systems

WX Anaesthesia, breathing support and resuscitation

WX1 Local anaesthesia

WX105 Topical anaesthesia on skin or mucosa

WX110 Local anaesthesia

WX2 Blockade of nerve

WX290 Other blockade of nerve

8 Most Common TMD ICD-10 Diagnoses

ICD-10 code	Specification
F45.82	Teeth grinding
K07.10	Asymmetry of jaw
K07.6	Temporomandibular joint disorders
K07.60	Temporomandibular joint-pain-dysfunction syndrome
K07.61	Snapping jaw
K07.62	Recurrent subluxation of temporomandibular joint
K07.63	Pain in temporomandibular joint
K07.64	Stiffness of temporomandibular joint
K07.65	Degenerative joint disease of temporomandibular joint
M06	Rheumatoid arthritis of temporomandibular joint
M12.5	Traumatic arthropathy of temporomandibular joint
M19.0	Primary osteoarthritis, temporomandibular joint
M79.1	Myalgia
S03.0	Dislocation of jaw
S03.0	Dislocation of temporomandibular joint
S03.4	Sprain and strain of jaw

9 Dental Terminology Finnish–English

Alkutarkastus	Dental inspection
Avaa suu	Open your mouth
Hammas	A tooth, teeth
Hammas täytyy juurihoitaa/hioa/paikata	The tooth needs to root canal treatment/ be grind/filled/
Hammaskivi	Tartar
Hammaslanka	Dental floss
Hammassärky	Toothache
Hammasväliharja	Interdental brush
lentasku	Gingival pocket
lentulehdus	Gingivitis
Ikenet	Gums
Kiillottaa	Polish
Kivulias	Painful
Leukanivel	Jaw joint
Limakalvo	Mucous membrane
Liu'uta leukaa oikealle/vasemmalle	Slid your jaw right/left
Narskutella hampaita yhteen	Grind one's teeth
Oikomishoito	Orthodontics
Oletteko allerginen jollekin	Are you allergic to something?
Onko tämä hammas särkenyt	Have you had toothache on this tooth?
Onko teillä sairauksia tai käytättekö lääkkeitä	Do you have some disease or do you use regular medication?
Parodontiitti	Periodontitis
Plakki	Plaque
Porata	To drill
Puhdistaa (esim. hammaskivestä)	Scale
Puremalihakset	Masticatory muscles
Puuduttaa	Numb the mouth
Puudutus	Anesthesia
Reikä	A cavity
Röntgenkuva	X-ray
Tarkastaa	Check up
Vastaanottoaika	An appointment
Vihloa	Hurt
Yhdistelmämuovi	Composite filling

Table 14. Dental terminology in Finnish and English.

10 Useful Links

- ICD 10 codes:

<http://apps.who.int/classifications/icd10/browse/2016/en>

- Procedure codes:

<http://www.terveysportti.fi/terveysportti/toimenpideluokitus.koti>

- Dental Trauma Guide:

<http://www.dentaltraumaguide.org/>

11 Sources

- Chapter 2.4:
<http://www.utu.fi/fi/yksikot/med/opiskelu/Perustutkinto/Sivut/Tiedekunnan-ohje-opetuksestapoissaolojen-k%C3%A4yt%C3%A4nn%C3%B6iksi-ja-korvaamismenettelyiksi.aspx>
- Chapter 4.1:
WINHIT NYKYSTATUKSEN KÄSIKIRJA. Opas rakenteisen statuksen kirjaamiseen WinHIT-järjestelmässä. In Net Oy 2017. http://www.innet.fi/help/wp-content/uploads/2017/08/20170503_WinHIT_statuksen_kasikirja.pdf
<http://www.winhit.fi/>
- Chapter 4.9:
<https://www.uef.fi/documents/1299922/1299939/Jonna+Hassinen+2012.pdf/6ae9b367-6b6a-42aea08b-a0aec49dc2d1>
<http://www.digipaper.fi/hammaslaakarilehti/116840/index.php?pgnumb=34>
<http://pre20031103.stm.fi/suomi/eho/julkaisut/kipeaesite/hammas.pdf>
- Chapter 4.10:
<https://www.uef.fi/documents/1299922/1299939/Jonna+Hassinen+2012.pdf/6ae9b367-6b6a-42aea08b-a0aec49dc2d1>
<http://www.digipaper.fi/hammaslaakarilehti/116840/index.php?pgnumb=34>
<http://pre20031103.stm.fi/suomi/eho/julkaisut/kipeaesite/hammas.pdf>
- Chapters 5.1.1, 5.2.5.1:
Meurman J., Murtomaa H., Le Bell, Y., Autti H. (ed.): Therapia Odontologica. Academica-Kustannus 2008.
- Chapter 5.2.3.2:
Hiiri, A.: Hampaiston kehityshäiriöt. Terveystieteiden tutkimuskeskus, 15.9.2009.
- Chapter 5.2.4.1:
WINHIT PARODONTOLOGINEN STATUS. Parodontologisen statuksen ohjekirja. In Net Oy,2017.

http://www.innet.fi/help/wp-content/uploads/2017/08/20170707_WinHIT_parodontologinen_status.pdf

- Chapter 5.2.4.4:

Tonetti MS, Greenwell H, Kornman KS.: Staging and grading of periodontitis: Framework and proposal of a new classification and case definition [published correction appears in *J Clin Periodontol.* 2019 Jul;46(7):787]. *J Clin Periodontol.* 2018;45 Suppl 20:S149-S161.doi:10.1111/jcpe.12945

http://old.lminstruments.com/pdf/downloads/Paronopas_J%20Talonpoika_FI.pdf.pdf

- Chapter 5.3.1.4:

Huumonen, S.: Lectures on radiology. University of Turku, spring 2013.

Meurman J., Murtomaa H., Le Bell, Y. Autti H. (ed.): *Therapia Odontologica*. Academica-Kustannus 2008.

White S., Pharoach M.: *Oral Radiology, Principles and Interpretation*. Mosby 2009.

- Chapter 6.2:

<http://www.turku.fi/public/default.aspx?contentid=25493>

- Chapter 6.3.3:

Suomen Hammaslääkärilehti 2010;8: 19–27.

- Chapter 6.3.4:

Coe-pak® instructions.

ColtenePerfect®TCS II electric knife instructions.

Könönen, E., Gursoy, U., Hurttia, H., Pöllänen, M.: Lectures on periodontology. University of Turku. Institute of Dentistry, spring 2013.

Meurman J., Murtomaa H., Le Bell, Y., Autti H. (ed.): *Therapia Odontologica*. Academica-Kustannus 2008.

Newman M., Takei H., Perry R. (ed.): *Carranza's Clinical Periodontology*. 11th ed. Saunders, 2011.

- Chapter 6.4.1:

<http://www.kaypahoito.fi/web/kh/suosituksset/suositus?id=hoi50078#kuvatjakaaviot>

- Chapter 6.4.2.1.2.1:
Biodentine brochure. Septodont 2013.
MTA brochure. Dentsply 2013.
Niemi T., Karjalainen S.: MTA – parantava hiekka. Suomen Hammaslääkärilehti 10/2010.
Sirén Eva, Haapasalo Markus: Kattaminen. Therapia Odontologica 2008.
- Chapter 6.4.2.2:
TorgilsLægreid, Tom Paulseth ja Arne Lund: Täytteen tekeminen – Näkökulmia käytännön paikkaushoitoon. Suomen Hammaslääkärilehti 2011;15(4):20-25.
- Chapter 6.4.3.1.1 (20.6.2013):
<http://www.hammaslaakariliitto.fi/suun-terveys/suun-hoito/hampaiden-paikkaus>
- Chapter 6.4.3 (20.6.2013):
<http://www.digipaper.fi/hammaslaakarilehti/89247/index.php?pgnumb=20>
Therapia Odontologica: Juurihoidossa käytettävät materiaalit
<http://dSPACE2.lib.helsinki.fi:8082/dikk/bitstream/handle/2455/138055/Kar.%20TP%203.%20s2012%20Syv%C3%A4n%20kariuksen%20hoito,%20v%C3%A4liaikaiset%20paikk.pdf?sequence=1>
- Chapter 6.5:
Laine M.: Lectures on endodontics. University of Turku, spring 2013.
- Chapter 6.6.1 (10.10.2013):
Happonen R., Teerijoki-Oksa T.: Lectures on oral and maxillofacial surgery. University of Turku, spring 2013.
Hupp, Ellis, Tucker: Contemporary Oral and Maxillofacial Surgery. Mosby Elsevier 2008.
Suuronen et al.: Kuiva alveoli -oireyhtymä, alveolitis sicca dolorosa, dry socket -syndrooma (K10.3). Therapia Odontologica 2008.
http://www.terveysportti.fi.ezproxy.utu.fi:2048/dtk/tod/kotip_artikkeli=tod21050&p_haku=alveoliitti

- Chapter 6.6.2:
Hietanen J, Autti H.: Suupatologia. Kirjassa Meurman J, Murtomaa H, Le Bell Y, Autti H. (ed.): Therapia Odontologica 2008:227–38. Academica-Kustannus.
Suusyöpä (online). Käypä hoito -suositus. Suomalaisen Lääkäriseura Duodecimin ja Suomen Hammaslääkäriseura Apollonian asettama työryhmä. Suomalainen Lääkäriseura Duodecim, 2012. <http://www.kaypahoito.fi/web/kh/suosituksset/naytaartikkeli/tunnus/hoi07025>
- Chapter 6.6.2.2:
Happonen R., Teerijoki-Oksa T.: Lectures on oral and maxillofacial surgery. University of Turku, spring 2013.
- Chapter 6.7:
Teerijoki-Oksa T.: Lectures on local anaesthetics. University of Turku, spring 2012.
<http://www.dentsply.com.au/xylocaine-5-ointment-topical-anaesthetic-35g-608/w1/i1024453>
- Chapter 6.8:
Kuruhela ja Konttinen: Katsaus hammaslääkärin määräämiin lääkkeisiin – Osa 1. Lääkehoidon indikaatiot ja käytetyimmät lääkkeet. Suomen Hammaslääkärilehti 2006;13:1006-10.
Koulu, Tuomisto: Farmakologia ja toksikologia 2007. Medicina.
Käypähoito -suositus: Hammasperäiset äkilliset infektiot ja mikrobilääkkeet. 2011.
- Chapter 6.10.1:
<http://www.digipaper.fi/hammaslaakarilehti/89707/index.php?pgnumb=22>
- Chapter 6.10.2 (10.3.2014):
http://www.terveyskirjasto.fi/kotisivut/tk.koti?p_artikkeli=trs00127 10.3.2014
http://www.diabetes.fi/diabetesliitto/lehdet/diabeteslehden_juttuarkisto/muu_diabeteksen_hoito/hammasharjalla_hyokkaykseen!.728.news
- Chapter 6.10.3:
http://www.terveyskirjasto.fi/kotisivut/tk.koti?p_artikkeli=trs0013
- Chapter 6.10.4:
Honkala, S.: Terve suu. Therapia Odontologica, 15.9.2009.

- Chapter 6.10.11:
<http://www.dysfagia.fi/wp-content/uploads/2012/04/Suunhoito.pdf>
- Chapter 6.11.11:
Tommila M.: Lectures on emergency situations at a dentist's appointment. University of Turku, autumn 2012.
- Chapter 6.12:
<http://www.utu.fi/fi/yksikot/med/opiskelu/Perustutkinto/Sivut/Toiminta-neulanpisto--tai-muussaverikontaktitapaturmassa.aspx>
- Chapter 8 (19.6.2013):
<http://www.terveysportti.fi/terveysportti/toimenpideluokitus.koti>
- Chapter 13.1.1.1:
http://www.gceurope.com/pid/14/ifu/GC_Dentin_Conditioner.pdf
- Chapter 13.1.1.2:
http://www.gceurope.com/pid/1/ifu/GC_Fuji_II_LC_Capsules.pdf
- Chapter 13.1.2.2:
http://www.laakeinfo.fi/Medicine.aspx?m=13746&d=21355&i=COLGATEPALMOLIVE_DURAPHAT_DURAPHAT%C2%AE+22%2C6+mgF-%2Fml
- Chapter 14.1.2.1:
https://www.voco.dental/en/portaldata/1/resources/products/instructions-for-use/e1/bifluorid-5_ifu_e1.pdf

12 Appendices

12.1. Instructions

Instructions for the substances most often used in the teaching clinic.

12.1.1 Fillings

Instructions for temporary fillings, composites, some haemostatic agents and calcium hydroxide.

12.1.1.1 Dentin Conditioner

Dentin Conditioner is a mild polyacrylic acid solution.

Indications:

Removal of dentinal smear layer and conditioning of dentine and enamel by demineralising them.
Increases the bond between glass ionomer and dentin.

Use:

1. Apply Dentin Conditioner to the cavity for 20 secs.
2. Rinse with water. Dry carefully (leave moist).
3. Fill cavity with filling material.

Note: Close the bottle immediately after use.

Source: <http://www.gceurope.com/products/dentinconditioner>.

12.1.1.2 Riva Self Cure

If needed, cap pulp with calcium hydroxide.

How to use Riva Self Cure:

Indications:

Non stress bearing Class I and II restorations, deciduous teeth restorations, geriatric restorations, intermediate restorative and base material for Class I and II cavities using the sandwich technique, cervical (Class V) restorations, core build ups, temporary fillings, restorative in the field using the ART technique, dentine replacement.

Contraindications:

Pulp capping.

Procedure:

1. Clean and isolate tooth.
2. In cases where pulp protection is necessary, use a calcium hydroxide liner.
3. Remove excess water. Keep moist. Avoid contamination.
4. Mix for 10 seconds.
5. Extrude Riva Self Cure into the cavity, being careful not to trap air under the restoration.
6. At the end of the working time, apply resin coating to all exposed surfaces of restoration.
7. Let harden for 6 minutes from start of mixing.

Source: https://www.sdi.com.au/downloads/instructions/INST_SHEET_RIVA_SC.pdf

12.1.1.3 Filtek Z250 (3M Espe)

Filtek Z250 is a light-cured radiopaque composite filling material. The material has been designed to be used in

the fillings of both front teeth and back teeth. Filtek Z250 filling material is BIS-GMA, UDMA and BIS-EMA based combination of plastic. Filler material is zirconium/silica.

Indications:

- Direct and indirect fillings of the front teeth and back teeth (inlay, onlay, laminate), for pillar material and connecting of teeth.

Usage:

- Select the shade, compare the tone to a moist tooth.
- Take the filling material to a cavity in several small batches. Maximum layer depth is 2.5 mm, light-cure between batches for 20 secs (note that in back teeth the undermost layer should be at most 1 mm).
- Overfill the cavity a little over the edges. Shape with a carver and a burnisher.
- Avoid strong lighting. Remember to keep the point of the curing light as near as possible to the surface of the filling.

Shades:

- The yellowness of the tooth increases in the area of the gingival margin. The filling materials around the gingival margin may contain shades of grey, yellow or brown.
- The apical area contains blue or grey shades.
- Furthermore, the opaqueness of the filling and the tooth should match the surrounding teeth.

Light-curing a test model:

- Take the filling material of your choice to the unetched surface of the tooth.
- Press the filling material with the help of a plastic strip to a layer that correlates to the final thickness and extent of the filling. Light cure through the strip.
- Estimate the suitability of the material in different lighting circumstances.
- Loosen the sample lot with a probe.
- If the tone is not suitable, select a new tone.

NB: Filtek Z250 contains methacrylates. Some people can become sensitive to acrylic plastics. Touching the material with bare hands should be avoided before light-curing, but acrylics also pierce ordinary disposable gloves. Use a working technique in which contact with skin has been eliminated.

12.1.1.4 ViscoStat, Astringedent&Astringedent X

ViscoStat, Astringedent and Astringedent X are coagulating, haemostatic materials.

Indications:

Subgingival preparations and bleeding gingival pockets.

Usage:

- Rub the agent against the bleeding tissue by pressing the stick sufficiently.
- Rinse with a strong spray of air and water.
- Dampen a retraction cord with a haemolytic solution and push the cord into the gingival pocket with the help of, for example, a carver or an Ultrapak Packer.
- After filling the cavity remove the dampened retraction cord.

NB: In order to bond and condense the filling perfectly, it is extremely important to wash and clean the cavity and its margins to prevent micro bleeding and weakened bonding. Mixtures of haemostatic materials and/or blood can contaminate the interface of the bonding agent and/or prevent resin polymerisation or hardening.

NB: Do not use for patients who are allergic to ferrous sulphates.

12.1.1.5 Calcimol LC

Calcimol LC is a light-cured radiopaque calcium hydroxide material.

Indications:

Indirect capping of the pulp, insulator under filling material or pulp protection against etching acid.

Usage:

- Dry the surface of the tooth and avoid spit contamination with the help of, for example, cotton balls/rolls.
- The material can be taken directly from the applicator to the indicated section.
- Light-cure at least 20 secs.
- Apply as little as possible of the material because it weakens the bonding of the composite (surpluses cannot be removed with a probe). If necessary, remove extra material with a bur.

NB: Close the applicator/tube tightly immediately after use.

12.1.2 Hypersensitive Teeth

Listed underneath are two different fluoride compounds that are used among other things to treat uncovered dental cervices.

12.1.2.1 Bifluorid 5

Bifluorid 5 is a double fluoride varnish to treat hypersensitivity. Varnish attached well to dry enamel and dentin and forms a watertight protective layer against heat and chemical effects.

Indications:

- Hypersensitive dental cervices and edges of crowns.
- Fluoridation of enamel and desensitising of exposed dentin after the polishing of a tooth/teeth.
- Prevention of secondary caries after a filling.

Usage:

- Clean and dry surfaces with air-water spray and isolate with cotton rolls.
- Mix the solution by shaking the bottle well and, if necessary, is warmed in hands.
- Spread a thin layer on the desired area. Let the material stay for 10–20 seconds and dry the surfaces with air.
- The brushing of teeth should be avoided for 12–24 hours. Varnish will stick to the surfaces for several days.

Source: Instructions for use. https://www.voco.dental/en/portaldata/1/resources/products/instructions-for-use/e1/bifluorid-5_ifu_e1.pdf.

12.1.2.2 Duraphat® 22,6 mgF-/ml

Duraphat is a fluoride suspension which in the varnish form fastens to the tooth surface for long enough so that the fluoride has time to be absorbed to the enamel and exposed dentin.

Indications:

Prevention of caries and hypersensitive dental cervices.

Use:

Varnish is spread thinly onto indicated surfaces.

Deciduous teeth	At most 0.25 ml of varnish (5.7 mg of fluoride)
Succedaneous teeth	At most 0.40 ml of varnish (9.0 mg of fluoride)
Permanent teeth	At most 0.75 ml of varnish (17.0 mg of fluoride)

Table 15: Dosing and maximum doses of varnish.

After the spreading of the varnish the patient can close his/her mouth as saliva will harden the varnish. Eating of solid food should be avoided for 4 hrs and the brushing of teeth for 24 hrs. To caries-active patients Duraphat is recommended semi-annually. To the risk patients varnishing is recommended once every three months. The recommendation applies to surfaces which are susceptible especially to caries, for example molars that have recently erupted and deciduous teeth.

Contraindications:

Ulcerative gingivitis and stomatitis.

Source: http://www.laakeinfo.fi/Medicine.aspx?m=1714&d=2045992&i=COLGATE-PALMOLIVE_DURAPHAT_DURAPHAT+dentaalisuspensio+22%2c6+mg%2fml

12.2 Special Health Care – Oral and Maxillofacial Surgery

Place: TYKS Oral and Maxillofacial Unit: outpatient department + surgical ward, Dentalia 2nd floor.

Objectives:

- To become acquainted with oral and maxillofacial surgery in the special health care.
- To participate in an outpatient department and surgical ward treatment (among other things, students assist in operations, possibly operate themselves with help from teachers).

- To think and to analyse their experiences with the help of a learning diary.

Shifts and instructions:

- See the shift schedule during clinical practice.
- Follow the specialised/specialising dentists' and the nurses' work in the operating room and in the outpatient department.
- The objective is also to participate in the patients' treatments depending on the situation – be active and don't be afraid to ask!
- Monday mornings: be present at Dent 3 at 8.00 for the morning meeting.
After the meeting report in the recovery room to the nurses. Tell them who you are and that you are getting to know oral and maxillofacial surgery in the special health care.
- Tuesday, Wednesday and Thursday mornings: report for duty to the nurses in the recovery room at 8.00. Tell them who you are and that you are getting to know oral and maxillofacial surgery in the special health care.
- Friday morning: be present at Dent 3 at 8.00 for the morning meeting.
After the meeting report in the recovery room to the nurses. Tell them who you are and that you are getting to know oral and maxillofacial surgery in the special health care.
- Tuesday afternoon and Thursday morning: mucous membrane policlinic in the outpatient department room – see the appendix.
- In the afternoons: report for duty to the nurses in the recovery room at 12.30. Tell them who you are and that you are getting to know oral and maxillofacial surgery in the special health care.
- Wednesday afternoons: at 14.30 Dent 3 – Wednesday seminar, in which presentations of oral and maxillofacial surgery.
- If there are no operations in the operating room, you may follow the outpatient department's activities.
- The schedules outside the operating rooms are plans and are subject to change. Sometimes operations indeed last longer than anticipated and the next operation will begin late. Sometimes we also must change schedules, for example, because of emergency operations. If the operation does not begin according to the schedule, ask the nurses in the recovery room about the estimated start time.
- Many patients are not suitable for students' practice patients. In that case, however, ask if it is possible to be able to assist in the operation.
- It is always worth thinking why the patient is in the special health care and what examinations and procedures have been done before the operation and what kind of further treatment the patient will receive. A large part of the treatment takes place both before and after the operation.
- Observe the patient's progress from the recovery room to the operating room and the patient's follow-up and post-operative treatment.

- Observe the different professionals' role in the patient's treatment and in the operating room. Think how tasks have been shared between different stages of treatment.
- Clothing: day-specific blue surgical outfit of TYKS and socks are in the roller cage next to the women's dressing room. Name plates must be visible. Long-sleeved coats and bags must be left in the dressing room.
- Kindly let the staff work in peace and respect the patient.
- As a rule, one candidate per operating room. The candidate can change the operating room once during an operation but any extra traffic in the operating room has to be avoided.
- Do not socialise in the operating room, in the recovery room or in the hallways.
- Sometimes operations are challenging, or the patient has a lot of fears, and the surgeon may ask you to pose your questions about the operation after the procedure and not during the operation itself. Be active after the operation!

Other practices:

- Register all of your procedures and assistances in operations to a blue card.
- The information of the card will be examined at the final stage of studies.
- A learning diary (one A4) will be written about the week and given to MeiraLääveri via e-mail (meira.laaveri@utu.fi) at the latest during the following week after the procedures in question.
- The learning diary is marked as accepted/rejected and short feedback will be given.
- All practical changes to the planned schedule must be agreed with departmental secretary Susan Pekkonen.

Learning diary:

- A tool for the production and recording of the thinking and self-assessment of the matter to be learned.
- A contemplating report of the operation of the week.
- To analyse own work and to process thoughts.
- To practise writing.
- Make notes, think and ponder.

Further questions:

What do I expect of this week? How did I experience this week and what will I learn today/this week? For which matter would I like to get additional information? Will I find connections to earlier information and experiences? Did I understand the big picture of the matters at hand? Was the subject matter important?