

CASE REPORT

Surgical management of stress fracture of the contralateral pedicle in a baseball player with unilateral lumbar spondylolysis : A case report

Yusaku Nakayama, Kazuta Yamashita, Kosuke Sugiura, Makoto Takeuchi, Masatoshi Morimoto, Fumitake Tezuka, Yoichiro Takata, Toshinori Sakai, Toru Maeda, and Koichi Sairyō

Department of Orthopedics, Institute of Biomedical Sciences, Tokushima University Graduate School, Tokushima, Japan

Abstract : We describe successful surgical treatment in a case of L5 unilateral spondylolysis with contralateral pedicle stress fracture that was not resolved by conservative treatment in a high-performing college baseball player. The 20-year-old man presented with left low back pain that stopped his sports activities. Over the previous year, he had experienced a couple of episodes of pain that subsided with cessation of sports but reappeared after a return to sports. Computed tomography and magnetic resonance imaging revealed a right terminal stage pars fracture and a left pedicle stress fracture at L5. The pain originated from the left pedicle fracture, with no pain from the right unilateral spondylolysis. Given that conservative treatment for 1 year had not been effective, we decided on surgical treatment. Bilateral pedicle screws and the smiley face rod method were applied, and both fractures subsequently healed. In the 2 years since the surgery, the patient has returned to sports and has the potential to become a professional player. *J. Med. Invest.* 67 : 382-385, August, 2020

Keywords : spondylolysis, pedicle fracture, direct repair surgery, elite athlete

INTRODUCTION

Spondylolysis is a stress fracture of the pars interarticularis, and lumbar spondylolysis is a well-known cause of low back pain in adolescents, especially athletes (1, 2). Lumbar spondylolysis may be unilateral or bilateral. A study of the prevalence of spondylolysis in the Japanese population by Sakai *et al.* (3) identified lumbar spondylolysis in abdominal computed tomography (CT) scans in 117 of 2,000 (5.9%) cases, 26 of which showed unilateral spondylolysis (21.0%). Unilateral spondylolysis is generally considered to be clinically benign, based on the low probability of forward slippage found in a 45-year longitudinal study of patients with spondylolysis (4).

Although unilateral spondylolysis should be benign in itself, it was reported to be the precursor to an additional fracture on the contralateral side (5). The biomechanical stress on the contralateral pars and pedicle is very high in unilateral spondylolysis. We have previously reported an interesting case of a 17-year-old baseball player with left unilateral spondylolysis at L5 who developed a right pedicle fracture that healed with conservative treatment but a right pars fracture developed on his return to sports (6). These biomechanical and clinical findings suggest that pediatric patients with unilateral spondylolysis who are very active at sports should be monitored for contralateral pars or pedicle stress fracture.

We have since encountered a young adult baseball player with left pedicle stress fracture and right pars fracture who was able to return to his original competitive level after surgical treatment. Here, we describe successful surgical treatment of the unilateral spondylolysis with contra-lateral pedicle fracture.

CASE REPORT

History of present illness

The patient was a 20-year-old baseball pitcher who first experienced right low back pain as a 16-year-old high school student. He was diagnosed with right unilateral lumbar spondylolysis in the terminal stage at L5 by a local doctor. His low back pain had subsided with conservative treatment using a trunk brace and with cessation of sports activity. Two years later, during the first year of college, his low back pain reappeared during baseball practice, this time with left-sided pain. He was diagnosed as having right unilateral spondylolysis at L5 and was treated conservatively. The left low back pain disappeared after 2 months of no sports activity. A couple of weeks after returning to sport, the pain recurred and steadily worsened, prompting a further visit to another local doctor. His low back pain was diagnosed as sacroiliac joint pain. The pain resolved after 2 further months of no sports activity but reappeared when he returned to sports. As a result of these repeated episodes of pain, the patient had 1 year without any active participation in baseball. When he entered his second year of college, his baseball coach, recognizing his potential to become a professional player, recommended that he visits us for a second opinion.

Preoperative examination and diagnosis

The height and body weight of patient were 182 cm, 78 kg, respectively. Physical examination revealed tenderness over the L5 spinous process and left L5 paravertebral muscle. The low back pain worsened in lumbar extension and was provoked on the left side by Kemp's test. Neurologically, he had no muscle weakness or sensory disturbance. Straight leg raising and femoral nerve stretch tests were negative, and deep tendon reflexes were normoactive.

CT showed a right-sided fracture of the L5 pars interarticularis that was in the terminal stage (2). A high density area around a low density area at the left pedicle was suggestive of a stress fracture (Figure 1). T1-weighted and T2-weighted magnetic resonance images (MRI) of the left pedicle showed

Received for publication June 3, 2020 ; accepted July 18, 2020.

Address correspondence and reprint requests to Kazuta Yamashita, MD, PhD, Tokushima University Graduate School of Medicine, 3-18-15 Kuramoto, Tokushima, 770-8503, Japan and Fax : +81-88-633-0178.

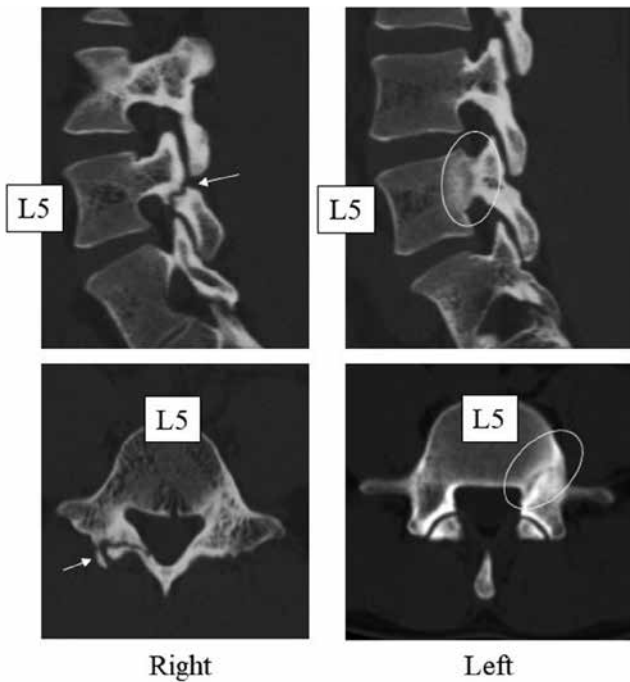


Figure 1. Computed tomography (CT) scans at the first visit show right-sided unilateral spondylolysis (terminal stage, arrow) and a high density area around a low density area at the left pedicle suggestive of a stress fracture (circle).

low signal intensity, also suggesting a chronic stress fracture (Figure 2).

Based on these findings, we diagnosed a left pedicle fracture subsequent to right unilateral lumbar spondylolysis and strongly suspected the source of pain as the left pedicle fracture. However, the cause of the pedicle fracture was the contra-lateral pars fracture. Given that the patient had repeated painful episodes, we considered that direct repair of both the right pars and left pedicle fractures was indicated.

Surgical intervention

We opted for minimally invasive direct repair surgery using the smiley face rod method (7), whereby the pars is repaired

directly using a pair of percutaneous pedicle screws (PPS) and a U-shaped modular link that passes beneath the spinal process and stabilizes the fracture. This technique is a modification of minimally invasive direct repair using PPS and a hook construct (8). We placed the patient in the prone position on a hall frame. A 5-cm midline skin incision was made to expose the lamina and right pars defect. The defect was covered with synovial tissue with surrounding bursitis. We removed them with a curette and then performed decortication using a diamond surgical bur. Next, two small 2-cm incisions were made at 3 cm lateral from the midline for insertion of the PPS. Before insertion, a cancellous bone graft was harvested from the left iliac crest via the incision for the PPS. After the PPS was inserted bilaterally, a curved rod (length 110 mm) was placed just beneath the spinous process to fix the lamina. Bone grafts combined with bone marrow and artificial bone were then placed on the pars defect. Finally, we placed a drainage tube and closed the wound. Plain radiographs after the surgery confirmed the two pedicle screws were inserted correctly and the entire lamina was secured with the U-shaped rod (Figure 3). Operative time and blood loss were 105 minutes and 110 ml.

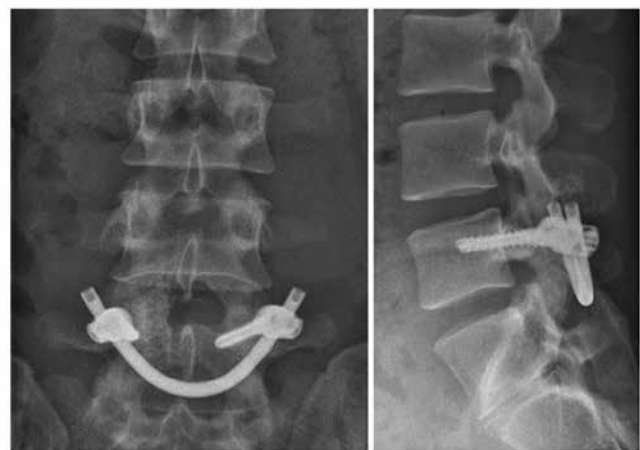


Figure 3. Plain radiographs after the surgery show correct placement of the two pedicle screws and the entire lamina secured with the U-shaped rod.

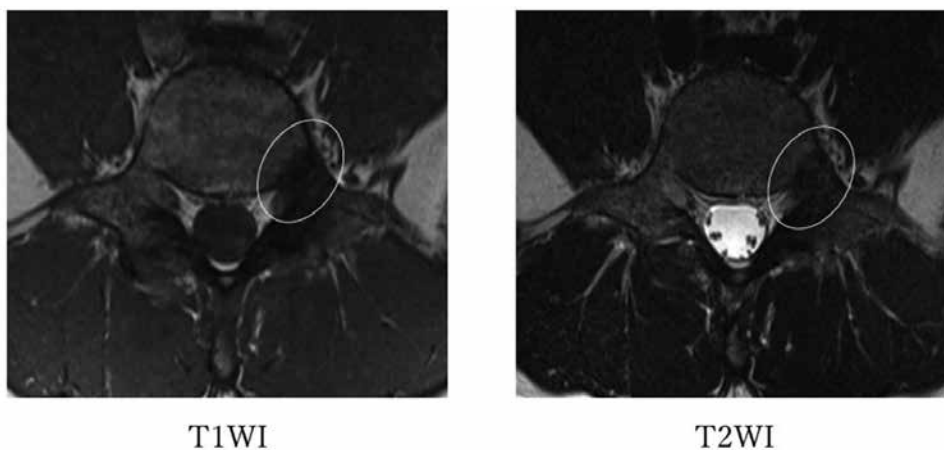


Figure 2. T1-weighted and T2-weighted magnetic resonance images at L5 show an area of low signal intensity suggesting healing of the fracture (circle).

Postoperative course

The patient underwent rehabilitation consisting of core trunk muscle stabilization and mobilization of the thorax and tendons of the lower extremities, including the hamstrings. Three months after surgery, he made a partial return to baseball practice. Six months after surgery, both fractures achieved complete bony union (Figure 4) and the patient returned to his original competitive level of play. In the 2 years since the surgery, he is playing well and has the potential to become a professional baseball player.

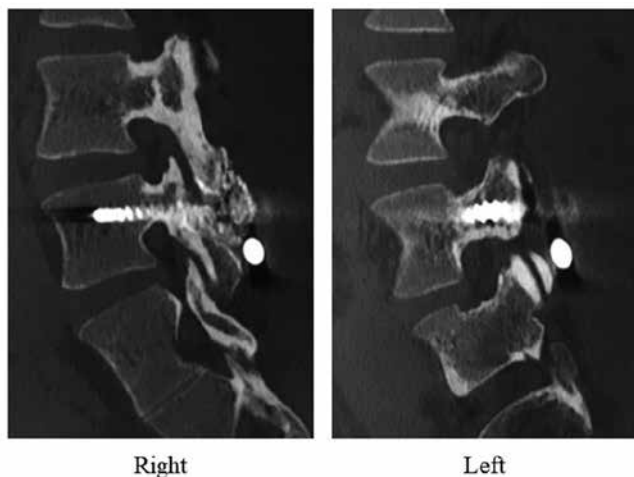


Figure 4. Sagittal CT scans 6 months after surgery confirm bone fusion at both the pedicle and pars fractures.

DISCUSSION

In this case, surgical treatment was successful for unilateral pars fracture and contralateral pedicle fracture in a young high-performing baseball player. The pedicle fracture was not diagnosed for about 1 year, highlighting the potential difficulties in diagnosing a pedicle fracture. In this case, we opted for direct repair for both fractures. Postoperatively, the patient could return to sport at a highly competitive level.

Diagnosis

Fractures can usually be diagnosed on plain radiographs. However, plain radiographs are not always adequate for diagnosis of a pedicle fracture. Jeong *et al.* (9) highlighted the importance of CT and MRI in diagnosing these fractures. In our case, diagnosis was not possible from plain radiographs for more than 1 year. Yamashita *et al.* (10) also demonstrated the diagnostic importance of CT and MRI when identifying the pain generator in 13 pediatric patients with low back pain. In our case, the pedicle stress fracture was easily identified on CT and MRI (Figures 1 and 2).

When a very active athlete with a diagnosis of unilateral spondylolysis complains of contralateral low back pain, we believe that it is important to check for a contralateral pars or pedicle fracture. A biomechanics study that investigated changes in stress after development of unilateral spondylolysis, using finite element analysis, revealed that the increase in stress on the pedicle was up to 12.6-fold that in the normal case. As mentioned in the Introduction, unilateral spondylolysis may be a precursor to a fracture on the contralateral side. To identify the pain source as contralateral pedicle fracture, it is important to have the

knowledge about it and make effort to search the pain source. Taking careful physical examination and appropriate radiological findings like CT and MRI, it is not difficult to reach the real pain source.

Treatment

The literature contains several case reports on unilateral spondylolysis with a contralateral pedicle fracture (5, 6, 9, 11-17). We have treated previous cases conservatively and obtained osseous healing (5, 6). Guillodo *et al.* (14) similarly reported that a pedicle stress fracture could heal osseously without surgery. Vialle *et al.* (17) reported successful treatment of a 12-year-old boy with an acute L5 pedicle fracture and contralateral spondylolysis using a Boston brace. The pedicle fracture healed osseously and they concluded that conservative treatment should be considered a treatment option in skeletally immature patients. Jeong *et al.* (9) reported a 35-year-old patient with a pedicle fracture that was already at the pseudoarthrosis stage whose pain could be managed with rehabilitation and activity modification. However, surgical management has sometimes been required (12, 13, 15).

In this case, the left pedicle stress fracture likely recurred a couple of times given that the patient experienced episodes of the low back pain within the previous year. Therefore, we decided on surgical management of the left pedicle fracture, which was the pain generator in this patient. However, there remained the question of how to treat the painless right pars fracture in the terminal stage. If we treated the pedicle fracture only, the unilateral spondylolysis would have remained after the surgery for the pedicle fracture. We therefore decided to treat this fracture simultaneously given that unilateral spondylolysis is the precursor for contralateral pars or pedicle fracture.

There were possible three surgical options in our case: a right Buck screw (18) and left pedicle screw; a right pedicle screw hook rod (8, 19) and a left pedicle screw; and bilateral pedicle screws and the smiley face rod method (7, 20). Because the patient is a very active baseball pitcher who is highly likely to become a professional player, his lumbar spine needed to withstand repetitive loading in extension, flexion, and rotation after the surgery. A Buck screw through the pars interarticularis may also be loaded during such repetitive mechanical stress at the pars after surgery, and a hook placed near the facet joint could have interfered with this joint during strong rotation movements (19). Therefore, we decided on the smiley face rod method, whereby two pedicle screws and a U-shaped rod can support the entire lamina including the pars without interfering with any other spinal construct. There is a couple of pit falls in performing smiley face rod method. It is important to contact the U-shaped rod to the caudal side of spinous process, otherwise appropriate compression force to the pars would not occur. In this case, having achieved complete bony union with enough compression force, the patient is now able to play well without removal of the implant.

CONCLUSION

We encountered a rare case of left pedicle stress fracture and right pars fracture in a young adult baseball player. The exact diagnosis was elusive for about 1 year and CT and MRI were useful for definitive diagnosis. Because 1 year of conservative treatment was not effective, we opted for surgical treatment. The patient could return to his original competitive level postoperatively. There have been no further fractures in the 2 years since the surgery and, importantly, he no longer has any low back pain. Physicians should pay attention to the contralateral pars and pedicle if there is pain at the contralateral side of unilateral spondylolysis.

CONFLICT OF INTEREST

All authors have no conflict of interest.

REFERENCES

1. Standaert CJ, Herring SA : Spondylolysis : a critical review. *Br J Sports Med* 34 : 415-422, 2000
2. Sairyo K, Sakai T, Yasui N : Conservative treatment of lumbar spondylolysis in childhood and adolescence : the radiological signs which predict healing. *J Bone Joint Surg Br* 91 : 206-209, 2009
3. Sakai T, Sairyo K, Takao S, Nishitani H, Yasui N : Incidence of Lumbar Spondylolysis in the General Population in Japan Based on Multi-detector CT Scans from 2,000 Subjects. *Spine* 21(34) : 2345-2350, 2009
4. Beutler WJ, Fredrickson BE, Murtland A, Sweeney CA, Grant WD, Baker D : The natural history of spondylolysis and spondylolisthesis : 45-year follow up evaluation. *Spine* 28 : 1027-1035, 2003
5. Sairyo K, Katoh S, Sasa T, Yasui N, Goel VK, Vadapalli S, Masuda A, Biyani A, Ebraheim N : Athletes with unilateral spondylolysis are at risk of stress fracture at the contralateral pedicle and pars interarticularis : A clinical and biomechanical study. *Am J Sports Med* 33 : 583-590, 2005
6. Sairyo K, Katoh S, Sakamaki T, Komatsubara S, Endo K, Yasui N : Three successive stress fractures at the same vertebral level in an adolescent baseball player. *Am J Sports Med* 31 : 606-610, 2003
7. Yamashita K, Higashino K, Sakai T, Takata Y, Hayashi F, Tezuka F, Morimoro M, Nagamachi A, Sairyo K : The reduction and direct repair of isthmic spondylolisthesis using the smiley face rod method in adolescent athlete : technical note. *J Med Invest* 64 : 168-172, 2017
8. Sairyo K, Sakai T, Yasui N : Minimally invasive technique for direct repair of pars interarticularis defects in adults using a percutaneous pedicle screw and hook-rod system. *J Neurosurg Spine* 10(5) : 492-495, 2009
9. Jeong IH, Hwang EH, Bae WT : Contralateral pedicular fracture with unilateral spondylolysis. *J Korean Neurosurg Soc* 46 : 584-587, 2009
10. Yamashita K, Sakai T, Takata Y, Tezuka F, Manabe H, Morimoto M, Kinoshita Y, Yonezu H, Chikawa T, Mase Y, Sairyo K : Low back pain in adolescent athletes : Comparison of diagnoses made by general orthopedic surgeons and spine surgeons. *Int J Spine Surg* 30 ; 13(2) : 178-185, 2019.
11. Aland C, Rineberg BA, Malberg M, Fried SH : Fracture of the pedicle of the fourth lumbar vertebra associated with contralateral spondylolysis. *J Bone Joint Surg Am* 68 : 1454-1455, 1986
12. Weatherley CR, Mehdian H, Berghe LV : Low back pain with fracture of the pedicle and contralateral spondylolysis. A technique of surgical management. *J Bone Joint Surg Br* 73 : 990-993, 1991
13. Gunzburg R, Fraser RD : Stress fracture of the lumbar pedicle. Case reports of "pediculolysis" and review of the literature. *Spine* 16 : 185-189, 1991
14. Guillodo Y, Botton E, Saraux A, Le Goff P : Contralateral spondylolysis and fracture of the lumbar pedicle in an elite female gymnast. A case report. *Spine* 25 : 2541-2543, 2000
15. Garber JE, Wright AM : Unilateral spondylolysis and contralateral pedicle fracture. *Spine* 11 : 63-66, 1986
16. Kessous E, Borsinger T, Rahman A, d'Hemecourt PA : Contralateral spondylolysis and fracture of the lumbar pedicle in a young athlete. *Spine* 42(18) : E1087-E1091, 2017
17. Vialle R, Mary P, de Carvalho A, Ducou le Pointe H, Damsin JP, Filipe G : Acute L5 pedicle fracture and contralateral spondylolysis in a 12-year-old boy : a case report. *Eur Spine J* 16 Suppl 3(Suppl 3) : 316-317, 2007
18. Higashino K, Sairyo K, Katoh S, Sakai T, Kosaka H, Yasui N : Minimally invasive technique for direct repair of the pars defects in young adults using a spinal endoscope : a technical note. *Minim Invasive Neurosurg* 50(3) : 182-186, 2007
19. Arai T, Sairyo K, Shibuya I, Kato K, Dezawa A : Multilevel direct repair surgery for three-level lumbar spondylolysis. *Case Rep Orthop* 472968, 2013
20. Sumita T, Sairyo K, Shibuya I, Kitahama Y, Kanomori Y, Matsumoto H, Koga S, Kitagawa Y, Dezawa A : V-rod technique for direct repair surgery of pediatric lumbar spondylolysis combined with posterior apophyseal ring fracture. *Asian Spine J* 7(2) : 115-118, 2013