

## REVIEW

# Basic research and surgical techniques for brain arteriovenous malformations

Yasushi Takagi, Yasuhisa Kanematsu, Yoshifumi Mizobuchi, Hideo Mure, Kenji Shimada, Yoshiteru Tada, Ryoma Morigaki, Shu Sogabe, Toshitaka Fujihara, Takeshi Miyamoto, and Kazuhisa Miyake

*Department of Neurosurgery, Graduate School of Biomedical Sciences, Tokushima University, Tokushima, Japan*

**Abstract :** Arteriovenous malformations (AVMs) are hemorrhagic vascular diseases in which arteries and veins are directly connected with no capillary bed between the two. We herein introduce the results of basic research of this disease and surgical techniques based on our data and experiences. The results obtained from our research show that cell death- and inflammation-related molecules changed or became activated compared with control specimens. These findings indicate that chronic inflammation occurs in and around the nidus of AVMs. Various molecules are involved in the mechanisms of cell death and angiogenesis during this process. Confirmation of blood flow in the nidus is very important to avoid hemorrhagic complications during surgical removal of the nidus. The risk of hemorrhage increases when the blood flow in the nidus is not reduced. We reported the advantages of serial indocyanine green videoangiography, which is used to assess the blood flow during AVM nidus removal. Since publication of the ARUBA trial and Scottish Audit, treatments with high morbidity have not been allowed. It is especially important for neurosurgeons to treat low Spetzler–Martin grade AVMs with low morbidity. *J. Med. Invest.* 67:222-228, August, 2020

**Keywords :** Arteriovenous malformations, basic research, surgical techniques, ICG videoangiography

## INTRODUCTION

Arteriovenous malformations (AVMs) are hemorrhagic vascular diseases in which arteries and veins are directly connected with no capillary bed between the two. Their origin is unknown, and they may cause intracerebral hemorrhage in younger patients. We herein introduce the results of basic research of this disease and surgical techniques based on our data and experiences.

## BASIC RESEARCH OF AVMS

Molecular and histological studies of human brain AVM specimens shows that the levels of angiogenic factors and inflammatory cytokines are higher in AVMs than those in normal brain. Brain AVMs are also infiltrated with inflammatory cells. However, the pathogenesis of brain AVMs is not completely clarified (1). Abnormal expression patterns of inflammatory mediators and cytokines, as well as an influx of inflammatory cells in AVMs, have been observed by a lot of investigators(2-6). Inflammatory markers are overexpressed in AVMs, including myeloperoxidase (MPO) and IL-6, both of which highly correlate with matrix MMP-9 expression. Remodeling of the vascular network in AVMs is facilitated by a number of proteases that can enlarge the vascular elements in the nidus. This remodeling is partially mediated through VEGF activity and modulated by proangiogenic signals such as MMP expression. MMP-9 is expressed at significantly higher levels in bAVMs than in control tissue (3,7). MMP-9 expression and activity during inflamma-

tion are stimulated by the cytokines IL-1 $\beta$ , and IL-6.

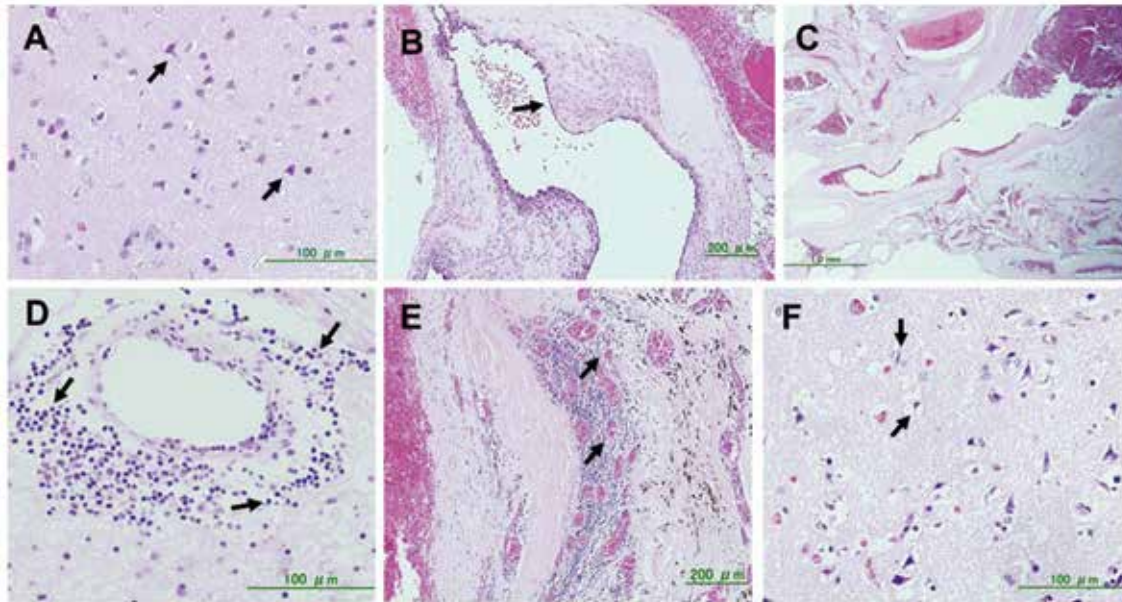
The main histopathological features of AVMs are venous ectasia, microvessel proliferation, inflammatory cell infiltration, and endothelial thickening (Figure 1) (8). Among these characteristics, endothelial thickening is more common in patients of advanced age, patients with a compact nidus, male patients, patients with Spetzler–Martin grade I or II AVMs, and patients with higher flow than in any other patients, according to our previous reports. In addition, venous ectasia is more common in patients of advanced age (8). Based on these characteristics, AVMs are not only vascular anomalies but are also dynamically changing and active vascular lesions. We investigated the changes in vascular walls in the nidus and perinidal neurons of AVMs mainly by molecular immunohistochemical methods. First, we reported that apoptotic cells exist in the vascular walls of the nidus and perinidal areas (9). Proliferating cell nuclear antigen-positive cells possessing proliferative activity were located in the walls of the nidus. In addition, these cells were positive for phosphorylated extracellular signal-regulated kinase (ERK), which is a mitogen-activated protein kinase (10). Phosphorylated ERK reportedly induces cell proliferation in many cell types. These observations indicate that many biological events occur in and around AVMs. Apoptosis of the neurons in perinidal areas occurs through caspase-8, which triggers neuronal apoptosis (11). In the vascular walls of the nidus and infiltrating cells around the nidus, transcription factors, including nuclear factor kappa B, Signal transduction and activator of transcription (STAT)3, and STAT1, are also activated (Figure 2) (5,12). These factors induce cell death and angiogenesis. In younger patients with early regrowth of the nidus, increased expression of CD105 and phosphorylated ERK can induce angiogenesis (13). We also performed DNA array analysis using AVM specimens (14). Smooth muscle cells (SMCs) in the vascular walls have been reported to be involved in the remodeling process in AVMs. SMC dedifferentiation from a contractile to a synthetic phenotype occurs in brain AVMs, particularly in arterialized veins, which is characterized by the expression of smooth muscle myosin

Received for publication April 21, 2020 ; accepted June 15, 2020.

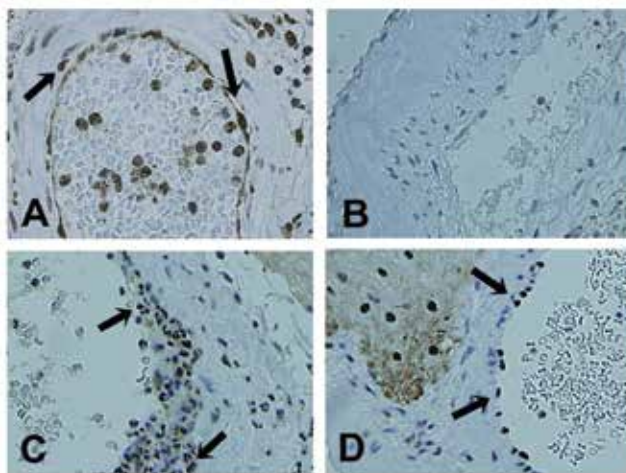
Address correspondence and reprint requests to Yasushi Takagi, M.D., Ph. D., Department of Neurosurgery, Graduate School of Biomedical Sciences, Tokushima University, 3-18-15 Kuramoto-cho, Tokushima 770-8503, Japan and Fax : +81-88-632-9464.

heavy chain (Figure 3). The results obtained from this study showed that cell death- and inflammation-related genes changed compared with control specimens. These findings indicate that chronic inflammation occurs in and around the nidus of AVMs. Various molecules are involved in the mechanisms of cell death and angiogenesis during this process (Figure 4).

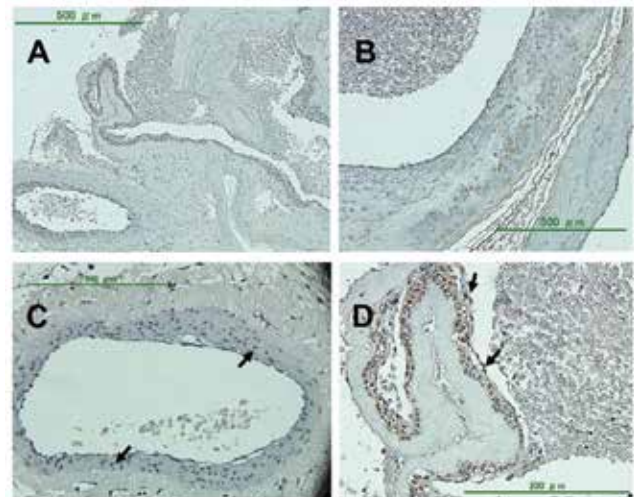
A recent topic in basic research of AVMs is the presence of KRAS mutations in the endothelial cells of the nidus (15). We also reported KRAS mutations using Japanese samples (16). These observations also indicate that AVMs are not only congenital vascular malformations but also dynamically changing lesions.



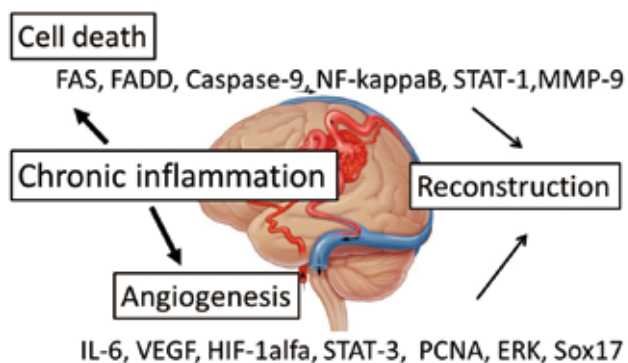
**Figure 1.** Hematoxylin-eosin staining of human brain AVM tissues. A. Neuronal death with various degrees of nuclear degeneration (arrows) at perinidal cortical tissues with accompanying moderate degree of gliosis. B. Increased intimal thickness at some regions of the venous wall (arrow). C. Severe venous enlargement. D. Infiltrating cells surrounding the vessels (arrows). E. Microvessel accumulation (arrows) with profound infiltrating cells at the enlarged and hyperplastic vein. F. Loss of neuronal structure at the cortical tissue with profound degree of reactive gliosis and neuronal death (arrows).



**Figure 2.** Activation of STAT3 in the endothelial and perivascular infiltrating inflammatory cells of the AVM specimens (cytoplasmic and nuclear immunoreactivity). A. Nuclear immunoreactivity for phospho-STAT3 Ser727 in the intima (arrows). B. No immunoreactivity for STAT3 in the control areas in a highly magnified image. C. Nuclear immunoreactivity for phospho-STAT3 Ser727 in the perivascular area (arrows). D. Nuclear immunoreactivity for phospho-STAT3 Tyr705 in the intima (arrows) (from Aziz *et al.*, World Neurosurg 78(5) : 487-97, 2012).



**Figure 3.** Photomicrographs of SMemb-positive vessels in human brain AVMs. A. SMemb expression at both vein and artery sites. B. Positive SMemb cells that were distributed along the tunica media through the intimal layer of the vein; furthermore, the positive cells had rounded morphology, presumably resembling the synthetic phenotype of VSMCs. C. SMemb-positive cells were spread out in the tunica media of the artery (arrows). D. SMemb-positive cells at the intimal layer of veins (arrows).



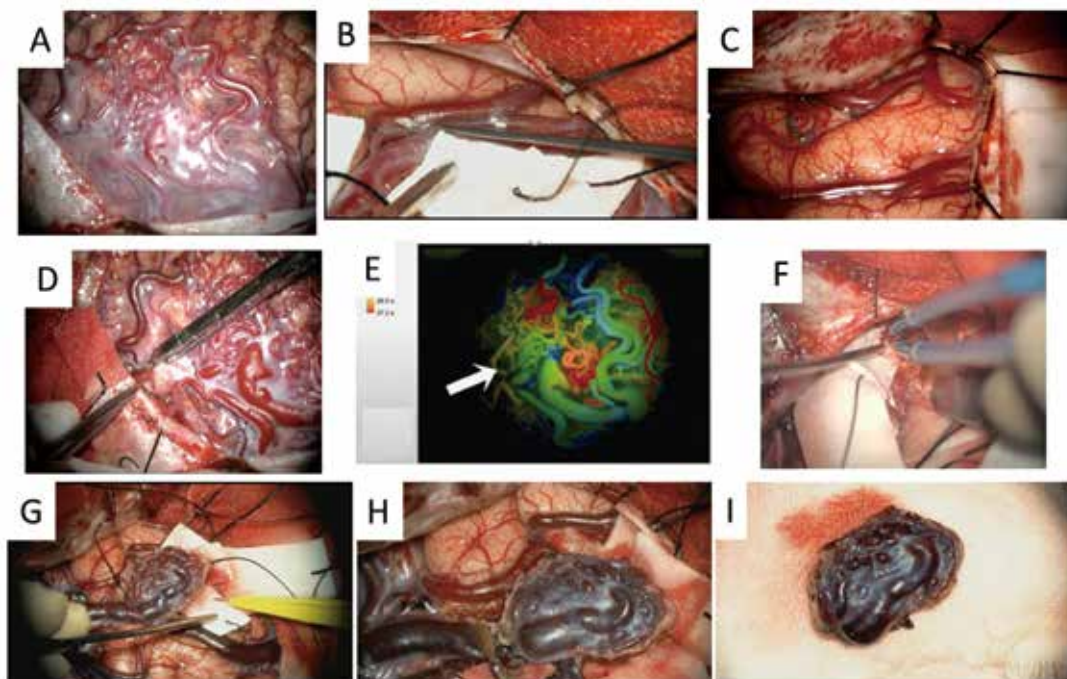
**Figure 4.** Biological function of various molecules in and around the nidus of brain AVMs.

### SURGICAL TECHNIQUES OF AVMs

Base on the history of neurosurgery, one of the most famous modern neurosurgeons, Walter E. Dandy termed AVMs as “arteriovenous aneurysms” and reported high morbidity and mortality after surgical treatment (17). More than 90 years since Dandy’s report, AVM is still difficult to be treated without morbidity. Recently, two important reports were published about the treatment of AVMs. The surgical strategy for unruptured AVMs changed after publication of these two reports, the ARUBA trial and Scottish Audit (18,19). Furthermore, a novel scientific statement from the AHA/ASA was published in 2017 (20). This statement described the treatment of unruptured AVMs. Two clinical

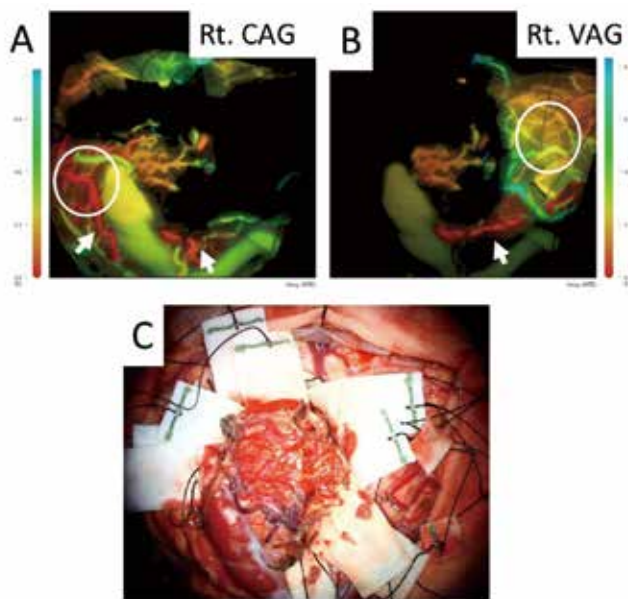
trials (ARUBA and the Scottish Audit) support more conservative management of unruptured AVMs. However, two major limitations weakened the described management strategy. These clinical studies had short follow-up periods and included small numbers of juvenile patients. The surgical morbidity rate was higher than expected. Among patients with ruptured AVMs, small and superficial AVMs can be removed during emergency surgery; however, emergency removal is associated with a risk of increased morbidity and mortality. Deep-seated AVMs should be treated 2 to 6 weeks after hemorrhage. In patients with Spetzler–Martin high-grade AVMs, worsen neurological deficit was considered even in the cases of patients with neurological symptoms. Based on these statements, unruptured AVMs should be treated after consideration of the surgical risk, treatment modality, and life expectancy. In patients with ruptured AVMs, treatment options and modalities should be determined after careful consideration of the surgical risks and benefits (20). We emphasize that safe surgical treatment and low morbidity are most important, especially in patients with unruptured AVMs.

The concept of direct microsurgery for AVMs involves dividing and removing easily accessed hemorrhagic vascular lesions from the brain tissue using the gliotic tissue, in which neurons are degenerating and decreasing in number (21,22,23). The use of non-stick bipolar forceps that do not stick to burned brain tissue and assessment of blood flow in the nidus during surgical removal are important in this procedure (23,24). The steps of AVM nidus removal are as follows: (i) confirmation of the nidus, (ii) dissection of the arachnoid around the nidus, (iii) confirmation of the locations of feeders and drainers, (iv) clipping or coagulation of the feeders, (v) confirmation of blood flow in the nidus, (vi) subpial dissection of the nidus, (vii) nidus dissection, (viii) coagulation and cutting of the drainers, and (ix) removal of the nidus (Figure 5) (22,23). Among these steps, confirmation of blood flow

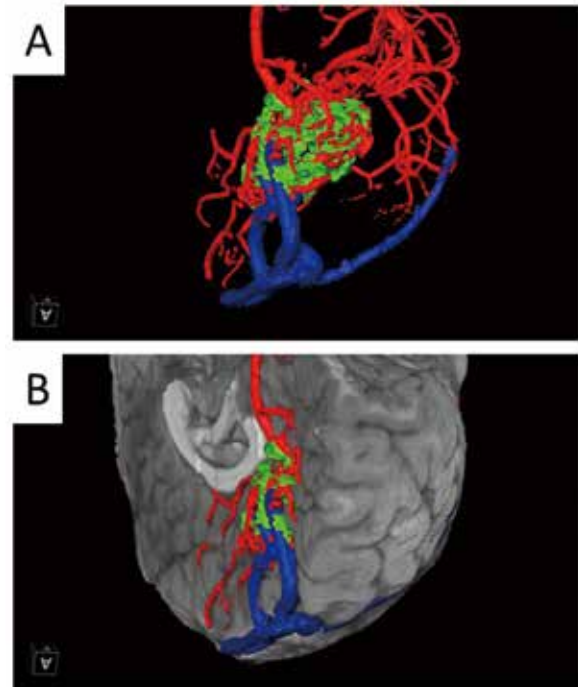


**Figure 5.** Steps of microsurgical dissection for brain AVMs using ICG videoangiography. A. AVM nidus. B. Arachnoid dissection. C. Feeder and drainer confirmation. D. Feeder clipping. E. Confirmation of nidus flow by ICG videoangiography. Color map represents the flow speed in the nidus assessed by FLOW800 software based on fluorescent image evoked by Near infrared ray under operative microscope. Red is fast flow and blue is slow flow. F. Subpial dissection. G. Nidus dissection. H. Drainer coagulation. I. Nidus removal

in the nidus is very important for avoiding hemorrhagic complications. The risk of hemorrhage increases when the blood flow in the nidus is not reduced. We first reported the advantages of serial indocyanine green (ICG) videoangiography, which is used to assess the blood flow during AVM nidus removal. In 2007, we introduced this technique after receiving approval from the ethics committee of Kyoto University Graduate School of Medicine. In 2007, we also reported its usefulness in assessment of a residual nidus in children with AVM. In 2010, we reported the advantages and efficacy of this technique in the surgical treatment of AVMs (24). We now employ this technique in our hybrid operation room using simultaneous cerebral angiography at Kyoto University. At Tokushima University, we also employ this method in the hybrid operation room and use it for intra-arterial administration of ICG. This method allows surgeons to achieve a clearer and sharper image of ICG (Figure 6). Furthermore, we reported the usefulness of three-dimensional simulation in the surgical treatment of AVMs (23,25). Using Amira or Vincent software, an operative view can be obtained before surgery with a combination of magnetic resonance imaging, cerebral angiography, and computed tomography. Three-dimensional simulation reveals the location of the deep-seated feeders and the extent of the nidus, enabling surgeons to perform safe direct surgical treatment of AVMs (Figure 7). In addition, the combination of magnetic resonance imaging and tractography allows visualization of the corticospinal tract and confirms the location of the tract that the surgeon should not injure. Three-dimensional simulation is effective for avoiding postoperative complications.



**Figure 6.** Transarterial ICG videoangiography in Case 1. A. ICG videoangiography from the catheter placed in the internal carotid artery discloses blood supply from feeders from the middle cerebral artery (see circle and arrow). B. ICG videoangiography from the catheter placed in the vertebral artery discloses blood supply from feeders from the posterior cerebral artery (see circle and arrow). (Rt. CAG: right carotid angiogram, Rt.VAG: right vertebral angiogram). Color map represents the flow speed in the nidus assessed by FLOW800 software based on fluorescent image evoked by Near infrared ray under operative microscope. Red is fast flow and blue is slow flow. C. Intraoperative view after total dissection of the nidus of AVM.



**Figure 7.** 3D simulation image. Red: artery, green: nidus, blue: vein. A. The location and relationship between the nidus and vessels are indicated. B. The nidus is buried in the interhemispheric surface of the brain.

## CASE ILLUSTRATIONS

**Case 1.** A 43-year-old woman with an unruptured frontal Spetzler–Martin grade II AVM underwent surgical treatment after coil embolization of the feeders. Transarterial ICG videoangiography showed blood flow from the middle cerebral artery and vertebral artery on Flow 800 software (Figures 6 and 8).

**Case 2.** A 13-year-old boy with a ruptured occipital Spetzler–Martin grade III AVM underwent transarterial ICG videoangiography, which showed blood flow in the drainer (Figure 9).

## REAL-WORLD SURGICAL TREATMENT OF AVMS

AVM patients are referred to Kyoto University hospital not only from Kyoto prefecture but also from Osaka, Shiga, and other prefectures. Both surgically treated patients and conservatively managed patients are admitted to the hospital. From January 2008 to October 2017, 102 patients were admitted to the hospital. Among them, 62 patients were surgically treated; 91% of patients with Spetzler–Martin grade I and II AVMs and 46% of patients with Spetzler–Martin grade III and IV AVMs were surgically treated. Among those with grade II AVMs, non-hemorrhagic cases tended to be treated by stereotactic radiosurgery. More recently, the proportion of patients treated by direct surgery has decreased and the proportion treated by irradiation has increased. Patients are referred to Tokushima University Hospital from the entirety of Tokushima prefecture and parts of Kagawa, Ehime, and Kochi prefectures. Most admitted patients are surgically treated. Tokushima University Hospital has a stroke care unit. About 300 patients per year are admitted to the hospital. Among them, about 60 patients have hemorrhagic

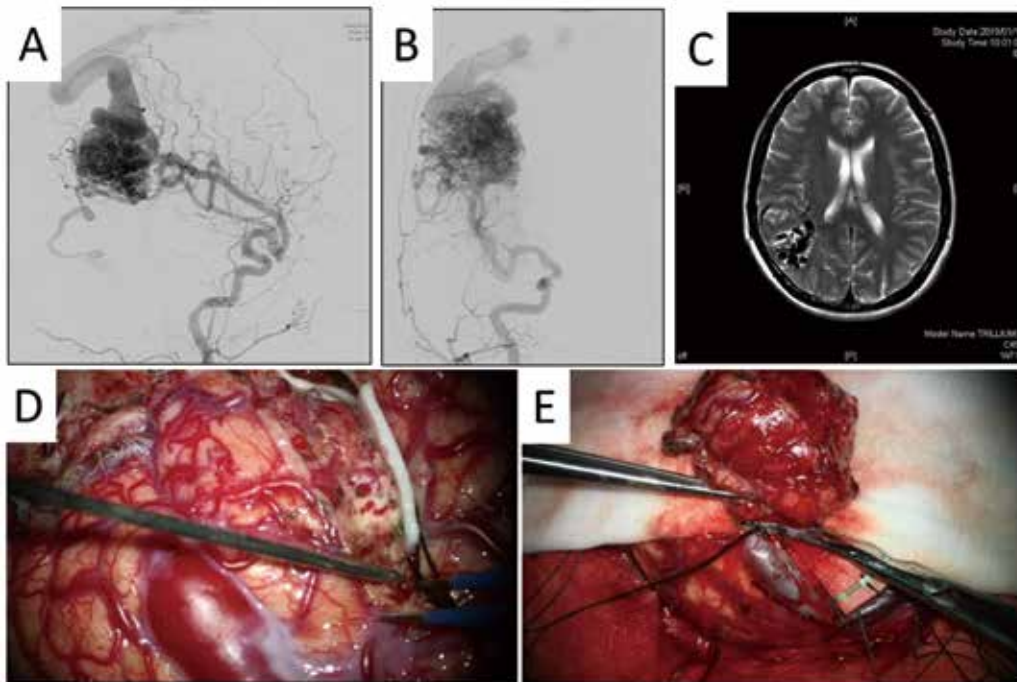


Figure 8. Case 1. A. Right internal cerebral angiogram (lateral view). B. Right internal cerebral angiogram (AP view). C. MRI T2 weighed image; AVM is located in the right frontal lobe. D and E. Intraoperative view.

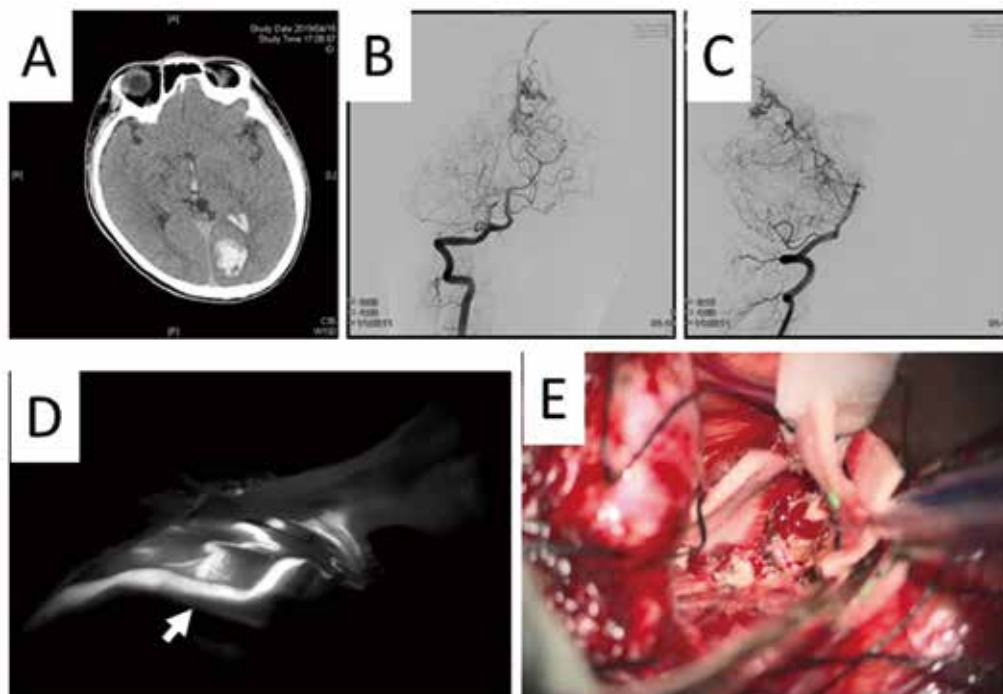


Figure 9. Case 2. A. CT. B. Right vertebral angiogram (AP view). C. Right vertebral angiogram (lateral view). AVM is located in the left occipital lobe. D. ICG videoangiography from the catheter placed in vertebral artery discloses blood in the drainer (see arrow). White signal means fluorescent image evoked by Near infrared ray under operative microscope. The density and speed of white signal means blood volume and blood flow. E. Intraoperative view.

disease. From January 2008 to March 2020, 41 patients with AVMs were surgically treated; 30 had hemorrhagic disease and 11 had non-hemorrhagic disease. Twenty-nine patients had Spetzler–Martin grade I or II AVMs (26).

## FUTURE PERSPECTIVE

Since publication of the ARUBA trial and Scottish Audit, treatment with high morbidity has not been allowed. It is important for us to achieve surgical treatment of Spetzler–Martin grade I and II AVMs with low morbidity. For Spetzler–Martin high-grade AVMs, it is also important to select which cases can be treated with low morbidity. Novel treatments are needed for patients with a poor prognosis or high morbidity. Both our basic research and recent studies on genetic mutations in the endothelium of the nidus show that AVMs are not only congenital vascular anomalies but also dynamically changing lesions.

## REFERENCES

- Chen W, Choi EJ, McDougall CM, Su H : Brain arteriovenous malformation modeling, pathogenesis, and novel therapeutic targets. *Transl Stroke Res* 5(3) : 316-329, 2014
- Pawlikowska L, Tran MN, Achrol AS, McCulloch CE, Ha C, Lind DL, Hashimoto T, Zaroff J, Lawton MT, Marchuk DA, Kwok PY, Young WL ; UCSF BAVM Study Project : Polymorphisms in genes involved in inflammatory and angiogenic pathways and the risk of hemorrhagic presentation of brain arteriovenous malformations. *Stroke* 35(10) : 2294-300, 2004
- Chen Y, Fan Y, Poon KY, Achrol AS, Lawton MT, Zhu Y, McCulloch CE, Hashimoto T, Lee C, Barbaro NM, Bollen AW, Yang GY, Young WL : MMP-9 expression is associated with leukocytic but not endothelial markers in brain arteriovenous malformations. *Front Biosci* 11 : 3121-3128, 2006
- Shenkar R, Shi C, Check IJ, Lipton HL, Awad IA : Concepts and hypotheses : inflammatory hypothesis in the pathogenesis of cerebral cavernous malformations. *Neurosurgery* 61(4) : 693-702, 2007
- Aziz MM, Takagi Y, Hashimoto N, Miyamoto S : Activation of nuclear factor  $\kappa$ B in cerebral arteriovenous malformations. *Neurosurgery* 67(6) : 1669-1680, 2010
- Sturiale CL, Puca A, Sebastiani P, Gatto I, Albanese A, Di Rocco C, Maira G, Pola R : Single nucleotide polymorphisms associated with sporadic brain arteriovenous malformations: where do we stand? *Brain* 136(Pt 2) : 665-681, 2013
- Hashimoto T, Wen G, Lawton MT, Boudreau NJ, Bollen AW, Yang GY, Barbaro NM, Higashida RT, Dowd CF, Halbach VV, Young WL ; University of California, San Francisco BAVM Study Group : Abnormal expression of matrix metalloproteinases and tissue inhibitors of metalloproteinases in brain arteriovenous malformations. *Stroke* 34(4) : 925-931, 2003
- Hermanto Y, Takagi Y, Yoshida K, Ishii A, Kikuchi T, Funaki T, Mineharu Y, Miyamoto S : Histopathological Features of Brain Arteriovenous Malformations in Japanese Patients. *Neurol Med Chir (Tokyo)* 56(6) : 340-344, 2016
- Takagi Y, Hattori I, Nozaki K, Ishikawa M, Hashimoto N : DNA fragmentation in central nervous system vascular malformations. *Acta Neurochir (Wien)* 142(9) : 987-994, 2000
- Takagi Y, Kikuta K, Sadamasa N, Nozaki K, Hashimoto N : Proliferative activity through extracellular signal-regulated kinase of smooth muscle cells in vascular walls of cerebral arteriovenous malformations. *Neurosurgery* 58(4) : 740-748, 2006
- Takagi Y, Kikuta K, Nozaki K, Fujimoto M, Hayashi J, Hashimoto N : Neuronal expression of Fas-associated death domain protein and caspase-8 in the perinidal parenchyma of cerebral arteriovenous malformations. *J Neurosurg* 106(2) : 275-282, 2007
- Aziz MM, Takagi Y, Hashimoto N, Miyamoto S : Expression and activation of STAT family proteins in cerebral arteriovenous malformations. *World Neurosurg* 78(5) : 487-497, 2012
- Takagi Y, Kikuta K, Nozaki K, Hashimoto N : Early regrowth of juvenile cerebral arteriovenous malformations : report of 3 cases and immunohistochemical analysis. *World Neurosurg* 73(2) : 100-107, 2010
- Takagi Y, Aoki T, Takahashi JC, Yoshida K, Ishii A, Arakawa Y, Kikuchi T, Funaki T, Miyamoto S : Differential gene expression in relation to the clinical characteristics of human brain arteriovenous malformations. *Neurol Med Chir (Tokyo)* 54(3) : 163-175, 2014
- Nikolaev SI, Vetiska S, Bonilla X, Boudreau E, Jauhiainen S, Rezai Jahromi B, Khyzha N, DiStefano PV, Suutarinen S, Kiehl TR, Mendes Pereira V, Herman AM, Krings T, Andrade-Barazarte H, Tung T, Valiante T, Zadeh G, Tymianski M, Rauramaa T, Ylä-Herttuala S, Wythe JD, Antonarakis SE, Frösen J, Fish JE, Radovanovic I : Somatic Activating KRAS Mutations in Arteriovenous Malformations of the Brain. *N Engl J Med* 378(3) : 250-261, 2018
- Oka M, Kushamae M, Aoki T, Yamaguchi T, Kitazato K, Abekura Y, Kawamata T, Mizutani T, Miyamoto S, Takagi Y : KRAS G12D or G12V Mutation in Human Brain Arteriovenous Malformations. *World Neurosurg* 126 : e1365-e1373, 2019
- Dandy WE : Arteriovenous aneurysm of the brain. *Arch Surg* 17 : 190-243, 1928
- Mohr JP, Parides MK, Stapf C, Moquete E, Moy CS, Overbey JR, Al-Shahi Salman R, Vicaut E, Young WL, Houdart E, Cordonnier C, Stefani MA, Hartmann A, von Kummer R, Biondi A, Berkefeld J, Klijn CJ, Harkness K, Libman R, Barreau X, Moskowitz AJ ; international ARUBA investigators : Medical management with or without interventional therapy for unruptured brain arteriovenous malformations (ARUBA) : a multicentre, non-blinded, randomised trial. *Lancet* 383 : 614-621, 2014
- Al-Shahi Salman R, White PM, Counsell CE, du Plessis J, van Beijnum J, Josephson CB, Wilkinson T, Wedderburn CJ, Chandy Z, St George EJ, Sellar RJ, Warlow CP ; Scottish Audit of Intracranial Vascular Malformations Collaborators : Outcome after conservative management or intervention for unruptured brain arteriovenous malformations. *JAMA* 311 : 1661-1669, 2014
- Derdeyn CP, Zipfel GJ, Albuquerque FC, Cooke DL, Feldmann E, Sheehan JP, Torner JC, American Heart Association Stroke Council : Management of Brain Arteriovenous Malformations : A Scientific Statement for Healthcare Professionals From the American Heart Association/American Stroke Association. *Stroke* 48(8) : e200-e224, 2017
- Hashimoto N, Nozaki K, Takagi Y, Kikuta K, Mikuni N : Surgery of cerebral arteriovenous malformations. *Neurosurgery* 61(1 Suppl) : 375-87, 2007
- Takagi Y, Hashimoto N : Fundamental Surgical Techniques for Cerebral Arteriovenous Malformations. *Neurological Surgery No Shinkei Geka* 34(12) : 1207-1214, 2006
- Takagi Y : Surgically treating Brain Arteriovenous Malformations : Selecting Treatment Options after the ARUBA Trial. *Jpn J Neurosurg (Tokyo)* 26 : 117-124, 2017

24. Takagi Y, Sawamura K, Hashimoto N, Miyamoto S : Evaluation of serial intraoperative surgical microscope-integrated intraoperative near-infrared indocyanine green videoangiography in patients with cerebral arteriovenous malformations. *Neurosurgery* 70(1 Suppl Operative) : 34-42, 2012
25. Takagi Y : Surgical Resection using 3D Simulation, and Intraoperative ICG Videoangiography in Patients with Cerebral Arteriovenous Malformations located in the Non-superficial Eloquent Cortex : Technical-note. *Jpn J Neurosurg (Tokyo)* 25(3) : 259-263, 2016
26. Takagi Y : Real-world and Evidence in the Surgical Treatment of Brain Arteriovenous Malformation. *Jpn J Neurosurg (Tokyo)* 28 : 142-148, 2019