

REVIEW

Osteochondritis Dissecans of the Capitellum : Review of the Literature

Tetsuya Matsuura, Toshiyuki Iwame, Jyoji Iwase, and Koichi Sairyo

Department of Orthopedics, Tokushima University, Tokushima, Japan

Abstract : Osteochondritis dissecans (OCD) of the capitellum is a leading cause of elbow disability in adolescent baseball players. Previous studies have not found an association of player position with capitellar OCD. Elbow pain and a longer playing history might be related to progression of capitellar OCD but do not in themselves increase the risk of development of the condition. The cause of capitellar OCD is likely to include a combination of repetitive microtrauma and internal factors, such as ischemia and genetic predisposition. A combination of radiography, computed tomography, magnetic resonance imaging, and ultrasonography have aided our understanding of the pathology of capitellar OCD. Screening using ultrasonography enables early detection and provides an opportunity for successful conservative treatment. Treatment has conventionally included both operative and nonoperative measures based on the stage and size of the lesion, skeletal maturity, subjective symptoms, and structural integrity of the cartilage. Early-stage lesions respond better to nonoperative treatment than those in more advanced stages. Operative indications include persistent symptoms despite nonoperative treatment, symptomatic loose bodies, and displacement or detachment of fragments. *J. Med. Invest.* 67: 217-221, August, 2020

Keywords : elbow, osteochondritis dissecans, baseball

INTRODUCTION

Osteochondritis dissecans (OCD) of the capitellum is a leading cause of elbow disability in adolescent athletes and generally affects those, such as baseball players and gymnasts, who engage in repetitive overhead or weight-bearing activities involving the upper extremities. Capitellar OCD is relatively uncommon but can be responsible for prolonged absence from sports activity if advanced (1, 2). In this review, we address the epidemiology, etiology, imaging, and treatment of capitellar OCD.

EPIDEMIOLOGY

In 1933, Nielsen reported that capitellar OCD had a prevalence of over 4% in 1000 workers aged 15 years or older (3). However, his research has since been criticized for selection bias in that 10% of the participants in his study were patients with multiple other diseases and 90% were friends or family members visiting patients in the hospital.

There has been little research on the epidemiology of capitellar OCD in young baseball players, despite a substantial number of patients with this condition being known to play baseball. Some studies have investigated the epidemiology of capitellar OCD radiographically. In 1976, Gugenheim *et al.* screened 549 Little League pitchers aged 9–13 years and did not identify any cases of capitellar OCD (4). Similarly, Hang *et al.* investigated 343 Little League pitchers, catchers, and fielders aged 9–12 years and found capitellar OCD in only 1 player (0.3%) (5).

Harada *et al.* reported that ultrasonography was useful and reliable (as confirmed against radiographic findings) for detecting

elbow injuries (6). They performed ultrasonography in 153 baseball players aged 9–12 years in the field during practice and found 2 cases of capitellar OCD (1.3%) (6). Two cross-sectional studies that included a number of baseball players investigated the prevalence of capitellar OCD using ultrasonography. One of these studies was performed by our research group and included 1,040 baseball players aged 10–12 years; 2.1% of the players were found to have capitellar OCD and 90.9% of affected players had stage I lesions (7). In the other study, Kida *et al.* found that 3.4% of 2,433 baseball players aged 12–18 years had capitellar OCD and that 14.7% of affected players had stage I lesions, 38.2% had stage II lesions, and 13.2% had stage III lesions (8). These findings suggest that the risk of developing capitellar OCD is highest in players aged 10–12 years.

Previous studies of the prevalence of capitellar OCD in youth baseball players have used a cross-sectional design that did not allow for determination of the causes of any observed associations (4-8). Therefore, we followed a group of preadolescent baseball players prospectively to identify the risk factors for capitellar OCD and found the 1-year cumulative incidence to be 1.8% (9). Players aged 10–11 years were at significantly higher risk of capitellar OCD than their counterparts aged 6–9 years. Taking up baseball earlier in life, more years of play, and more training hours increases the amount of repetitive valgus stress on the humeral capitellum and may be risk factors for OCD at this site. However, none of these factors showed a significant association with capitellar OCD in our study (9). Kida *et al.* found that baseball players with capitellar OCD started playing baseball at an earlier age and had played for longer periods (8). They also found that capitellar OCD was associated with elbow pain (8); however, this association was not found in our study (9). Furthermore, the study by Kida *et al.* included a relatively low percentage of subjects with stage I capitellar OCD and a higher percentage of subjects with advanced capitellar OCD, as mentioned earlier. These findings suggest that elbow pain and a longer playing history are associated with progression of capitellar OCD but do not in themselves increase the risk of development of the condition. The number of throwing opportunities that baseball players

Received for publication December 1, 2019 ; accepted January 15, 2020.

Address correspondence and reprint requests to Tetsuya Matsuura, MD, PhD, Department of Orthopedics, Tokushima University, 3-18-15 Kuramoto, Tokushima 770-8503, Japan and Fax : +81-88-633-0178.

have depends on the player position. Pitchers and catchers perform the most throws, and playing in these positions is reported to be a risk factor for elbow injury (10, 11). However, previous studies did not find an association of player position with capitellar OCD (7-9) (Table 1).

Table 1. Comparison of studies of factors associated with capitellar OCD

	Matsuura <i>et al.</i> (9)	Kida <i>et al.</i> (8)
Study design	Prospective	Retrospective
Age, years	6–11	12–18
Stage	Early	Advanced
Elbow pain	Not associated	Associated
Age at starting baseball	Not associated	Associated
Years of play	Not associated	Associated

ETIOLOGY

Given the above-mentioned findings, the cause of capitellar OCD is likely to include a combination of repetitive microtrauma (12) and internal factors such as ischemia (13) and genetic pre-disposition (14-16).

Repetitive throwing is considered one of the main causes of capitellar OCD. During the acceleration phase of throwing, the elbow joint may be stressed into a valgus position and the capitellum may be subjected to compression and shear forces. Momma *et al.* measured the distribution of subchondral bone density through the distal articular surface of the humerus using a computed tomography (CT) osteoabsorptiometry method (12). They demonstrated a significant distribution of the area of maximum density in the anterior part of the capitellum in pitchers. Differences in the biomechanical properties of the radial head and capitellum are also believed to contribute to microtrauma, with the stiffer radial head articulating with the softer lateral capitellar surface and causing increased strain (17).

Haraldsson, in what we believe to have been the first description of the blood supply to the capitellum, noted that the blood supply was predominantly from the arteries entering posteriorly and passing through the compressible epiphyseal cartilage with no connection to adjacent metaphyseal vessels (13). This tenuous blood supply would be at risk in the presence of repetitive injury to the elbow.

Genetic factors are also thought to play a role in the pathogenesis of capitellar OCD but relevant data are limited. There have been a few reports of capitellar OCD affecting multiple family members, sometimes over several generations (14-16). However, despite some case reports describing familial OCD, no definitive data establishing a hereditary connection have been reported and no specific gene associated with capitellar OCD has been identified to our knowledge.

IMAGING

The age at diagnosis ranges from the teens to the 20s and the appearance of the capitellar lesion varies according to stage. Careful evaluation is important when choosing the treatment most appropriate for the stage of capitellar OCD. A combination of radiography, CT, magnetic resonance imaging (MRI), and ultrasonography might facilitate accurate interpretation of the pathology of capitellar OCD.

Imaging evaluation of a patient with capitellar OCD begins

with conventional radiography. Several authors have noted that a routine elbow series consisting of anteroposterior and lateral views has low sensitivity for identification of capitellar OCD (18-20). Addition of an anteroposterior view with the elbow in 45° of flexion improves the ability of a radiographic examination to detect capitellar OCD (1, 2) (Figure 1). Capitellar OCD is classified into three stages according to the findings on the anteroposterior view with the elbow in 45° of flexion (1, 2). Stage I is characterized by radiolucent areas, stage II by nondisplaced fragments, and stage III by loose bodies and sclerotic change (1, 2).

MRI can detect early capitellar OCD when radiography is normal or demonstrates only subtle changes (9, 18, 21). Early MRI findings include lesions of uniform low-signal intensity in the superficial capitellum on T1-weighted images, with the T2-weighted images demonstrating no changes or abnormalities (18). Patients with early-stage capitellar OCD were found to show high signal intensity in the subchondral bone of the capitellum on proton-density fat-saturated images (9) (Figure 2). Kijowski *et al.* reported that lesions surrounded by a rim of high signal intensity or a fluid-filled cyst on T2-weighted images were unstable (21). MRI can also reveal cartilage lesions that are indistinct on radiographic images.

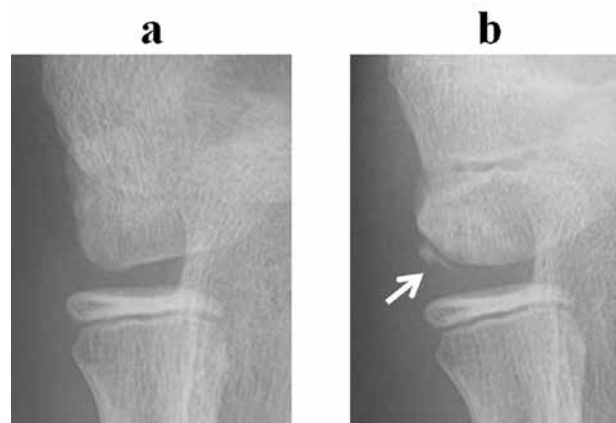

Figure 1. Capitellar OCD is not clear in the anteroposterior view (a). Anteroposterior view with the elbow in 45° of flexion (b) clearly demonstrates capitellar OCD. OCD, osteochondritis dissecans of the capitellum

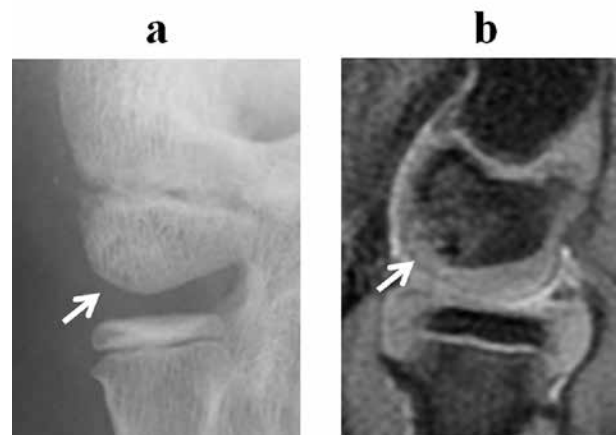


Figure 2. (a) Radiograph demonstrating only subtle changes. (b) Magnetic resonance scan reveals high signal intensity in the subchondral bone of the capitellum on sagittal proton-density fat-saturated images, indicating osteochondritis dissecans of the capitellum.

CT scans are not used as often as MRI for detection of capitellar OCD lesions. However, CT can accurately identify and localize a lesion at the same time as defining its extent (1,22,23) (Figure 3). Furthermore, CT has the advantages of wider availability and a shorter acquisition time than MRI (24). A CT scan of the elbow seems to be the best imaging technique for confirming a diagnosis of capitellar OCD. An OCD lesion of the capitellum is not always visible on radiography and loose bodies are often missed on standard radiographs and MRI scans (25). Furthermore, CT allows confirmation of the intra-articular position of loose bodies (22).

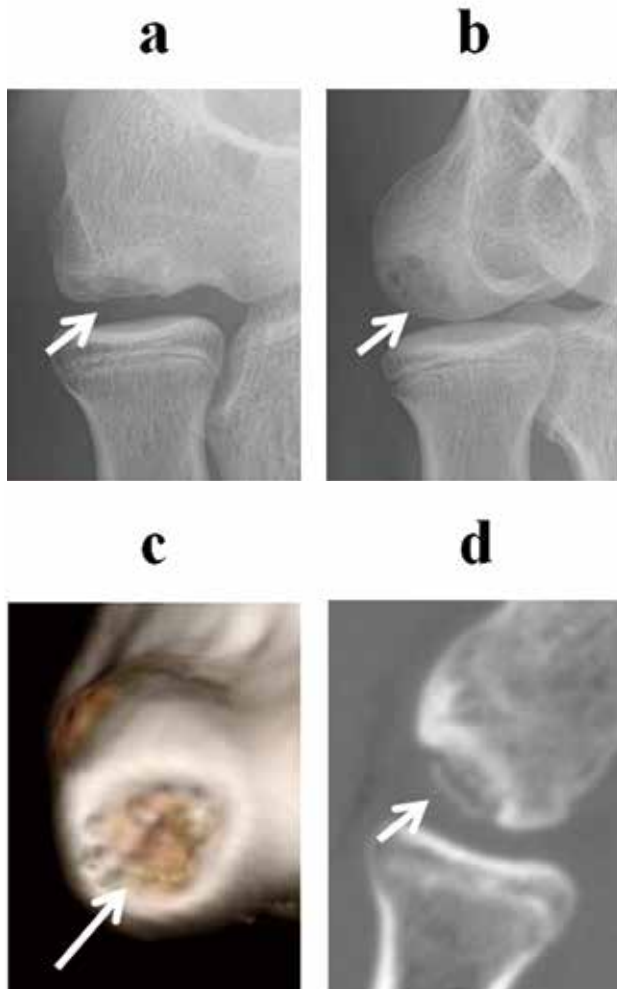


Figure 3. Computed tomography scans (c, d) can identify and localize a lesion and define its extent more accurately than radiographs (a, b).

Ultrasonography is recommended as an additional imaging modality in the evaluation of capitellar OCD. Ultrasonography is an inexpensive and portable diagnostic imaging modality that does not involve exposure to radiation and has been used successfully to assess elbow injuries (6-9, 18, 26-28). Recent improvements in the spatial resolution of ultrasonography have enabled acquisition of more detailed cross-sectional images of capitellar OCD. Yoshizuka *et al.* evaluated the correlation between ultrasonographic findings and surgical findings in patients with capitellar OCD and compared the diagnostic accuracy of ultrasonography with that of MRI (27). The accuracy of the ultrasonographic diagnoses was superior to that of the MRI di-

agnoses. Although early detection of capitellar OCD is desirable, it is difficult to detect early-stage capitellar OCD because most patients are asymptomatic or minimally symptomatic. However, screening for OCD using ultrasonography enables early detection and provides an opportunity for successful conservative treatment (6-9, 18, 26, 28) (Figure 4). However, it is vital to be aware that ultrasonographic examination may not be able to distinguish between OCD and minor injury or normal development during ossification. Therefore, OCD should be confirmed on additional radiographic examination.

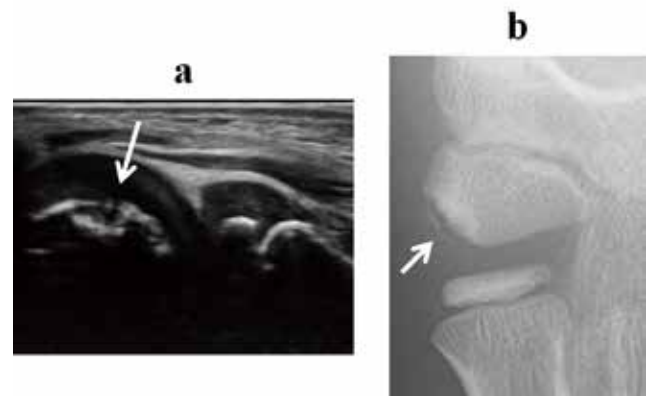


Figure 4. Screening for osteochondritis dissecans of the capitellum using ultrasonography (a) enables early detection and can be confirmed on radiography (b).

TREATMENT

Treatment has conventionally included both operative and nonoperative measures based on the stage and size of the lesion, skeletal maturity, subjective symptoms, and structural integrity of the cartilage. Capitellar OCD responds better to nonoperative treatment when it is in the early stages. Indications for surgery include persistent symptoms despite nonoperative treatment, symptomatic loose bodies, and displacement or detachment of a fragment.

Nonoperative treatment

In 1972, Tullos *et al.* reported 4 cases of capitellar OCD in pitchers (29). Three of these patients were treated successfully with rest and 1 required surgical excision. Torg recommended initial immobilization and rest until the acute symptoms subside, with excision considered only for loose bodies (30). DeHaven echoed these recommendations after reviewing 10 elbow injuries from a database of sports injuries in 548 patients aged up to 15 years (31). However, Takahara *et al.* found that only 6 (55%) of 11 early lesions healed or improved radiographically after nonoperative treatment (32). They concluded that capitellar OCD had only a slight tendency to heal. In contrast, we reported that conservative treatment, including avoiding heavy use of the elbow, promoted healing in 90.5% of patients with stage I lesions and in 52.9% of those with stage II lesions (1), which suggests that capitellar OCD can be successfully treated conservatively if treatment is started early.

Operative treatment

There is still debate about the best practice for capitellar OCD lesions requiring operative intervention. Several surgical methods have been reported, including arthroscopic removal of loose bodies with or without drilling or microfracture (33-37),

arthroscopic or open fragment fixation (38-40), bone peg fixation (41, 42), closed-wedge osteotomy (43, 44), and osteochondral transplantation (45-47). Arthroscopic removal of loose bodies or osteochondral transplantation is indicated in most cases.

Arthroscopic removal of loose bodies with or without drilling or microfracture may be indicated in patients who have a small lesion. This technique has become increasingly popular because it provides a minimally invasive alternative when surgical management is indicated (Figure 5). Arthroscopic removal of loose bodies with or without drilling or microfracture has been shown to have good to excellent functional results in the short to medium term, although the studies were often retrospective in nature and included patients with lesions of variable severity (33-36, 48). Several studies have reported return to sports following arthroscopic debridement for capitellar OCD (33, 34). The prognosis varies from report to report because the studies have included patients of various ages at the time of surgery and a wide range of sporting activities. Osteochondral transplantation may be indicated as a primary procedure in patients with large lesions or may be used as a salvage procedure if primary surgical treatment (debridement and marrow stimulation) has failed in athletes who desire to return to their preinjury or higher level of activity (45-50).

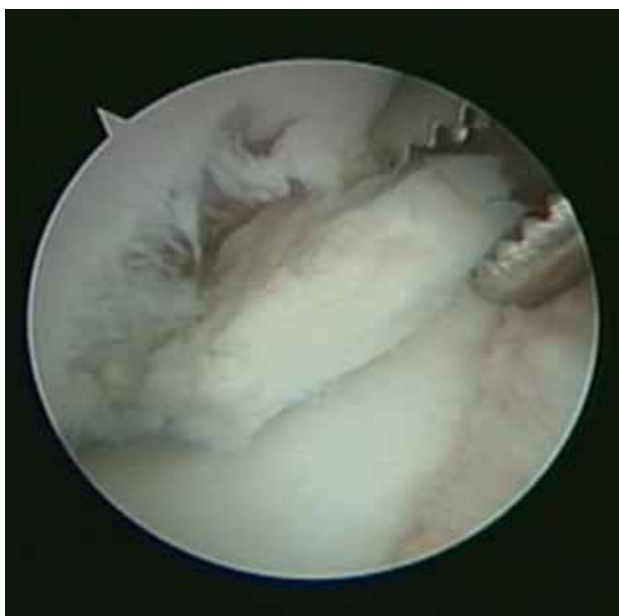

Figure 5. Arthroscopic removal of loose bodies.

FUTURE DIRECTIONS

The precise etiology and natural history of capitellar OCD remain poorly understood. Moreover, optimal treatment has yet to be determined. Further research is needed to assess the exact influence of lesion size on the prognosis and treatment of capitellar OCD. A better understanding of these factors may assist in surgical decision-making and preoperative planning.

DISCLOSURE OF CONFLICTS OF INTEREST

None of the authors received any funding to complete this report or has any conflicts of interest to declare.

ACKNOWLEDGMENTS

This research received no specific grant from any funding agency in the public, commercial, or not-for-profit sectors.

REFERENCES

1. Matsuura T, Kashiwaguchi S, Iwase T, Takeda Y, Yasui N : Conservative treatment for osteochondrosis of the humeral capitellum. *Am J Sports Med* 36 : 868-872, 2008
2. Iwase T, Ikata T : Osteochondrosis dissecans of the capitellum. In : Kashiwagi D, ed. *Seikeigeka Mook No. 54* [in Japanese]. Kanehara, Tokyo, 1988, pp. 26-44
3. Nielsen NA : Osteochondritis dissecans capituli humeri. *Acta Orthop Scand* 4 : 307-418, 1933
4. Gugenheim JJ Jr, Stanley RF, Woods GW, Tullos HS : Little League survey : the Houston study. *Am J Sports Med* 4 : 189-200, 1976
5. Hang DW, Chao CM, Hang YS : A clinical and roentgenographic study of Little League elbow. *Am J Sports Med* 32 : 79-84, 2004
6. Harada M, Takahara M, Sasaki J, Mura N, Ito T, Ogino T : Using sonography for the early detection of elbow injuries among young baseball players. *AJR Am J Roentgenol* 187 : 1436-1441, 2006
7. Matsuura T, Suzue N, Iwame T, Nishio S, Sairyō K : Prevalence of osteochondritis dissecans of the capitellum in young baseball players. Results based on ultrasonographic findings. *Orthop J Sports Med* 2 : 2325967114545298, 2014
8. Kida Y, Morihara T, Kotoura Y, Hojo T, Tachiiri H, Sukenari T, Iwata Y, Furukawa R, Oda R, Arai Y, Fujiwara H, Kubo T : Prevalence and clinical characteristics of osteochondritis dissecans of the humeral capitellum among adolescent baseball players. *Am J Sports Med* 42 : 1963-1971, 2014
9. Matsuura T, Iwame T, Suzue N, Takao S, Nishio S, Arisawa K, Sairyō K : Cumulative incidence of osteochondritis dissecans of the capitellum in preadolescent baseball players. *Arthroscopy* 35 : 60-66, 2019
10. Matsuura T, Suzue N, Kashiwaguchi S, Arisawa K, Yasui N : Elbow injuries in youth baseball players without prior elbow pain : A 1-year prospective study. *Orthop J Sports Med* 1 : 2325967113509948, 2013
11. Matsuura T, Iwame T, Suzue N, Arisawa K, Sairyō K : Risk factors for shoulder and elbow pain in youth baseball players. *Phys Sportsmed* 45 : 140-144, 2017
12. Momma D, Iwasaki N, Oizumi N, Nakatsuchi H, Funakoshi T, Kamishima T, Tadano S, Minami A : Long-term stress distribution patterns across the elbow joint in baseball players assessed by computed tomography osteoabsorptiometry. *Am J Sports Med* 39 : 336-341, 2011
13. Haraldsson S : On osteochondrosis deformans juvenilis capituli humeri including investigation of intra-osseous vascular in distal humerus. *Acta Orthop Scand* 38 Suppl : 1-232, 1959
14. Matsuura T, Wada K, Suzue N, Iwame T, Fukuta S, Sairyō K : Bilateral osteochondritis dissecans of the capitellum in fraternal twins : a case report. *JBJS Case Connect* 7 : e44, 2017
15. Pudas T, Koskinen SK, Hiltunen A, Mattila KT : Osteochondritis dissecans of the humeral capitellum in identical twins. *Acta Radiol Short Rep* 1, 2012
16. Kenniston JA, Beredjikian PK, Bozentka DJ : Osteochondritis dissecans of the capitellum in fraternal twins : case report. *J Hand Surg Am* 33 : 1380-1383, 2008
17. Schenck RC Jr, Athanasiou KA, Constantinides G, Gomez E : A biomechanical analysis of articular cartilage of the

- human elbow and a potential relationship to osteochondritis dissecans. *Clin Orthop Relat Res* (299) : 305-312, 1994
18. Takahara M, Shundo M, Kondo M, Suzuki K, Nambu T, Ogino T : Early detection of osteochondritis dissecans of the capitellum in young baseball players. Report of three cases. *J Bone Joint Surg Am* 80 : 892-897, 1998
 19. Janarv PM, Hesser U, Hirsch G : Osteochondral lesions in the radiocapitellar joint in the skeletally immature : radiographic, MRI, and arthroscopic findings in 13 consecutive cases. *J Pediatr Orthop* 17 : 311-314, 1997
 20. Kijowski R, De Smet AA : Radiography of the elbow for evaluation of patients with osteochondritis dissecans of the capitellum. *Skelet Radiol* 34 : 266-271, 2005
 21. Kijowski R, De Smet AA : MRI findings of osteochondritis dissecans of the capitellum with surgical correlation. *AJR Am J Roentgenol* 185 : 1453-1459, 2005
 22. Holland P, Davies AM, Cassar-Pullicino VN : Computed tomographic arthrography in the assessment of osteochondritis dissecans of the elbow. *Clin Radiol* 49 : 231-235, 1994
 23. Ruchelsman DE, Hall MP, Youm T : Osteochondritis dissecans of the capitellum : current concepts. *J Am Acad Orthop Surg* 18 : 557-567, 2010
 24. Verhagen RA, Maas M, Dijkgraaf MG, Tol JL, Krips R, van Dijk CN : Prospective study on diagnostic strategies in osteochondral lesions of the talus. Is MRI superior to helical CT? *J Bone Joint Surg Br* 87 : 41-46, 2005
 25. van den Ende KIM, Keijsers R, van den Bekerom MPJ, Eygendaal D : Imaging and classification of osteochondritis dissecans of the capitellum : X-ray, magnetic resonance imaging or computed tomography? *Shoulder Elbow* 11 : 129-136, 2009
 26. Takahara M, Ogino T, Tsuchida H, Takagi M, Kashiwa H, Nambu T : Sonographic assessment of osteochondritis dissecans of the humeral capitellum. *AJR Am J Roentgenol* 174 : 411-415, 2000
 27. Yoshizuka M, Sunagawa T, Nakashima Y, Shinomiya R, Masuda T, Makitsubo M, Adachi N : Comparison of sonography and MRI in the evaluation of stability of capitellar osteochondritis dissecans. *J Clin Ultrasound* 46 : 247-252, 2018
 28. Iwame T, Matsuura T, Suzue N, Tamaki S, Yokoyama K, Sairyo K : Two-year follow-up study of subchondral surface irregularities of the capitellum on ultrasonography in baseball players under the age of 10 years. *Skeletal Radiol* 46 : 1499-1505, 2017
 29. Tullos HS, Erwin WD, Woods GW, Wukasch DC, Cooley DA, King JW : Unusual lesions of the pitching arm. *Clin Orthop Relat Res* 88 : 169-182, 1972
 30. Torg JS : The little league pitcher. *Am Fam Physician* 6 : 71-76, 1972
 31. DeHaven KE : Elbow problems in the adolescent athlete. *Cleve Clin Q* 42 : 297-302, 1975
 32. Takahara M, Ogino T, Fukushima S, Tsuchida H, Kaneda K : Nonoperative treatment of osteochondritis dissecans of the humeral capitellum. *Am J Sports Med* 27 : 728-732, 1999
 33. Brownlow HC, O'Connor-Read LM, Perko M : Arthroscopic treatment of osteochondritis dissecans of the capitellum. *Knee Surg Sports Traumatol Arthrosc* 14 : 198-202, 2006
 34. Jones KJ, Weisel BB, Sankar WN, Ganley TJ : Arthroscopic management of osteochondritis dissecans of the capitellum : mid-term results in adolescent athletes. *J Pediatr Orthop* 30 : 8-13, 2010
 35. Ueda Y, Sugaya H, Takahashi N, Matsuki K, Tokai M, Onishi K, Hoshika S, Hamada H : Arthroscopic fragment resection for capitellar osteochondritis dissecans in adolescent athletes : 5- to 12-year follow-up. *Orthop J Sports Med* 5 : 2325967117744537, 2017
 36. Baumgarten TE, Andrews JR, Satterwhite YE : The arthroscopic classification and treatment of osteochondritis dissecans of the capitellum. *Am J Sports Med* 26 : 520-523, 1998
 37. Bauer M, Jonsson K, Josefsson PO, Linden B : Osteochondritis dissecans of the elbow : a long-term follow up study. *Clin Orthop Relat Res* 284 : 156-160, 1992
 38. Harada M, Ogino T, Takahara M, Ishigaki D, Kashiwa H, Kanauchi Y : Fragment fixation with a bone graft and dynamic staples for osteochondritis dissecans of the humeral capitellum. *J Shoulder Elbow Surg* 11 : 368-372, 2002
 39. Uchida S, Utsunomiya H, Taketa T, Sakoda S, Hatakeyama A, Nakamura T, Sakai A : Arthroscopic fragment fixation using hydroxyapatite/poly-L-lactate acid thread pins for treating elbow osteochondritis dissecans. *Am J Sports Med* 43 : 1057-1065, 2015
 40. Kuwahata Y, Inoue G : Osteochondritis dissecans of the elbow managed by Herbert screw fixation. *Orthopedics* 21 : 449-451, 1998
 41. Oshiba H, Itsubo T, Ikegami S, Nakamura K, Uchiyama S, Kato H : Results of bone peg grafting for capitellar osteochondritis dissecans in adolescent baseball players. *Am J Sports Med* 44 : 3171-3178, 2006
 42. Maruyama M, Harada M, Satake H, Tomohiro U, Takagi M, Takahara M : Bone-peg grafting for osteochondritis dissecans of the humeral capitellum. *J Orthop Surg (Hong Kong)* 24 : 51-56, 2016
 43. Kiyoshige Y, Takagi M, Yuasa K, Hamasaki M : Closed-wedge osteotomy for osteochondritis dissecans of the capitellum : a 7- to 12-year follow-up. *Am J Sports Med* 28 : 534-537, 2000
 44. Ueki M, Moriya K, Yoshizu T, Tsubokawa N, Kouda H, Endo N : Closed-wedge osteotomy of the distal humerus for treating osteochondritis dissecans of the capitellum in young patients. *Orthop J Sports Med* 7 : 2325967119876247, 2019
 45. Yamagami N, Yamamoto S, Aoki A, Ito S, Uchio Y : Outcomes of surgical treatment for osteochondritis dissecans of the elbow : evaluation by lesion location. *J Shoulder Elbow Surg* 27 : 2262-2270, 2018
 46. Funakoshi T, Momma D, Matsui Y, Kamishima T, Matsui Y, Kawamura D, Nagano Y, Iwasaki N : Autologous osteochondral mosaicplasty for centrally and laterally located, advanced capitellar osteochondritis dissecans in teenage athletes : clinical outcomes, radiography, and magnetic resonance imaging findings. *Am J Sports Med* 46 : 1943-1951, 2018
 47. Matsuura T, Hashimoto Y, Nishino K, Nishida Y, Takahashi S, Shimada N : Comparison of clinical and radiographic outcomes between central and lateral lesions after osteochondral autograft transplantation for osteochondritis dissecans of the humeral capitellum. *Am J Sports Med* 45 : 3331-3339, 2017
 48. Takahara M, Mura N, Sasaki J, Harada M, Ogino T : Classification, treatment, and outcomes of osteochondritis dissecans of the humeral capitellum. *J Bone Joint Surg Am* 89 : 1205-1214, 2007
 49. Maruyama M, Takahara M, Harada M, Satake H, Takagi M : Outcomes of an open autologous osteochondral plug graft for capitellar osteochondritis dissecans : time to return to sports. *Am J Sports Med* 42 : 2122-2127, 2014
 50. Vogt S, Siebenlist S, Hensler D, Weigelt L, Ansah P, Woertler K, Imhoff AB : Osteochondral transplantation in the elbow leads to good clinical and radiologic long-term results : an 8- to 14-year follow-up examination. *Am J Sports Med* 39 : 2619-2625, 2011