



# Shunt Nephritis and Pyogenic Spondylitis With a Positive PR3-ANCA Associated With Chronically Infected Ventriculoatrial Shunt

Hiroyuki Ono<sup>1</sup>, Seiji Kishi<sup>1</sup>, Taizo Inagaki<sup>1</sup>, Masako Mizusawa<sup>2</sup>, Fumi Kishi<sup>1</sup>, Sakiya Yoshimoto<sup>1</sup>, Masanori Tamaki<sup>1</sup>, Masanori Minato<sup>1</sup>, Sayo Ueda<sup>1</sup>, Taichi Murakami<sup>1</sup>, Kojiro Nagai<sup>1</sup>, Hideharu Abe<sup>1</sup> and Toshio Doi<sup>1</sup>

<sup>1</sup>Department of Nephrology, Tokushima University Hospital, Tokushima, Japan; and <sup>2</sup>Division of Medical Microbiology, Johns Hopkins School of Medicine, Baltimore, Maryland, USA

**Correspondence:** Seiji Kishi, Department of Nephrology, Tokushima University Hospital, 2-50-1 Kuramoto-cho, Tokushima, 7708503, Japan. E-mail: [kichikun\\_s@yahoo.co.jp](mailto:kichikun_s@yahoo.co.jp)

*Kidney Int Rep* (2017) **2**, 774–778; <http://dx.doi.org/10.1016/j.ekir.2017.02.013>

© 2017 International Society of Nephrology. Published by Elsevier Inc. This is an open access article under the CC BY-NC-ND license (<http://creativecommons.org/licenses/by-nc-nd/4.0/>).

## INTRODUCTION

Shunt nephritis is a rare complication mostly described in the setting of chronic infection of ventriculoatrial (VA) shunts inserted for the treatment of congenital or acquired hydrocephalus.<sup>1,2</sup> The diagnosis of shunt nephritis is challenging and may be overlooked. We report a case of successfully treated shunt nephritis and pyogenic spondylitis with positive antiproteinase 3 antineutrophil cytoplasmic antibody (PR3-ANCA) in a patient who presented with acute kidney injury.

## CASE PRESENTATION

A 56-year-old Japanese man presented with hematuria, proteinuria, progressive kidney dysfunction, and a persistent low grade fever for 4 months. The patient also had mild spontaneous lower back pain. He had a medical history of alcoholic liver cirrhosis and secondary hydrocephalus due to non-HIV cryptococcal meningitis at the age of 50, initially treated by a ventriculoperitoneal shunt. The shunt was subsequently replaced with a VA shunt because of an intra-abdominal abscess.

On physical examination, his vital signs revealed a temperature of 37.2 °C, a pulse of 71/min with regular rhythm, and a blood pressure of 115/77 mm Hg. No abnormalities were detected in the patient's lungs, heart, abdomen, or extremities.

Laboratory data revealed an elevated creatinine (2.35 mg/dl, baseline 0.86 mg/dl; 5 months before admission), anemia (hemoglobin 9.8 g/dl), mild elevation of liver enzymes (L-aspartate aminotransferase 67 U/l, alanine aminotransferase 46 U/l), low

complement (complement component 3 66 mg/dl, 50% hemolytic unit of component 28 U/ml), elevated C-reactive protein (4.33 mg/dl), and positive PR3-ANCA (67.4 U/ml; reference range <3.5 U/ml). Urinalysis showed proteinuria (1.63 g/gCr) and hematuria (>100 erythrocytes/high power field), both new findings. Blood culture and cerebrospinal fluid culture were positive for oxacillin-resistant *Staphylococcus capitis* (Table 1). Transthoracic echocardiography showed no vegetation. Transesophageal echocardiography was not performed, because infectious endocarditis was not high in our differential diagnosis. There was increased uptake in the lumbar spine L3-L4 disc on gallium scintigraphy. Lumbar-spine plain magnetic resonance imaging findings were consistent with pyogenic spondylitis.

We suspected a VA shunt infection with pyogenic spondylitis. The VA shunt was removed and antimicrobial therapy was immediately started (Figure 1). The VA shunt was not cultured. Initially, based on the guideline,<sup>3</sup> i.v. vancomycin (0.5–1.0 g/d determined by the daily trough value) was given for 25 days until the patient developed a drug eruption. We then switched to a combination of minocycline (200 mg/d) and clindamycin (1800 mg/d). We continued parenteral antibiotics for a total of 9 weeks. Blood cultures turned negative on day 10 of antibiotic treatment. During the antibiotic therapy, his proteinuria and hematuria resolved, and renal function returned to his baseline. Complement and C-reactive protein normalized over the treatment course (Figure 1). His lower back pain also improved. Symptoms of hydrocephalus remained absent even without a VA shunt. There were no signs or

**Table 1.** Laboratory findings on admission

Hematology	Reference range	Serology	Reference range	Urinalysis	Reference range			
WBC	6600/ $\mu$ l	4500–9000	IgG	3398 <sup>a</sup> mg/dl	870–1700	pH	5.0	5.0–7.0
Neutrophils	73.6%		IgG4	21 <sup>a</sup> mg/dl	48–105	RBC	>100 <sup>a</sup> /HPF (dysmorphic)	<5
Lymphocytes	16.5%		IgA	344 mg/dl	110–410	WBC	20–29 <sup>a</sup> /HPF	<5
Eosinophils	0.3%		IgM	305 <sup>a</sup> mg/dl	33–190	Hyaline cast	0–1/LPF	
Hb	9.8 <sup>a</sup> g/dl	14.0–17.0	IgE	35.7 mg/dl	<170	Granular cast	1–2 <sup>a</sup> /LPF	<1
Plt	179 $\times$ 10 <sup>3</sup> / $\mu$ l	150–350 $\times$ 10 <sup>3</sup>	C3	66 mg/dl	65–135	$\beta$ 2MG	189.7 $\mu$ g/l	<360
Biochemistry			C4	18 mg/dl	13–35	NAG	10.7 U/l	<11.2
TP	8.1 g/dl	6.5–8.2	CH50	28 <sup>a</sup> U/ml	32–49	U-pro/U-Cr	1.63 g/gCr	<0.15
Alb	2.5 <sup>a</sup> g/dl	3.9–4.9	RF	<10 U/ml	<15	CSF		
BUN	38 <sup>a</sup> mg/dl	8–20	Cryoglobulin	(–)	(–)	Cells	1/ $\mu$ l	0–5
Cr	2.35 <sup>a</sup> mg/dl	0.5–1.1	ANA	$\times$ 80 <sup>a</sup>	< $\times$ 40	Protein	16 mg/dl	14–45
Na	136 mEq/l	135–146	MPO-ANCA	<1.0 U/ml	<3.5	Glucose	55 mg/dl	50–75
K	4.9 <sup>a</sup> mEq/l	3.5–4.8	PR3-ANCA	67.4 <sup>a</sup> IU/ml	<3.5			
Ca	8.6 <sup>a</sup> mg/dl	8.8–10.1	Anti-GBM Ab	<2.0 U/ml	<3.0	CSF culture		
UA	7.3 <sup>a</sup> mg/dl	3.0–7.0	HBs-Ag	(–)	(–)	Positive for <i>Staphylococcus capitis</i>		
AST	67 <sup>a</sup> U/l	10–35	HCV-Ab	(–)	(–)	Blood culture		
ALT	46 <sup>a</sup> U/l	5–40	HIV Ag/Ab	(–)	(–)	Positive for <i>Staphylococcus capitis</i>		
CK	26 <sup>a</sup> U/l	40–200	STS/TPHA	(–)	(–)			
T-Bil	0.6 mg/dl	0–1.0	T-SPOT	(–)	(–)			
T-Cho	142 mg/dl	130–220	1,3- $\beta$ -D-glucan	<6.0 pg/ml	(–)			
HDL-C	35 <sup>a</sup> mg/dl	40–100						
TG	100 mg/dl	35–150						
HbA1c	5.8%	4.6–6.2						
Ferritin	296 <sup>a</sup> ng/ml	21–275						
CRP	4.33 <sup>a</sup> mg/dl	<0.3						

Ab, antibody; Ag, antigen; Alb, albumin; ALT, alanine aminotransferase; ANA, antinuclear antibody; ANCA, antineutrophil cytoplasmic antibody; AST, L-aspartate aminotransferase;  $\beta$ 2MG, beta 2 microglobulin; BUN, blood urea nitrogen; C3, complement component 3; C4, complement component 4; Ca, calcium; CH50, 50% hemolytic unit of component; CK, creatine kinase; Cr, creatinine; CRP, C-reactive protein; CSF, cerebrospinal fluid; GBM, glomerular basement membrane; Hb, hemoglobin; HBs, hepatitis B surface; HCV, hepatitis C virus; HDL-C, high-density lipoprotein cholesterol; HIV, human immunodeficiency virus; HPF, high power field; K, potassium; LPF, low power field; MPO, myeloperoxidase; Na, sodium; NAG, N-acetyl-beta-D-glucosaminidase; Plt, platelet; PR3, proteinase 3; RBC, red blood cell; RF, rheumatoid factor; STS, serologic test for syphilis; T-Bil, total bilirubin; T-Cho, total cholesterol; T-SPOT, a type of enzyme-linked immunospot assay used for tuberculosis diagnosis, which belongs to the group of interferon-gamma release assays; TG, triglyceride; TP, total protein; TPHA, treponema pallidum latex agglutination; U-pro/U-Cr, urinary protein-creatinine ratio; UA, uric acid; WBC, white blood cell.

<sup>a</sup>Values that are out of normal range.

symptoms of granulomatosis with polyangiitis (Wegener's granulomatosis), although serum levels of PR3-ANCA did not decrease. After 5 months from the beginning of treatment, titers for PR3-ANCA remain high (85.1 U/ml).

## DISCUSSION

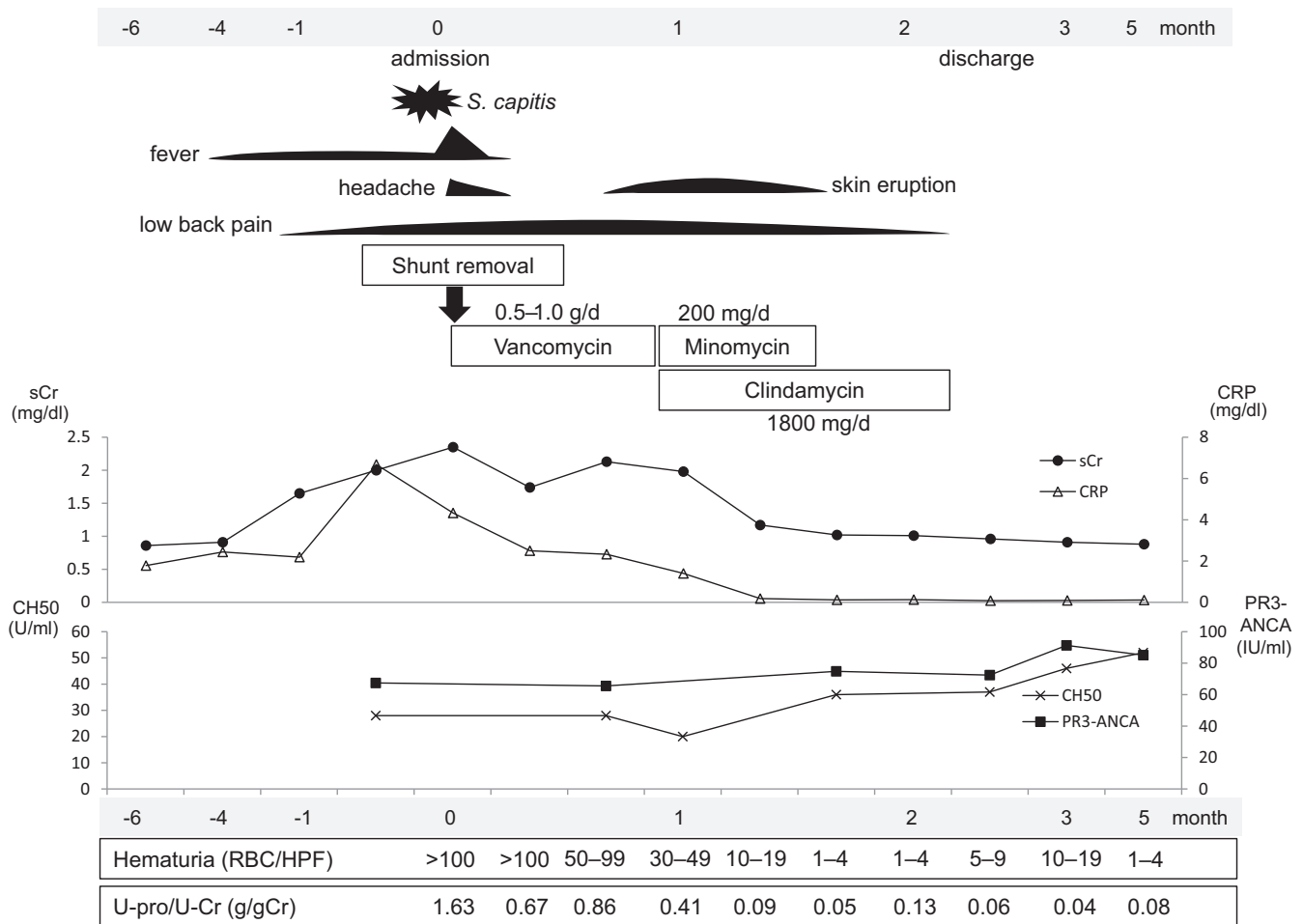
Shunt nephritis, an infection-related glomerulonephritis, is a dreaded complication of a VA shunt. Although the incidence of VA shunt infection is relatively high, approximately 12%, only 0.7% to 2.3% of infected patients develop shunt nephritis.<sup>2</sup> Therefore, its diagnosis is sometimes difficult and often delayed or missed. Although 160 cases have been reported in the literature,<sup>4,5</sup> the number of patients with shunt nephritis is decreasing because VA shunts are being replaced with ventriculoperitoneal shunts.<sup>6</sup>

There have been some recent reports about immune-complex-mediated glomerulonephritis related to infections of long-term central venous catheter usage, often placed for extensive cancer chemotherapy treatment.<sup>6,7</sup> Cases of shunt nephritis may increase because of the increased usage of these indwelling central

venous catheters. Physicians should be aware of the diagnosis and management of this condition.

Kidney biopsy often suggests a diagnosis of shunt nephritis. A typical kidney biopsy of shunt nephritis shows membranoproliferative glomerulonephritis with immune-complex deposition.<sup>5</sup> In this case, we did not perform a kidney biopsy because of the presence of persistent bacteremia and prioritization of shunt removal by the neurosurgeons. In this case, the clinical improvement with antibiotics, resolution of proteinuria and hematuria, and improvement of renal function strongly support the diagnosis of shunt nephritis.

It is unclear how long antibiotics should be used for this situation. In this case, we followed the recommended antibiotic treatment period for pyogenic spondylitis. A total duration of 6 weeks of parenteral or highly bioavailable oral antimicrobial therapy is recommended.<sup>3</sup> In another literature review, criteria for discontinuation of antimicrobial treatment include symptom resolution or improvement and the normalization of erythrocyte sedimentation rate or C-reactive protein.<sup>8</sup> Considering this information, the period of bacteremia before treatment, and the possibility of



**Figure 1.** Clinical course. ANCA, antineutrophil cytoplasmic antibody; CH50, 50% hemolytic unit of component; CRP, C-reactive protein; HPF, high power field; PR3, proteinase 3; RBC, red blood cell; sCr, serum creatinine; U-pro/U-Cr, urinary protein-creatinine ratio.

immunological impairment related to liver cirrhosis, we used antibiotics for a total of 9 weeks, while monitoring the urinalysis and C-reactive protein. After treatment his lower back pain improved and there has been no recurrence of nephritis and spondylitis.

*Coagulase-negative staphylococci*, especially *Staphylococcus epidermidis*, are the most common cause of foreign body infections, including shunt nephritis.

*S. capitis* was the cause of nephritis in our case. It is generally considered a nonpathogenic bacterium and is rarely associated with foreign body infections.<sup>9</sup>

Cryptococcosis is an opportunistic infection that defines AIDS in HIV+ patients but is also seen in other immunocompromised situations. Our patient was previously diagnosed with cryptococcal meningitis despite the negative HIV infection. Although there was no decrease in CD4 nor impaired humoral response, it is still possible that this patient has immune deficiency related to chronic liver cirrhosis that might have allowed this nonpathogenic attenuated bacterium to cause the persistent bacteremia and nephritis.

ANCAs were originally described in 1982,<sup>10</sup> and the PR3 antigen was discovered in 1989.<sup>11</sup> PR3-ANCA usually causes a C-ANCA pattern and is well known as a specific marker of granulomatosis with polyangiitis. Testing for PR3-ANCA by using an indirect immunofluorescence technique or enzyme-linked immunosorbent assay has very high specificity (95%–100%) and high sensitivity (61.8%–97.1%).<sup>12</sup> Although PR3-ANCA testing is a useful clinical tool in daily practice, it is still considered controversial because ANCA becomes positive under conditions other than vasculitis (e.g., infections or exposure to drugs). In these cases, the patient’s condition might be worsened by immunosuppression.<sup>12</sup> ANCA formation has been reported in the course of various chronic viral (e.g., *HIV*, *Hepatitis B*, *Hepatitis C*), bacterial (e.g., *Streptococcus*, *Staphylococcus*, *Enterococcus*), fungal (e.g., *Aspergillus*), protozoal (e.g., *Streptococcus*, *Staphylococcus*, *Enterococcus*), and multicellular parasitic infection (e.g., *Echinococcus*).<sup>13</sup> For example, PR3-ANCA in infectious endocarditis is a typical disease.<sup>14,15</sup> In shunt nephritis, PR3-ANCA could also become positive. Three

**Table 2.** Shunt nephritis with positive PR3-ANCA in published case reports and our patients

Case	Bonarek <i>et al.</i> <sup>16</sup>	Nagashima <i>et al.</i> <sup>17</sup>	Iwata <i>et al.</i> <sup>18</sup>	Our patient
Age, sex	50, F	17, F	55, M	56, M
Cause of hydrocephalus	Arachnoid cyst	Congenital hydrocephalus	Brain abscess	Secondary hydrocephalus
Shunt	Cyst-atrial	VA	VA	VA
Causal organism	<i>Propionibacterium acnes</i>	<i>Gemella morbillorum</i>	<i>Propionibacterium acnes</i>	<i>Staphylococcus capitis</i>
Duration of shunt (yr)	9	10	7	2
Serum creatinine	1.4 mg/dl	1.1 mg/dl	1.5 mg/dl	2.35 mg/dl
Urinary protein	3.5 g/d	1.4 g/d	5.4 g/d	1.63 g/gCr
C3 (reference range, 65–135 mg/dl)	55	39.9	39.9	66
C4 (reference range, 13–35 mg/dl)	16	3	10.3	18
CH50 (reference range, 32–49 U/ml)	Undetectable	<8	<5	28
PR3-ANCA (before therapy)	1/500	44 U/ml	113 U/ml	67.4 U/ml
PR3-ANCA (after therapy)	Negative	11 U/ml (4 mo)	6.3 U/ml (9 mo)	85.1 U/ml (5 mo)
Renal pathology	MPGN	MPGN	MPGN	Not performed
Treatment	Shunt removal antibiotics	Shunt removal, antibiotics PSL, mPSL pulse	Shunt replacement antibiotics, PSL	Shunt removal, antibiotics
Outcome	Improve	Improve	Improve	Improve

ANCA, antineutrophil cytoplasmic antibody; C3, complement component 3; C4, complement component 4; CH50, 50% hemolytic unit of component; MPGN, membranoproliferative glomerulonephritis; mPSL, methylprednisolone; PR3, proteinase 3; PSL, prednisolone; VA, ventriculoatrial.

previously published case reports and our case of shunt nephritis with positive PR3-ANCA are shown in Table 2.<sup>16–18</sup> Earlier reports showed that PR3-ANCA returned to normal after treatment.

There remains much unknown about the precise relationship between ANCA formation and vasculitis. Previous studies revealed the relationship between ANCA-related diseases and infection.<sup>19–21</sup> Recent studies have shown that neutrophil exudate traps may play an important role with regard to ANCA levels and tissue injury. Neutrophil exudate traps are nuclear-derived chromatin fibers released from activated neutrophil and contain PR3. Neutrophil exudate traps can not only be a cause but also be a result of inflammation.<sup>22</sup> PR3-ANCA stimulates neutrophil exudate trap secretion, and on the other hand, bacterial PR3 enhances antibody production against PR3. This malignant cycle is considered as one of the pathogenesises underlying ANCA-related vasculitis or glomerulonephritis.<sup>13</sup> PR3-ANCA levels in our patient remain high and have not changed over 3 months after resolution of clinical signs and symptoms. A previous single-center study indicated that patients who showed positive c-ANCA/PR3-ANCA without sufficient clinical or other evidence of a systemic vasculitis had a small risk of developing vasculitis later (Table 3).<sup>23</sup> It is unclear whether or not an elevated PR3-ANCA is related to the pathophysiology in this case, and we will carefully observe the patient's clinical course in the future.

**Table 3.** Teaching points

- Shunt nephritis is a rare but important form of infection-related, immune complex-mediated glomerulonephritis
- Mostly occurred in patients with chronically infected ventriculoatrial shunts
- The diagnosis of shunt nephritis is challenging
- Early diagnosis and treatment initiation with antibiotics and shunt removal is a key to the successful management

## CONCLUSION

We successfully treated a patient with shunt nephritis with antibiotic treatment and shunt removal. Hematuria, proteinuria, and progressive kidney dysfunction all improved. It is unclear why PR3-ANCA becomes positive in conditions related to chronic infection, and it will be necessary to follow the PR3-ANCA titer in this case. Physicians should be aware of the risks of infection-related glomerulonephritis in patients with VA shunts as early diagnosis and treatment initiation with antibiotics and shunt removal is a key to the successful management.

## DISCLOSURE

All the authors declared no competing interests.

## ACKNOWLEDGMENTS

We would like to thank Dr. Naoka Murakami, MD, PhD, Renal Division at Brigham and Women's Hospital and Dr. George Meyer, MD, Clinical Professor of Medicine at the University of California at Davis for critical reading of our manuscript and English language editing.

## REFERENCES

1. Black JA, Challacombe DN, Ockenden BG. Nephrotic syndrome associated with bacteraemia after shunt operations for hydrocephalus. *Lancet*. 1965;2:921–924.
2. Narchi H, Taylor R, Azmy AF, et al. Shunt nephritis. *J Pediatr Surg*. 1988;23:839–841.
3. Berbari EF, Kanj SS, Kowalski TJ, et al. 2015 Infectious Diseases Society of America (IDSA) clinical practice guidelines for the diagnosis and treatment of native vertebral osteomyelitis in adults. *Clin Infect Dis*. 2015;61:e26–e46.
4. Arze RS, Rashid H, Morley R, et al. Shunt nephritis: report of two cases and review of the literature. *Clin Nephrol*. 1983;19:48–53.

5. Haffner D, Schindera F, Aschoff A, et al. The clinical spectrum of shunt nephritis. *Nephrol Dial Transplant*. 1997;12:1143–1148.
6. Okada M, Sato M, Ogura M, et al. Central venous catheter infection-related glomerulonephritis under long-term parenteral nutrition: a report of two cases. *BMC Res Notes*. 2016;9:196.
7. Hayashi S, Mori A, Kawamura T, et al. Glomerulonephritis caused by CV catheter-related blood stream infection. *Intern Med*. 2015;54:2219–2223.
8. Lee KY. Comparison of pyogenic spondylitis and tuberculous spondylitis. *Asian Spine J*. 2014;8:216–223.
9. Needham CA, Stempsey W. Incidence, adherence, and antibiotic resistance of coagulase-negative Staphylococcus species causing human disease. *Diagn Microbiol Infect Dis*. 1984;2:293–299.
10. Davies DJ, Moran JE, Niall JF, Ryan GB. Segmental necrotising glomerulonephritis with antineutrophil antibody: possible arbovirus aetiology? *Br Med J (Clin Res Ed)*. 1982;285:606.
11. Niles JL, McCluskey RT, Ahmad MF, Arnaout MA. Wegener's granulomatosis autoantigen is a novel neutrophil serine proteinase. *Blood*. 1989;74:1888–1893.
12. Csernok E, Moosig F. Current and emerging techniques for ANCA detection in vasculitis. *Nat Rev Rheumatol*. 2014;10:494–501.
13. Konstantinov KN, Uiff-Moller CJ, Tzamaloukas AH. Infections and antineutrophil cytoplasmic antibodies: triggering mechanisms. *Autoimmun Rev*. 2015;14:201–203.
14. Subra JF, Michelet C, Laporte J, et al. The presence of cytoplasmic antineutrophil cytoplasmic antibodies (C-ANCA) in the course of subacute bacterial endocarditis with glomerular involvement, coincidence or association? *Clin Nephrol*. 1998;49:15–18.
15. de Corla-Souza A, Cunha BA. Streptococcal viridans subacute bacterial endocarditis associated with antineutrophil cytoplasmic autoantibodies (ANCA). *Heart Lung*. 2003;32:140–143.
16. Bonarek H, Bonnet F, Delclaux C, et al. Reversal of c-ANCA positive mesangiocapillary glomerulonephritis after removal of an infected cysto-atrial shunt. *Nephrol Dial Transplant*. 1999;14:1771–1773.
17. Nagashima T, Hirata D, Yamamoto H, et al. Antineutrophil cytoplasmic autoantibody specific for proteinase 3 in a patient with shunt nephritis induced by *Gemella morbillorum*. *Am J Kidney Dis*. 2001;37:E38.
18. Iwata Y, Ohta S, Kawai K, et al. Shunt nephritis with positive titers for ANCA specific for proteinase 3. *Am J Kidney Dis*. 2004;43:e11–e16.
19. Wagner J, Andrassy K, Ritz E. Is vasculitis in subacute bacterial endocarditis associated with ANCA? *Lancet*. 1991;337:799–800.
20. Mahr A, Batteux F, Tubiana S, et al. Brief report: prevalence of antineutrophil cytoplasmic antibodies in infective endocarditis. *Arthritis Rheumatol*. 2014;66:1672–1677.
21. Ying CM, Yao DT, Ding HH, Yang CD. Infective endocarditis with antineutrophil cytoplasmic antibody: report of 13 cases and literature review. *PLoS One*. 2014;9:e89777.
22. Schonermarck U, Csernok E, Gross WL. Pathogenesis of antineutrophil cytoplasmic antibody-associated vasculitis: challenges and solutions 2014. *Nephrol Dial Transplant*. 2015;30(suppl 1):i46–i52.
23. O'Donnell JL, Hayman MW, Spellerberg MB, et al. Antineutrophil cytoplasmic antibody measurement: advantages and disadvantages of a capture PR3 ELISA and a direct PR3 ELISA. *Pathology*. 2007;39:258–263.