

# PROPAEDEUTICS OF INTERNAL MEDICINE

Collection of clinical lectures by T. Khomazyuk



PART 1

State Establishment  
«Dnepropetrovsk Medical Academy  
of Health Ministry of Ukraine»

# PROPAEDEUTICS OF INTERNAL MEDICINE

---

## **Collection of clinical lectures by T. Khomazyuk**

The educational and visual guide  
on training students of the second (master's) level of higher  
education, educational qualification "Master of Medicine",  
professional qualification "Doctor"  
for English speaking students

In two parts | PART 1

УДК 616.1/4:616.6]-07(042.4)(075.8)  
Х76

*Рекомендовано до друку з грифом вченої ради ДЗ «ДМА МОЗ України» (протокол № 12 від 13.06.2019 р.).*

**Автор:** док. мед. наук., проф. кафедри пропедевтики внутрішньої медицини **Т.А. Хомазюк**

**Рецензенти:**

**Долженко М.М.** – док. мед. наук., професор, завідувач кафедри кардіології НМАПО ім. П.Л.Шупика

**Ілащук Т.О.** – док. мед. наук., професор, завідувач кафедри пропедевтики внутрішньої медицини Буковинського медичного університету

**Учбово-наочний посібник «Propaedeutics of internal medicine. Collection of clinical lectures»** є виданням «Курсу лекцій з пропедевтики внутрішньої медицини» в авторській редакції, призначений для підготовки фахівців другого (магістерського) рівня вищої освіти, освітньої кваліфікації «Магістр медицини» професійної кваліфікації «Лікар», які навчаються на англійській мові.

В ілюстраціях до клінічних лекцій автор використав інформаційні матеріали з відкритої мережі Інтернету.

Ілюстрації на обкладинці: «Твори Гіппократа», 1932–1934 рр. (Кольоровий літо) Друк Жикле Джозефа Куна-Реньє.

**The author:** M.D., D.Med.Sc., Professor TA Khomazyuk. Department of Propaedeutics of Internal Medicine

**Reviewers:**

**Dolzhenko MM** – M.D., D.Med.Sc., Professor, Head of the Cardiology Department, PL Shupyk National Medical Academy of Postgraduate Education

**Ilaschuk TO** – M.D., D.Med.Sc., Professor, Head of the Department of Propaedeutics of Internal Medicine, Bukovina Medical University

Cover Illustrations: "The Works of Hippocrates", 1932–1934 (Colour Litho) Giclee Print by Joseph Kuhn-Regnier.

**Khomazyuk T.**

X76 Propaedeutics of internal medicine. Collection of clinical lectures: the educational and visual guide: in two parts. Part 1. – Dnipro: Gerda, 2019. – 372 p.

ISBN 978-617-7639-18-2 (ч. 1, pdf)

Textbook designed for the training of specialists of the second (master's) level of higher education, educational qualification "Master of Medicine", professional qualification "Doctor" for English speaking students.

**УДК 616.1/4:616.6]-07(042.4)(075.8)**

ISBN 978-617-7639-17-5

ISBN 978-617-7639-18-2 (ч. 1, pdf)

© Хомазюк Т., 2019

# CONTENTS

## Part 1

1. Propaedeutics of internal medicine as the introduction into the clinic of internal diseases.  
Basic methods of examination of patients. CASE HISTORY SCHEME 5
2. Symptoms and signs of Respiratory diseases based on questioning the patient, palpation and percussion of the chest 36
3. Symptoms and signs of Respiratory diseases based on auscultation of the lungs 78
4. Symptoms and signs of heart diseases based on a survey, palpation, percussion 100
5. AUSCULTATION OF THE HEART:  
the main signs of normal and pathological tones and heart sounds 132
6. Symptoms and signs of Vascular diseases based on the study of the pulse and blood pressure 173
7. Instrumental methods of CV investigation 227
8. Clinical ECG 277
9. Symptoms and signs of Digestive diseases 324

## Part 2

10. The main syndromes of diseases of the Respiratory system
11. ARTERIAL HYPERTENSION SYNDROME
12. CORONARY SYNDROME
13. Heart failure syndrome
14. The main syndromes of LIVER DISEASES
15. The main syndromes of RENAL DISEASES
16. CLINICAL EXAMINATION in Blood diseases. Anemia syndrome

LECTURE # **1**

**PROPAEDEUTICS OF INTERNAL MEDICINE  
AS THE INTRODUCTION INTO THE CLINIC  
OF INTERNAL DISEASES.**

**BASIC METHODS OF EXAMINATION  
OF PATIENTS.**

**CASE HISTORY SCHEME**

## THE PLAN

- Propaedeutics of internal medicine
- What is Diagnostics?
- Main principles of medical practice
- The history of Ukrainian medicine
- Main terms
- Examination of the patient. The PLAN
- Case HISTORY
- References

## INTERNAL MEDICINE

**Internal medicine** is the major branch of medical practice and research because internal diseases **are the most common and impairing the patient's objective condition** and his working capacity

**Internal diseases have the highest mortality rates as well**



**The term "internal diseases" came into use in the 19th century to stand alongside with the then-popular term "therapy"**

The development of new, complicated methods of diagnosis and treatment, requiring specialized skills and training on the part of the physician, has led to the formation of **separate branches** of medicine such as **cardiology, gastroenterology, endocrinology, and hematology**

## PROPAEDEUTICS OF INTERNAL MEDICINE

Our course is an introduction to therapy, or propaedeutics of internal medicine



Course is given to students after they have studied the fundamentals of medicine, such as anatomy, physiology, biochemistry, etc.

During their further studies the students broaden and improve their knowledge of all **major internal diseases**, their differential diagnoses and treatment

The students start managing patients independently

## WHAT IS DIAGNOSTICS?

Successful treatment of disease becomes only possible with a correct diagnosis (**a good diagnostician is a good doctor**)

**Diagnostics** (Gk dia through, gnosis knowledge) is the science of methods by which diseases are identified. The term diagnostics also implies examination and observation of the patient by the doctor

## WHAT IS DIAGNOSTICS ?

Diagnostics includes:

- 1) the study of methods of observation and examination of the patient (physical and laboratory-instrumental methods); this is the **medical diagnostic technique**;
- 2) the study of the diagnostic value of the symptoms of the disease; this is known as **semeiology** (Gk semeion, sign) or **symptomatology**;
- 3) the study of special ways of pondering aimed at identification of the disease — **diagnostic methods**

## GENERAL PRINCIPLES OF SUCCESS

- Qbi bene interrogat, bene diagnoscit...
- Qbi bene diagnoscit, bene curat...


## MAIN PRINCIPLES OF MEDICAL PRACTICE

The **main object** of a physician is to cure his patient

Hippocrates would say that "**Nature will cure most ailments if she is given a chance**". The main object of treatment is therefore to maintain the forces of the patient in his struggle against the disease

Another important principle is to "**do no harm**" to the patient by inappropriate action





### Hippocrates

is a famous Greek healer, doctor and philosopher. He went down in history as the "father of medicine"



### Avicenna


Portrait on Silver Vase – Museum at BuAli Sina (Avicenna) Mausoleum - Hamadan - Western Iran

## MAIN PRINCIPLES OF MEDICAL PRACTICE



- «A not good doctor is rather harmful, than useful...»
- «The doctor must treat the patient rather than the disease...»

M. Mudrov (1776-1831)



## THE PRIDE OF UKRAINIAN MEDICINE

**Victor Dzyak (1920–1980)**

Development and perfection of CLINICAL THOUGHT

Features of rheumatism's flow

Development of studies about GB, HF, AF

Mathematic diagnostics models in medicine

Basis of sporting medicine



## THE PRIDE OF UKRAINIAN MEDICINE

**George Dzyak (1945–2018)**

Academician of the Ukrainian NMSc.A,  
RECTOR of DSMA

The Leading specialist of international practice in area of cardiology, rheumatology and SPORTS medicine

Author of more than 500 scientific works, 22 monographs, 2 textbooks, 18 inventions

Were prepared 19 DMSc. and 68 KMSc.



## THE PRIDE OF UKRAINIAN MEDICINE

**Pertseva  
Tatiana Alexeevna**

Corresponding member of NAS of Ukraine

Leading scientist and international  
clinician in the field of pulmonology



## SALUS AEGROTI SUPREMA LEX

**Kolesnyk  
Tatyana Vladimirovna**

Head of the department of Propaedeutics  
of Internal Medicine

Professor,

Doctor of Medical Scienc

## MAIN TERMS

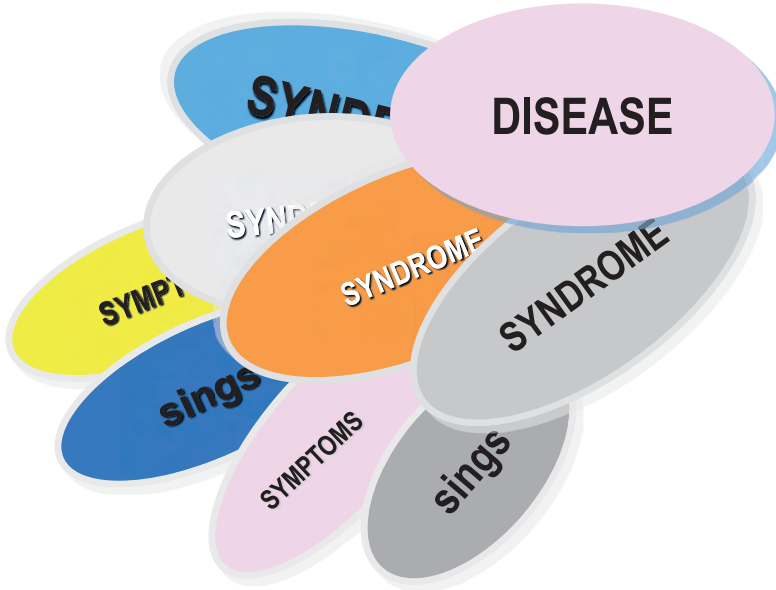
- Symptom refers to what the patient feels
- Sign refers to that which the examiner finds
- Syndrome – a set of symptoms connected by single pathogenesis characterizing a disease or condition
- Simiology – science about symptoms and syndromes and their meaning

## SCHEME AND METHODS OF CLINICAL EXAMINATION OF PATIENTS


A healthy person does not feel any unpleasant sensations. Pain, nausea, vomiting, elevated body temperature, enlargement of certain internal organs, e.g. of the spleen, occur only in the sick, and are considered as **signs** or **symptoms** (**Gk symptoma that which happens**) of diseases

Some symptoms indicate changes that occur in the entire body (e.g. elevated temperature), while others (e.g. diarrhea) may only indicate dysfunction of a particular organ or a system, or changes in the structure of an organ (e.g. an enlarged and firm spleen)

Pain or nausea are **subjective symptoms** experienced by the patient. These sensations reflect objective changes that occur in the patient's body. Signs of the disease that are revealed by the physician during his examination of the patient, e.g. jaundice or enlarged liver, are **objective symptoms** or **signs** of the disease. It is almost impossible to diagnose a disease by only one symptom. A correct diagnosis can only be established by investigating several symptoms if the physician follows a definite plan in his examinations

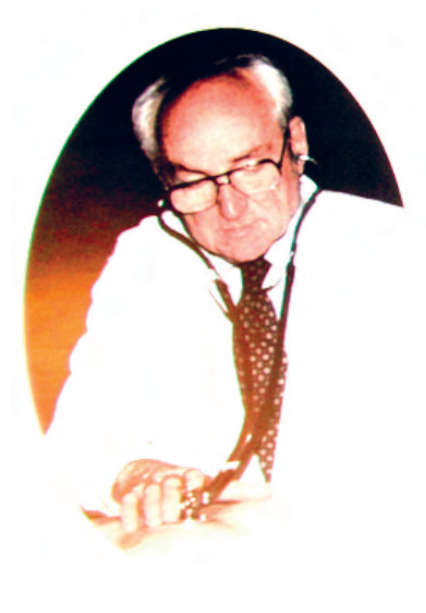

## EXAMINATION OF THE PATIENT. THE PLAN



«EVERYBODY SEE WHAT UNDEstand...»

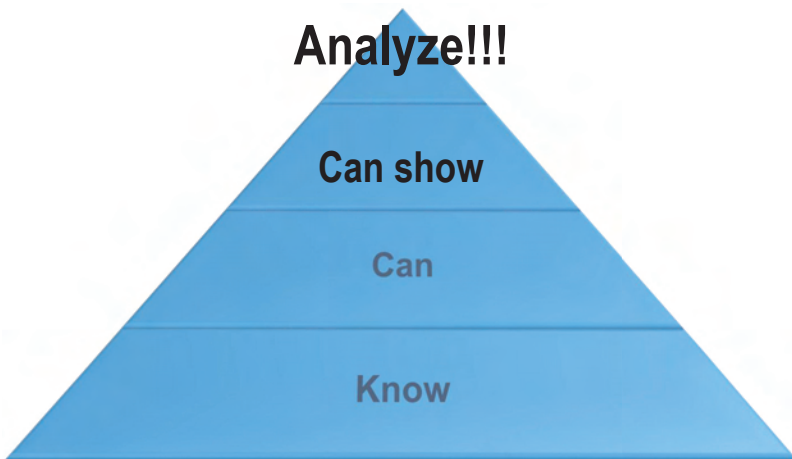
I.V.GETE



“ **Five-finger**” approach to diagnosis: detailed history, physical examination, electrocardiogram, X-ray, and appropriate tests, in that order.”

W. Proctor Harvey, 1959

## PYRAMID OF CLINICAL COMPETENCE



Wass V., et al., Lancet 2001;357:945-949

## EXAMINATION OF THE PATIENT. THE PLAN


- INTERVIEW - anamnesis, interrogation
- GENERAL PART
- COMPLAINTS
- HISTORY
- LIFE HISTORY
- GENERAL SURVEY - inspection
- EXAMINATION due to SYSTEMS AND ORGANS - examination

### Case HY. NeISTORxt step!!!

The **next step** is a systematic and thorough functional inquiry of the patient according to a predetermined scheme

**Chief complaint** or the reason for seeking care should be determined. If the patient complains of retrosternal pain, the character and exact location of this pain, its **focus** and **intensity** should be determined; **the time of the onset**, and possible causes that **provoked** the pain (strain, cough, taking food, etc.) should be established. The patient should be asked which **remedies** remove this pain

Other **associated complaints** should also be analyzed. The study of the chief complaints can lead the examiner to a conclusion concerning the general character of the disease, e.g. high body temperature would normally indicate an infectious process, cough and expectorated sputum indicate possible disease of the lungs



# WHY?



Besides chest pain (angina) and shortness of breath, some other common symptoms of heart disease include jaw pain, back pain, and heart palpitations





Other symptoms of heart disease may include dizziness, weakness, irregular heartbeat, nausea, and abdominal pain

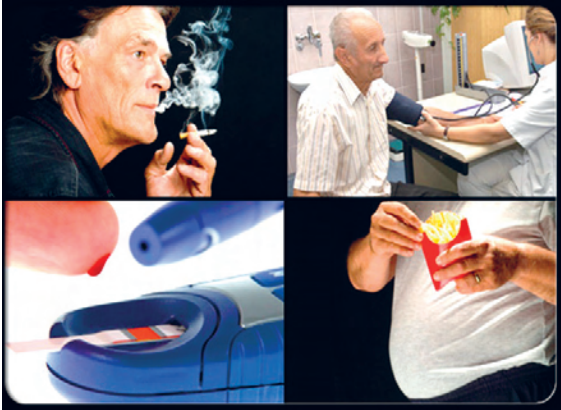

## Case HISTORY. Next step!!!

- **History of present illness (Anamnesis morbi)** should include information concerning the onset of the disease and its development until the present. The patient's general condition before the disease should first be determined and the causes that might have provoked the disease established wherever possible. The patient should be questioned in detail about the first signs of the disease and the **chronology of their development**, about relapses or exacerbations, remissions and their duration
- If some other physicians examined the patient during an exacerbation of the disease, the results of the examinations and treatment should be studied. Motives for hospitalization should also be determined (exacerbation of the disease, verification of the diagnosis, etc.)
- History of present illness gives information about the character of the disease (acute or chronic)
- **Review of systems (Anamnesis communis)** gives the physician information concerning the condition of various organs and systems of the patient (cardiovascular, respiratory, gastrointestinal, genitourinary, nervous, musculoskeletal, etc.). The patient should be questioned according to a specially outlined scheme
- Changes in the patient's **general state** should be established first (**loss of weight, fever, weakness, edema, headache**)
- **Next is the most affected system**
- **Then some questions about each system should be included.** For example, the condition of cardiovascular system is established by asking the patient about chest pain or distress, palpitations, dyspnea, orthopnea (number of pillows needed), edema, claudication, hypertension and so on

## Case HISTORY

- **Life history (*Anamnesis vitae*)** is often very important for establishing the character, the cause, and conditions for the onset of the disease
- It is a **medical biography** of the patient in every period of his life (infancy, childhood, adolescence, and maturity)
- **Personal and social history** should be taken first. It begins with the general biographical information. Birthplace is important, because some diseases (e.g. endemic goiter) usually predominate in one locality and are not met in others
- The patient should be asked if he was born at term, if there were other children in the family, if he was breast fed or artificially; and if he had marked signs of rickets during his childhood
- It is necessary to find out if the patient's **physical and mental development** was not retarded and what was his progress at school
- The patient should inform the physician on his **home conditions** (separate apartment, hostel, country house, illumination, the presence of dampness, if any, hygienic conditions, etc.)
- The **composition of the family** is important: large or small family, their health, well-being, income, etc.
- **Malnutrition** is an important factor for the onset of some diseases. The patient should be asked if his diet is sufficiently rich in vegetables, fruits, etc. The way in which the patient spends his leisure time is also important
- The patient should report on the time he **sleeps, rests**, walks in the fresh air, what sports and exercises he goes in for, and what **harmful habits** he has



Some of the risk factors for heart disease include smoking, high blood pressure, high cholesterol, diabetes, and obesity



Additional heart disease risk factors include lack of exercise, an unhealthy diet, stress, and a "type A" personality

Lifestyle changes: using alcohol in moderation and quitting smoking



## Case HISTORY

- **Unfavorable labor conditions and industrial hazards** (some harmful dusts) are important, for they may cause bronchial asthma and chronic diseases of the bronchi and lungs. Strong noise, vibration, high ambient temperature, drafts, and cold (work in the open) can cause pathology
- **Industrial poisoning** by mercury, lead, carbon monoxide and other harmful agents, and also exposure to radiation (improper safety measures) may also cause disease
- The working schedule is also important
- **Past medical history** should be established in chronologic order. Childhood and major adult illnesses, surgery, serious injuries, immunizations and medications are important
- **Some infectious diseases**, such as measles or scarlet fever, do not recur because of acquired immunity, while other diseases, such as rheumatism or erysipelas, tend to recur. Rheumatism or diphtheria often provokes heart diseases. Nephropathy often develops after scarlet fever
- **Contacts with infectious patients** are important, especially in the presence of epidemics (e.g. influenza)
- **Family history** helps the physician to make a conclusion on the role of hereditary factors in the development or origin of the disease. Ask if there are any blood relatives in the patient's family who have illnesses with features similar to the patient's illness
- **Determine the ethnicity; health; and the cause of death of parents, including their ages at death**
- Establish whether there is a **history of heart disease**, high blood pressure, cancer, tuberculosis, stroke, epilepsy, diabetes, gout, kidney disease, thyroid disease, asthma and other allergic states, forms of arthritis, blood diseases, sexually transmitted diseases, or any other familial disease

- Determine the health of **patient's spouse and children**. If there is a hereditary disease, such as sickle cell disease, inquire into the history of the grandparents, aunts, uncles, siblings, and cousins
- A pedigree diagram is often helpful in recording this information
- **Allergological anamnesis** is very important. Some patients often develop a pathologically heightened (or inverted) response of the immune system (allergy), and this is essential in the pathogenesis of certain diseases of internal organs. It is necessary therefore to determine whether the patient or his relatives had allergies, especially to medications, but also to environmental allergens or foods. Strawberry, eggs, canned crabs, and other foods may frequently act as allergen. Allergies in man vary from vasomotor rhinitis, nettle rash or Quincke's edema to anaphylactic shock
- **Objective examination** of the patient (*status praesens*) gives information on the condition of the entire body and the state of the internal organs. It should be carried out according to a predetermined plan
- **The patient is first given a general inspection;**
  - next the physician should use palpation, percussion, auscultation,
  - and other diagnostic procedures by which the condition of
    - the respiratory organs,
    - the cardiovascular,
    - gastrointestinal and
    - urinary system,
    - locomotion,
    - lymph nodes,
    - endocrine glands, and
    - the nervous system may be examined
- Despite the great value of anamnesis, it is never sufficient for establishing a diagnosis: the conjectured diagnosis is confirmed by the objective methods of physical examination

- **General inspection (*inspectio*)** is the process of observation
  - Your eyes and nose are sensitive tools for gathering data. Inspection – unlike palpation, percussion, and auscultation – can continue throughout history-taking process and during physical examination
  - **Adequate lighting** is essential. The patient should be examined in the daytime, because electric light will mask any yellow coloring of the skin and the sclera
  - In addition to direct light, which outlines the entire body and its separate parts, side light will also be useful to reveal pulsation on the surface of the body, respiratory movements of the chest, peristalsis of the stomach and the intestine
- 
- **Inspection technique.** The body should be inspected by successively uncovering the patient and **examining him in direct and side light from head to feet**
  - The trunk and the chest are better examined when the patient is in a vertical posture
  - When the abdomen is examined, the patient may be either in the upright or supine position
  - The examination should be carried out according to a special plan, since the physician can miss important signs that otherwise could give a clue for the diagnosis
  - The entire body is first inspected in order to reveal general symptoms. Next, separate parts of the body should be examined: **the skin, lymph nodes, head, face, neck, trunk, limbs, muscles, bones, and joints**
  - The following signs characterize the **general condition** of the patient: **consciousness and the psyche, posture and body-built**

- **Consciousness can be clear or deranged.** The patient should be oriented to time, place, and person and be able to respond appropriately to questions and environmental stimuli. Depending on the degree of disorder, the following states are differentiated:
  1. **Stupor.** The patient cannot orient himself to the surroundings, he gives delayed answers.
  2. **Sopor** is an unusually deep sleep from which the patient recovers only for short periods of time when called loudly, or roused by an external stimulus. The reflexes are preserved.
  3. **Coma** is the full loss of consciousness with complete absence of response to external stimuli, with the absence of reflexes, and **deranged vital functions.**

The most common forms of coma are alcoholic, apopleptic, hypoglycemic, hyperglycemic, hepatic, uremic, and epileptic coma.
  4. **Irritative disorders of consciousness are characterized by excitation of the central nervous system in the form of hallucinations, delirium.**
- Other psychic disorders (depression, apathy) may occur in the patient.

- The concept of **habitus** includes the **body-build** (i.e. constitution), height, and body weight
- **Constitution** (L. constituero to set up) is the combination of functional and morphological bodily features that are based on the inherited and acquired properties, and that account for the body response to endo- and exogenic factors. The classification adopted in Ukraine (M. Chernorutsky) differentiates between the following three main constitutional types:
  - **asthenic,**
  - **hypersthenic, and**
  - **normosthenic**



- During the general inspection, the physician should pay attention to the **open parts of the patient's body, the head, the face and the neck**
- The **facial expression** can indicate various psychic and somatic conditions. For example, facies Hippocratica is associated with collapse in grave diseases of the abdominal organs (diffuse peritonitis, perforated ulcer of the stomach or duodenum, rupture of the gall bladder)
- **The face** is characterized by sunken eyes, pinched nose, deadly livid and cyanotic skin, which is sometimes covered with drops of cold sweat
- **Inspection of the eyes and eyelids, nose, mouth and tongue** can reveal some essential diagnostic signs. During inspection of the neck attention should be paid to pulsation of the carotid artery, swelling and pulsation of the external jugular veins, enlarged lymph nodes, diffuse or local enlargement of the thyroid gland
- The **colour, elasticity**, and moisture of **the skin**, eruptions and scars are important. In certain forms of anemia, the skin is specifically pallid: with a characteristic yellowish tint in Addison-Biermer anemia, with a greenish tint in chlorosis, brown or ash-coloured in malaria. Red colour of the skin can be transient in fever. Cyanotic skin can be due to hypoxia in circulatory insufficiency, in chronic pulmonary diseases, etc. Yellowish colour of the skin and mucosa can be due to upset secretion of bilirubin by the liver or due to increased hemolysis
- **Elasticity and turgor of the skin** can be determined by pressing a fold of skin (usually on the abdomen or the extensor surface of the arm) between the thumb and the forefinger. The fold disappears quickly on normal skin when the pressure is released while in cases with decreased turgor, the fold persists for a long period of time
- Eruptions on the skin vary in shape, size, colour, persistence, and spread. The diagnostic value of eruptions is great in some infections and allergic manifestations.
- **Scars** on the skin, e.g. on the abdomen and the hips, remain after pregnancy (striae gravidarum), in Itsenko-Cushing disease, and in extensive edema. Postoperative scars indicate surgical operations in past history. Cirrhosis of the liver is often manifested by development of specific vascular stellae (telangiectasia)
- Abnormal growth of hair is usually due to endocrine diseases
- **Nails** become excessively brittle in myxoedema, anemia and hypovitaminosis, and can also be found in some fungal diseases of the skin

- **Subcutaneous fat** can be normal or to various degrees excessive (*obesity*) or deficient (*cachexia*). The fat can be distributed uniformly or deposited in only certain parts of the body. Its thickness is assessed by palpation
- **Edema** can be caused by penetration of fluid through the capillary walls and its accumulation in tissues. Accumulated fluid may be congestive (**transudation**) or inflammatory (**exudation**). Local edema is a result of some local disorders in the blood or lymph circulation. General edema associated with diseases of the heart, kidneys or other organs is characterized by general distribution of edema throughout the entire body (**anasarca**) or by symmetrical localization in limited regions of the body. It can be due to the patient lying on one side
  - If edema is generalized, transudate may accumulate in the body's cavities: in the abdomen (ascites), pleural cavity (hydrothorax) and in the pericardium (hydropericardium)
  - Observation reveals swollen glossy and tense skin. Edema can also be revealed by palpation
- When pressed by the finger, the edematous skin overlying bones (external surface of the leg, malleolus, loin) remains depressed for 1—2 minutes after the pressure is released
- **Inspect** each area of the body for apparent **lymph nodes**, edema, erythema, red streaks, and skin lesions
- **Using the pads of the second, third, and fourth fingers, gently palpate for the superficial lymph nodes.** Try to detect any hidden enlargement, and note the consistency, mobility, tenderness, size, and warmth of the nodes. Easily palpable lymph nodes generally are not found in healthy adults. Superficial nodes that are accessible to palpation but not large or firm enough to be felt are common. You may detect small, movable, discrete, shotty nodes less than centimeter in diameter that move under your fingers. Lymph nodes that are large, fixed or matted, inflamed, or tender indicate a problem. It is possible to infer the site of an infection from the pattern of lymph node enlargement. Submandibular nodes swell in the presence of inflammation in the mouth
- Chronic enlargement of the cervical lymph nodes is associated with development of tuberculosis in them. In tuberculosis the lymph nodes are usually “cold”, soft, matted, and often not tender or painful

- **Palpation** (L **palpare to touch gently**) is the clinical method by which the physical properties, topographic correlation, tenderness and functional characteristic of tissues and organs can be studied by the sense of touch
  - **Palpation has been known since the ancient times.** But it was formerly used mainly to study the physical properties of superficially located organs, e.g. the skin, joints, bones, or pathological growths (tumors), and also for feeling the pulse. Physicians began studying **vocal fremitus and the apex beat** by palpation only in the middle of the 19th century (Laënnec, Skoda), while systematic use of palpation of the **abdominal cavity** was begun late in the 19th century, mainly after publication of works by **Botkin, Glenard, Obratsov, and Strazhesko**
  - Palpation is widely used as an important method for diagnosis of diseases of the internal organs, muscles and bones, lymphatic system, and the skin. Palpation technique differs depending on the object of examination, but the physician should always follow a certain plan in his manipulations
  - In order to feel temperature of separate parts of the body, the physician should place his palms flat on the body or the extremities, on symmetrical joints (the skin overlying the affected joint is warmer), etc.
  - The **pulse** is determined by feeling the skin over the artery by the fingers; the properties of the arterial wall and the character of the pulse can thus be determined
- 
- Cancer of the stomach and, less frequently, cancer of the intestine can metastasize into the **lymph nodes of the neck** (on the left)
  - The **axillary lymph nodes** are sometimes enlarged in mammary cancer
  - In the presence of metastases the lymph nodes are firm, their surface is rough, palpation is painless
  - Tenderness of a lymph node in palpation and reddening of the overlying skin indicates inflammation in the node
  - **Systemic enlargement** of the lymph nodes is observed in lympholeukaemia, lymphogranulomatosis, and lymphosarcomatosis
  - In lymphatic leukaemia and lymphogranuloma the nodes fuse together but do not suppurate

- Next step is examination of the **muscular system, bones and joints of the head, chest, spine, and extremities.**
- Examination of the **extremities** can reveal varicosity of the veins, edema, changes in the skin, atrophy and paralysis of the muscles, tremor of the extremities, deformities, swelling and hyperemia of the joints, ulcers, and scars.
- Palpation may be either **light (surface) or deep**
- For light palpation press in to a depth up to 1 cm; for deep palpation press in about 4 cm
- Light palpation should always precede deep palpation, since the latter may elicit tenderness or disrupt tissue or fluid, thus interfering with your ability to gather information through light palpation. **Short fingernails are essential to avoid discomfort or injury to the patient**
- A variant of deep palpation is penetrating palpation during which the fingertip is impressed into the body to determine the painful area
- Among other palpation techniques are **bimanual palpation** (with both hands) and ballottement of firm organs (liver, spleen, tumors) in the abdomen containing much fluid, kneepan (exudates in the knee joint), etc. Obratzsov and Strazhesko developed a palpating technique known as sliding palpation, which is used for studying organs located deep in the abdomen
- It is the convention, at least in Ukraine, to teach students to examine patients from the right side and to palpate and percuss with the right hand
- **Percussion (L *percutere* to strike through)** was first proposed by an Austrian physician Auenbrugger in 1761
- **Tapping various parts of the human body produces sounds by which one can learn about the condition of the underlying organs.** In percussion your finger functions as a hammer, and the vibration is produced by the impact of the finger against underlying tissue
- Sound waves are heard as **percussion tones (called resonance)** that arise from vibrations 4 to 6 cm deep in the body tissue
- The degree of percussion tone is determined by the density of the medium through which the sound waves travel
- The more dense is the medium, the quieter the percussion tone
- **The percussion tone over air is loud, over fluid less loud, and over solid areas soft**

## Case HISTORY. Percussion

- **Main rules of percussion**

1. **The patient should be in a comfortable posture and relaxed.** The best position is standing or sitting. When the patient is percussed from his back, he should be sitting on a chair, his face turned to the chair back. The head should be slightly bent forward; his arms should rest against his lap
2. **The room should be warm and protected from external noise**
3. **The physician should be in a comfortable position as well**
4. **The middle finger of the left hand (pleximeter) should be pressed tightly to the examined surface.** The neighboring fingers should be somewhat set apart. The physician's hands should be warm
5. **The downward snap of the striking finger originates from the wrist and not the forearm or shoulder.** The tap should be sharp and rapid to prevent damping the sound. Tapping should be uniform, the force of percussion strokes depending on the object being examined
6. **In topographic percussion, the finger should be placed parallel to the anticipated border of the organ.** Organs giving resonant note should be examined first: the ear will better detect changes in sound intensity. The border is marked by the edge of the pleximeter directed toward the zone of the more resonant sounds
7. **Comparative percussion** should be carried out on exactly symmetrical points

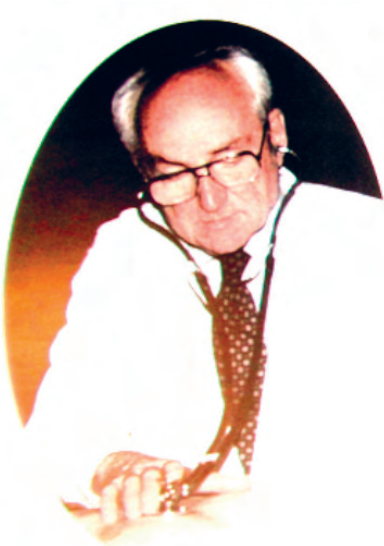## Case HISTORY. Auscultation

- **Auscultation (L *auscultare* to listen)** means listening to sounds inside the body
- Auscultation is *direct* when the examiner presses his ear to the patient's body, or *indirect* (instrumental)
- The French physician Laënnec first developed auscultation in 1816 and invented the first **stethoscope**. He described and named almost all the auscultative sounds (vesicular, bronchial respiration, crepitation, murmurs)
- The development of auscultation technique is connected with invention of the **binaural stethoscope** and **phonendoscope**, the study of the physical principles of auscultation and elaboration of methods for recording sounds (**phonography**). The graphic record of heart sounds was first made in 1894 by Einthoven

- The **acoustic stethoscope** is a closed cylinder that transmits sound waves from their source and along its column to the ear
- Its **rigid diaphragm** has a natural frequency of around 300 Hz. It screens out low-pitched sounds, and best transmits high-pitched sounds such as second heart sound
- The **bell** endpiece, with which the skin acts as the diaphragm, has a natural frequency varying with the amount of pressure exerted. It transmits low-pitched sounds when very light pressure is used

- ***Auscultation techniques***

- The environment should be **quiet** and **free from distracting noises**.
- Place the stethoscope on the **naked skin**, because clothing obscures the sound
- The ambient temperature should provide comfort for the undressed patient.
- During auscultation the patient either sits or stands upright. If the patient is in grave condition he may remain lying in bed
- To stabilize the stethoscope when in place, hold the endpiece between the fingers, pressing the diaphragm firmly against the skin
- The diaphragm “piece” should **never be used** without diaphragm. Because the bell functions by picking vibrations, it must be positioned so that the vibrations are not dampened
- **Place the bell** evenly and lightly on the skin, making sure there is skin contact around the entire edge
- To prevent extraneous noise, avoid touching the tubing with your hands or allowing the tubing to rub against any surfaces
- The skin to which the bell is pressed should be hairless because hair produces additional friction



"Your ears are better than any test and don't cost the patient a cent."

W. Proctor Harvey, 1959



«The DOCTOR with out books – like a worker without hands».

M. Mudrov

## ADDITIONAL METHODS

- **Laboratory tests**

  - General

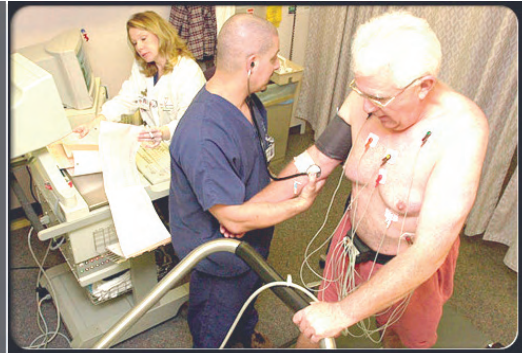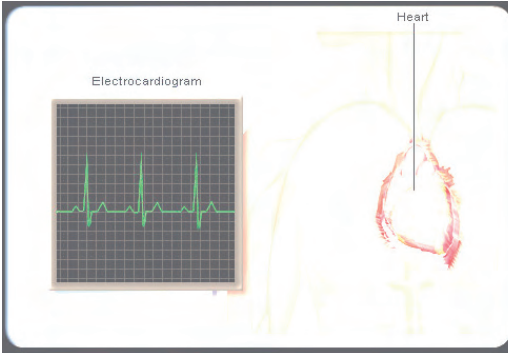
  - Biochemical

  - Genetic

- **Instrumental tests**

  - Noninvasive

  - Invasive

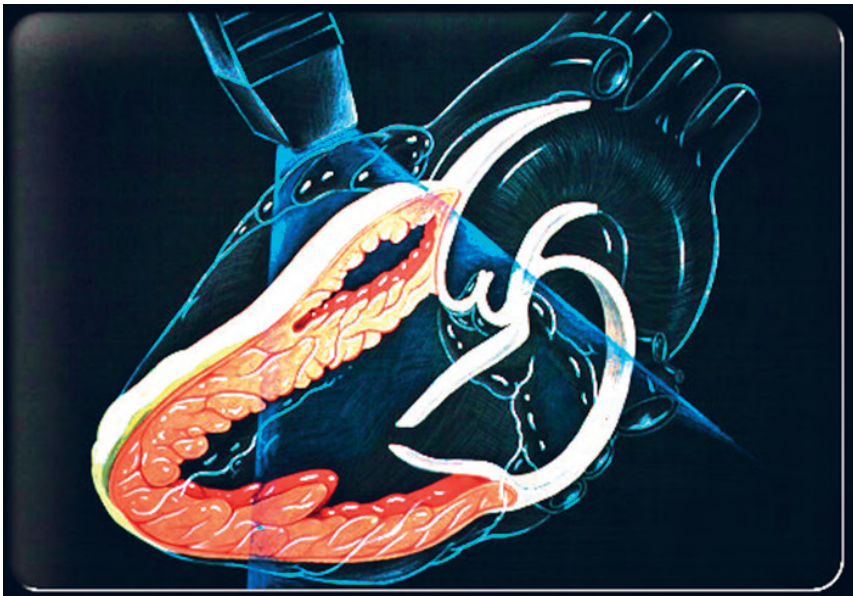


## ECG

## ECG

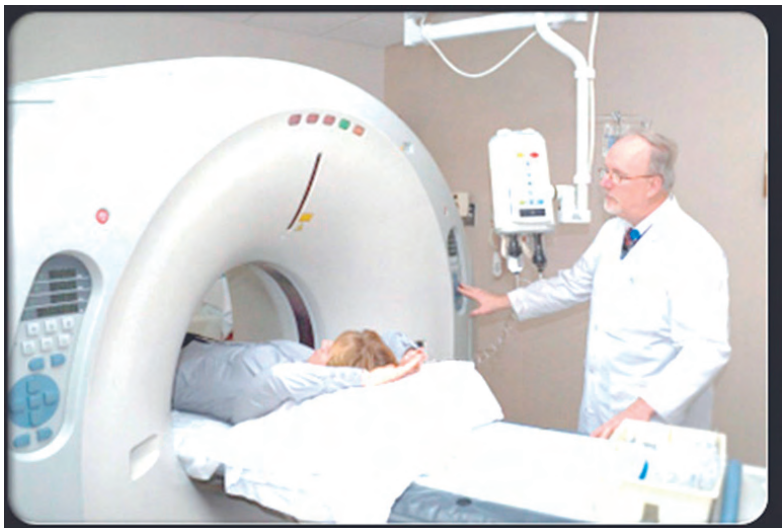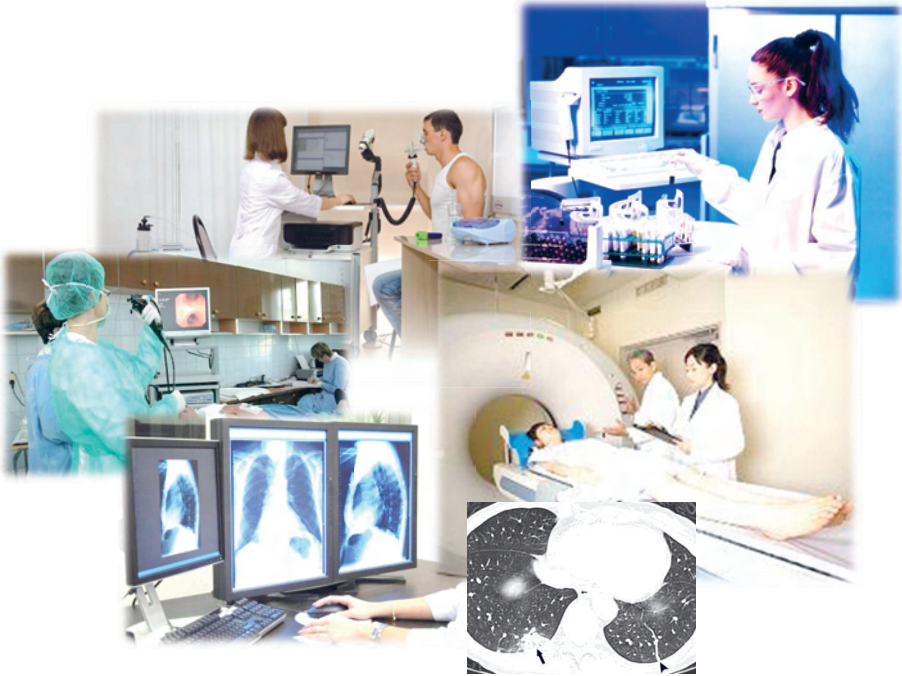stress test to evaluate the heart's response to physical exercise and stress

## ULTRASOUND HEART TESTING

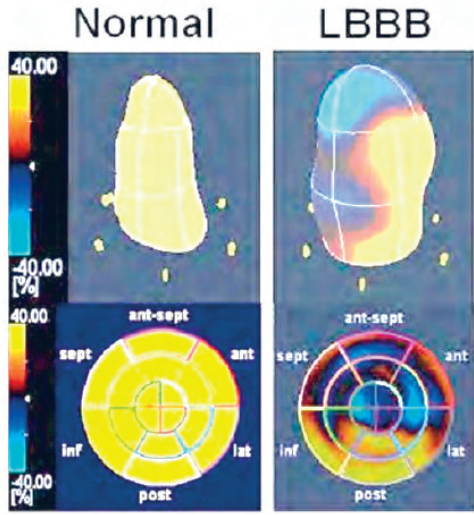


Echocardiogram – procedure using ultrasound waves that produce two-dimensional pictures of the valves and chambers of the heart so the doctor can evaluate their size and motion

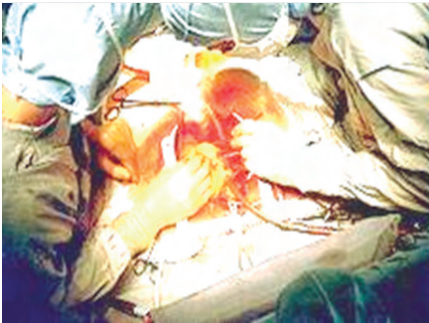
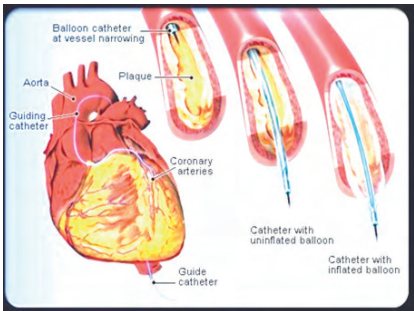
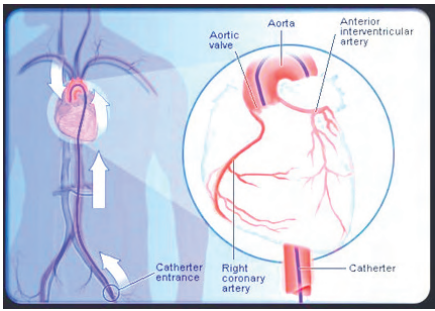




Computerized tomography (CT)



**Demonstration of Time Sequence of Left Ventricular Mechanical Activation Using Novel Three Dimensional Speckle Tracking Analysis**



## CORONARY ANGIOGRAPHY

## REFERENCES

**Mosby's Guide to Physical Examination/** Henry M. Seidel et al. – 5th ed. – Mosby, 2003. – P.15-37, 49-67, 84-94, 110-112, 127-132, 153-158, 167-189, 236-245, 257-264, 283-291, 323-341, 707-733, 861-868.

**Online access to free Evolve Student Learning Resources designed for textbook Seidel: Mosby's Guide to Physical Examination, 5th edition;**

Login: <http://evolve.elsevier.com/Seidel/>

**Kovalyova O.N., Ashcheulova T.V.** Propedeutics to Internal Medicine. Part 1. – Vinnytsya: NOVA KNYHA, 2017. – 424 p.

**Kovalyova O.N., Asheulova T.V.** General inspection: manual for students. – Kharkov: "Turbo". – 2004. – 60 p.

**Khomazjuk V.A., Ostashevskaya T.G., Krasnyuk I.V.** Propaedeutics of Internal Medicine and Patient Care: Study guide for the practical classes. Part I. – Kyiv: NMU, 2005. – 44 p.

**Kovalyova O.N., Asheulova T.V.** Diagnostics of respiratory organs disease: manual for students. – Kharkov: "Turbo". – 2004. – 64p.

**Bickley, Lynn S.; Szilagy, Peter G.** Bates' Guide to Physical Examination and History Taking, 10th Edition. – 934p. Copyright ©2009 Lippincott Williams & Wilkins

The Point online resources, <http://thepoint.lww.com>

LECTURE # **2**

**SYMPTOMS AND SIGNS OF RESPIRATORY  
DISEASES**

**BASED ON QUESTIONING THE PATIENT,  
PALPATION AND PERCUSSION  
OF THE CHEST**

## THE PLAN

- Main complaints
- Cough (dry, productive)
- Varieties of sputum, their diagnostic value
- Other complaints ("minor")
- Anamnesis of the disease
- Anamnesis of life
- System approach to physical examination of a patient
- General inspection
- Variations of shortness of breath
- Phenotypes of patients
- Measurements in the study of the chest
- Variants of frequency and rhythm of breathing
- Chest shape options
- Palpation of the chest
- Voice trembling
- Percussion of the chest (topographical, comparative):  
rules and technique
- References

## MAIN COMPLAINTS

- Cough (tussis)
- Sputum
- Hemoptysis
- Short breathing (dyspnea, asthma)
- Pain with breathing
- Wheezing audible at a distance
- Sleep Apnea



**Cough (dry, productive)**



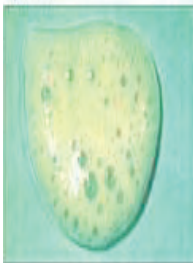

## Characteristics to note when assessing sputum.

- Mucoid
- Purulent
- Frothy
- Bloodstained
- Rusty

## Varieties of sputum

Sputum



▲ Serosus/frothy/pink  
Pulmonary oedema



▲ Mucopurulent  
Bronchial or pneumonic  
infection

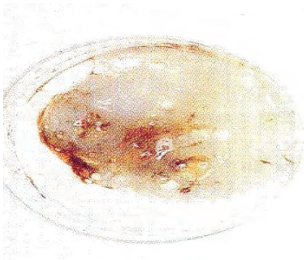

▲ Purulent  
Bronchial or pneumonic  
infection

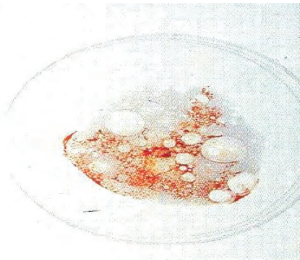


▲ Blood-stained  
Cancer, tuberculosis,  
bronchiectasis,  
pulmonary embolism

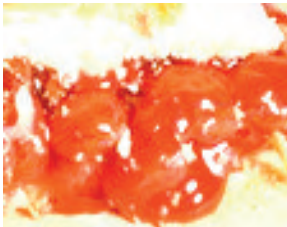
# Sputum



Rusty



Frothy



Bloody



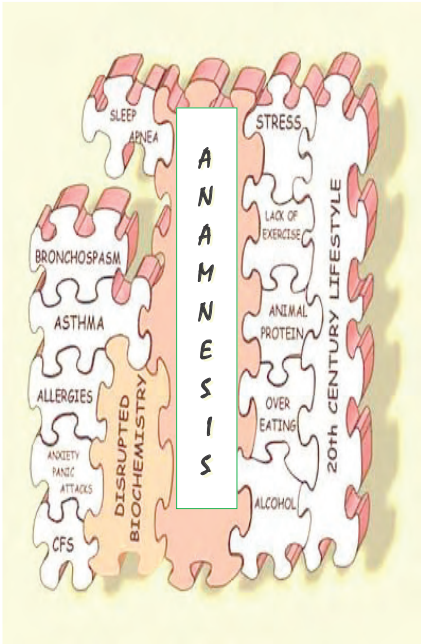
Cork

# Signs of general inflammation





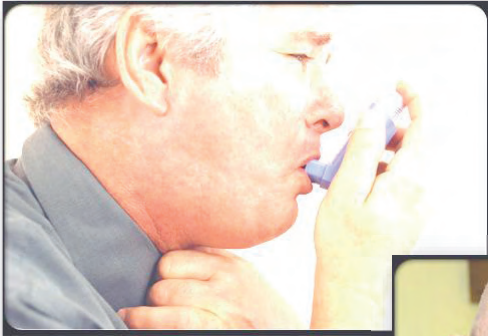## Anamnesis morbi & vitae



## Anamnesis morbi & vitae



### Anamnesis morbi & vitae



### Anamnesis morbi & vitae



## Anamnesis morbi & vitae

### RISK FACTORS

Primary cause of pulmonary problems is heavy, long-term cigarette smoking, smoke, occupational hazards



## SYSTEMATIC APPROACH TO PHYSICAL EXAMINATION OF THE CHEST

### 1. Inspection

- Initial impression – distress, wheeze, malnourishment, etc.
- Respiratory rate, depth, and pattern
- Asynchronous motion of the rib cage and abdomen
- Recession of the intercostal, supraclavicular, or suprasternal spaces
- Tracheal tug
- Cyanosis
- Finger clubbing or nicotine stains
- Accessory muscle employment
- Pursed-lip breathing
- Chest wall shape and deformity

### 2. Palpation

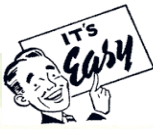- Tracheal deviation
- Chest expansion (globally/locally)
- Vocal fremitus
- Pleural rub
- Lymphadenopathy
- Subcutaneous emphysema

### 3. Percussion

- Normal, dull, or increased

### 4. Auscultation

- Breath sounds – can be only normal, reduced, or bronchial (last associated with increased vocal resonance, whispering pectoriloquy, and egophony)
- Added sounds – can be only absent, wheezes, crackles, or pleural rub



## Points to note in a general assessment.

- Physique
- Voice
- Breathlessness
- Clubbing
- Cyanosis or pallor
- Intercostal recession
- Use of accessory respiratory muscles
- Venous pulses
- Lymph nodes

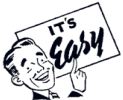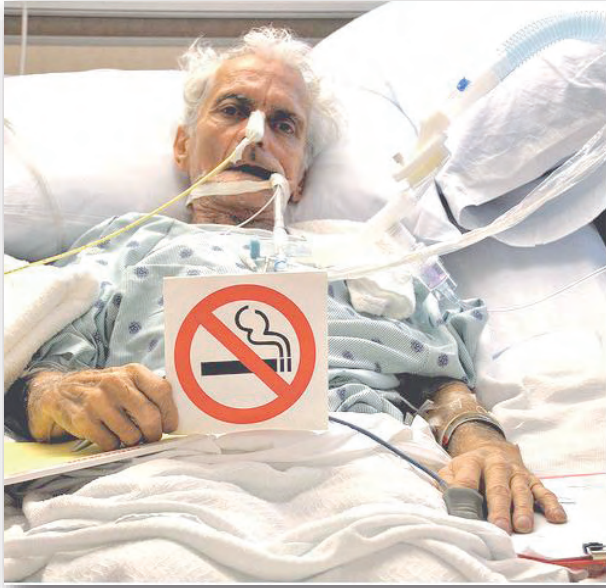## Other Symptoms & Signs

In addition to the main symptoms of pulmonary disease, there are other, less common symptoms.

These include the following:

- Stridor (noisy breathing)
- Voice changes
- Swelling of the ankles (dependent edema)

## General inspection



### Common Conditions Associated with Dyspnea

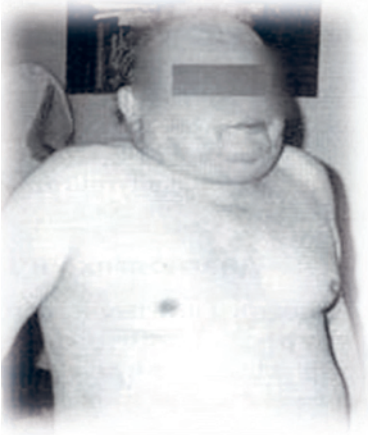Condition	Dyspnea	Other Symptoms
Asthma	Episodic; symptom free between attacks	Wheezing, chest pain, productive cough
Pulmonary edema	Abrupt	Tachypnea, cough, orthopnea, and paroxysmal nocturnal dyspnea with chronic state
Pulmonary fibrosis	Progressive	Tachypnea, dry cough
Pneumonia	Exertional, insidious onset	Productive cough, pleuritic pain
Pneumothorax	Sudden, moderate to severe	Sudden pleuritic pain
Emphysema	Insidious onset, severe	Cough as disease progresses
Chronic bronchitis	As disease progresses and with infection	Chronic, productive cough
Obesity	Exertional	



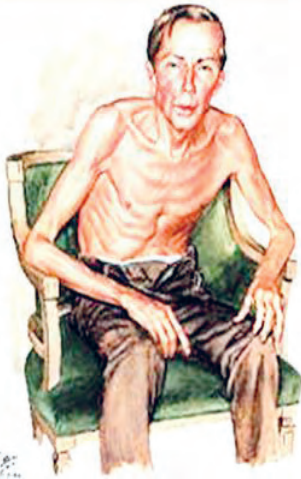### Positional Dyspnea

Type	Possible Causes
Orthopnea	Congestive heart failure Mitral valvular disease Severe asthma (rarely) Emphysema (rarely) Chronic bronchitis (rarely) Neurologic diseases (rarely)
Trepopnea	Congestive heart failure
Platypnea	Postpneumonectomy status Neurologic diseases Cirrhosis (intrapulmonary shunts) Hypovolemia

### Orthopnea



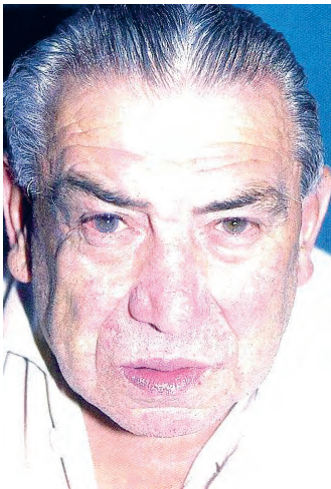### Tripod position



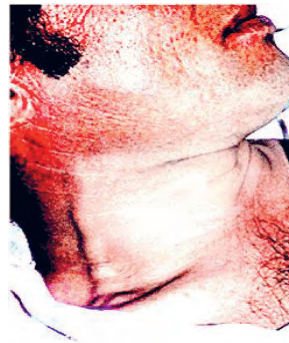**“Pink puffers”**



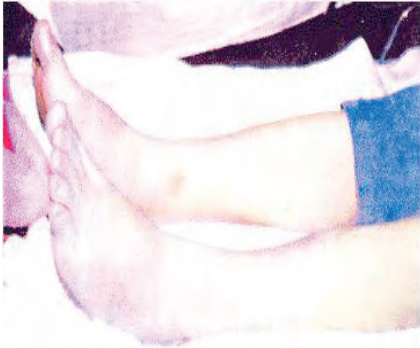**“Blue edemas”**



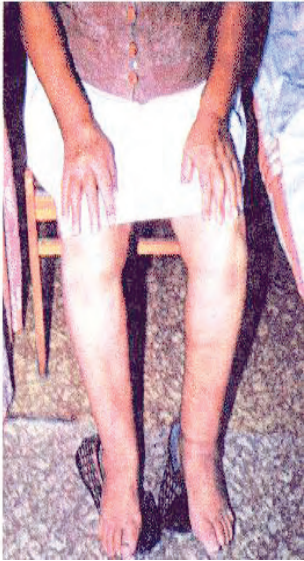**Central cyanosis**



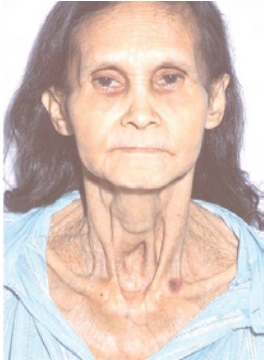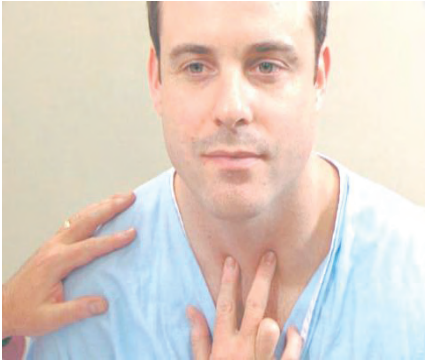**Sign of swollen cervical veins**



Swelling of the ankles  
(dependent edema)



**Technique for  
determining the position of the  
trachea**

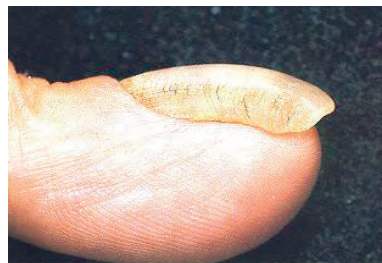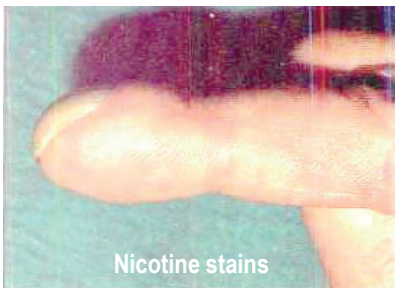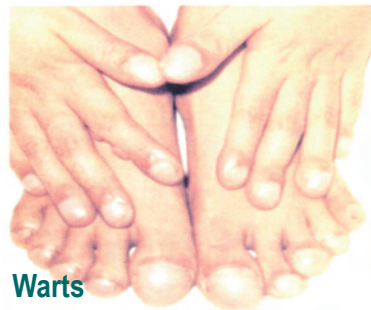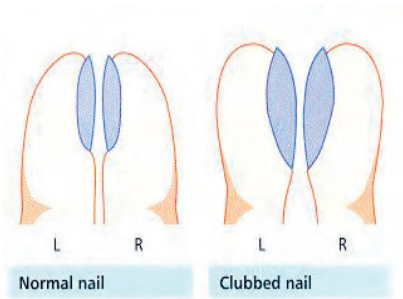


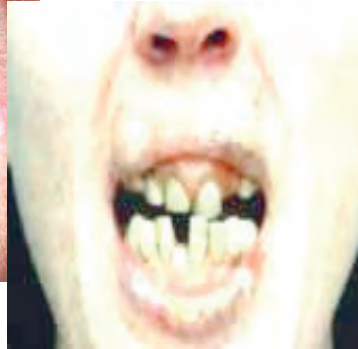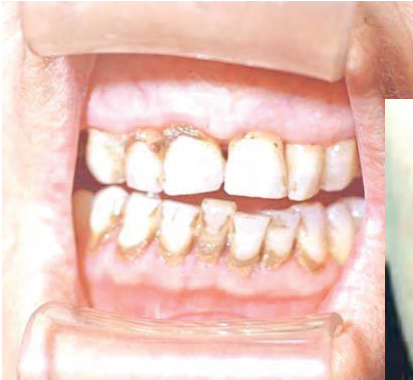**Tracheal deviation.**  
**Note the marked tracheal deviation to the patient's right**



## YELLOW NAIL SYNDROME IN BRONCHIECTASIS

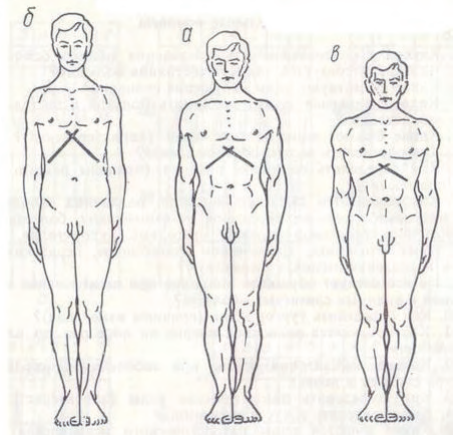
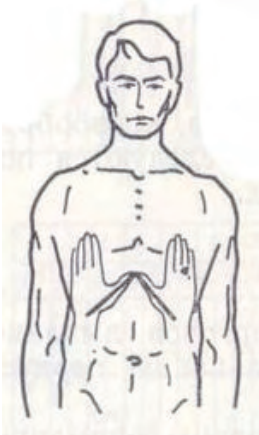### Findings in the Gums and Teeth



Yellow nail syndrome in bronchiectasis.

Inspect hands, nails

### Static inspection



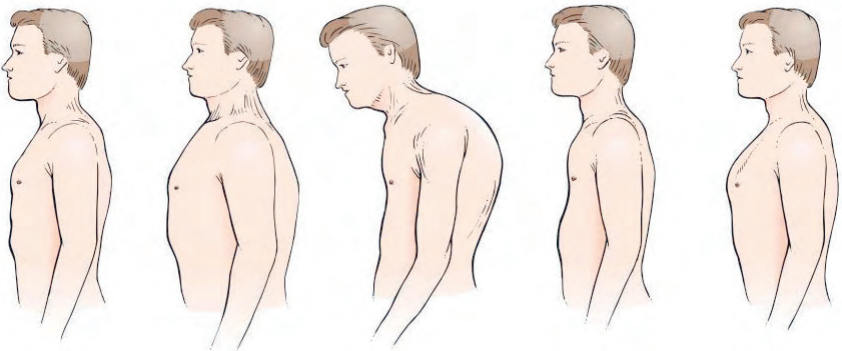
Asthenic chest   Normosthenic chest   Hypersthenic chest



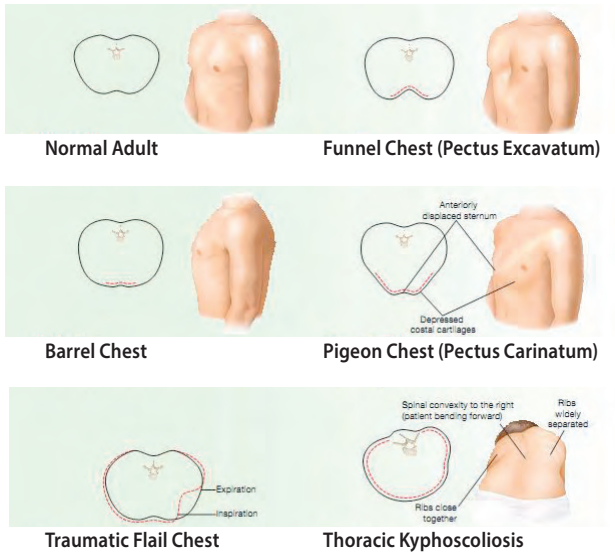
### Features to note in assessing the shape of the chest.

- Kyphosis
- Scoliosis
- Flattening
- Over-inflation

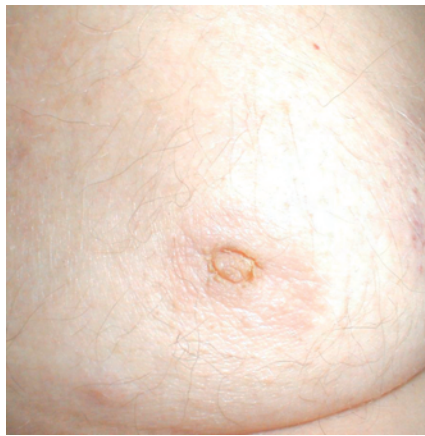
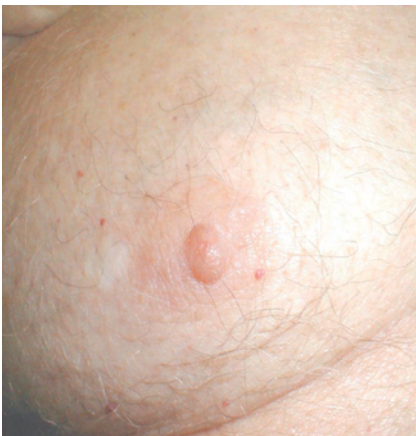### Static inspection



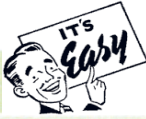## Deformities of the Thorax



## Breast examination



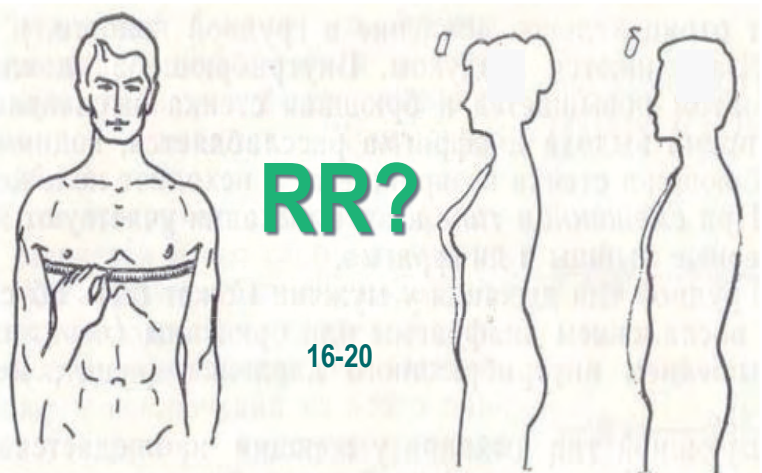
**Retracted nipple**



### Measurements of the chest.

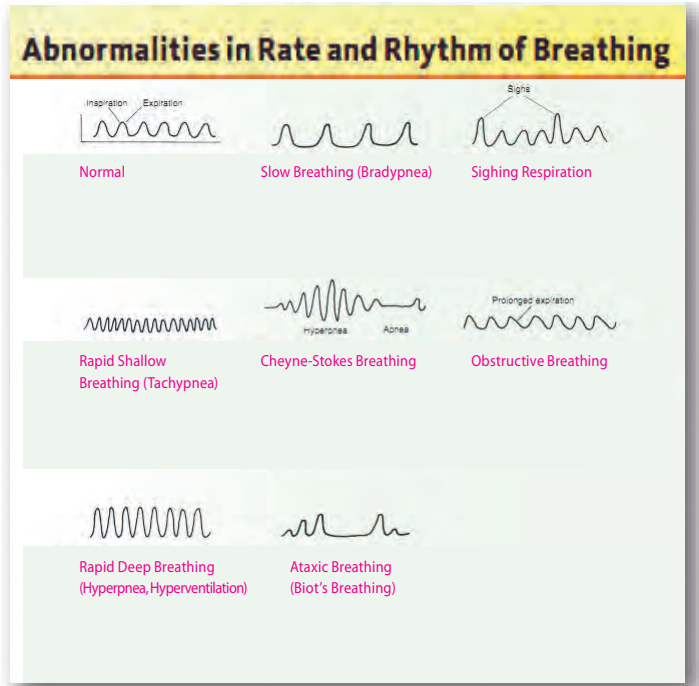
- Rate of respiration
- Rhythm of respiration
- Chest expansion
- Symmetry

### Dynamic inspection



Chest expansion

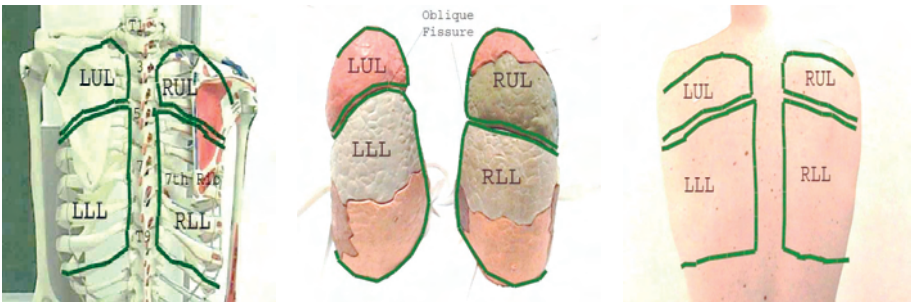
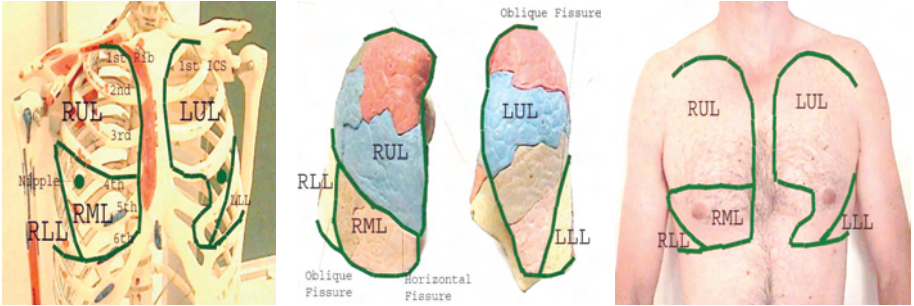
Chest and abdominal or mixed types of respiration



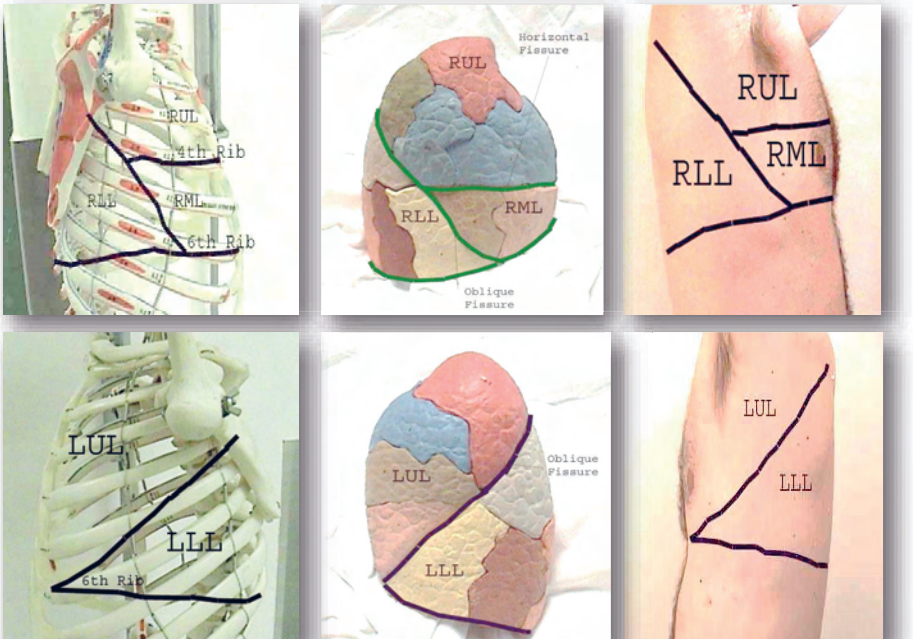
### Abnormalities in Rate and Rhythm of Breathing

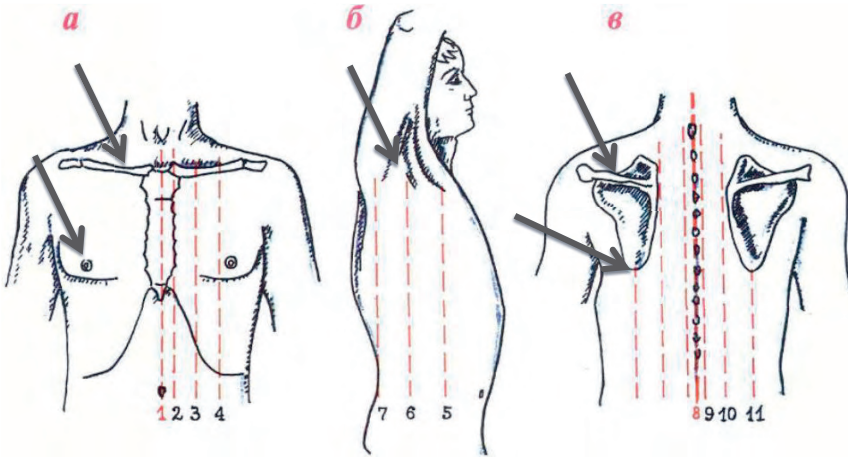
Pattern	Characteristic	Cause
Apnea	Absence of breathing	Cardiac arrest
Biot's respiration	Irregular breathing with long periods of apnea	Increased intracranial pressure Drug-induced respiratory depression Brain damage (usually at the medullary level)
Cheyne-Stokes respiration	Irregular breathing with intermittent periods of increased and decreased rates and depths of breaths alternating with periods of apnea	Drug-induced respiratory depression Congestive heart failure Brain damage (usually at the cerebral level)
Kussmaul's respiration	Fast and deep	Metabolic acidosis

Projection of the lungs on the chest wall. Anterior view.

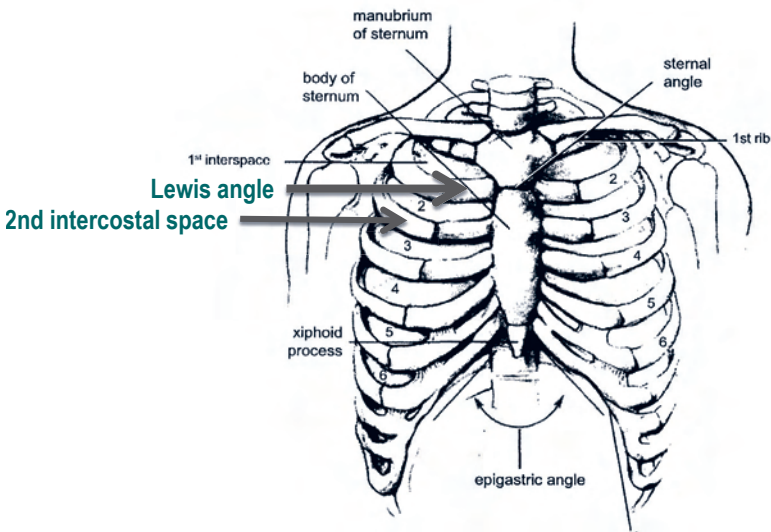


Projection of the lungs on the chest wall. Posterior view.



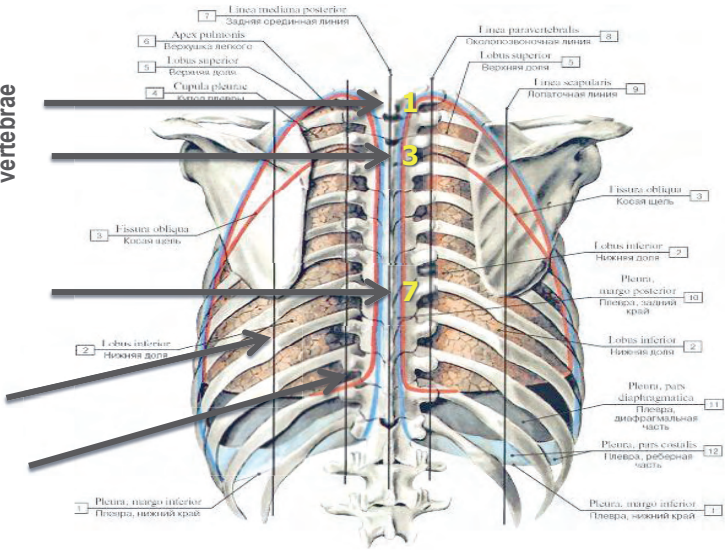


Chest landmarks & lines



Chest landmarks

Spinous processes of the thoracic vertebrae



Chest land marks & lines

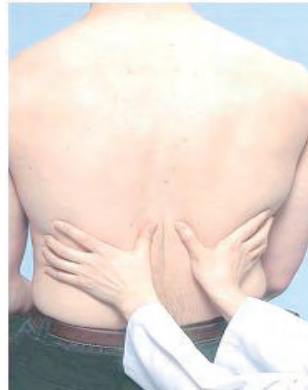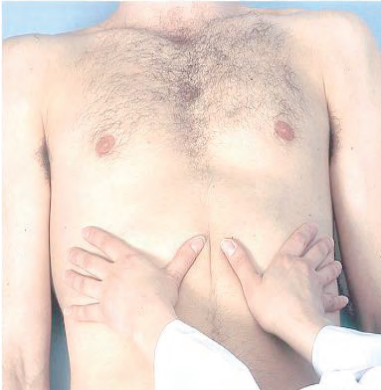## Palpation

Palpation is used to assess the following:

- ▣ Areas of tenderness
- ▣ Symmetry of chest excursion
- ▣ Tactile fremitus



## Palpation

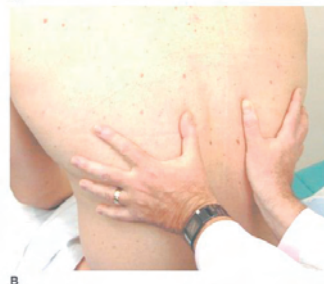
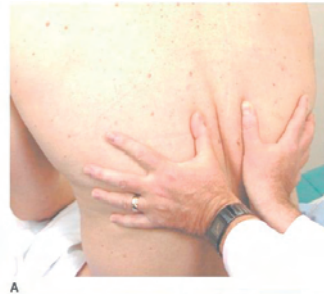
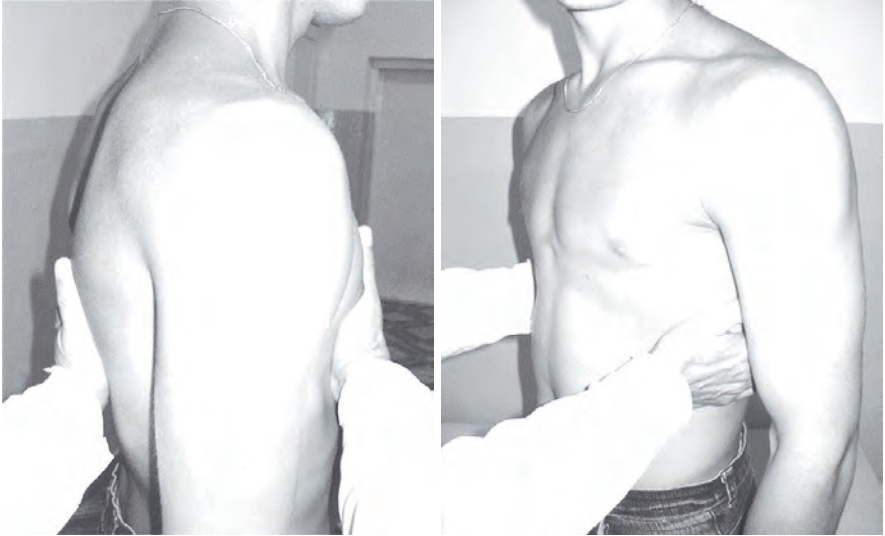Symmetry of chest excursion

Technique for evaluating posterior chest excursion

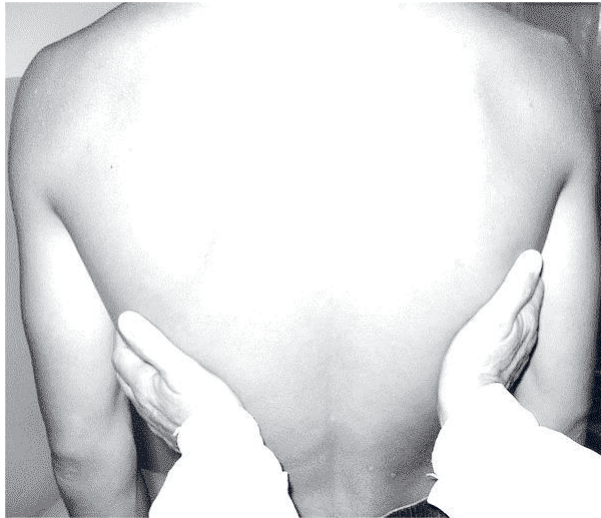A, Placement of the examiner's hands during normal expiration.

B, Placement of the examiner's hands after normal inspiration

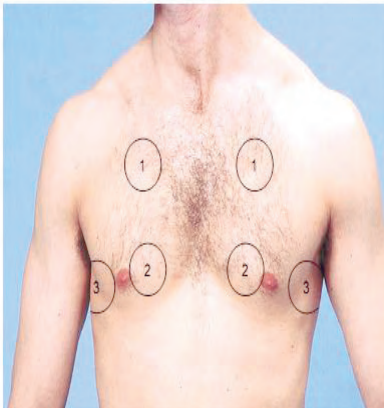




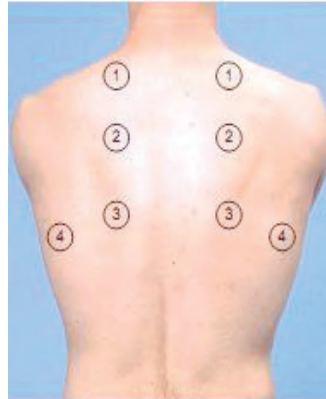
*Assessment of elasticity of the chest.*



**Method for determining voice tremor – filling fremitus**

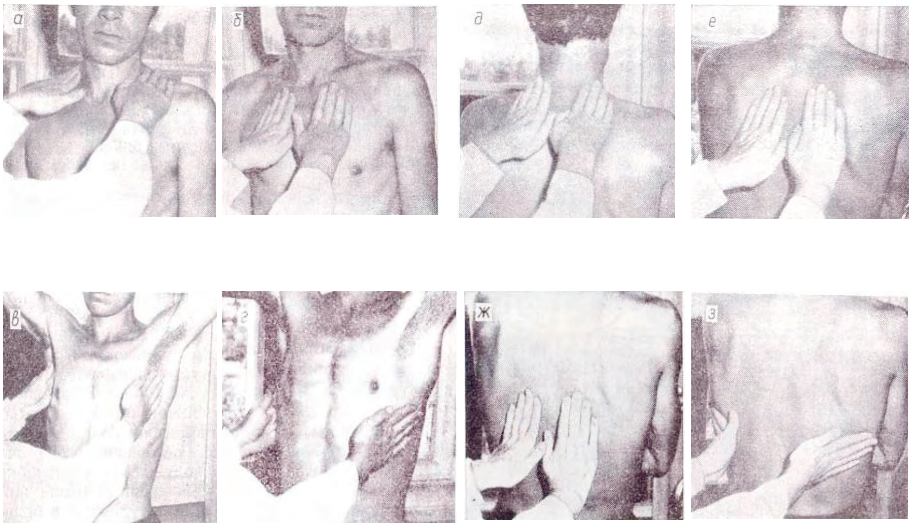


LOCATIONS FOR FEELING FREMITUS

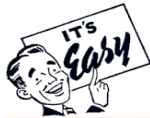

LOCATIONS FOR FEELING FREMITUS

**Method for determining voice tremor – filling fremitus**



**Tactile fremitus**



### Causes of Changes in Tactile Fremitus

#### Increased Tactile Fremitus

Pneumonia

#### Decreased Tactile Fremitus

Unilateral

Pneumothorax

Pleural effusion

Bronchial obstruction

Atelectasis (incomplete expansion of lung tissue)

Bilateral

Chronic obstructive lung disease

Chest wall thickening (muscle, fat)

Percussion (*L. percutere* to strike through) was first proposed by an Austrian physician Auenbrugger in 1761 year.

Tapping various parts of the human body produces sounds (notes) by which one can learn about the condition of the underlying organs.


Percussion is done by tapping with a plexor (hammer) on a pleximeter placed on the body, or by a finger on another finger.



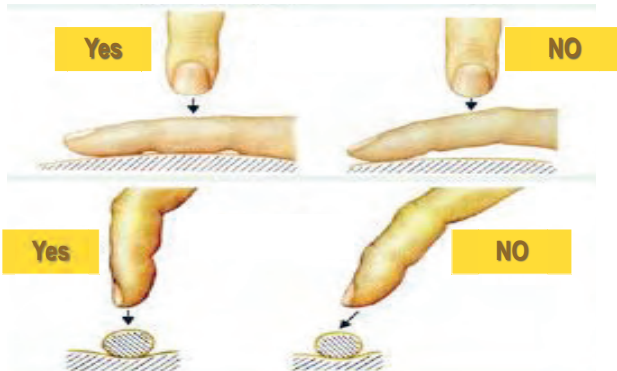
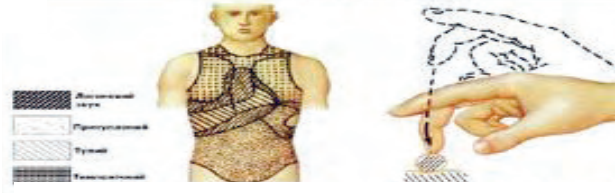
Jean Nicholas Corvisart, 1755-1821

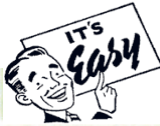

L.Auenbrugger, 1722-1809



## Percussion technique





Points to note on percussion of the chest.

- Resonance
- Dullness
- Pain and tenderness

Percussion Notes and Their Characteristics

	Relative Intensity	Relative Pitch	Relative Duration	Example of Location
<b>Flatness</b>	Soft	High	Short	Thigh
<b>Dullness</b>	Medium	Medium	Medium	Liver
<b>Resonance</b>	Loud	Low	Long	Normal lung
<b>Hyperresonance</b>	Very loud	Lower	Longer	None normally
<b>Tympany</b>	Loud	High*	*	Gastric air bubble or puffed-out cheek

\* Distinguished mainly by its musical timbre.

## Physical Characteristics of the Percussion Note

Percussion note depends on physical properties of a underlying vibrating body (physical properties of components within the percussion zone - *air and solid particles*).

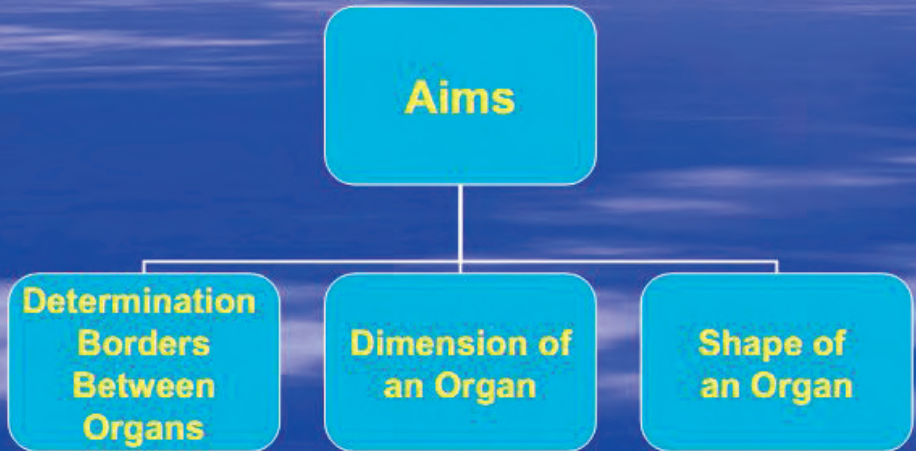
Percussion notes differ in loudness, duration, pitch, and timbre.

Main Types  
of Percussion  
of the Lungs

Topographic  
Percussion

Comparative  
Percussion

# Topographic Percussion



## Topographic Percussion of the Lungs is Used for Location:

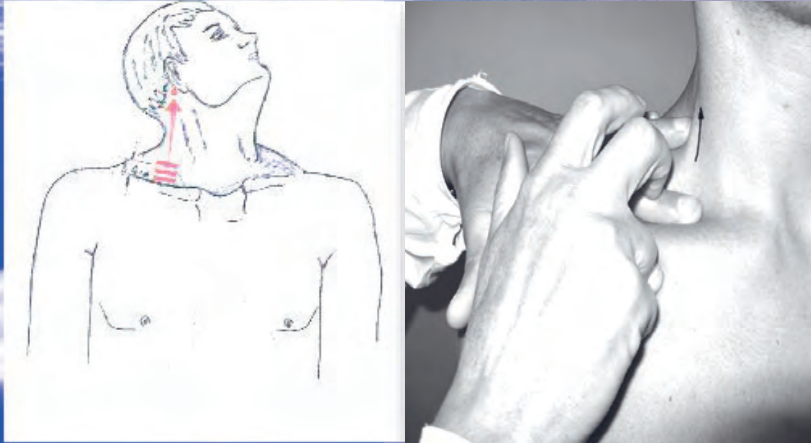
1. Upper level of pulmonary apices (height of apices) in the front side and in the back side, width of pulmonary apices (Kroenig's

2. Lower borders of the lungs for each of their topographic lines

3. Range of movement of the lower pulmonary borders (diaphragmatic movement)



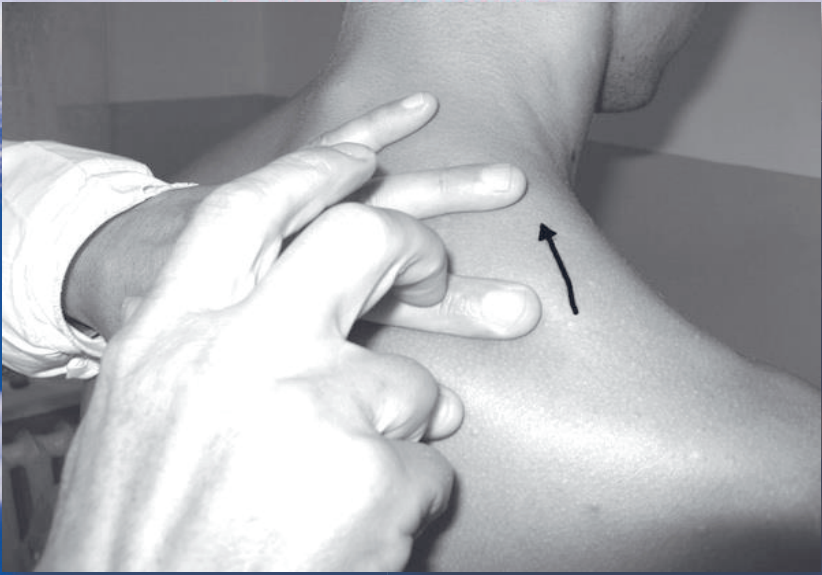## Upper Level of Pulmonary Apices in the Front Side



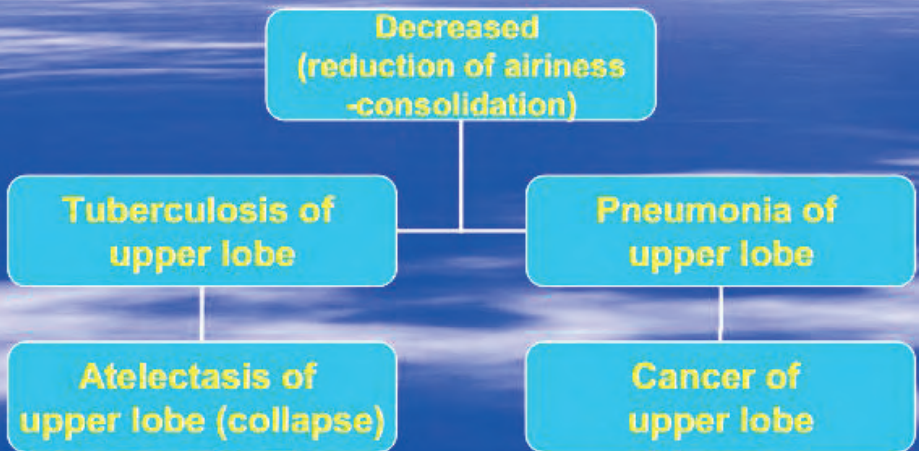
## Upper Level of Pulmonary Apices in the Front Side

**Normal level is 3-4 cm above the  
clavicles (in the right side is  
1 cm lower)**

## Upper Level of Pulmonary Apices



## Upper Level of Pulmonary Apices in the Pathology



## Upper Level of Pulmonary Apices in the Pathology

Increased  
(increased airiness of  
the lungs)

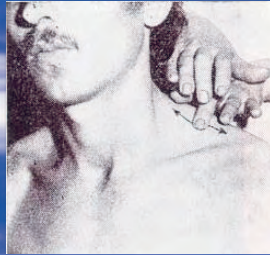Emphysema of lungs  
(bilateral)

## Upper Level of Pulmonary Apices in the Back Side

Normal level is about at level of the  
spinous process of the 7-th cervical  
vertebra

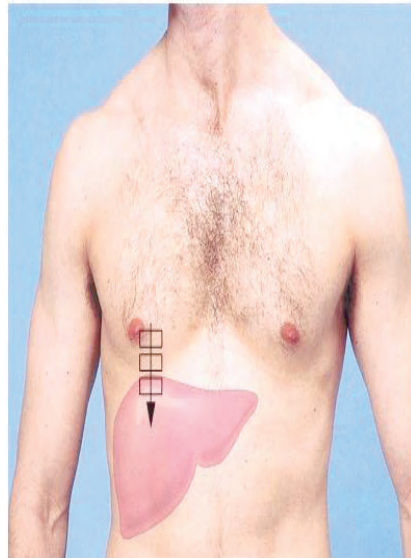
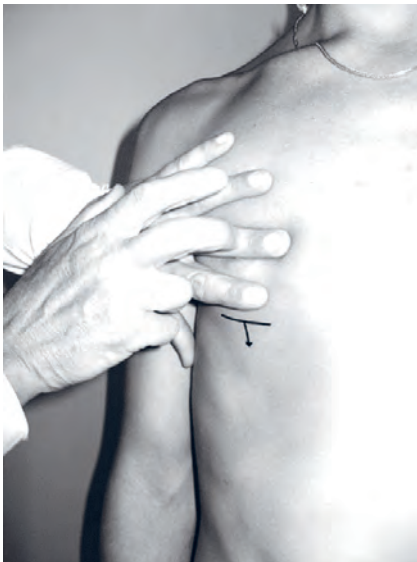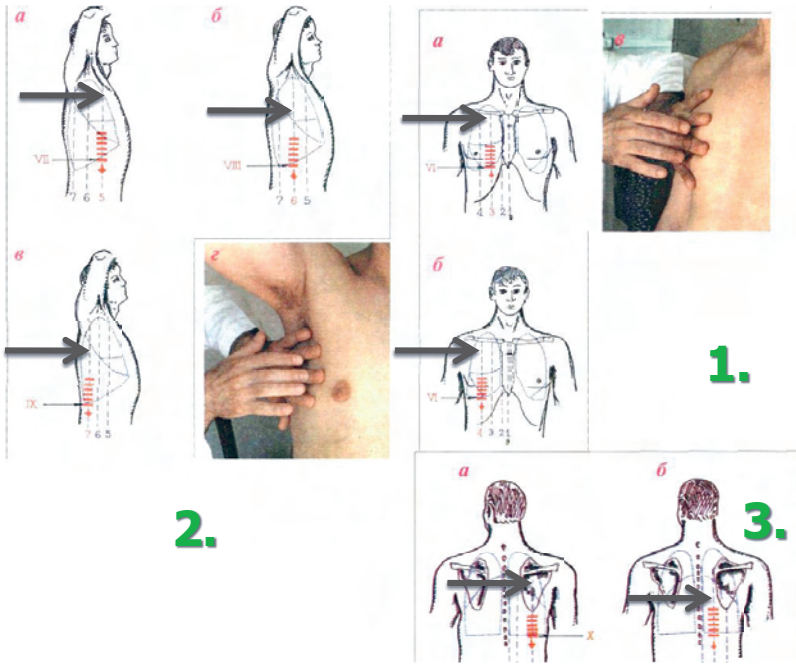
## Width of Pulmonary Apices (Kroenig`s areas)

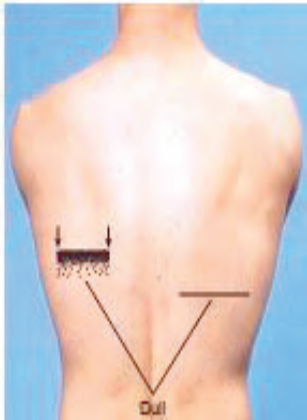
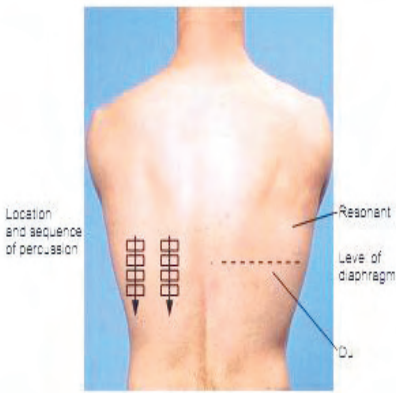
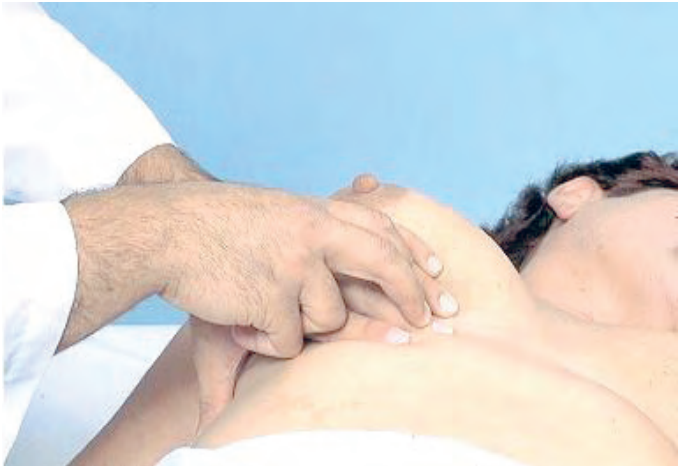**Normal width is 4-7 cm**  
**( in the right side is 2 cm less)**



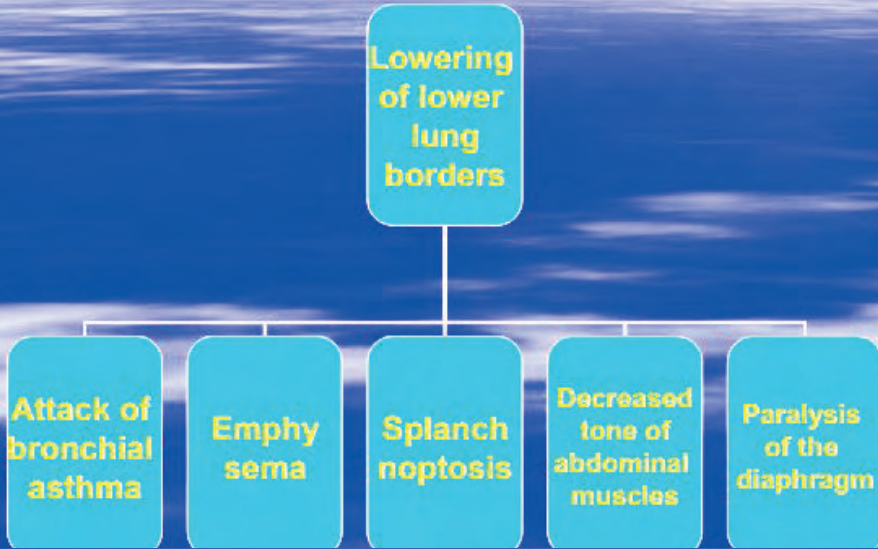
### Normal Lower Borders of the Lungs for Each of Their Topographic Lines

<b>Topographic Lines</b>	<b>Normal Location of Lower Pulmonary Borders</b>
Parasternal Line	5-th intercostal space
Midclavicular Line	6-th rib or 6-th intercostal space
Anterior Axillary Line	7-th rib
Midaxillary Line	8-th rib
Posterior Axillary Line	9-th rib
Scapulae Line	10-th rib
Paraspinal Line	spinous process of 11-th thoracic vertebra

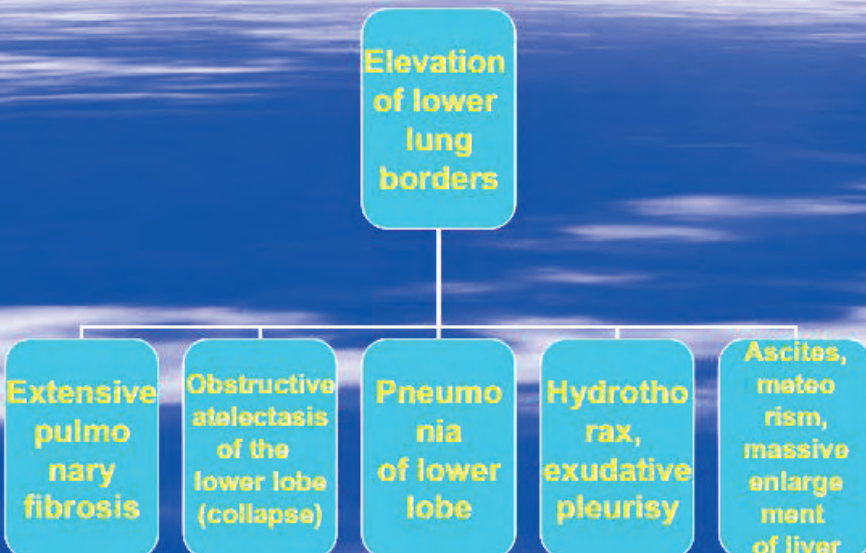


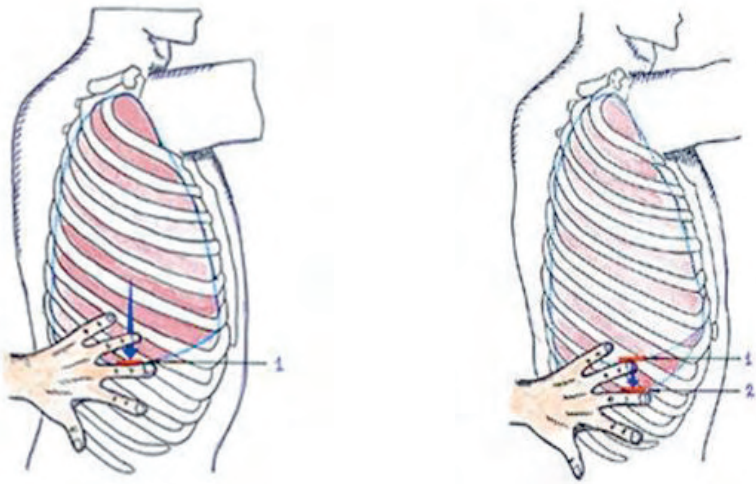


## Lower Borders of the Lungs in the Pathology



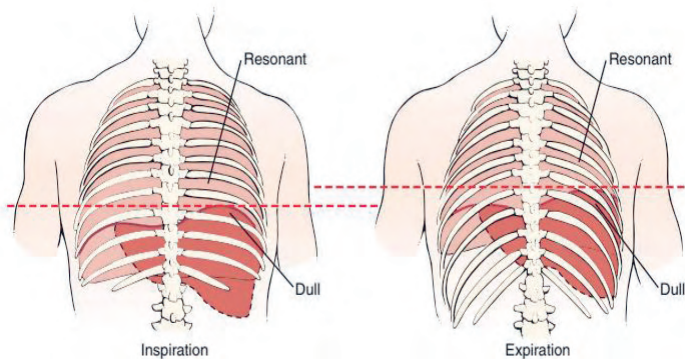
## Lower Borders of the Lungs in the Pathology





Mobility of the pulmonary region

### Technique for evaluating diaphragmatic motion



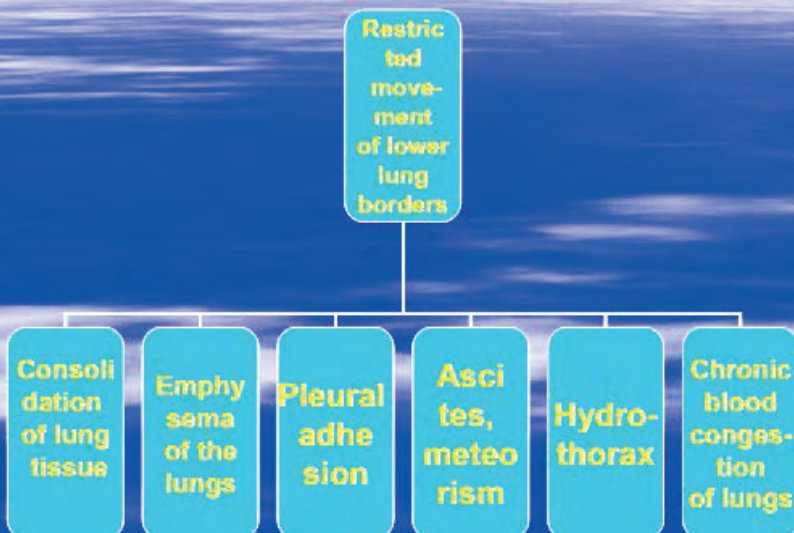
During inspiration (left), percussion in the right seventh posterior interspace at the midscapular line would be resonant as a result of the presence of the underlying lung. During expiration (right), the liver and diaphragm move up. Percussion in the same area would now be dull, owing to the presence of the underlying liver



## Range of Movement of Lower Pulmonary Borders

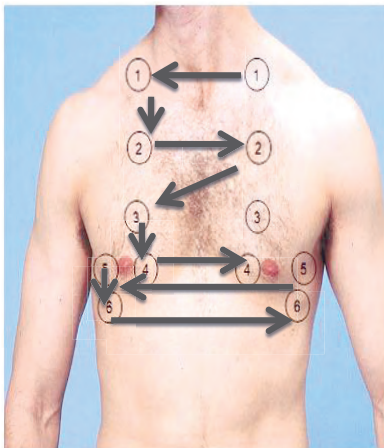
Midclavicular line	-	4-6 cm
Midaxillary line	-	6-8 cm
Scapular line	-	4-6 cm

## Range of Movement of Lower Pulmonary Borders in the Pathology

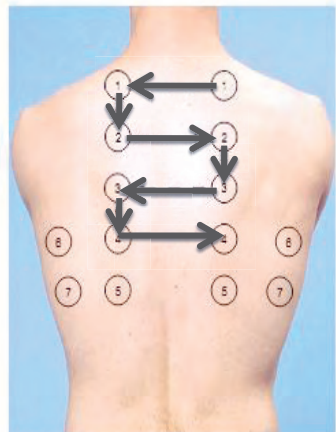


## Comparative Percussion:

- \* Percussion notes over the lungs on the symmetrical points of the chest are compared.
- \* It must be resonant note over the lungs on symmetrical points of the chest.



LOCATIONS FOR PERCUSSION AND AUSCULTATION



"LADDER" PATTERN FOR PERCUSSION AND AUSCULTATION

## Changes of Percussion Note Over Lungs

**Dull Note**  
(only dense elements,  
absence of air)

Lobar pneumonia in 2-nd stage

Large pulmonary cavity with fluid (pus)

Tumour

Massive accumulation of fluid in pleural cavity

Complete obstructive atelectasis

**Dullish (impaired) Note**  
(more dense elements, than air)

Pulmonary fibrosis

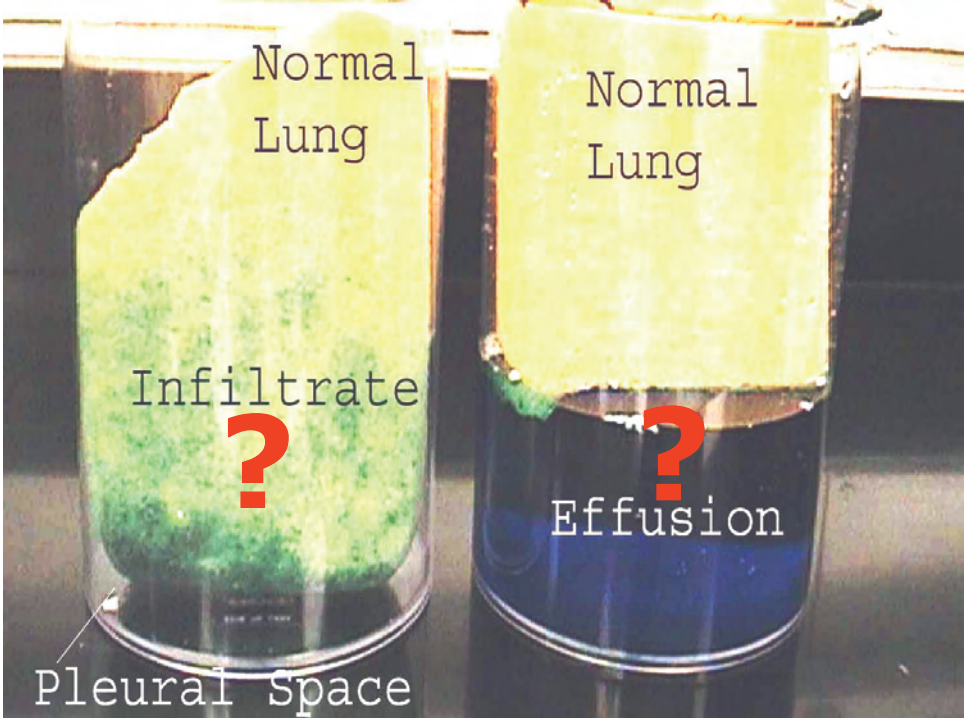
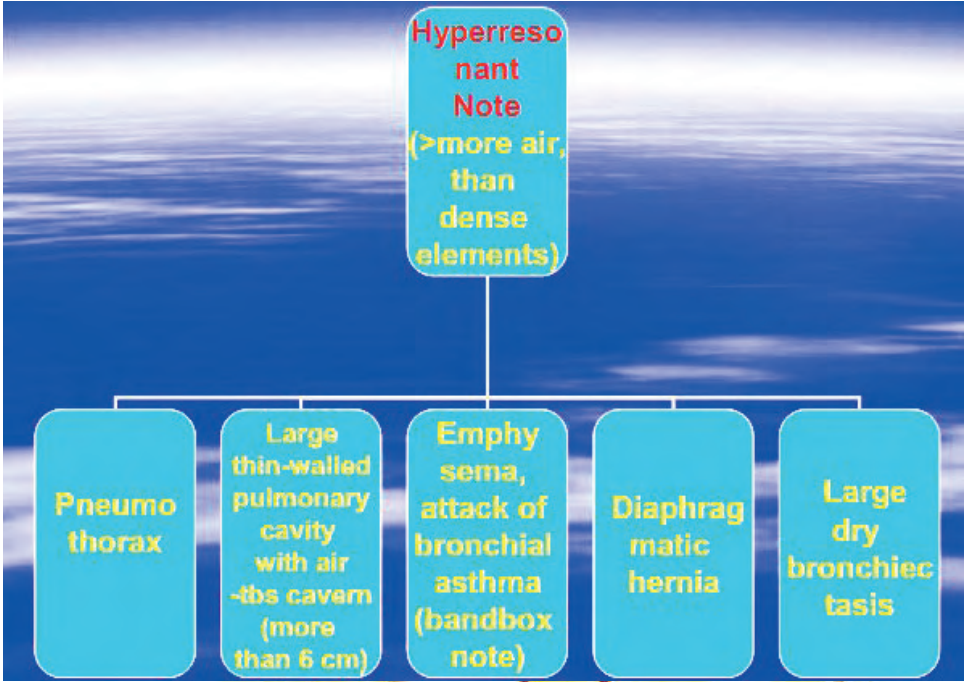
Pleural adhesion

Lobular pneumonia

Obstructive atelectasis

Hydrothorax less than 6 cm

Pulmonary oedema



## REFERENCES

- Kovalyova O.N., Ashcheulova T.V. Propedeutics to Internal Medicine. Part 1. – Vinnytsya: NOVA KNYHA, 2017. – 424 p.
- Kovalyova O.N., Asheulova T.V. General inspection: manual for students. – Kharkov: “Turbo”. – 2004. – 60p.
- Khomazjuk V.A., Ostashevskaya T.G., Krasnyuk I.V. Propaedeutics of Internal Medicine and Patient Care: Study guide for the practical classes. Part I. – Kyiv: NMU, 2005. – 44 p.
- Kovalyova O.N., Asheulova T.V. Diagnostics of respiratory organs disease: manual for students. – Kharkov: “Turbo”. – 2004. – 64p.
- Bickley, Lynn S.; Szilagyi, Peter G. Bates' Guide to Physical Examination and History Taking, 10th Edition. – 934 p. Copyright ©2009 Lippincott Williams & Wilkins.
- The Point online resources, <http://thepoint.lww.com>

LECTURE # **3**

**SYMPTOMS & SIGNS  
OF RESPIRATORY DISEASES BASED  
ON AUSCULTATION  
OF THE LUNGS**

## THE PLAN

- Historical reference
- Auscultation method
- Rules & techniques
- Semiotics of respiratory noises
- Types of Breath Sounds (Tracheal, Bronchial, Bronchovesicular, Vesicular)
- Adventitious sounds (Crackles, Wheeze, Rhonchi, Pleural rub)
- Stridor (self help, Heimlich method)
- References



From the Hippocrates Medicine series by Joseph Wilfrid Louis KUN-RENIER, 1932-34



**Teobal'd Chartran.**  
**Laennec with stetoskop examines a patient with students**

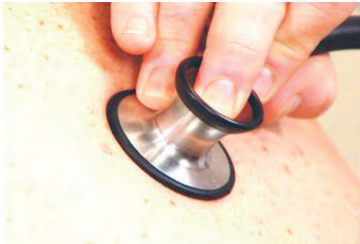
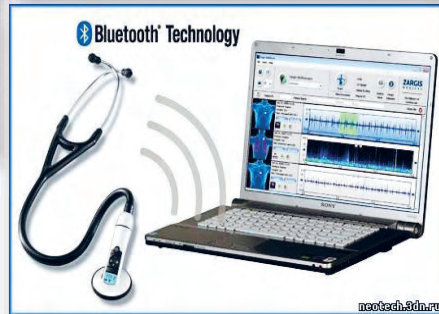
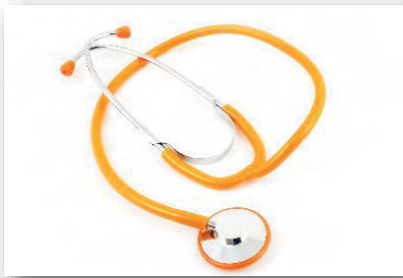
**Dr. George Cammann**  
**1855**

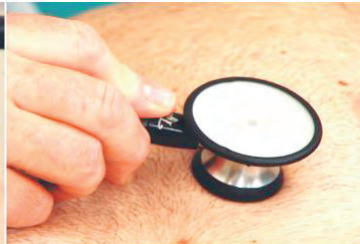

**Cammann Stethoscope, 1852**





A



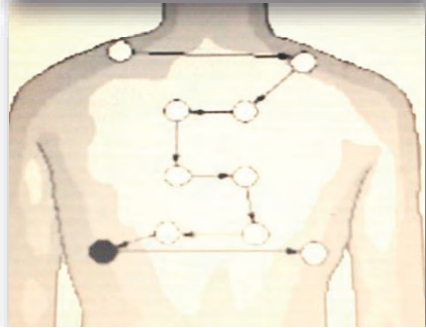

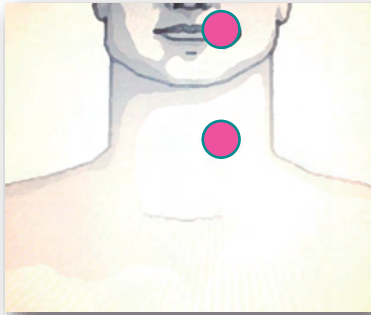
B

**Placement of stethoscope heads.**

**A, Correct placement of the diaphragm. Notice that the head is applied tightly to the skin.**

**B, Placement of the bell. Notice that the bell is applied lightly to the skin**

### Auscultation Algorithm of the lungs



## Types of Breath Sounds

Breath sounds are heard over most of the lung fields. They consist of an inspiratory phase followed by an expiratory phase. There are four types of normal breath sounds:

- Tracheal
- Bronchial
- Bronchovesicular
- Vesicular

## Abnormal sounds heard during auscultation are called adventitious sounds

Adventitious sounds include the following:

- Crackles
- Wheezes
- Rhonchi
- Pleural rub

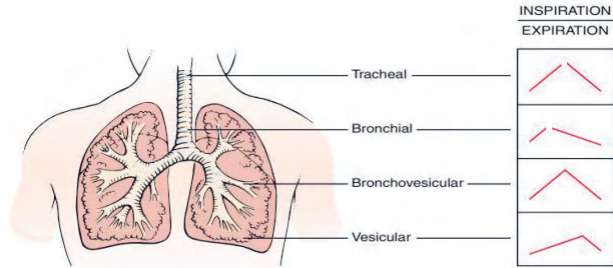
### ▪ Adventitious Breath sounds

- Adventitious sounds
  - ✓ wheezes & ronchi
  - ✓ crackles
  - ✓ pleural rub

### Additional tests

- Vocal fremitus & resonance
  - ✓ bronchophony
  - ✓ aegophony
- ✓ whispering pectoriloquy

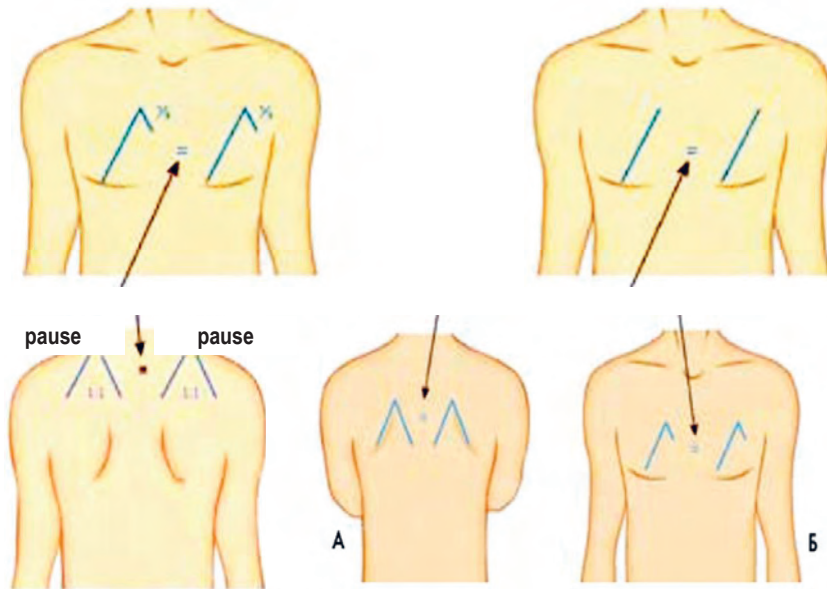
## Characteristics & location of main breath sounds



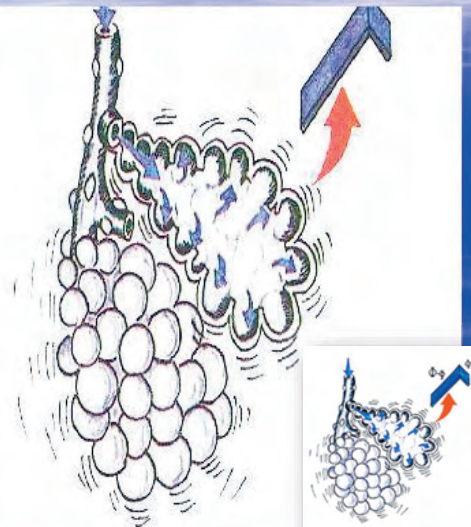
Characteristic	Tracheal	Bronchial	Bronchovesicular	Vesicular
Intensity	Very loud	Loud	Moderate	Soft
Pitch	Very high	High	Moderate	Low
I:E ratio*	1:1	1:3	1:1	3:1
Description	Harsh	Tubular	Rustling but tubular	Gentle rustling
Normal locations	Extrathoracic trachea	Manubrium	Over mainstem bronchi	Most of peripheral lung

\*Ratio of duration of inspiration to that of expiration.

	Duration of Sounds	Intensity of Expiratory Sound	Pitch of Expiratory Sound	Locations Where Heard Normally
<b>Vesicular*</b> 	Inspiratory sounds last longer than expiratory sounds.	Soft	Relatively low	Over most of both lungs
<b>Broncho-vesicular</b> 	Inspiratory and expiratory sounds are about equal.	Intermediate	Intermediate	Often in the 1st and 2nd interspaces anteriorly and between the scapulae
<b>Bronchial</b> 	Expiratory sounds last longer than inspiratory ones.	Loud	Relatively high	Over the manubrium, (larger proximal airways)
<b>Tracheal</b> 	Inspiratory and expiratory sounds are about equal.	Very loud	Relatively high	Over the trachea in the neck



## Vesicular (Alveolar) Breath Sounds

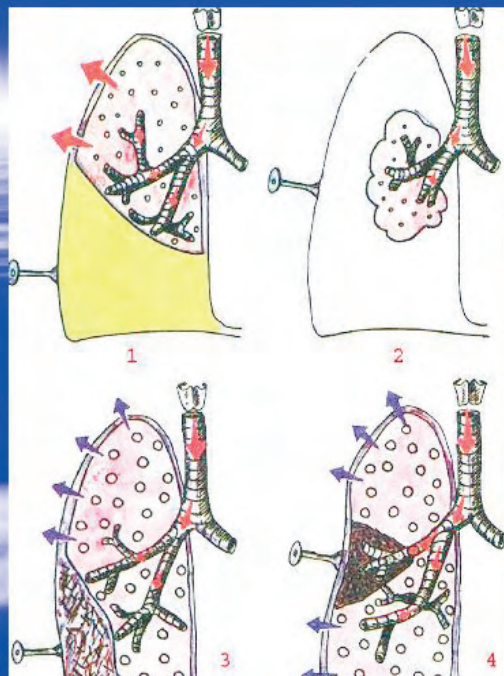
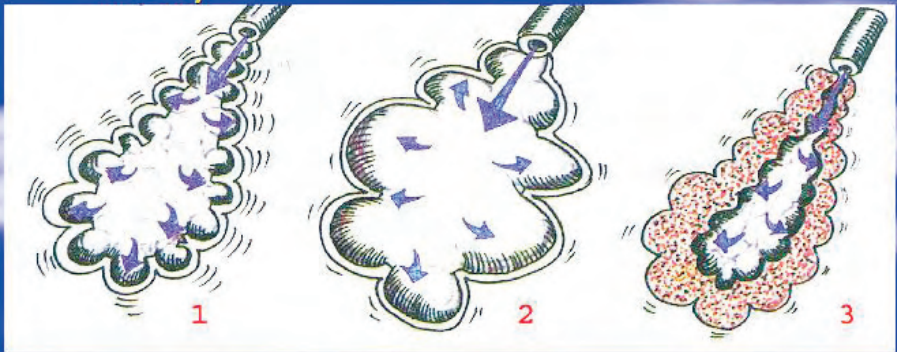


### Mechanism of the occurrence

- \* They arise due to vibration of the alveolar walls during their filling with air in inspiration.
- \* Summation of these sounds gives long soft (blowing) sound.

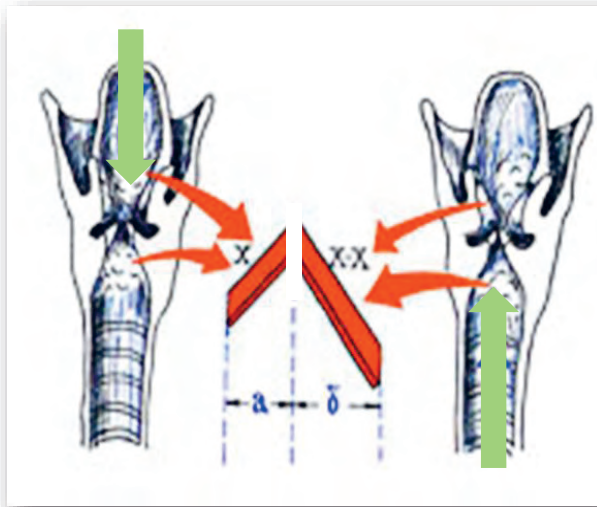
## Reasons Of Pathological Diminished Vesicular Breath Sounds

1. Emphysema (decreased elasticity of alveoli)
2. Lobar pneumonia at I and III stages
3. Oedema of the lungs ( swelling of alveolar walls)



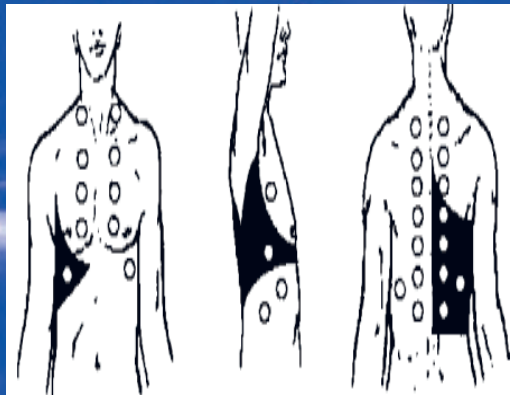
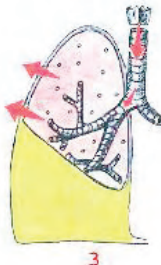
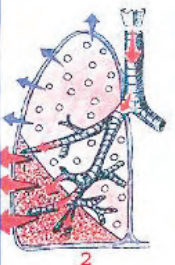

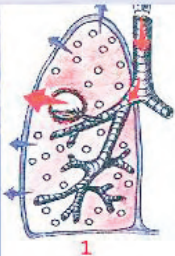
4. Accumulation of fluid in pleural cavity ( pleural effusion-hydrothorax, exudative pleurisy) or air (pneumothorax)
5. Pneumofibrosis
6. Incomplete obstructive atelectasis ( by a tumour)
7. Pleural thickening ( adhesion)

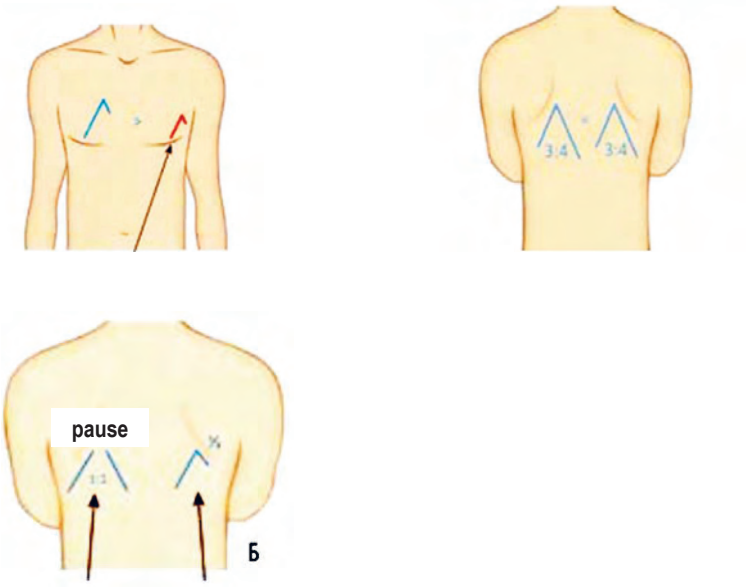
## Bronchial respiration



### Conditions for Occurrence of Pathological Bronchial Breath Sounds:

1. Free passage in bronchi
2. Consolidation of lung tissue





### ADVENTITIOUS (ADDED) LUNG SOUNDS

**Crackles**

Inspiration Expiration

**Wheezes and Rhonchi**

**Stridor**

**Pleural Rub**



## Adventitious or Added Breath Sounds



### Crackles (or Rales)

- ▶ **Discontinuous**
- ▶ Intermittent, nonmusical, and brief
- ▶ Like dots in time
- ▶ *Fine crackles*: soft, high-pitched, very brief (5–10 msec)
- ▶ *Coarse crackles*: somewhat louder, lower in pitch, brief (20–30 msec)

• • • • •

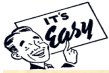• • • • •

### Wheezes and Rhonchi

- ▶ **Continuous**
- ▶  $\geq 250$  msec, musical, prolonged (but not necessarily persisting throughout the respiratory cycle)
- ▶ Like dashes in time
- ▶ *Wheezes*: relatively high-pitched ( $\geq 400$  Hz) with hissing or shrill quality
- ▶ *Rhonchi*: relatively low-pitched ( $\leq 200$  Hz) with snoring quality

~~~~~

~~~~~



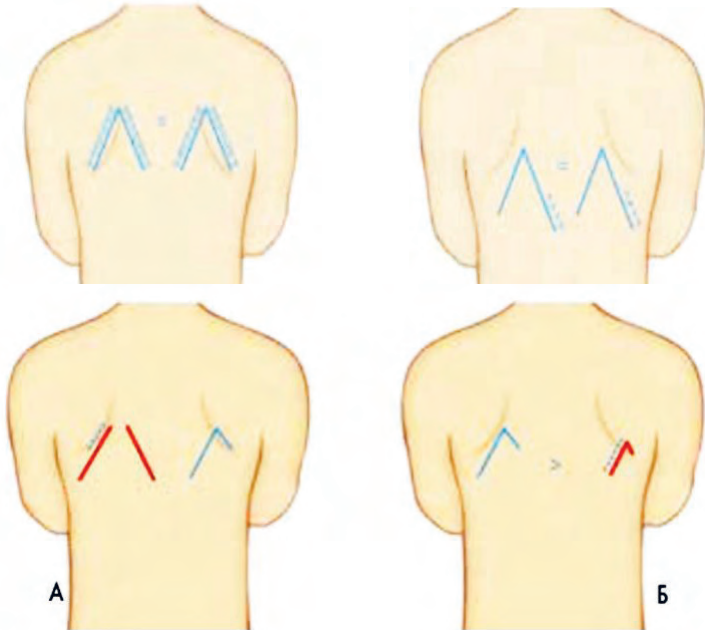
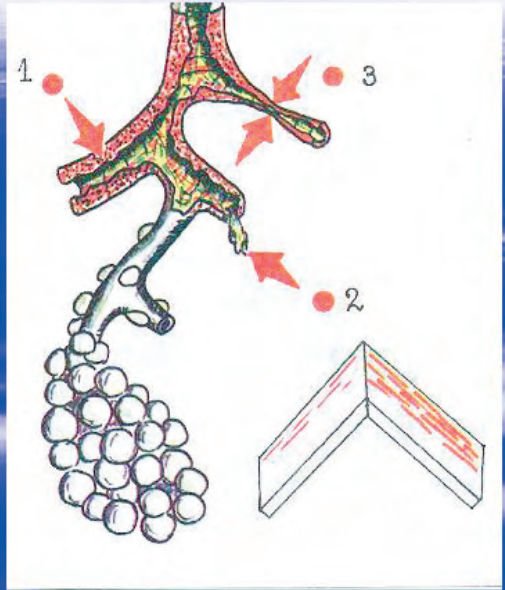
### Adventitious Sounds

Recommended Term	Older Term	Mechanism	Causes
Crackle	Rale Crepitation	Excess airway secretions	Bronchitis, respiratory infections, pulmonary edema, atelectasis, fibrosis, congestive heart failure
Wheeze	Sibilant rale Musical rale Sonorous rale Low-pitched wheeze	Rapid airflow through obstructed airway	Asthma, pulmonary edema, bronchitis, congestive heart failure
Rhonchus		Transient airway plugging	Bronchitis
Pleural rub		Inflammation of the pleura	Pneumonia, pulmonary infarction

# Rhonchi:

## Mechanism of their occurrence:

- 1. Swelling of the bronchial mucosa
- 2. Accumulation of viscous sputum in the bronchi
- 3. Constriction of lumen in the bronchi  
*(spasm of smooth muscles of the bronchi)*

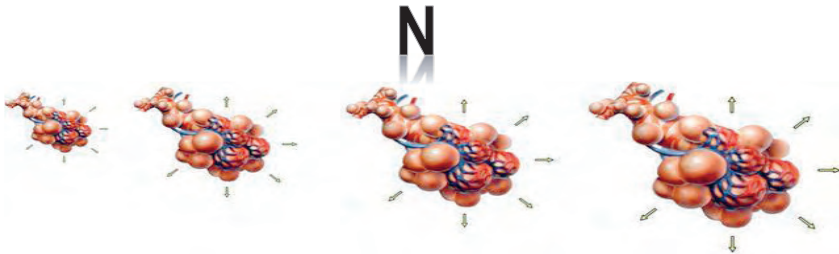
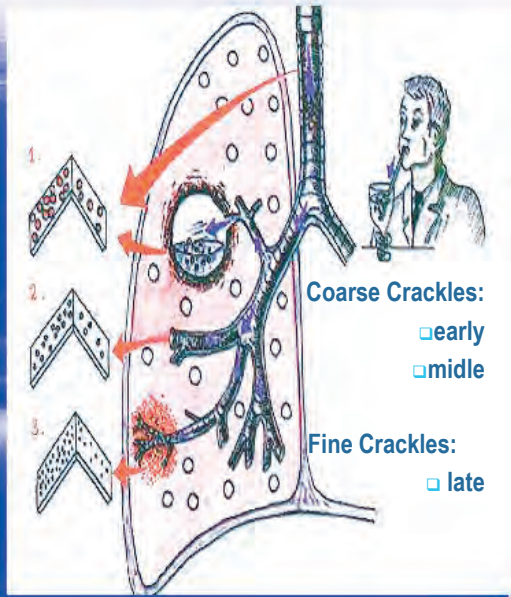


# Crackles

## Mechanism of occurrence:

\* Accumulation of liquid secretion ( watery sputum , pus, blood) in bronchi or cavities through which air passes

\* Air bubbles pass through the fluid and produce specific cracking sound on surface of a fluid  
If it is cavity it must communicate with bronchus



CREPITATION

=

Fine Crackles !!!





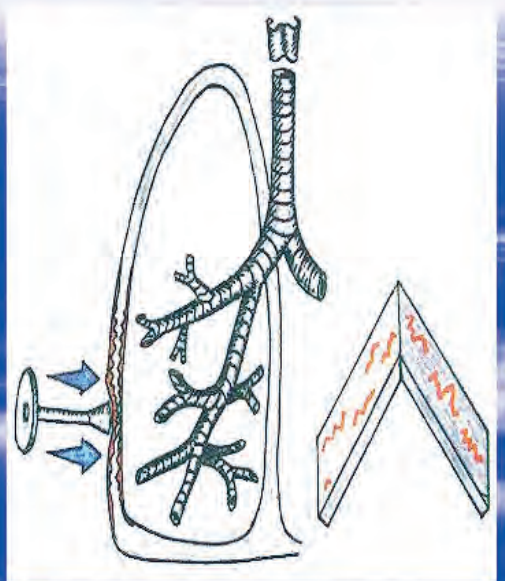
Timing of Common Inspiratory Crackles

Disease	Early Crackle	Late Crackle
Congestive heart failure	Very common	Common
Obstructive lung disease	Present	Absent
Interstitial fibrosis	Absent	Present
Pneumonia	Absent	Present

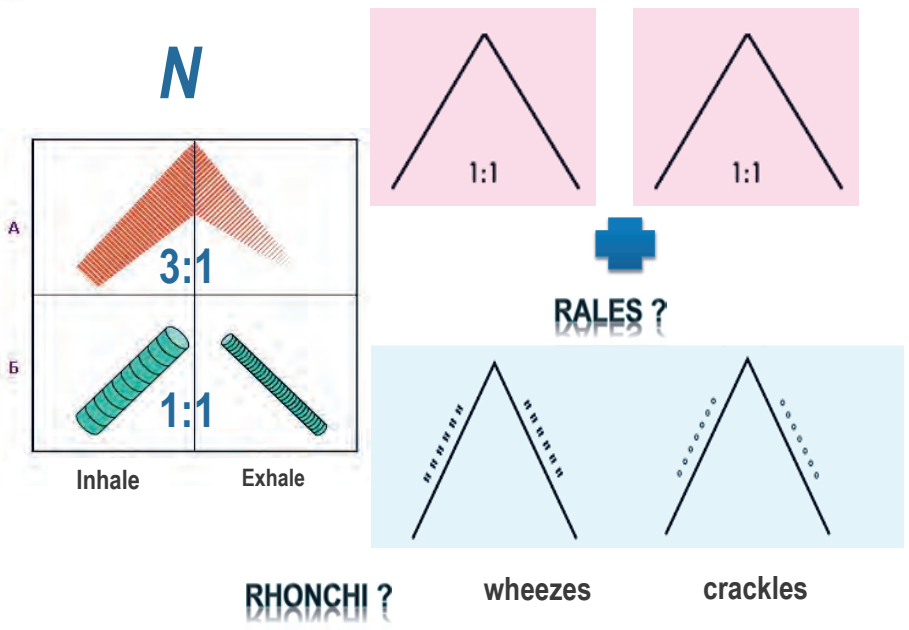
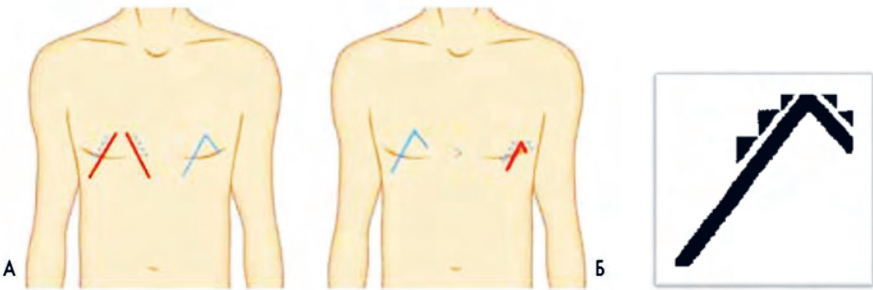
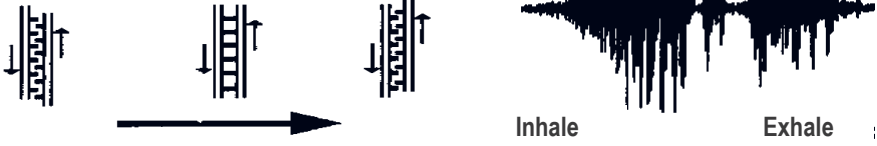**Pleural Rub:**

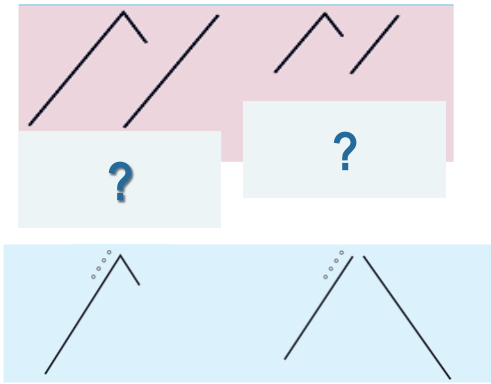
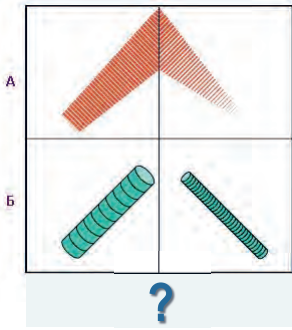
**Mechanism of occurrence:**

1. Fibrin is deposited in inflamed pleura to make its surface rough (dry pleurisy)
2. Commissures, bands between pleural layers
3. Tubercles on layers in tbs, tumours, metastasis, carcinomatosis of pleura
4. Dryness of pleural layers (severe dehydration)



# Pleural RUB





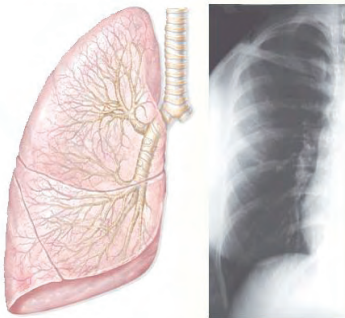
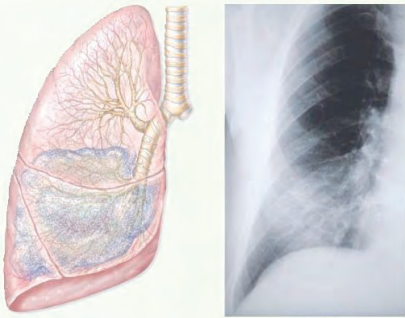
**Crepitation=late crackles**

**Transmitted Voice Sounds.** If you hear abnormally located bronchovesicular or bronchial breath sounds, assess transmitted voice sounds. With a **stethoscope**, listen in symmetric areas over the chest wall as you assess any abnormal vocal resonances suspicious for pneumonia or pleural effusion.

- Ask the patient to say **“ninety-nine.”** Normally the sounds transmitted through the chest wall are muffled and indistinct. Louder voice sounds are called *bronchophony*.
- Ask the patient to say **“ee.”** You will normally hear a muffled long E sound.
- Ask the patient to **whisper “ninety-nine” or “one-two-three.”** The whispered voice is normally heard faintly and indistinctly, if at all.

Louder, clearer whispered sounds are called *whispered pectoriloquy*.

If “ee” sounds like “A,” an **E-to-A** change, or **egophony**, is present, seen in lobar consolidation from *pneumonia*. The “A” has a nasal bleating quality, and should be localized. In patients with fever and cough, the presence of bronchial breath sounds and egophony more than triples the likelihood of pneumonia.<sup>22</sup>

	Normal Air-Filled Lung	Airless Lung, as in Lobar Pneumonia
		
<b>Breath Sounds</b>	Predominantly vesicular	Bronchial or bronchovesicular over the involved area
<b>Transmitted Voice Sounds</b>	Spoken words muffled and indistinct Spoken "ee" heard as "ee" Whispered words faint and indistinct, if heard at all	Spoken words louder ( <i>bronchophony</i> ) Spoken "ee" heard as "ay" ( <i>egophony</i> ) Whispered words louder, clearer ( <i>whispered pectoriloquy</i> )
<b>Tactile Fremitus</b>	Normal	Increased

## ADVENTITIOUS (ADDED) LUNG SOUNDS

**Crackles**

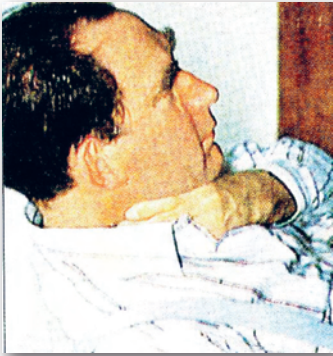Inspiration Expiration

**Wheezes and Rhonchi**

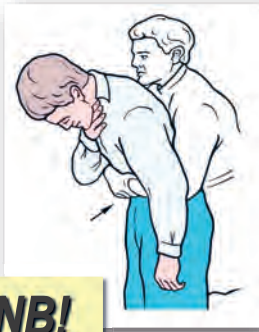**Stridor**

**Pleural Rub**

Stridor

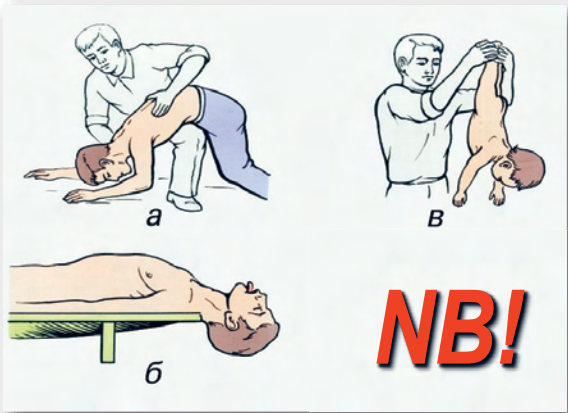


Self-help

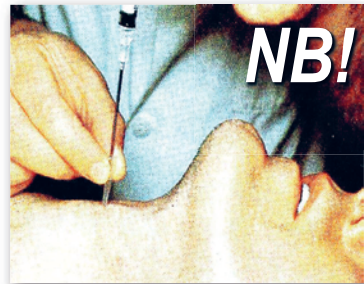

**NB!**

Heimlich method



**NB!**



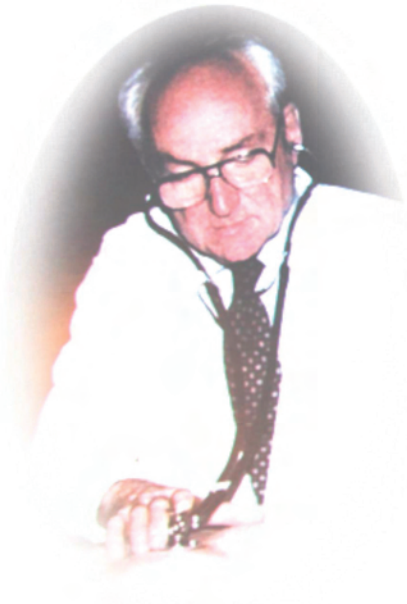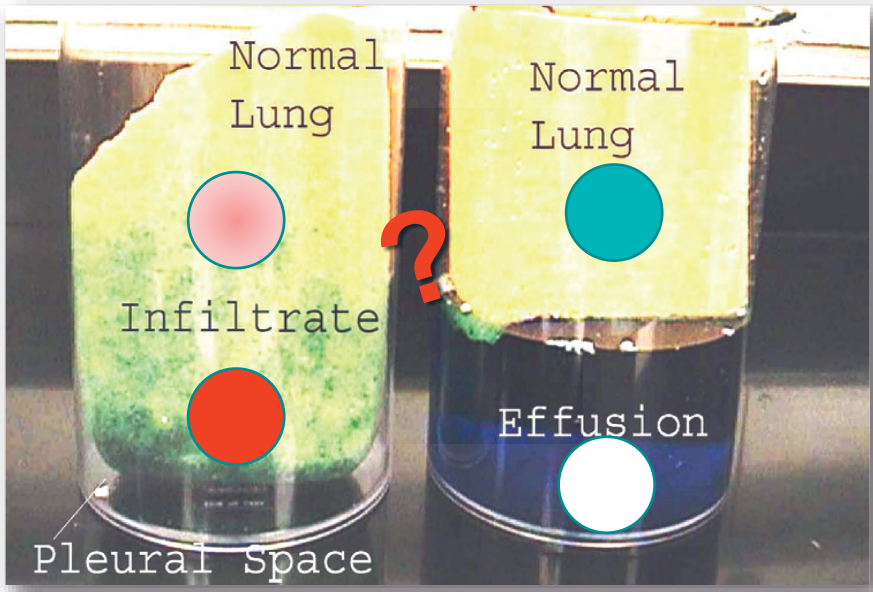


## Physical Findings in Selected Chest Disorders

Condition	Percussion Note	Trachea	Breath Sounds	Adventitious Sounds	Tactile Fremitus and Transmitted Voice Sounds
<p><b>Normal</b> The tracheobronchial tree and alveoli are clear; pleurae are thin and close together; mobility of the chest wall is unimpaired.</p>	Resonant	Midline	Vesicular, except perhaps bronchovesicular and bronchial sounds over the large bronchi and trachea, respectively	None, except perhaps a few transient inspiratory crackles at the bases of the lungs	Normal
<p><b>Chronic Bronchitis</b> The bronchi are chronically inflamed and a productive cough is present. Airway obstruction may develop.</p>	Resonant	Midline	Vesicular (normal)	None; or scattered coarse crackles in early inspiration and perhaps expiration; or wheezes or rhonchi	Normal
<p><b>Left-Sided Heart Failure (Early)</b> Increased pressure in the pulmonary veins causes congestion and interstitial edema (around the alveoli); bronchial mucosa may become edematous.</p>	Resonant	Midline	Vesicular	Late inspiratory crackles in the dependent portions of the lungs; possibly wheezes	Normal
<p><b>Consolidation</b> Alveoli fill with fluid or blood cells, as in pneumonia, pulmonary edema, or pulmonary hemorrhage.</p>	Dull over the airless area	Midline	<p>Brachial over the involved area</p>	Late inspiratory crackles over the involved area	Increased over the involved area, with bronchophony, egophony, and whispered pectoriloquy
<p><b>Atelectasis (Lobar Obstruction)</b> When a plug in a mainstem bronchus (as from mucus or a foreign object) obstructs air flow, affected lung tissue collapses into an airless state.</p>	Dull over the airless area	May be shifted toward involved side	Usually absent when bronchial plug persists. Exceptions include right upper lobe atelectasis, where adjacent tracheal sounds may be transmitted.	None	Usually absent when the bronchial plug persists. In exceptions (e.g., right upper lobe atelectasis) may be increased

## Physical Findings in Selected Chest Disorders

Condition	Percussion Note	Trachea	Breath Sounds	Adventitious Sounds	Tactile Fremitus and Transmitted Voice Sounds
<p><b>Pleural Effusion</b> Fluid accumulates in the pleural space, separates air-filled lung from the chest wall, blocking the transmission of sound.</p>	Dull to flat over the fluid	Shifted toward opposite side in a large effusion	Decreased to absent, but bronchial breath sounds may be heard near top of large effusion.	None, except a possible pleural rub	Decreased to absent, but may be increased toward the top of a large effusion
<p><b>Pneumothorax</b> When air leaks into the pleural space, usually unilaterally, the lung recoils from the chest wall. Pleural air blocks transmission of sound.</p>	Hyperresonant or tympanic over the pleural air	Shifted toward opposite side if much air	Decreased to absent over the pleural air	None, except a possible pleural rub	Decreased to absent over the pleural air
<p><b>Chronic Obstructive Pulmonary Disease (COPD)</b> Slowly progressive disorder in which the distal air spaces enlarge and lungs become hyperinflated. Chronic bronchitis is often associated.</p>	Diffusely hyperresonant	Midline	Decreased to absent	None, or the crackles, wheezes, and rhonchi of associated chronic bronchitis	Decreased
<p><b>Asthma</b> Widespread narrowing of the tracheobronchial tree diminishes air flow to a fluctuating degree. During attacks, air flow decreases further, and lungs hyperinflate.</p>	Resonant to diffusely hyperresonant	Midline	Often obscured by wheezes	Wheezes, possibly crackles	Decreased



***"Your ears are better than any test and don't cost the patient a cent."***

*Dr. Harvey*

## REFERENCES

- Kovalyova O.N., Ashcheulova T.V. Propedeutics to Internal Medicine. Part 1. – Vinnytsya: NOVA KNYHA, 2017. – 424 p.
- Kovalyova O.N., Asheulova T.V. General inspection: manual for students. – Kharkov: “Turbo”. – 2004. – 60p.
- Khomazjuk V.A., Ostashevskaya T.G., Krasnyuk I.V. Propaedeutics of Internal Medicine and Patient Care: Study guide for the practical classes. Part I. – Kyiv: NMU, 2005. – 44 p.
- Kovalyova O.N., Asheulova T.V. Diagnostics of respiratory organs disease: manual for students. – Kharkov: “Turbo”. – 2004. – 64p.
- Bickley, Lynn S.; Szilagy, Peter G. Bates' Guide to Physical Examination and History Taking, 10th Edition. -934p. Copyright ©2009 Lippincott Williams & Wilkins
- The Point online resources, <http://thepoint.lww.com>


LECTURE # **4**

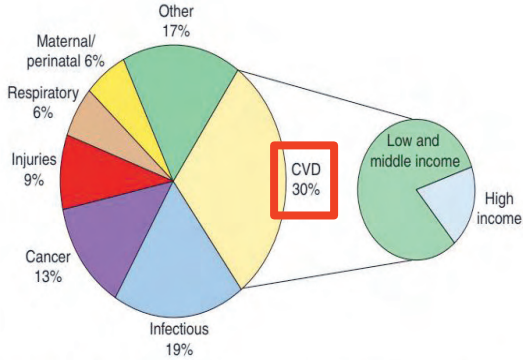
**SYMPTOMS AND SIGNS  
OF HEART DISEASES BASED ON A SURVEY,  
PALPATION, PERCUSSION**

## THE PLAN

- Introduction – CVD over the World, CV Continuum
- Risk Factors
- Morbidity related to CVD
- Stratification CV Risk: SCORECARD
- Cardinal symptoms of CVD
- Chest Pain
- Palpitation
- Dyspnea (clinical types)
- Edema
- Clinical sings of CVD (general survey, local inspection, palpation, percussion, auscultation)
- Subclinical damage of Target organs
- New methods to detect "asymptomatic" individuals with a high degree risk of cardiovascular events
- References

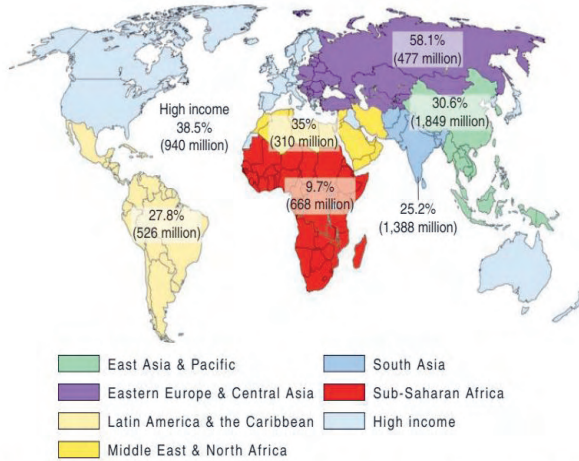
### The burden of cardiovascular disease





**CVD data compared with other causes of death.** CVD: cardiovascular disease. (Based on data from CD Mathers et al: Deaths and Disease Burden by Cause: Global Burden of Disease Estimates for 2001 by

World Bank Country Groups. Disease Control Priorities Working Paper 18. April 2004, revised January 2005.)

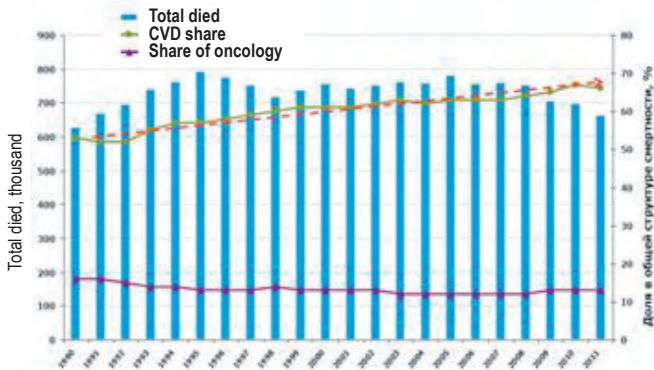


**CVD death as a percentage of total deaths** and total population in seven economic regions of the world defined by the World Bank (Based on data from CD Mathers et al: Deaths and Disease Burden by

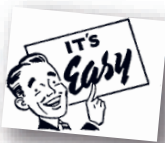Cause: Global Burden of Disease Estimates for 2001 by World Bank Country Groups. Disease Control Priorities Working Paper 18. April 2004, revised January 2005.)



## Structure of mortality in Ukraine from various causes, thousands of people



State Committee of Statistics of Ukraine



### Estimated Morbidity Related to Heart Disease: 2010-2030

Deaths	By 2010	By 2030
CVD deaths: annual number of all deaths	18.1 million	24.2 million
CVD deaths: percentage of all deaths	30.8%	32.5%
CHD deaths: percentage of all male deaths	13.1%	14.9%
CHD deaths: percentage of all female deaths	13.6%	13.1%
Stroke deaths: percentage of all male deaths	9.2%	10.4%
Stroke deaths: percentage of all female deaths	11.5%	11.8%

**Abbreviations:** CHD, coronary heart disease; CVD, cardiovascular disease.

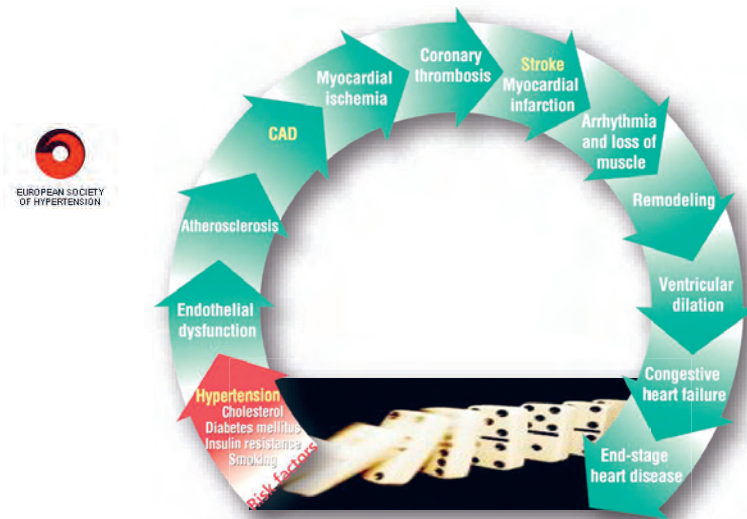
**Source:** Adapted from J Mackay, G Mensah: *Atlas of Heart Disease and Stroke*. Geneva, World Health Organization, 2004.

## Cost/year of cardiovascular disease in EU (billion euros)

- Total costs 169 billion
- Direct health care cost 105 billion
  - Hospital care 63 billion (~62%)
- Productivity losses 35.5 billion
- Informal care 19.5 billion
- Medications 18.4 billion

Leoni J, et al. Eur Heart J 2006

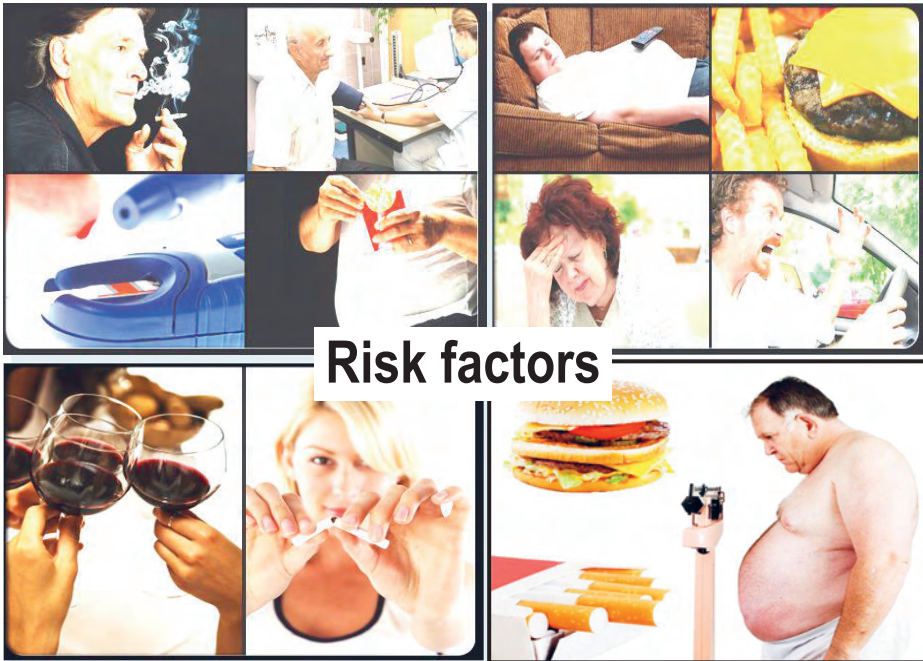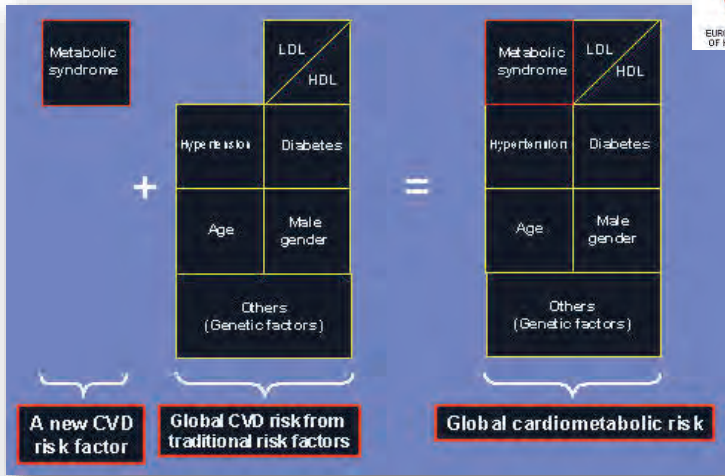
## Cardiovascular CONTINUUM



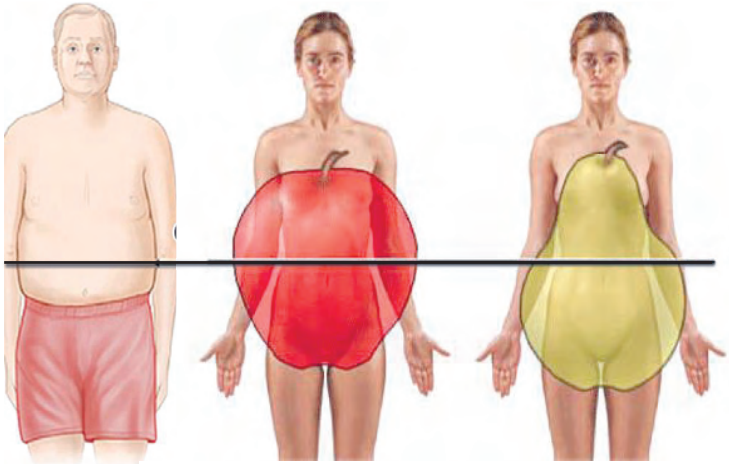
JE Deanfield Circulation 2007;115:1285-1295  
Adapted from Dart AM and Kingwell BA. J Am Coll Cardiol. 2001;37:975-84.



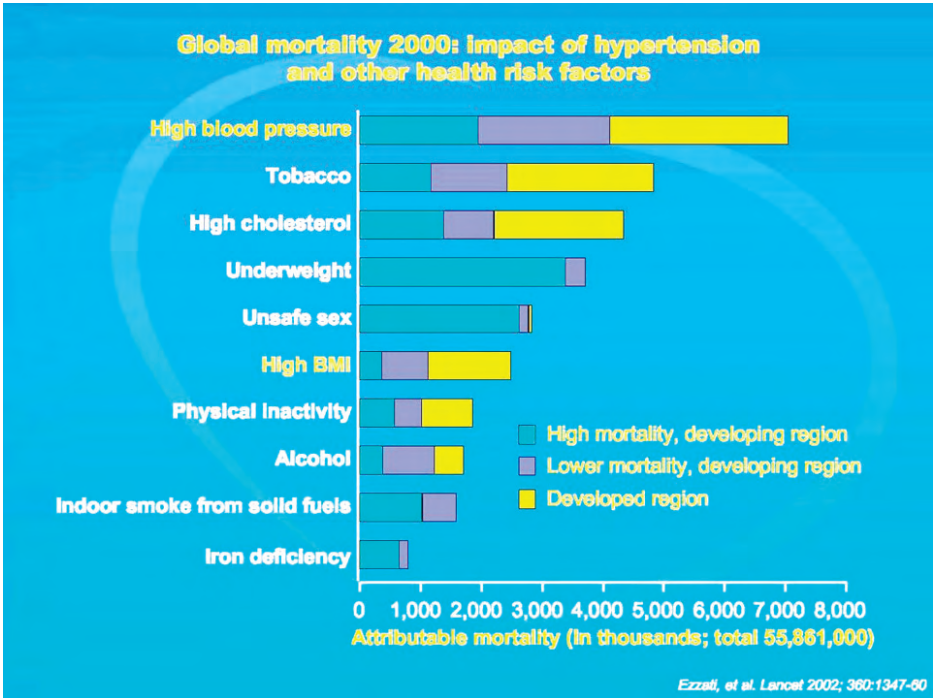
# Risk factors



# Risk factors



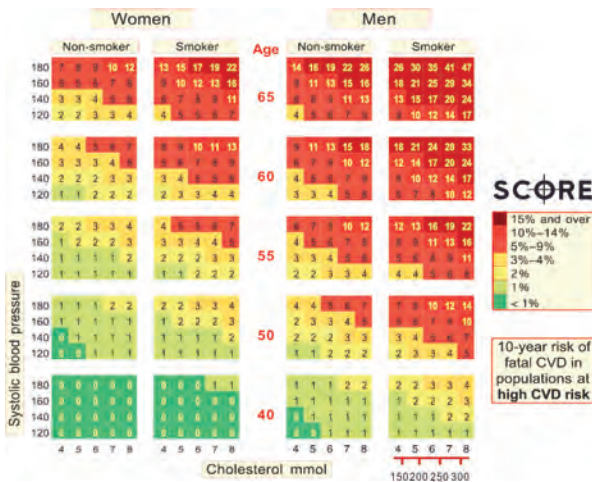
Abdominal (visceral) obesity



## Major Cardiovascular Risk Factors and Screening Frequency


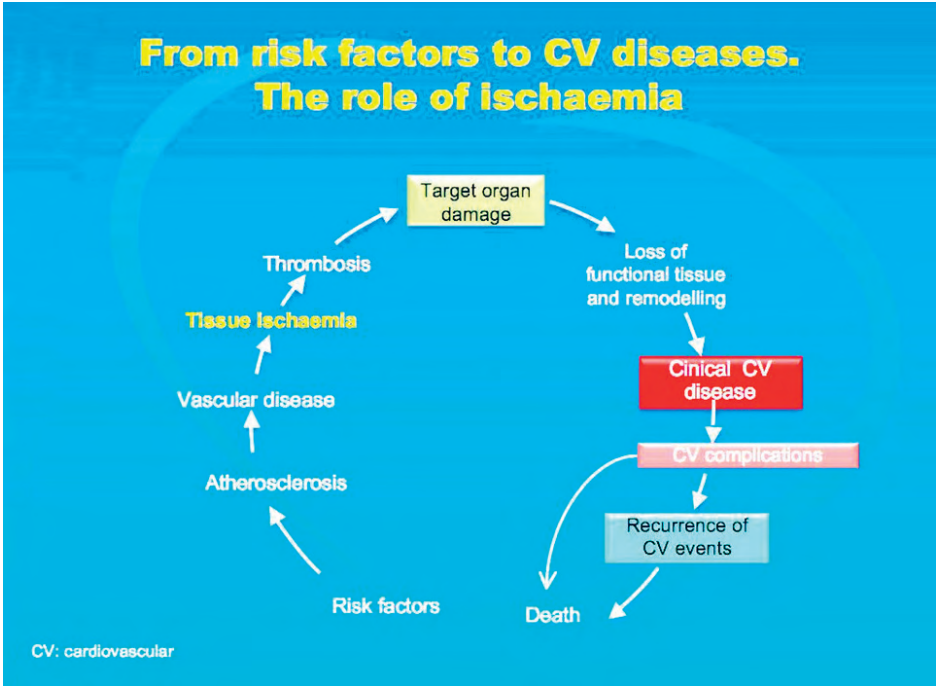
Risk Factor	Screening Frequency	Goal
Family history of premature CVD (at age <55 years in first-degree male relatives and <65 years in first-degree female relatives)	Update regularly	
Cigarette smoking	At each visit	Cessation
Poor diet	At each visit	Improved overall eating pattern
Physical inactivity	At each visit	30 min moderate intensity daily
Obesity, especially central adiposity	At each visit	BMI 20–25 kg/m <sup>2</sup> ; waist circumference 40 inches in men, ≤35 inches in women
Hypertension	At each visit	<140/90 <135/85 if African American with HTN and without end-organ or CVD <130/80 if diabetes or African American with HTN and end-organ or CVD <125/75 if renal disease
Dyslipidemias	Every 5 years if low risk Every 2 years if risk factors	See ATP III guidelines
Diabetes	Every 3 years beginning at age 45 More frequently at any age if risk factors	HgA <sub>1c</sub> ≥6.5%, at risk if 5.7%–6.4%
Pulse	At each visit	Identify and treat atrial fibrillation

## Stratification CVR: SCORECARD



- ▶ Screening for cardiovascular risk factors
  - ▶ Step 1: Screen for global risk factors
  - ▶ Step 2: Calculate 10-year and long-term CVD risk using online calculators
  - ▶ Step 3: Track individual risk factors—hypertension, diabetes, dyslipidemias, metabolic syndrome, smoking, family history and obesity
- ▶ Promoting lifestyle modification and risk factor reduction

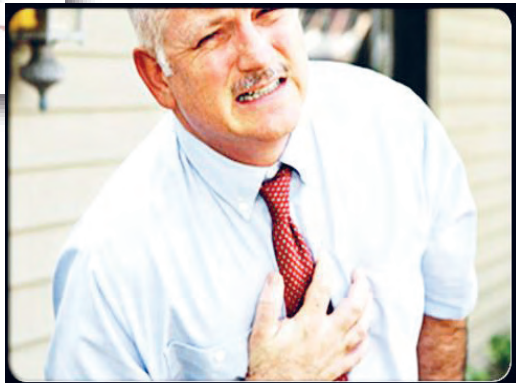# From risk factors to CV diseases. The role of ischaemia





## CARDINAL SYMPTOMS OF CARIOVASCULAR DISEASE

- ❑ Chest pain or discomfort
- ❑ Dyspnea, ortopnea, paroxysmal nocturnal dyspnea, wheezing
- ❑ Palpitations, dizziness, syncope
- ❑ Cough, hemoptysis
- ❑ Fatigue, weakness
- ❑ Pain in extremities with exertion (claudication)

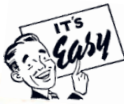



Characteristics of Chest Pain\*

Feature	Angina	Not Angina
Location	Retrosternal, diffuse	Left inframammary, localized
Radiation	Left arm, jaw, back	Right arm
Description	"Aching," "dull," "pressing," "squeezing," "viselike"	"Sharp," "shooting," "cutting"
Intensity	Mild to severe	Excruciating
Duration	Minutes	Seconds, hours, days
Precipitated by	Effort, emotion, eating, cold	Respiration, posture, motion
Relieved by	Rest, nitroglycerin	Nonspecific

\*Angina and other chest pain may manifest in a variety of ways. The characteristics listed here are the common manifestations. This list, however, is not exhaustive and should be used only as a guide.

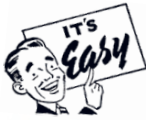

Common Causes of Chest Pain

Organ System	Cause
Cardiac	Coronary artery disease Aortic valvular disease Pulmonary hypertension Mitral valve prolapse Pericarditis Idiopathic hypertrophic subaortic stenosis
Vascular	Dissection of the aorta
Pulmonary	Pulmonary embolism Pneumonia Pleuritis Pneumothorax
Musculoskeletal	Costochondritis* Arthritis Muscular spasm Bone tumor
Neural	Herpes zoster†
Gastrointestinal	Ulcer disease Bowel disease Hiatal hernia Pancreatitis Cholecystitis
Emotional	Anxiety Depression

\*Tietze's syndrome, which is an inflammation of the costal cartilages.

†Shingles, which is a viral invasion of the peripheral nerves in a dermatomal distribution.




## New York Heart Association Functional Classification

Class I	Class III
No limitation of physical activity	Marked limitation of physical activity
No symptoms with ordinary exertion	Less than ordinary activity causes symptoms
Class II	Asymptomatic at rest
Slight limitation of physical activity	Class IV
Ordinary activity causes symptoms	Inability to carry out any physical activity without discomfort
	Symptoms at rest

*Source:* Modified from The Criteria Committee of the New York Heart Association.

"I've got heart failure and this is what I feel like every morning"





## SYMPTOMS

- *Palpitations* are an unpleasant awareness of the heartbeat.
- *Shortness of breath* may represent dyspnea, orthopnea, or PND.
  - *Dyspnea* is an uncomfortable awareness of breathing that is inappropriate for a given level of exertion.
  - *Orthopnea* is dyspnea that occurs when the patient is lying down and improves when the patient sits up. It suggests *left ventricular heart failure* or *mitral stenosis*; it also may accompany *obstructive pulmonary disease*.
  - *PND* describes episodes of sudden dyspnea and orthopnea that awaken the patient from sleep, usually 1 to 2 hours after going to bed, prompting the patient to sit up, stand up, or go to a window for air.

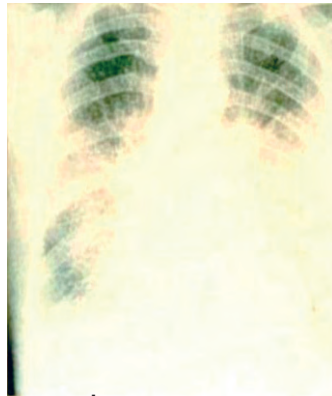



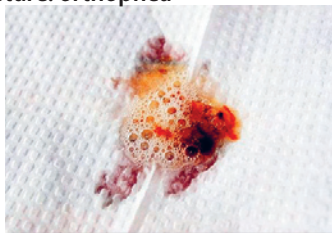
### Common Causes of Dyspnea

Organ System or Condition	Cause
Cardiac	Left ventricular failure Mitral stenosis
Pulmonary	Obstructive lung disease Asthma Restrictive lung disease Pulmonary embolism Pulmonary hypertension
Emotional	Anxiety
High-altitude exposure	Decreased oxygen pressure
Anemia	Decreased oxygen-carrying capacity

## AL HF

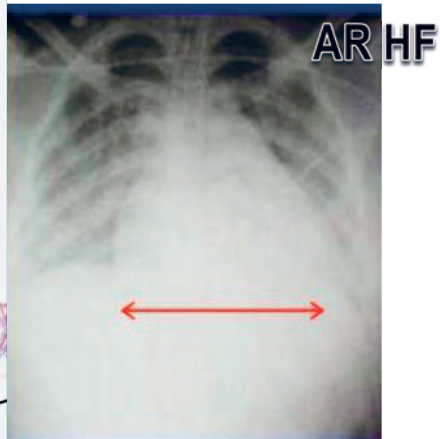
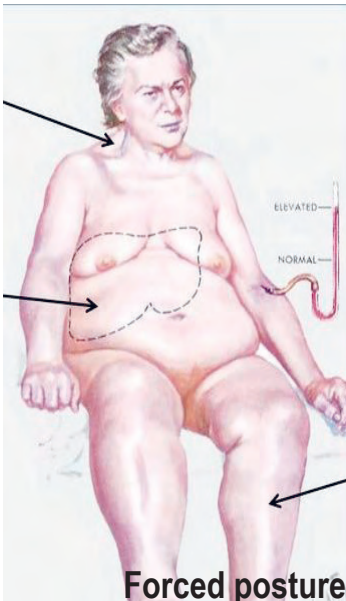


Forced posture: orthopnea

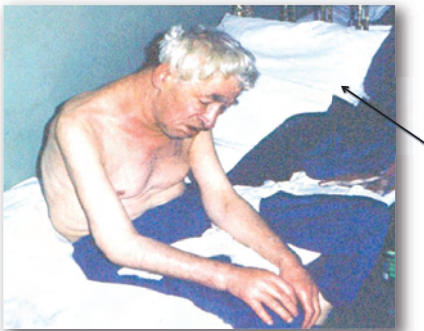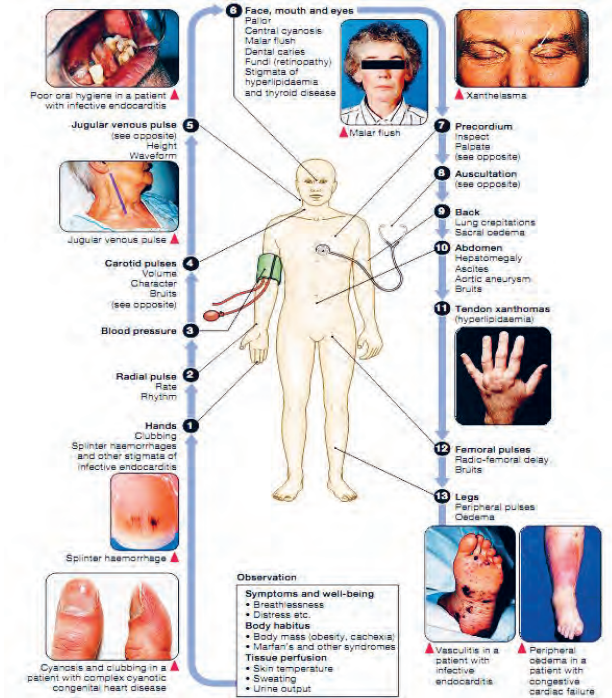


## SYMPTOMS

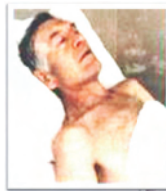- *Palpitations* are an unpleasant awareness of the heartbeat.
  - *Shortness of breath* may represent dyspnea, orthopnea, or PND.
  - *Dyspnea* is an uncomfortable awareness of breathing that is inappropriate for a given level of exertion.
  - *Orthopnea* is dyspnea that occurs when the patient is lying down and improves when the patient sits up. It suggests *left ventricular heart failure* or *mitral stenosis*; it also may accompany *obstructive pulmonary disease*.
  - *PND* describes episodes of sudden dyspnea and orthopnea that awaken the patient from sleep, usually 1 to 2 hours after going to bed, prompting the patient to sit up, stand up, or go to a window for air.
- *Edema* refers to the accumulation of excessive fluid in the interstitial tissue spaces; it appears as swelling. *Dependent edema* appears in the feet and lower legs when sitting or in the sacrum when bedridden.



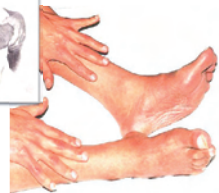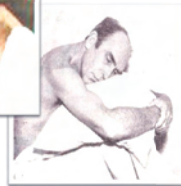**Forced posture: orthopnea**



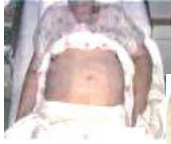Forced posture: orthopnea



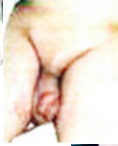Forced posture



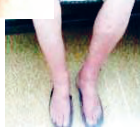Acrocyanosis, swelling of feet



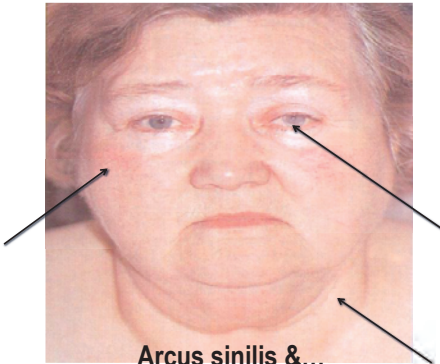
**ANASARCA**



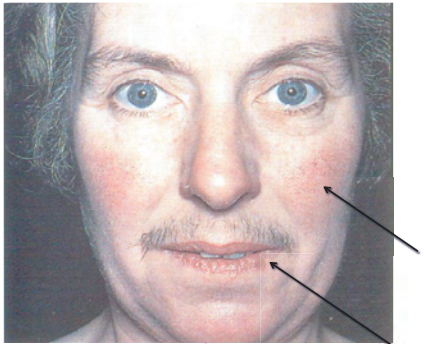
**Cardiac edema**



**Corvizar's face with severe HF**



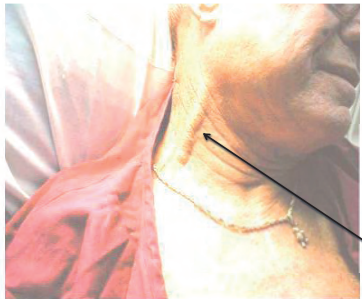**Arcus sinilis &...**



**Mitral face**



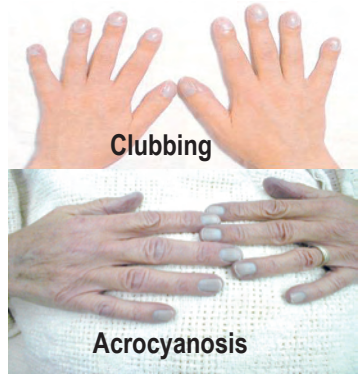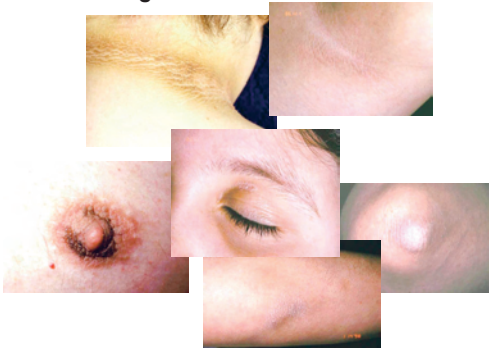**Effects of stroke**



Typical distention of the internal jugular vein.

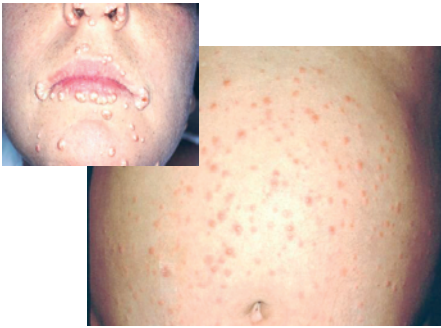
(From [http://courses.cvc.vccs.edu/Wiseman/Dijugular\\_vein\\_distention.htm](http://courses.cvc.vccs.edu/Wiseman/Dijugular_vein_distention.htm))

**Acanthosis nigricans**

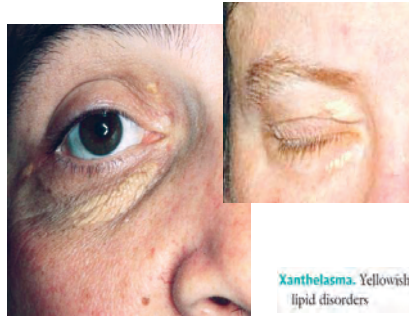


**Clubbing**

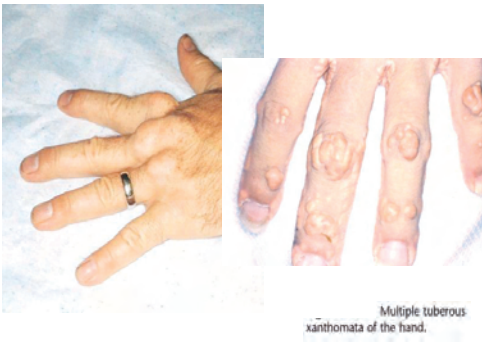**Acrocyanosis**



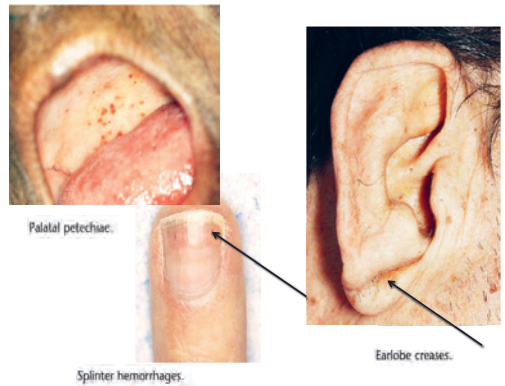
Eruptive xanthomata on the abdomen.



**Xanthelasma.** Yellowish plaque seen in lipid disorders



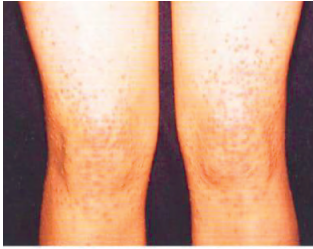Multiple tuberous xanthomata of the hand.



Palatal petechiae.

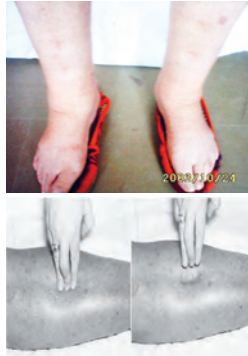Splinter hemorrhages.

Earlobe creases.



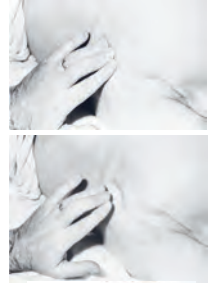Eruptive xanthomas of the extensor surfaces of the lower extremities. This patient had marked hypertriglyceridemia.

(From Massengale WT, Nesbitt LT Jr: Xanthomas. In: Bologna JL, Jorizzo JL, Rapini RP [eds]: Dermatology. Philadelphia, Mosby, 2003, p 1449.)

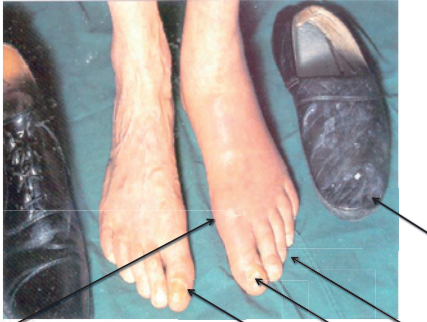

Technique for testing for pitting edema. A. The examiner presses into the patient's shin area. B. When pitting edema is present, indentation occurs after the fingers are lifted.

**Cardiac edema**

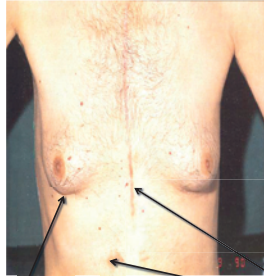


Technique for testing for pitting edema over the sacrum. A. The examiner presses into the sacrum of a bedridden patient. B. The pitting edema is evident.

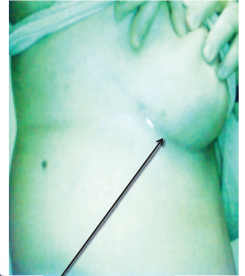


**Gout**

**Additional signs**

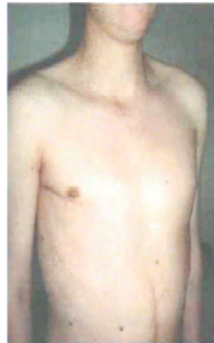
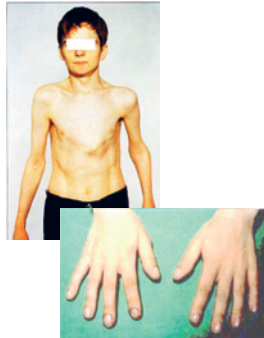
**Gynecomastia**



**Postoperative scars**

**Chest deformity due to congenital heart disease**



### Sequence of the Cardiac Examination

Patient Position	Examination
Supine, with the head elevated 30 degrees	Inspect and palpate the precordium: the 2nd interspaces; the right ventricle; and the left ventricle, including the apical impulse (diameter, location, amplitude, duration).
Left lateral decubitus	Palpate the apical impulse if not previously detected. Listen at the apex with the <i>bell of the stethoscope for low-pitched extra sounds (S<sub>3</sub>, opening snap, diastolic rumble of mitral stenosis).</i>
Supine, with the head elevated 30 degrees	Listen at the 2nd right and left interspaces, along the left sternal border, and across to the apex with the <i>diaphragm</i> . Listen with the bell at the right sternal border for tricuspid murmurs and sounds.
Sitting, leaning forward, after full exhalation	Listen along the left sternal border and at the apex for the soft decrescendo diastolic murmur of <i>aortic insufficiency</i> .

### Sequence of the Cardiac Examination

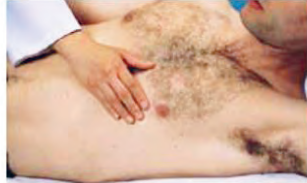Patient Position	Examination
Supine, with the head elevated 30°	Inspect and palpate the precordium: the 2nd interspaces; the right ventricle; and the left ventricle, including the apical impulse (diameter, location, amplitude, duration).
Left lateral decubitus	Palpate the apical impulse if not previously detected.

### Percussion

### Auscultation

### INSPECTION AND PALPATION

Inspect and palpate the anterior chest for heaves, lifts, or thrills.



Identify the *apical impulse*. Turn patient to left as necessary. Note:

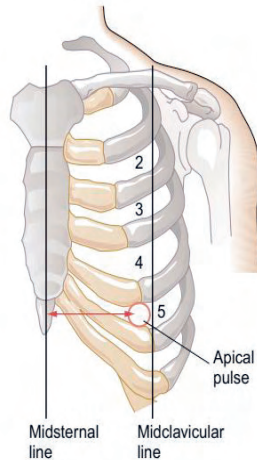
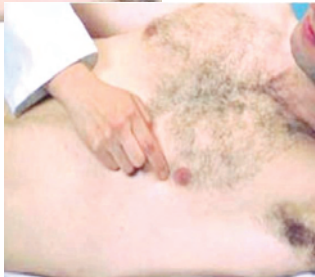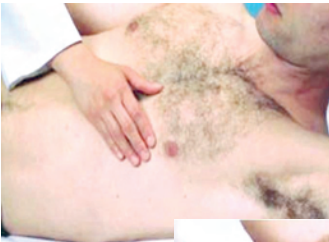- Location of impulse
- Diameter
- Amplitude—usually *tapping*
- Duration

Displaced to left in pregnancy

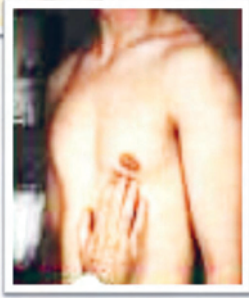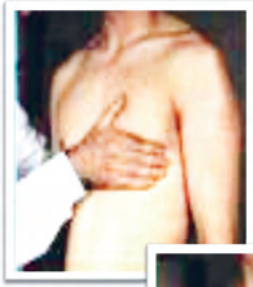Increased diameter, amplitude, and duration in left ventricular dilatation from congestive heart failure (CHF) or ischemic cardiomyopathy

Sustained in left ventricular hypertrophy; diffuse in CHF

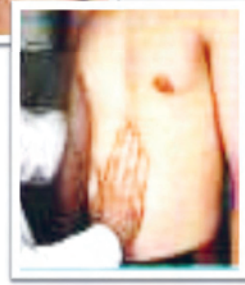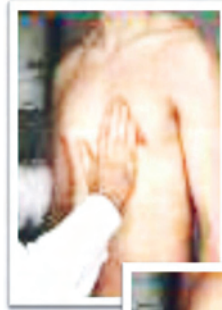### Definition of apical impulse





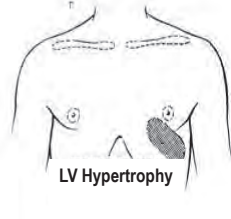
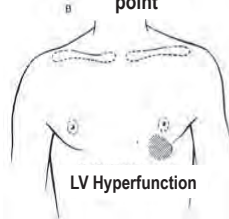
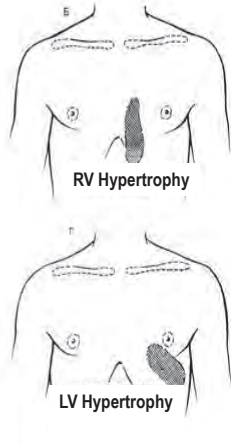
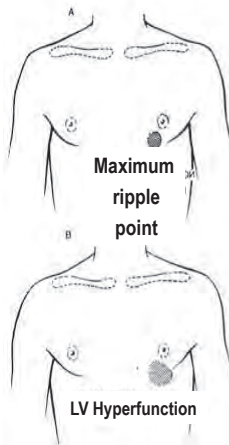
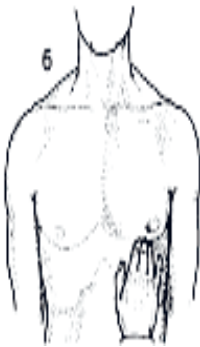
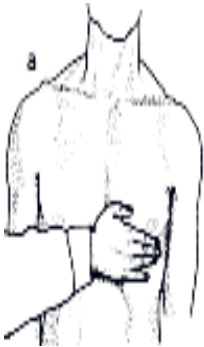

Definition of apical impulse

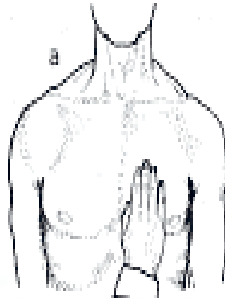


Definition of heart impulse

Definition of apical impulse



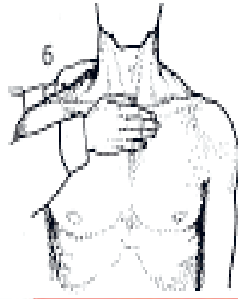
Types of pathology



**EXAMINATION TECHNIQUES**

Feel for a right ventricular impulse in left parasternal and epigastric areas.

Palpate left and right second interspaces close to sternum. Note any thrills in these areas.

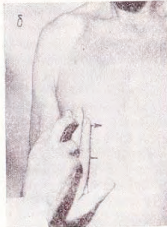
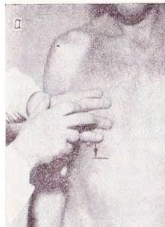
**POSSIBLE FINDINGS**

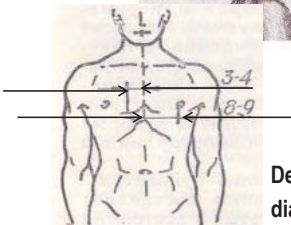
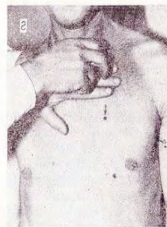
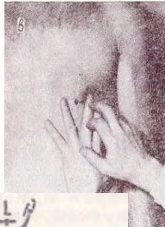Prominent impulses suggest right ventricular enlargement.

Pulsations of great vessels; accentuated S<sub>2</sub>; thrills of aortic or pulmonic stenosis

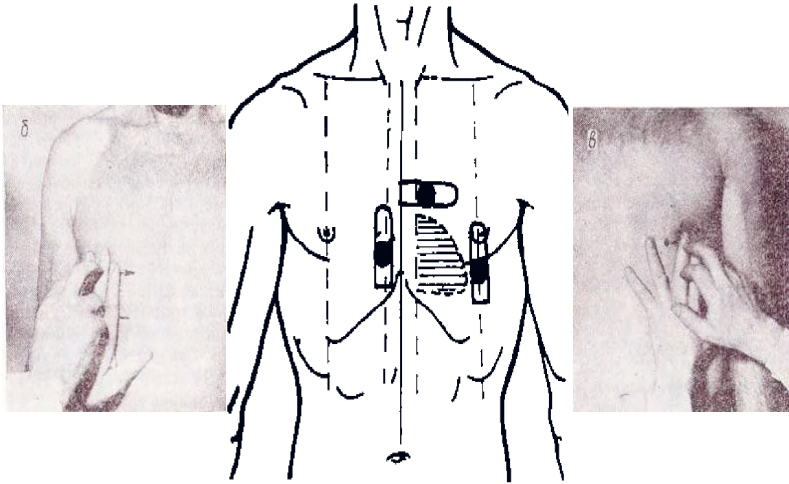
«Cat's purr»...



Determination of the relative dullness of the heart borders

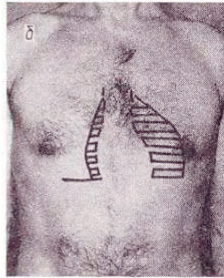
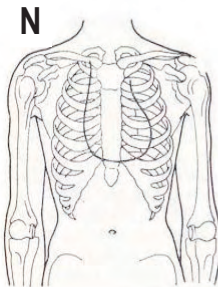


Determination of the diameter of the heart

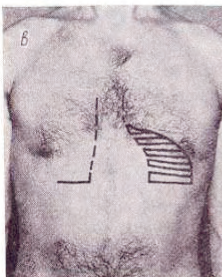


Determination of the absolute dullness of the heart borders

## Shape of the heart



Mitral



Aortic



## **MAIN SYNDROMS OF CARIOVASCULAR DISEASE**

- CORONARY SYNDROM**
- Cardiac Arrhythmias SYNDROM**
- Arterial Hypertension**
- Pulmonary Hypertension**
- Valvular Heart Disease**
- Heart Failue**
- Peripheral Arterial Disease**
- Peripheral VenousDisease**

## **Target organs Subclinical damage**

- The determining factor cardiovascular risk
- Determine the stage of development of the disease in the context of the cardiovascular continuum

## Target organs Subclinical damage

- heart
  - ECG (LVH, overload, ischemia, arrhythmias)
  - Echocardiography (concentric type of LVH, DD)
- blood vessels
  - Ultrasound of the carotid arteries
  - Pulse wave velocity
  - The ankle-brachial index
- kidneys
  - The glomerular filtration rate
  - Creatinine clearance
  - Albumin in the urine (test strips, rapid test)
- fundoscopy
- brain
  - MRI, CT (latent infarction, lacunar infarctions, microbleeds, damage white substance)
  - Cognitive tests in the elderly

## Additional markers of Target organs damage (Study)

- The calcium content in the blood vessels of the heart
- The qualitative composition of the cardiac / vascular tissue
- Circulating markers of collagen
- Endothelial dysfunction
- Brain gaps / white matter lesions of the brain

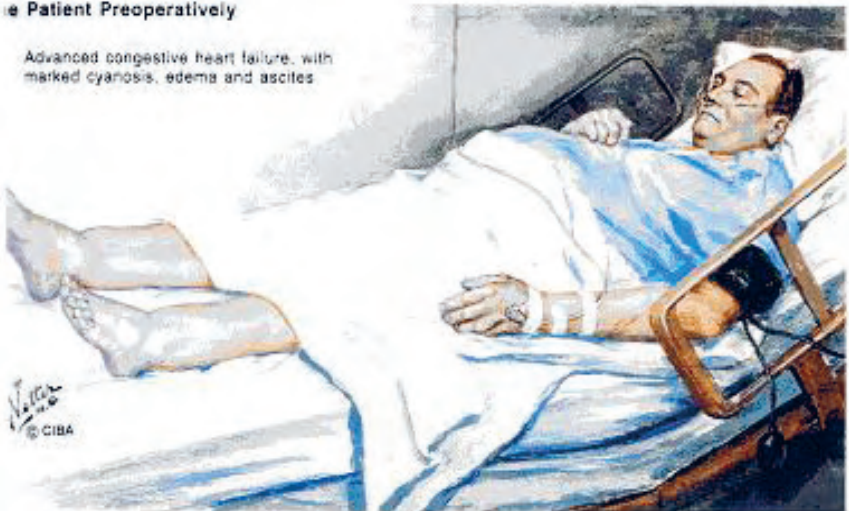
## New methods to detect "asymptomatic" individuals with a high degree risk of cardiovascular events



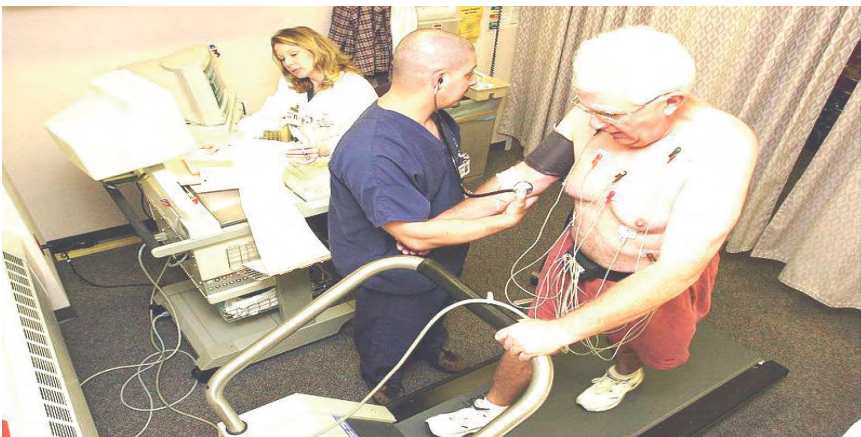
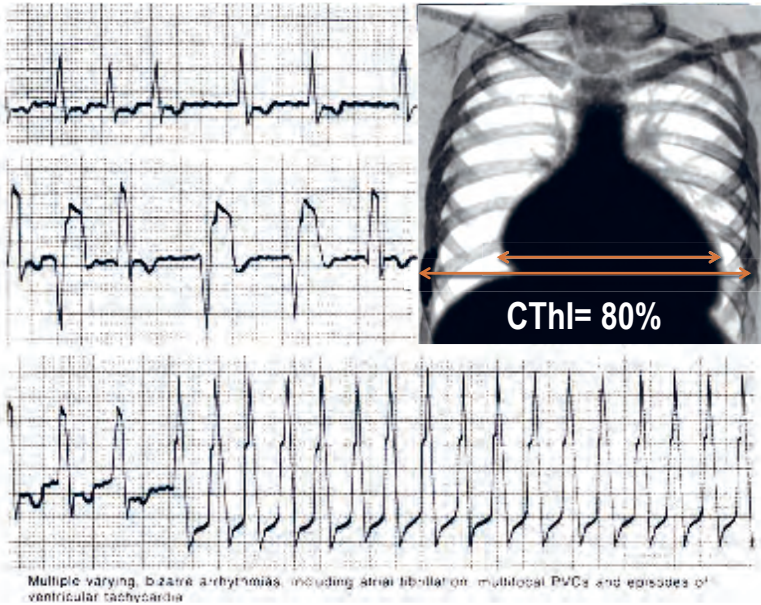
- The results of magnetic resonance imaging walls of the arteries
- Determination of coronary calcifications with by computed tomography
- Measurement of intima-media thickness of the carotid arteries ultrasound

### • Patient Preoperatively

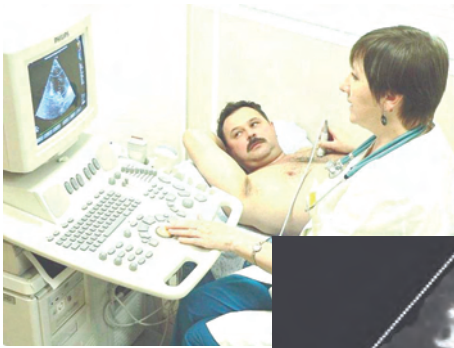Advanced congestive heart failure, with marked cyanosis, edema and ascites



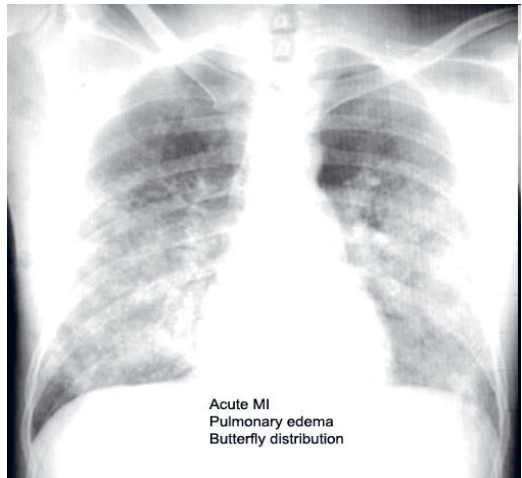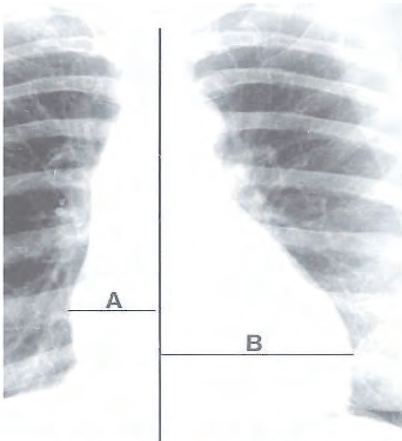
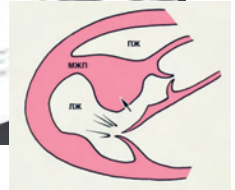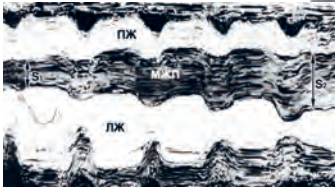
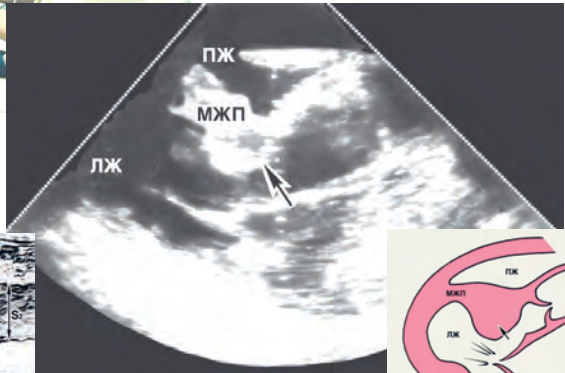
### Cadiomegaly – bull's heart



Physical load treadmill test

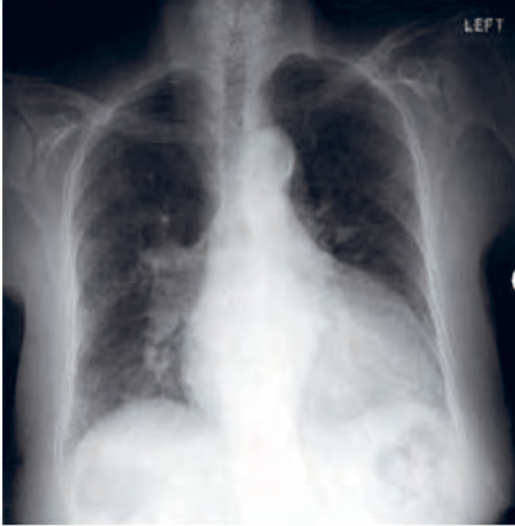

# Echocardiography

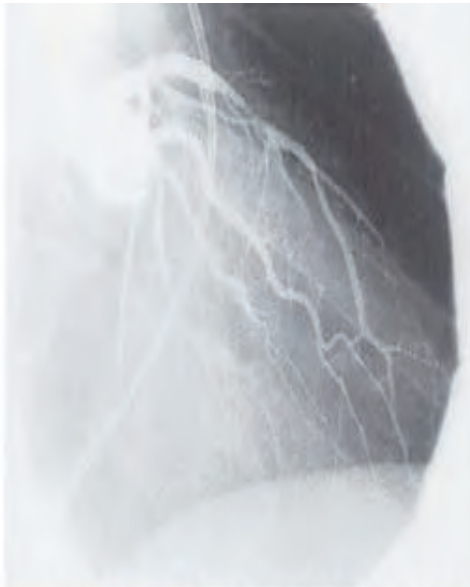

Measurement of the transverse cardiac diameter. Severe aortic stenosis with a 95-mm systolic gradient across the valve is present. The heart, though considerably hypertrophied, is normal in size and configuration. A vertical line is drawn through the heart. The greatest distances to the right cardiac border (A) and to the left cardiac border (B) are then measured. Transverse cardiac diameter = A + B.

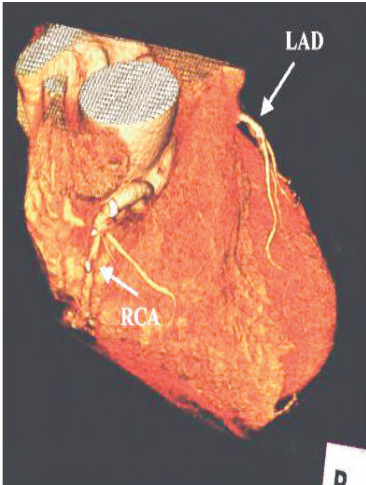
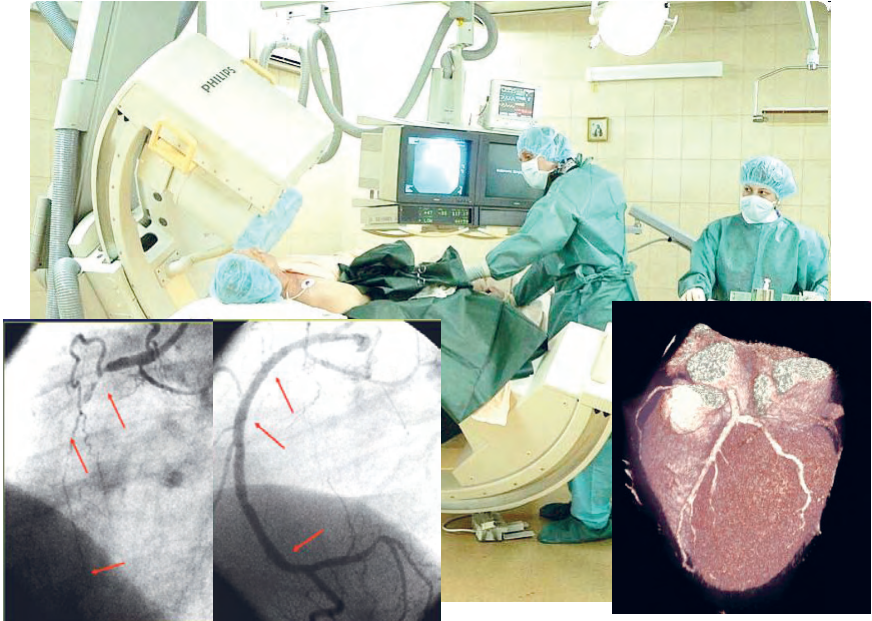




*Chest x-ray of heart failure with cardiomegaly*

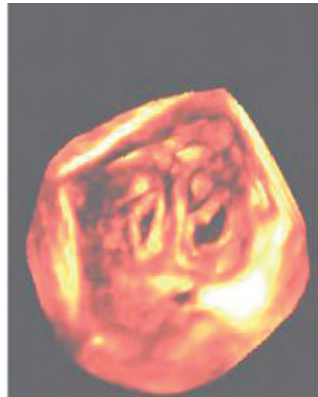


**An example of a significant stenosis in the left anterior descending coronary artery.**



Three-dimensional display of a contrast-enhanced CT coronary angiogram demonstrating multiple calcified lesions in the right coronary artery (RCA), with one focal obstructive lesion noted (see arrow). The left anterior descending artery (LAD) is also displayed and is without focal stenoses

Copyright © 2008 by Saunders, an imprint of Elsevier Inc. All rights reserved



Real-time three-dimensional image showing the tricuspid and mitral valves from the perspective of the left and right atrium.

(Courtesy of Phillips Ultrasound, Andover, MA. From Otto CM. Textbook of Clinical Echocardiography, 3rd ed. Philadelphia, Elsevier Saunders, 2004, p 100, Fig. 4-6.)

# NB!

**"Learn to see, learn to hear, learn to feel, learn to smell, and  
know that only through practice  
you can become an expert."**

***W.Osler***

## REFERENCES

Kovalyova O.N., Ashcheulova T.V. Propedeutics to Internal Medicine. Part 1. – Vinnytsya: NOVA KNYHA, 2017. – 424 p.

Kovalyova O.N., Asheulova T.V. General inspection: manual for students. – Kharkov: "Turbo". – 2004. – 60 p.

Khomazjuk V.A., Ostashevskaya T.G., Krasnyuk I.V. Propaedeutics of Internal Medicine and Patient Care: Study guide for the practical classes. Part I. – Kyiv: NMU, 2005. – 44 p.

Kovalyova O.N., Asheulova T.V. Examination of the patients with cardiovascular disease: manual for students. – Kharkov: "Turbo". – 2003. – 92p.

Kovalyova O.N., Asheulova T.V., Shapovalova S.A. Instrumental methods examination of cardiovascular system: manual for students. – Kharkov: KSMU. – 2004. – 147p.

Bickley, Lynn S.; Szilagy, Peter G. Bates' Guide to Physical Examination and History Taking, 10th Edition. – 934p. Copyright ©2009 Lippincott Williams & Wilkins

The Point online resources, <http://thepoint.lww.com>

LECTURE # **5**

**AUSCULTATION OF THE HEART:**

**THE MAIN SIGNS OF NORMAL  
AND PATHOLOGICAL TONES  
AND HEART SOUNDS**

## THE PLAN

- Introduction – History
- Understanding heart sound origins
- Tasks of heart auscultation
- Aims of auscultation
- What to look for during auscultation
- Auscultator sequence. The rule of «8»
- Positions for auscultation
- Algorithm of heart auscultation
- Heart sounds
- The first tone (1 tone) of the heart – S1
- The second tone (2 tone) of the heart – S2
- The third tone (3 tone) of the heart – S3
- The fourth tone (4 tone) of the heart – S4
- Gallops
- Murmurs origin
- Evaluation of Heart Murmurs
- Differentiation of functional and organic murmurs
- Irradiation of murmurs
- How to optimize the auscultation
- Pericardial rub
- Auscultation of vessels
- References



"Learn to listen, and you can gain benefit ..."

**Plutarch**

## AUSCULTATION OF THE HEART

- Auscultation of the heart - method of examination of heart's structure and function, based on listening of the sounds which accompanying heartbeats

## HISTORY...


- It is known that Hippocrates (460 - 370 BC) advised to put his ear on the bare chest in case of empyema suspicion. It is believed that he also offered to listen the sounds of the heart
- Auscultation of the heart was first introduced in the 2nd century BC by Greek physician Aretey
- In 1616 William Harvey (William Harvey, 1578-1657) described the presence of two tones during listening to the heart
- At the end of the XVII century Robert Hooke at the report in the Royal Society said: "I absolutely could hear the beating of the human heart. Probably, it is possible to detect the action of internal parts of the body by the sounds which they produce"

"... The most important part of the art is the ability to observe carefully."

*Rene Theophile Hyacinthe Laënnec, 1819*



1781-1826



1816

Stethoscope by Rene Laennec's design (Museum of the University of Nantes)

### Technical evolution

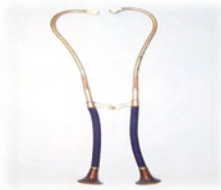

Classic Rapaport, Hewlett-Packard

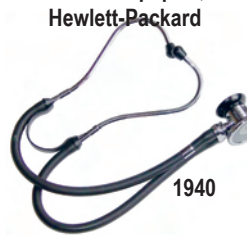

First DI

1894



Stereo-effect?



1940



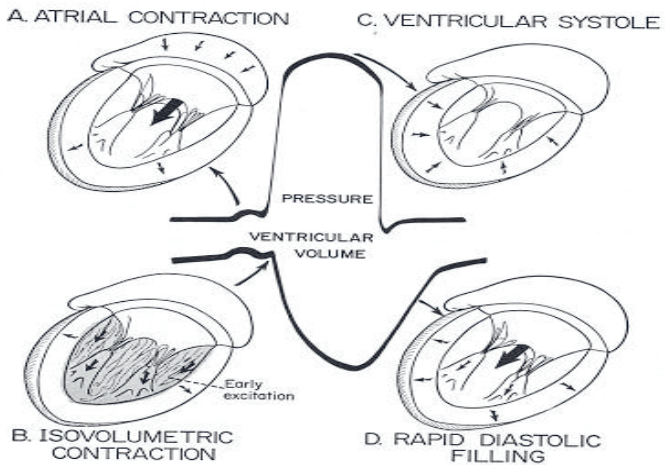
D.Littman, 1960



***"Your ears are better than any test and don't cost the patient a cent."***

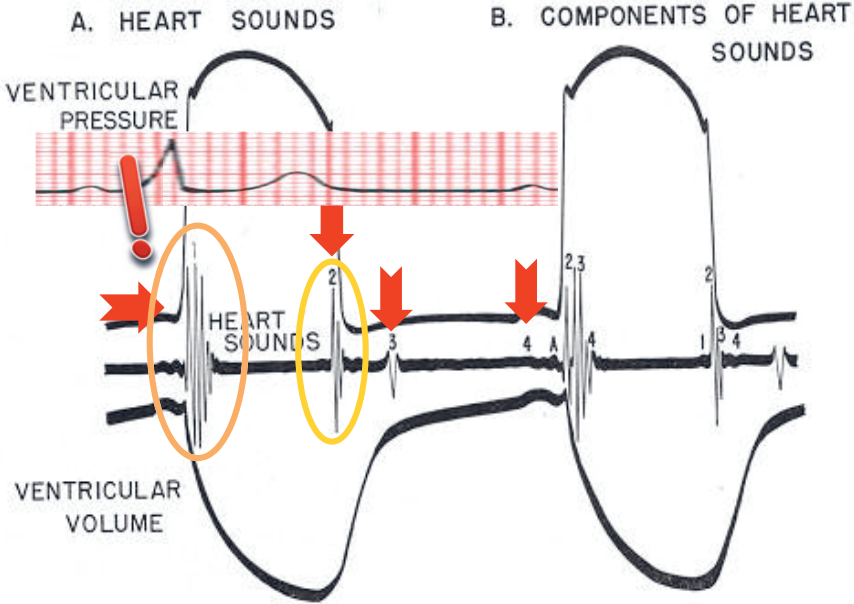
*W. Proctor Harvey, 1959*

## Cardiac cycle

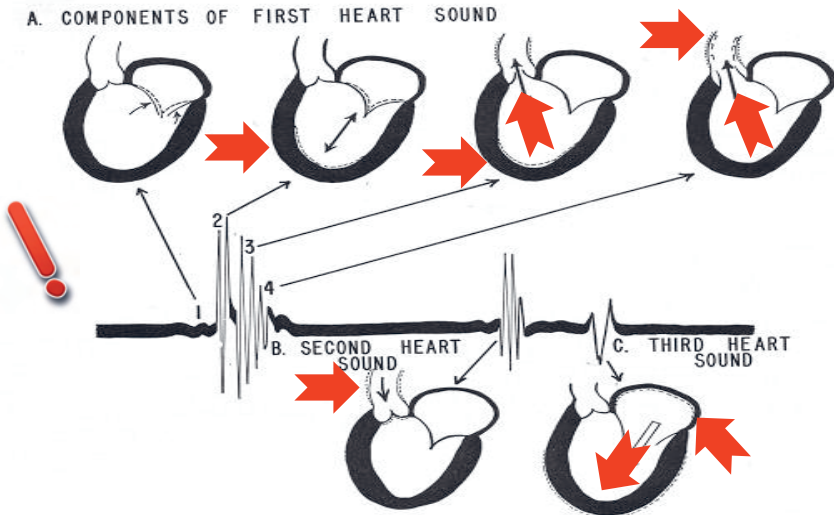




## THE TIMING OF HEART SOUNDS



### Understanding heart sound origins



## TASKS OF HEART AUSCULTATION:

- Detection of violations of intracardiac hemodynamics:
  - valvular (stenosis, insufficiency)
  - pathology of papillary apparatus
  - defects in the walls of the heart
- Indirect assessment of ventricular myocardium (systolic and diastolic function)
- Changing of the wall of aorta
- Detection of lesions of the pericardium:
  - inflammation;
  - hydropericardium

## AIMS OF AUSCULTATION:

- The intensity of I tone (S1) at all points
- The intensity of II tone (S2) at all points
- Characteristics of any systolic sounds
- Characteristics of any diastolic sounds

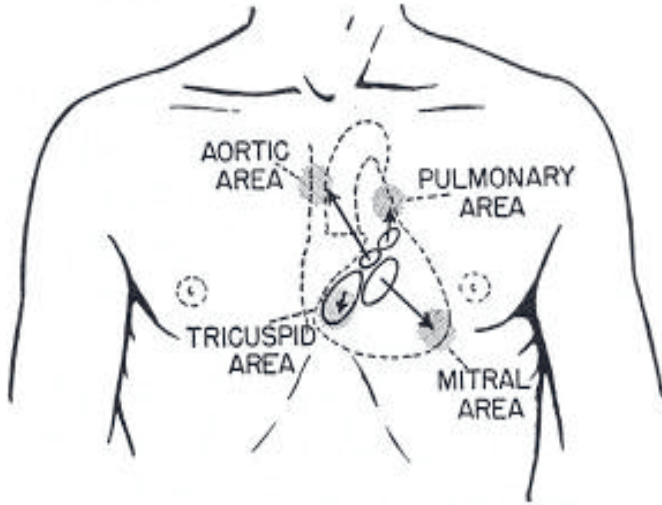
## Technique of auscultation:

<p><b>Stetho-phonendoscope</b></p> <p><b>D</b></p>	<p>Press tightly to the chest wall          All auscultation points          High pitched sounds          I and II tones          Noises at the mitral and aortic insufficiency          Pericardial rub</p>
<p><b>Stethoscope</b></p> <p><b>B</b></p>	<p>Do not press strongly          The apex of the heart and the lower border of the sternum          Low-pitched sounds          III and IV tones          Noise at the mitral stenosis</p>

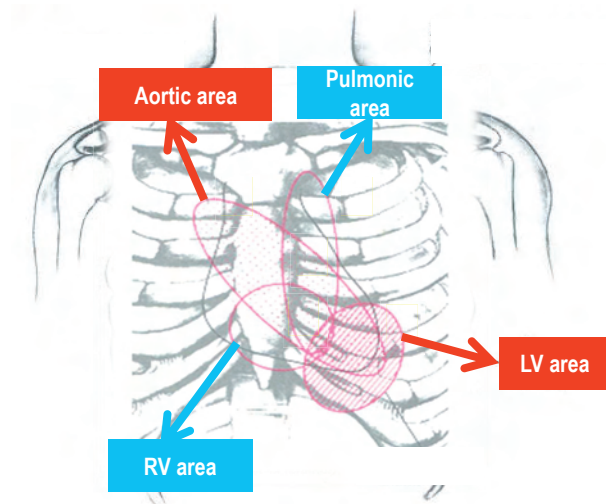
## WHAT TO LOOK FOR DURING AUSCULTATION:

- I and II of tones: the strength and the possible splitting
- Additional tones during diastole - III or IV tones, opening click
- Effect of phases of the respiratory cycle
- Systolic murmurs
- Diastolic murmurs
- Properties of heart murmurs:
  - Time of occurrence
  - Configuration
  - Place of the best listening
  - Irradiation
  - The intensity (six-point scale)
  - Height (high tone, medium, low)
  - The character ("blowing", "rude", "rattling", "music")

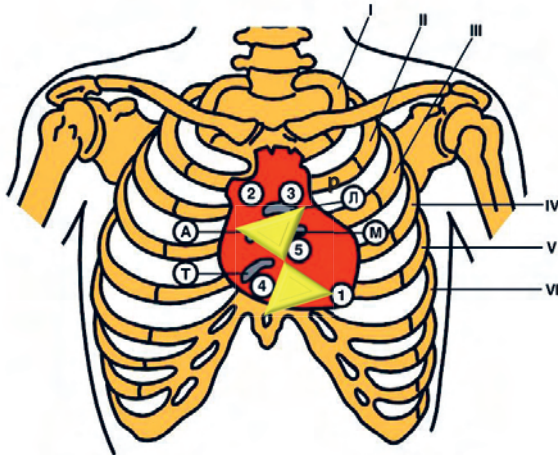
## TRANSMISSION OF SOUNDS AND MURMURS




## Auscultator sequence & alternate auscultation areas



## Auscultator sequence. The rule of «8»

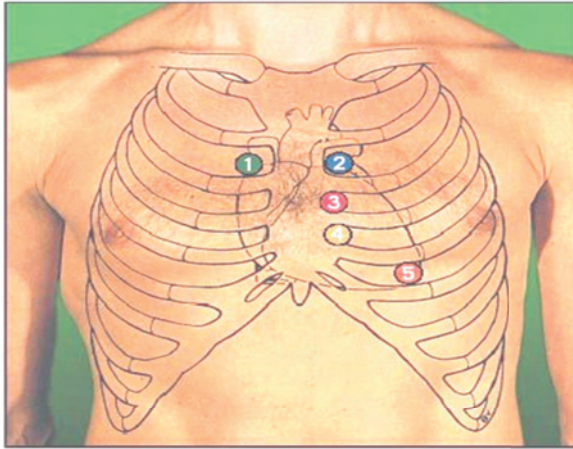


### Algorithm of heart auscultation (1)



## Algorithm of heart auscultation (2)


### Locating the assessment points



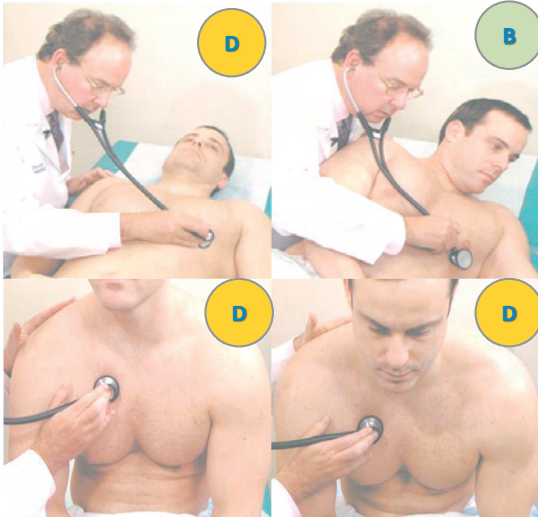
- 1 Aortic area—second intercostal space, right sternal border
- 2 Pulmonic area—second intercostal space, left sternal border
- 3 Erb's point—third intercostal space, left sternal border
- 4 Tricuspid area—fourth (or fifth) intercostal space, left sternal border
- 5 Mitral area or apex—fifth intercostal space, left midclavicular line

A patient should be examined in the following positions:

- ❖ lying on the back 30°
- ❖ lying on the left side
- ❖ sitting
- ❖ standing



## Positions for auscultation

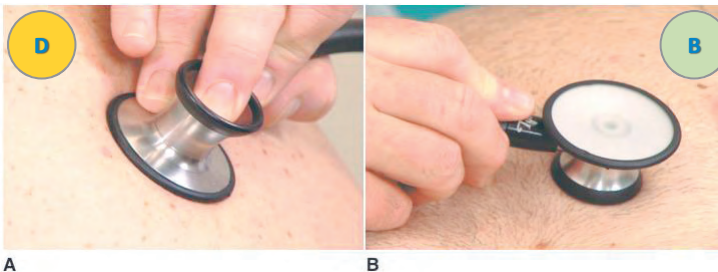


**A**, The supine position, used for listening to all areas.

**B**, The left lateral decubitus position, used for listening with the bell in the mitral area.

**C**, The upright position, used for listening to all areas.

**D**, The upright, leaning-forward position, used for listening with the diaphragm at the base positions.



**A**

**B**

### Placement of stethoscope heads.

**A**, Correct placement of the diaphragm. Notice that the head is applied tightly to the skin.


**B**, Placement of the bell. Notice that the bell is applied lightly to the skin

# All “heart music” consists of two elements:

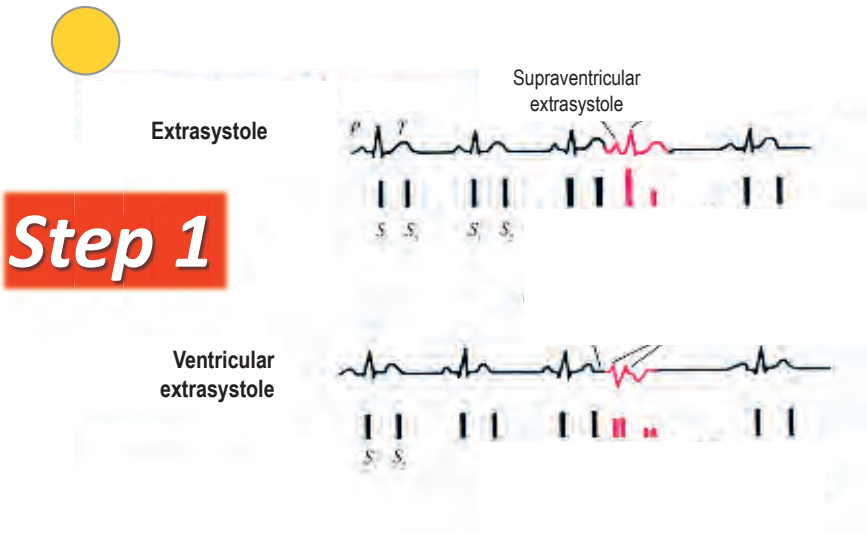
- **Heart sounds.**  
Short, beat-like or click-like.
- **Heart murmurs.**  
Prolonged in time.



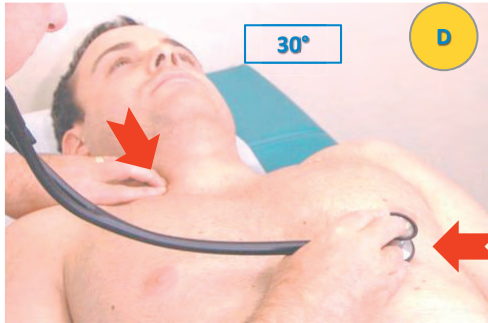Cardiac cycle repeats over time. Let's depict time on a horizontal line. Time goes from left to right. Like this:



## Rhythm & Rate



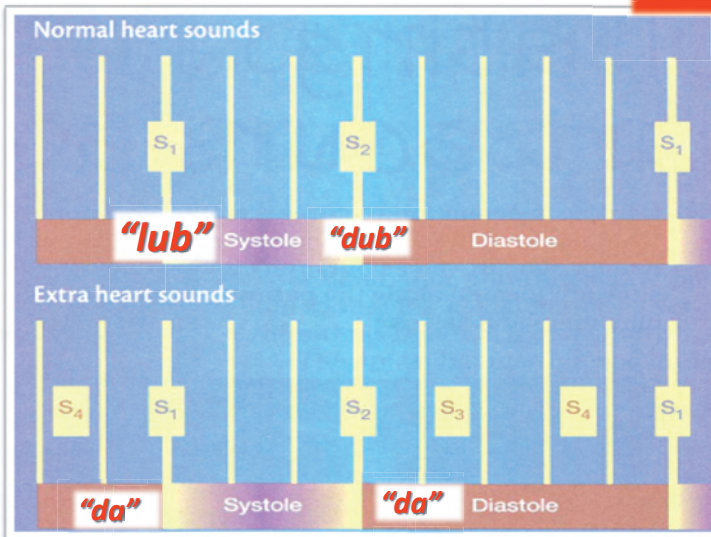


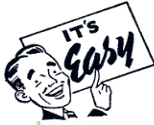

Technique for  
timing the heart sounds

## Heart sounds

### Step 2

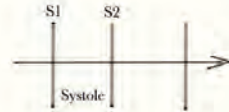




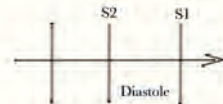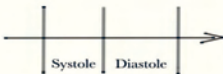### Approach to Cardiac Auscultation

Position	Evaluate
Supine	S <sub>1</sub> in all areas S <sub>2</sub> in all areas Systolic murmurs or sounds in all areas
Left lateral decubitus	Diastolic events at apex with bell of stethoscope
Upright	S <sub>1</sub> in all areas S <sub>2</sub> in all areas Systolic murmurs or sounds in all areas Diastolic murmurs or sounds in all areas
Upright, leaning forward	Diastolic events at base with diaphragm of stethoscope

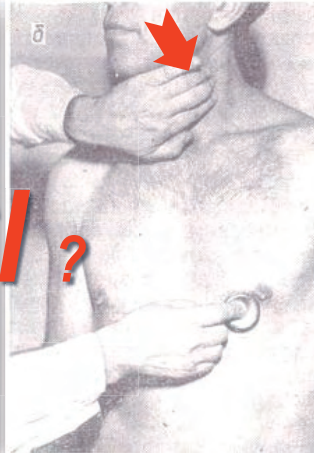
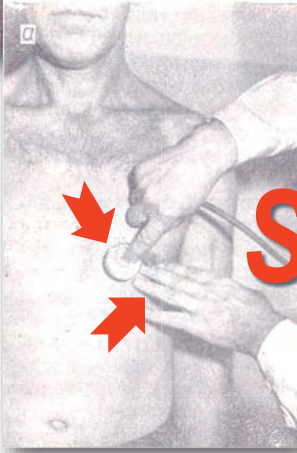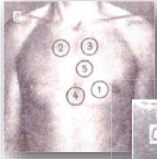Cardiac cycle repeats over time. Let's depict time on a horizontal line. Time goes from left to right. Like this:



The period between T1 and T2 is systole

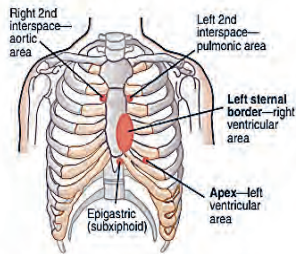


The period between S2 and S1 is diastole



## Auscultation

Listen to heart by “inching” your stethoscope from the base to the apex (or apex to base) in the areas illustrated.



Use the *diaphragm* in the areas illustrated above for relatively *high-pitched sounds* like  $S_1, S_2$ .

Also murmurs of aortic and mitral regurgitation; pericardial friction rubs

Use the *bell* for *low-pitched sounds* at the lower left sternal border and apex.

$S_3, S_4$ , murmur of mitral stenosis

Listen at each area for:

Heart sounds, Variations of S-1,2

## Auscultation (2)

• S <sub>1</sub>	
• S <sub>2</sub> . Is splitting normal in left 2nd and 3rd interspaces?	Physiologic (inspiratory) or pathologic (expiratory) splitting
• Extra sounds in systole	Systolic clicks
• Extra sounds in diastole	S <sub>3</sub> , S <sub>4</sub>
• Systolic murmurs	Midsystolic, pansystolic, late systolic murmurs
• Diastolic murmurs	Early, mid-, or late diastolic murmurs

## The first tone (I tone) of the heart occurs during ventricular systole

Systolic heart sound consists of four components (groups of oscillations):

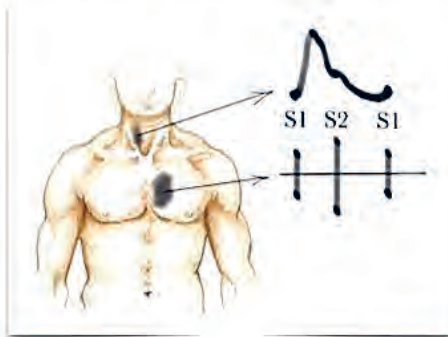
- **Muscular component** - fluctuations in the muscles of the ventricles during its tension (period of ventricular muscle tension, phase of asynchronous contraction)
- **Component of atrioventricular valves** - fluctuations of atrioventricular valves during their closing (isometric contraction phase)
- **Component of semilunar valves** - fluctuations of semilunar valves during their opening (phase of isometric contraction)
- **Vascular component** – fluctuations of the walls of the great arteries (the aorta and the pulmonary trunk) during the passage of blood on them (the period of the expulsion of blood from the ventricles, the phase of rapid ejection)

## The second tone (II tone) of the heart occurs during diastole of the ventricles

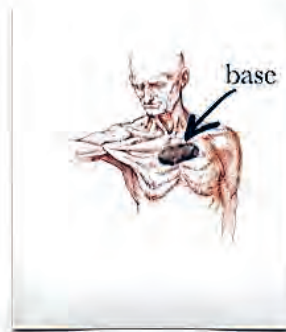
Diastolic heart sound consists of four components (groups of oscillations):

- **Muscular component** – fluctuations of the muscles of the ventricles during its relaxation (protodiastolic period)
- **Component of semilunar valves** – fluctuations of semilunar valves during their closing (protodiastolic period)
- **The vascular component** – fluctuations of the walls of the great arteries (the aorta and the pulmonary trunk) when blood flow reflected from the closed semilunar valves (the period of isovolumetric relaxation of the muscles of the ventricles)
- **Component of atrioventricular valves** – fluctuations of atrioventricular valves during their opening (the period of isovolumetric relaxation of the muscles of the ventricles)

The peak of common carotid pulse wave falls on S1-S2 period



S2 is almost always louder at the base of the heart

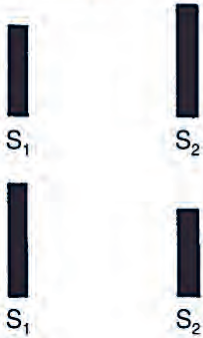


Let's repeat these four rules:

- S1 and S2 sound differently
- S1 and S2 have specific areas, where they are extra loud
- S1-S2 period is usually shorter than S2-S1 period
- The peak of the carotid pulse wave falls on S1-S2 period



### Normal Variations



S<sub>1</sub> is softer than S<sub>2</sub> at the *base* (right and left 2nd interspaces).

## Step 2

S<sub>1</sub> is often but not always louder than S<sub>2</sub> at the *apex*.

## Focuses on the pathologic changes

Focuses on the pathologic changes that result in the following:

- Abnormalities of S<sub>1</sub>
- Abnormalities of S<sub>2</sub>
- Systolic clicks
- Diastolic opening snaps
- Murmurs

## Step 3




### Accentuated S<sub>1</sub>



Occurs in (1) tachycardia, rhythms with a short PR interval, and high cardiac output states (e.g., exercise, anemia, hyperthyroidism), and (2) mitral stenosis.

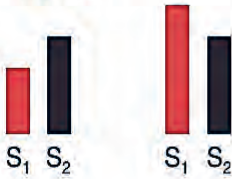


**Diminished S<sub>1</sub>**



Occurs in first-degree heart block, calcified mitral valve of mitral regurgitation, and ↓ left ventricular contractility in heart failure or coronary heart disease.

**Varying S<sub>1</sub>**



S<sub>1</sub> varies in complete heart block and any totally irregular rhythm (e.g., atrial fibrillation).

**Split S<sub>1</sub>**



Normally heard along the *lower left sternal border* if audible tricuspid component. If S<sub>1</sub> sounds split at apex, consider an S<sub>4</sub>, an aortic ejection sound, an early systolic click, right bundle branch block, and premature ventricular contractions.

## Factors that may influence the intensity of the heart sounds

**Loud first sound**

- Hyperdynamic circulation (fever, exercise)
- Mitral stenosis
- Atrial myxoma (rare)

**Soft first sound**

- Low cardiac output (rest, heart failure)
- Tachycardia
- Severe mitral regurgitation (caused by destruction of valve)

**Variable intensity of first sound**

- Atrial fibrillation
- Complete heart block

**Loud aortic component of second sound**

- Systemic hypertension
- Dilated aortic root

**Soft aortic component of second sound**

- Calcific aortic stenosis

**Loud pulmonary component of second sound**

- Pulmonary hypertension

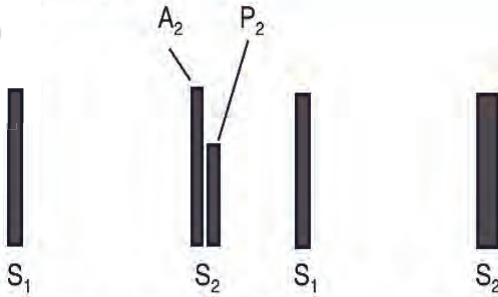




## Variations in the Second Heart Sound— $S_2$ During Inspiration and Expiration

### D Physiologic Splitting

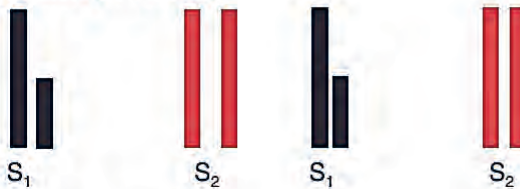**$S_2$**



**Step 4**

Heard in the 2nd or 3rd left interspace: the pulmonic component of  $S_2$  is usually too faint to be heard at the apex or aortic area, where  $S_2$  is single and derived from aortic valve closure alone. Accentuated by inspiration; usually disappears on exertion.

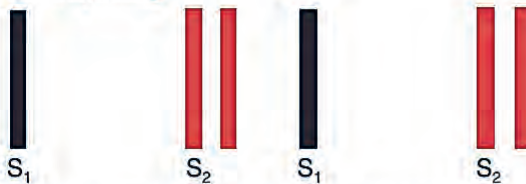
### Pathologic Splitting



**$S_2$**

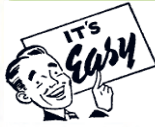Wide splitting of  $S_2$  persists throughout respiration; arises from delayed closure of the pulmonic valve (e.g., by pulmonic stenosis or right bundle branch block); also from early closure of the aortic valve, as in mitral regurgitation.

### Fixed Splitting



Does not vary with respiration, as in atrial septal defect, right ventricular failure.

(continued)

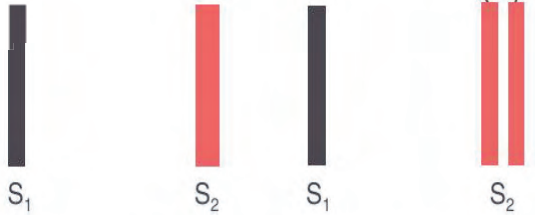

Variations in the Second Heart Sound— $S_2$   
During Inspiration and Expiration (continued)

Paradoxical or Reversed Splitting

**$S_2$**

**Step 4**



Appears on expiration and disappears on inspiration. Closure of the aortic valve is abnormally delayed, so  $A_2$  follows  $P_2$  on expiration, as in left bundle branch block.


Systolic clicks

**Step 5**

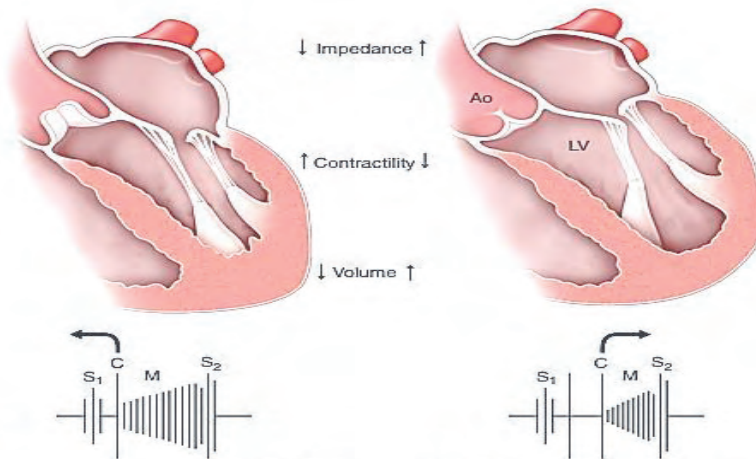
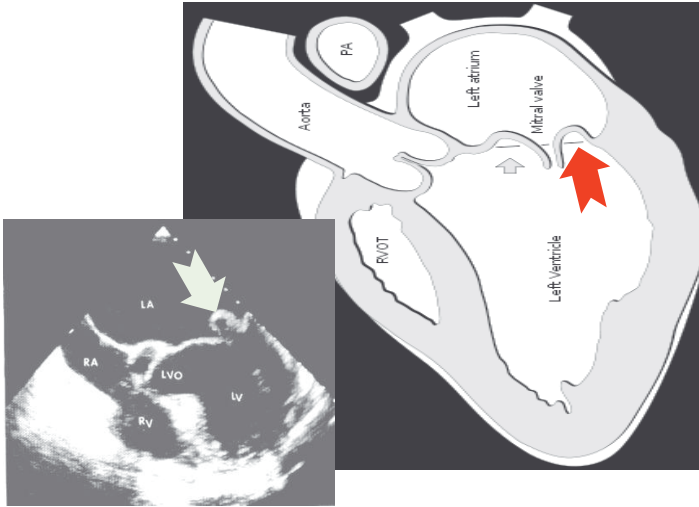


**D**

Clicks

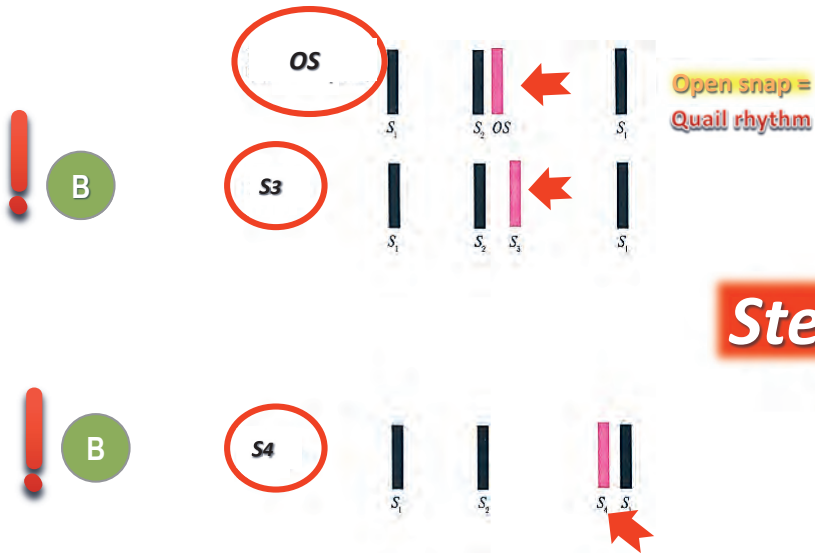

# Mitral prolapse



**Behavior of the click (C) and murmur (M) of mitral valve prolapse with changes in loading (volume, impedance) and contractility.**  $S_1$ , first heart sound;  $S_2$ , second heart sound. With standing (left side of figure), volume and impedance decrease, as a result of which the click and murmur move closer to  $S_1$ . With squatting (right), the click and murmur move away from  $S_1$  owing to the increases in left ventricular volume and impedance (afterload). (Adapted from RA O'Rourke, MH Crawford: *Curr Prob Cardiol* 1:9, 1976.)

## Diastolic extra sounds

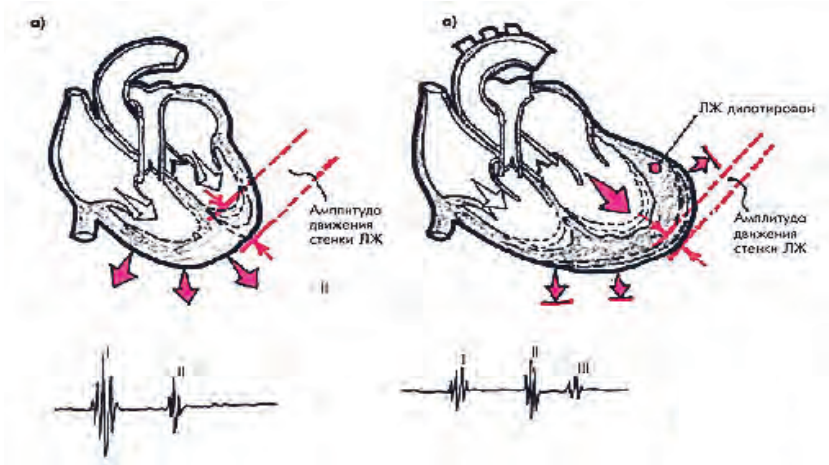


## Third tone (III tone) of the heart - diastolic

- It may sometimes be heard in the middle third of the ventricular diastole through  $\sim 0,11 \div 0,16$  seconds after the II-nd tone. Its duration  $\sim 0,02 \div 0,06$  sec.
- Apparently it is due to fluctuations of the ventricle walls, caused by the movement of blood from the atria to the ventricles (ventricular diastole, during the filling of the ventricles with blood, a phase of rapid filling)
- The third tone has a very low intensity
- Bass tones – due to very low elasticity of the ventricles during diastole
- The third tone does not occur in the first third of diastole, when the ventricles are not filled with blood, and there is not any tension of its walls, necessary for occurrence of oscillations
- The third tone does not appear in the last third of ventricular diastole, because at this time the ventricles do not receive such amount of blood which is necessary for the occurrence of oscillations

B

## Diastolic S3



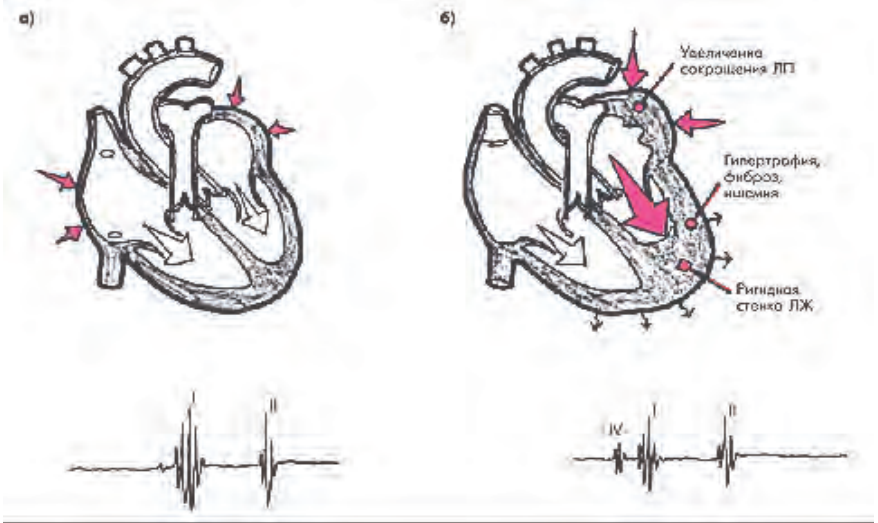
## Fourth tone (IV tone) of the heart - diastolic

- The fourth tone (IV tone) precedes the first tone or merges with it. Its duration  $\sim 0,04 \div 0,06$  sec.
- Occurs during the atrial contraction, when the blood is ejected from the atria to the ventricles and causes fluctuations of ventricle walls

B



# Presystolic S4



# GALLOPS

**S<sub>3</sub>: Classic sign of heart failure**

S<sub>3</sub>, also known as ventricular gallop, is commonly heard in children and may be normal in patients during the last trimester of pregnancy; however, it may be a cardinal sign of heart failure in other adults. Because it follows S<sub>2</sub>, it's commonly compared to the "y" sound in "Ken-luck-y." S<sub>3</sub> is low-pitched; you'll hear it best at the apex when the patient is lying on his left side.



**S<sub>4</sub>: An MI aftereffect**

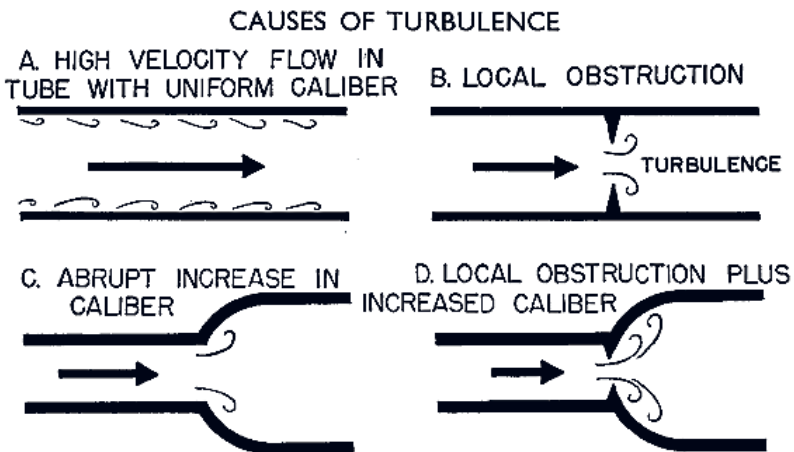
Also called an atrial gallop, S<sub>4</sub> is an adventitious heart sound that you'll hear best over the tricuspid or mitral area when the patient lies on his left side. Patients who are elderly and those with hypertension, aortic stenosis, or a history of MI may have an S<sub>4</sub>. It's commonly described as sounding like "Ten-tes-see" because it occurs just before S<sub>1</sub>, after atrial contraction.





The murmurs - sounds resulting from vibration of vessels and/or structure of the heart due to the change of direction of blood flow or its strengthening

## Murmurs origin

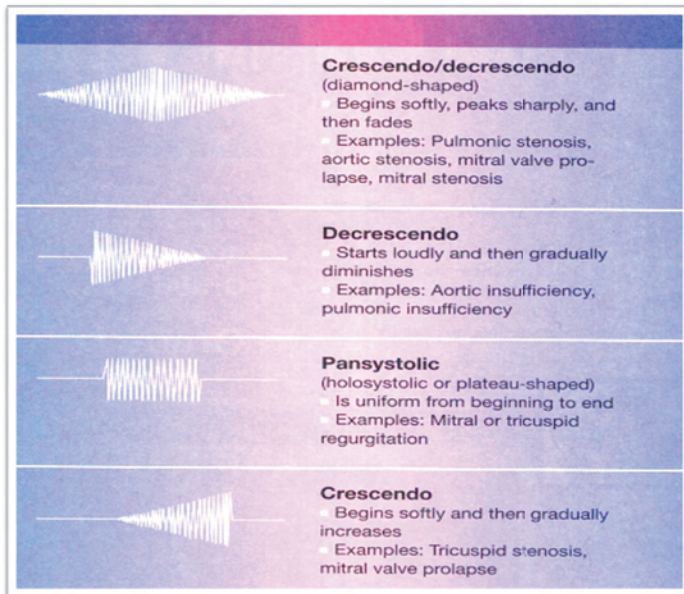


### 3 main mechanisms of murmurs formation:

- Acceleration of blood flow through an anatomically normal or narrowing vessel
- Blood flow in the zone of expansion of the vessel or chamber of the heart
- Reverse physiological blood flow (regurgitation) through a leaky valve, septal defect or vascular fistula

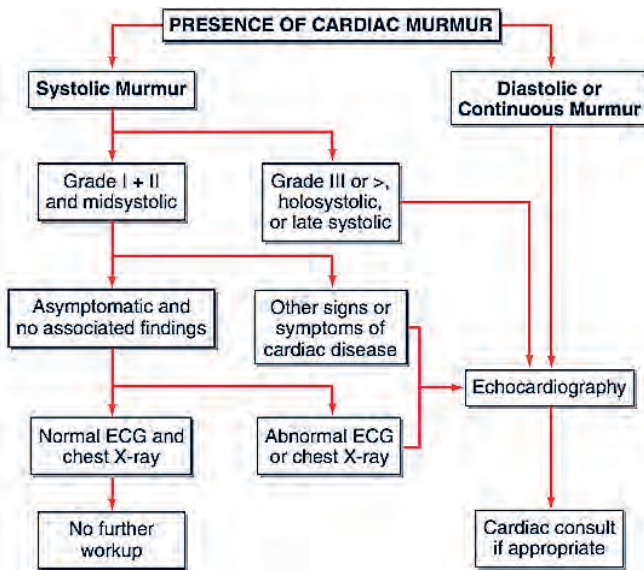


### Heart murmurs *(shape)*





## Evaluation of Heart Murmurs



### EXAMINATION TECHNIQUES

### POSSIBLE FINDINGS

#### D

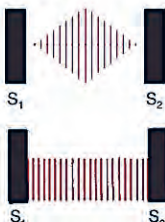
### ASSESSING AND DESCRIBING MURMURS

Identify, if murmurs are present, their:

- Timing in the cardiac cycle (systole, diastole). It is helpful to palpate the carotid upstroke while listening to any murmur—murmurs occurring simultaneously with the upstroke are systolic.

See Table 9-4, Heart Murmurs, p. 165.

- Shape




Plateau, crescendo, decrescendo

A *crescendo-decrescendo* murmur first rises in intensity, then falls (e.g., aortic stenosis).

A *plateau* murmur has the same intensity throughout (e.g., mitral regurgitation).

## Step 7



A **crescendo murmur** grows louder (e.g., mitral stenosis).

A **decrescendo murmur** grows softer (e.g., aortic regurgitation).

- Location of maximal intensity
- Radiation
- Pitch
- Quality
- Intensity on a 6-point scale

Murmurs loudest at the **base** are often aortic; at the **apex**, they are often mitral.

High, medium, low

Blowing, harsh, musical, rumbling

See "Gradations of Murmurs" on next page.

👂 Listen at the apex with patient turned toward left side for low-pitched sounds.

Left-sided **S<sub>3</sub>**, and diastolic murmur of **mitral stenosis**

### AIDS TO IDENTIFY SYSTOLIC MURMURS

#### Valsalva Maneuver

Ask patient to strain down.

In suspected *mitral valve prolapse (MVP)*, listen to the timing of click and murmur.

Ventricular filling decreases, the systolic click of MVP is earlier, and the murmur lengthens.

To distinguish *aortic stenosis (AS)* from *hypertrophic cardiomyopathy (HC)*, listen to the intensity of the murmur.

In AS, the murmur decreases; in HC, it often increases.

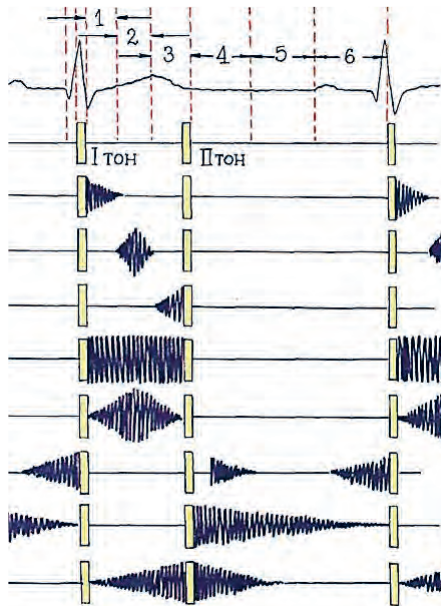
#### 👤/👤 Squatting and Standing

In suspected MVP, listen for the click and murmur in both positions.

Squatting increases ventricular filling and delays the click and murmur. Standing reverses the changes.

Try to distinguish AS from HC by listening to the murmur in both positions.

Squatting increases murmur of AS and decreases murmur of HC. Standing reverses the changes.

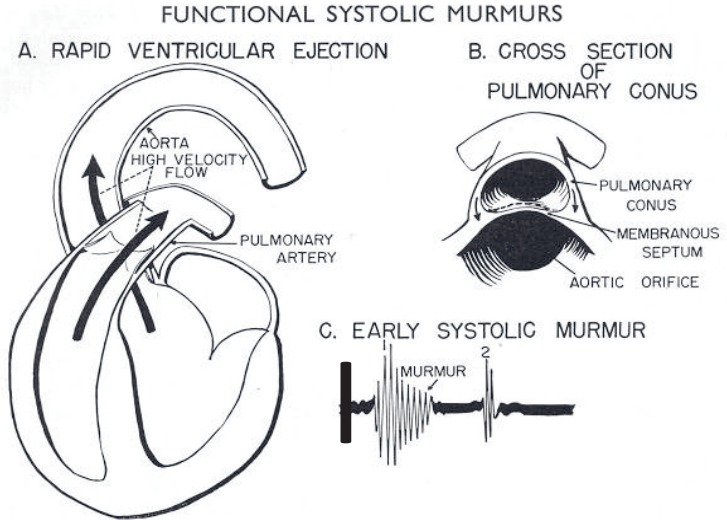


Heart murmurs (*types*)

## Differentiation of functional and organic murmurs

Properties of noise	Functional	Organic
Phase	Systolic	Systolic and diastolic
Localization	Different	Special points
Duration	< ½ of cycle	> ½ of cycle
Loudness	1-2	More or equal 3
Irradiation	No	Yes
Timbre	Blowing	Overtones
Variability	Disappear	Stable

# Functional systolic murmurs



# Intensity of Heart Murmurs

Grade 1 – barely audible, even to the trained ear

Grade 2 – clearly audible

Grade 3 – moderately loud

Grade 4 – loud with palpable thrill

Grade 5 – very loud with a palpable thrill; can be heard when the stethoscope has only partial contact with the chest

Grade 6 – extremely loud with a palpable thrill; can be heard with the stethoscope lifted just off the chest wall



## Heart Murmurs

### Likely Causes

#### Midsystolic



Innocent murmurs (no valve abnormality)  
 Physiologic murmurs (from  $\uparrow$  flow across a semilunar valve, as in pregnancy, fever, anemia)

Aortic stenosis

Murmurs that mimic aortic stenosis—aortic sclerosis, bicuspid aortic valve, dilated aorta, and pathologically  $\uparrow$  systolic flow across aortic valve

Hypertrophic cardiomyopathy

Pulmonic stenosis

## Step 7

#### Pansystolic



Mitral regurgitation

Tricuspid regurgitation


Ventricular septal defect

#### Late Systolic



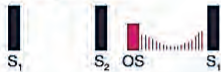Mitral valve prolapse, often with click (C)

#### Early Diastolic



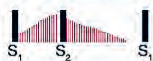Aortic regurgitation

#### Middiastolic and Presystolic

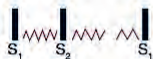

Mitral stenosis—note opening snap (OS)

#### Continuous Murmurs and Sounds



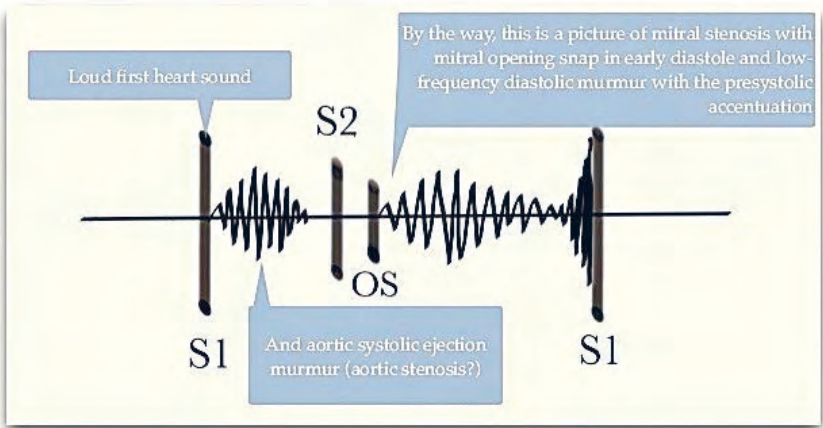
Patent ductus arteriosus—harsh, machinery-like



Pericardial friction rub—a scratchy sound with 1–3 components



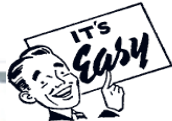Venous hum—continuous, above midclavicles, loudest in diastole

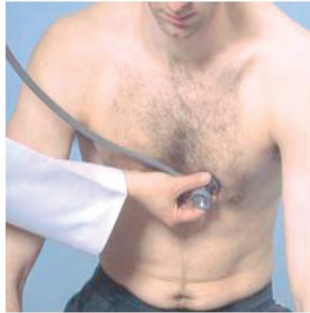


That's how we scanned complete cardiac cycle without missing anything

## Sites of radiation of murmurs

Cause	Primary site	Radiation
Tricuspid regurgitation	Lower left sternal edge	Lower right sternal edge, liver
Pulmonary stenosis	Upper left sternal edge	Towards left clavicle, beneath left scapula
Mitral regurgitation	Apex	Left axilla, beneath left scapula
Aortic regurgitation	Left sternal edge	Down left sternal edge towards apex
Aortic stenosis	Apex	Towards upper right sternal edge, over carotids
Ventricular septal defect	Left sternal edge	All over pericardium
Mitral stenosis	Apex	Does not radiate



**EXAMINATION TECHNIQUES****POSSIBLE FINDINGS**

7 Listen down left sternal border to the apex as patient sits, leaning forward, with breath held after exhalation.

*Diastolic decrescendo murmur of aortic regurgitation*

## IRRADIATION OF MURMURS

- **Rule № 1:** The more marked hemodynamic defect – the greater the area of irradiation
- **Rule № 2:** direction of irradiation coincides with the direction of blood flow from the place of origin of the murmur

## HOW TO OPTIMIZE THE AUSCULTATION?

Methods used to evaluate the variability of murmurs:

- Inhale / exhale
- Load
- Change position
- Valsalva's maneuver
- Pharmacological tests

## HOW TO OPTIMIZE THE AUSCULTATION?

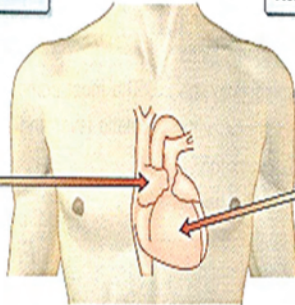
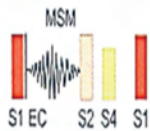
Respiratory variation of murmurs

**RULE!**

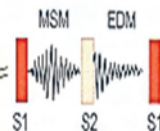
- Deep inhalation increases the intensity of right heart murmurs, deep exhalation – from the left heart



## Aortic stenosis



## Aortic regurgitation



## Clinical memo

## Aortic stenosis

Pulse: Sinus rhythm, low volume, slow rising  
 Aortic area: Systolic thrill  
 Apex: Not displaced, sustained  
 Sounds: Ejection click, soft A2, S4  
 Murmurs: Systolic, low pitched, ejection, radiating to carotids

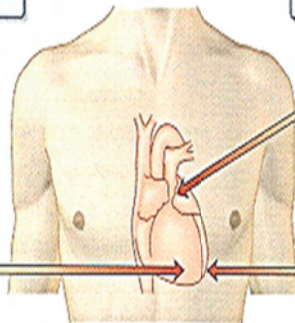

Murmurs heard best with patient leaning forwards and breath held in expiration

## Clinical memo

## Aortic regurgitation


Pulse: Sinus rhythm, large volume, collapsing  
 Blood pressure: Wide pulse pressure  
 Apex: Displaced, diffuse, forceful  
 Murmurs: (1) High pitched, early diastolic at LSE  
 (2) Ejection systolic at base and into neck (high flow)  
 (3) Mid-diastolic rumble at apex (Austin-Flint) (not shown)

## Mitral regurgitation



Murmurs heard best with patient on left side

## Mitral stenosis



## Clinical memo

## Mitral regurgitation

Pulse: Sinus rhythm or atrial fibrillation  
 Apex: Forceful, displaced, systolic thrill  
 Sounds: Soft S1, S3  
 Murmurs: Pansystolic

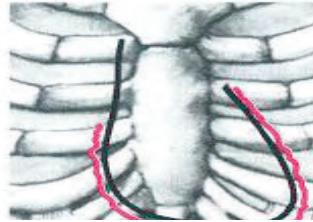
## Clinical memo

## Mitral stenosis

Face: Mitral facies  
 Pulse: Atrial fibrillation  
 RV: Heaving, sustained  
 Apex: Localized, tapping  
 Sounds: Loud S1, loud P2, opening snap  
 Murmurs: Mid-diastolic rumble at apex

# Pericardial rub

D



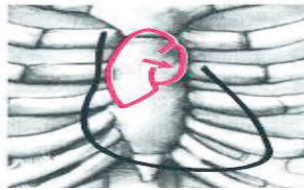
Systole                      Diastole                      Atrium systole




Rustle murmur or sound while walking on loose snow

# Opened ductus arteriosus

D



Systole                      Diastole



Continuous noise, during systole and diastole

II intercostal space

Irradiation to left clavicle

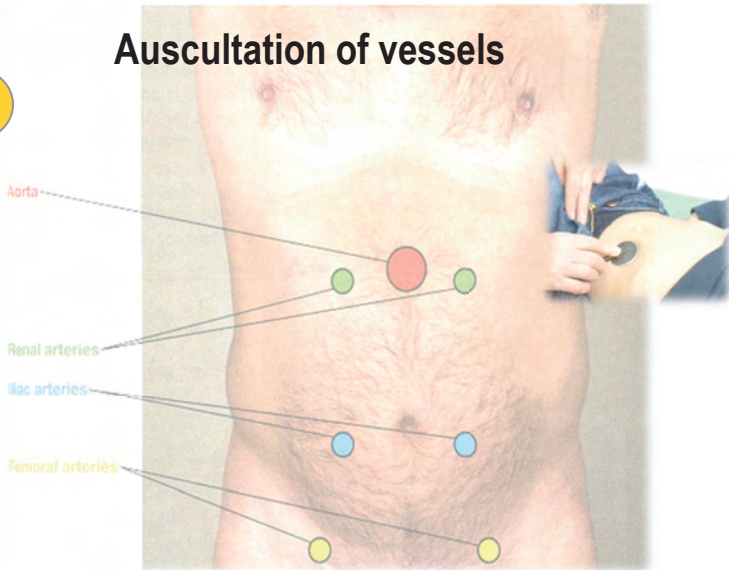
Loud, sometimes accompanied by trembling

Rough, similar to work of the engine

## Abdominal auscultation points

D

## Auscultation of vessels




## Plan of auscultation

1. Evaluation and identification of basic and additional tones

2. Verification of murmurs

3. Dynamic auscultation

4. Conclusion



## REFERENCES

Kovalyova O.N., Asheulova T.V. Propedeutics to Internal Medicine. Part 1. – Vinnytsya: NOVA KNYHA, 2017. – 424 p.

Kovalyova O.N., Asheulova T.V. General inspection: manual for students. – Kharkov: "Turbo". – 2004. – 60 p.

Khomazjuk V.A., Ostashevska T.G., Krasnyuk I.V. Propaedeutics of Internal Medicine and Patient Care: Study guide for the practical classes. Part I. – Kyiv: NMU, 2005. – 44 p.

Kovalyova O.N., Asheulova T.V. Examination of the patients with cardiovascular disease: manual for students. – Kharkov: "Turbo". – 2003. – 92 p.

Kovalyova O.N., Asheulova T.V., Shapovalova S.A. Instrumental methods examination of cardiovascular system: manual for students. – Kharkov: KSMU. – 2004. – 147 p.

Bickley, Lynn S.; Szilagy, Peter G. Bates' Guide to Physical Examination and History Taking, 10th Edition. -934 p. Copyright ©2009 Lippincott Williams & Wilkins

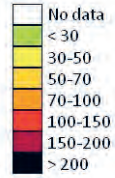
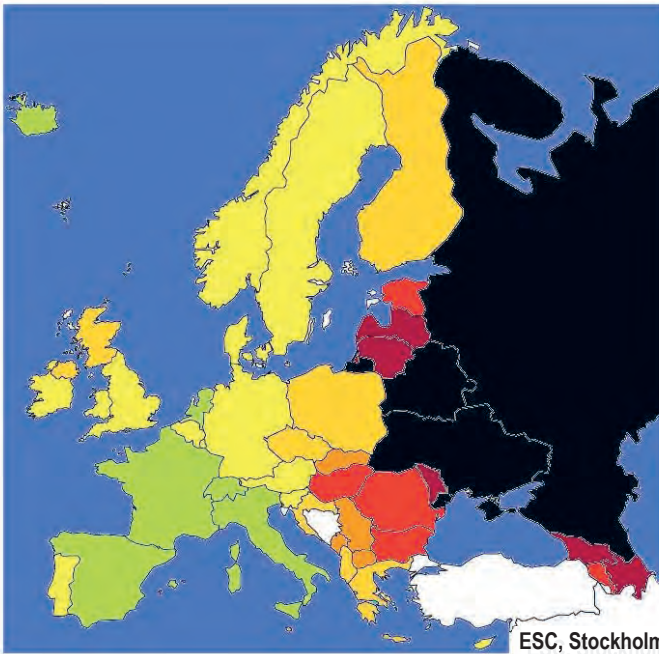
The Point online resources, <http://thepoint.lww.com>

LECTURE # **6**

**SYMPTOMS AND SIGNS  
OF VASCULAR DISEASES  
BASED ON THE STUDY  
OF THE PULSE AND BLOOD PRESSURE**

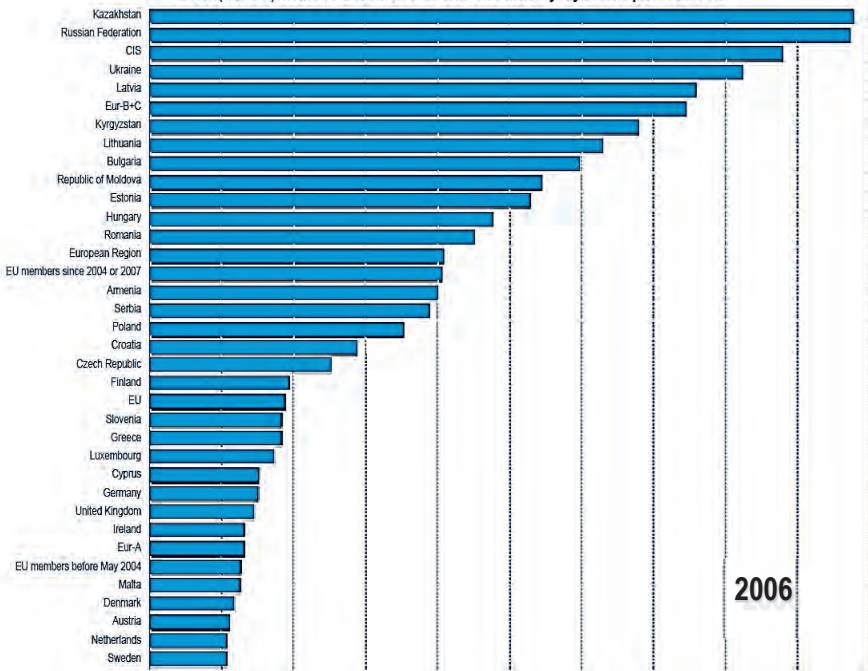
## THE PLAN

- Introduction – prevalence of VD
- Specific Symptoms & Signs (Pain, Changes in skin temperature and color, Edema, Ulceration, Emboli, Stroke, Dizziness)
- Complaints – PAIN! heaviness in the arms and legs swelling, cramping, fatigue, constant coldness of the skin, hearing loss, pains in the limbs with a load or walking, the appearance of spider, heaviness in the legs, veins expansion of the saphenous veins
- Risk factors
- Arterial stiffness
- EARLY vessels Aging - EVA-syndrome
- The physical examination of the peripheral vascular system – Inspection, Examination of the arterial pulses, Examination of the lymphatic
- system, Other special techniques
- Vascular pathology: signs – Cyanosis, Stokes Collar, Carotid Dance, Bulging of the neck veins, (Swelling), Wire pulse, «Worm» Sign, Kwinke pulse, Hippocratic Fingers, Randu-Osler Sign, Osler nodes, Osler Sign, Pulselessness, Epigastric pulsation, Expansion of the veins on the chest, abdomen, limbs
- Technique for evaluating the radial artery pulses
- Grading of Pulse
- Pulse Properties
- BP: That? Where? How? to measure and analyze....
- References



Age standardised  
CHD mortality  
rates (under 65)  
in men &  
women

SDR(45-59),males, Diseases of the circulatory system, per 100000





Harvey Williams Cushing, 1869-1939





## Review of Specific Symptoms

- Many patients with peripheral vascular disease are asymptomatic
- When patients are symptomatic, vascular disease causes the following:
  - Pain
  - Changes in skin temperature and color
    - Edema
  - Ulceration
    - Emboli
    - Stroke
  - Dizziness

## Vascular pathology: Complaints...

- PAIN!
- heaviness in the arms and legs
- swelling
- cramping
- fatigue
- constant coldness of the skin
- hearing loss
- pains in the limbs with a load or walking
- the appearance of spider
- heaviness in the legs
- veins expansion of the saphenous veins



**PAIN !!!**

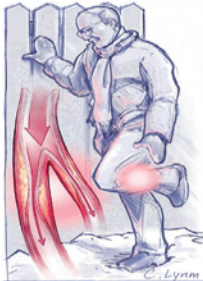## PERIPHERAL VASCULAR DISEASE

### PERIPHERAL ARTERIAL DISEASE

Peripheral vascular disease (PVD) is commonly caused by atherosclerosis and usually affects the aorto-iliac or infra-inguinal arteries. It is present in 7% of middle-aged men and 4.5% of middle-aged women, but these patients are more likely to die of myocardial infarction or stroke than lose their leg.

Limb ischaemia may be classified as chronic or acute.

<span style="font-size: 2em; font-weight: bold; color: white;">i</span> Factors influencing the clinical manifestations of peripheral arterial disease
<b>Anatomical site</b>
<b>Cerebral circulation</b> <ul style="list-style-type: none"> <li>• TIA, amaurosis fugax, vertebrobasilar insufficiency</li> </ul>
<b>Renal arteries</b> <ul style="list-style-type: none"> <li>• Hypertension and renal failure</li> </ul>
<b>Mesenteric arteries</b> <ul style="list-style-type: none"> <li>• Mesenteric angina, acute intestinal ischaemia</li> </ul>
<b>Limbs (legs <math>\gg</math> arms)</b> <ul style="list-style-type: none"> <li>• Intermittent claudication, critical limb ischaemia, acute limb ischaemia</li> </ul>
<b>Collateral supply</b>
<ul style="list-style-type: none"> <li>• In a patient with a complete circle of Willis, occlusion of one carotid artery may be asymptomatic</li> <li>• In a patient without cross-circulation, stroke is likely</li> </ul>
<b>Speed of onset</b>
<ul style="list-style-type: none"> <li>• Where PAD develops slowly, a collateral supply will develop</li> <li>• Sudden occlusion of a previously normal artery is likely to cause severe distal ischaemia</li> </ul>



Lameness = claudicating intermittence



### Mechanism of injury

#### Haemodynamic

- Plaque must reduce arterial diameter by 70% ('critical stenosis') to reduce flow and pressure at rest. On exertion (e.g. walking), a much lesser stenosis may become 'critical'. This mechanism tends to have a relatively benign course due to collateralisation

#### Thrombotic

- Occlusion of a long-standing critical stenosis may be asymptomatic due to collateralisation. However, acute rupture and thrombosis of a non-haemodynamically significant plaque usually has severe consequences

#### Atheroembolic

- Symptoms depend upon embolic load and size
- Carotid (TIA, amaurosis fugax or stroke) and peripheral arterial (blue toe/finger syndrome) plaque are common examples

#### Thromboembolic

- Usually secondary to atrial fibrillation
- The consequences are usually dramatic, as the thrombus load is often large and occludes a major, previously healthy, non-collateralised artery suddenly and completely

## Patients with high or very high cardiovascular risk ...? Who are they?



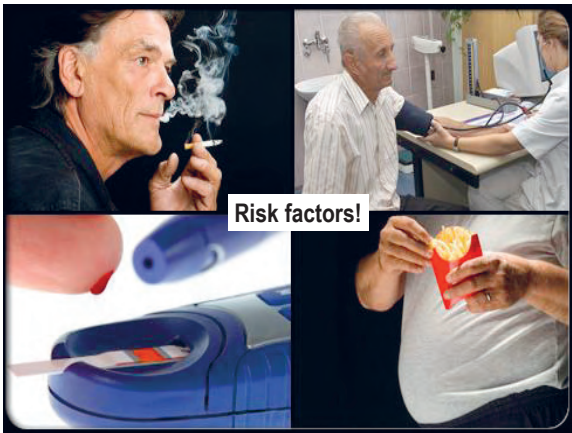**Risk factors!**





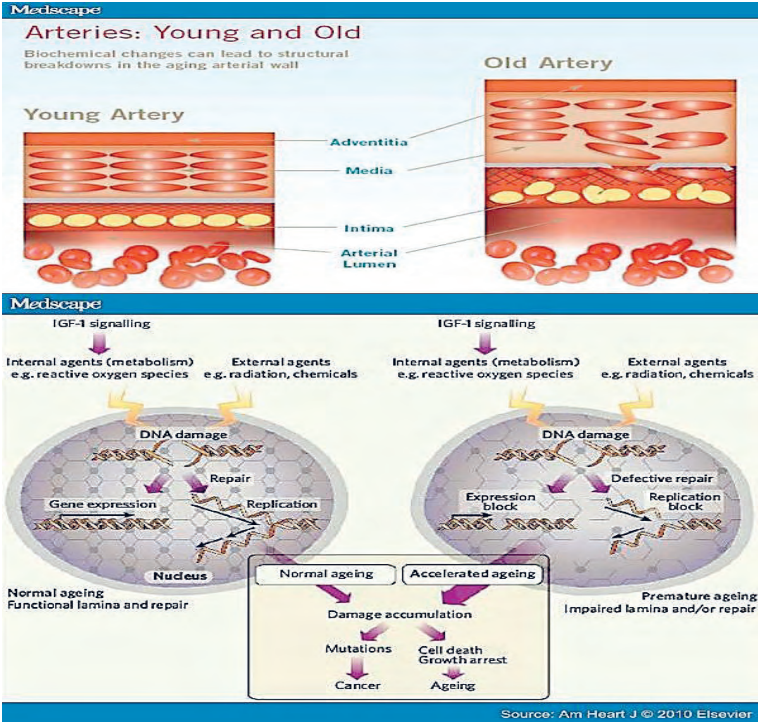
## ARTERIAL STIFFNESS

- EARLY vessels Aging – EVA-syndrome
- Atherosclerosis

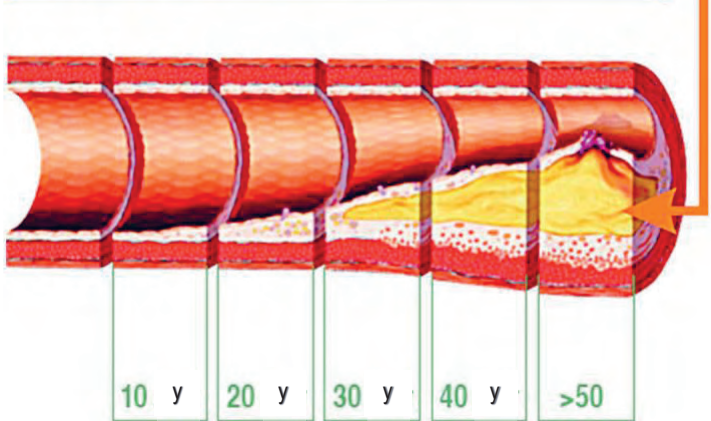


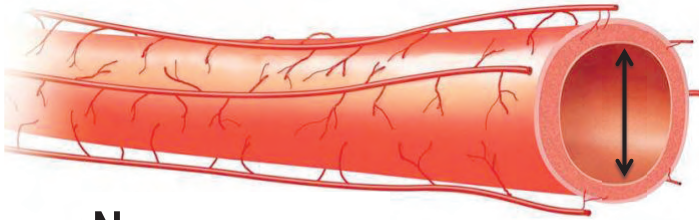
Is smoking medicine from stress ?



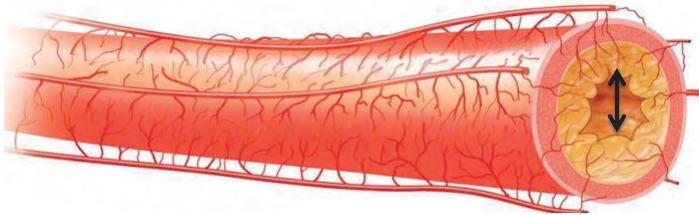


# Atherosclerosis

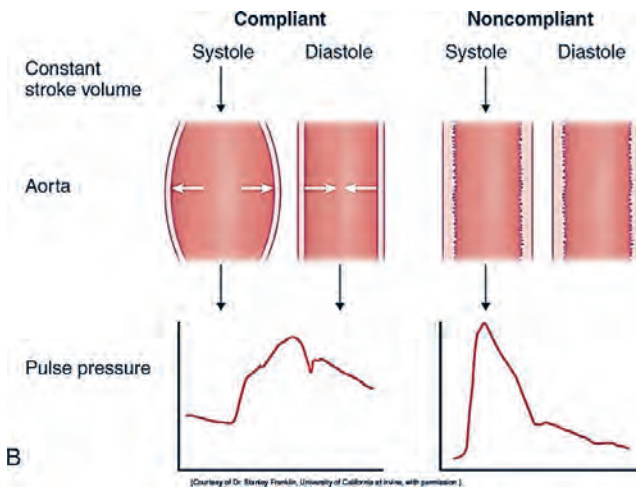




N



## Atherosclerosis



**Aging and pulse pressure. A,** Age-dependent changes in systolic and diastolic blood pressure in the United States. (From Burt V, Whelton P, Rocella EJ, et al: Prevalence of hypertension in the U.S. adult population. Results from the Third National Health and Nutrition Examination Survey, 1988–1991. *Hypertension* 1995;25:305–313.)

**B,** Schematic diagram showing the relation between aortic compliance and pulse pressure. (Courtesy of Dr. Stanley Franklin, University of California at Irvine, with permission.)

## THE PHYSICAL EXAMINATION OF THE PERIPHERAL VASCULAR SYSTEM

The **equipment** necessary for the examination of the peripheral vascular system consists of a stethoscope, a tourniquet, and a tape measure

The physical examination of the peripheral vascular system consists of inspection, palpation of the arterial pulses, and some additional tests if disease is thought to be present

All these techniques are usually integrated with the rest of the physical examination

**The patient lies supine**, with the examiner standing to the right of the bed.

The evaluation of the peripheral vascular system includes the following:

- Inspection
- Examination of the arterial pulses
- Examination of the lymphatic system
- Other special techniques

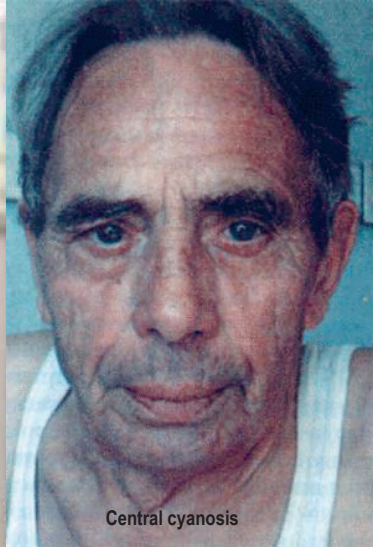## VASCULAR PATHOLOGY: SIGNS

- Cyanosis
- Stokes Collar
- Carotid Dance
- Bulging of the neck veins (Swelling)
- Wire pulse
- «Worm» Sing
- Kwinke pulse
- Hippocratic Fingers
- Randu-Osler Sing
- Osler nodes
- Osler Sing
- Pulselessness
- Epigastric pulsation
- Expansion of the veins on the chest, abdomen, limbs





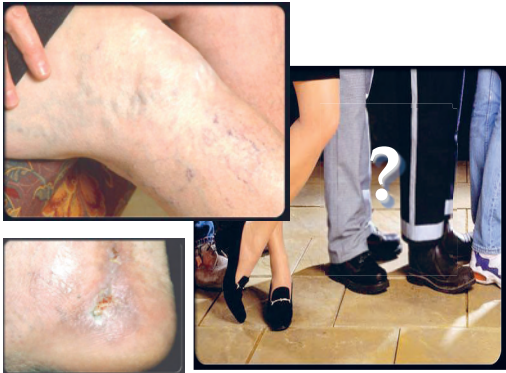
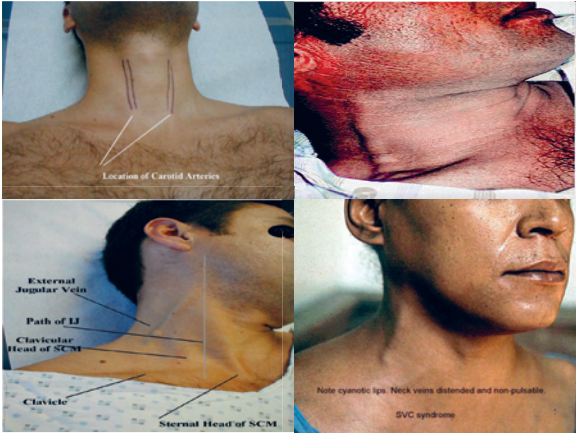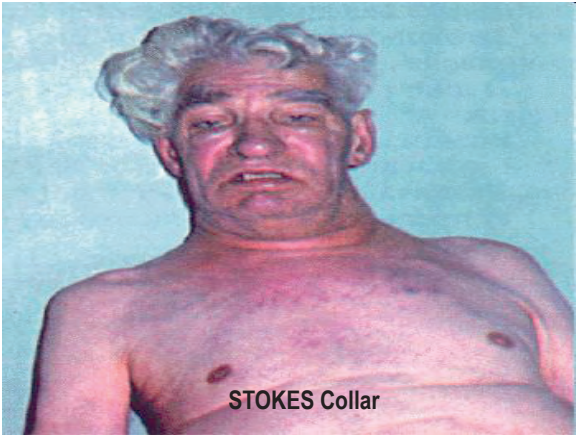
Peripheral cyanosis

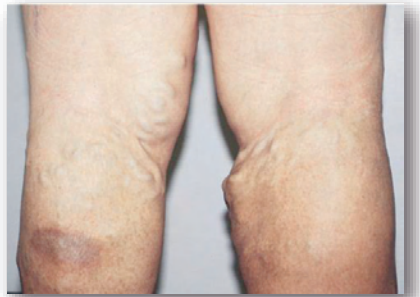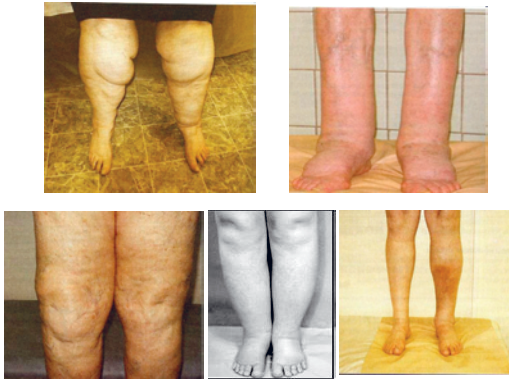


Central cyanosis

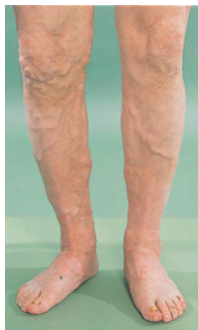

Pavlov A.F.  
Portrait of I.P. Pavlov.  
1945

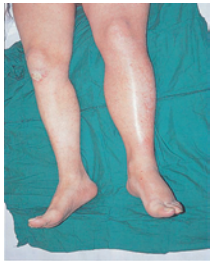
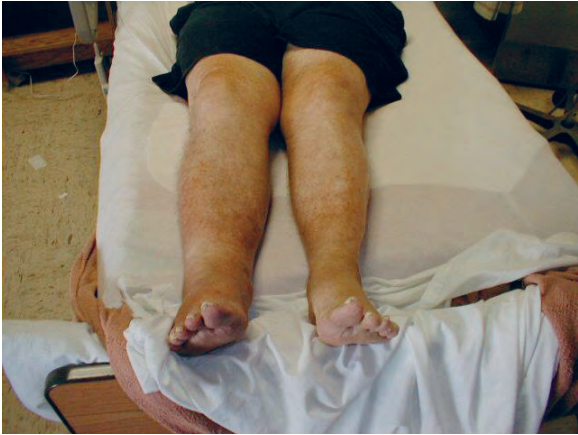


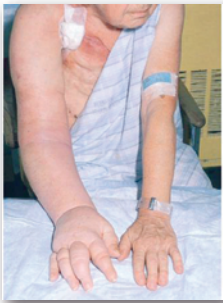**Marked  
varicosities of the popliteal fossa**



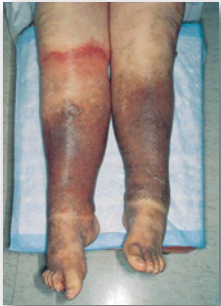**Varicose veins are a risk factor for deep venous thrombosis and may result from it.**  
(From Forbes CD, Jackson WF: Color Atlas and Text of Clinical Medicine, 3rd ed. London, Mosby, 2003, with permission.)



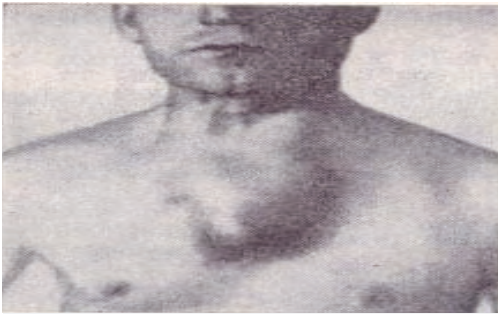
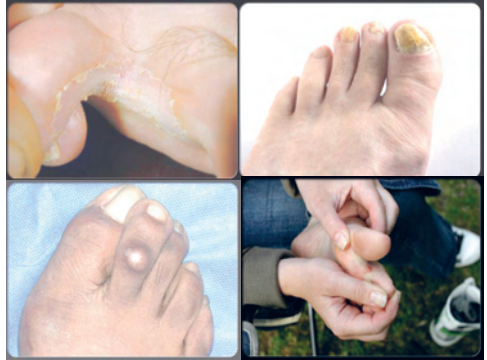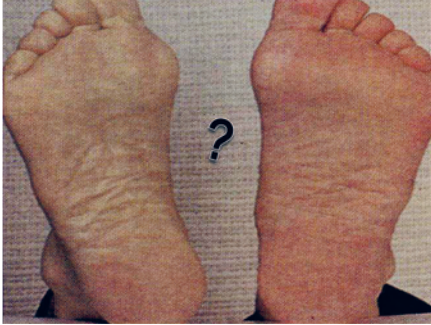**Deep venous thrombosis (DVT) presenting as an acutely swollen left leg.** Note the dilation of the superficial veins. The leg was hot to the touch, and palpation along the line of the left popliteal and femoral veins caused pain. Less than 50% of DVTs present in this way, and other conditions may mimic DVT, so further investigation is always indicated. Note the coincidental psoriatic lesion below the patient's right knee. (From Forbes CD, Jackson WF. Color Atlas and Text of Clinical Medicine, 3rd ed. London, Mosby, 2003, with permission.)



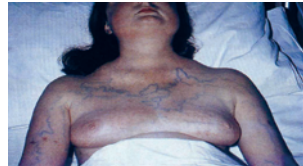**Lymphedema**



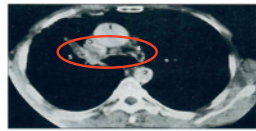
**Chronic venous insufficiency**



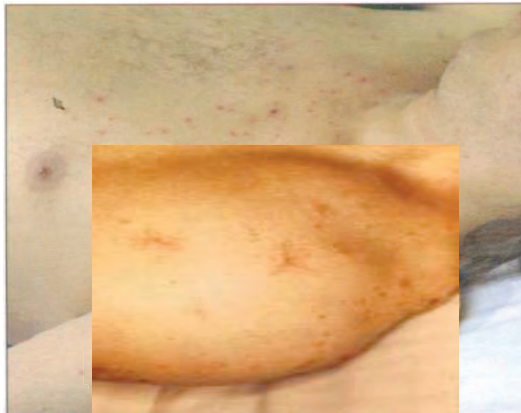Thrusting out - is aneurysm of aorta  
(bulging and throbbing)

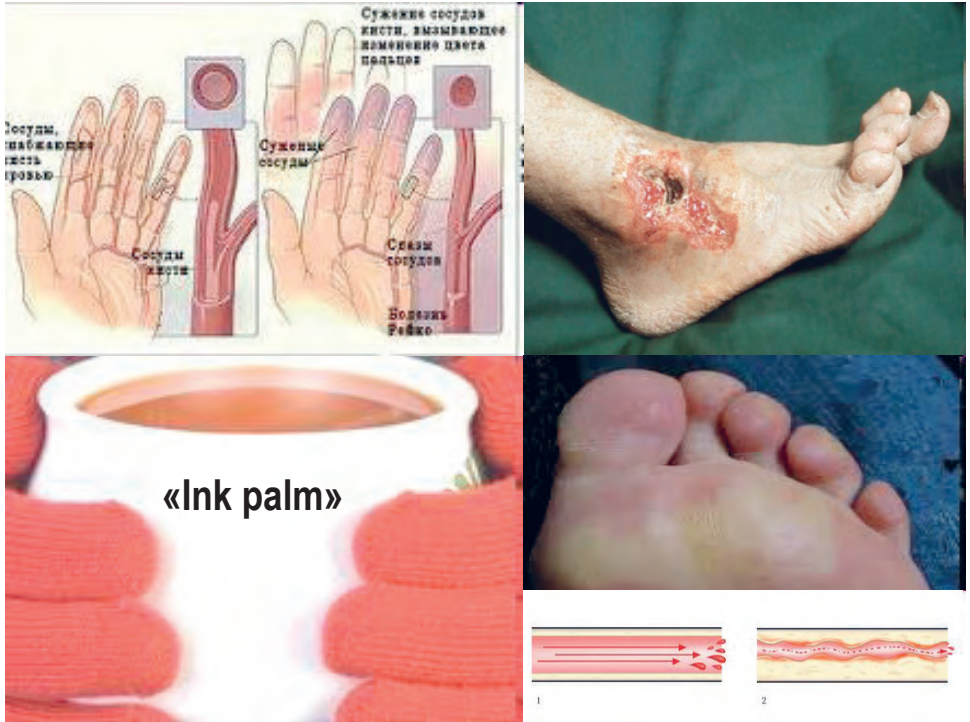

Bronchial cancer



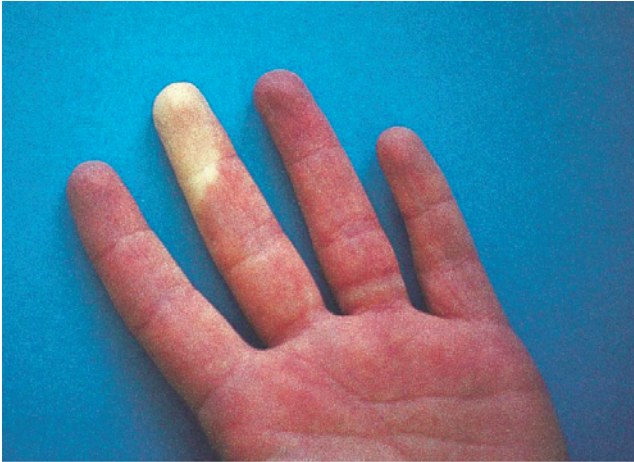CT





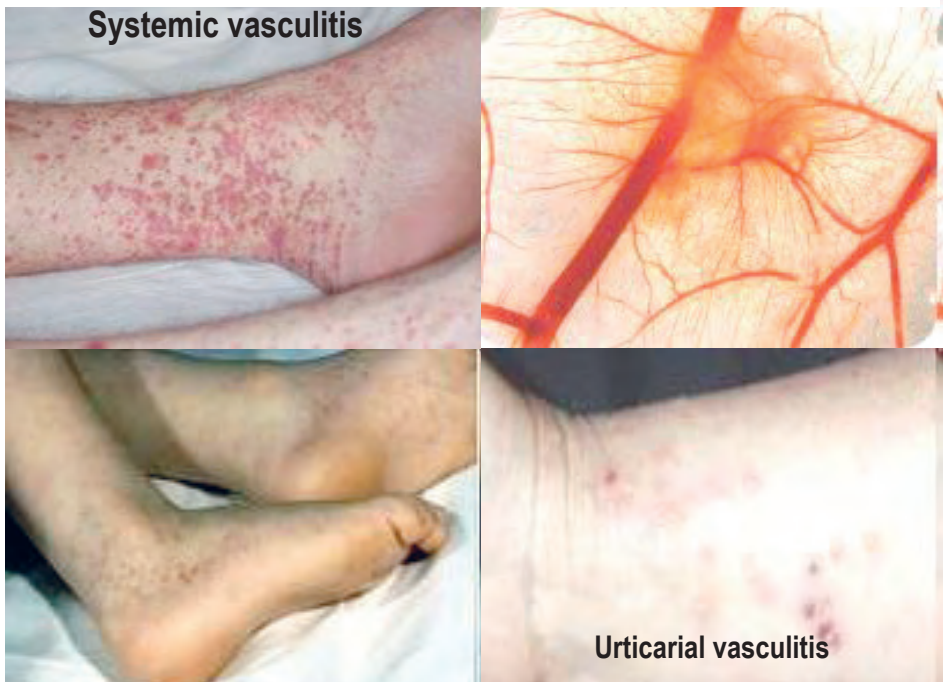
## Raynaud's phenomenon and Raynaud's disease

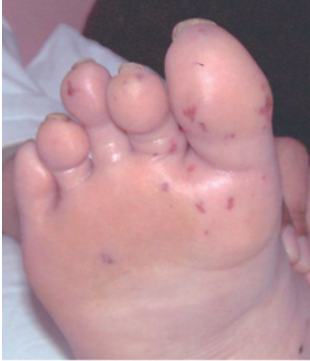Cold (and emotional) stimuli may trigger vasospasm, leading to the characteristic sequence of digital pallor due to vasospasm, cyanosis due to deoxygenated blood, and rubor due to reactive hyperaemia.



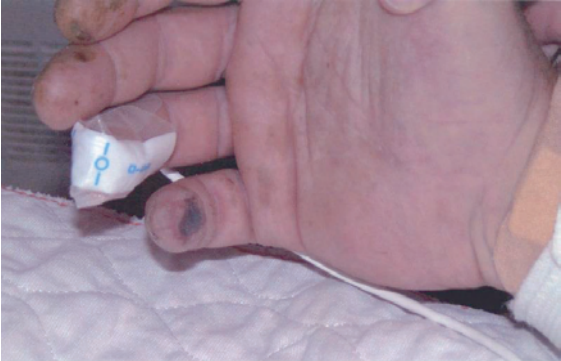(From Forbes CD, Jackson WF: Color Atlas and Text of Clinical Medicine, 3rd ed. London, Mosby, 2003.)

**Raynaud's phenomenon in the acute phase, with severe blanching of the tip of one finger.** (From Forbes CD, Jackson WF: Color Atlas and Text of Clinical Medicine, 3rd ed. London, Mosby, 2003.)

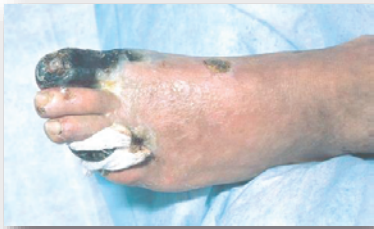



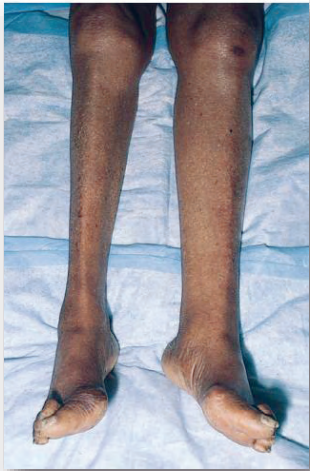Petechiae in infective endocarditis



Osler's node in infective endocarditis



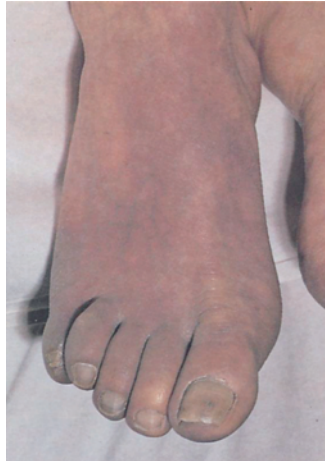
Diabetic gangrene



Deep vein thrombosis, left leg

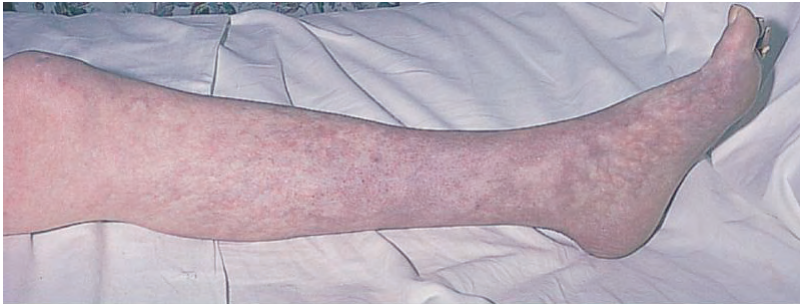

Symptoms and signs of acute limb ischaemia	
Symptoms/signs	Comment
Pain	} May be absent in complete acute ischaemia, and can be present in chronic ischaemia
Pallor	
Pulselessness	
Perishing cold	Unreliable, as the ischaemic limb takes on the ambient temperature
Paraesthesia	} Important features of impending irreversible ischaemia
Paralysis	



(From Forbes CD, Jackson WF: Color Atlas and Text of Clinical Medicine, 3rd ed. London, Mosby, 2003, with permission.)

**Critical ischemia of the foot.** The patient had a sudden onset of foot discomfort, with coldness and loss of sensation in the toes and the dorsum of the foot. He had previously suffered from intermittent claudication and has evidence of chronic ischemia, including absence of hair and thinness of the skin. Arteriography is necessary to define the nature of the lesion. (From Forbes CD, Jackson WF: Color Atlas and Text of Clinical Medicine, 3rd ed. London, Mosby, 2003, with permission.)




(From Forbes CD, Jackson WD: Color Atlas and Text of Clinical Medicine, 3rd ed. London, Mosby, 2003, with permission.)

**Arterial embolism causing acute ischemia and cyanosis of the leg.**

Initial pallor of the leg and foot was followed by cyanosis.

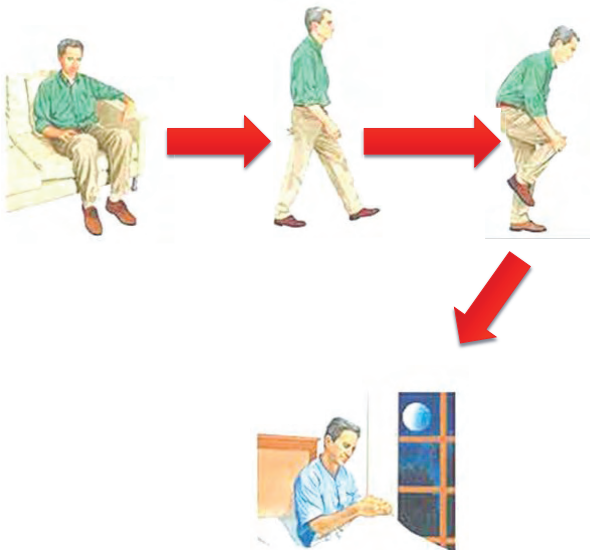
(From Forbes CD, Jackson WD: Color Atlas and Text of Clinical Medicine, 3rd ed. London, Mosby, 2003, with permission.)

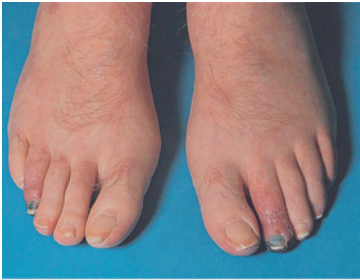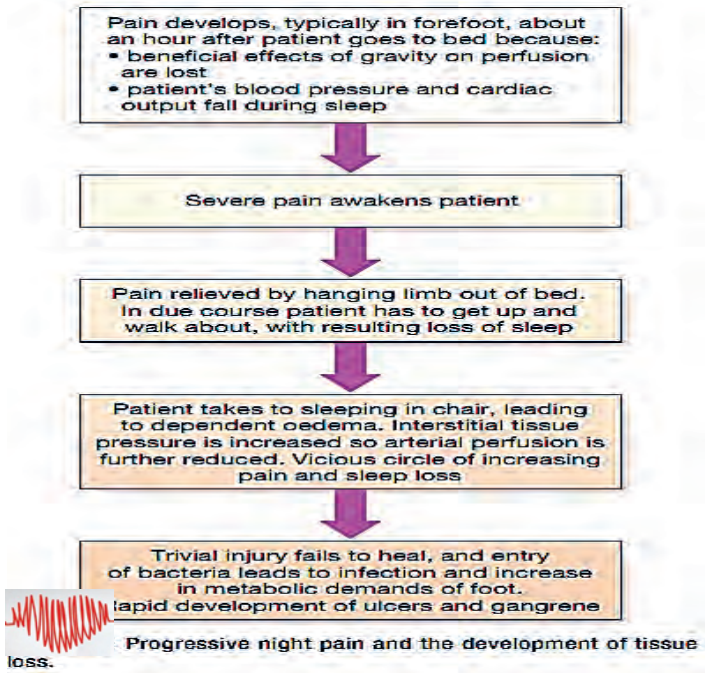
 <b>Acute limb ischaemia: distinguishing features of embolism and thrombosis in situ</b>		
Clinical features	Embolism	Thrombosis in situ
<b>Severity</b>	Complete (no collaterals)	Incomplete (collaterals)
<b>Onset</b>	Seconds or minutes	Hours or days
<b>Limb</b>	Leg 3:1 arm	Leg 10:1 arm
<b>Multiple sites</b>	Up to 15%	Rare
<b>Embolic source</b>	Present (usually atrial fibrillation)	Absent
<b>Previous claudication</b>	Absent	Present
<b>Palpation of artery</b>	Soft, tender	Hard, calcified
<b>Bruits</b>	Absent	Present
<b>Contralateral leg pulses</b>	Present	Absent
<b>Diagnosis</b>	Clinical	Angiography
<b>Treatment</b>	Embolectomy, warfarin	Medical, bypass, thrombolysis
<b>Prognosis</b>	Loss of life > loss of limb	Loss of limb > loss of life



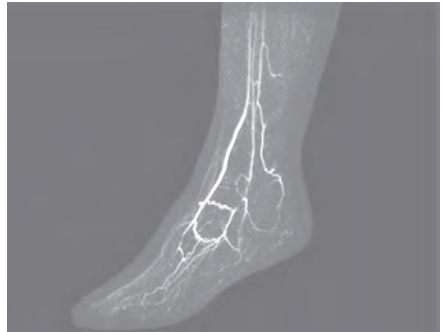## Clinical features of chronic lower limb ischaemia

- Pulses: diminished or absent
- Bruits: denote turbulent flow but bear no relationship to the severity of the underlying disease
- Reduced skin temperature
- Pallor on elevation and rubor on dependency (Buerger's sign)
- Superficial veins that fill sluggishly and empty ("gutter") upon minimal elevation
- Muscle-wasting
- Skin and nails: dry, thin and brittle
- Loss of hair





Typical dry gangrene of two toes in a patient with diffuse atheroma. The patient had a history of intermittent claudication. Note the chronic nail changes that are also seen (resembling onycholysis). The residual hair on the dorsum of the feet is unusual in chronic ischemia; usually the hair is lost. (From Forbes CD, Jackson WF. Color Atlas and Text of Clinical Medicine, 3rd ed. London, Mosby, 2003, with permission.)

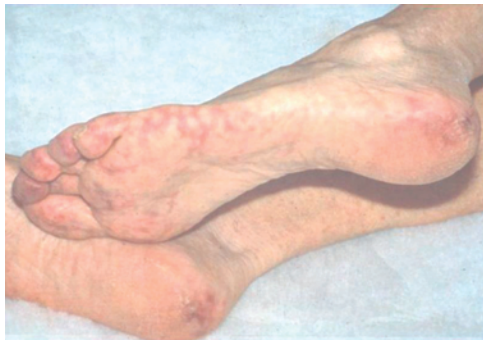

Non CE arterial flowFlow Spoiled FBI, a contrast-free technique, demonstrates slower arterial flow in a diabetic foot

## Chronic upper limb arterial disease

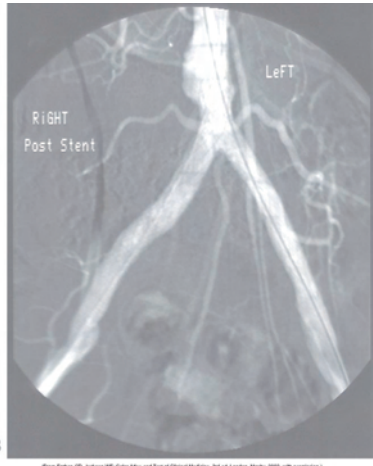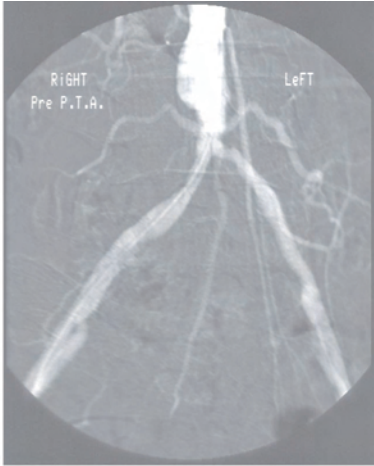
In the arm, the subclavian artery is the most common site of disease, which may manifest as:

- *Arm claudication* (rare).
- *Atheroembolism* (blue finger syndrome). Small emboli lodge in digital arteries and may be confused with Raynaud's phenomenon (see below) but, in this case, the symptoms are unilateral. Failure to make the diagnosis may eventually lead to amputation.
- *Subclavian steal*. When the arm is used, blood is 'stolen' from the brain via the vertebral artery. This leads to vertebro-basilar ischaemia, which is characterised by dizziness, cortical blindness and/or collapse. Where possible, subclavian artery disease is treated by means of angioplasty and stenting, as surgery (e.g. carotid-subclavian bypass) can be difficult.

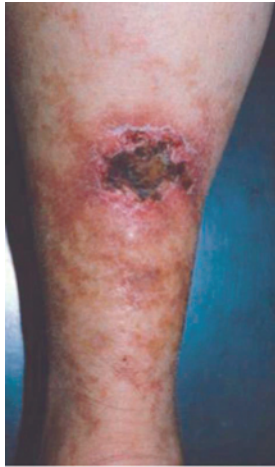

(From Bartholomew JR, Olin JW: Atheromatous embolization. In Young JR, Olin JW, Bartholomew JR [eds]: Peripheral Vascular Diseases, 2nd ed. St. Louis, Mosby, 1996.)

Typical livedo reticularis on the lateral portion of the left foot and both heels. The second and fourth toes are cyanotic. These findings are typical of atheromatous embolization, and the fact that both feet are involved indicates a source above the aortic bifurcation. (From Bartholomew JR, Olin JW: Atheromatous embolization. In Young JR, Olin JW, Bartholomew JR [eds]: Peripheral Vascular Diseases, 2nd ed. St. Louis, Mosby, 1996.)

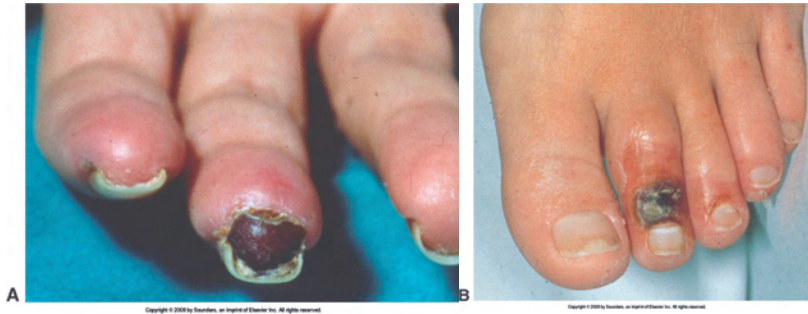

**Percutaneous transluminal angioplasty (PTA) may be used in peripheral vascular disease.** A, Significant narrowing of the aortic bifurcation and both common iliac arteries. The narrowing in both common iliac arteries was successfully treated by angioplasty, and bilateral stents were inserted to maintain patency (B). The patient had presented with bilateral calf claudication, which was relieved by this procedure. (From Forbes CD, Jackson WF: Color Atlas and Text of Clinical Medicine, 3rd ed. London, Mosby, 2003, with permission.)



Copyright © 2008 by Saunders, an imprint of Elsevier Inc. All rights reserved.

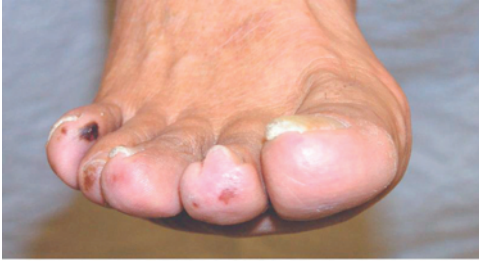**Livedoid vasculitis.** Ischemic ulceration is evident on the posterior portion of the calf surrounded by a livedoid pattern to the skin.



**Buerger's disease.** Ischemic finger of a young male patient (A) and ischemic toe of a 28-year-old woman (B) with Buerger's disease

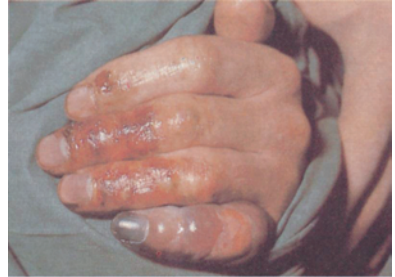### ***Buerger's disease (thromboangiitis obliterans)***

This is an inflammatory obliterative arterial disease that is distinct from atherosclerosis and usually presents in young (20–30 years) male smokers. It is most common in those from the Mediterranean and North Africa. It characteristically affects distal arteries, giving rise to claudication in the feet or rest pain in the fingers or toes. Wrist and ankle pulses are absent but brachial and popliteal pulses are present. Disease also affects the veins, giving rise to superficial thrombophlebitis. It often remits if the patient stops smoking; sympathectomy and prostaglandin infusions may be helpful. Major limb amputation is the most frequent outcome if patients continue to smoke.



Copyright © 2008 by Saunders, an imprint of Elsevier Inc. All rights reserved.

**Pernio on the toes of the right foot.** The lesions on the second, third, and fourth toes are the typical red, brown, and yellow scaling lesions. The lesion on the fifth toe can be confused with atheromatous embolization



© Alan Pollack MD, Jackson WF, Color Atlas and Text of Clinical Medicine, 3rd ed. London, Mosby, 2003.

**Frostbite of the hand in a mountaineer.** On rewarming, the hand became painful, red, and edematous, with signs of probable gangrene in the fifth finger. (From Forbes CD, Jackson WF: Color Atlas and Text of Clinical Medicine, 3rd ed. London, Mosby, 2003.)



**The Doctor's Visit**  
Frans Van Mieris, THE ELDER, 1657  
Kunsthistorisches Museum, Vienna

The doctor feeling the pulse of his patient has always been a popular subject in expressive art. For thousands of years, palpation of the pulse was the only diagnostic tool of the physician. The earliest miniatures depicting this clinical examination may be seen in Arabic manuscripts of about the 10th century onwards.



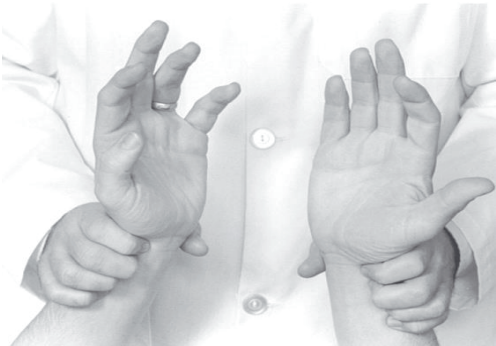
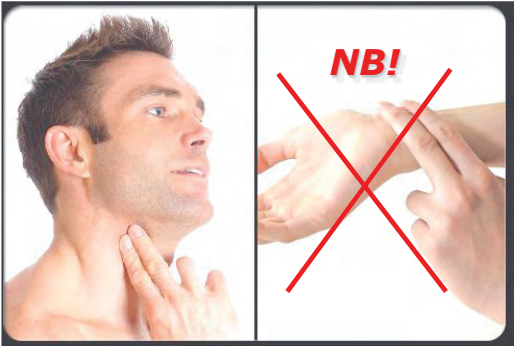Ancient Chinese diagnostics:

HOW to study properties of the pulse... by Chinese doctors even during the reign of Emperor Huang Ti (2698-2598 BC)



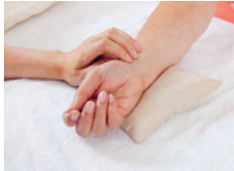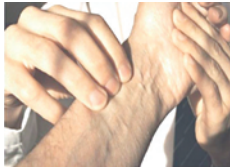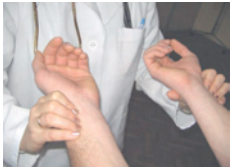**PULSE=Jerky arterial wall oscillations associated with heart cycles**



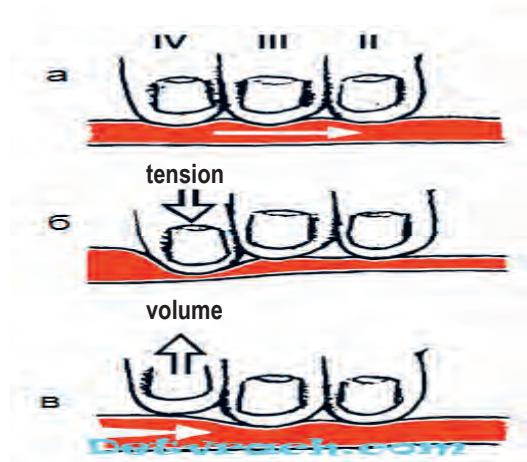


Technique for evaluating the radial artery pulses

- The rate and rhythm of the heart
- The contour of the pulse
- The amplitude of the pulse

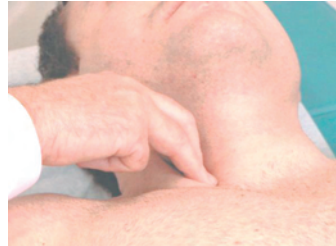
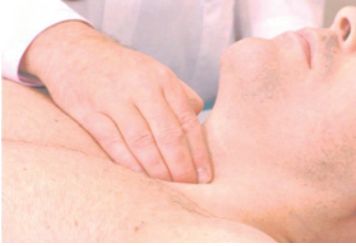
## Determination of tension and volume of pulse

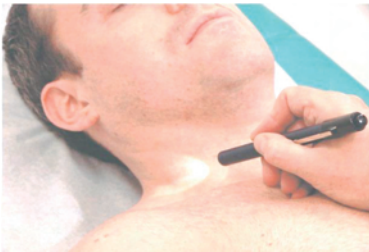

### Examination of the arterial pulse.

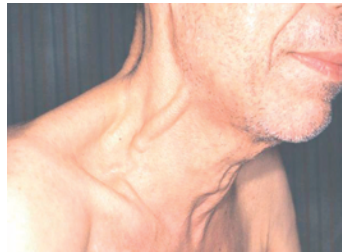Examination sequence	Factors that cause pulse characteristics	Norm	Pathology
Symmetry on the pair arteries	Degree of arteries filling	Symmetric	Asymmetrical <i>p. differens</i>
Rhythm	Cardiac activity	Rhythmic <i>p. regularis</i>	Arrhythmic <i>p. irregularis</i>
Rate (PR)	Heart rate (HR)	60–80 beats per minute (b.p.m.)	Frequent – <i>p. frequens</i> , Rare – <i>p. rarus</i>
Correlation between PR and HR	Contractile ability of the heart	HR = PR	HR > PR – pulse deficit <i>p. dificiens</i>
Tension	BP level in the greater circulation	Sufficient tension	Soft (BP low) – <i>p. mollis</i> Firm (BP high) – <i>p. durus</i>
Volume	Volume of circulating blood	Sufficient volume	Large volume – <i>p. plenus</i> Empty or low volume – <i>p. vacuus</i>
Size	Stroke volume, arteries filling	Moderate size	Large – <i>p. magnus</i> High – <i>p. altus</i> Small – <i>p. parvus</i> Thready – <i>p. filiformis</i>
Speed	Speed of pressure changes in the arteries	Moderate speed	Fast – <i>p. celer</i> Slow – <i>p. tardus</i>
Shape	Stroke volume, velocity of the BP changes during systole and diastole	Moderate size and velocity, uniform – <i>p. aequalis</i>	Fast ( <i>p. celer</i> ) and high ( <i>p. altus</i> ) Slow ( <i>p. tardus</i> ) and small ( <i>p. parvus</i> ) Nonuniform – <i>p. inaequalis</i> Variable – <i>p. alternans</i>




Technique for evaluating the carotid artery pulsations



Technique for evaluating the jugular wave forms

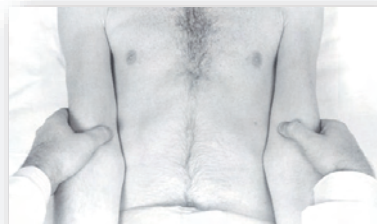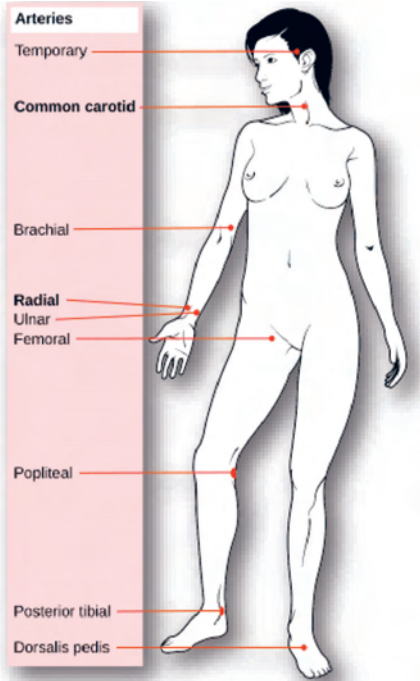
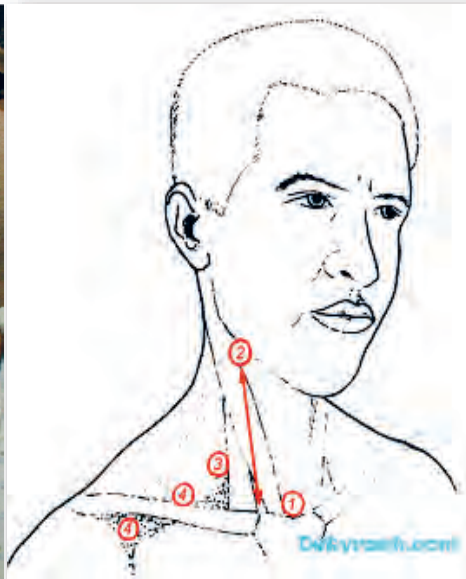
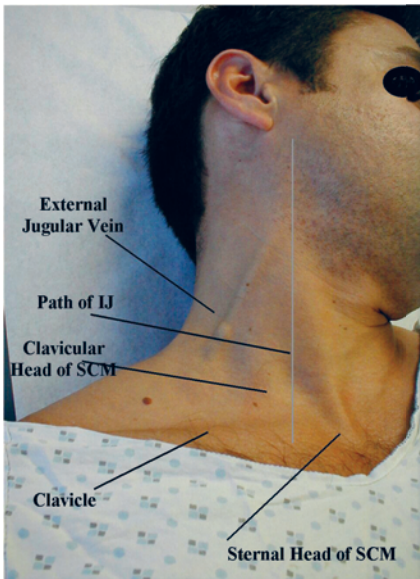


Neck vein distention

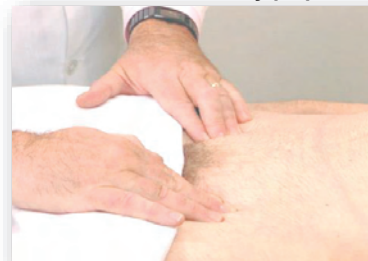 Differentiation of Jugular and Carotid Pulses

Feature	Internal Jugular Pulse	Carotid Pulse
Palpation	Not palpable	Palpable
Waveforms	Multiform: two or three components	Single
Quality	Soft, undulating	Vigorous
Pressure*	Wave forms obliterated	No effect
Inspiration	Decreased height of wave forms	No effect
Sitting up	Decreased height of wave forms	No effect
Valsalva maneuver	Increased height of wave forms	No effect

\*Light pressure on the vessel above the sternal end of clavicle.

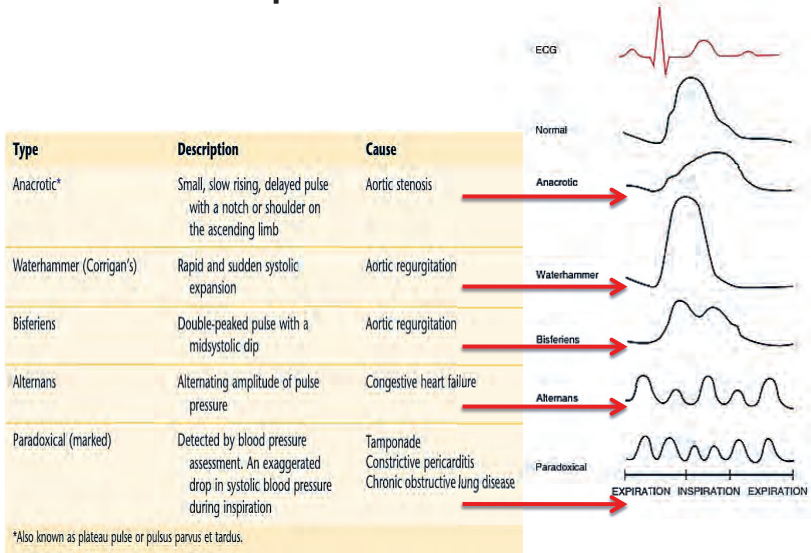


Technique for brachial artery palpation



Technique for palpation of the femoral arteries

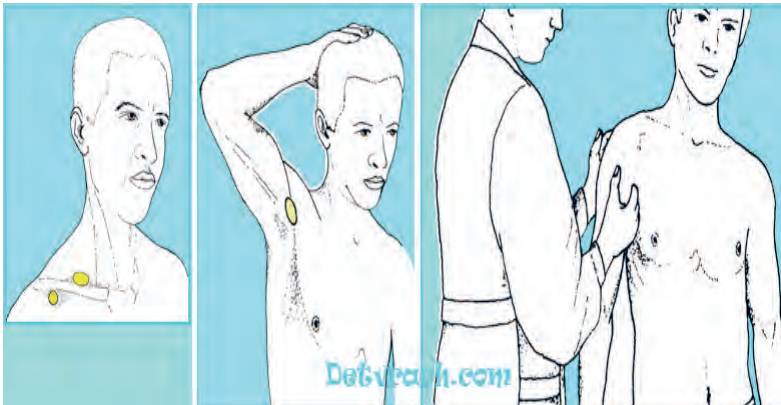
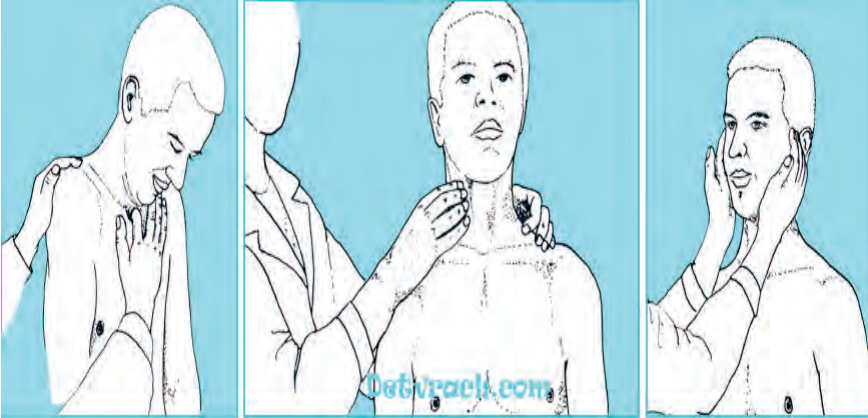## Arterial pulse abnormalities. ECG

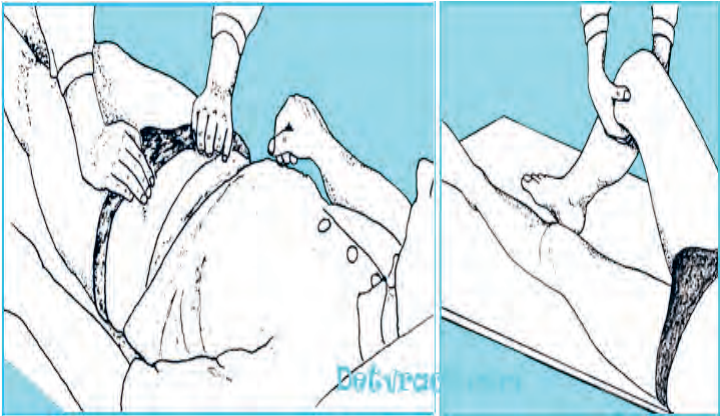
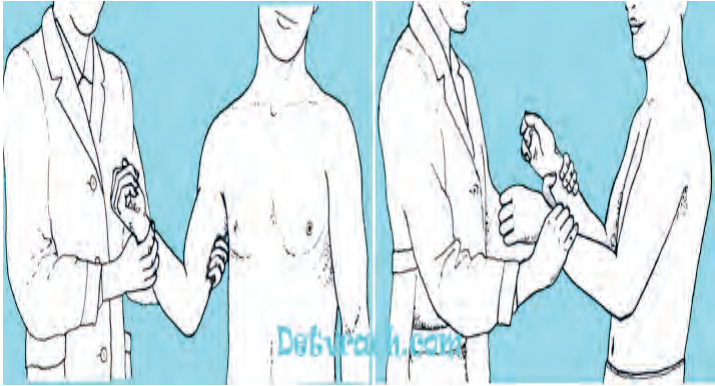


## Grading of Pulse

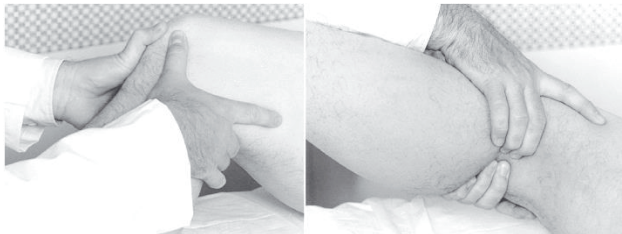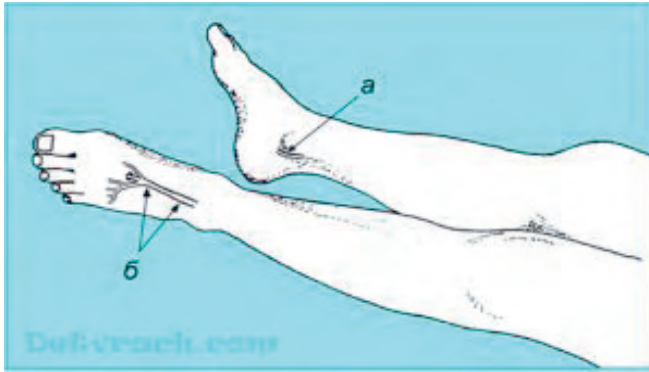
The description of the amplitude of the pulse is most important. The following is the most widely accepted grading system:

- 0 Absent
- 1 Diminished
- 2 Normal
- 3 Increased
- 4 Bounding

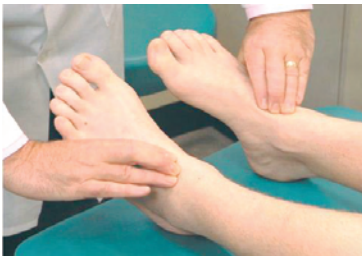




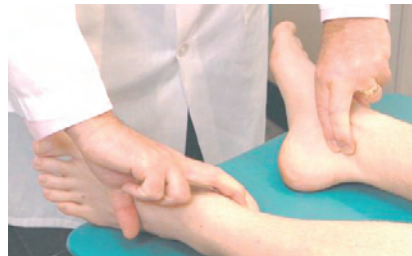


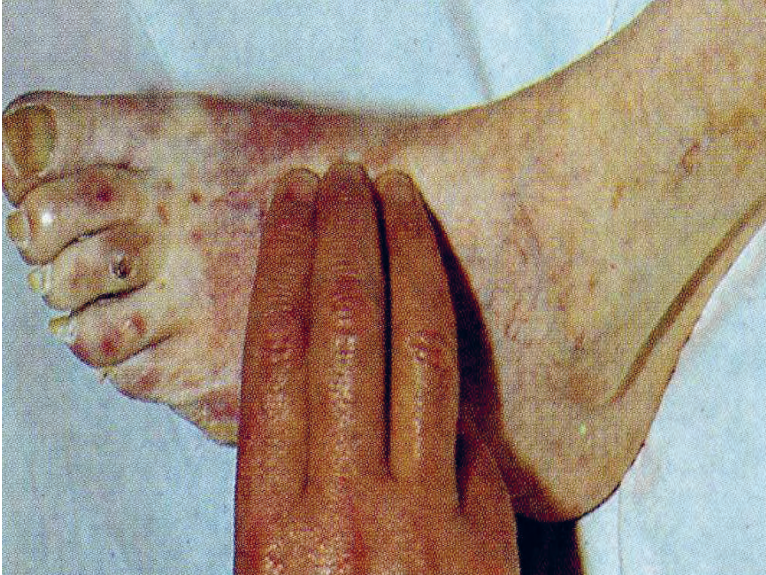Technique for palpation of the popliteal artery. A, Correct position of the hands from the front. B, View from behind the popliteal fossa



Technique for palpation of the dorsalis pedis arteries



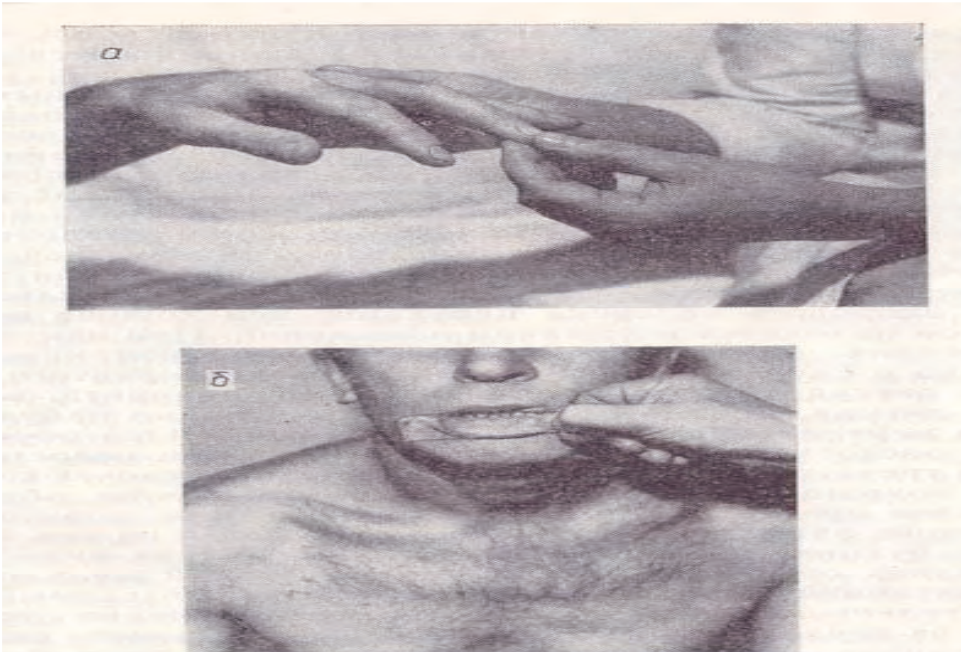
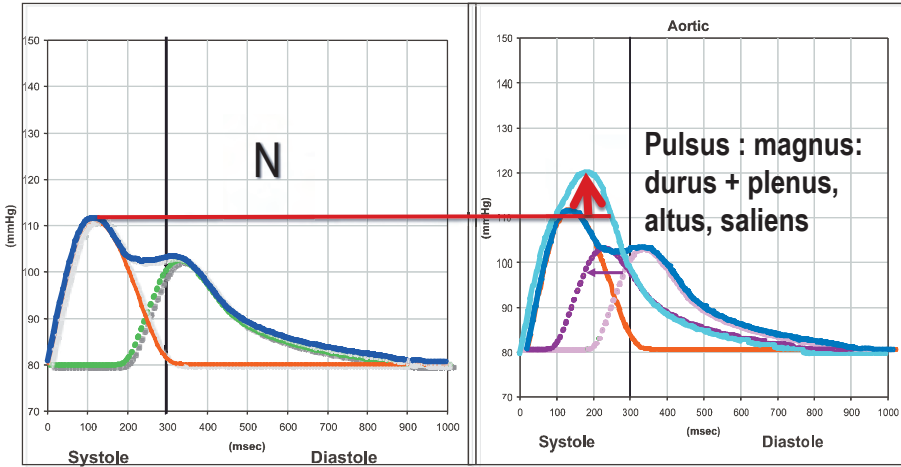
Technique for palpation of the posterior tibial arteries



## • Pulse Properties

- same (different)
- rhythm (regular, irregular)
- frequency (frequent, liquid)
- filling (full, empty)
- voltage (solid, soft, moderate voltage)
- magnitude (large, small, threadlike)
- speed (fast, slow)
- the ratio of heart rate and pulse rate (pulse deficit)
  
- **Pulsation:** aorta, trunk of the pulmonary artery, sleepy, temporal, subclavian, femoral, popliteal arteries, arteries of the foot
- **Vinous pulse:** negative, positive

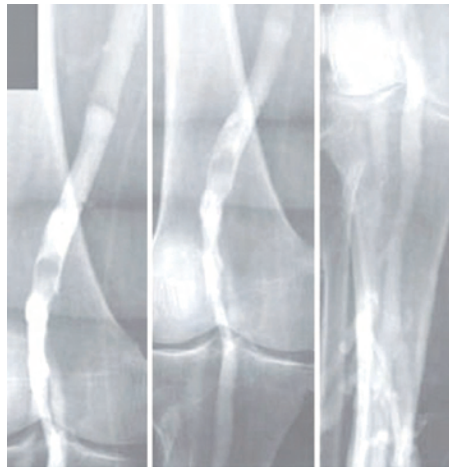
# Arterial pulse: physiology and pathology



**Kwinke Pulse**

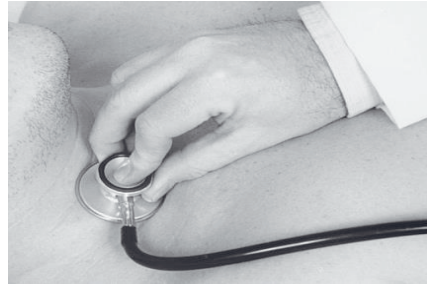## Takayasu's disease

This is rare, except in Japan. It is known as the pulseless disease or aortic arch syndrome. It is of unknown aetiology and occurs in females. There is a vasculitis involving the aortic arch as well as other major arteries. There is also a systemic illness, with pain and tenderness over the affected arteries. Absent peripheral pulses and hypertension are common. Corticosteroids help the constitutional symptoms. Eventually heart failure and strokes may occur but most patients survive for at least 5 years. Treatment may require a surgical bypass to improve perfusion of the affected areas.

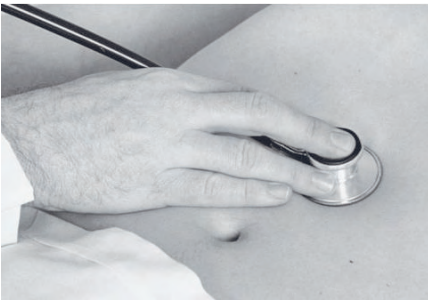


Copyright © 2008 by Saunders, an imprint of Elsevier Inc. All rights reserved.

**Abnormal venogram demonstrates a persistent (two or more different views) intraluminal filling defect in the popliteal vein**



Technique for auscultation  
of the carotid artery



Technique for  
auscultation of the abdominal  
aorta

## Pathology of vessels: syndromes

### Systemic | local

- Acute vascular failure: shock, collapse, fainting
- Chronic vascular insufficiency: arterial, venous
- Acute|Chronic lower limb ischemia
- Acute|Chronic upper limb ischemia
- Aneurysm s.
- High blood pressure
- Low blood pressure
- Venous hypertension
- Raynaud's s.


The study of the dynamics of blood circulation was first started by the English theologian and naturalist Stephen Hales (Stephen Hales, 1667-1761)



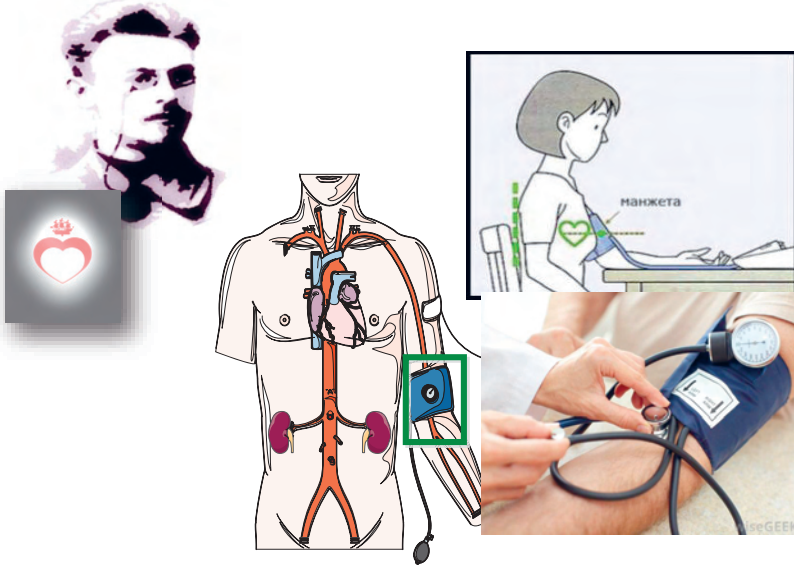
In 1731, he first measured the blood pressure of a horse, entering the glass tube directly into the artery. The blood column in the tube rose exactly eight feet and three inches above horse's left



**Scipione Riva-Rocci,  
1863-1937**



### Auscultative method of measuring blood pressure N.S. Korotkov - 1905!



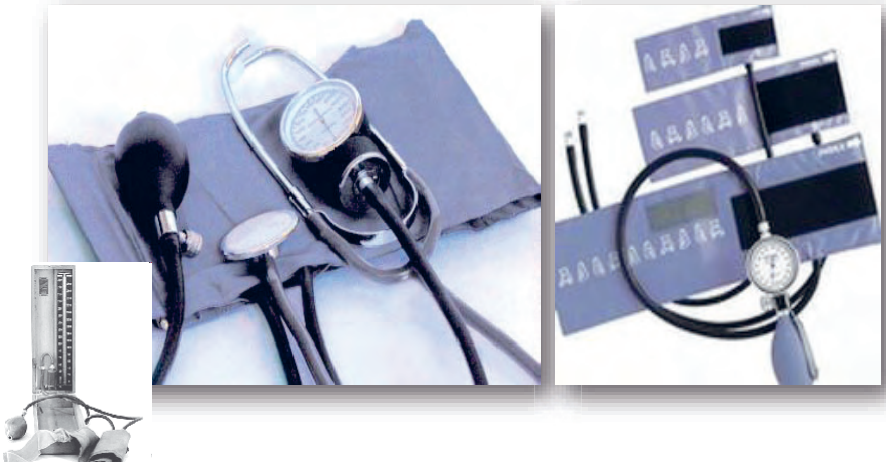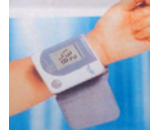Measure the circumference of the arm (at the mid arm level) and ensure that the correct size of arm cuff is used

- For arms with circumference < 32 cm, use regular cuff
- For arms with circumference 32-42 cm, use large cuff
- For arms with circumference >42 cm, use extra-large cuff
- For arms with circumference <20cm use paediatric cuff

NB!!!: 23-32; 33-42!



< !!!

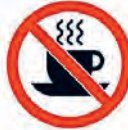

For 15 minutes before their blood pressure is measured, the person must not...

**SMOKE**



**DRINK ALCOHOL**



**CONSUME A CAFFEINATED DRINK\***

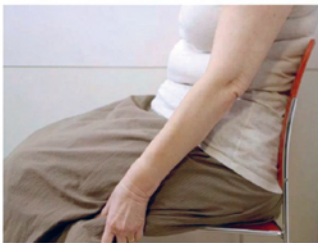\*This includes colas and other carbonated drinks like Red Bull as well as tea and coffee



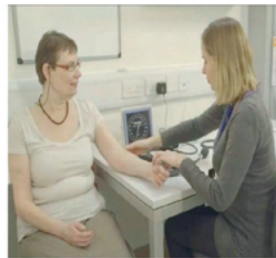

## How to measure blood pressure

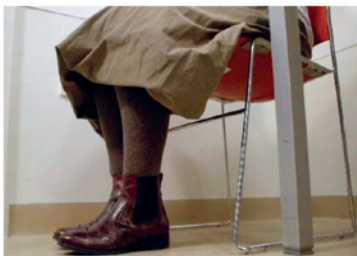- Use a machine that has been validated, well maintained and properly calibrated
- Measure sitting BP routinely, with additional standing BP in elderly and diabetic patients and those with possible postural hypotension
- Remove tight clothing from the arm
- Support the arm at the level of the heart
- Use a cuff of appropriate size (the bladder must encompass more than two-thirds of the arm)
- Lower the pressure slowly (2 mmHg per second)
- Read the BP to the nearest 2 mmHg
- Use phase V (disappearance of sounds) to measure diastolic BP
- Take two measurements at each visit



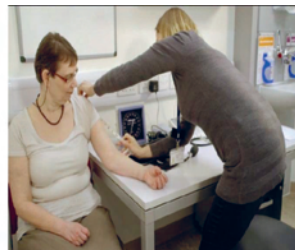The person's posture is important. They need to sit on a chair with their back supported.



The person's elbow should rest on the table, with arm supported, at about the same level as their heart. Use either arm, but the left arm is preferred.



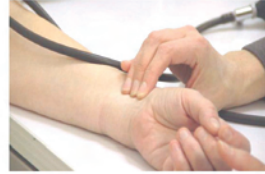The person's legs should not be dangling, should not be crossed, and should be flat on the floor.



The length of the automated device bladder should be 80% of the circumference of the upper arm. Larger, more muscular people with thicker arms need a larger bladder.



Position the cuff's lower edge about an inch (2.5cm) above the elbow bend.  
Close the cuff and then secure with the Velcro fastening.

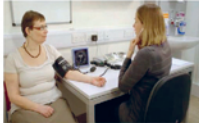

When you are using a conventional sphygmomanometer and stethoscope, first measure the person's heart rate.

Feel for the pulse in their wrist, count the number of pulses per minute, and record using the MMM app or the document we provide. You can access both at [www.maymeasure.com](http://www.maymeasure.com)

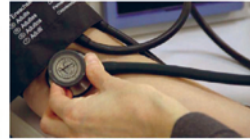**Now let the person rest for FIVE MINUTES with the cuff attached to their arm before taking the first measurement.**

**Do not talk to them or allow them to talk to other people, or allow them to move from their chair.**



Next measure the blood pressure — it's best not to talk during this process.

First put the stethoscope earpieces in your ears...



Place the stethoscope bell over the brachial artery found in the inside of the person's bent elbow.

Listen for a steady thump in the brachial artery.



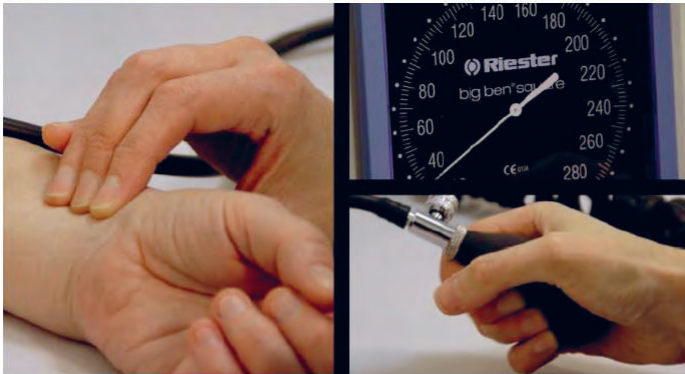
**Tighten the screw at the side of the rubber bulb....**




**Squeeze the bulb.**



**As air is squeezed into the bulb, the cuff will expand.**



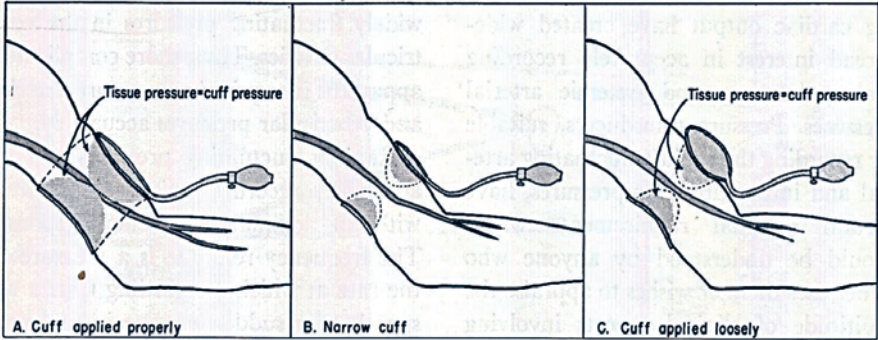
Take two further blood pressure and heart rate readings and record these using the MMM17 app or the document we provide. The person needs to sit quietly for one minute between the first and second and second and third readings.

 <b>Definition of hypertension</b>		
Category	Systolic BP (mmHg)	Diastolic BP (mmHg)
<b>BP</b>		
Optimal	< 120	< 80
Normal	< 130	85
High normal	130–139	85–89
<b>Hypertension</b>		
Grade 1 (mild)	140–159	90–99
Grade 2 (moderate)	160–179	100–109
Grade 3 (severe)	≥ 180	> 110
<b>Isolated systolic hypertension</b>		
Grade 1	140–159	< 90
Grade 2	≥ 160	< 90

# NB!!!



## TRANSMISSION OF CUFF PRESSURES TO THE TISSUES OF THE ARM

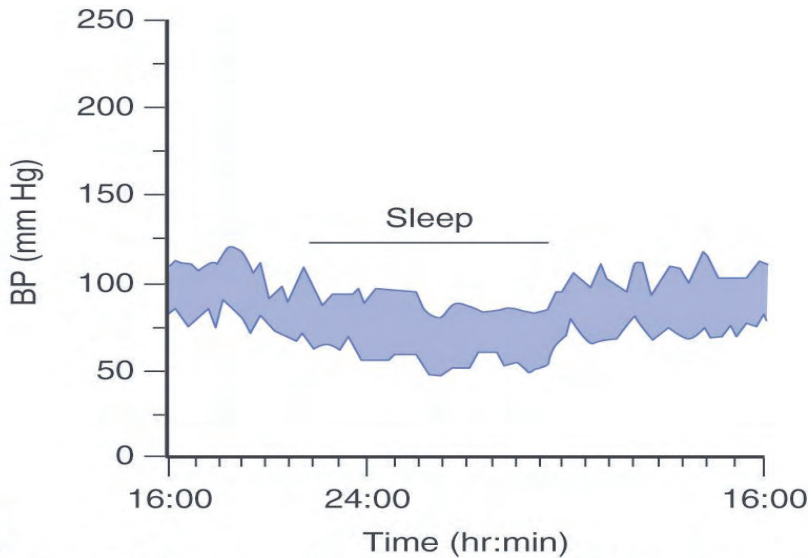


## BP: That? Where? How? to measure and analyze....

	SBP	DBP
Office or clinical	140	90
24-h	125 - 130	80
Day	130 - 135	85
Nigth	120	70
Home	130 - 135	85



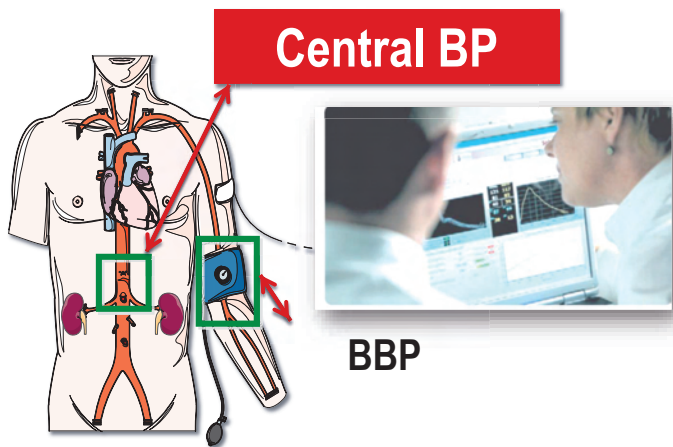
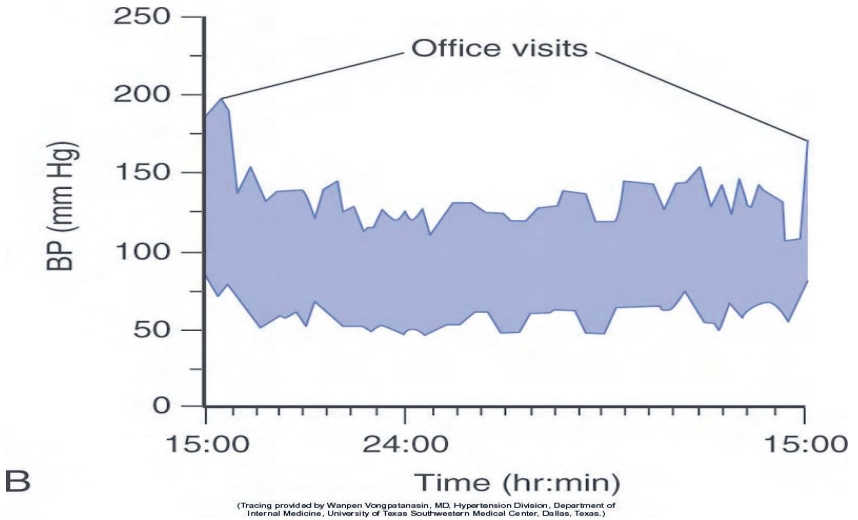
The 24-hour ambulatory blood pressure (BP) monitor tracings of two different patients. A, Optimal blood pressure in a healthy 37-year-old woman.



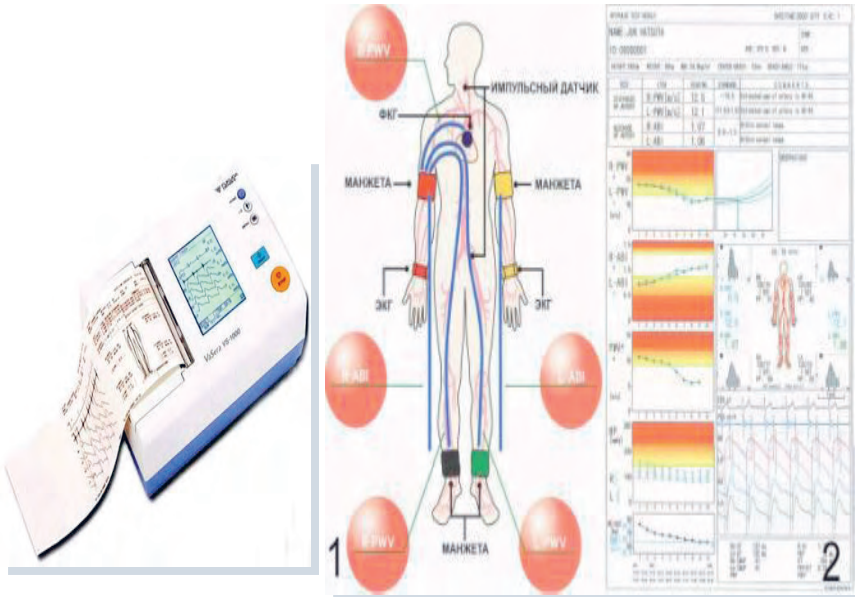
A

(Tracing courtesy of Ronald G. Victor, MD, Hypertension Division, Department of Internal Medicine, University of Texas Southwestern Medical Center, Dallas, Texas.)

The 24-hour ambulatory blood pressure (BP) monitor tracings of two different patients. **B**, Pronounced white coat effect in an 80-year-old woman referred for evaluation of medically refractory hypertension.



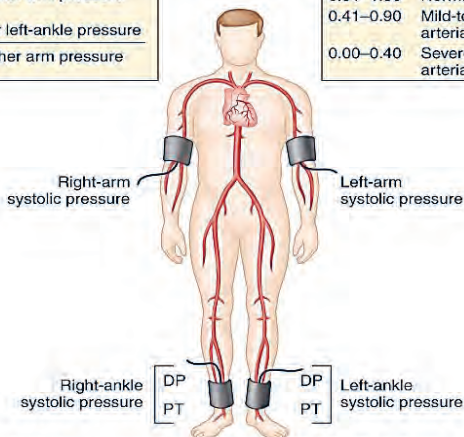
## Determination of the velocity of the pulse wave



VaSera VS-1000

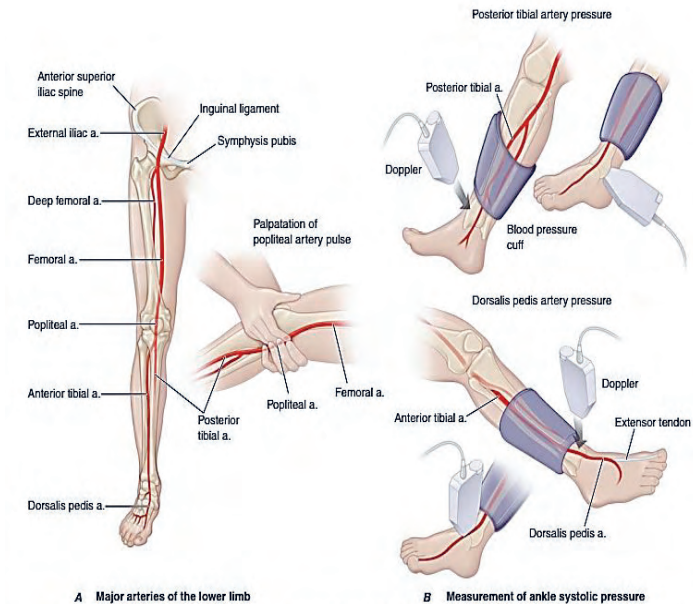
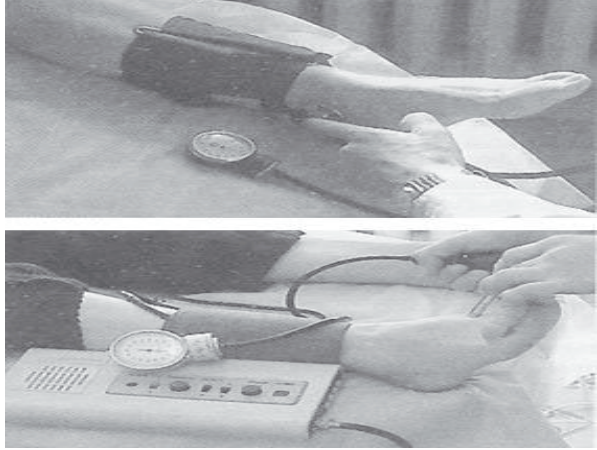
Right ABI	Higher right-ankle pressure
	Higher arm pressure
Left ABI	Higher left-ankle pressure
	Higher arm pressure

Interpretation of ABI	
>1.30	Noncompressible
0.91–1.30	Normal
0.41–0.90	Mild-to-moderate peripheral arterial disease
0.00–0.40	Severe peripheral arterial disease



(From Hiatt WR: Medical treatment of peripheral arterial disease and claudication. N Engl J Med 2001;344:1608–1621, with permission.)

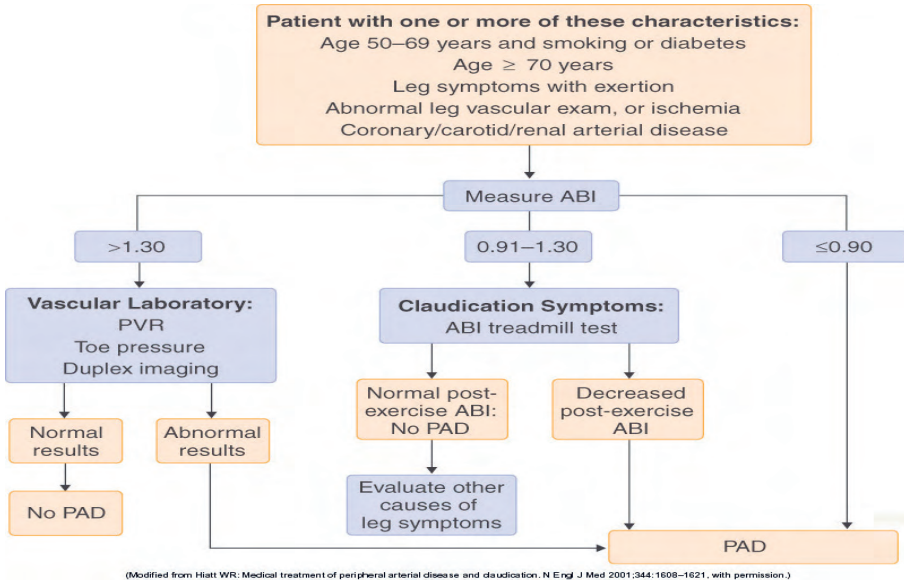
**Measurement and interpretation of the ankle-brachial index (ABI).** DP = dorsalis pedis; PT = posterior tibial. (From Hiatt WR: Medical treatment of peripheral arterial disease and claudication. N Engl J Med 2001;344:1608–1621, with permission.)



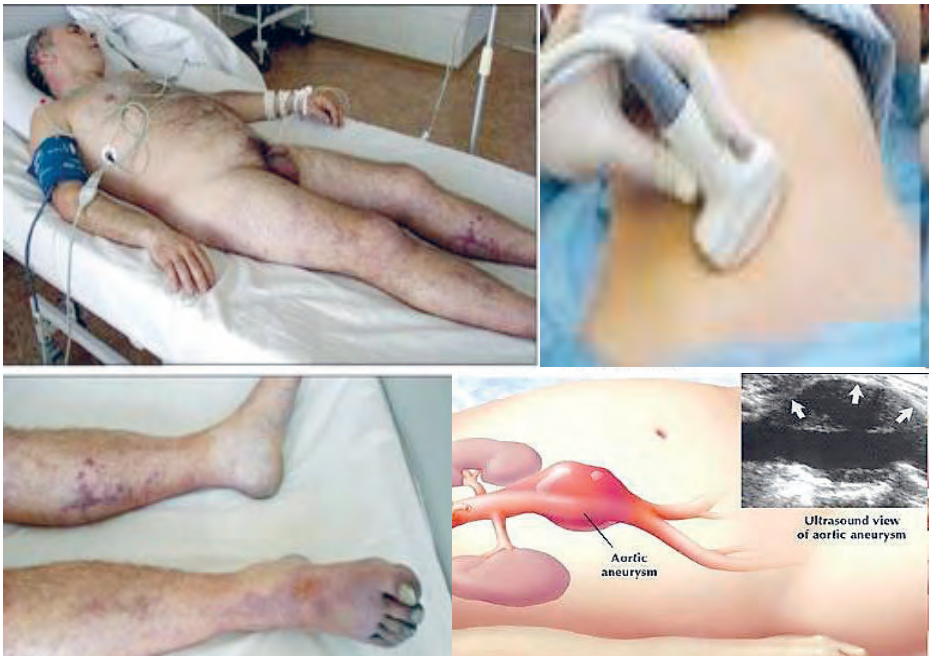**A.** Anatomy of the major arteries of the leg. **B.** Measurement of the ankle systolic pressure. (From NA Khan et al. JAMA 295:536, 2006.)







**Diagnosis of peripheral arterial disease.** ABI = ankle-brachial index; PAD = peripheral arterial disease; PVR = pulmonary vascular resistance. (Modified from Hiatt WR: Medical treatment of peripheral arterial disease and claudication. N Engl J Med 2001;344:1608–1621, with permission.)



## REFERENCES

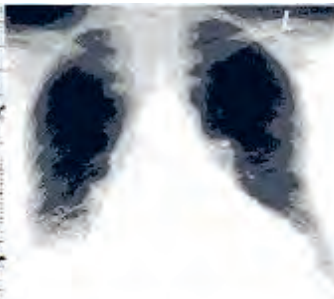
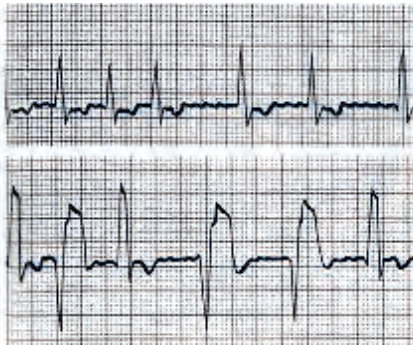
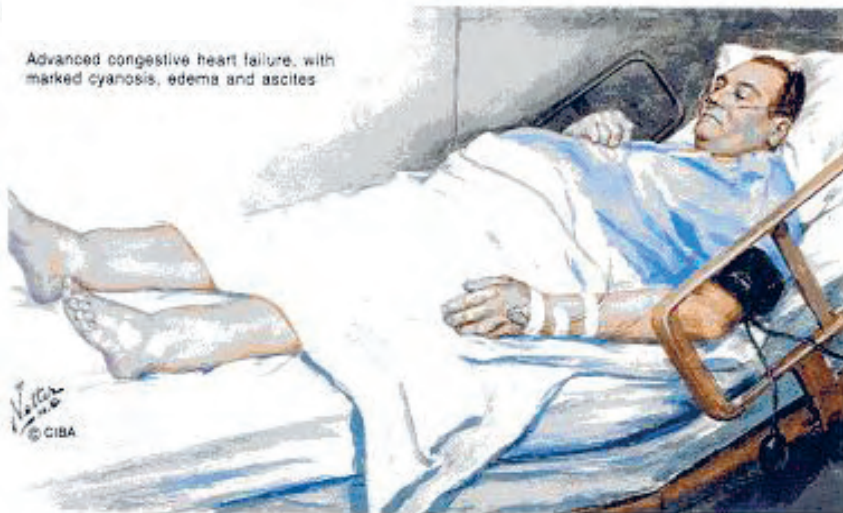- Kovalyova O.N., Ashcheulova T.V. Propedeutics to Internal Medicine. Part 1. – Vinnytsya: NOVA KNYHA, 2017. – 424 p.
- Kovalyova O.N., Asheulova T.V. General inspection: manual for students. – Kharkov: "Turbo". – 2004. – 60 p.
- Khomazjuk V.A., Ostashevskaya T.G., Krasnyuk I.V. Propaedeutics of Internal Medicine and Patient Care: Study guide for the practical classes. Part I. – Kyiv: NMU, 2005. – 44 p.
- Kovalyova O.N., Asheulova T.V. Examination of the patients with cardiovascular disease: manual for students. – Kharkov: "Turbo". – 2003. – 92 p.
- Kovalyova O.N., Asheulova T.V., Shapovalova S.A. Instrumental methods examination of cardiovascular system: manual for students. – Kharkov: KSMU. – 2004. – 147 p.
- Bickley, Lynn S.; Szilagyi, Peter G. Bates' Guide to Physical Examination and History Taking, 10th Edition. – 934p. Copyright ©2009 Lippincott Williams & Wilkins
- The Point online resources, <http://thepoint.lww.com>

LECTURE # **7**

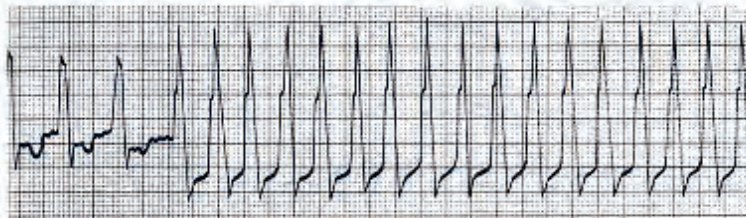
**INSTRUMENTAL METHODS  
OF CV INVESTIGATION**

## THE PLAN

- Chest X-ray
- Electrocardiography
- Transesophageal ECG and pacing
- ECG monitoring device
- Combined ECG and BP monitoring
- Echocardiography
- Two-dimensional (2D) echocardiography
- Transesophageal echocardiography (TEE)
- STRESS ECHOCARDIOGRAPHY
- Nuclear cardiology
- CT & CTA
- Magnetic resonance imaging
- Myocardial Perfusion Imaging
- MRI AND CT IMAGING
- Cardiac catheterization and angiography
- CORONARY ANGIOGRAPHY
- INTRAVASCULAR ULTRASOUND, FRACTIONAL FLOW RESERVE, AND CORONARY FLOW RESERVE
- References



Tremendously enlarged heart

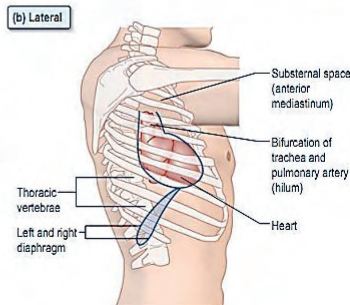
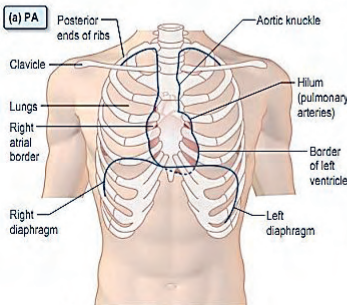
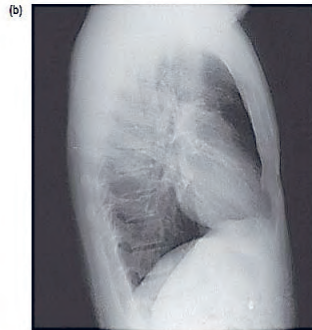
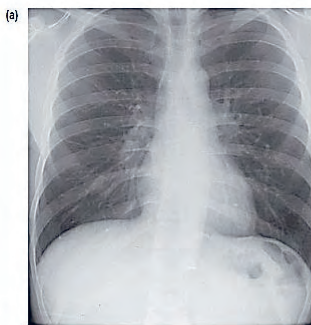


Multiple varying, bizarre arrhythmias, including atrial fibrillation, multifocal PVCs and episodes of ventricular tachycardia

## Chest X-ray

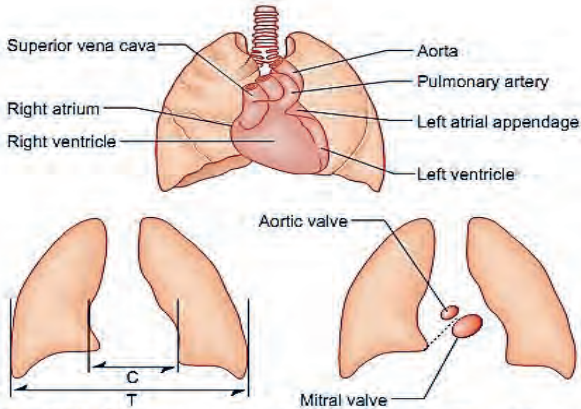
This is useful for determining the size and shape of the heart, and the state of the pulmonary blood vessels and lung fields. Most information is given by a postero-anterior (PA) projection taken in full inspiration. Antero-posterior (AP) projections are convenient when patient movement is restricted but result in magnification of the cardiac shadow.

An estimate of overall heart size can be made by comparing the maximum width of the cardiac outline with the maximum internal transverse diameter of the thoracic cavity. 'Cardiomegaly' is the term used to describe an enlarged cardiac silhouette where the 'cardiothoracic ratio' is greater than 0.5. It can be caused by chamber dilatation, especially left ventricular dilatation, or by a pericardial effusion. Artefactual cardiomegaly



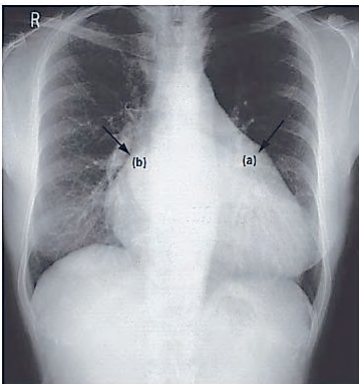
Chest X-rays. (a) PA. (b) Lateral.

Certain patterns of specific chamber enlargement may be seen on the chest X-ray:



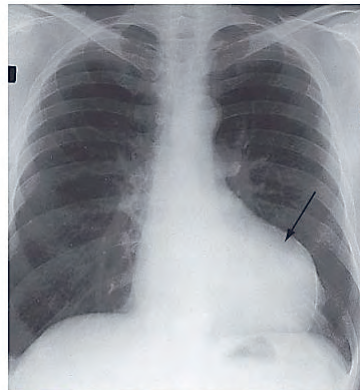
**Diagrams to show the heart silhouette on the chest X-ray, measurements of the cardiothoracic ratio (CTR) and the location of the cardiac valves. The dotted line is an arbitrary line from the left hilum to the right cardiophrenic angle; a calcified aortic valve is seen above this line.  $CTR = (C/T) \times 100\%$ ; normal  $CTR < 50\%$ .**

## Mitral configuration of the heart



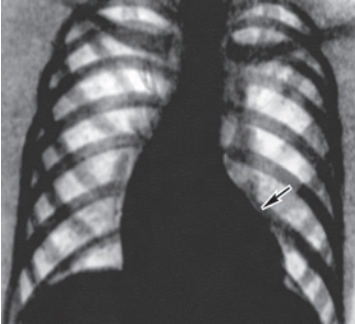
**Plain PA chest X-ray of a patient with mixed mitral valve disease.** The left atrium is markedly enlarged (arrow a). Note the large bulge on the left heart border (left atrium) and the 'double shadow' (border of the right and left atria) (arrow b) on the right side of the heart. There is cardiac (left ventricular) enlargement due to mitral regurgitation.

## Aortic configuration



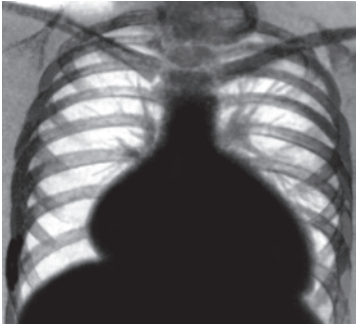
**Left ventricular aneurysm: plain PA chest X-ray demonstrating a cardiac silhouette with a 'bulge' (arrow) on the left lateral border.** This bulge is due to aneurysm formation of many years following a myocardial infarction. A thin line of calcification can be seen along the edge of this bulge.

AORTIC CONFIGURATION OF THE HEART

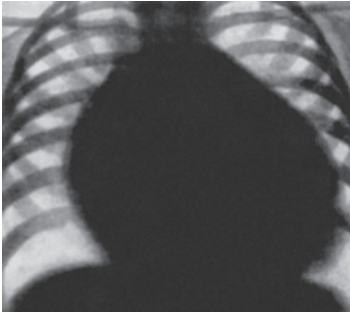


In case of aortic heart configuration accentuated heart waist is observed due to the left ventricular dilatation (aortic valvular heart disease)

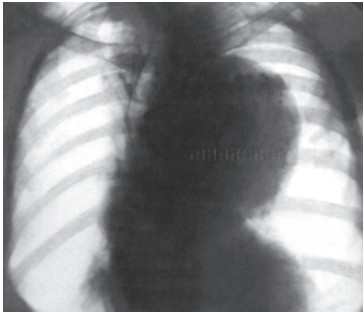
CARDIOMYOPATHY (TRAPEZOID)



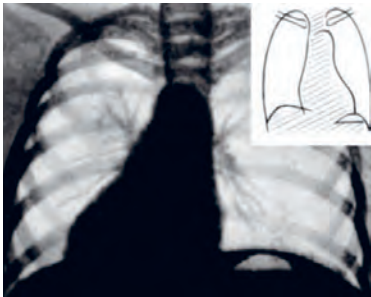
BIVENTRICULAR HYPERTROPHY = cor bovinum (spherical)



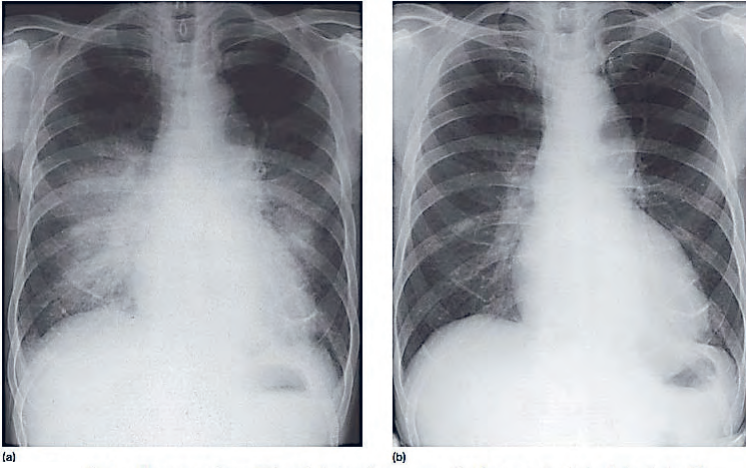
ANEURYSM OF THE THORACIC AORTA



DEXTROCARDIA

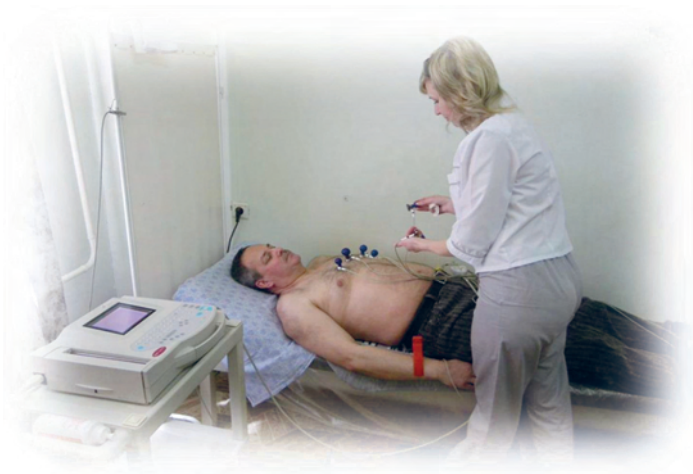





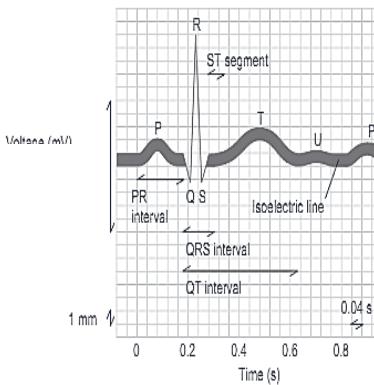
**Acute pulmonary oedema.** This pair of chest X-rays were taken from a patient before (a) and after (b) treatment of acute pulmonary oedema. The X-ray taken when the oedema was present demonstrates hilar haziness, Kerley B lines, upper lobe venous engorgement and fluid in the right horizontal interlobar fissure. These abnormalities are resolved on the film taken after successful treatment.

## Electrocardiography - a graphic representation of the electrical processes in the heart

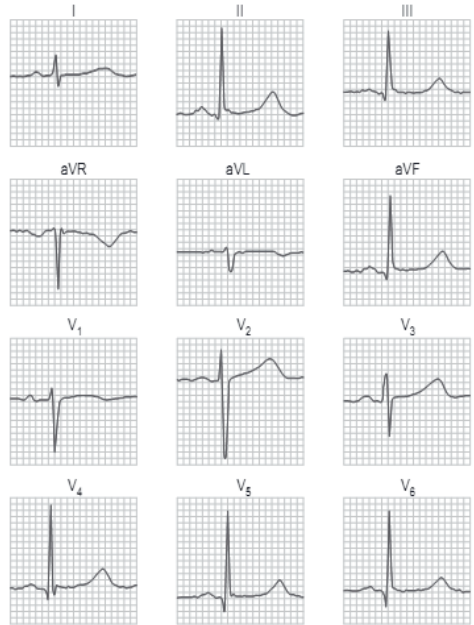


# ELECTROCARDIOGRAPHY

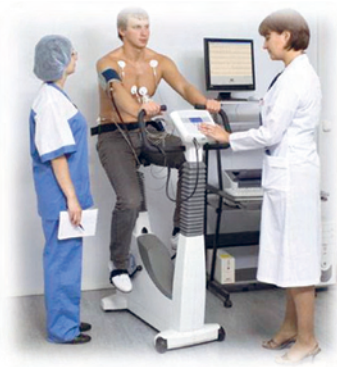- Electrocardiography, which has changed surprisingly little since it was initially introduced by Einthoven in the early 1900s, allows recording of myocardial activation from several vantage points on the body's surface, there by permitting analysis of electrical activation in different myocardial regions
- Surface electrocardiography may be supplemented with intracardiac recordings, which are particularly helpful in the diagnosis and management of cardiac arrhythmias




† The waves and elaboration of the normal electrocardiogram. From Goldman MJ. *Principles of Clinical Electrocardiography*, 9th edn. Los Altos: Lange, 1976.



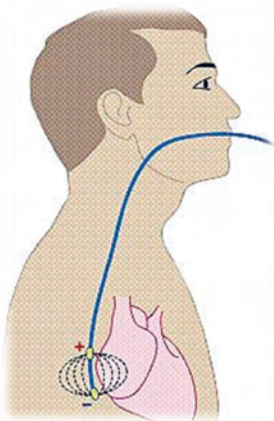
### Bicycle ergometer test



### Treadmill test



## Transesophageal ECG and pacing



Non-invasive procedure of recording of the electrical impulses of the myocardium using a special esophageal electrode and registration equipment

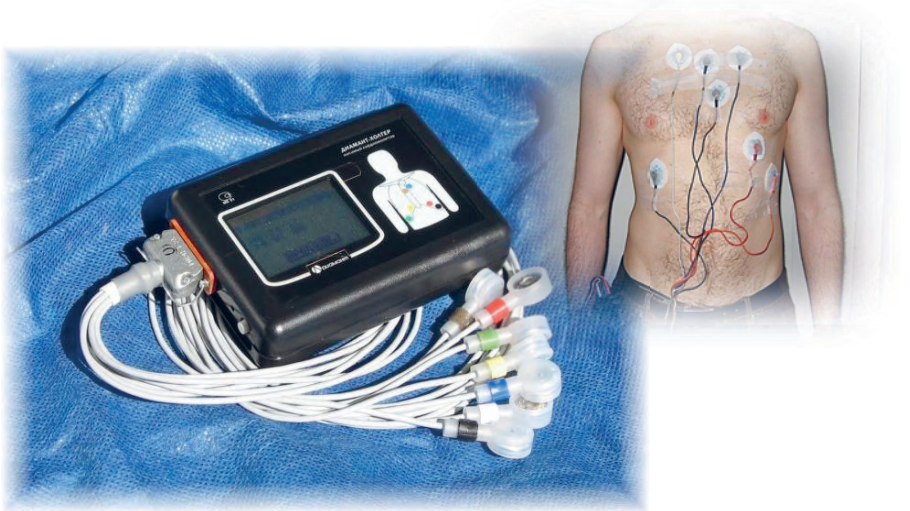
Close anatomical location of the esophagus and the heart allows to stimulate atria and ventricles



1914 - 1983

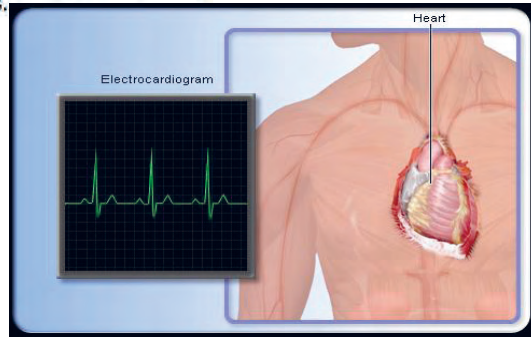
Generalizing twenty-five years of research experience in the field of registration of electrical phenomena, **Norman J. Holter** created and introduced in 1961 a new method of ECG

## ECG monitoring device



## Electrophysiology study

Patients with known or suspected arrhythmia are investigated by percutaneous placement of electrode catheters into the heart via the femoral and neck veins. Electrophysiology study (EPS) is most commonly performed to evaluate patients for catheter ablation, normally done during the same procedure. It is occasionally used for risk stratification of patients suspected of being at risk of ventricular arrhythmias.

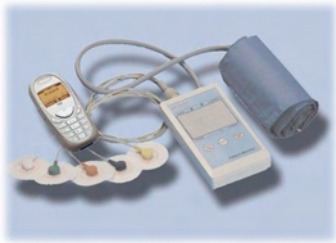

## BP monitoring

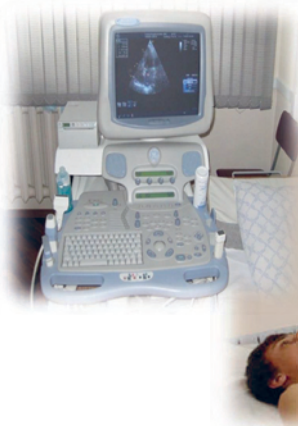Blood pressure monitoring should be used not only for diagnosis and monitoring of the effectiveness of the treatment of hypertension, but also for the study of the effects on blood pressure of various stressful situations, diet, alcohol intake, smoking, physical activity, concomitant medication, and so etc.



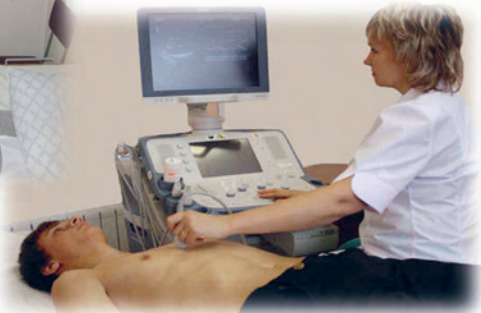### Combined ECG and BP monitoring



### Noninvasive Cardiac Imaging: Echocardiography, Nuclear Cardiology, and MRI/CT Imaging



### Echocardiography



- Echocardiography is the clinical standard for evaluating cardiac function in patients with known or suspected heart disease

## TWO-DIMENSIONAL (2D) ECHOCARDIOGRAPHY

- Cardiovascular imaging plays an essential role in the practice of cardiology
- Two-dimensional (2D) echocardiography is able to **visualize the heart directly in real time** using ultrasound, providing instantaneous **assessment of the myocardium, cardiac chambers, valves, pericardium, and great vessels**management of cardiac arrhythmias

## DOPPLER ECHOCARDIOGRAPHY

- Doppler echocardiography measures **the velocity of moving red blood cells** and has become a noninvasive alternative to cardiac catheterization for assessment of hemodynamics


## TRANSESOPHAGEAL ECHOCARDIOGRAPHY (TEE)

- Transesophageal echocardiography (TEE) provides a unique window for high-resolution imaging of posterior structures of the heart, particularly the left atrium, mitral valve, and aorta

**i** **Common indications for echocardiography**

- Assessment of left ventricular function
- Diagnosis and quantification of severity of valve disease
- Identification of vegetations in endocarditis
- Identification of structural heart disease in atrial fibrillation, cardiomyopathies or congenital heart disease
- Detection of pericardial effusion
- Identification of structural heart disease or intracardiac thrombus in systemic embolism

### M-mode ECHOCARDIOGRAPHY





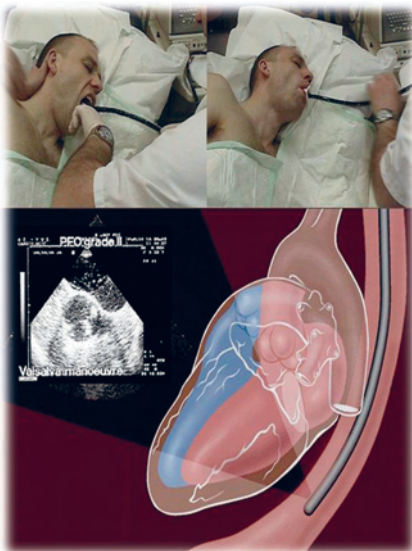
## TWO-DIMENSIONAL ECHOCARDIOGRAPHY

- **Basic principles**

2D echocardiography **uses the principle of ultrasound reflection off cardiac structures** to produce images of the heart

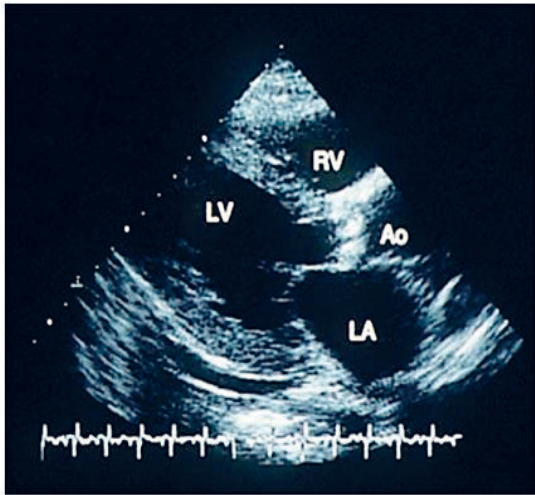
- For a transthoracic echocardiogram (TTE), the imaging is performed with a handheld transducer placed directly on the chest wall
- In selected patients, a **TEE** may be performed, in which an **ultrasound transducer is mounted on the tip of an endoscope placed in the esophagus** and directed toward the cardiac structures

### Transesophageal echocardiography

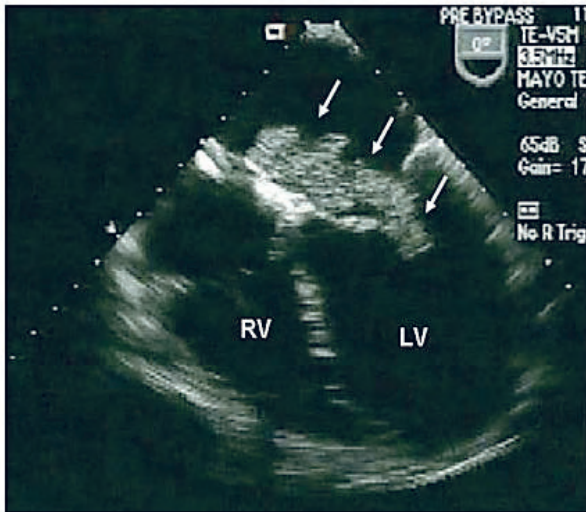


Transesophageal echocardiography - the ultrasound sensor is located in the esophagus. The esophagus is located directly behind the heart, the ultrasonic ray is not needed to overcome obstacles in the form of a chest wall and the lung

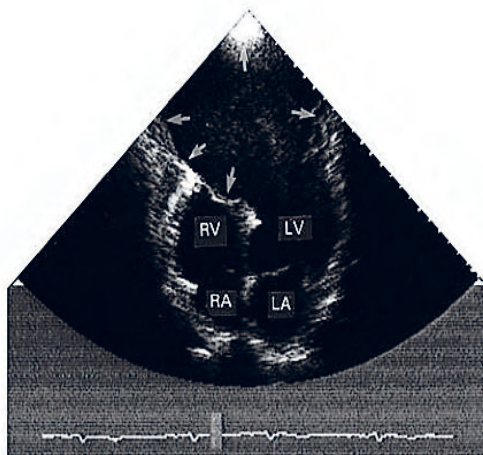
Clinical Uses of Echocardiography	
<b>Two-Dimensional Echocardiography</b>	<b>Doppler Echocardiography</b>
Cardiac chambers	Valve stenosis
Chamber size	Gradient
Left ventricular hypertrophy	Valve area
Regional wall motion abnormalities	Valve regurgitation
Valve	Semiquantitation
Morphology and motion	Intracardiac pressures
Pericardium	Volumetric flow
Effusion	Diastolic filling
Tamponade	Intracardiac shunts
Masses	<b>Transesophageal Echocardiography</b>
Great vessels	Inadequate transthoracic images
<b>Stress Echocardiography</b>	Aortic disease
Two-dimensional	Infective endocarditis
Myocardial ischemia	Source of embolism
Viable myocardium	Valve prosthesis
Doppler	Intraoperative
Valve disease	



Two-dimensional echocardiographic still-frame images from a patient with aortic stenosis. Parasternal long-axis view shows a heavily calcified aortic valve. RV, right ventricle; LV, left ventricle; AO, aorta; LA, left atrium.



Transesophageal still-frame echocardiographic images of a patient with a left atrial myxoma. There is a large echo-dense mass in the left atrium, attached to the atrial septum. The mass moves across the mitral valve in diastole. LV, left ventricle; RV, right ventricle.

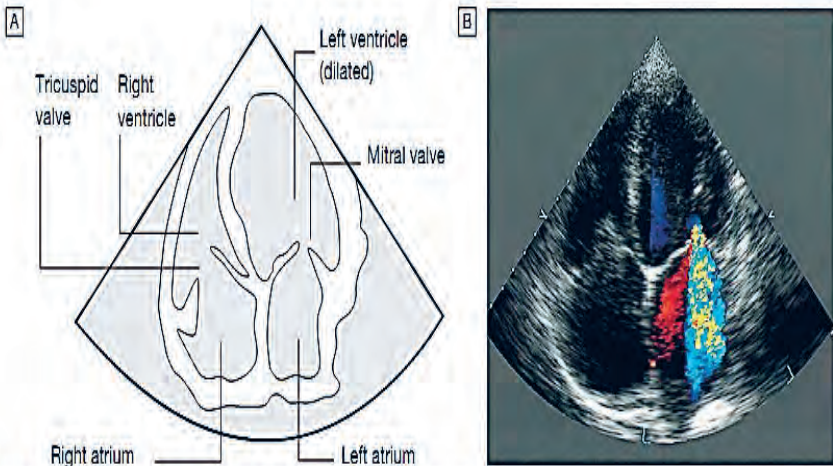


2-D Echocardiogram (apical four-chamber view) showing a very large apical left ventricular aneurysm (arrows). The relatively static blood in the aneurysm produces a swirling 'smoke' effect. This aneurysm was successfully resected surgically. LV, left ventricle; LA, left atrium; RV, right ventricle; RA, right atrium.

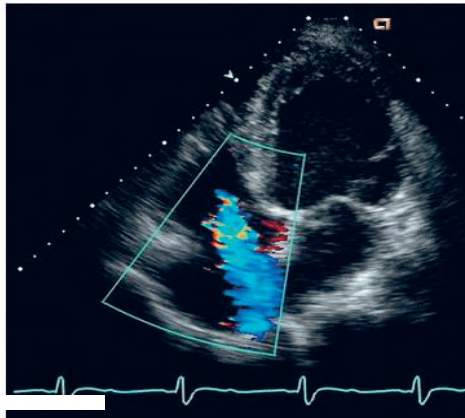
## DOPPLER ECHOCARDIOGRAPHY

- Doppler echocardiography uses **ultrasound reflecting off moving red blood cells to measure the velocity of blood flow across valves, within cardiac chambers, and through the great vessels**
- Normal and abnormal blood flow patterns can be assessed noninvasively
- Color-flow Doppler imaging displays **the blood velocities** in real time superimposed upon a 2D echocardiography image
- The different colors indicate the direction of blood flow (**red toward and blue away from the transducer**), with **green superimposed when there is turbulent flow**
- Continuous-wave Doppler echocardiography can measure high velocities of blood flow directed along the line of the Doppler beam, such as occur in the presence of valve stenosis, valve regurgitation, or intracardiac shunts
- Doppler can be used **to determine the pressure gradient across the valve**
  - Valve gradients
  - Valvular regurgitation
  - Intracardiac pressures
  - Cardiac output
  - Diastolic filling
  - Congenital heart disease

## Doppler-echocardiography

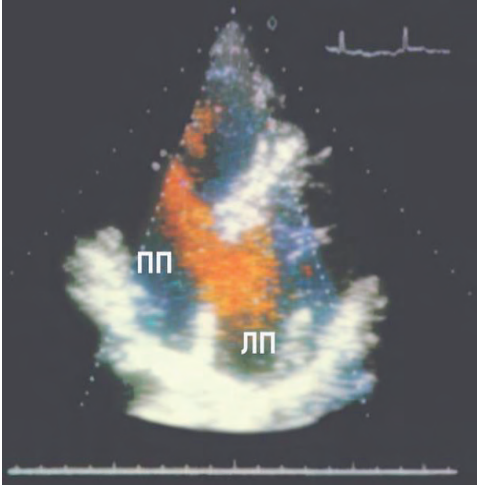


Echocardiographic illustration of the principal cardiac structures in the 'four-chamber' view. **A** The major chambers and valves. **B** Colour-flow Doppler has been used to demonstrate mitral regurgitation: a flame-shaped (yellow/blue) turbulent jet into the left atrium.

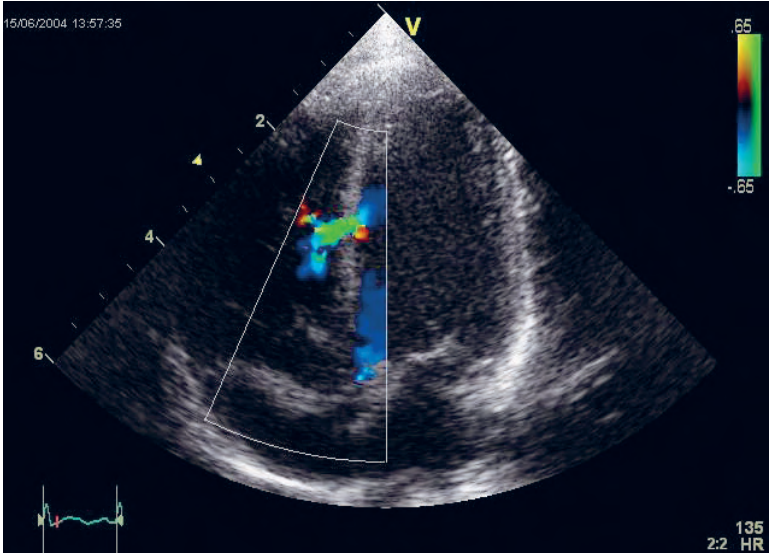


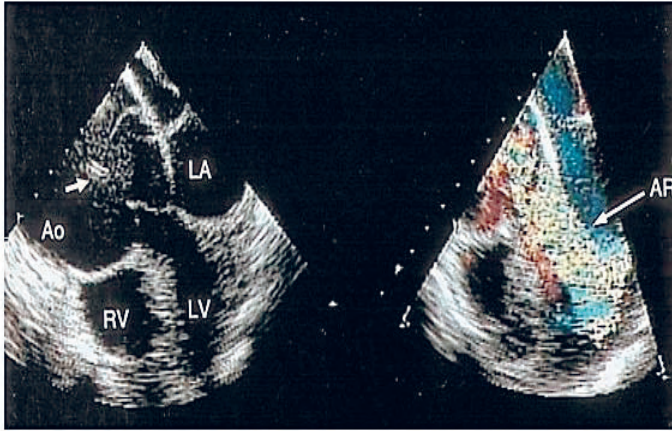
**Fig. 13.26** Colour Doppler shows blood flowing away from the echocardiography probe as a blue signal and towards the probe as a red signal. In this patient with tricuspid regurgitation, blood leaks from the right ventricle to the right atrium during cardiac systole.

# Doppler-echocardiography

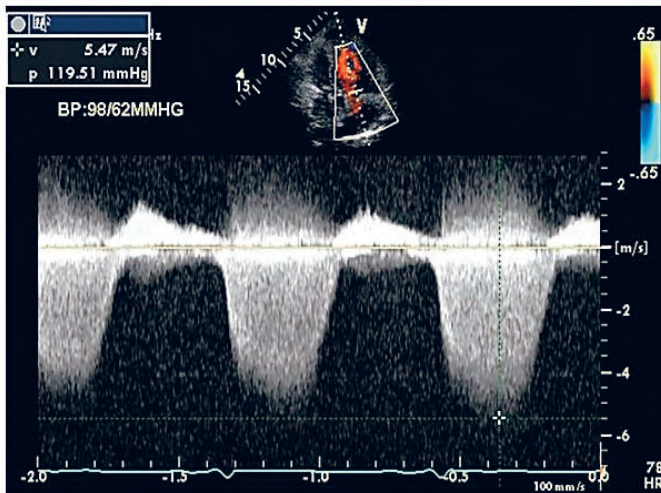


It is established for all echocardiographic systems that red color corresponding to blood flow towards the sensor, blue – from the sensor.

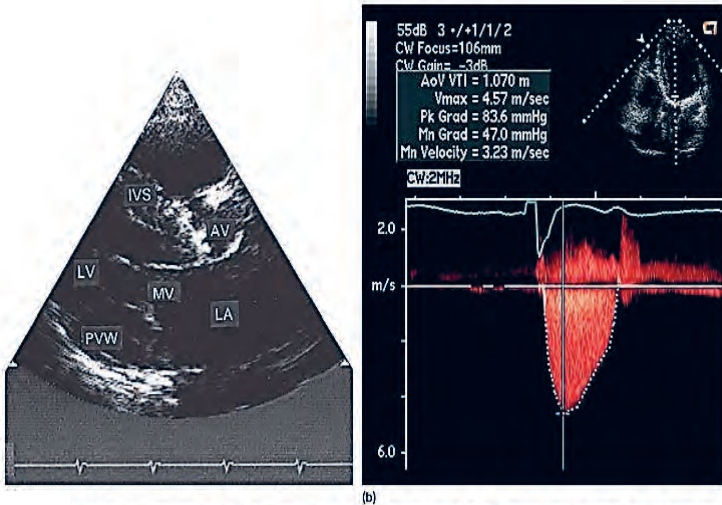




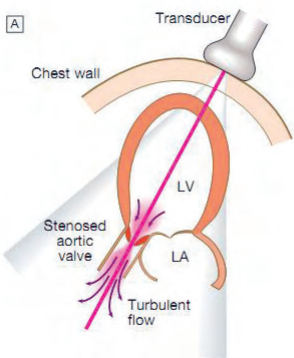
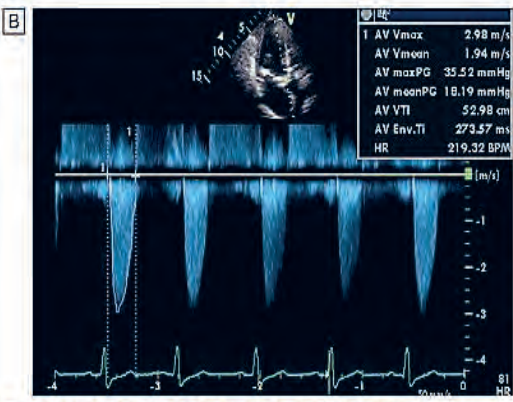
Transesophageal still-frame echocardiographic view of a patient with a dilated aorta, aortic dissection, and severe aortic regurgitation. The arrow points to the intimal flap that is seen in the dilated ascending aorta. *Left:* The long-axis apex-down view of the black-and-white two-dimensional image in diastole. *Right:* Color-flow imaging that demonstrates a large mosaic jet of aortic regurgitation. Ao, aorta; RV, right ventricle; AR, aortic regurgitation.



Continuous-wave Doppler of tricuspid regurgitation in a patient with pulmonary hypertension. There is an increase in the velocity to 5.4 m/s. Using the modified Bernoulli equation, the peak pressure gradient between right ventricle and right atrium during systole is 116 mmHg. Assuming a right atrial pressure of 10 mmHg, the right ventricular systolic pressure is 126 mmHg. In the absence of right ventricular outflow tract obstruction, this indicates there is severe pulmonary hypertension with a pulmonary artery systolic pressure of 126 mmHg.

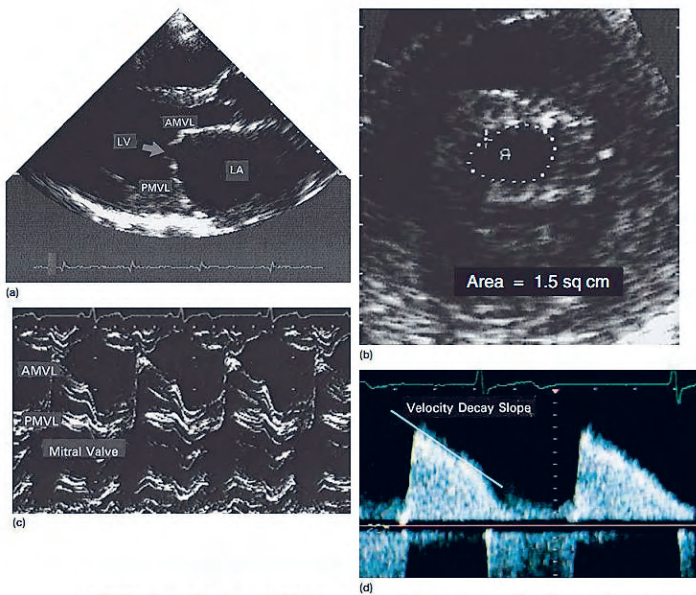


**Cardiac echograms.** (a) 2-D Echocardiogram (long-axis view) in a patient with calcific aortic stenosis. The calcium in the valve generates abnormally intense echoes. There is some evidence of the associated left ventricular hypertrophy. (b) Continuous-wave (CW) Doppler signals obtained from the right upper parasternal edge, where the high-velocity jet from the stenotic valve is coming towards the transducer. AV, aortic valve; LA, left atrium; MV, mitral valve; LV, left ventricle; IVS, interventricular septum; PVW, posterior ventricular wall.

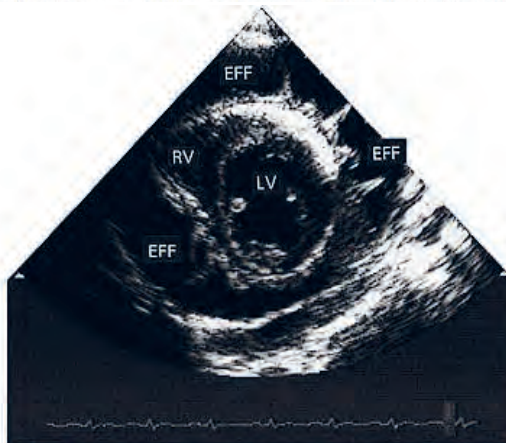


**Doppler echocardiography in aortic stenosis.** (A) The aortic valve is imaged and a Doppler beam passed directly through the left ventricular outflow tract and the aorta into the turbulent flow beyond the stenosed valve. (B) The velocity of the blood cells is recorded to determine the maximum velocity and hence the pressure gradient across the valve. In this example, the peak velocity is approximately 450 cm/sec (4.5 m/sec), indicating severe aortic stenosis (peak gradient of 81 mmHg).





**Echocardiograms in rheumatic mitral valve disease.** (a) 2-D Long-axis view showing enlarged left atrium and 'hooked' appearance of the mitral valve leaflets resulting from commissural fusion. (b) Magnified short-axis view showing the mitral valve orifice as seen from the direction of the arrow in (a). The orifice area can be planimetered to assess the severity; in this case it is 1.5 cm<sup>2</sup>, indicating moderately severe disease. (c) M-mode recording of the mitral valve showing restricted motion of the thickened leaflets. (d) Continuous-wave (CW) Doppler recording showing slow rate of decay of flow velocity from the left atrium to the left ventricle during diastole. It is also possible to derive the valve orifice area from the velocity decay rate. LA, left atrium; LV, left ventricle; AMVL, PMVL, anterior and posterior mitral valve leaflets.

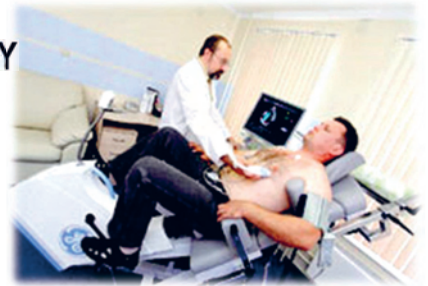

**2-D Echocardiogram (short-axis view) from a patient with a large pericardial effusion associated with pulmonary tuberculosis.** The exudate is seen between the visceral and parietal layers of the pericardium and would give a false impression of cardiomegaly on a chest X-ray. Note the multiple fibrous strands within the effusion, showing that it is consolidating and will probably lead to constriction of cardiac function. LV, left ventricle; RV, right ventricle; EFF, effusion.

## TTE

- Current echocardiography machines are portable and **can be wheeled directly to the patient's bedside**
- Thus, a major advantage of echocardiography over other imaging modalities is the ability to obtain instantaneous images of the **cardiac structures for immediate interpretation**
- Thus, **echocardiography has become an ideal imaging modality for cardiac emergencies!**
- A **limitation of TTE** is the inability to obtain high-quality images in all patients, especially those with a thick chest wall or severe lung disease, as ultrasound waves are poorly transmitted through lung parenchyma

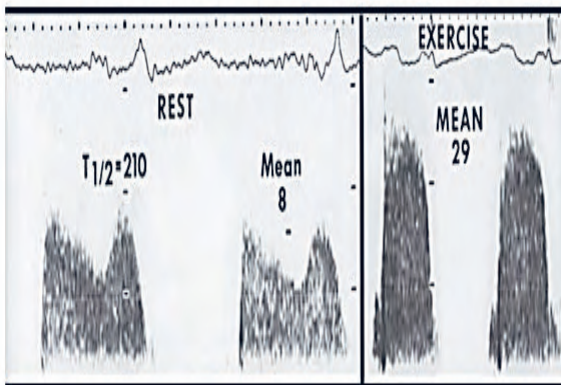
## STRESS ECHOCARDIOGRAPHY



- 2D and Doppler echocardiography are usually performed with the patient in the resting state
- Further information can be obtained by reimaging during either exercise or pharmacologic stress
- The primary indications for stress echocardiography are to confirm the suspicion of ischemic heart disease and determine the extent of ischemia

## STRESS ECHOCARDIOGRAPHY

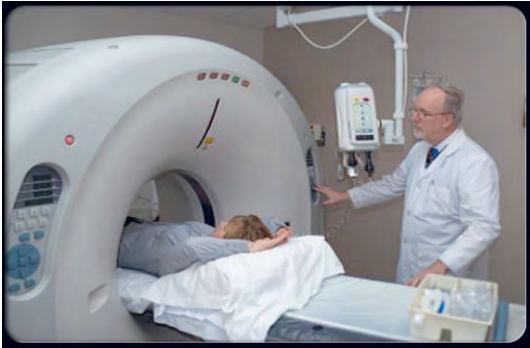- Exercise stress testing is usually done with exercise protocols using either upright **treadmill or bicycle exercise**. In patients who are not able to exercise, pharmacologic testing can be performed by infusion of dobutamine to increase myocardial oxygen demand
- **Dobutamine echocardiography** has also been used to assess myocardial viability in patients with poor systolic function and concomitant CAD; when used for this purpose, dobutamine is administered at lower doses than standard pharmacologic stress doses
- Doppler echocardiography can be used at rest and during exercise in patients with valvular heart disease to determine the hemodynamic response of valve gradients and pulmonary pressures
- In patients with low-output, low-gradient aortic stenosis, the response of the gradient to dobutamine stimulation is of diagnostic and therapeutic value



Continuous-wave Doppler echocardiogram across the mitral valve of a patient with mitral stenosis. In the resting state (*left*), there is a mean gradient of 8 mmHg. During exercise (*right*), the mean gradient rises to 29 mmHg, indicating a hemodynamically significant mitral stenosis.

## COMPUTED TOMOGRAPHY OF THE HEART

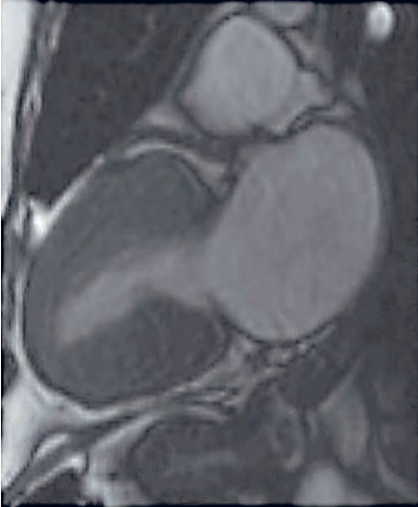
creates an image of the heart, using the technology of CT, with or without injection of intravenous contrast to visualize the anatomy of the heart and vessels (including the aorta, the pulmonary veins and arteries), coronary circulation



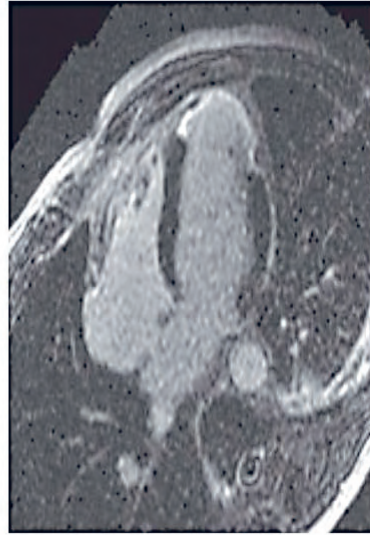
Computerized tomography (CT)

## COMPUTED TOMOGRAPHIC IMAGING

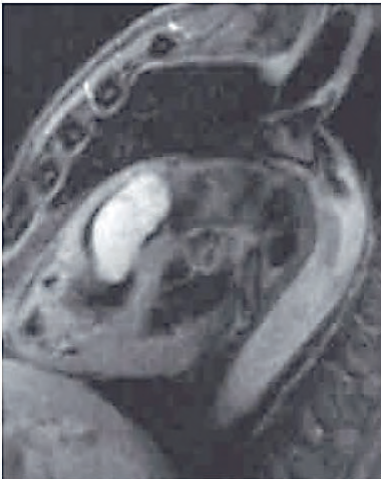- **BASIC PRINCIPLES**
- CT is a fast, simple, noninvasive technique that provides images of the myocardium and great vessels with excellent spatial resolution and good soft tissue contrast
- The development of electron-beam CT and multidetector-row CT have led to improved temporal resolution and routine imaging of the beating heart. Motion-free high-spatial-resolution images are now possible with multidetector CT technology ( $\geq 64$  channel) that allows imaging of the coronary arteries



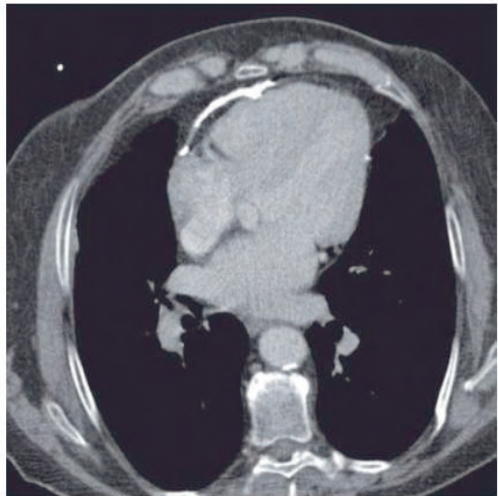
MRI scan of a patient with hypertrophic cardiomyopathy, showing the severe increase in left ventricular wall thickness. Cardiac MRI is an ideal imaging modality for diagnosing cardiomyopathies.



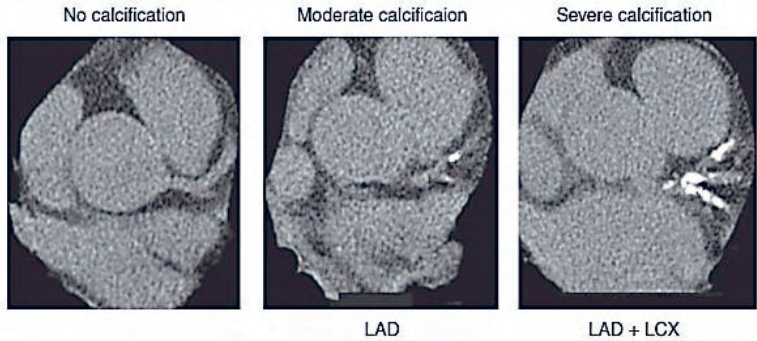
MRI scan with delayed gadolinium enhancement in a patient with a large anteroapical infarction. The gadolinium (white area) accumulated in the extracellular space in the presence of cell death from myocardial infarction.



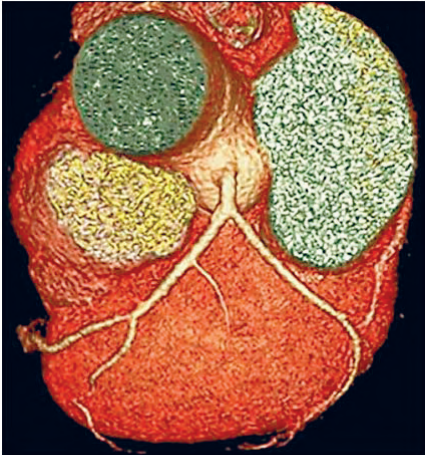MR image of a patient with a right ventricular myxoma, which is shown as a bright oblong structure in the right ventricular outflow tract.



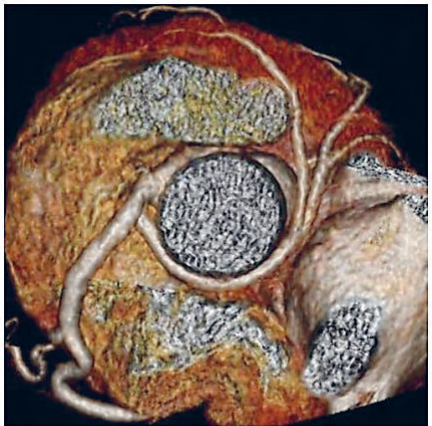
CT scan showing pericardial calcification, seen as a white linear density anterior to the myocardium.



**CT scans of three patients showing the ability to detect coronary calcification.**  
*Left:* Normal coronary arteries without calcification. *Middle:* Calcification in the left anterior artery (LAD). *Right:* Severe calcification in the LAD and circumflex (CX) arteries.



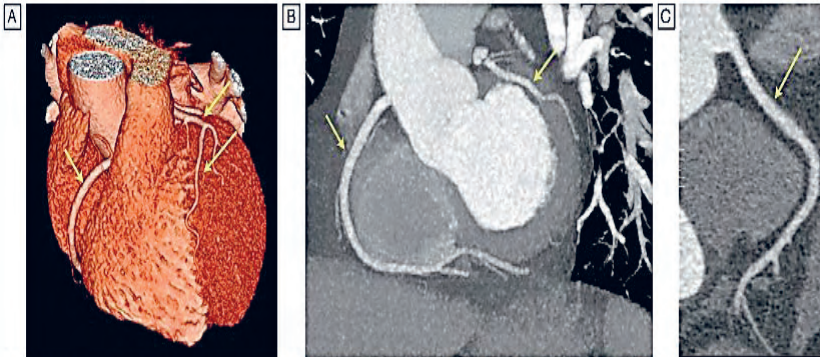
Three-dimensional volume rendered image of a contrast-enhanced CT angiogram demonstrating a normal left main coronary artery arising from the aorta and its two branches, the left anterior descending artery (*left*) and the circumflex artery (*right*).



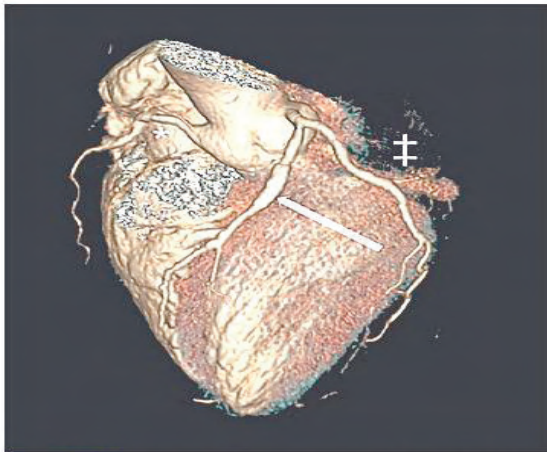
Three-dimensional volume rendered image of a contrast-enhanced CT angiogram illustrating an anomalous left coronary artery arising from the right coronary artery and traveling posterior to the aorta.

## Computed tomographic imaging

Computed tomography (CT) is useful for imaging the cardiac chambers, great vessels, pericardium, and mediastinal structures and masses.

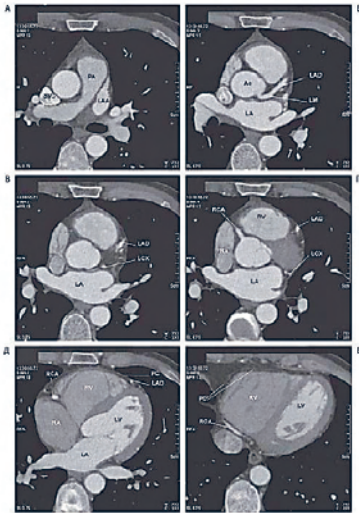


Computed tomography coronary angiography demonstrating normal coronary arteries (arrows).

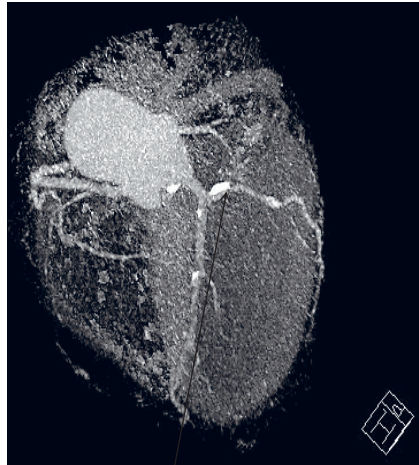


**Multi-slice CT – volume rendered image in a patient with coronary artery stent insertion (arrow)** demonstrating a patent left anterior descending coronary artery with mild stenosis before the stent. The right (\*) and the circumflex (↔) coronary arteries are free from significant stenoses.

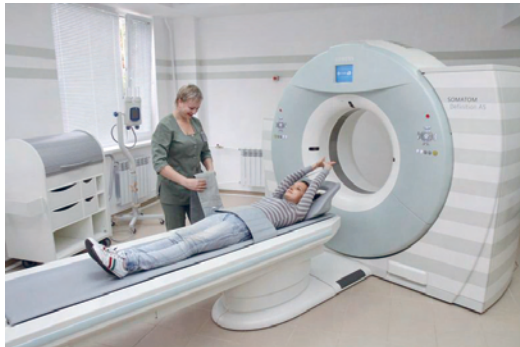# Computed tomography of the heart



Sections of the heart



Atherosclerotic plaques



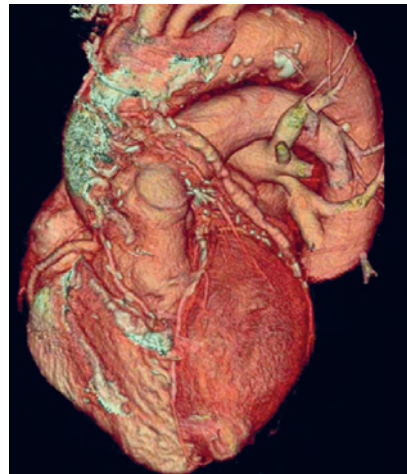
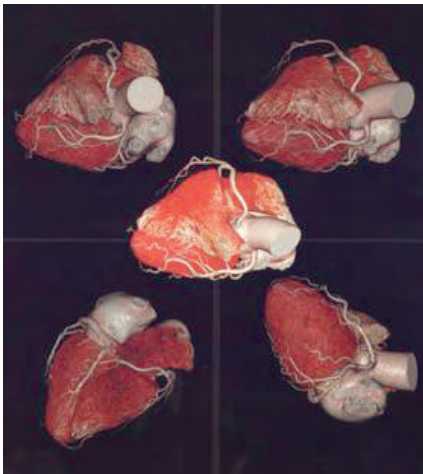
- **Magnetic resonance imaging** - a method of investigation of internal organs and tissues using the physical phenomenon of nuclear magnetic resonance - a method based on measuring the electromagnetic response of the nuclei of hydrogen atoms on the excitation of a certain combination of electromagnetic waves in a constant magnetic field of high intensity.

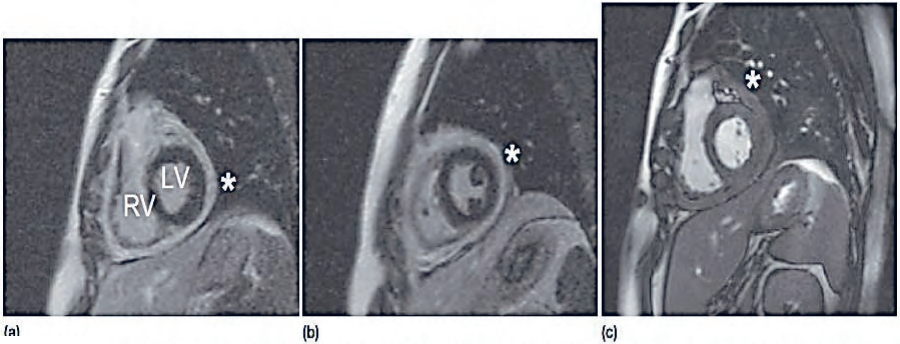


## WITH MAGNETIC RESONANCE IMAGING OF THE HEART WE CAN IDENTIFY:

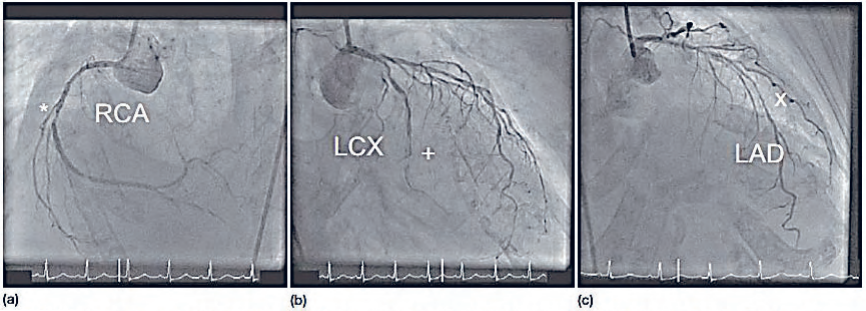
1. Structural features of the chambers of the heart and blood vessels;
2. Intracardial hemodynamic;
3. Blood flow in large vessels;
4. Congenital heart disease;
5. Aortic aneurysm, coarctation;
6. Tumors of the heart;
7. Cardiomyopathy, especially hypertrophic cardiomyopathy;
8. Pulmonary hypertension of unknown origin, the pathology of the right heart

### Magnetic resonance imaging of the heart

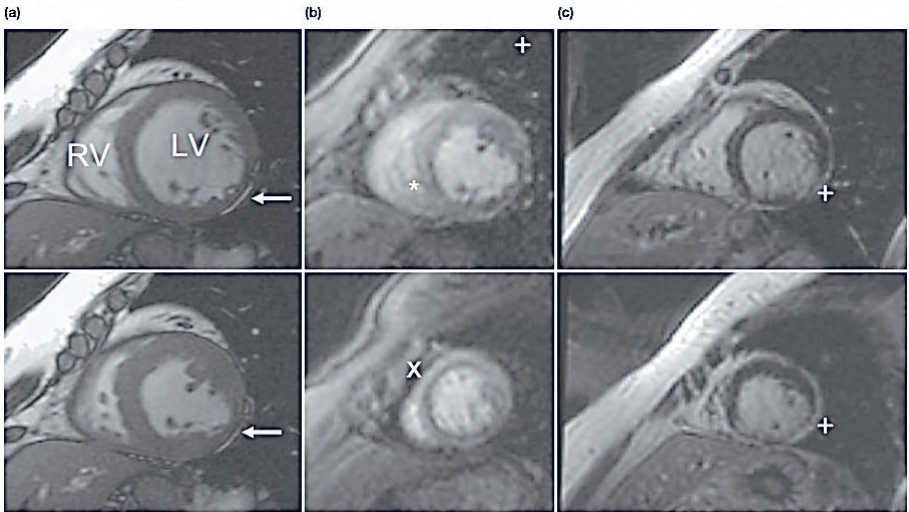




Short-axis cardiac magnetic resonance (CMR) in a patient with constrictive pericarditis. The pericardium is thickened (\*) and on ciné imaging (c) there is septal bounce. LV, left ventricle; RV, right ventricle.



Cardiac magnetic resonance (CMR). A diagnostic coronary angiography in a patient with Type 2 diabetes mellitus and exertional breathlessness demonstrates a severe stenosis (\*) in the right coronary artery (RCA), a sub-totally occluded (+) circumflex coronary artery (LCX), and a long segment of disease (x) in the left anterior descending coronary artery (LAD).



Cardiac magnetic resonance (CMR). (a) Short axis CMR FIESTA ciné imaging (diastole top, systole bottom) demonstrates thinning and hypokinesia of the inferolateral wall (arrows) but with preserved function of the rest of the myocardium. LV, left ventricle; RV, right ventricle. (b) First-pass perfusion CMR (mid top, apex bottom) demonstrates sub-endocardial perfusion defects in the inferolateral wall (+), infero-septum (\*) and apical segments (x). (c) Delayed enhancement CMR confirms a transmural myocardial infarction of the mid-apical infero-lateral wall (+) secondary to a previous infarction from the circumflex coronary artery and confirms inducible ischaemia in the right and left coronary

## NUCLEAR CARDIOLOGY

- Nuclear cardiology uses radioactive tracers to provide assessment of myocardial perfusion and metabolism, along with ventricular function, and is applied primarily to the evaluation of patients with ischemic heart disease

### BASIC PRINCIPLES OF NUCLEAR CARDIOLOGY

- Nuclear (or radionuclide) imaging requires intravenous administration of radiopharmaceuticals (isotopes or tracers)
- Once injected, the isotope traces physiologic processes and undergoes uptake in specific organs
- During this process, radiation is emitted in the form of photons, generally gamma rays, generated during radioactive decay when the nucleus of an isotope changes from one energy level to a lower one
- A special camera detects these photons and creates images via a computer interface
- The two most commonly used technologies in clinical nuclear cardiology are singlephoton emission computed tomography (SPECT) and positron emission tomography (PET)
- These technologies differ in instrumentation, acquisition, resolution, and nuclides used

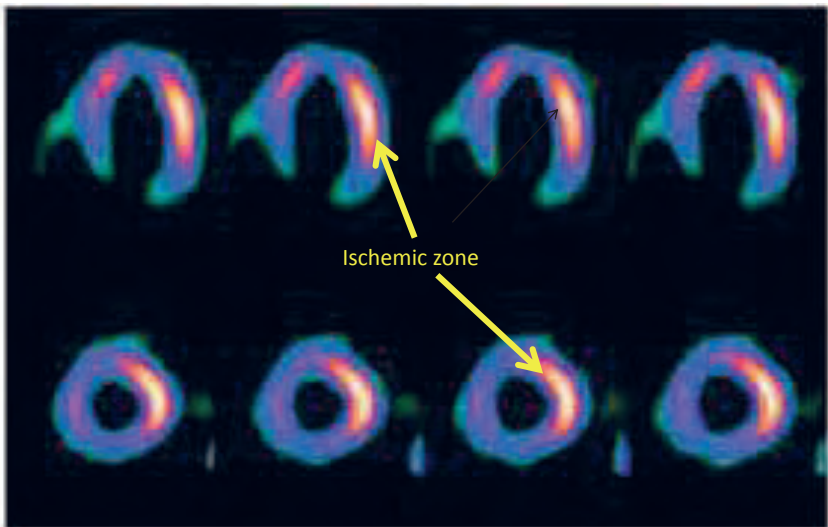
## MYOCARDIAL PERFUSION IMAGING

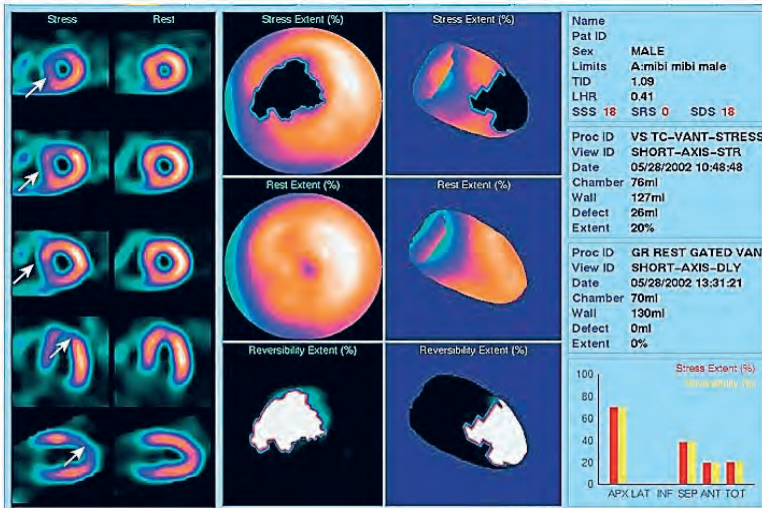
- Stress and rest short-axis  $^{99m}\text{Tc}$ -sestamibi tomograms in a patient with chest pain and 3 mm of upsloping ST-segment depression on exercise electrocardiogram stress testing
- Note a large defect involving the anterior wall, septum, and inferior wall; the defect is reversible on the resting study.
- These findings indicate significant inducible ischemia in the region of a proximal left anterior descending coronary artery stenosis. This patient was referred for further invasive evaluation

WITH MYOCARDIUM SCINTIGRAPHY WE CAN IDENTIFY:

1. Myocardial perfusion
2. Myocardial contractility
3. Myocardial infarction
4. Transient myocardial ischemia
5. Differential diagnosis between ischemic and non-ischemic myocardial damage

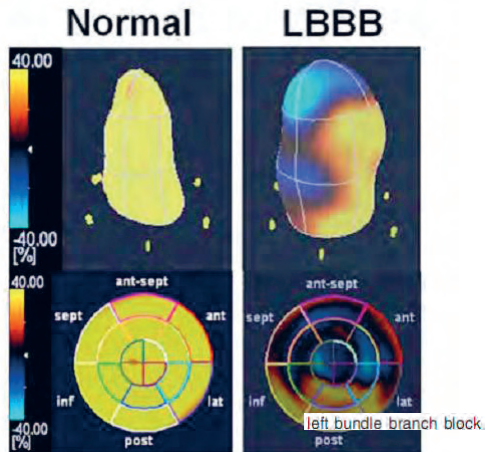
### Myocardium scintigraphy





**Myocardial SPECT study acquired with  $^{99m}\text{Tc}$ tetrofosmin tracer.** Left panel – three short axis slices, a horizontal and a vertical axis plane of the left ventricle after stress and following a resting re-injection of tracer. The **rest** images demonstrate normal tracer uptake (orange signal) in the whole of the left ventricle. The **stress** images demonstrate reduced tracer uptake (arrows; purple-blue signal) in the anterior and septal walls consistent with a significant stenosis in the left anterior descending artery. Middle panel – polar maps of the whole myocardium can localize the ischaemic territory. Right panel – quantitative analysis can help define the extent and reversibility of the ischaemia.

## Imaging of Ventricular Function

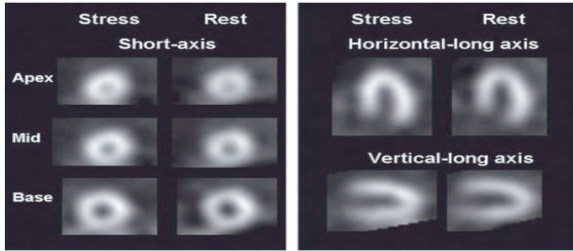


**Demonstration of Time Sequence of Left Ventricular Mechanical Activation Using Novel Three Dimensional Speckle Tracking Analysis**

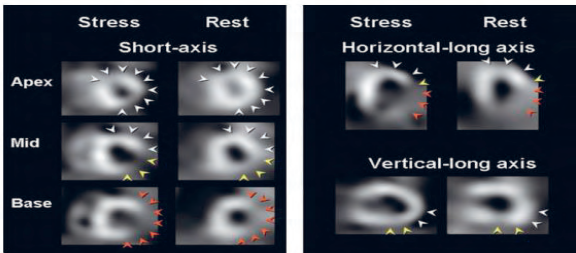
## CLINICAL APPLICATIONS

### ASSESSMENT OF MYOCARDIAL PERFUSION AND CORONARY ARTERY DISEASE

- Nuclear myocardial perfusion imaging (MPI) using **SPECT** and more recently **PET** has an established role in the evaluation and management of patients with known or suspected coronary artery disease (CAD)
- Both SPECT and PET MRI require the injection of isotopes at rest and during stress to produce images of regional myocardial uptake proportional to regional blood flow
- Normally, myocardial blood flow can be increased up to five fold above the resting state to meet the increased myocardial oxygen demand during stress. In the presence of a fixed coronary stenosis, the inability to increase myocardial perfusion in the territory supplied by the stenosis creates a flow differential and inhomogeneous myocardial tracer uptake
- In patients unable to exercise, **pharmacologic agents** are used to increase blood flow and create similar in homogeneities
- The most commonly used **SPECT perfusion tracers are thallium-201 (201Tl) and technetium-99m (99mTc) labeled isonitriles**
- 99mTc isonitriles have higher photon energies and shorter physical half-lives than 201Tl, permitting injection of higher doses with less radiation exposure while concurrently producing higher-quality images
- The FDA-approved **PET tracers are rubidium-82 (82Rb) and 13N ammonia (13NH3)** for high-dose administration and shorter imaging protocols

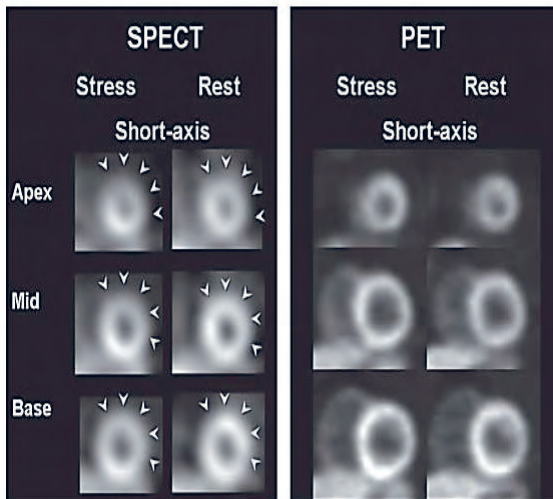


Exercise technetium-99m sestamibi images in a 65-year-old man with atypical angina. Images are shown in three standard views; stress (*left*) and rest (*right*) in each panel. There is uniform tracer uptake throughout the left ventricular myocardium at rest and peak stress in all three views.

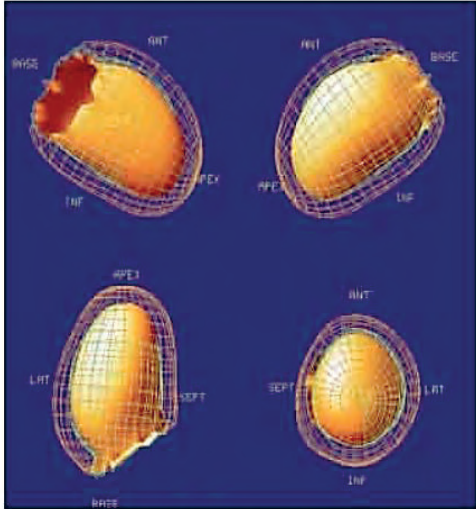


Exercise technetium-99m sestamibi and rest thallium-201 images in a 72-year-old woman with typical angina. Images are shown in three standard views, with stress (*left*) and rest (*right*) in each panel. Stress images demonstrate reduced tracer uptake in the apical, mid-anterior, mid-lateral, and mid-inferior regions (*white arrowheads*) with normal or near-normal tracer uptake in the corresponding regions on the rest images (*white arrowheads*), signifying a reversible defect consistent with ischemia. The lack of

complete normalization (or reversibility) of tracer uptake on the rest images at the mid-inferior and mid-lateral region represents associated infarction in that area (*yellow arrowheads*). On both stress and rest images, the basal inferior and basal lateral regions exhibit severely reduced tracer uptake, signifying a fixed defect consistent with infarction (*red arrowheads*). Subsequent invasive coronary angiography demonstrated severe stenosis of the mid left anterior descending coronary artery and occlusion of the left circumflex coronary artery with collaterals.



SPECT and PET images in a 67-year-old woman with atypical angina. Images are shown in short-axis views, with stress (*left*) and rest (*right*) in each panel. Shifting breast position between the rest and stress SPECT acquisitions produced an apparent reversible apical, anterior, and anterolateral attenuation artifact (*arrowheads*) resembling ischemia. With PET and its built-in attenuation correction in the same patient, the defect was not present. SPECT, single-photon emission computed tomography; PET, positron emission tomography.



Mesh cinegraphic display of images obtained from electrocardiographic gating of a SPECT <sup>99m</sup>Tc sestamibi scan in a 64-year-old male patient with a previous infarct (same patient as in Fig. e29-2). Gated images are generally acquired about 30–45 min following stress. Electrocardiographic gating allows calculation of left ventricular volumes and global systolic function, as well as visual assessment of regional wall motion. In this patient, the calculated left ventricular ejection fraction was 13%. There was severe global hypokinesis.

## MRI AND CT IMAGING

### MAGNETIC RESONANCE IMAGING

- Basic principles MRI is a technique based on the magnetic properties of hydrogen nuclei. In the presence of a large magnetic field, nuclear spin transitions from the ground state to excited states can be induced by an electric field, and as the nuclei relax and return to their ground state, they release energy in the form of electromagnetic radiation that is detected and processed into an image
- Although the large vascular vessels can be visualized on MRI without contrast agents, gadolinium is frequently employed as a contrast agent to produce magnetic resonance angiograms (MRAs)
- Contrast agents also provide enhanced soft tissue contrast as well as the opportunity to obtain rapid angiographic images during the first pass of contrast through the vascular system

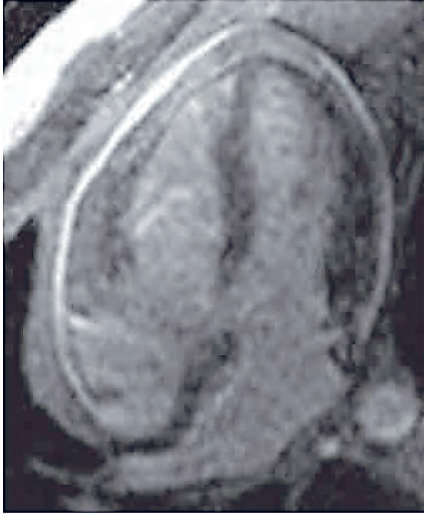

## MRA

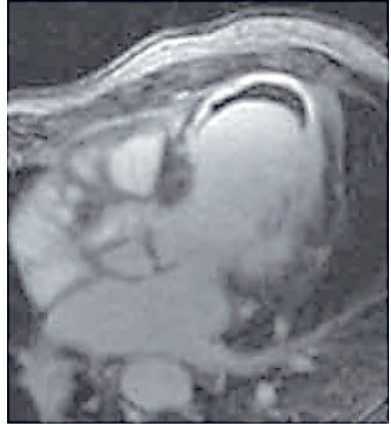
- **MRA** is a standard technique for imaging the aorta and large vessels of the chest and abdomen, with results essentially identical to conventional angiography
- **MRA** of the coronary arteries is a much more difficult challenge, both because of the small size of these vessels and because of their rapid and complex motion during the cardiac cycle; thus, coronary MRA is not yet a reliable clinical technique

## LIMITATIONS OF MRI

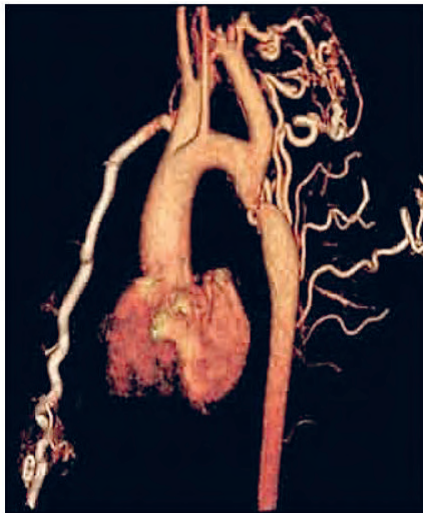- Relative contraindications to MRI include the presence of pacemakers, internal defibrillators, or cerebral aneurysm clips
- A small percentage of patients are claustrophobic and unable to tolerate the examination within the relatively confined quarters of the magnet bore
- Examination of clinically unstable patients and those undergoing stress testing is problematic, since close hemodynamic and electrocardiographic monitoring is difficult. Image quality in patients with significant arrhythmias is often limited
- Patients with renal disease receiving gadolinium contrast may be at risk of developing nephrogenic systemic fibrosis, characterized by increased tissue deposition of collagen in the skin and development of fibrosis in skin and other organs



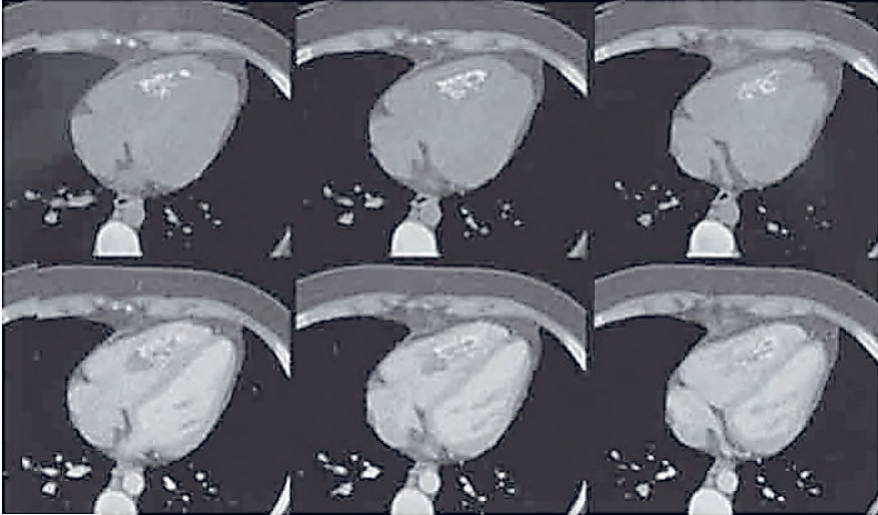
MR images with contrast enhancement in a patient with acute pericarditis. In the presence of pericardial inflammation, the gadolinium enhancement occurs, seen as a white layer in the pericardium.



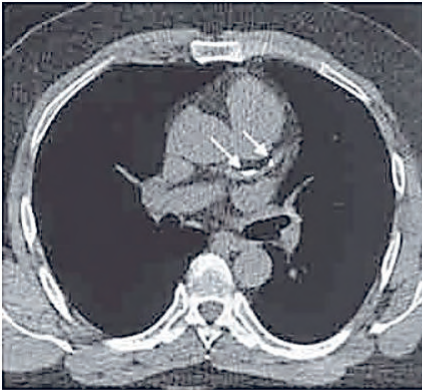
MR image with contrast enhancement of a patient with a large apical aneurysm and thrombus. Imaging the heart 10–20 min after gadolinium injection demonstrates enhancement of the infarcted tissue (visible as dense white image). The infarcted tissue retains contrast by virtue of its large extracellular volume. The left ventricular thrombus adherent to the infarcted myocardium is shown as a dark laminated area adjacent to the white myocardium.



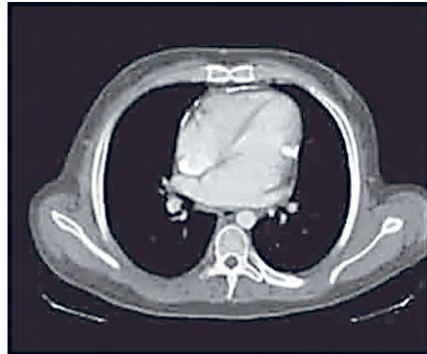
Three-dimensional reconstruction of a CT angiogram, showing a severe coarctation of the descending aorta. The large collateral vessels are the result of the severe stenosis of the distal thoracic aorta.



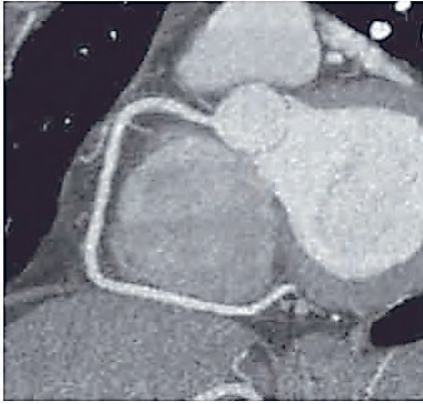
Cardiac CT images demonstrating a calcified mass in the right ventricle, which at pathologic examination was a chronic thrombus. Calcification is seen as a bright signal in both the noncontrast (*upper*) and contrast-enhanced (*lower*) images.



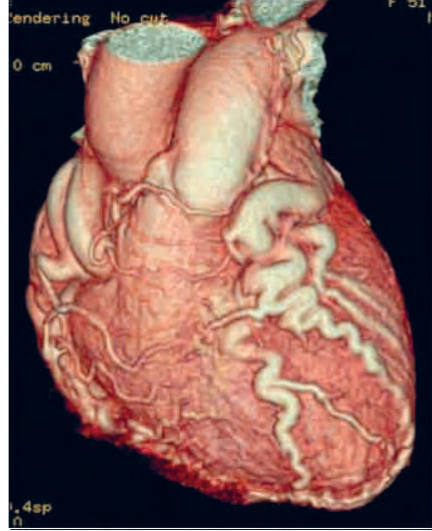
Noncontrast image from an electron beam CT revealing two small foci of calcification in the left anterior descending artery (*arrows*).



CT image from a patient with calcific constrictive pericarditis. Calcification is seen as a bright signal in the anterior pericardium as well as calcification extending into the lateral wall of the left ventricle.



A reconstructed CT coronary angiogram showing a normal right coronary artery.



Three-dimensional reconstruction of a CT angiogram showing a large fistula of the left anterior descending artery.

### Selection of Imaging Tests

	Echo	Nuclear	CT <sup>a</sup>	MRI <sup>b</sup>
LV size/function	Initial modality of choice Low cost, portable Provides ancillary structural and hemodynamic information	Available from gated SPECT or PET imaging.	Best resolution Highest cost	Best resolution Highest cost
Valve disease	Initial modality of choice Valve motion Doppler hemodynamics			Visualize valve motion Delineate abnormal flow
Pericardial disease	Pericardial effusion Doppler hemodynamics		Pericardial thickening	Pericardial thickening
Aortic disease	TEE rapid diagnosis <sup>c</sup> Acute dissection		Image entire aorta Acute aneurysm Aortic dissection	Image entire aorta Aortic aneurysm Chronic dissection
Cardiac masses	TTE—large intracardiac masses TEE—smaller intracardiac masses <sup>c</sup>		Extracardiac masses Myocardial masses	Extracardiac masses Myocardial masses

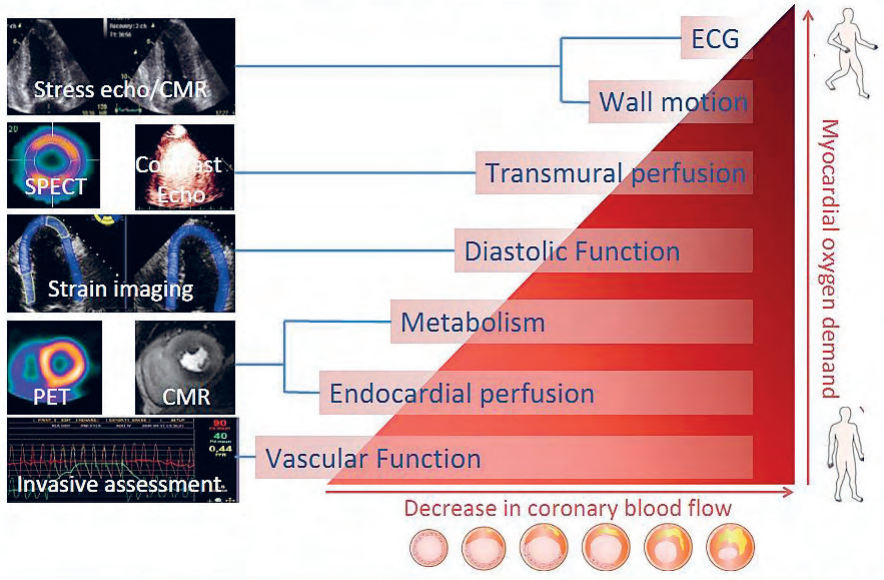
<sup>a</sup>Contrast required.

<sup>b</sup>Relative contraindication: pacemakers, metallic objects, claustrophobic.

<sup>c</sup>When not seen on TTE.

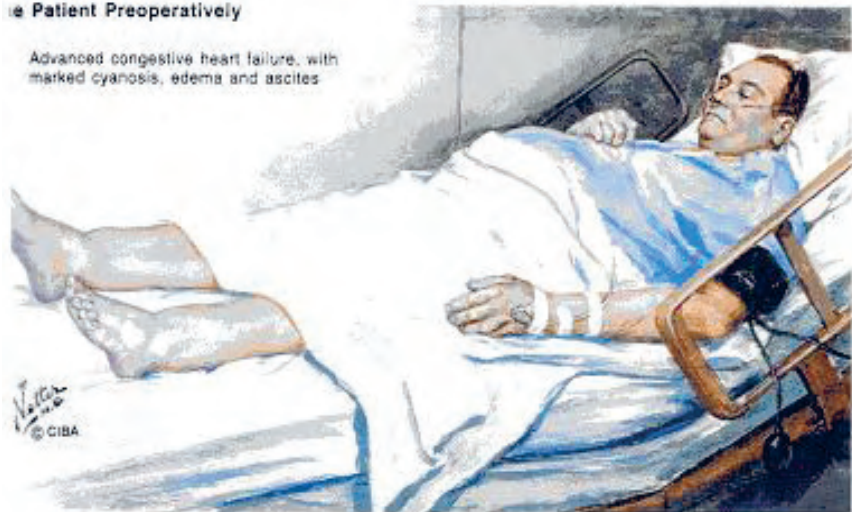
**Abbreviations:** Echo, echocardiography; PET, positron emission tomography; SPECT, single-photon emission computed tomography; TEE, transesophageal echocardiography; TTE, transthoracic echocardiogram.

# The ischaemic cascade - imaging



## ie Patient Preoperatively

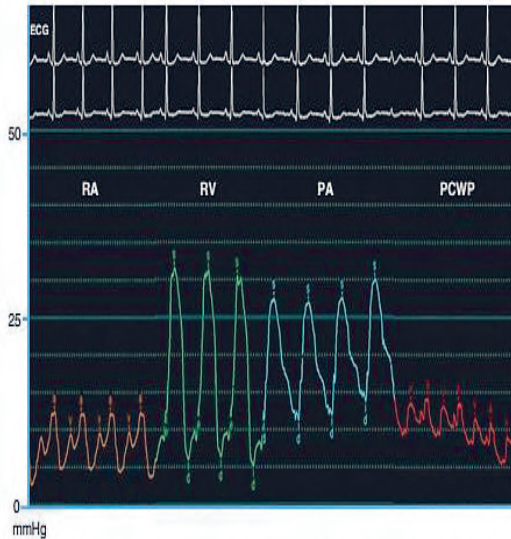
Advanced congestive heart failure, with marked cyanosis, edema and ascites



# Diagnostic Cardiac Catheterization and Coronary Angiography

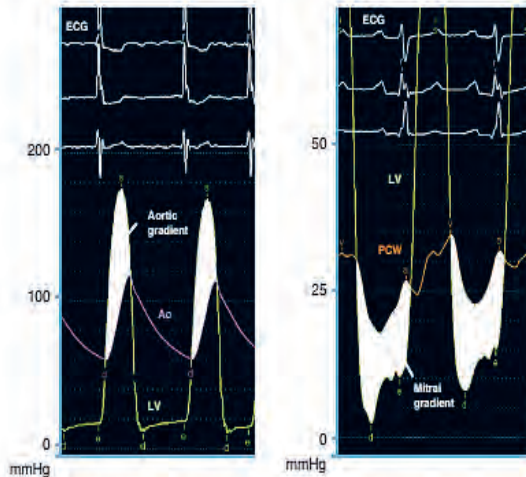
## CARDIAC CATHETERIZATION AND ANGIOGRAPHY

- Cardiac catheterization and angiography provide for detailed assessment of the anatomy and physiology of the heart and vasculature and represent the “gold standard” for assessment of cardiac disease
- The technique first was applied to humans by Forssmann in 1929, but it was expanded into a diagnostic tool by Cournard and Richards; in 1956, all three physicians shared the Nobel Prize for their discovery
- Selective coronary angiography was introduced by Sones in 1963 and modified further by Judkins
- Cardiac catheterization is now the second most common operative procedure in the United States, with almost 2 million procedures performed annually



Normal hemodynamic waveforms recorded during right heart catheterization. Atrial pressure tracings have a characteristic “a” wave that reflects atrial contraction and a “v” wave that reflects pressure changes in the atrium during ventricular systole. Ventricular pressure tracings have a low

pressure diastolic filling period and a sharp rise in pressure that occurs during ventricular systole. RA, right atrium; RV, right ventricle; PA, pulmonary artery; PCWP, pulmonary capillary wedge pressure; s, systole; d, diastole.

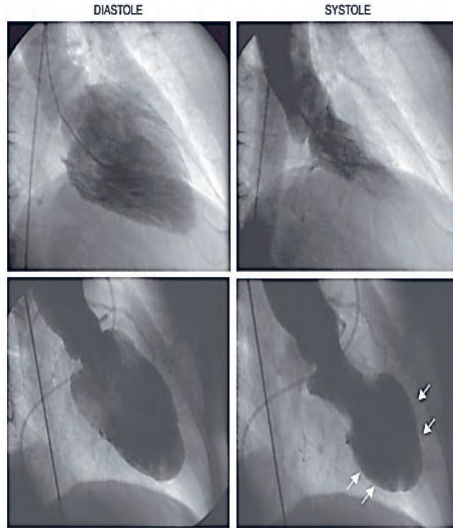


Severe aortic and mitral stenosis. Simultaneous recording of left ventricular (LV) and aortic (Ao) pressure tracings demonstrate a 62-mmHg mean systolic gradient (shaded area) that corresponds to an aortic valve area of  $0.6 \text{ cm}^2$  (left). Simultaneous recording of LV and pulmonary

capillary wedge (PCW) pressure tracings reveal a 14-mmHg mean diastolic gradient (shaded area) that is consistent with critical mitral stenosis (mitral valve area =  $0.5 \text{ cm}^2$ ). S, systole; d, diastole; e, end diastole.

## VENTRICULOGRAPHY AND AORTOGRAPHY

- Ventriculography to assess left ventricular function may be performed during cardiac catheterization
- A pigtail catheter is advanced retrograde across the aortic valve into the left ventricle and 30–45 mL of contrast is power-injected to visualize the left ventricular chamber during the cardiac cycle
- The ventriculogram is usually performed in the right anterior oblique projection to examine wall motion and mitral valve function
- Normal wall motion is observed as symmetric contraction of all segments; hypokinetic segments have decreased contraction, akinetic segments do not contract, and dyskinetic segments appear to bulge paradoxically during systole
- Ventriculography may also reveal a left ventricular aneurysm, pseudoaneurysm, or diverticulum and can be used to assess mitral valve prolapse and the severity of mitral regurgitation



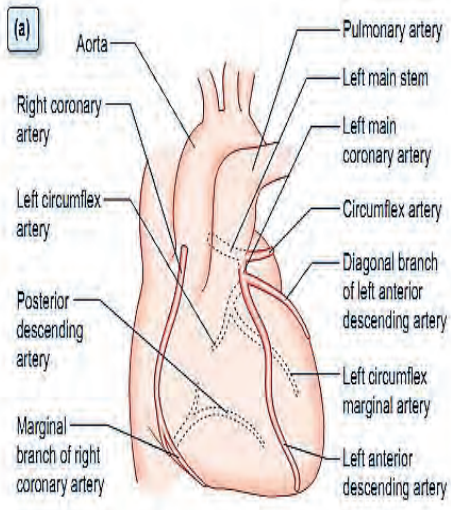
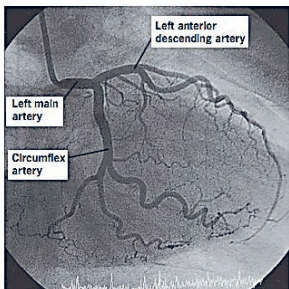
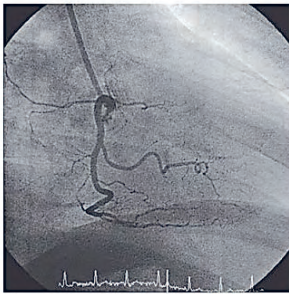
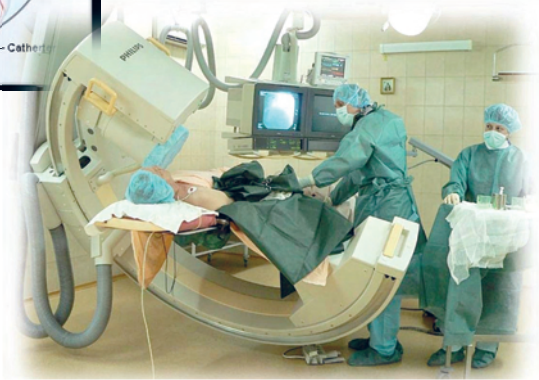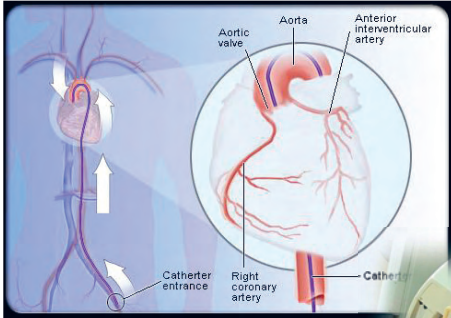
Left ventriculogram at end diastole (left) and end systole (right). In patients with normal left ventricular function, the ventriculogram reveals symmetric contraction of all walls (top). Patients with coronary artery disease may have wall motion abnormalities on ventriculography as seen in this 60-year-old male following a large anterior myocardial infarction. In systole, the anterior, apical, and inferior walls are akinesic (white arrows) (bottom).

## CORONARY ANGIOGRAPHY

- Selective coronary angiography is almost always performed during cardiac catheterization and is used to define the coronary anatomy and determine the extent of epicardial coronary artery and coronary artery bypass graft disease
- Specially shaped coronary catheters are used to engage the left and right coronary ostia. Hand injection of radiopaque contrast agents create a coronary “luminogram” that is recorded on a radiographic images (cine angiography)
- Because the coronary arteries are three-dimensional objects that are in motion with the cardiac cycle, angiograms of the vessels using several different orthogonal projections are taken to best visualize the vessels without overlap or foreshortening

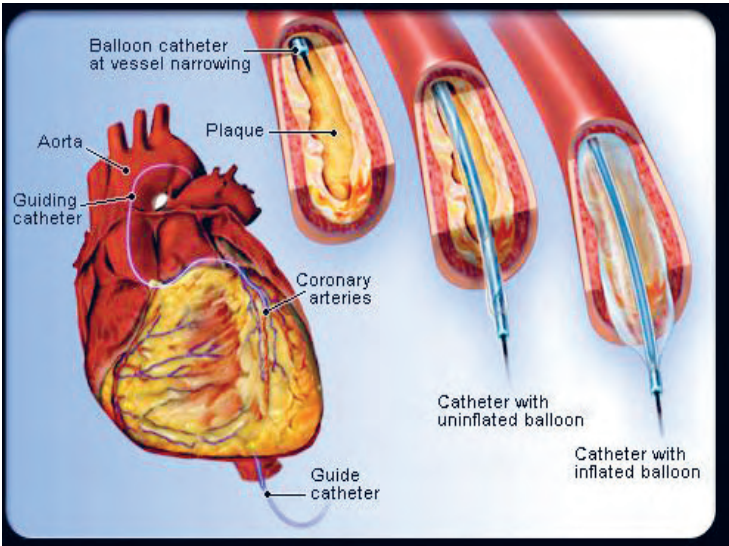
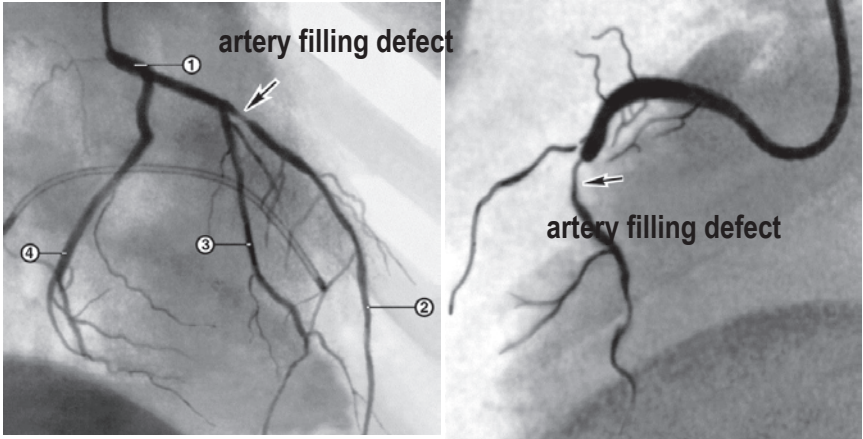


# Coronary angiography



a) Diagram of the normal coronary arterial anatomy. (b) Angiogram of non-dominant right coronary system. (c) Angiogram of dominant left coronary system.

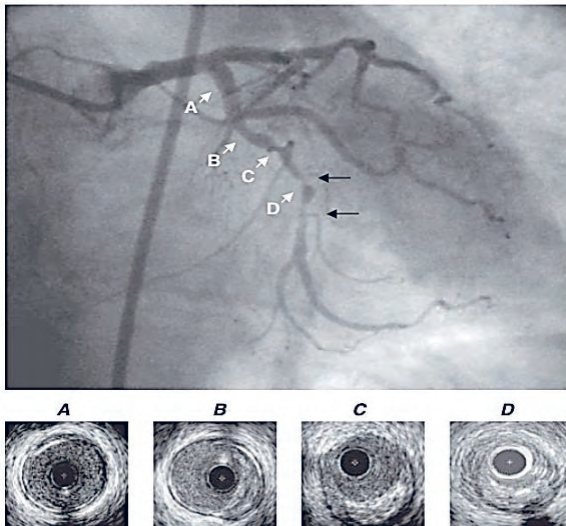
# Coronary angiography



# Coronary angioplasty

## INTRAVASCULAR ULTRASOUND, FRACTIONAL FLOW RESERVE AND CORONARY FLOW RESERVE

- During coronary angiography, intermediate stenosis (40–70%), indeterminate findings, or anatomic findings that are incongruous with the patient's symptoms may require further interrogation
- In these cases, intravascular ultrasound provides a more accurate anatomic assessment of the coronary artery and the degree of coronary atherosclerosis
- Intravascular ultrasound is performed using a small flexible catheter with a 40-mHz transducer at its tip that is advanced into the coronary artery over a guide wire
- Data from intravascular ultrasound studies may be used to image atherosclerotic plaque precisely, determine luminal cross-sectional area, and measure vessel size; it is also used during or following percutaneous coronary intervention to assess the stenosis and determine the adequacy of stent placement
- Measurement of the fractional flow reserve provides a functional assessment of the stenosis. The fractional flow reserve is the ratio of the pressure in the coronary artery distal to the stenosis divided by the pressure in the artery proximal to the stenosis at maximal vasodilation. Fractional flow reserve is measured using a coronary pressure-sensor guide wire at rest and at maximal hyperemia following the injection of adenosine. A fractional flow reserve of  $<0.75$  indicates a hemodynamically significant stenosis that would benefit from intervention



**Coronary stenoses on cine angiogram and intravascular ultrasound.** Significant stenoses in the coronary artery are seen as narrowings (black arrows) of the vessel. Intravascular ultrasound shows a normal segment of artery (A), areas with eccentric plaque (B, C), and near total obliteration of the lumen at the site of the significant stenosis (D). Note that the intravascular ultrasound catheter is present in the images as a black circle.

## REFERENCES

Kovalyova O.N., Ashcheulova T.V. Propedeutics to Internal Medicine. Part 1. – Vinnytsya: NOVA KNYHA, 2017. – 424 p.

Kovalyova O.N., Asheulova T.V. General inspection: manual for students. – Kharkov: "Turbo". – 2004. – 60 p.

Khomazjuk V.A., Ostashevskaya T.G., Krasnyuk I.V. Propaedeutics of Internal Medicine and Patient Care: Study guide for the practical classes. Part I. – Kyiv: NMU, 2005. – 44 p.

Kovalyova O.N., Asheulova T.V. Examination of the patients with cardiovascular disease: manual for students. – Kharkov: "Turbo". – 2003. – 92 p.

Kovalyova O.N., Asheulova T.V., Shapovalova S.A. Instrumental methods examination of cardiovascular system: manual for students. – Kharkov: KSMU. – 2004. – 147 p.

Bickley, Lynn S.; Szilagyi, Peter G. Bates' Guide to Physical Examination and History Taking, 10th Edition. -934p. Copyright ©2009 Lippincott Williams & Wilkins

The Point online resources, <http://thepoint.lww.com>

LECTURE # **8**

**CLINICAL ECG**

## THE PLAN

- Introduction – History
- Functions of the heart
- General scheme of ECG interpretation
- ECG SYNDROMES: Arrhythmia, s. Conduction disorders, Heart hypertrophy, Myocardial damage
- Ambulatory electrocardiogram – Indications for ambulatory ECG monitoring
- ARRHYTHMIAS
- RHYTHM ORIGEN
- Atrial FIBRILLATION
- Ventricular Flutter & Ventricles Fibrillation
- Heart conduction dysfunction
- Heart hypertrophy (LAH, RAH, LVH, RVH) - Selected criteria
- References



It's better not to know anything at all  
either than to know bad.

**Publius Sire**

## Key concepts

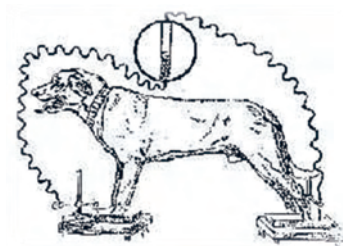
- The electrocardiogram (ECG) is one of the
  - simplest,
  - inexpensive,
  - safest,
- and reproducible techniques that exist in medicine

### • The limitations of the ECG

- ❑ The abnormal ECG without apparent heart disease
- ❑ and the normal ECG in serious heart disease: two extremes'




Augustus Desire Waller, 1856-1922



Waller AD. Introductory Address on The Electromotive Properties of the Human Heart. Brit. Med J, 1888; 2:751-754.

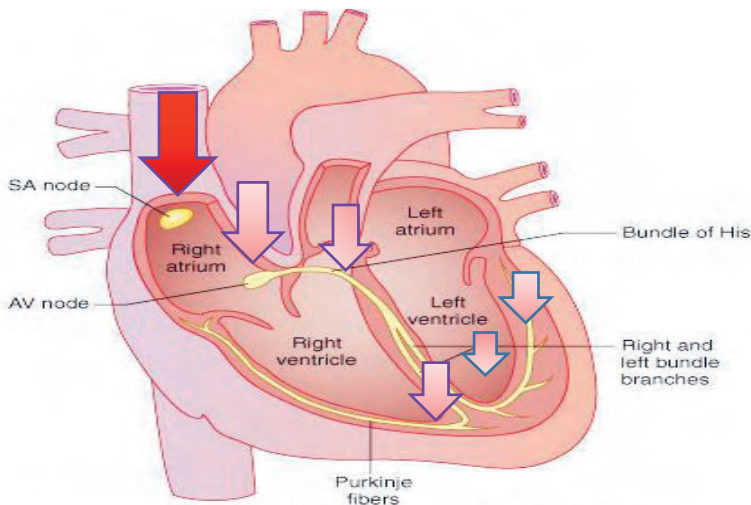
!....





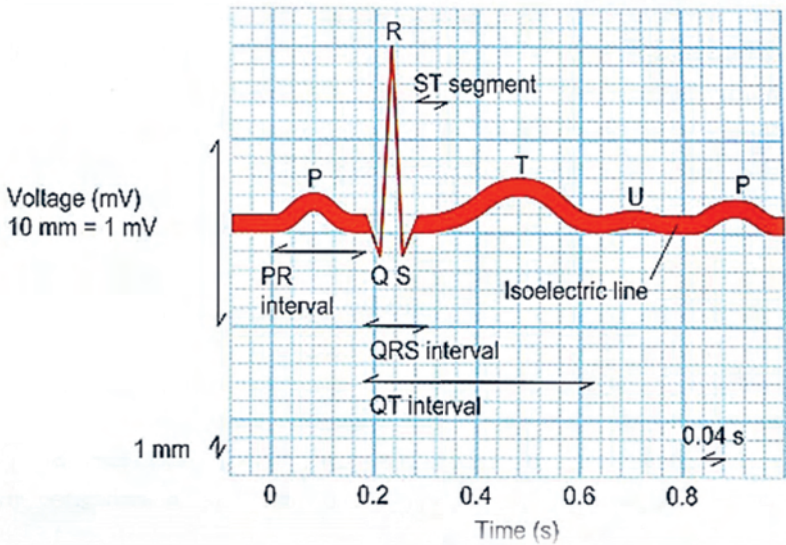
## Functions of the heart:

- **Automatism (chronotropic effect)** - the ability of the heart to generate electric impulses.
- **Conduction (dromotropic effect)** - the ability of the myocardium to conduct impulses from the point of origin to the contractile myocardium.
- **Excitability (bathmotropic effect)** - the ability of the heart to irritate under the influence of impulses.
- **Refractivity** - the inability of the excited myocardial cells become active again due to additional impulses:
  - absolute (heart does not respond to any stimulation) and
  - relative (heart responds to a very strong excitation).
- **Aberrantly** - pathological conduct electrical impulses on the atria and ventricles.
- **Contractility (inotropic effect)** - the ability of the heart to contract under the influence of impulses and provide the function of the pump.



• **Cardiac conduction system.** The normal conducting system consists of pacemaker cells in the sinoatrial (SA) nodal complex, specialized intra-atrial conducting tracts (including Bachmann's bundle), the atrioventricular (AV) node, the His-Purkinje system, and working atrial and ventricular myocardium.

Copyright © 2008 by Saunders, an imprint of Elsevier Inc. All rights reserved.



● **It's time to repeat.....**

## ECG analyses

General scheme of ECG interpretation:

1. Verifying the ECG registration.
2. Analysis of cardiac rhythm and conduction :
  - estimation of the regularity of heart rate,
  - heart rate calculation,
  - determination of the excitation source,
  - conduction analyses.
3. Determination of electrical axis of the heart.
4. P wave and P – Q interval analyses.
5. Ventricular complex QRST analyses:
  - **QRS complex analyses,**
  - **S – T segment analyses,**
  - **T wave analyses,**
  - **Q – T interval analyses.**
6. **ECG conclusion.**

## ECG conclusion

### ECG SYNDROMES:

- **Arrhythmias.**
- **Conduction disorders**
- **Heart hypertrophy**
- **Myocardial damage**

## The ECG is the best diagnostic tool

for the diagnosis and evaluation of...

- all types of active and passive arrhythmias,
- preexcitation syndromes,
- channelopathies,
- interatrial blocks,
- ventricular blocks, and acute ischemic events

It is very useful for detection of

- cardiomyopathies,
- athlete evaluation,
- follow-up of chronic ischemic heart disease, and other disorders

- **The ECG is also the technique used for control of pacemakers and cardiac resynchronization therapy**

*Key concepts*

## Ambulatory electrocardiogram

- Ambulatory electrocardiogram (AECG) monitoring has been used as a diagnostic procedure in cardiology for over **60** years. Current techniques used for AECG monitoring include continuous and/or intermittent external recorders, patch monitors, smartphone-based devices, and implantable loop recorders
- The major goal of AECG monitoring, independently of the applied technique, is to detect and characterize **arrhythmic events during daily activities of patients and to correlate symptoms with electrocardiogram (ECG) findings**
- It is particularly important in case of intermittent symptoms and/or transient ECG disturbances that cannot be detected by means of short, resting surface ECG recordings

### Ambulatory electrocardiogram

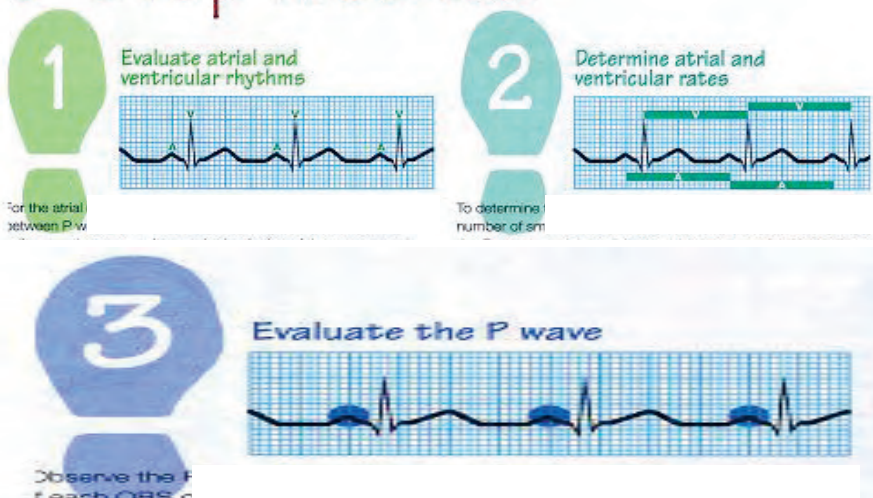


## Ambulatory electrocardiogram

### Indications for ambulatory ECG monitoring

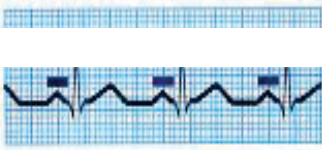
- The main indications for AECG monitoring include
  - (1) detection and characterization of arrhythmias in order to correlate them with patients' symptoms such as
    - syncope,
    - dizziness, palpitations, or
    - chest pain;
  - (2) diagnosis and risk stratification in certain cardiac diseases; and
  - (3) evaluation of the efficacy of pharmacological or invasive treatment (e.g. ablation procedures).

## 8-step method



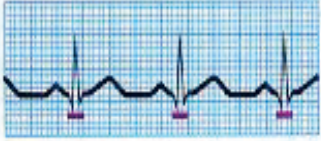
### 8-step method

**4** Calculate the PR interval



Count the num  
P wave and the

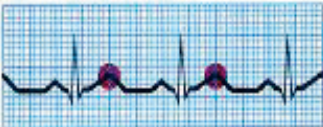
**5** Calculate the duration of the QRS complex



Count the num  
of the QRS co

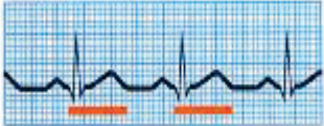
### 8-step method

**6** Evaluate the T wave



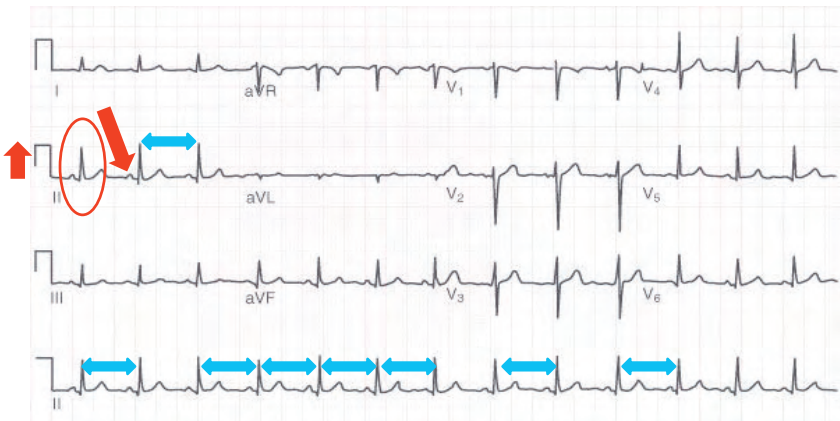
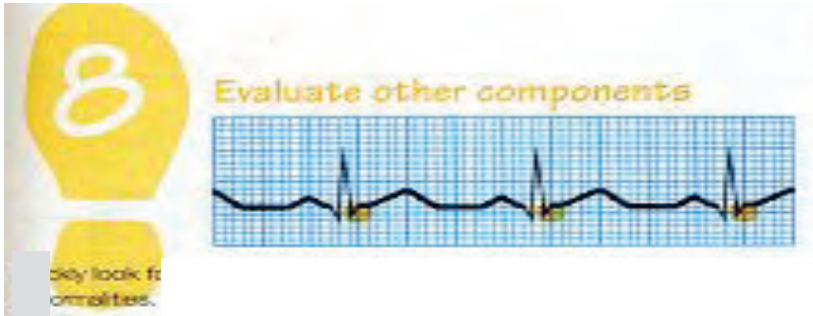
Check that T wave  
amplitude, and

**7** Calculate the duration of the QT interval



Count the num  
complex to the

## 8-step method



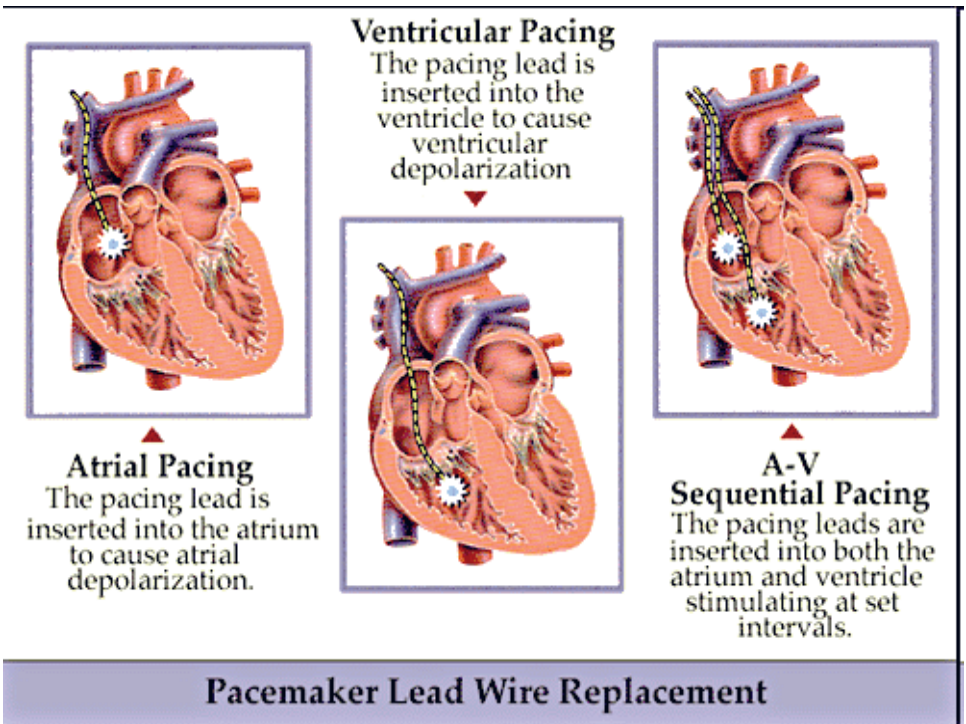
• **Normal electrocardiogram.** The heart rate is approximately 78 beats per minute, with minor irregularity. Sinus arrhythmia is present. The axis is approximately  $+60$  degrees. The PR, QRS, and QT intervals are approximately 140, 90, and 360 msec, respectively. P wave morphology, duration, and axis are normal. The transition is between leads  $V_3$  and  $V_4$ . No abnormal Q waves are present. ST segments are isoelectric, and T waves are concordant with QRS complexes.

Copyright © 2008 by Saunders, an imprint of Elsevier Inc. All rights reserved.

## ECG CONCLUSION

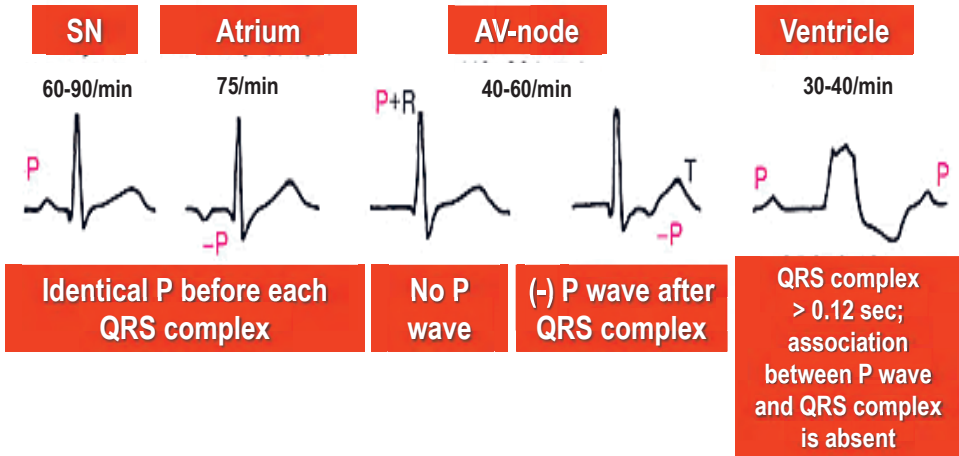
- ECG SYNDROMS:
- Arrhythmias
- Conduction disorders
- Heart hypertrophy
- Myocardial damage

## ARRHYTHMIAS

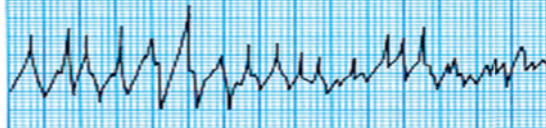
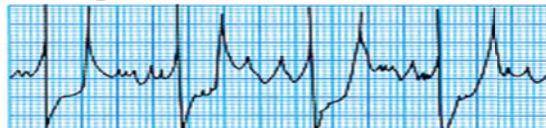
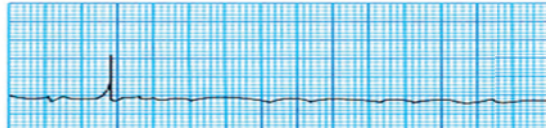




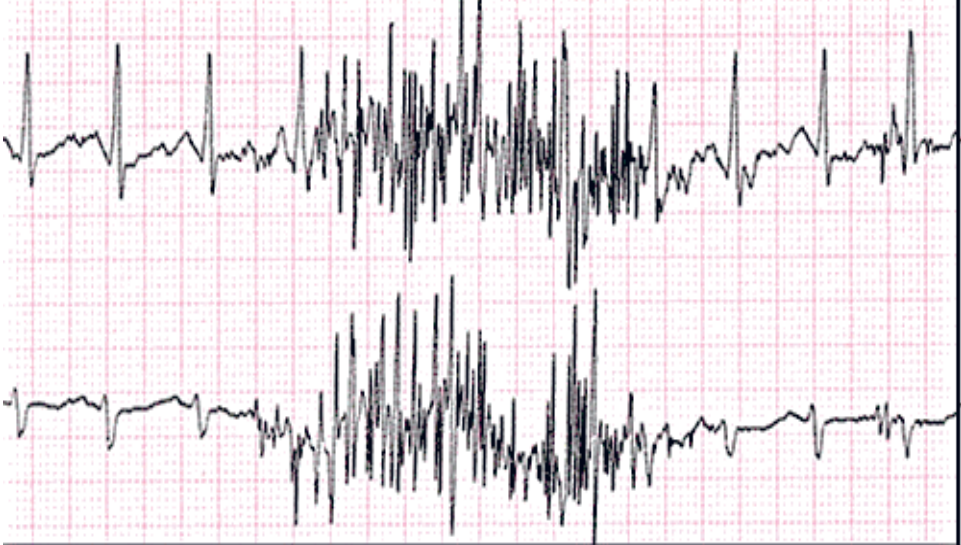
## RHYTHM ORIGIN



## Troubleshooting monitor problems

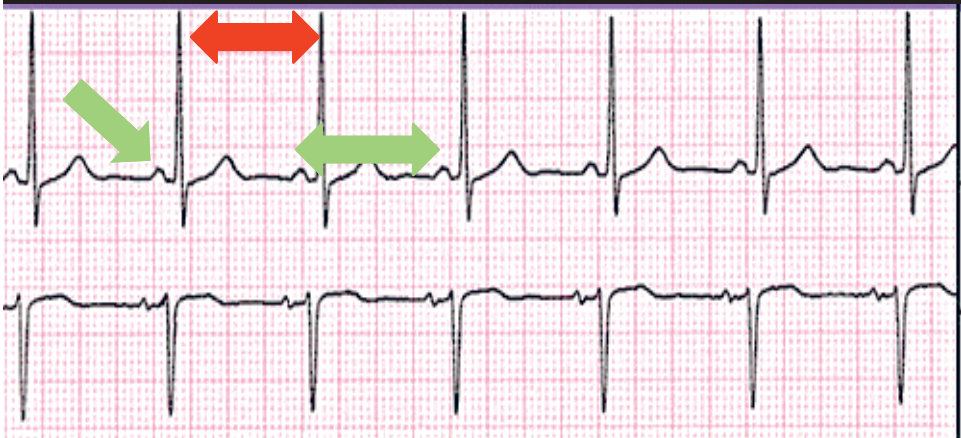
What you see	What might cause it
<p><b>Artifact (waveform interference)</b></p> 	<ul style="list-style-type: none"> <li>Seizures</li> <li>Chills</li> <li>Anxiety</li> <li>Improper electrode application</li> <li>Short circuit in lead-wires or cable</li> <li>Electrical interference from other electrical equipment in the room</li> </ul>
<p><b>False high-rate alarm</b></p> 	<ul style="list-style-type: none"> <li>Gain setting too high, particularly with MCL<sub>1</sub> setting</li> </ul>
<p><b>Weak signals</b></p> 	<ul style="list-style-type: none"> <li>Improper electrode application</li> <li>QRS complex too small to register</li> <li>Wire or cable failure</li> </ul>

### Muscle Tremor (somatic)



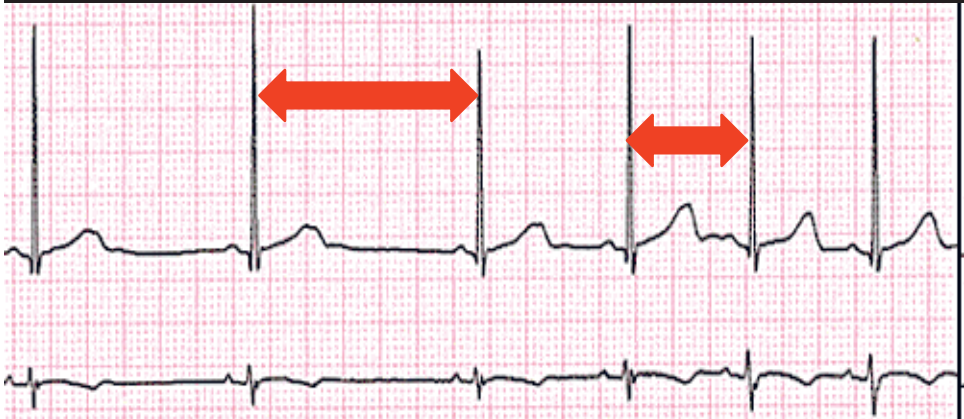
Electrical interference caused by the patient's tensed muscles.

### Normal Sinus Rhythm



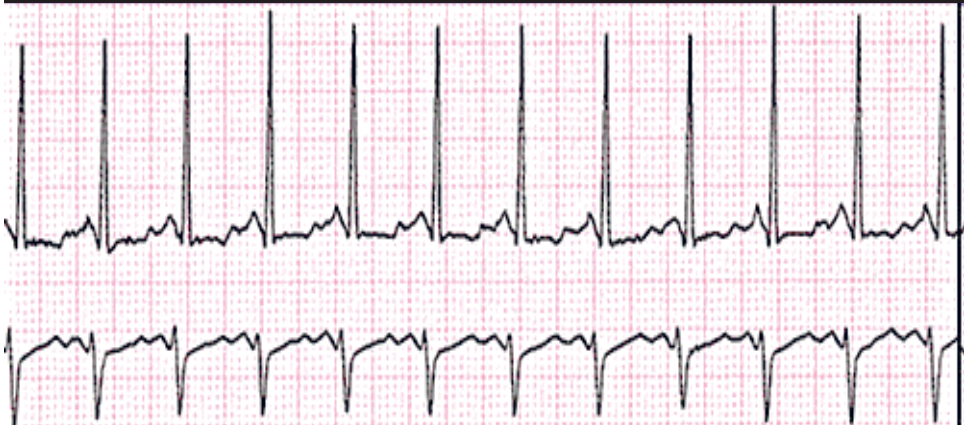Heart Rate	Rhythm	P Wave	PR interval (in seconds)	QRS (in seconds)
60-100 bpm	Regular	Before each QRS, identical	.12 to .20	<.12

## Sinus Arrhythmia



Heart Rate	Rhythm	P Wave	PR interval (in seconds)	QRS (in seconds)
Usually 60-100 bpm	Irregular	Before each QRS, identical	.12 to .20	<.12

## Sinus Tachycardia



Heart Rate	Rhythm	P Wave	PR interval (in seconds)	QRS (in seconds)
> 100 bpm	Regular	Before each QRS, identical	.12 to .20	<.12

# SD...

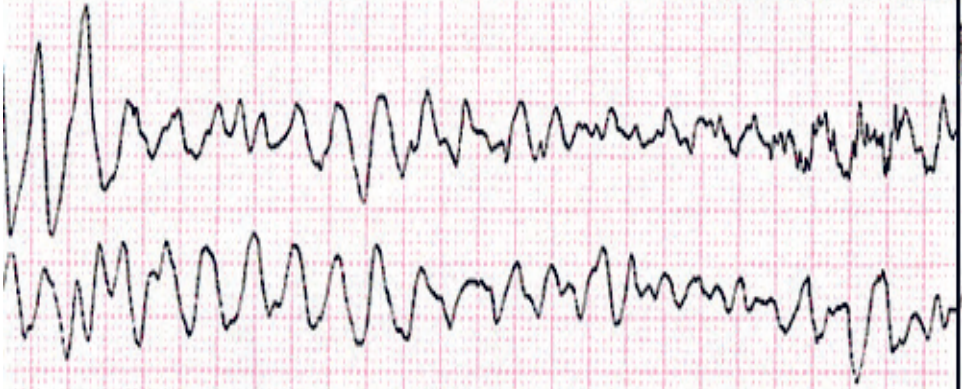24 Jan 2004, 24-year footballers, Miklos Feher (Hungary) died during the game....



## «SPORTS HEART»

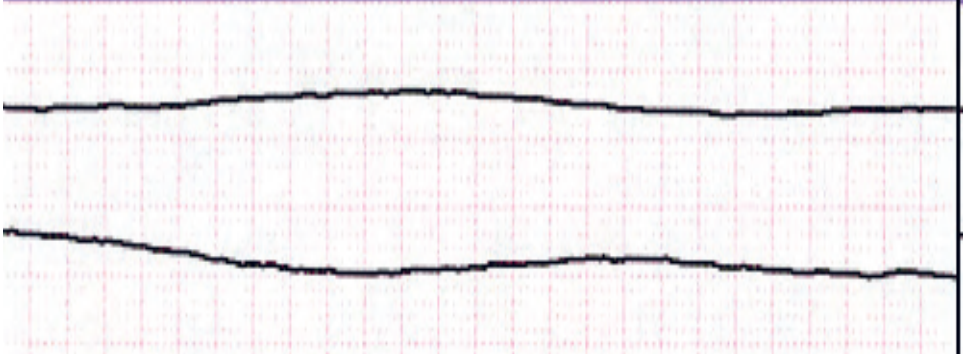


## Ventricular Fibrillation



Heart Rate	Rhythm	P Wave	PR interval (in seconds)	QRS (in seconds)
300-600	Extremely irregular	Absent	N/A	Fibrillatory baseline

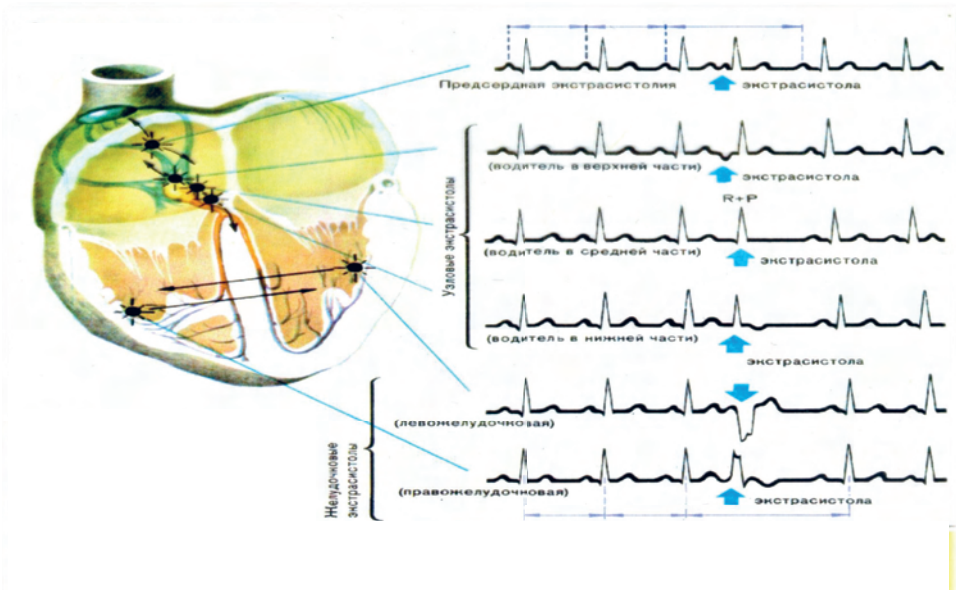
## Ventricular Asystole (standstill)



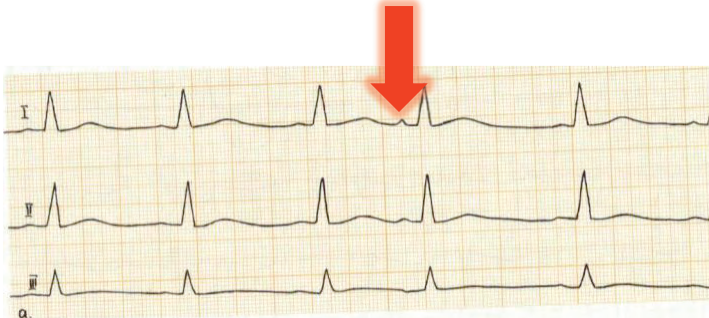
Heart Rate	Rhythm	P Wave	PR interval (in seconds)	QRS (in seconds)
Absent	Absent	Absent or present	N/A	Absent



## Premature beats

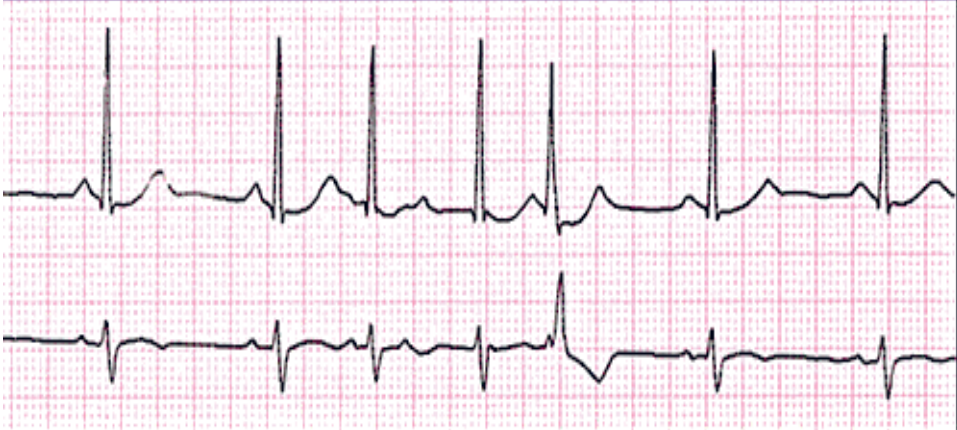

## Premature atrial beats



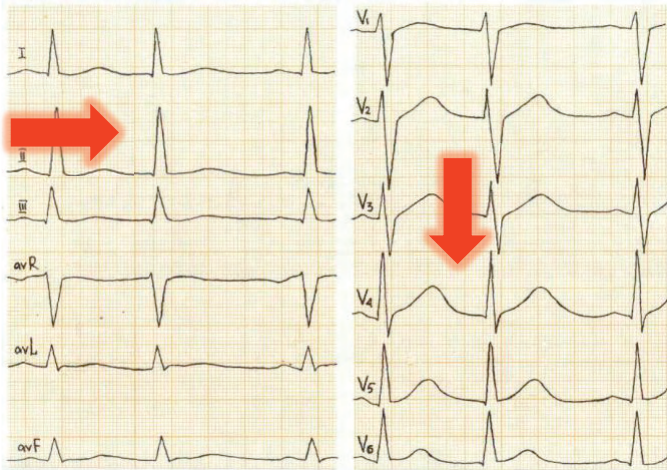
- 1) premature extraordinary appearance of the P-wave and the following QRST complex;
- 2) deformation or change in the polarity of the P-wave of the extrasystoles;
- 3) the presence of unchanged extrasystolic ventricular complex QRST, similar in shape to normal normal QRST complexes of sinus origin;
- 4) the presence after the atrial extrasystoles incomplete compensatory pause.

# Premature Atrial Contraction



Heart Rate	Rhythm	P Wave	PR interval (in seconds)	QRS (in seconds)
N/A	Irregular	Premature & abnormal or	<.20	<.12 Abnormal

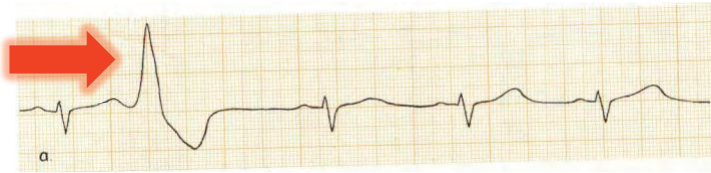
# Premature AV-beats



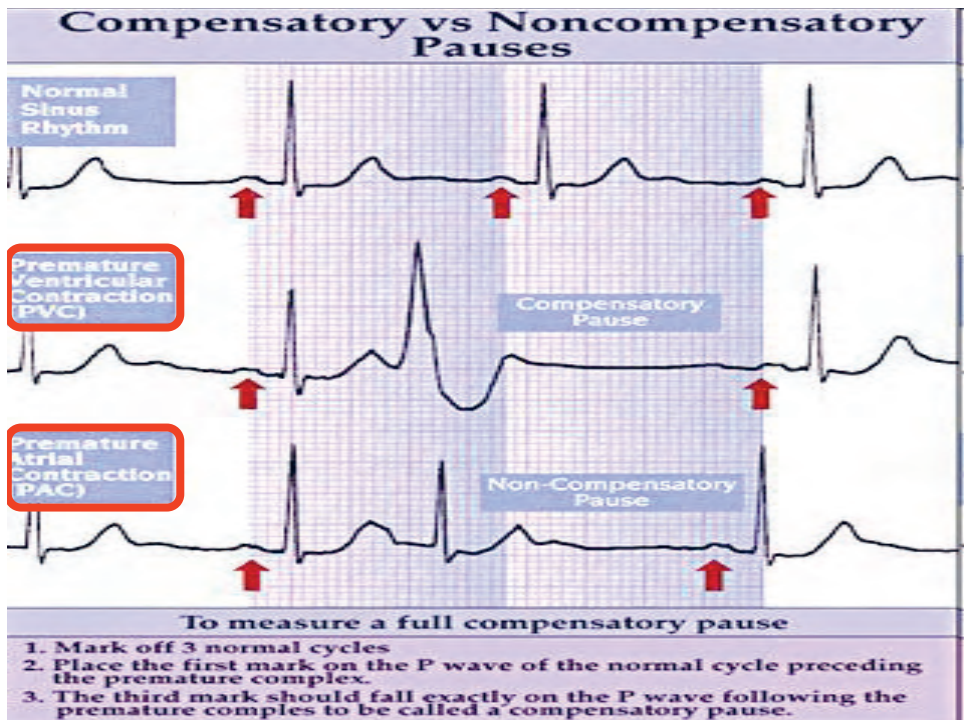
- 1) The appearance of premature unchanged ventricular QRS complex, similar in shape to the other QRST complexes of sinus origin;
- 2) negative prong P 'in leads II, III and aVF after extrasystolic QRS complex or absence of prong P' (merger of P 'and QRS')
- 3) presence of incomplete compensatory pause.

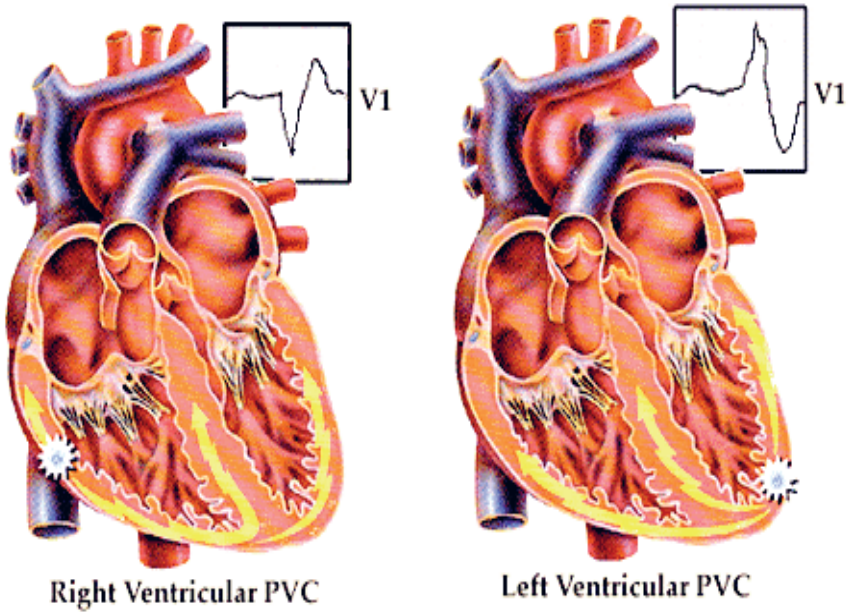


## Premature V-beats



- 1) premature extraordinary appearance on the ECG of a modified ventricular complex;
- 2) significant expansion and deformity of extrasystolic QRS complex;
- 3) the location of the RS segment — T and the T wave of extrasystoles is discordant to the direction of the main wave of the QRS complex;
- 4) the absence of a P wave before a ventricular extrasystole;
- 5) the presence in most cases after the ventricular extrasystole full compensatory pause.



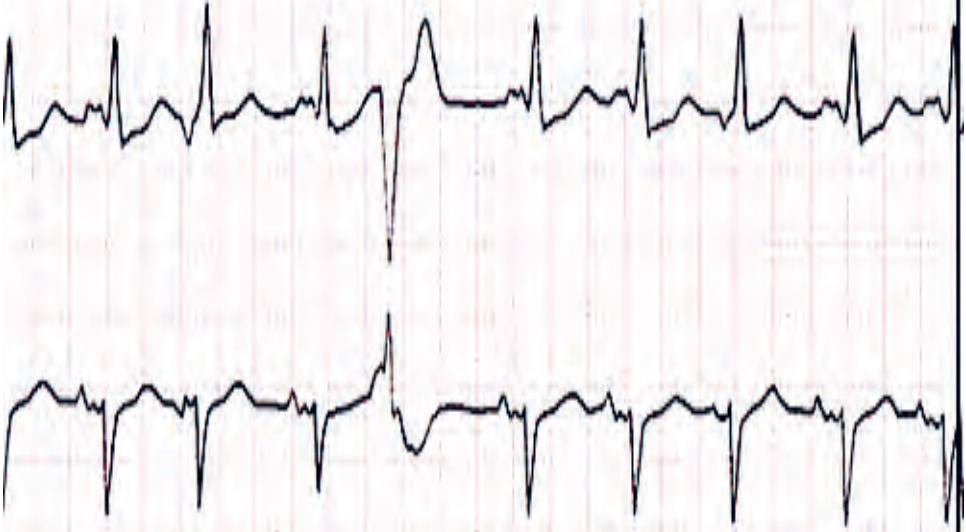

## Ventricular Conduction

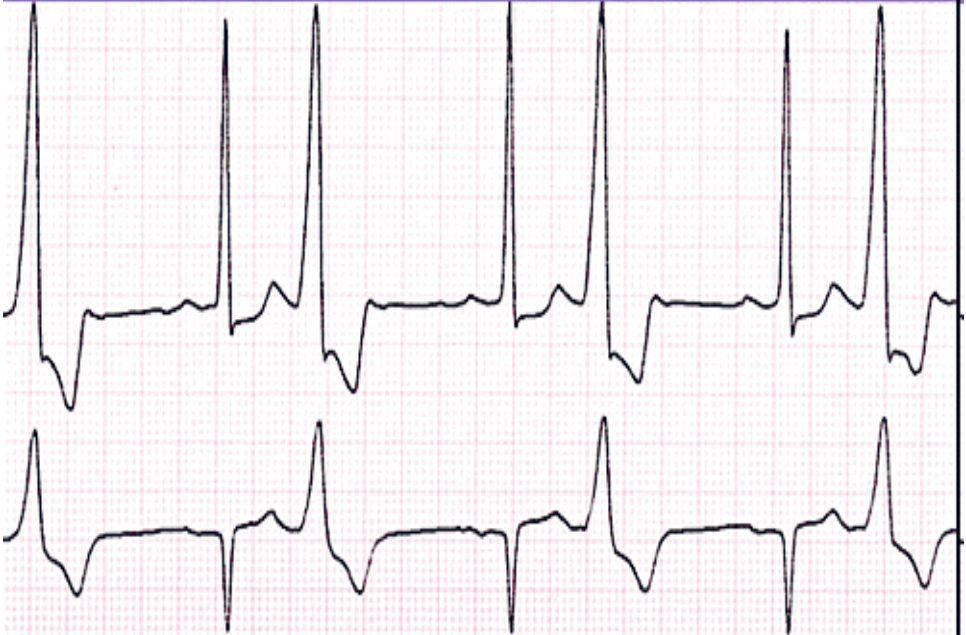
### Danger types of premature beats!!!

- frequent ventricular extrasystoles (more than 30 per hour), group (more than 3 consecutive);
- polytopic ventricular extrasystoles (different forms, enlarged ventricular complexes and ECG);
- early ventricular extrasystole so-called "R" to "T".

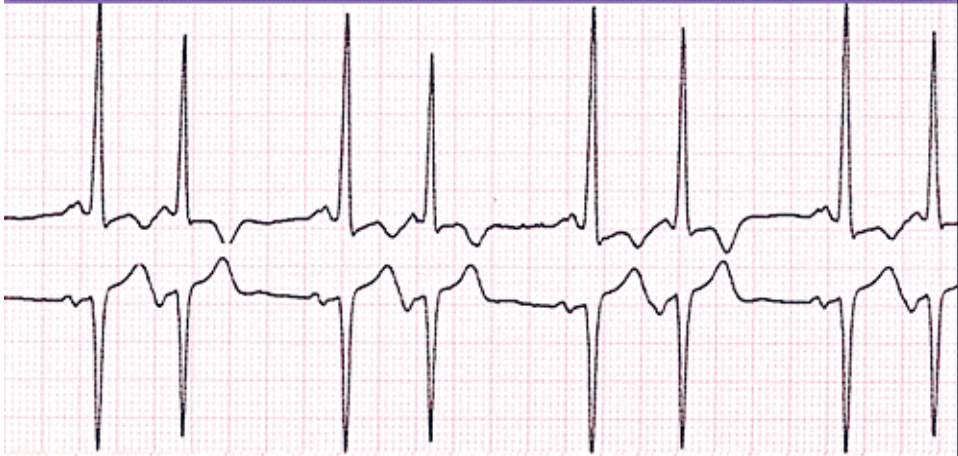
**R on T:** occur on the peak of the T wave of the preceding beat



**Bigeminal PVCs:** every other beat is a PVC

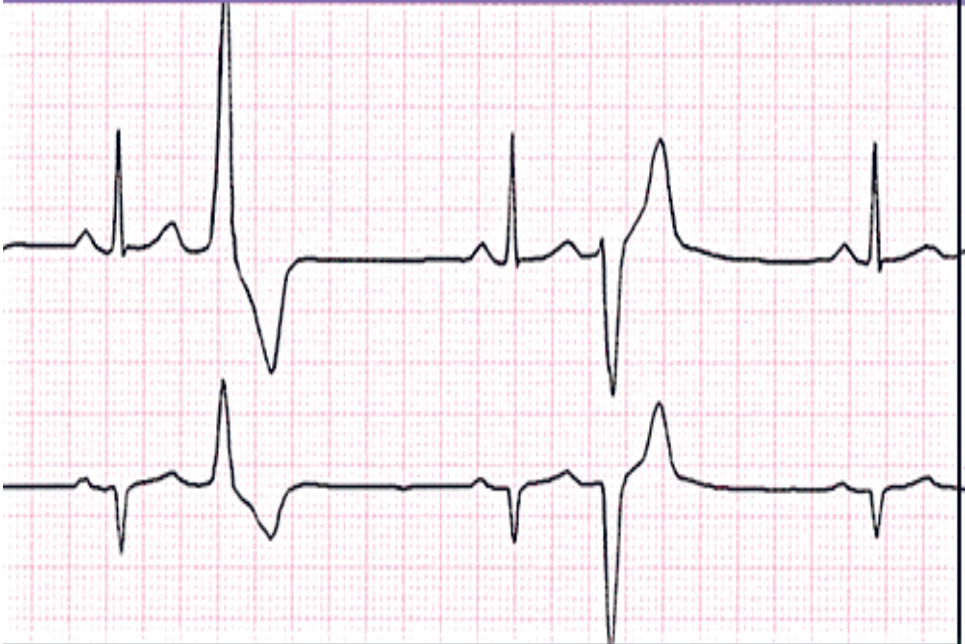

Premature Atrial Contraction – Atrial Bigeminy: every other beat is a PVC

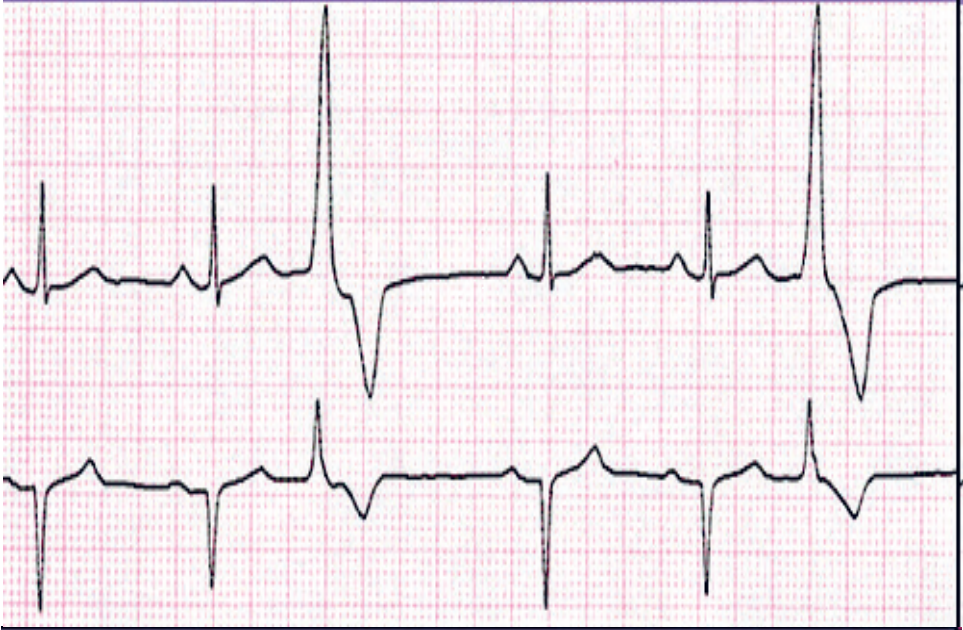


Heart Rate	Rhythm	P Wave	PR interval (in seconds)	QRS (in seconds)
N/A	Irregular	Premature & abnormal or hidden	<.20	<.12

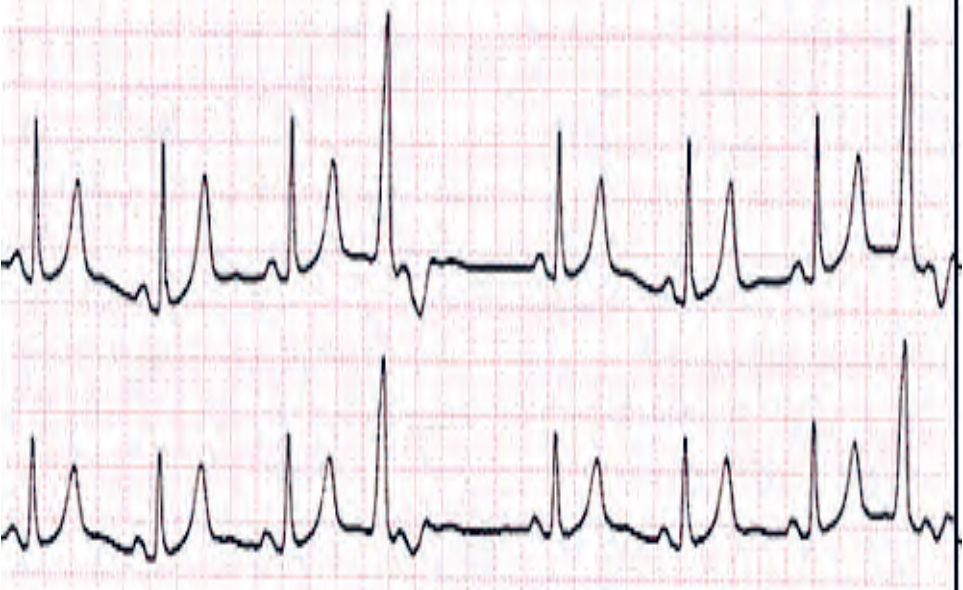Multifocal PVCs : more than one shape



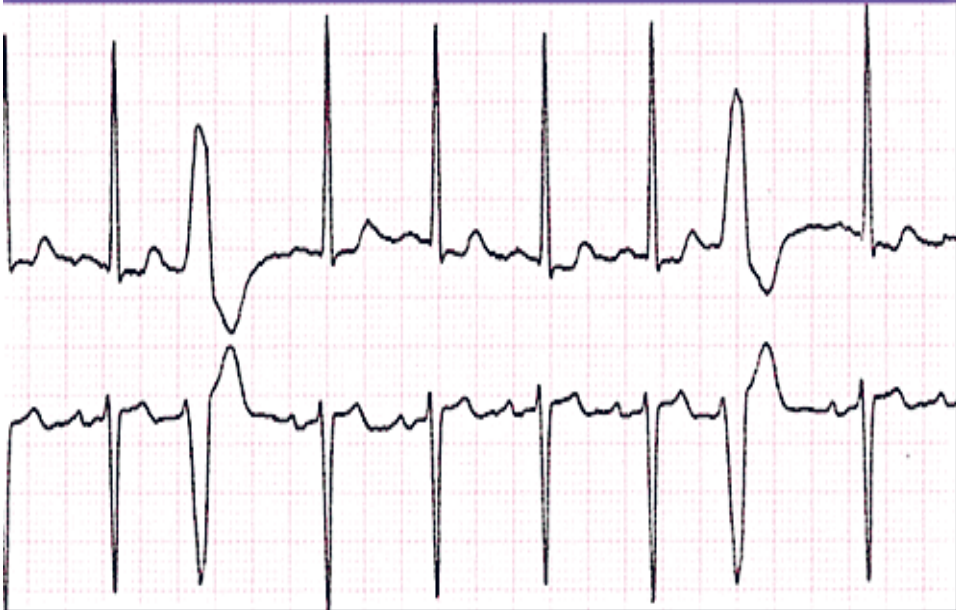
## Trigeminal PVCs: every third beat is a PVC



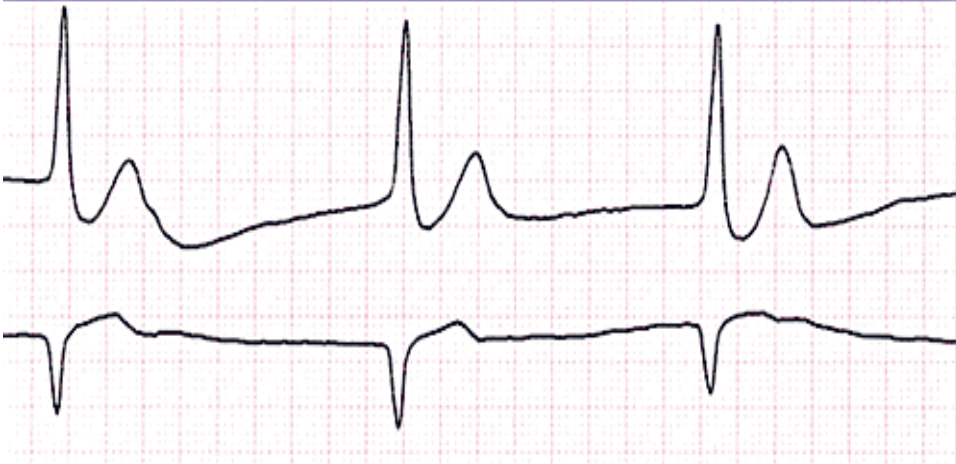
## Quadrigeminal PVCs: every fourth beat is a PVC



Unifocal PVCs: identical shapes  
Note: A single PVC is labeled isolated

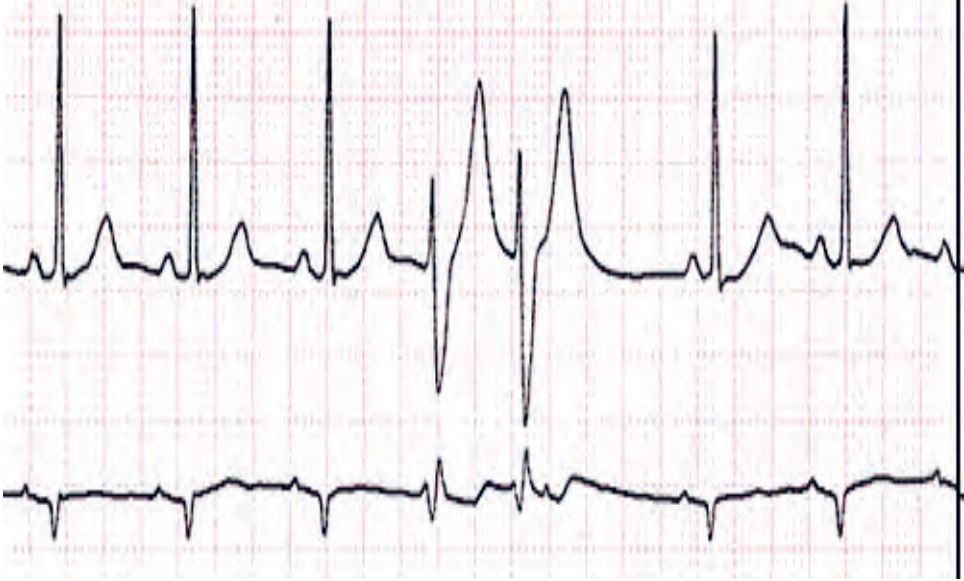

Idioventricular Rhythms

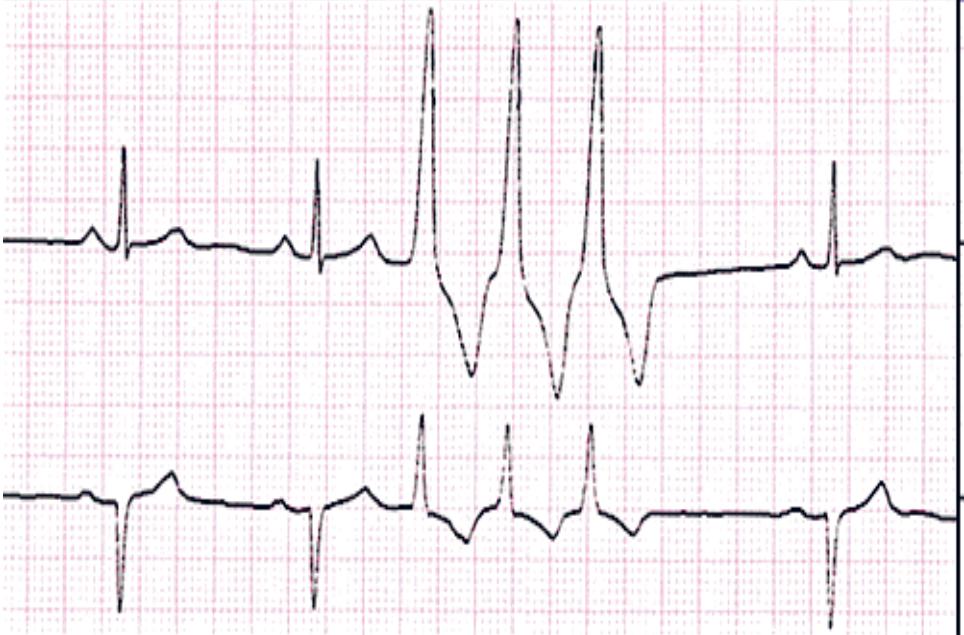

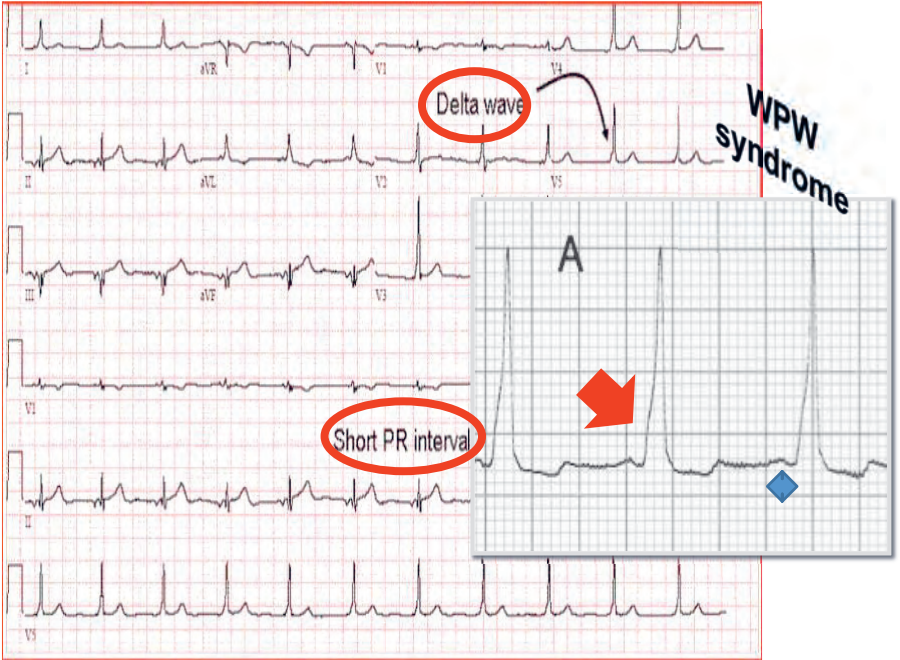
Heart Rate	Rhythm	P Wave	PR interval (in seconds)	QRS (in seconds)
20-40	Regular	Absent or not related	N/A	≥ .12

Coupled PVCs: occur in pairs

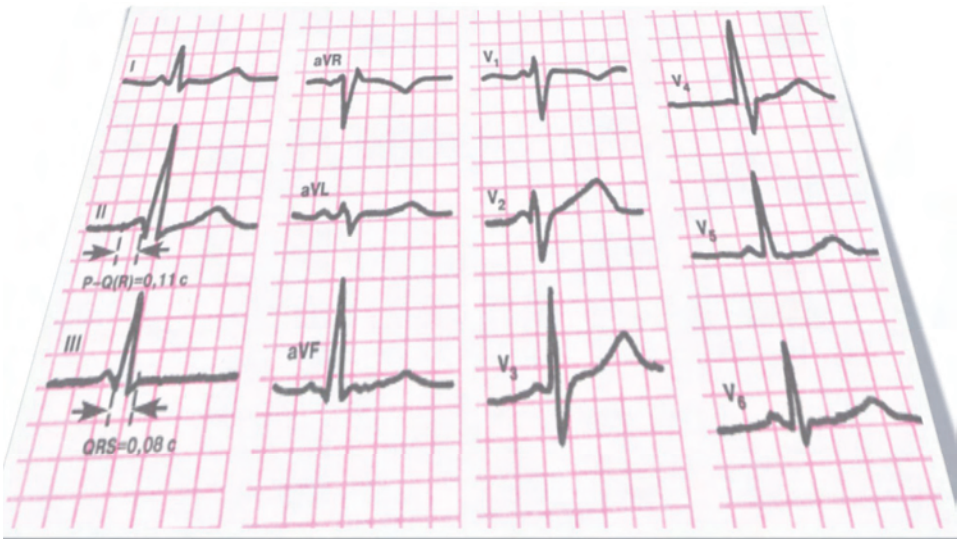


Triplet PVCs: occur in groups of three

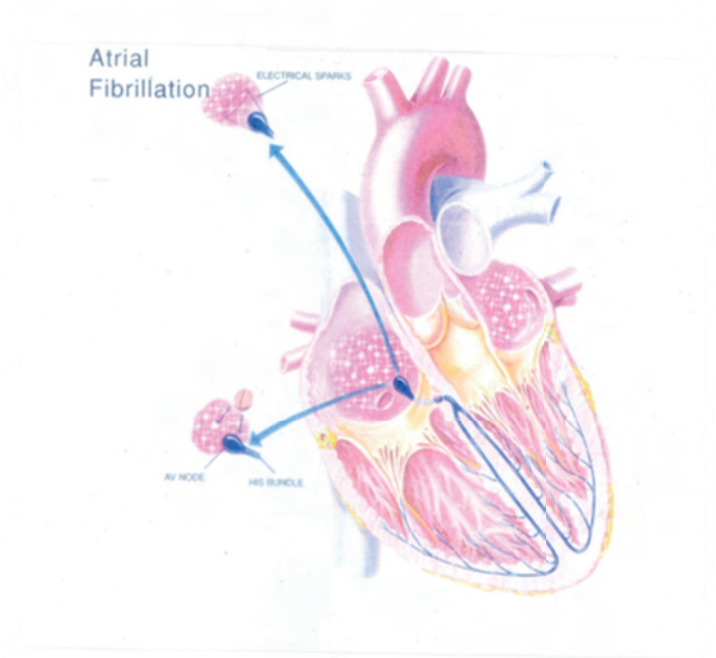



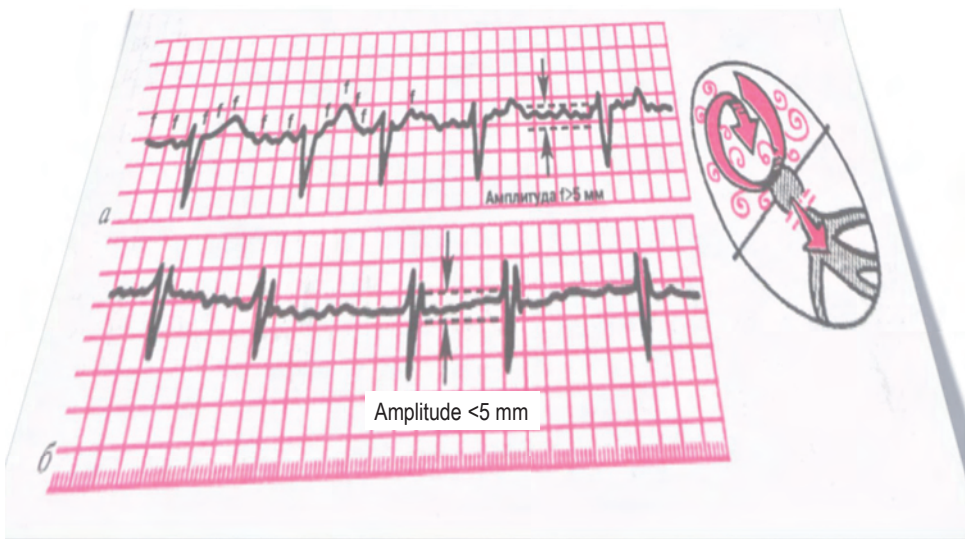
### CLC syndrome

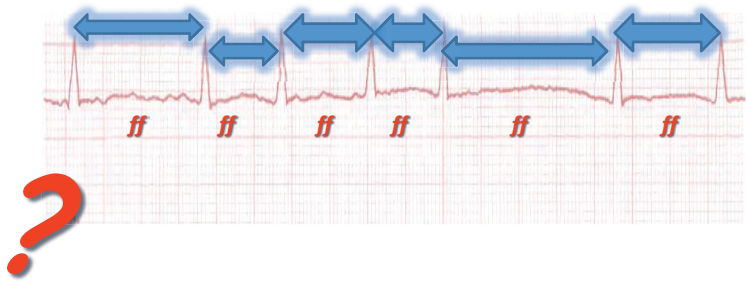






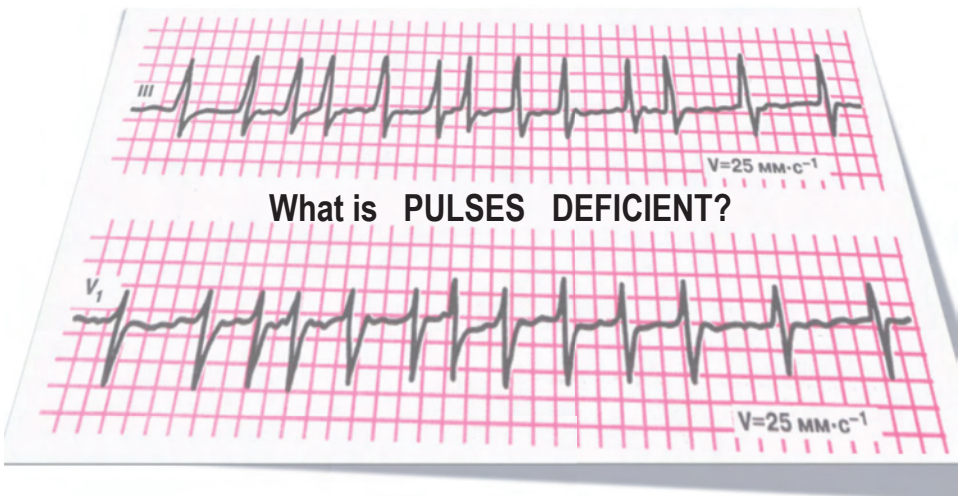
## Atrial fibrillation



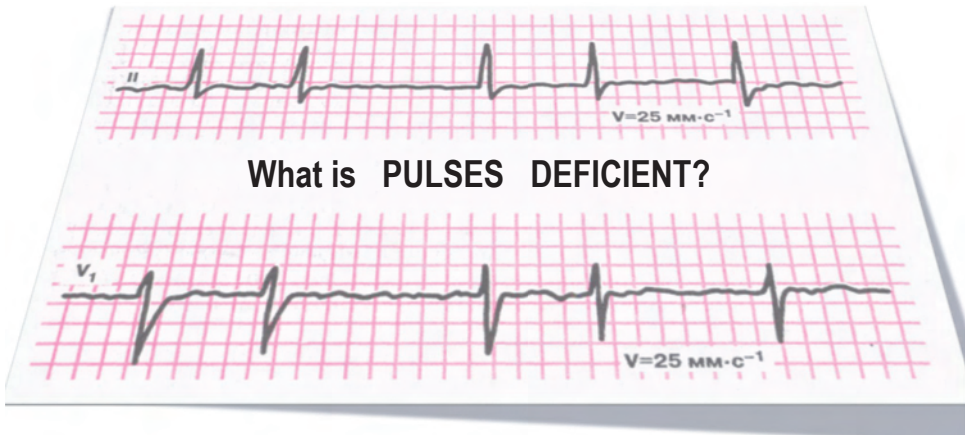


## Atrial FIBRILLATION

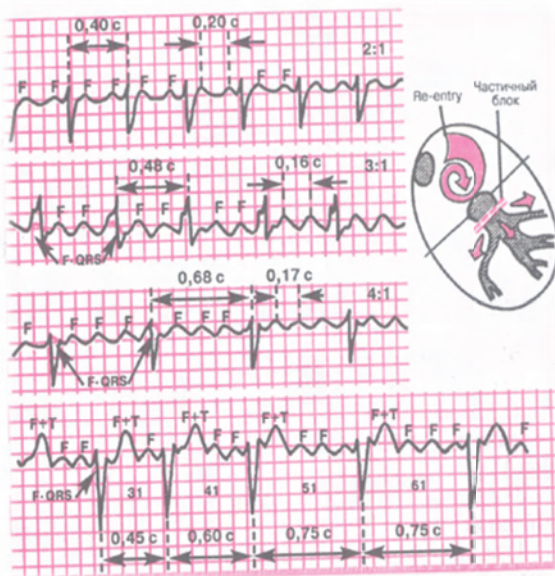
### Atrial FIBRILLATION (tachysystolic form)



## Atrial FIBRILLATION (bradysystolic form)



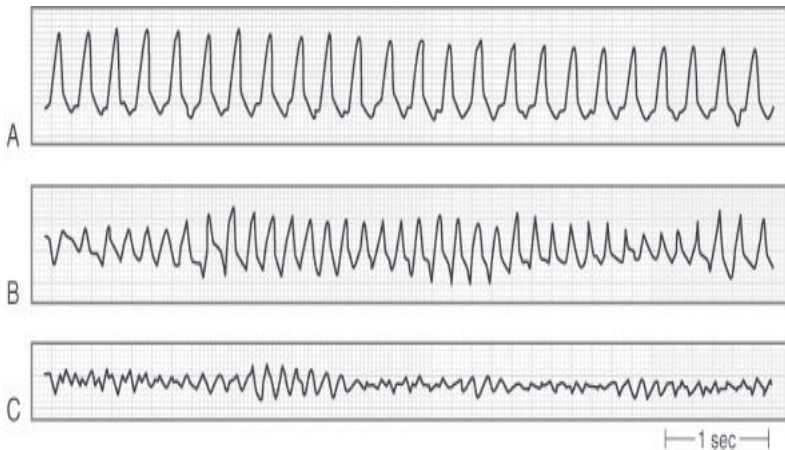
## Atrial Flutter



## Ventricular paroxysmal tachycardia

### ECG signs:

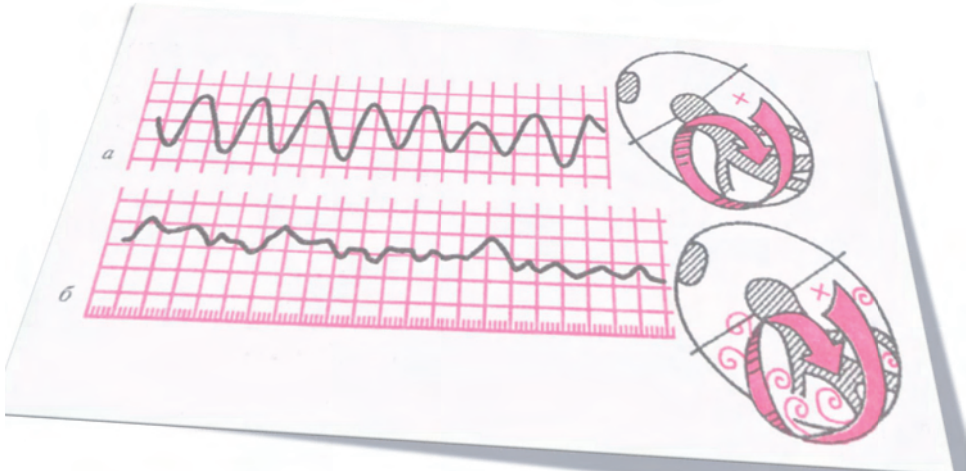
- Suddenly starting and just as suddenly ending attack.
- Deformation and expansion of the QRS complex over 0.12 s.



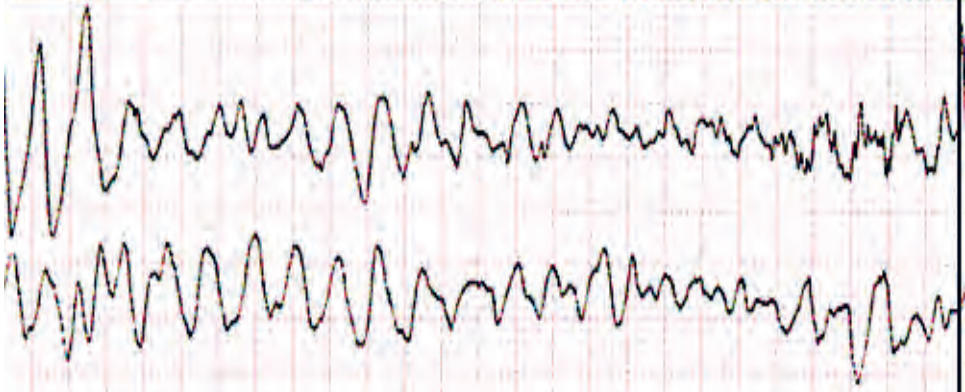
Ventricular tachyarrhythmias. A, Rhythm strip showing monomorphic ventricular tachycardia. B, Example of polymorphic ventricular tachycardia. C, Example of ventricular fibrillation. All tracings are from lead  $V_1$ .

Copyright © 2008 by Saunders, an imprint of Elsevier Inc. All rights reserved.

## Ventricular Flutter (a) & Ventricular Fibrillation (b)



### Ventricular Fibrillation

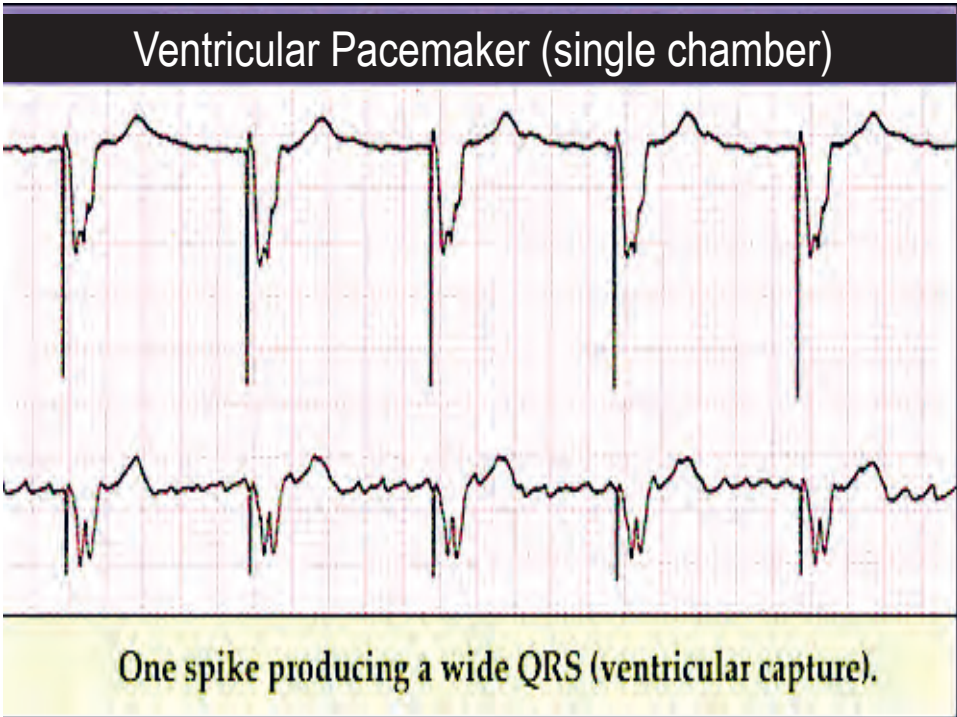


Heart Rate	Rhythm	P Wave	PR interval (in seconds)	QRS (in seconds)
300-600	Extremely irregular	Absent	N/A	Fibrillatory baseline

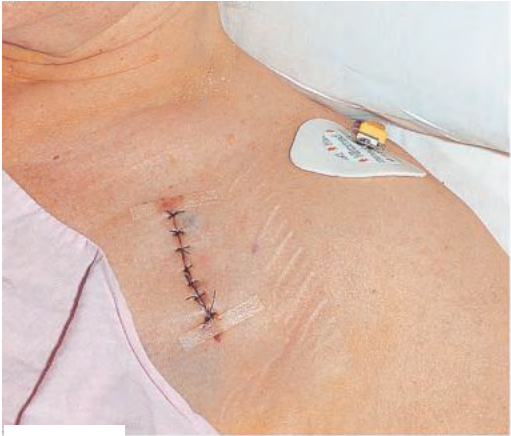


FIGURE 68-1 • Site of implantation of a permanent pacemaker or automatic implantable cardioverter-defibrillator. The pacemaker is usually implanted in the left pectoral region, but it may be placed elsewhere if necessary.

(From Forbes CD, Jackson WF: Color Atlas and Text of Clinical Medicine, 3rd ed. London, Mosby, 2003.)



## HEART CONDUCTION DYSFUNCTION

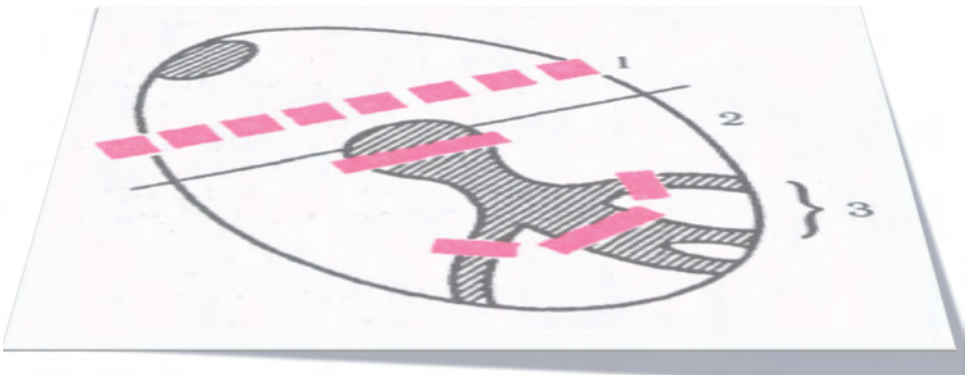
## Sinus Arrest

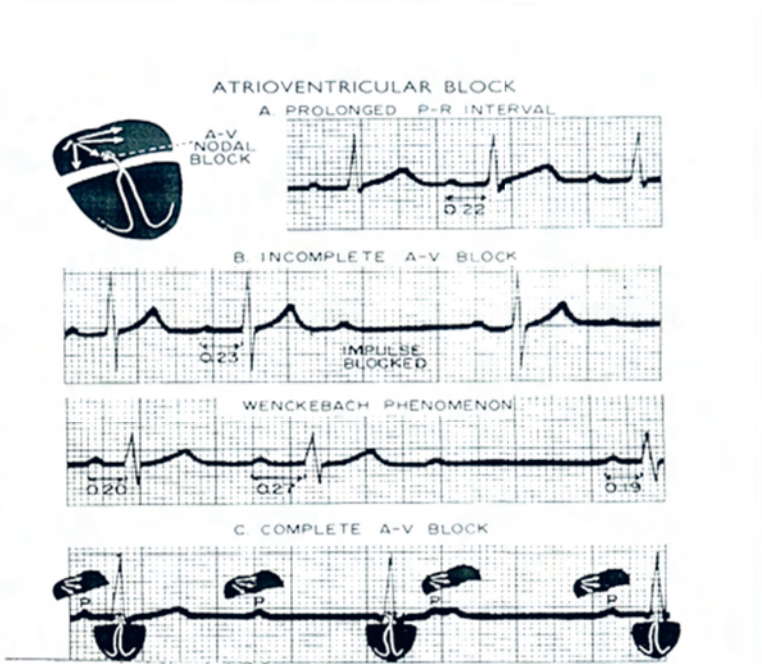


Please note: trace and grid have been reduced in size

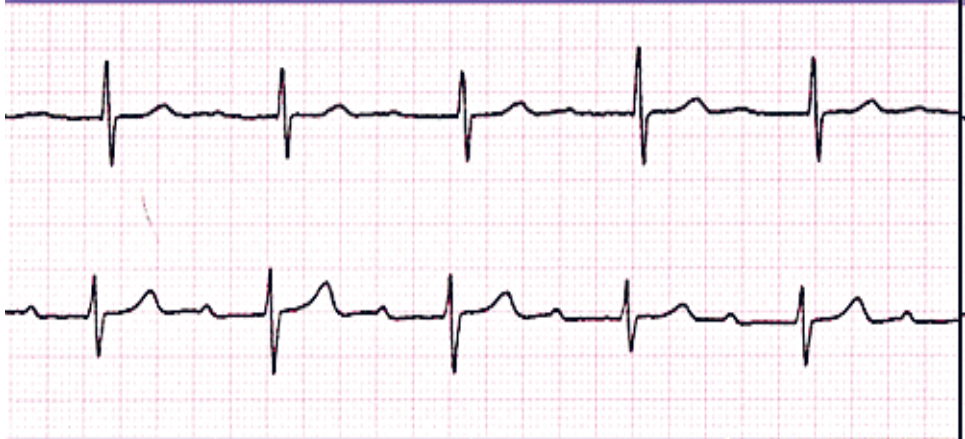
Heart Rate	Rhythm	P Wave	PR interval (in seconds)	QRS (in seconds)
N/A	Irregular	Before each QRS identical. New rhythm begins after a pause. The P to P interval is disturbed.	.12 to .20	<.12

## AV Blocks'





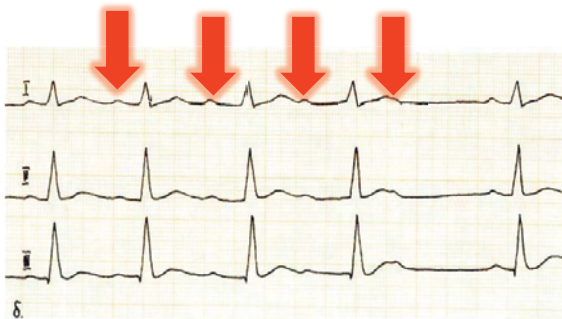
## First Degree AV Block



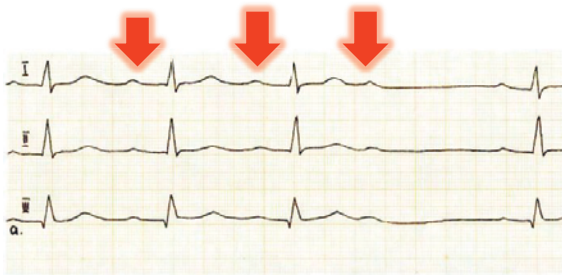
P Wave	PR Interval (in seconds)	QRS (in seconds)	Characteristics
Before each QRS, identical	>.20	>.12	Regular rhythm



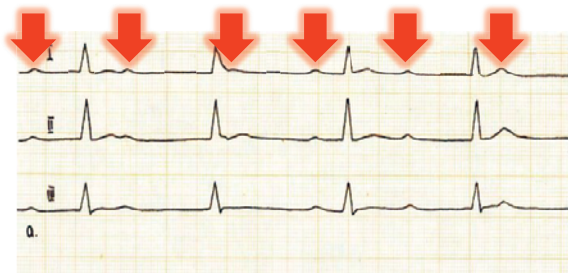
### II degree AV BLOCK-1

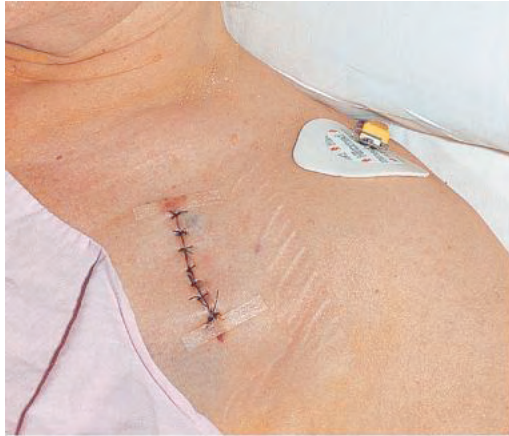

### II degree AV BLOCK-2



### III degree AV BLOCK

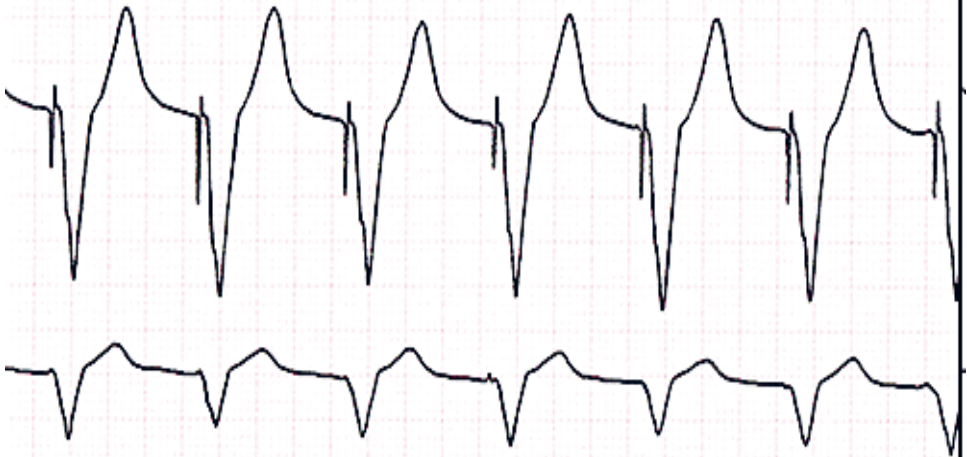



• Site of implantation of a permanent pacemaker or automatic implantable cardioverter-defibrillator. The pacemaker is usually implanted in the left pectoral region, but it may be placed elsewhere if necessary.

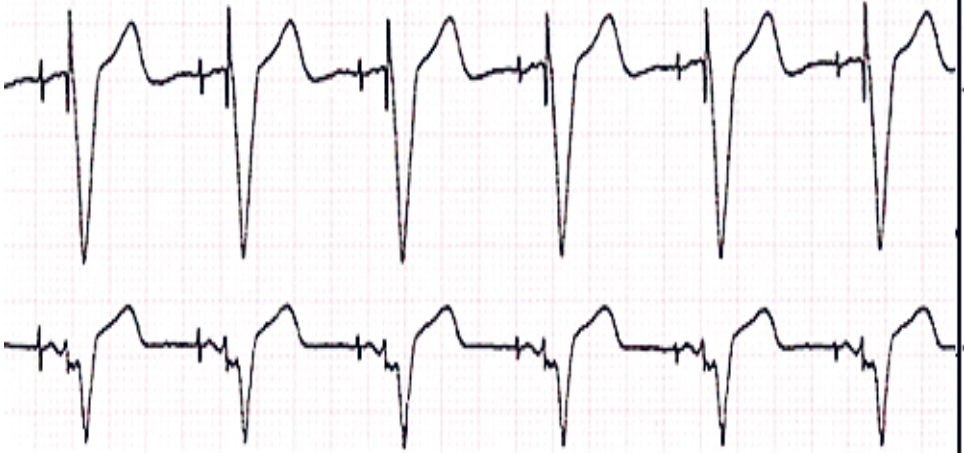(From Forbes CD, Jackson WF: Color Atlas and Text of Clinical Medicine, 3rd ed. London, Mosby, 2003.)

## Electric Pacemaker Spikes



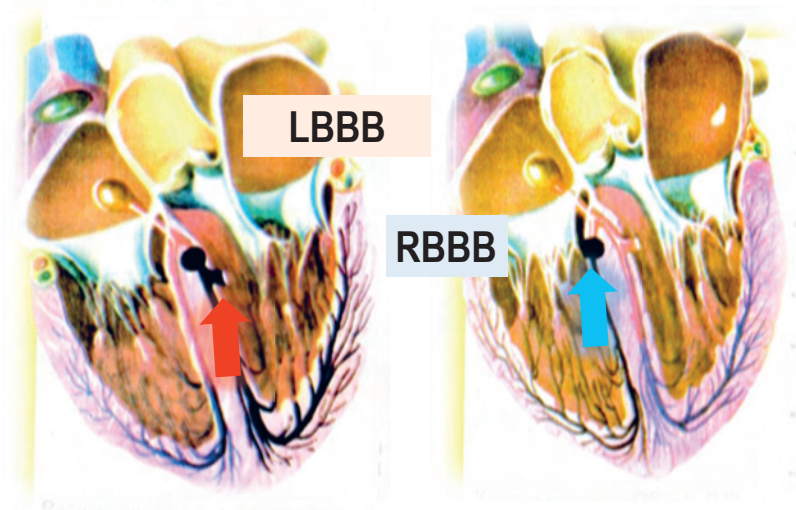
**Artificially induces electronic stimulus that paces the patient's rhythm causing a blip or spike on the ECG waveform**

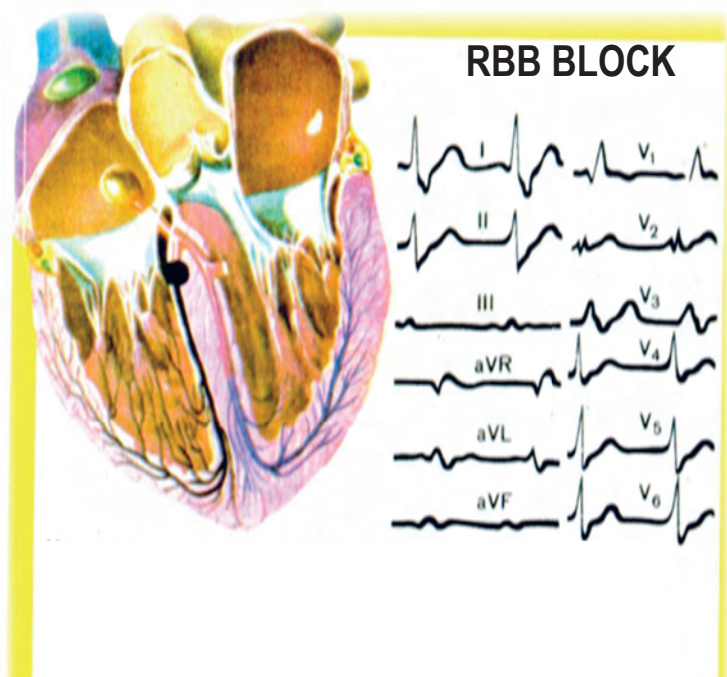
## AV Sequential Pacemaker (dual chamber)



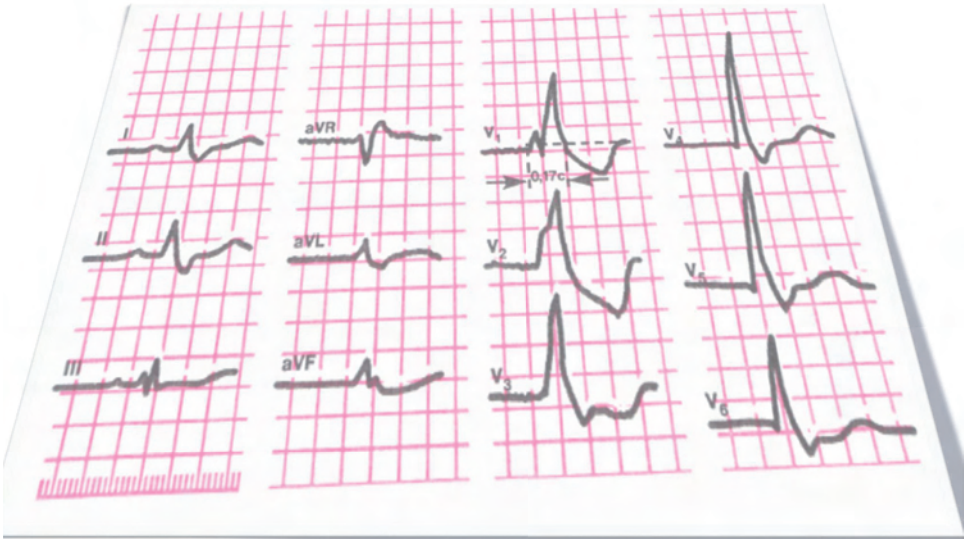One spike followed by an abnormal P (atrial capture) followed by a  
Second spike producing a wide QRS (ventricular capture).

## Heart conduction dysfunction

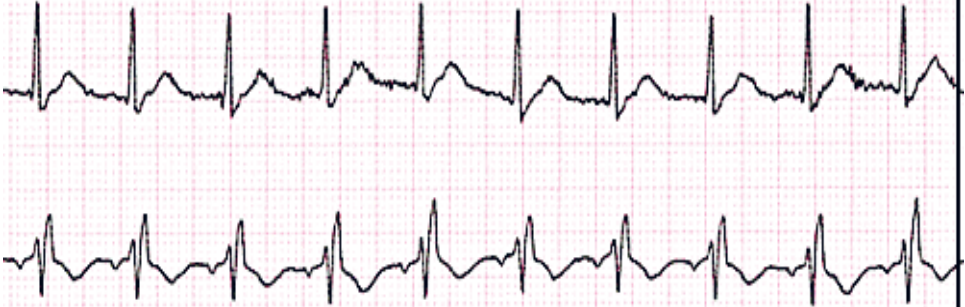



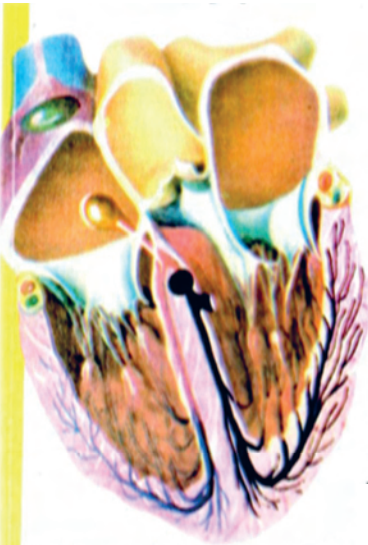**RBB BLOCK – full type**



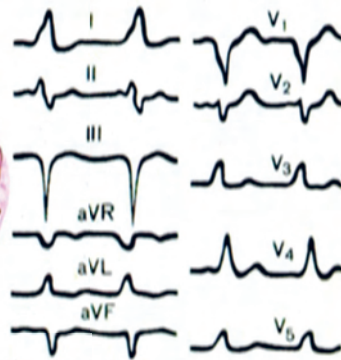## Right Bundle Branch Block



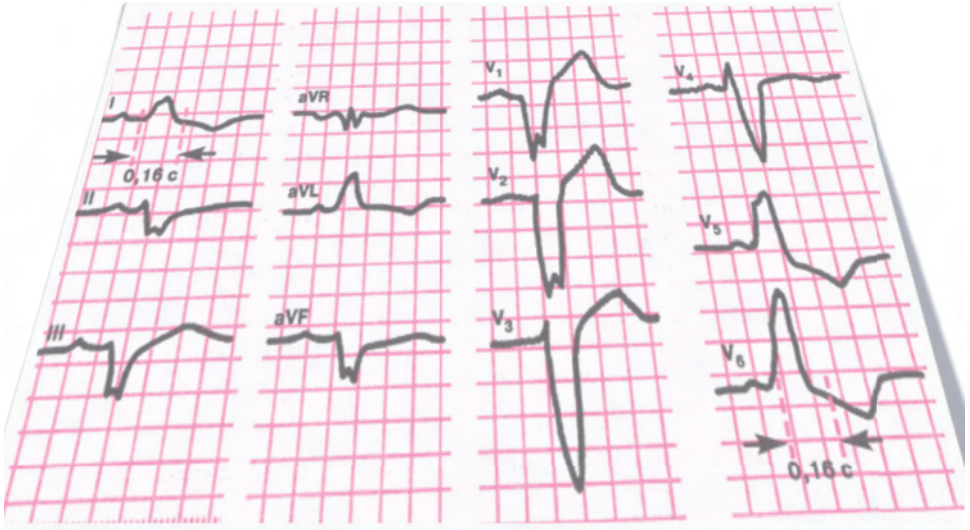
P Wave	PR Interval (in seconds)	QRS (in seconds)	Characteristics
Before each QRS, identical	.12 to .20	>.12	RSR' in V1



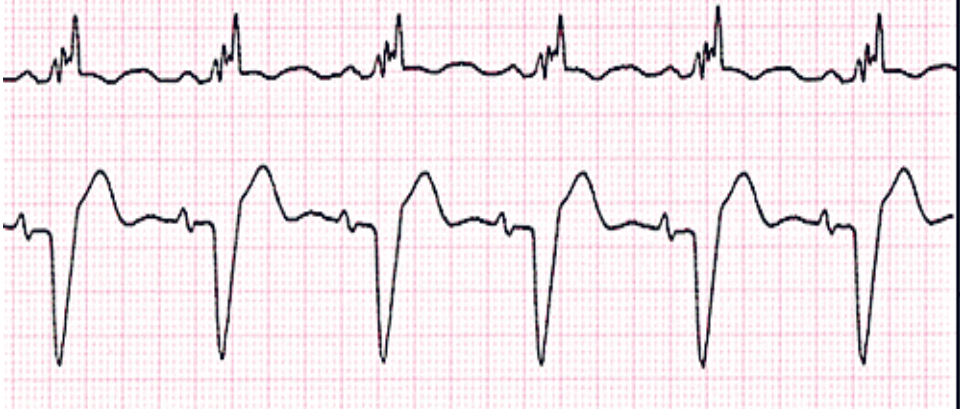## LBB BLOCK – full type



## LBB BLOCK – full type

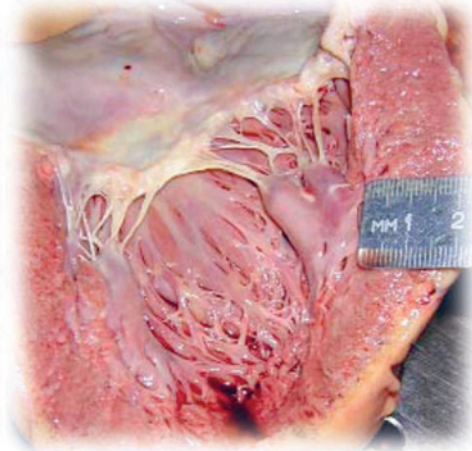
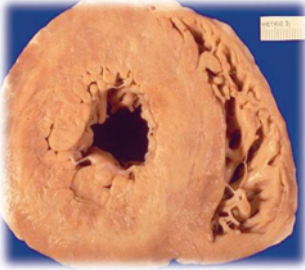

## Left Bundle Branch Block

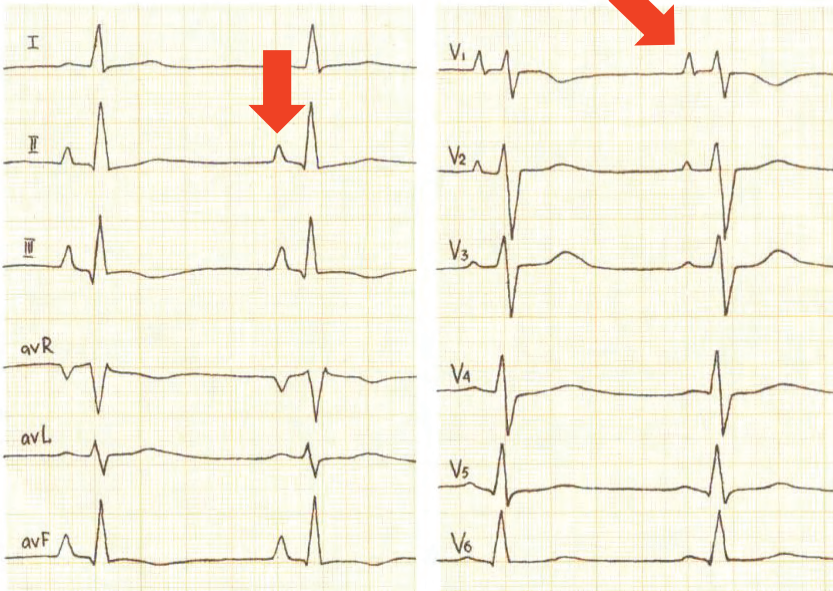


P Wave	PR Interval (in seconds)	QRS (in seconds)	Characteristics
Before each QRS, identical	.12 to .20	≥.12	RR' in V5

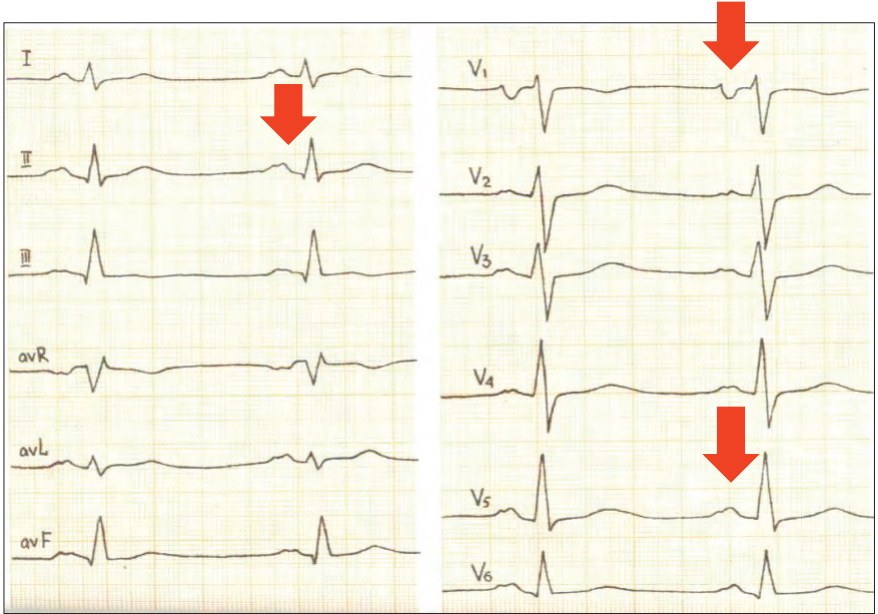
## Heart hypertrophy (LVH)



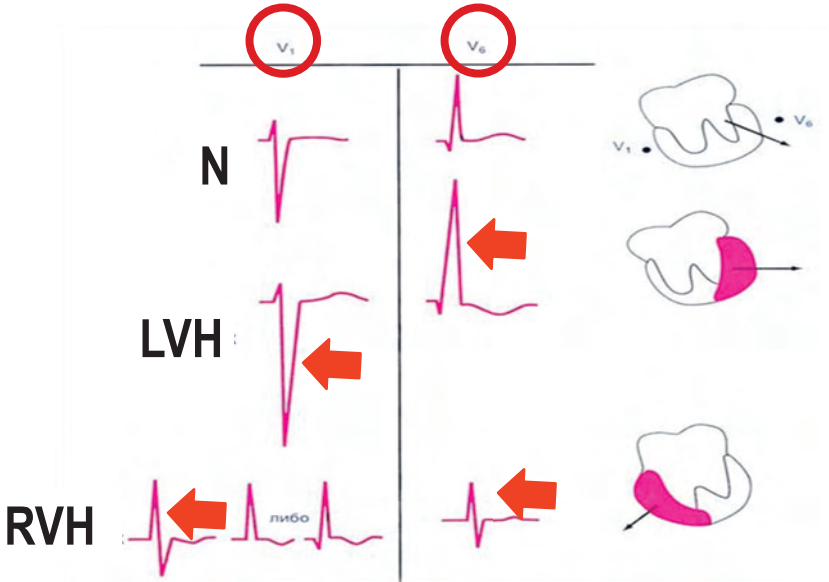
## Hypertrophy of the right atrium



### Hypertrophy of the left atrium



### Hypertrophy of the ventricles

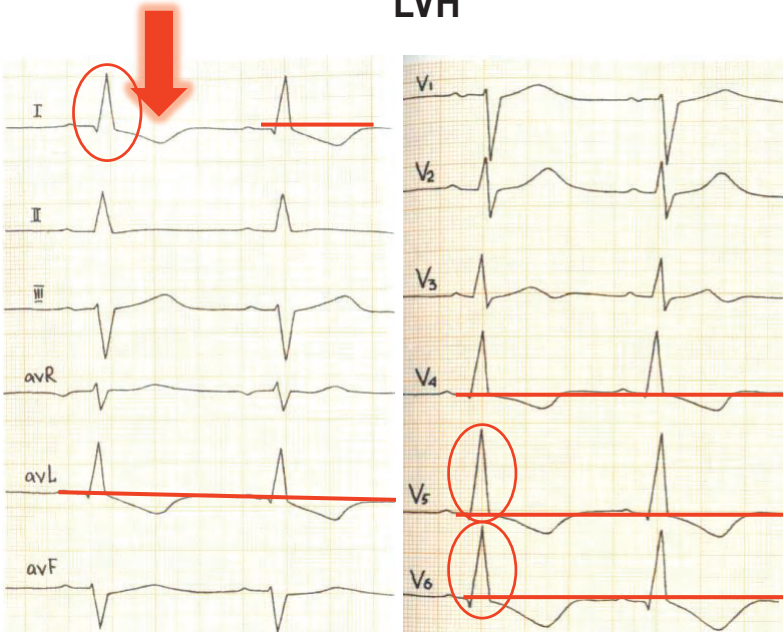




## Selected criteria for left ventricular hypertrophy

Gubner	$RI + SIII \geq 2.5 \text{ mV}$
Sokolow–Lyon	$SV1 + RV5/V6 > 3.5 \text{ mV}$
Cornell voltage	$RaVL + SV3 > 2.8 \text{ mV (men)}$ $RaVL + SV3 > 2.0 \text{ mV (women)}$

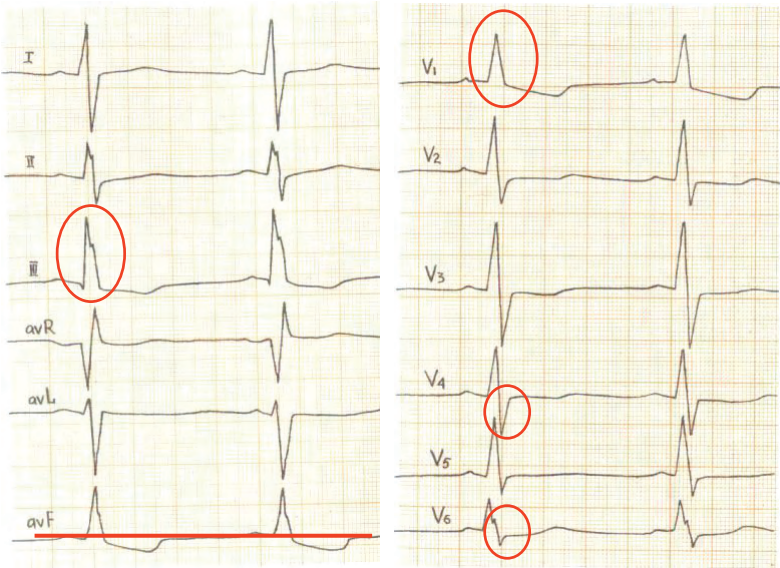
### LVH

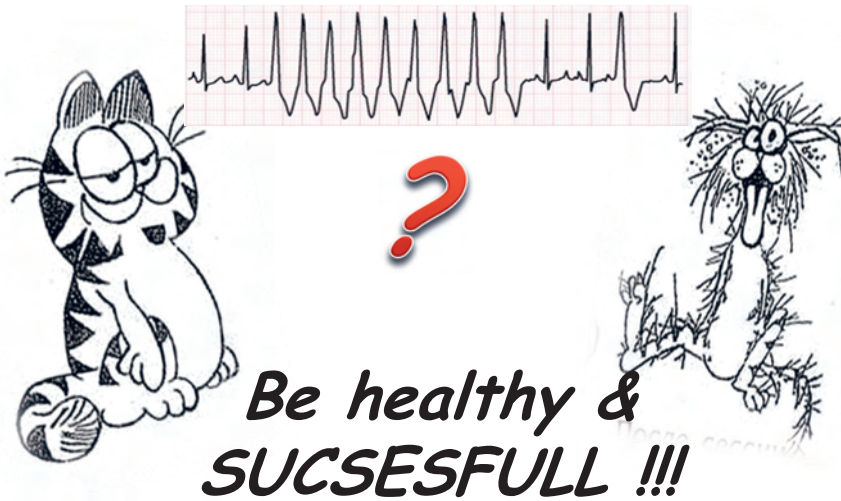

## Selected criteria for right ventricular hypertrophy

Lewis	$(RI + SIII) - (SI + RIII) < 15\text{mm}$
Sokolow–Lyon index for right ventricular hypertrophy (SL-RVH)	$[R \text{ in } V_1] + [S \text{ in } V_5 \text{ or } V_6] > 10.5\text{mm}$
Butler–Leggett	$[\text{max } R \text{ or } R' \text{ in } V_1 \text{ or } V_2] + [\text{max } S \text{ in } I \text{ or } V_6] - [S \text{ in } V_1] > 6 \text{ mm}$

### RVH





## REFERENCES

Kovalyova O.N., Ashcheulova T.V. Propedeutics to Internal Medicine. Part 1. – Vinnytsya: NOVA KNYHA, 2017. – 424 p.

Kovalyova O.N., Asheulova T.V. Clinical electrocardiography. Basic principles. – Kharkov: KSMU. – 2001. -68p.

Bickley, Lynn S.; Szilagy, Peter G. Bates' Guide to Physical Examination and History Taking, 10th Edition. – 934 p. Copyright ©2009 Lippincott Williams & Wilkins

Bayes de Luna A. Clinical Electrocardiography: Normal and abnormal ECG patterns. A Textbook. New York: Futura, 2007. 181-p.

The Point online resources, <http://thepoint.lww.com>

LECTURE # 9

**SYMPTOMS AND SIGNS  
OF DIGESTIVE DISEASES**

## THE PLAN

- Epidemiology
- Risk factors
- General algorithm of assessment
- The general list of Symptoms, Signs & Syndromes
- Review of Symptoms and signs of Digestive diseases
- Abdominal Pain
- Visceral Pain
- Somatoparietal Pain
- Referred Pain
- "RED FLAG" - ALARM SIGNS
- Acute Bleeding
- Chronic Bleeding
- Signs of helminthes invasion
- General survey
- Physical Examination
- Nonabdominal Examination
- Inspection
- Auscultation
- Percussion
- Evaluation of the patient with ascites
- Oriental Superficial palpation
- Deep Sliding Topographic Methodical palpation  
By V. Obratsov and N. Strazhesko
- References

## EPIDEMIOLOGY

- Gastrointestinal (GI) and liver diseases generate 50 million visits to physicians, hospitals, and emergency departments annually in the United States
- Non-food-borne gastroenteritis and food-borne illnesses are the most frequent diagnoses
- The estimated direct cost for these diseases is approximately \$90 billion per year, with a range of above \$10 billion for gastroesophageal reflux disease (GERD) to about \$7 billion for gallbladder disease and about \$5 to \$6 billion for colorectal cancer
- GI diseases account for approximately 10% of all deaths annually, with colorectal cancer being the most common cause of mortality

### Risk factors

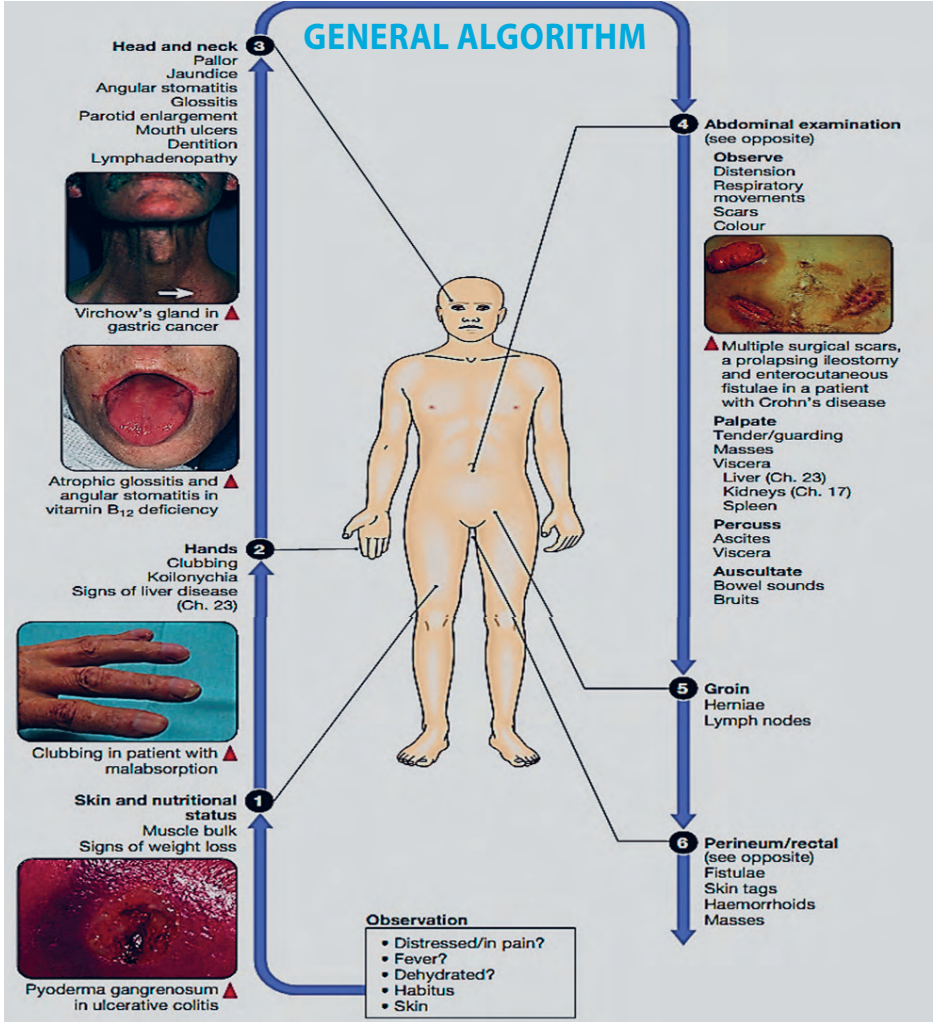


### Risk factors



### Risk factors





## SYMPTOMS, SIGNS & SYNDROMES

- |  |  |
|--|--|
| <ul style="list-style-type: none"> <li>● Abdominal Pain</li> <li>● GI Bleeding</li> <li>● Diarrhea</li> <li>● Steatorrhea</li> <li>● Constipation</li> <li>● Nausea and Vomiting</li> <li>● Dysphagia</li> </ul> | <ul style="list-style-type: none"> <li>● Odynophagia</li> <li>● GERD</li> <li>● Anorexia</li> <li>● Weight Loss</li> <li>● Jaundice</li> <li>● Abdomen enlargement</li> <li>● Ascitis</li> </ul> |
|--|--|



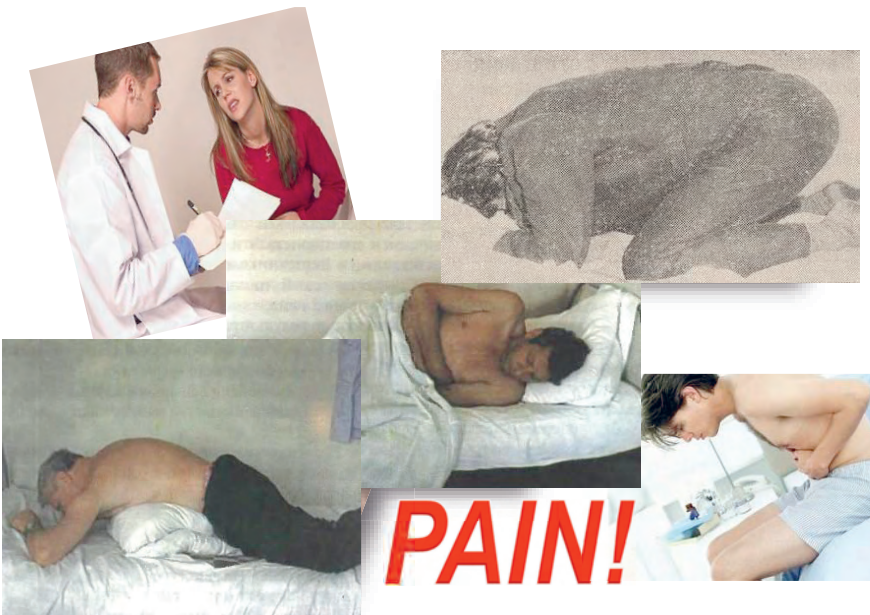## Review of Specific Symptoms

The most common symptoms of abdominal disease are as follows:

- Pain
- Nausea and vomiting
- Change in bowel movements
- Rectal bleeding
- Jaundice
- Abdominal distention
- Mass
- Pruritus (itching)

## Gastrointestinal Disorders

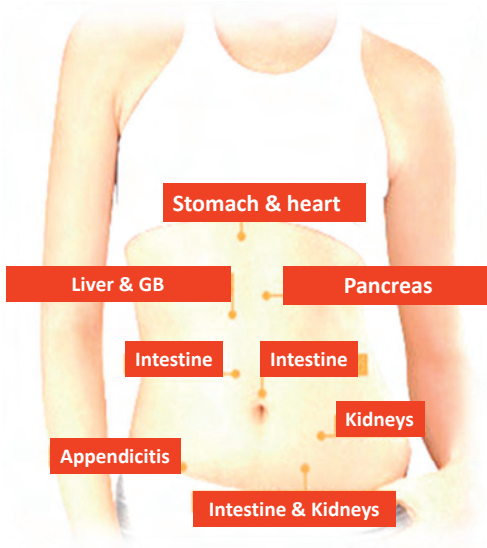
- ▶ Abdominal pain, acute and chronic
- ▶ Indigestion, nausea, vomiting including blood, loss of appetite, early satiety
- ▶ Dysphagia and/or odynophagia
- ▶ Change in bowel function
- ▶ Diarrhea, constipation
- ▶ Jaundice



# Symptoms and signs of Digestive diseases



## Typical localization of pain



## Abdominal Pain



- The classic five questions are still applicable in current times:
- **Where is the pain located?**
- **When did it start?**
- **Does it go anywhere?**
- **What does it feel like?**
- **Does anything make it better or worse?**
- Appropriate questioning and good listening will give accurate clues to the underlying pathology.

### THE GASTROINTESTINAL TRACT

Ask patients to *describe the abdominal pain in their own words*, especially timing of the pain (acute or chronic); then ask them to *point to the pain*.

Pursue important details:

“Where does the pain start?”

“Does it radiate or travel?”

“What is the pain like?”

“How severe is it?”

“How about on a scale of 1 to 10?”

“What makes it better or worse?”

Elicit any *symptoms associated with the pain*, such as fever or chills; ask their sequence.

## Abdominal Pain

The description of the pain will often aid in determining its etiology.

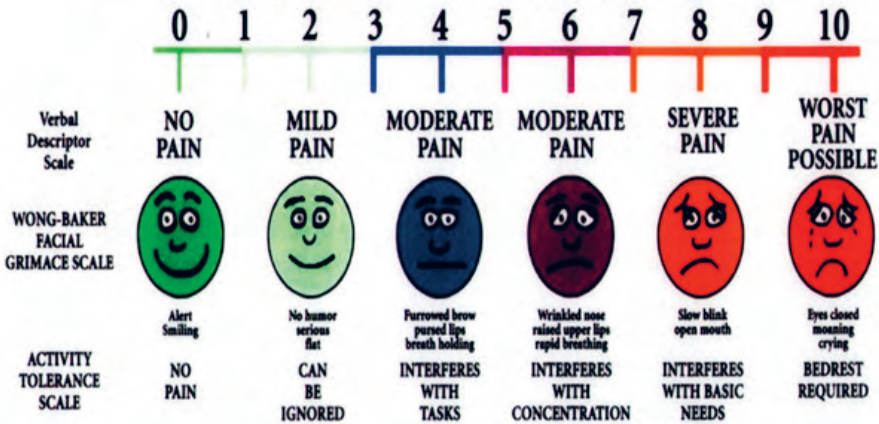
- **Pain can be either:**
  - acute or chronic ;
  - intermittent or constant;
  - crampy, sharp, or stabbing;
  - intense;
  - localized or radiating;
  - and burning, gnawing, dull, or achy.

## Abdominal Pain

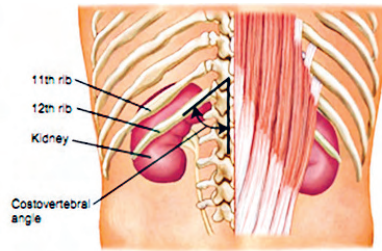
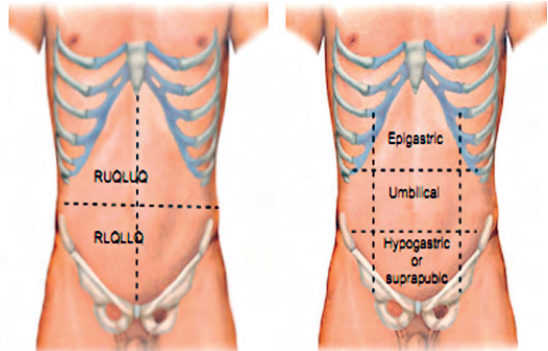
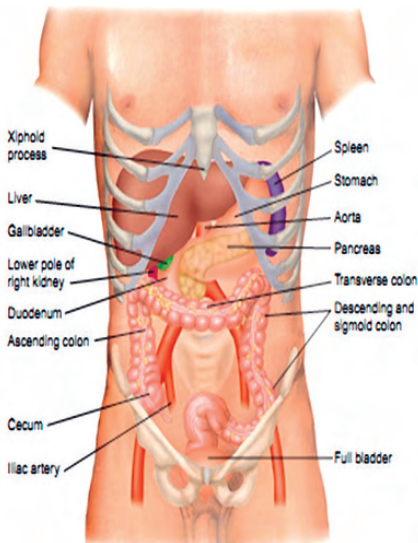
- **Patients should be queried about**
  - the duration,
  - character,
  - and intensity of the pain;
  - rapidity of onset;
  - progression of symptoms;
  - location;
  - exacerbating and alleviating factors;
  - coexisting symptoms;
  - past history and previous episodes of any pain;
  - social habits;
  - and family history of diseases and symptoms.

# UNIVERSAL PAIN ASSESSMENT TOOL

This pain assessment tool is intended to help patient care providers assess pain according to individual patient needs. Explain and use 0-10 Scale for patient self-assessment. Use the faces or behavioral observations to interpret expressed pain when patient cannot communicate his/her pain intensity.



## TOPOGRAPHY OF ORGANS, ABDOMINAL EXAMINATION AREAS



POSTERIOR VIEW

## Location of Pain in Abdominal Disease

Area of Pain	Affected Organ	Clinical Example
Substernal	Esophagus	Esophagitis
Shoulder	Diaphragm	Subphrenic abscess
Epigastric	Stomach Duodenum Gallbladder Liver Bile ducts Pancreas	Peptic gastric ulcer Peptic duodenal ulcer Cholecystitis Hepatitis Cholangitis Pancreatitis
Right scapula	Biliary tract	Biliary colic
Midback	Aorta Pancreas	Aortic dissection Pancreatitis
Periumbilical	Small intestine	Obstruction
Hypogastrium	Colon	Ulcerative colitis Diverticulitis
Sacrum	Rectum	Proctitis Perirectal abscess

## Visceral Pain

- **Visceral pain is often poorly localized and loosely corresponds to the spinal segment that innervates the involved viscus**
- Examples include peptic ulcer disease, in which pain is localized to the epigastrium, and early appendicitis, in which pain is localized around the periumbilical region

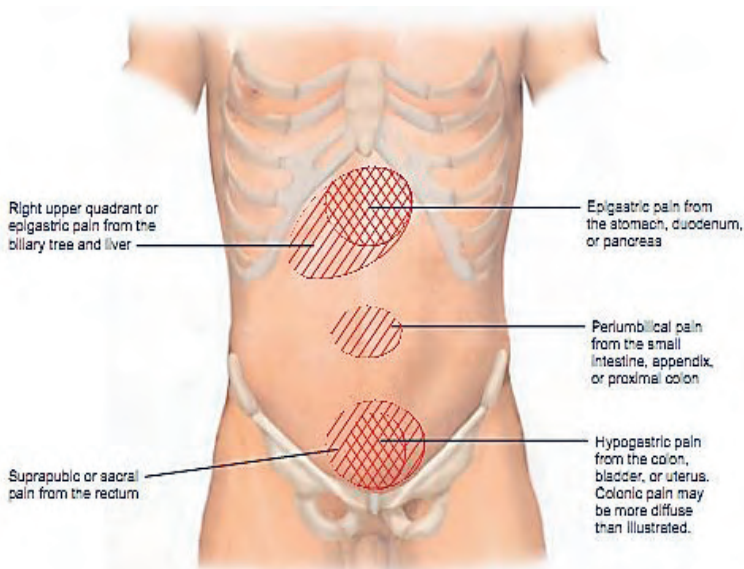
**Visceral pain**—occurs when hollow abdominal organs such as the intestine or biliary tree contract unusually forcefully or are distended or stretched.

Visceral pain in the right upper quadrant (RUQ) from liver distention against its capsule in alcoholic hepatitis

- May be difficult to localize
- Varies in quality; may be gnawing, burning, cramping, or aching
- When severe, may be associated with sweating, pallor, nausea, vomiting, restlessness.

"Pain is the greatest of all evils."

Epicurus



TYPES OF VISCERAL PAIN

## Somatoparietal Pain

- Somatoparietal pain arises from noxious stimulation of the parietal peritoneum
- **This type of pain is more localized and intense and corresponds to the dermatomal distribution that innervates the injured portion of the peritoneum**
- **Somatoparietal pain is aggravated by movement such as coughing or a bumpy car ride**
- Examples of somatoparietal pain include appendicitis, with localized right lower quadrant pain attributable to localized peritonitis, and an abscess, with localized pain over the perforated viscus and inflammatory collection

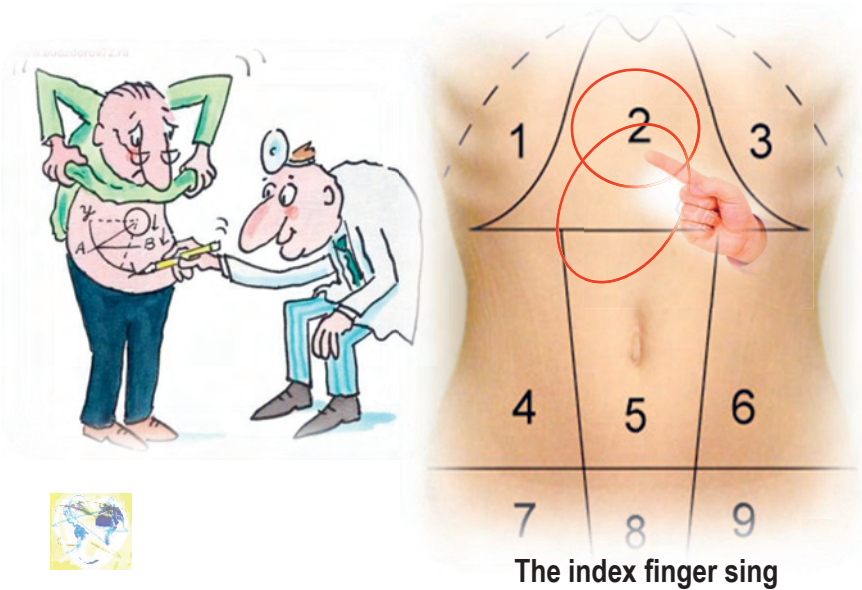
**Parietal pain**—from inflammation of the parietal peritoneum.

- Steady, aching
- Usually more severe
- Usually more precisely localized over the involved structure than visceral pain

Visceral periumbilical pain in *early acute appendicitis* from distention of inflamed appendix gradually changes to parietal pain in the right lower quadrant (RLQ) from inflammation of the adjacent parietal peritoneum.

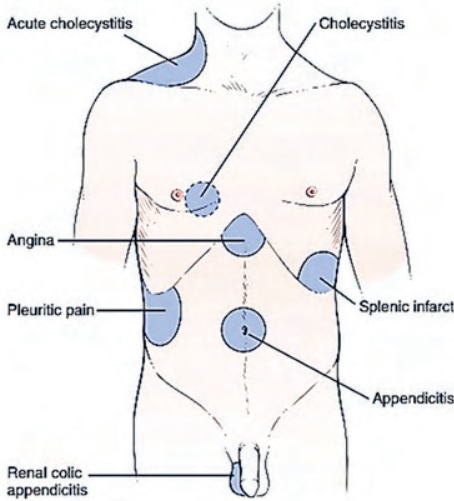


## Topography of pain



## Referred Pain

- Referred pain is perceived by the patient in areas that are **remote from** the diseased organ and occurs as a result of visceral and afferent neurons from **different anatomic regions converging at the same spinal cord segment**, such as a diseased gallbladder causing right subscapular pain
- **!** Nonabdominal diseases, including myocardial infarction and pneumonia, can cause pain that is centered in or radiates to the abdominal area

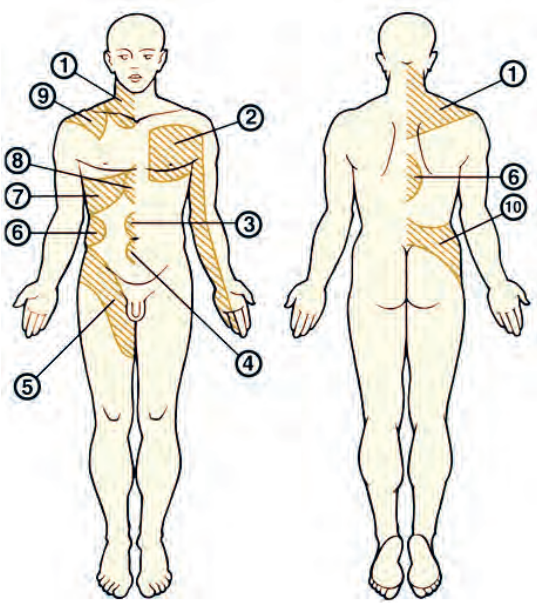


**Referred pain**—occurs in more distant sites innervated at approximately the same spinal levels as the disordered structure.

Pain from the chest, spine, or pelvis may be referred to the abdomen.

Pain of duodenal or pancreatic origin may be referred to the back; pain from the biliary tree—to the right shoulder or right posterior chest.

Pain from pleurisy or acute myocardial infarction may be referred to the upper abdomen.



**ZONE ZAKHARYIN - GED ON THE TRUNK AND EXTREMITIES**

Pain and hypersensitivity may appear in these areas in case of lung and bronchi diseases (1), heart (2), colon (3), the bladder (4), ureter (5), kidney (6), liver (7 and 9), gastric and pancreatic diseases (8), the genitourinary system (10)

## "RED FLAG" - ALARM SINGS !



# NB!

Some patients may have “*alarm symptoms*,” such as difficulty swallowing (*dysphagia*), pain with swallowing (*odynophagia*), recurrent vomiting, evidence of gastrointestinal bleeding, weight loss, anemia, or risk factors for gastric cancer, a palpable mass, or jaundice.

- Fever, HR, BP;
- inspect skin and contour of abdomen;
- bowel sounds—present or absent;
- presence of organomegaly or masses (abscess);
- location of pain;
- rebound or guarding;
- peritoneal signs, e.g., shaking, tenderness

## Abdominal Pain:

### Laboratory tests

- CBC,
- BUN,
- Cr,
- glucose,
- amylase, lipase,
- liver tests (ALT, AST, bilirubin, alkaline phosphatase),
- albumin,
- PT, PTT, U/A,
- stool for pathogens,
- *Helicobacter pylori* antibodies

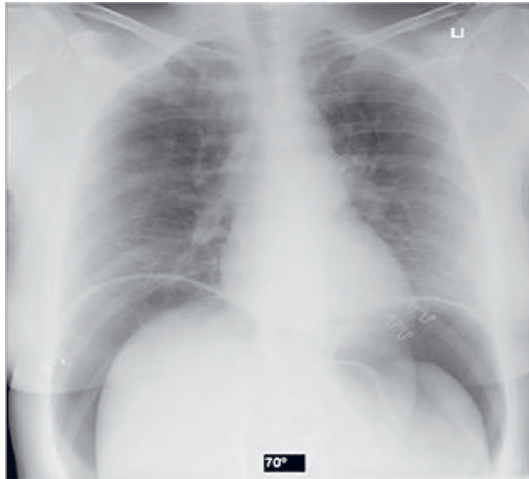
## Abdominal Pain:

### Endoscopy

- EGDs,
- colonoscopy,
- 24-hr pH probe

### Imaging

- CT scan,
- ultrasound,
- angiography

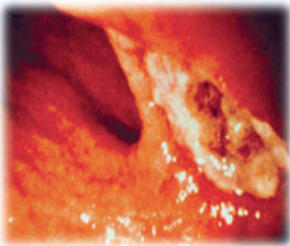
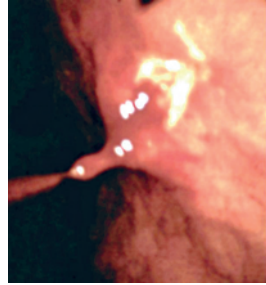


Plain abdominal radiograph in a supine patient with a perforated peptic ulcer. The radiograph shows free air under the diaphragm

A symptom of "sickle"

## GI Bleeding: History (ask the following questions)

- Acute vs. chronic (duration);
- intermittent vs. continuous;
- quantity;
- hematemesis,
- melena, or hematochezia;
- associated pain and location;
- symptoms of anemia, e.g., dyspnea, chest pain, lightheadedness;
- medication use, esp. aspirin/NSAIDs



Ulcer crater in the gastric wall

Actively bleeding ulcer with a visible blood jet

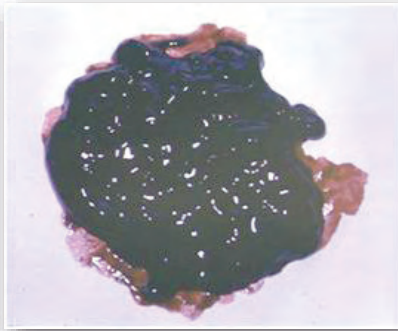
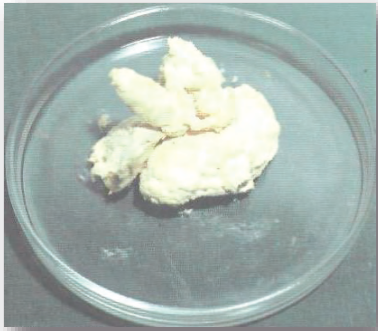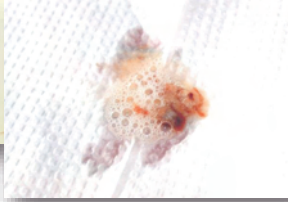
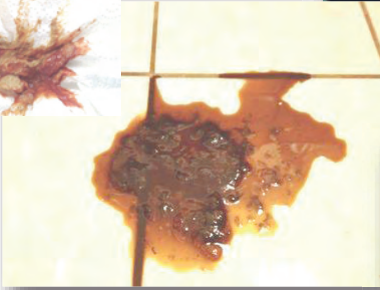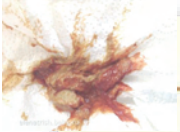
## Acute Bleeding

- **Acute upper GI bleeding, which may be manifested as hematemesis (blood contents), or vomiting like coffee grounds melena (black tarry feces) or lower GI bleeding - hematochezia (red or maroon colored feces) !!!**
- **Acute upper GI bleeding is three times more common than acute lower GI bleeding.**
- **Upper GI bleeding is further subdivided into variceal and nonvariceal bleeding because treatment of these two conditions differs markedly.**
- **The two most common causes of acute lower GI bleeding are diverticulosis and arteriovenous malformations.**
- **Whereas upper endoscopy is universally preferred as the first step in the evaluation of acute upper GI bleeding,**
- **the use of colonoscopy as the first diagnostic test for acute lower GI bleeding is more controversial.**
- **Acute GI bleeding from the small intestine, distal to the duodenum, is rare but occurs in 10% of patients with hematochezia.**

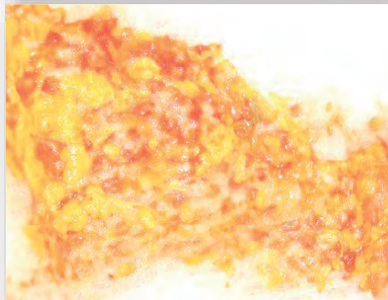
## Chronic Bleeding

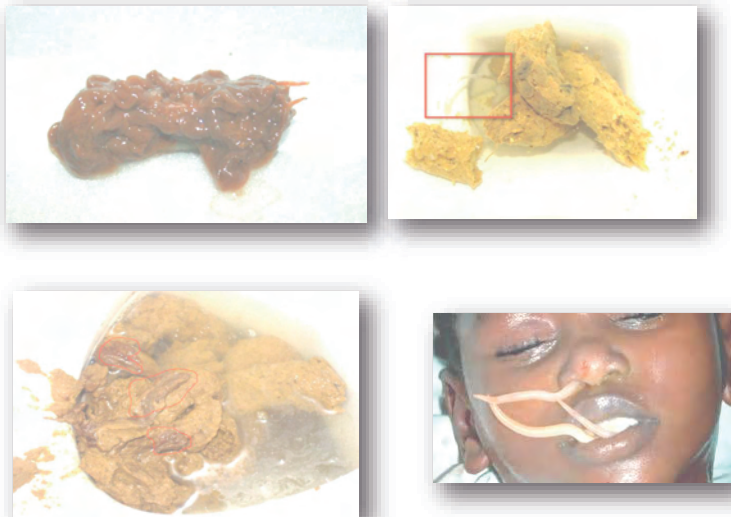- **Chronic GI bleeding is manifested as Hemocult-positive feces or iron deficiency anemia, or both**
- **The most worrisome etiology to exclude is an underlying malignancy of the GI tract, but other diseases can also be accompanied by chronic GI bleeding**
- **Endoscopic evaluation is the initial diagnostic test and will yield a diagnosis 95% of the time**

## Sings of GI Bleeding



## Types of feeses





## Signs of helminthes invasion

### General survey

- ❖ Position of the patient
- ❖ Use the correct terminology for locations on the abdomen
- ❖ Ask patient to point to areas of pain and examine that area last



## Physical Examination

- The physical examination of a patient with abdominal symptoms is as important as the history
- **The position of the patient** should be noted throughout the examination — a patient **loath to move** might have peritonitis (**somatoparietal pain**) because any movement increases irritation of the inflamed peritoneum,
- whereas a patient who has colicky pain (**visceral pain**) cannot get into a comfortable position and **often moves about restlessly while attempting to ease the paroxysms of pain**
- **In a patient with acute symptoms, measurement of vital signs is important to determine hemodynamic stability**
- A patient's weight should be compared with previous measurements

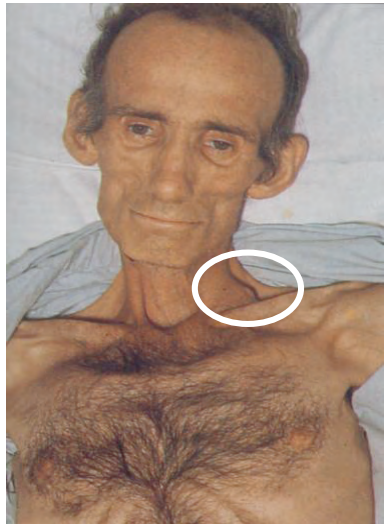
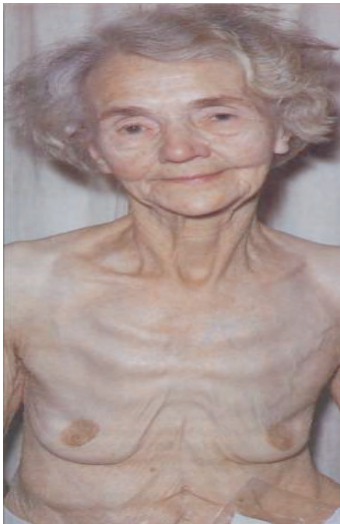
## Nonabdominal Examination

- When examining nonabdominal areas, the focus is on identifying possible clues to underlying or systemic diseases; **for example**, if jaundice, spider telangiectases, or other stigmata of chronic liver disease are present, varices should be suspected in a patient with acute upper GI bleeding
- **Examination of the eyes and skin may give clues to anemia or chronic liver disease**
- **Palpation of lymph nodes in the neck, axilla, and groin should be included as part of a routine examination to look for clues to underlying systemic or localized inflammation or malignancy**
- Examination of the heart and lungs may reveal wheezing, suggestive of esophageal reflux, or an irregular heart rate, S<sub>3</sub> or S<sub>4</sub>, suggestive of underlying cardiovascular disease, which is a **risk factor for intestinal angina or ischemia**

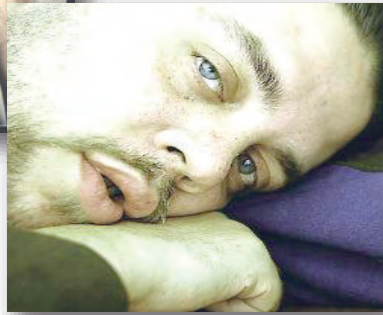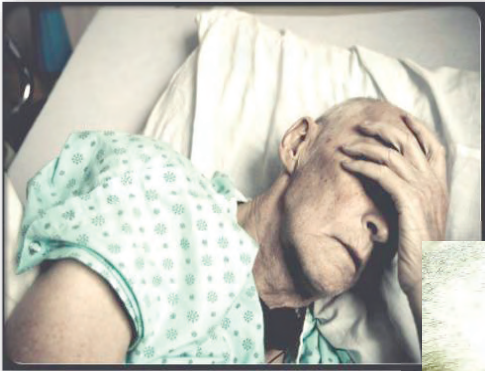## Abdominal Examination

- The abdominal examination consists of the traditional four parts: **inspection, auscultation, percussion, and palpation**
- **Inspection of the abdomen** should include evaluation for scars, diffuse or localized distention, or bulging flanks indicating ascites. In severe necrotizing pancreatitis, Cullen's sign (a faint bluish discoloration around the umbilicus indicative of hemoperitoneum) or Grey Turner's sign (a blue-red or green-brown discoloration of the flanks reflecting tissue catabolism of hemoglobin) may be seen
- **Auscultation takes place before percussion and palpation so that intestinal activity is not disturbed by the examiner's hands**
- The pitch, intensity, and frequency of sounds should be elicited. High-pitched, active bowel sounds might indicate an obstruction, whereas a **quiet abdomen might indicate peritonitis**. If the veracity of the patient's history is in doubt, using **the stethoscope for palpation** during auscultation may clarify the intensity of the abdominal pain because patients may voluntarily guard their muscles during manual palpation but are less likely to be aware of the depth of abdominal muscle compression during the use of a stethoscope
- **The physician should listen over the aorta and other arteries for bruits**, which indicate stenosis or abnormal blood flow, as occurs with an aortic aneurysm
- **A rub over the liver capsule indicates inflammation**, which may be present with a subcapsular hematoma

## General survey

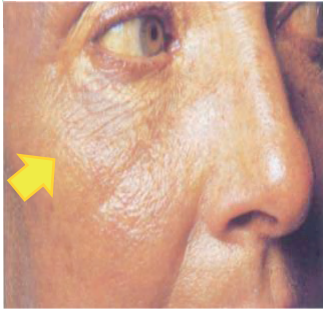


## Consciousness



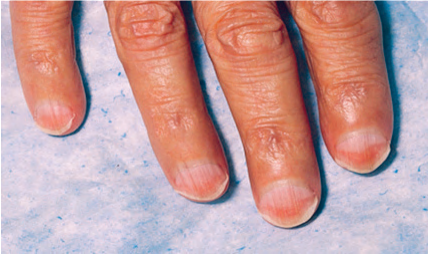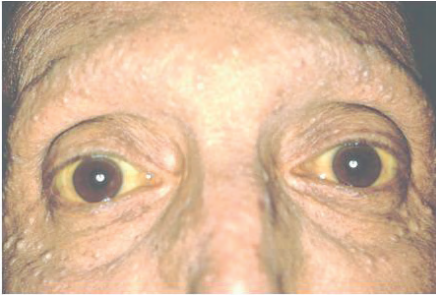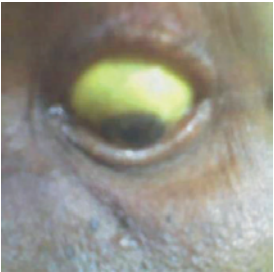## General survey



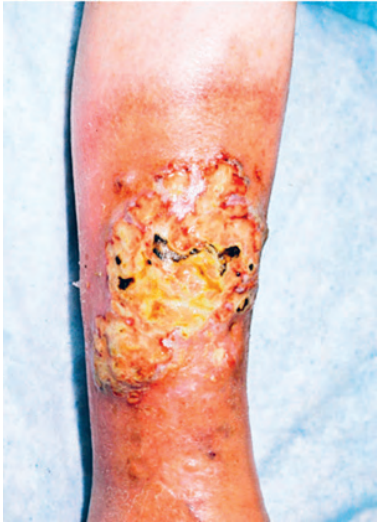

Severe cholestatic jaundice in a patient with primary biliary cirrhosis. The high level of conjugated bilirubin, maintained over a long period, gives a characteristic dark brown-orange pigmentation to the skin and sclerae. Large xanthelasmas and corneal arcus usually develop in patients with primary biliary cirrhosis as a consequence of disordered lipid metabolism. (From Forbes CD, Jackson WF: *Color Atlas and Text of Clinical Medicine*, 3rd ed. London, Mosby, 2003.)

Scleral icterus in a patient with biliary cirrhosis.

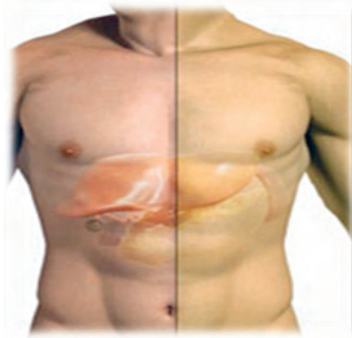
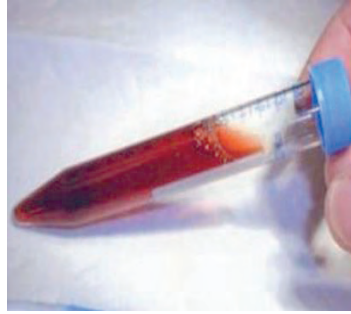
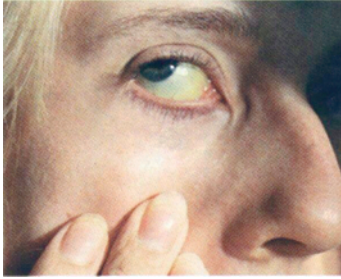
Lindsay's nails.

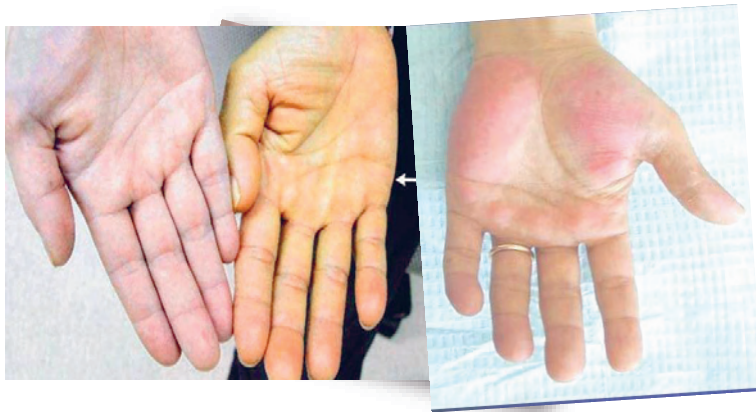

Pyoderma gangrenosum

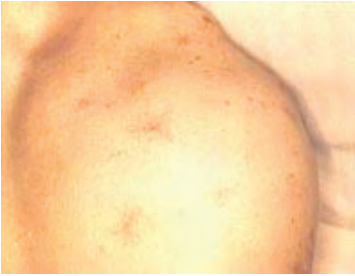The nails are examined for changes in the nail bed, especially an increase in the size of the lunula. The fingers of a patient with cirrhosis showing "half-and-half" nails are shown in Figure 17-7 (see also Fig. 8-8).



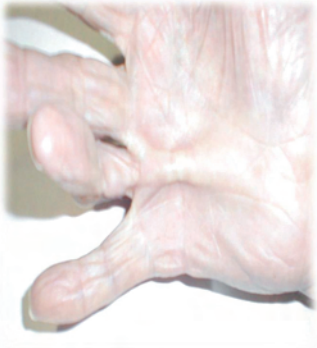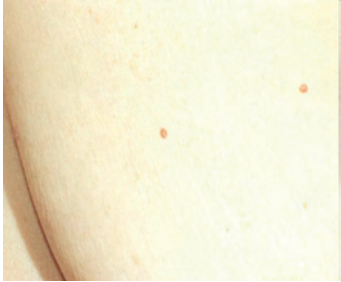
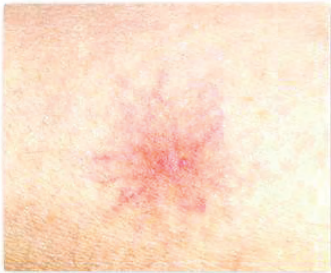
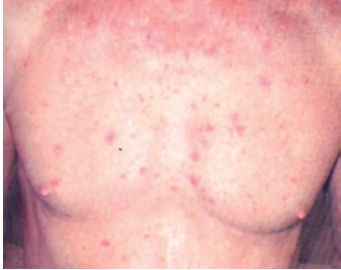Severe cholestatic jaundice in a patient with acute hepatitis



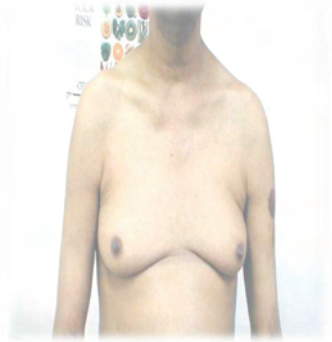Liver palms in liver cirrhosis



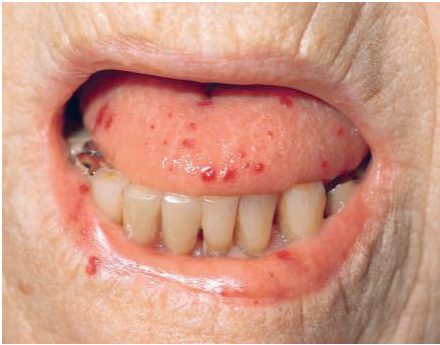Spider telangiectases on the chest of a patient with cirrhosis



Dyupitrens contracture

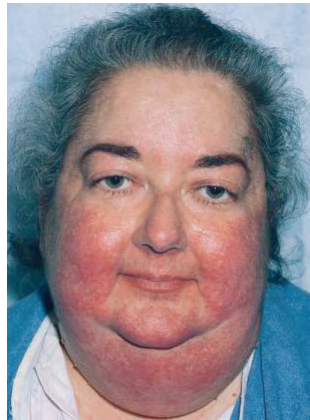


Genycomastya

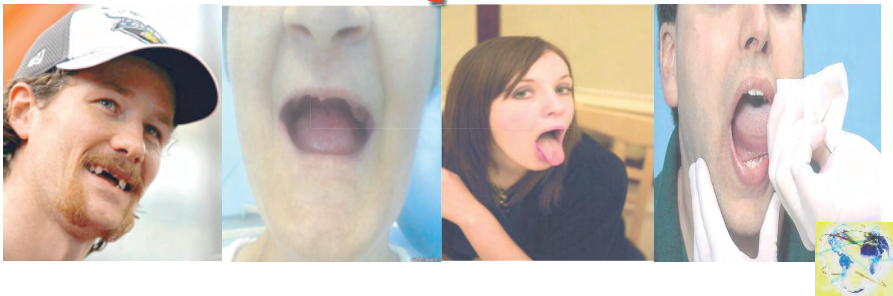
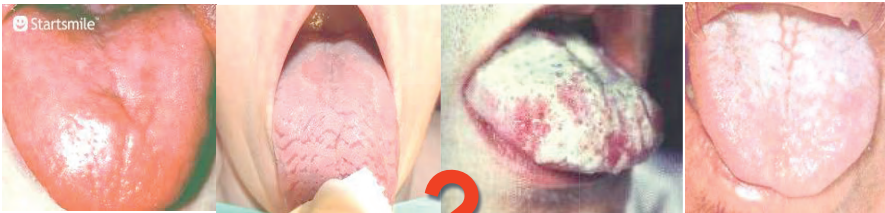

Osler-Weber-Rendu syndrome

Cushing's syndrome.  
Moon face. Buffalo hump.



## Study of the tongue, oral mucosa, teeth



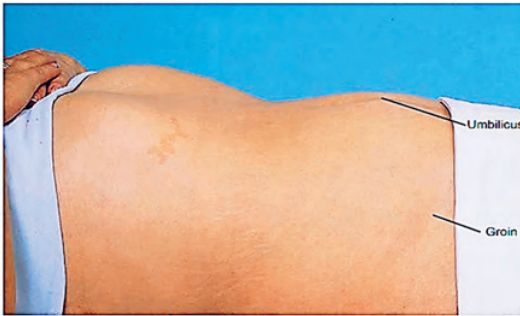
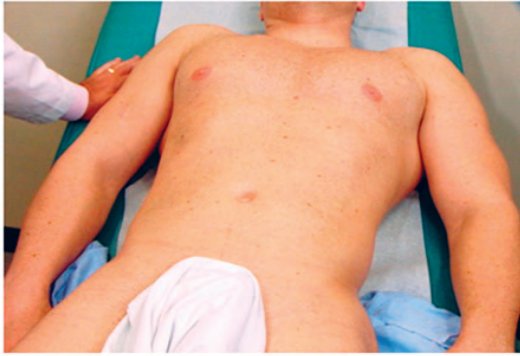# Abdomen

## Techniques of Examination

### Tips for Examining the Abdomen

- ▶ Check if the patient has an empty bladder.
- ▶ Make the patient comfortable in the supine position, with a pillow under the head and perhaps another under the knees. Slide your hand under the low back to see if the patient is relaxed and lying flat on the table.
- ▶ Ask the patient to keep the arms at the sides or folded across the chest. When the arms are above the head, the abdominal wall stretches and tightens, making palpation difficult. Move the gown to below the nipple line, and the drape to the level of the symphysis pubis.
- ▶ Before you begin palpation, ask the patient to point to any areas of pain so that you can examine these areas last.
- ▶ Warm your hands and stethoscope. To warm your hands, rub them together or place them under hot water. You can also palpate through the patient's gown to absorb warmth from the patient's body before exposing the abdomen.
- ▶ Approach the patient calmly and avoid quick, unexpected movements. *Watch the patient's face for any signs of pain or discomfort.* Avoid having long fingernails when examining the patient.
- ▶ Distract the patient, if necessary, with conversation or questions. If the patient is frightened or ticklish, begin palpation with the patient's hand under yours. After a few moments, slip your hand underneath to palpate directly.



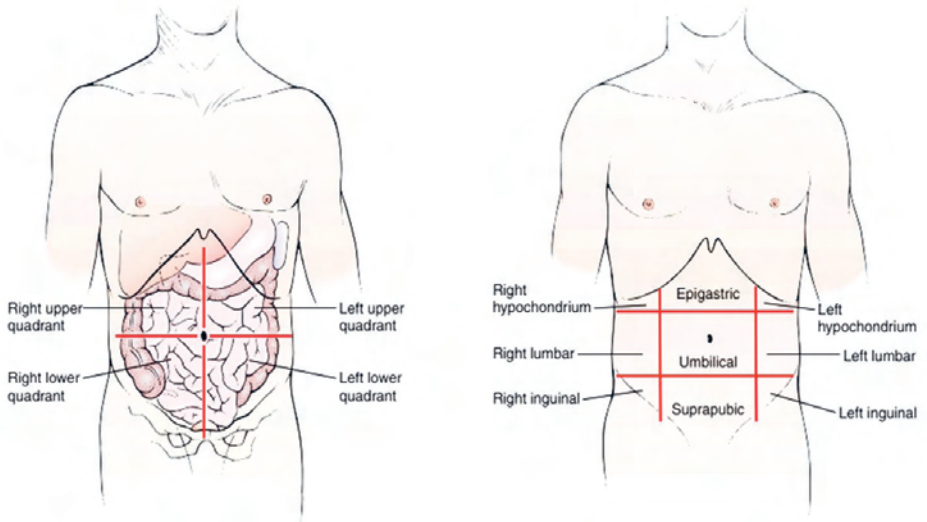


Inspect the surface, contours, and movements of the abdomen, including the following:

## THE ABDOMEN

— Inspect the abdomen, including:

- Skin
  - Scars, striae, veins, ecchymoses (in intra- or retroperitoneal hemorrhages)
- Umbilicus
  - Hernia, inflammation
- Contours for shape, symmetry, enlarged organs or masses
  - Bulging flanks of ascites, suprapubic bulge, large liver or spleen, tumors
- Any peristaltic waves
  - Increase in GI obstruction
- Any pulsations
  - Increased in aortic aneurysm

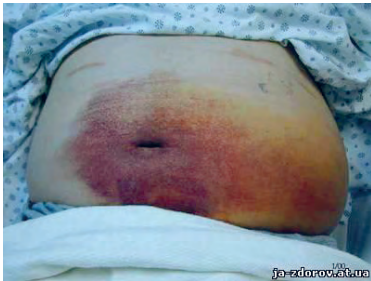
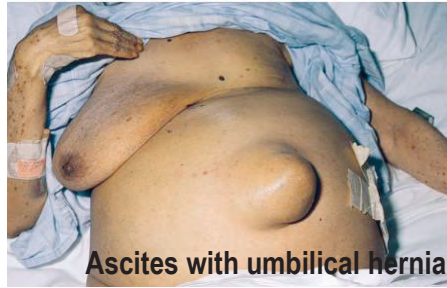
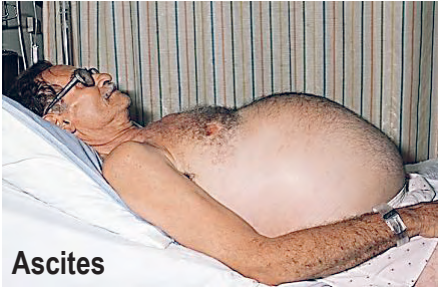The physical examination of the abdomen includes the following:

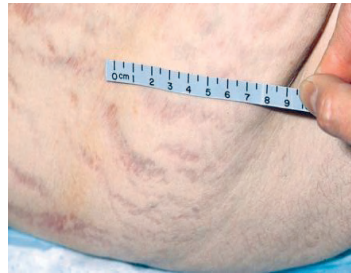
- ❖ Inspection
- ❖ Auscultation
- ❖ Percussion
- ❖ Palpation
- ❖ Rectal examination
- ❖ Special techniques

## Inspection

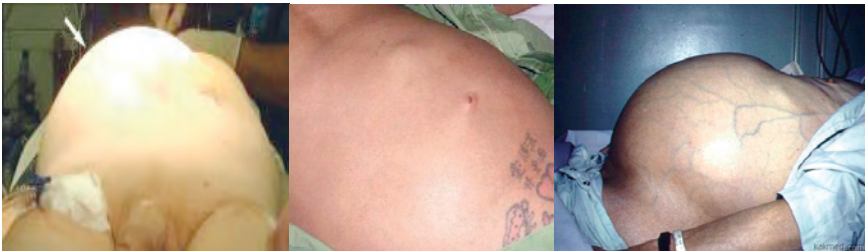- ❖ Look for scars, striae, hernias, vascular changes, lesions, or rashes
- ❖ Look for pulsations or peristalsis
- ❖ Observe the abdominal contour



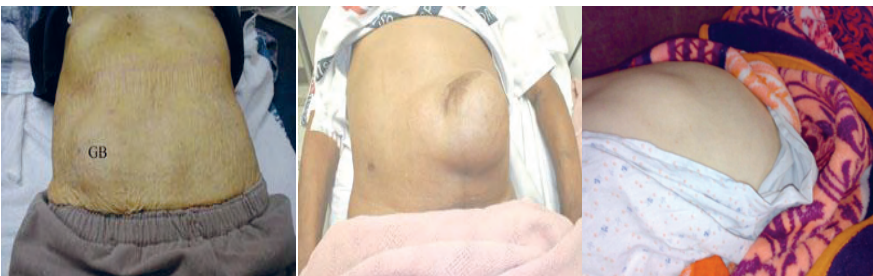Sinus or yellowish spots on the left side of the abdomen (Gray-Turner symptom) or in the navel (Cullen symptom)



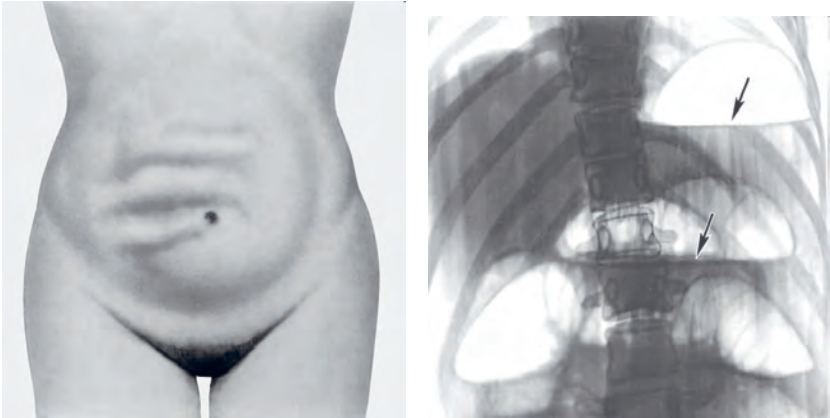
**Abdominal striae**



**Static and dynamic examination of the abdomen**



## Hyper peristalsis with intestinal obstruction



Kloiber bowls

### Bowel Sounds and Bruits

Change	Seen With
Increased bowel sounds	Diarrhea
Decreased, then absent bowel sounds	Early intestinal obstruction
High-pitched tinkling bowel sounds	Adynamic ileus
High-pitched rushing bowel sounds with cramping	Peritonitis
Hepatic bruit	Intestinal fluid
Arterial bruits	Air under tension in a dilated bowel
	Intestinal obstruction
	Carcinoma of the liver
	Alcoholic hepatitis
	Partial obstruction of the aorta or renal, iliac or femoral arteries

## Auscultation

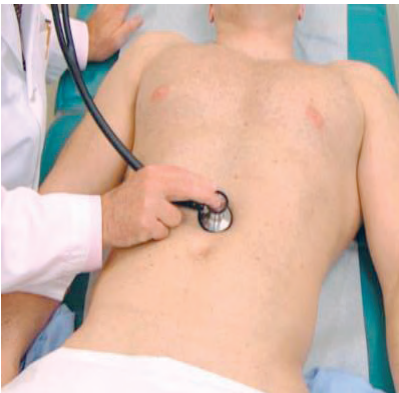- ❖ Listen until bowel sounds are heard or for a full minute
- ❖ Report sounds as increased, decreased, or normal

- ❖ **Auscultation for Bruits**

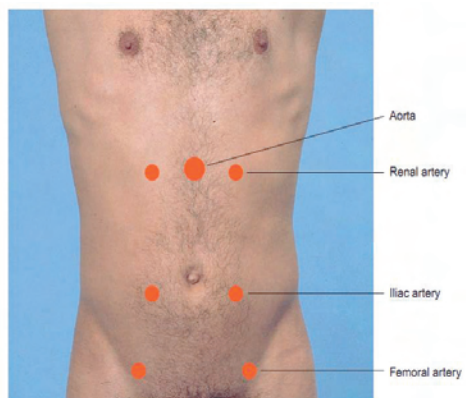
- ❖ **Auscultate for aorta**

- ❖ **Auscultate for renal arteries**

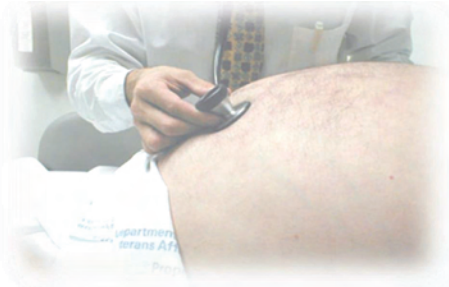- ❖ **Auscultate for iliac arteries**



Technique for studying bowel sounds

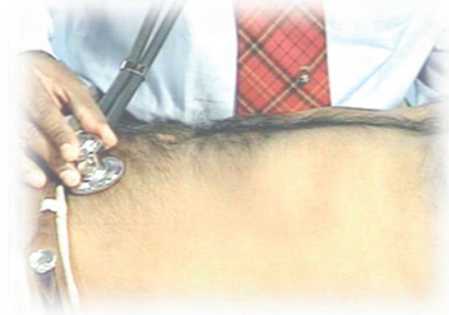

Vascular auscultation



Auscultation takes place before percussion and palpation so that intestinal activity is not disturbed by the examiner's hands

**NB!**



## Abdominal Examination

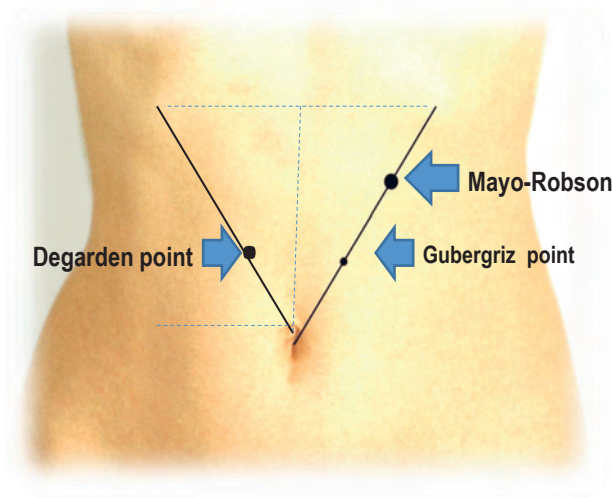
- Percussion and palpation are usually performed simultaneously and should involve all four quadrants, **the epigastrium, the periumbilical region, and the pelvis**
- Initial light percussion can indicate where the abdominal pain is most intense
- During palpation, one should **start with a survey of light palpation in the area farthest away from the point of maximum tenderness**, followed by gentle deeper and deeper palpation over the area of greatest tenderness. If the physician immediately palpates the place of maximum tenderness, the patient is unlikely to let the examination continue
- Localized or diffuse rebound tenderness and guarding should be gently elicited because even “accidentally” bumping the bed or stretcher will move the patient enough to cause peritoneal irritation and pain in patients who have inflammation of the parietal peritoneum (e.g., peritonitis)

## Abdominal Examination

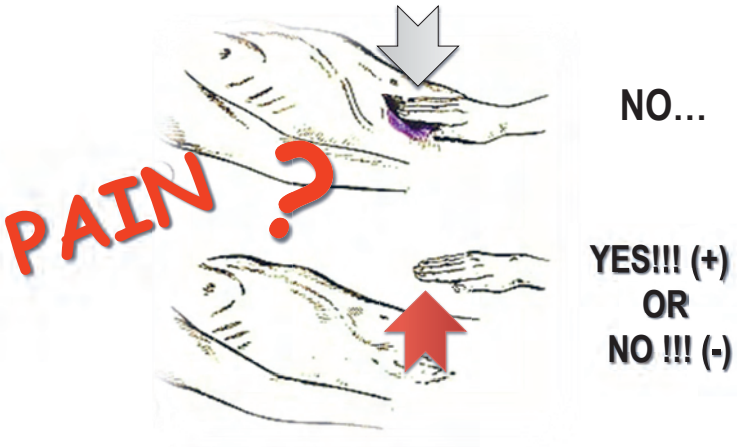
- The location of any referred pain, such as in the back, should also be examined to exclude extraintestinal diseases (e.g., pyelonephritis)
- Abdominal palpation should include **evaluation for any masses**, including their size, location, and consistency, as well as for the presence or absence of tenderness
- **Examination of the right upper quadrant** should include a determination of the size, texture, and presence of any liver tenderness or masses, in addition to the presence or absence of a distended gallbladder or evidence of pain on palpation of the gallbladder, such as Murphy's sign, which may be present in acute cholecystitis
- **Percussion of the left upper quadrant** in inspiration and expiration to evaluate spleen size is useful and will detect splenomegaly at its earliest stages
- **The back and costovertebral angles should be inspected** and gently percussed to exclude costovertebral angle tenderness, as found in pyelonephritis

## Percussion

- ❖ Check in all 4 quadrants
- ❖ Outline areas of dullness and tympanic
- ❖ Test liver span down the midclavicular line
- ❖ Test splenic dullness down the left anterior auxiliary line



**Pain points**



**Schetkin-Blyumberg sign (concussion s.)**



Percuss the abdomen for patterns of tympany and dullness.

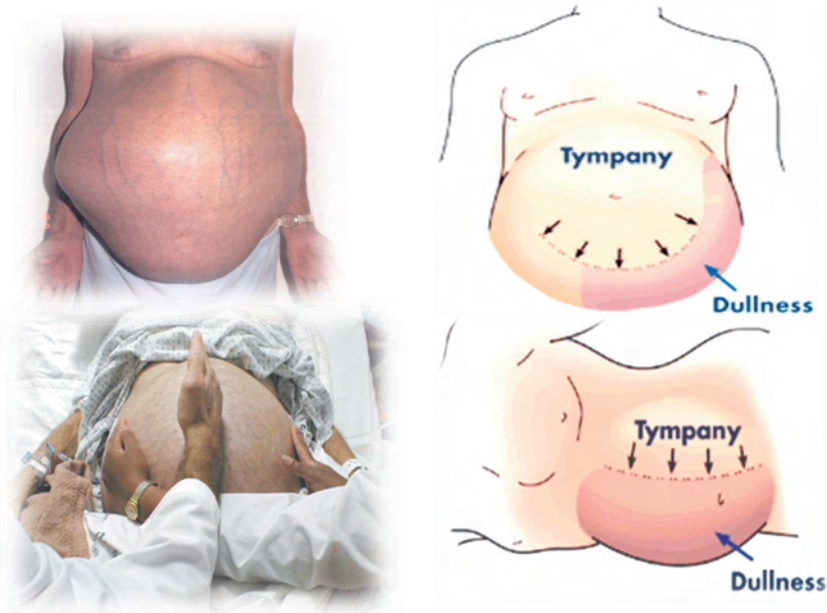
Ascites, GI obstruction, pregnant uterus, ovarian tumor

## Evaluation of the patient with ascites

### Special Considerations:

- ❖ Shifting Dullness
- ❖ Check level of dullness
- ❖ Ask patient to roll on side
- ❖ Test new level of dullness
- ❖ Repeat on other side

## Evaluation of the patient with ascites

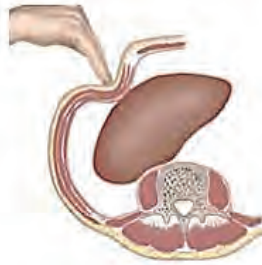

**EXAMINATION TECHNIQUES**

○— Ballote an organ or mass in an ascitic abdomen. Place your stiffened and straightened fingers on the abdomen, briefly jab them toward the structure, and try to touch its surface.

**POSSIBLE FINDINGS**

Your hand, quickly displacing the fluid, stops abruptly as it touches the solid surface.

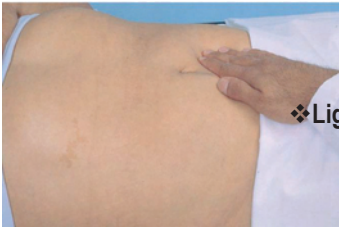

**Palpation**

Abdominal palpation is commonly divided into the following:

- Light palpation
- Deep palpation
- Liver palpation
- Spleen palpation
- Kidney palpation

## Oriental Superficial palpation



### Light Palpation

❖ Lightly palpate in all 4 quadrants and the midline

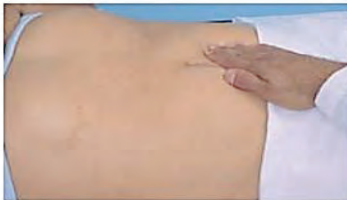❖ Observe for signs of discomfort

### Special Considerations:

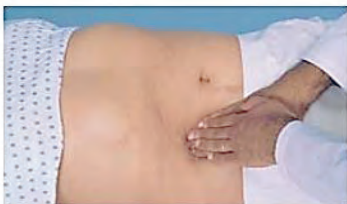- ❖ Rebound Tenderness
  - ❖ Warn patient
- ❖ Slowly press abdomen on the side of reported pain
  - ❖ Quickly release pressure
  - ❖ Observe for signs of discomfort

#### EXAMINATION TECHNIQUES

- Lightly for guarding, rebound, and tenderness



- Deeply for masses or tenderness



#### POSSIBLE FINDINGS

**"Acute abdomen" or peritonitis if:**

- **Firm, boardlike abdominal wall— suggests peritoneal inflammation.**
- **Guarding if the patient flinches, grimaces, or reports pain during palpation.**
- **Rebound tenderness from peritoneal inflammation; pain is greater when you withdraw your hand than when you press down. Press slowly on a tender area, then quickly "let go."**

**Tumors, a distended viscus**

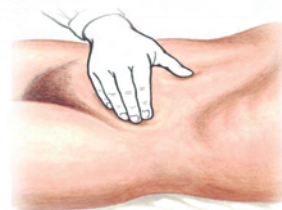## SLIDING topographic deep methodical palpation of the abdomen

By V. Obratsov and N. Strazhesko

The concept of topographic mean the following sequence:

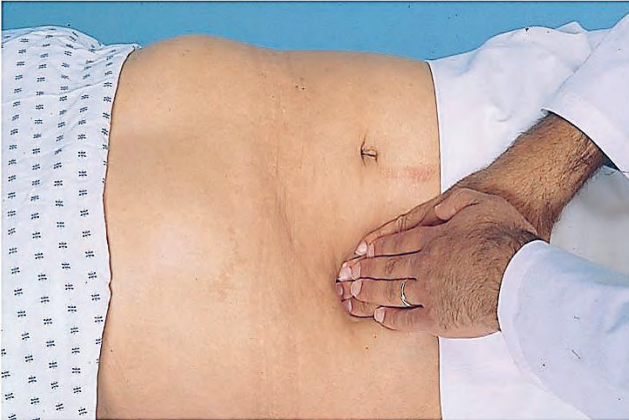
- the sigmoid colon,
- the cecum with the appendix,
- the final part of the ileum,
- the downward portion of the colon
- the ascending portion of the colon,
- transverse colon,
- stomach and its departments,
- the liver,
- gallbladder,
- pancreas,
- spleen
- and kidneys

### The rules & steps



- 1.** The position of right hand with slightly bent fingers set parallel to palpable organ.
- 2.** The formation of skin folds.
- 3.** The gradual sinking deeper the arm while exhale into the abdomen.
- 4.** Proper palpation: slide your fingertips over the back wall of the abdomen and examined organs.

**Deep Palpation.** This is usually required to delineate abdominal masses. Again using the palmar surfaces of your fingers, press down in all four quadrants. Identify any masses; note their location, size, shape, consistency, tenderness, pulsations, and any mobility with respiration or pressure from the examining hand. Correlate your palpable findings with their percussion notes.

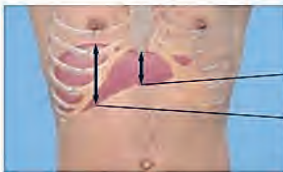

TWO-HANDED DEEP PALPATION

## THE LIVER

Percuss span of liver dullness in the midclavicular line (MCL).

**Hepatomegaly**



4–8 cm in midsternal line  
6–12 cm in right midclavicular line  
} Normal liver spans

Feel the liver edge, if possible, as patient breathes in.

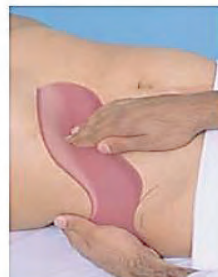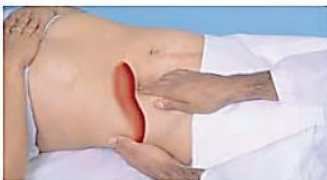**Firm edge of cirrhosis**

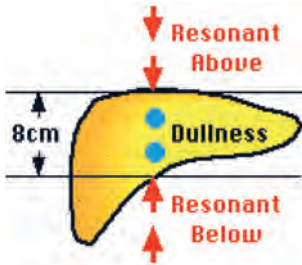
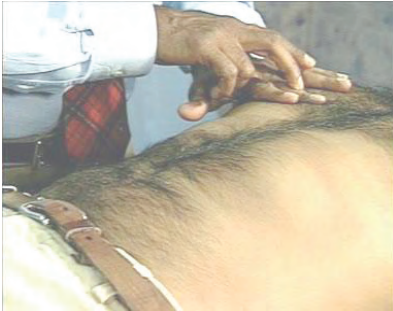### EXAMINATION TECHNIQUES

Measure its distance from the costal margin in the MCL.

### POSSIBLE FINDINGS

Increased in hepatomegaly—may be missed (as below) by starting palpation too high in the RUQ

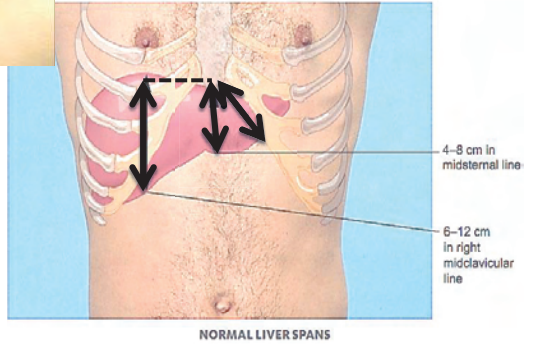




## The Liver

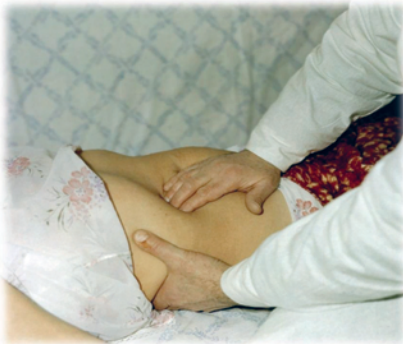### Examine Liver Size

According to Kurlov



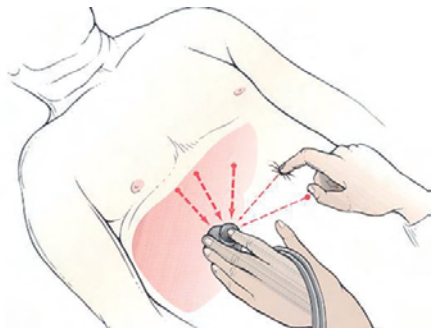
## The Liver

- ❖ Palpate the liver



### Special Considerations:

- ❖ Liver Scratch Test
  - ❖ Place diaphragm of stethoscope over upper margin of liver
  - ❖ Lightly scratch the skin below the anticipated lower edge of the liver
  - ❖ Methodically scratch higher until sound is magnified by the mass of the liver



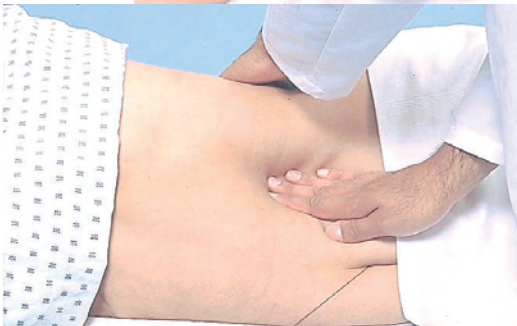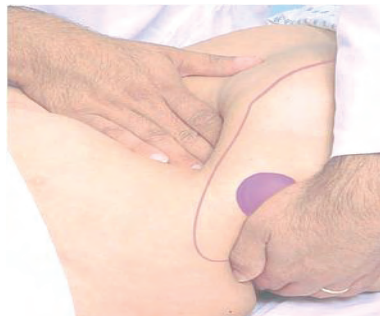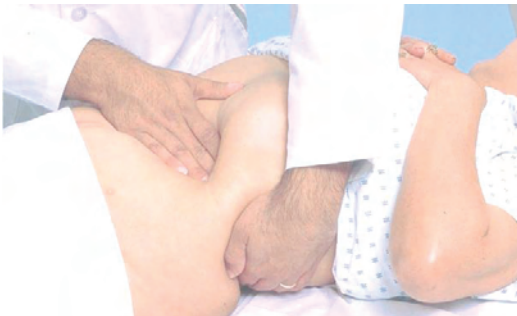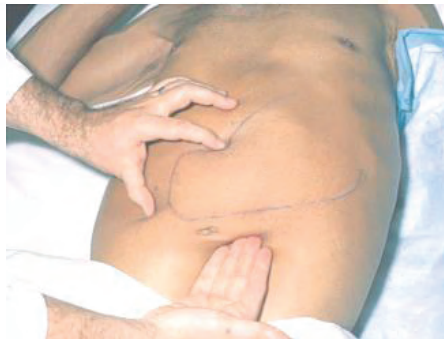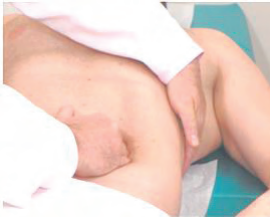## THE SPLEEN

Percuss across left lower anterior chest, noting change from tympany to dullness.

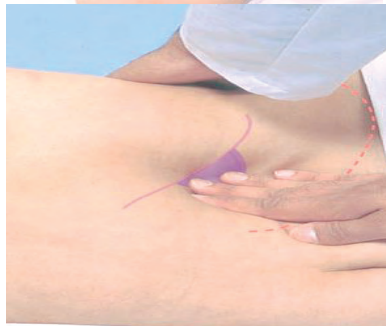Try to feel spleen with the patient:

- Supine

Lying on the right side with legs flexed at hips and knees



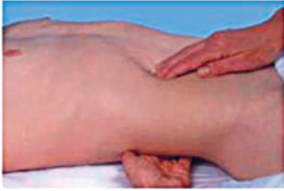Umbilicus



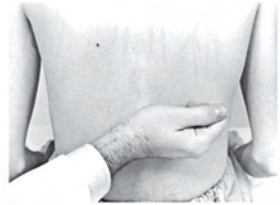## Splenomegaly

**THE KIDNEYS**

Try to palpate each kidney.

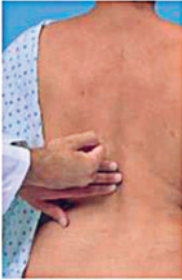

Enlargement from cysts, cancer, hydronephrosis



Sign of tapping in the lumbar region

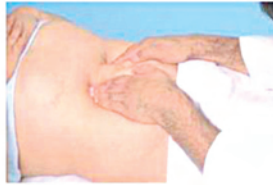Check for costovertebral angle (CVA) tenderness.



Tender in *pyelonephritis*

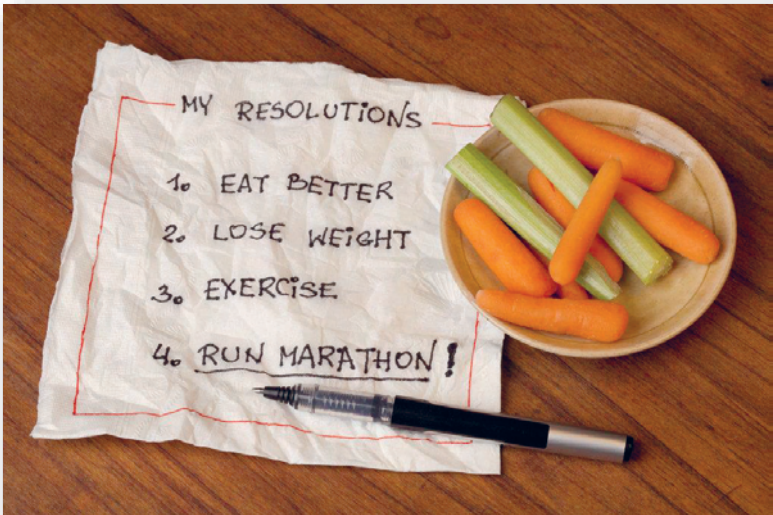**THE AORTA**

Palpate the aorta's pulsations. In older people, estimate its width.



Periumbilical mass with expansile pulsations  $\geq 3$  cm in diameter in *abdominal aortic aneurysm*. Assess further due to risk of rupture.

Palpate for the aorta and determines width



**Be healthy!**



## REFERENCES

Kovalyova O.N., Ashcheulova T.V. Propedeutics to Internal Medicine. Part 1. – Vinnytsya: NOVA KNYHA, 2017. – 424 p.

Kovalyova O.N., Asheulova T.V. General inspection: manual for students. – Kharkov: “Turbo”. – 2004. – 60 p.

Khomazjuk V.A., Ostashevskaya T.G., Krasnyuk I.V. Propaedeutics of Internal Medicine and Patient Care: Study guide for the practical classes. Part I. – Kyiv: NMU, 2005. – 44 p.

Kovalyova O.N., Asheulova T.V. Examination of the patients with digestive pathology: manual for students. – Kharkov: KSMU – 2004. – 112 p.

Bickley, Lynn S.; Szilagy, Peter G. Bates' Guide to Physical Examination and History Taking, 10th Edition. – 934 p. Copyright ©2009 Lippincott Williams & Wilkins

The Point online resources, <http://thepoint.lww.com>



Учбове видання

ХОМАЗЮК Тетяна Анастасіївна

## ПРОПЕДЕВТИКА ВНУТРІШНЬОЇ МЕДИЦИНИ

Учбово-наочний посібник

В двох частих. Частина 1  
(англійською мовою)

Відповідальна за випуск О.В. Вінниченко

Макет та верстка Misheal\_D

Формат 60x90/16. Папір офсетний. Гарнітура Myriad Pro.  
Ум. друк. арк. 23,0. Замовлення № 19/19.

Видавець і виготовлювач видавництво «ГЕРДА»,  
49000, м. Дніпро, пр. Д. Яворницького, 60  
Свідоцтво суб'єкта видавничої справи ДК № 397 від 03.04.2001  
[www.book-shop.in.ua](http://www.book-shop.in.ua)

ISBN 978-617-7639-17-5

ISBN 978-617-7639-18-2 (ч. 1, pdf)



