

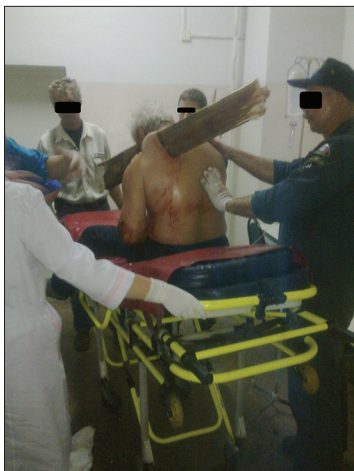## Challenges of Impalement Injuries

Dear Editor,

I read the paper on impalement injury by Kollahdouzan *et al.* with interest, for what I would like to thank the authors.<sup>[1]</sup> I would like to share an interesting case from our practice and my viewpoint.

A 61-year-old male patient was brought in by paramedics and a brigade of emergency situations with left-sided thoracic impalement injury. The patient, who was in a road maintenance team, was impaled by a wooden block while driving his truck in a construction site almost 2 h before admission [Figure 1]. On admission, his blood pressure was 90/60 mmHg, heart rate –116 bpm, and hemoglobin –10.8 g/dL. The patient underwent surgery immediately under general anesthesia in the right lateral recumbent position on the operating table. The fistulotomy-like incision connecting the entrance and the exit wounds was performed to uncover the traumatic agent and the wound canal. This incision was supplemented with the left anterolateral thoracotomy in the 5<sup>th</sup> intercostal space. The surgery revealed the comminuted fractures of the scapula and the clavicle, penetration of the injury to the left pleural cavity without any injury to vessels, but with minor injury to the lung. Primary repair of the lung, debridement, osteosynthesis, and drainage of the pleural cavity and the wound canal were performed. Postoperatively, the patient recovered uneventfully, for what he called himself “the luckiest man.” The patient was discharged on the 14<sup>th</sup> postoperative day. On the follow-up after 3 months, the patient was well.

Impalement injuries are defined as penetrating injuries where traumatic agent remains impaled in the human body.<sup>[2]</sup> Due to their rarity, the management of this clinical condition remains controversial. Impalement injuries are classified according to their mechanism and impaled regions (abdominal, thoracic,



**Figure 1:** The patient with impalement thoracic injury on admission

thoracoabdominal, perineal, neck, head, and so on). According to mechanism Type I injuries are those when traumatic agent is immobile, whereas in Type II injuries, the injured person is immobile against the mobile traumatic agent.<sup>[3]</sup> Our patient suffered Type II impalement injury. There are several challenges concerning impalement injuries which could be classified into three groups: prehospital care, transportation, and in-hospital management.<sup>[4]</sup> One of the major problems of prehospital care is deliverance from impaling object, especially when the object is huge, such as a wooden block. Paramedics who are called the first to the scene are not ready and competent to release the patient due to lack of skills and equipment leading to some delay. Another issue is that the deliverance *per se* requires time so that the traumatic agent has to be cut not to remove the traumatic agent (this is an important rule of prehospital care) as this can lead to massive bleeding and death.<sup>[5]</sup> Transportation is another specific challenge of impalement injuries so that the standard supine position is impossible in some cases. Hence, lateral recumbent positions are more helpful in cases of anterior-posterior impalement injuries and vice versa. Challenges of in-hospital management are instrumental diagnosis, anesthesia, and surgery. In some cases, especially when traumatic agent is huge, the radiologic examination is almost impossible. On the other hand, a patient with impaled traumatic agent always requires immediate surgery to remove the object, revise the wound canal, and manage accordingly. Hence, preoperative examinations except for clinical examination seem to be difficult and nonhelpful; instead, they are time-consuming what is, especially crucial for these patients who are usually brought in with delay. The problem of positioning on the operating table is more significant for anesthesiologist because it complicates the induction.<sup>[4]</sup> The most important rules of surgical strategy are the removal of the traumatic agent under the direct visual control, extensive debridement and drainage of the wound canal, thorough hemostasis, and open healing of the entrance and exit wounds.<sup>[5,6]</sup> Postoperatively, broad-spectrum antibiotics and tetanus prophylaxis should be administered.

To conclude, impalement injuries are complex, penetrating injuries accompanying with several challenges in prehospital care, transportation, and surgical management. Surgeons, anesthesiologists, and other related health-care specialists should be aware of this clinical entity and its challenges.

### Declaration of patient consent

The authors certify that they have obtained all appropriate patient consent forms. In the form the patient(s) has/have given his/her/their consent for his/her/their images and other clinical information to be reported in the journal. The patients understand that their names and initials will not be published

and due efforts will be made to conceal their identity, but anonymity cannot be guaranteed.

### Financial support and sponsorship

Nil.

### Conflicts of interest

There are no conflicts of interest.

#### Mahir Gachabayov


Department of Abdominal Surgery, Vladimir City Clinical Hospital of Emergency Medicine, Vladimir, Russia

**Address for correspondence:** Dr. Mahir Gachabayov,  
Department of Abdominal Surgery, Vladimir City Clinical Hospital of  
Emergency Medicine, Stavrovskaya Street, 6-73, Vladimir600022, Russia.  
E-mail: Gachabayovmahir@gmail.com

### REFERENCES

1. Kolahdouzan M, Rezaee MT, Shahabi S. Impalement thoracoabdominal trauma secondary to falling on metallic (Iron) bars: An extremely rare and unique case. Arch Trauma Res 2016;5:e18330.
2. Horowitz MD, Dove DB, Eismont FJ, Green BA. Impalement injuries. J Trauma 1985;25:914-6.
3. Eachempati SR, Barie PS, Reed RL 2<sup>nd</sup>. Survival after transabdominal impalement from a construction injury: A review of the management of impalement injuries. J Trauma 1999;47:864-6.
4. Kaur K, Singhal SK, Bhardwaj M, Kumar P. Penetrating abdomino-thoracic injury with an iron rod: An anaesthetic challenge. Indian J Anaesth 2014;58:742-5.
5. Angelopoulos S, Mantzoros I, Kyziridis D, Fontalis A, Parpoudi S, Konstandaras D, *et al*. A rare case of a transabdominal impalement after a fall from a ladder. Int J Surg Case Rep 2016;22:40-3.
6. Lunca S, Morosanu C, Alexa O, Perlea M. Severe thoracic impalement injury: Survival in a case with delayed surgical definitive care. Ulus Travma Acil Cerrahi Derg 2015;21:152-6.

This is an open access article distributed under the terms of the Creative Commons Attribution-NonCommercial-ShareAlike 3.0 License, which allows others to remix, tweak, and build upon the work non-commercially, as long as the author is credited and the new creations are licensed under the identical terms.

Access this article online	
<b>Quick Response Code:</b> 	<b>Website:</b> www.archtrauma.com
	<b>DOI:</b> 10.4103/atr.atr_23_17

**How to cite this article:** Gachabayov M. Challenges of impalement injuries. Arch Trauma Res 2017;6:53-4.  
© 2017 Archives of Trauma Research | Published by Wolters Kluwer - Medknow