



Volume 6 | Issue 4

Article 6

2020

## Pyloric Stenosis Leading to Sinus Venous Thrombosis; A Case Report

Amber Wright, Andrew J. Weaver, and Daniel Beals

### Author Affiliations

Andrew J. Weaver (*Marshall University Joan C. Edwards School of Medicine, Huntington, West Virginia*)

### Corresponding Author

Andrew J. Weaver MD

Marshall University Joan C. Edwards School of Medicine

Huntington, West Virginia

Email: [weaveran@marshall.edu](mailto:weaveran@marshall.edu)

Follow this and additional works at: <https://mds.marshall.edu/mjm>

 Part of the [Surgery Commons](#)



This work is licensed under a [Creative Commons Attribution 4.0 License](#).

## Recommended Citation

Wright, Amber; Weaver, Andrew J.; and Beals, Daniel (2020) "Pyloric Stenosis Leading to Sinus Venous Thrombosis; A Case Report," *Marshall Journal of Medicine*: Vol. 6: Iss. 4, Article 6.

DOI: [10.33470/2379-9536.1307](https://doi.org/10.33470/2379-9536.1307)

Available at: <https://mds.marshall.edu/mjm/vol6/iss4/6>

DOI: [10.33470/2379-9536.1307](https://doi.org/10.33470/2379-9536.1307)

Author Footnote: Authorship: All authors attest that they meet the current ICMJE criteria for authorship. Conflict of Interest: None Author Contribution: 1. Amber Wright: literature search, drafting article 2. Andrew J Weaver: literature search, drafting article 3. Daniel Beals: Manuscript concept, analysis, critical revision

Open Access | 

## **Pyloric stenosis leading to sinus venous thrombosis: a case report**

### **Abstract**

Pyloric stenosis is typically diagnosed early and repaired after resuscitation and electrolyte correction in a timely manner. Delay in diagnosis or presentation of a patient can lead to significant morbidity and even mortality. We present a case of pyloric stenosis leading to dehydration severe enough to cause venous sinus thrombosis. This case highlights the importance of early detection of pyloric stenosis with timely correction of fluid status and electrolytes. Venous sinus thrombosis is a serious complication associated with our patient's pyloric stenosis that has not yet been reported on in the literature.

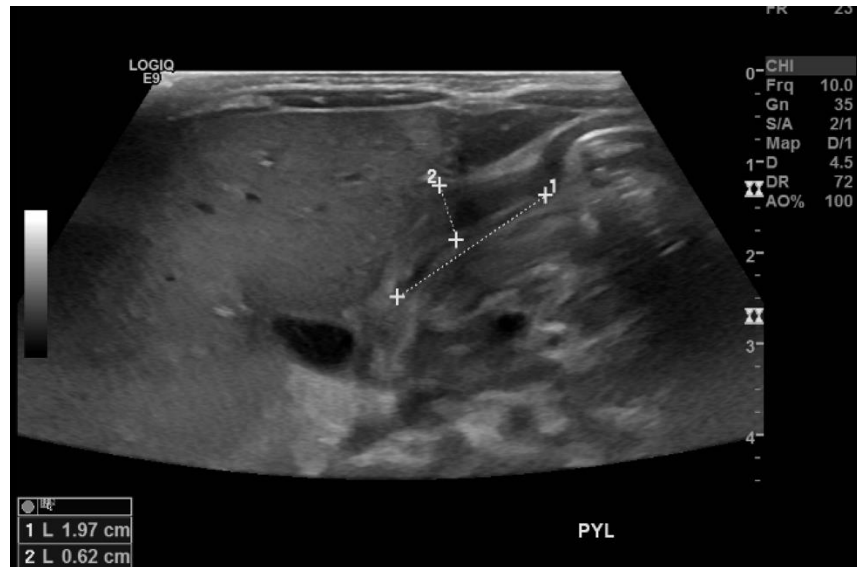
### **Keywords**

Pyloric stenosis, Venous sinus thrombosis

### **Case Report**

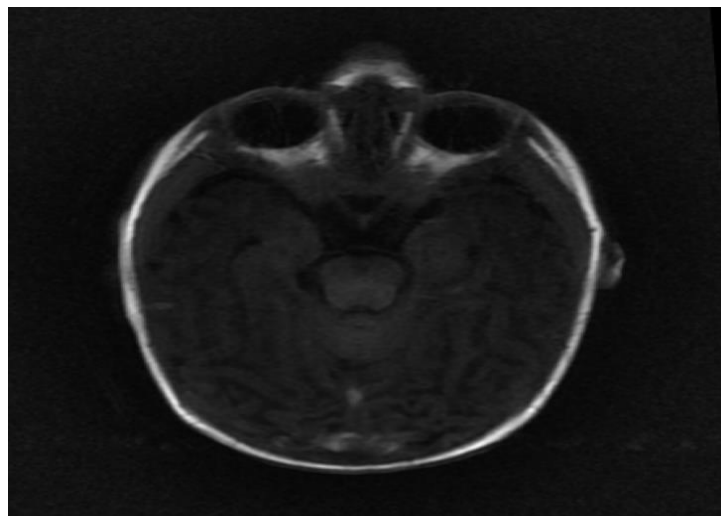
Our patient was a 30-day-old female born via NSVD to a 34-year-old G11 P5 mother with a pregnancy complicated by poor prenatal care and diet-controlled gestational diabetes mellitus. The patient presented from an outside clinic with failure to thrive. Born 7lbs 9oz, her weight declined to 5lbs 14oz at the time of her admission. She was formula fed since birth, with frequent spit-ups that gradually worsened and developed into projectile vomitus over the course of the two weeks prior to presentation.

On the day of admission, the patient had six seizure-like episodes lasting thirty seconds each and was therefore transferred to the PICU. She presented with the classical metabolic abnormalities of hypokalemia, hypochloremia, and metabolic alkalosis, which are seen with hyperemesis. Due to a history concerning for pyloric stenosis, she underwent an ultrasound with findings of pyloric length 18mm and muscle thickness 6mm, confirming the diagnosis (Figure 1).

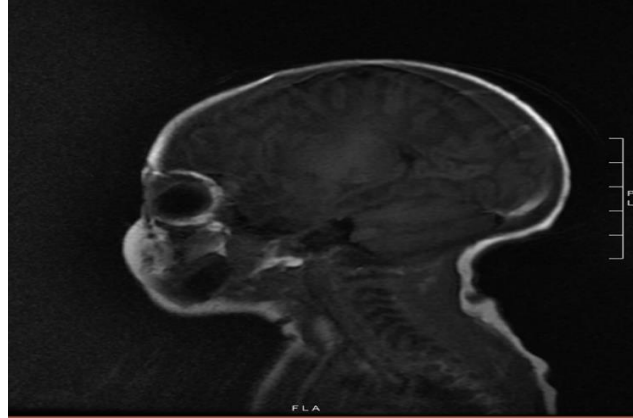

**Figure 1:** Ultrasound of pyloric stenosis

In working up the seizure-like activity, and in order to rule out the possibility of intracerebral hemorrhage, the patient underwent head CT with no acute findings. She then underwent an MRI to rule out venous sinus thrombosis, with findings of thrombosis in the straight sinus extending into the torcula and superior sagittal sinus (Figures 2-3). There was also questionable thrombus within the internal cerebral veins. With these findings in hand, the patient was started on Lovenox for anticoagulation. Of note, the patient had no family history of any hypercoagulation disorders. Hematology was consulted to assist with the choice of anticoagulation.



**Figure 2:** Axial MRI of venous sinus thrombosis



**Figure 3:** Sagittal ultrasound of venous sinus thrombosis

On hospital day two, the electrolyte abnormalities had been corrected and no further seizure-like activity was observed in the patient. A joint multidisciplinary decision was made to take the patient for laparoscopic pyloromyotomy.

The patient was kept on a small volume Pedialyte feeds postoperative day one and advanced to formula on postoperative day two, which she tolerated well with infrequent episodes of spit-ups and no further episodes of projectile vomitus. The patient went home on postoperative day eight.

## Discussion

Infantile hereditary pyloric stenosis was described first by Hirschsprung in 1888. It is the most reported cause of gastric outlet obstruction in infancy.<sup>4</sup> Pyloric stenosis tends to occur more in males by an approximate 4:1 ratio.<sup>1</sup> Our patient presented with the classic presentation of non-bilious emesis with the expected metabolic abnormalities of hypokalemia, hypochloremia, and metabolic alkalosis. Ultrasound is the gold standard for imaging diagnosis, with the generally accepted guidelines of 3mm for pyloric muscle thickness and 15mm for pyloric muscle length set forth by Rohrschneider et al., although some argue that for small infants a lower threshold should be considered in muscle size.<sup>5,6</sup>

Dehydration is one of the most common risk factors of venous sinus thrombosis in neonates. Other risk factors include fever, anemia, and infections such as URI, otitis, sinusitis.<sup>3</sup> Other reported cases are from complications of cancers such as ALL.<sup>7</sup> Venous sinus thrombosis has variable presentations. In our case, it was seizure-like activity. Other possible symptoms that should raise suspicion are altered mental status, encephalopathy, and focal or diffuse neuro deficits.

The treatment of pyloric stenosis is a pyloromyotomy, typically completed laparoscopically. Pyloric stenosis does not usually present as an emergent case, and surgery should be completed after the correction of electrolyte abnormalities. Approximately one in four cases are diagnosed and treated after symptoms are present for longer than one week.<sup>8</sup> This was the case with our patient, which likely contributed to the more serious complication.

The treatment for venous sinus thrombosis is anticoagulation. In the 1990s, heparin was found to be an effective treatment.<sup>9</sup> Misra et al. found low-molecular-weight heparin to be associated with lower morbidity than unfractionated heparin.<sup>10</sup> Although one can see how pyloric stenosis leading to dehydration causing venous sinus thrombosis is logical theoretically, this is the only case of this mechanism found in an extensive literature review.

## **Conclusion**

This case highlights the importance of early detection of pyloric stenosis with timely correction of fluid status and electrolytes. Venous sinus thrombosis is a serious complication associated with our patient's pyloric stenosis that has not yet been reported on in the literature.

## **Lessons Learned**

Delay in diagnosis or presentation of a patient with pyloric stenosis can lead to significant morbidity.

## References

1. To T, Wajja A, Wales PW, Langer JC. Population demographic indicators associated with incidence of pyloric stenosis. *Arch Pediatr Adolesc Med.* 2005;159(6):520-5.
2. Taylor ND, Cass DT, Holland AJ. Infantile hypertrophic pyloric stenosis: has anything changed? *J Paediatr Child Health.* 2013;49(1):33-7.
3. Dlamini N, Billingham L, Kirkham FJ. Cerebral venous sinus (sinovenous) thrombosis in children. *Neurosurg Clin N Am.* 2010;21(3):511-27.
4. Chalya PL, Manyama M, Kayange NM, Mabula JB, Massenga A. Infantile hypertrophic pyloric stenosis at a tertiary care hospital in Tanzania: a surgical experience with 102 patients over a 5-year period. *BMC Res Notes.* 2015;8:690.
5. Rohrschneider WK, Mittnacht H, Darge K, Troger J. Pyloric muscle in asymptomatic infants: sonographic evaluation and discrimination from idiopathic hypertrophic pyloric stenosis. *Pediatr Radiol.* 1998;28(6):429-34.
6. Said M, Shaul DB, Fujimoto M, Radner G, Sydorak RM, Applebaum H. Ultrasound measurements in hypertrophic pyloric stenosis: don't let the numbers fool you. *Perm J.* 2012;16(3):25-7.
7. Ghanem KM, Dhayni RM, Al-Aridi C, Tarek N, Tamim H, Chan AKC, et al. Cerebral sinus venous thrombosis during childhood acute lymphoblastic leukemia therapy: Risk factors and management. *Pediatr Blood Cancer.* 2017;64(12).
8. Acker SN, Garcia AJ, Ross JT, Somme S. Current trends in the diagnosis and treatment of pyloric stenosis. *Pediatr Surg Int.* 2015;31(4):363-6.
9. de Bruijn SF, Stam J. Randomized, placebo-controlled trial of anticoagulant treatment with low-molecular-weight heparin for cerebral sinus thrombosis. *Stroke.* 1999;30(3):484-8.
10. Misra UK, Kalita J, Chandra S, Kumar B, Bansal V. Low molecular weight heparin versus unfractionated heparin in cerebral venous sinus thrombosis: a randomized controlled trial. *Eur J Neurol.* 2012;19(7):1030-6.