

2020

## Recurrent Reversible Encephalopathy with Ataxia and D-Lactic acidosis in Short bowel Syndrome

Abdul Rana, Salman Assad, Sucharita Katikala, Shuja Asad Malik, Mahmoud Abouzid, Mehar Zahid, and Swaroopa Pulivarthi

### Author Affiliations

Author affiliations:

Abdul Rana (*Marshall University Joan C. Edwards School of Medicine, Huntington, West Virginia*)

Salman Assad (*Marshall University Joan C. Edwards School of Medicine, Huntington, West Virginia*)

Sucharita Katikala (*Marshall University Joan C. Edwards School of Medicine, Huntington, West Virginia*)

Shuja Asad Malik (*University of Gujrat, Pakistan*)

Mahmoud Abouzid (*Marshall University Joan C. Edwards School of Medicine, Huntington, West Virginia*)

Mehar Zahid (*Marshall University Joan C. Edwards School of Medicine, Huntington, West Virginia*)

Swaroopa Pulivarthi (*Marshall University Joan C. Edwards School of Medicine, Huntington, West Virginia*)

### Corresponding Author

Salman Assad MD

Marshall University, Joan C. Edwards School of Medicine

Follow this and additional works at: <https://mds.marshall.edu/mjm>

Huntington, West Virginia  
Part of the [Neurology Commons](#)  
Email: [assad@marshall.edu](mailto:assad@marshall.edu)



This work is licensed under a [Creative Commons Attribution 4.0 License](#).

## Recommended Citation

Rana, Abdul; Assad, Salman; Katikala, Sucharita; Malik, Shuja Asad; Abouzid, Mahmoud; Zahid, Mehar; and Pulivarthi, Swaroopa (2020) "Recurrent Reversible Encephalopathy with Ataxia and D-Lactic acidosis in Short bowel Syndrome," *Marshall Journal of Medicine*: Vol. 6: Iss. 3, Article 11.

DOI: [10.33470/2379-9536.1260](https://doi.org/10.33470/2379-9536.1260)

Available at: <https://mds.marshall.edu/mjm/vol6/iss3/11>

DOI: [10.33470/2379-9536.1260](https://doi.org/10.33470/2379-9536.1260)

Open Access |

## **Recurrent reversible encephalopathy with ataxia and D-lactic acidosis in short bowel syndrome**

### **Abstract**

The short gut syndrome can lead to multiple metabolic disorders along with chronic malnutrition. Such patients can develop changes in mental status due to metabolic alterations. We present a case of an eleven-year-old male who presented to the hospital with an altered mental state. There were repeated admissions to the hospital with similar complaints with non-conclusive cerebrospinal fluid analysis and normal neuroimaging findings. The patient suffered from chronic malnutrition and multiple hospitalizations with altered mental status, encephalopathy. However, he responded well to bicarbonate therapy and prophylactic metronidazole treatment.

### **Keywords**

D-Lactic acidosis, Encephalopathy, Short gut syndrome

### **Introduction**

The post-natal or premature loss of small bowel more than fifty percent with or without large intestinal loss is known as short bowel syndrome (SBS). This condition can lead to lactic acidosis and chronic malnutrition.<sup>1</sup> Congenital SBS usually presents as malrotation or gastroschisis in utero. Crohn's disease, trauma or other multiple small bowel conditions lead to surgical resection of the bowel leading to SBS.<sup>2</sup>

### **Case Presentation**

We present a case of an eleven-year-old male with a past medical history of hypocomplementemia, generalized clonic seizure (GTC), and gastroschisis, who came to the hospital with complaints of dizziness, confusion, and wobbly gait for twenty-four hours prior to the visit. The patient mentioned about passing out episodes of unspecified duration without any random jerking body movements. When seen by a neurology resident, the patient was alert, awake, oriented, and following commands without any problems. He was feeling sluggish and tired but was cooperative during the physical exam (Table 1). The laboratory findings have been mentioned in Table 2.

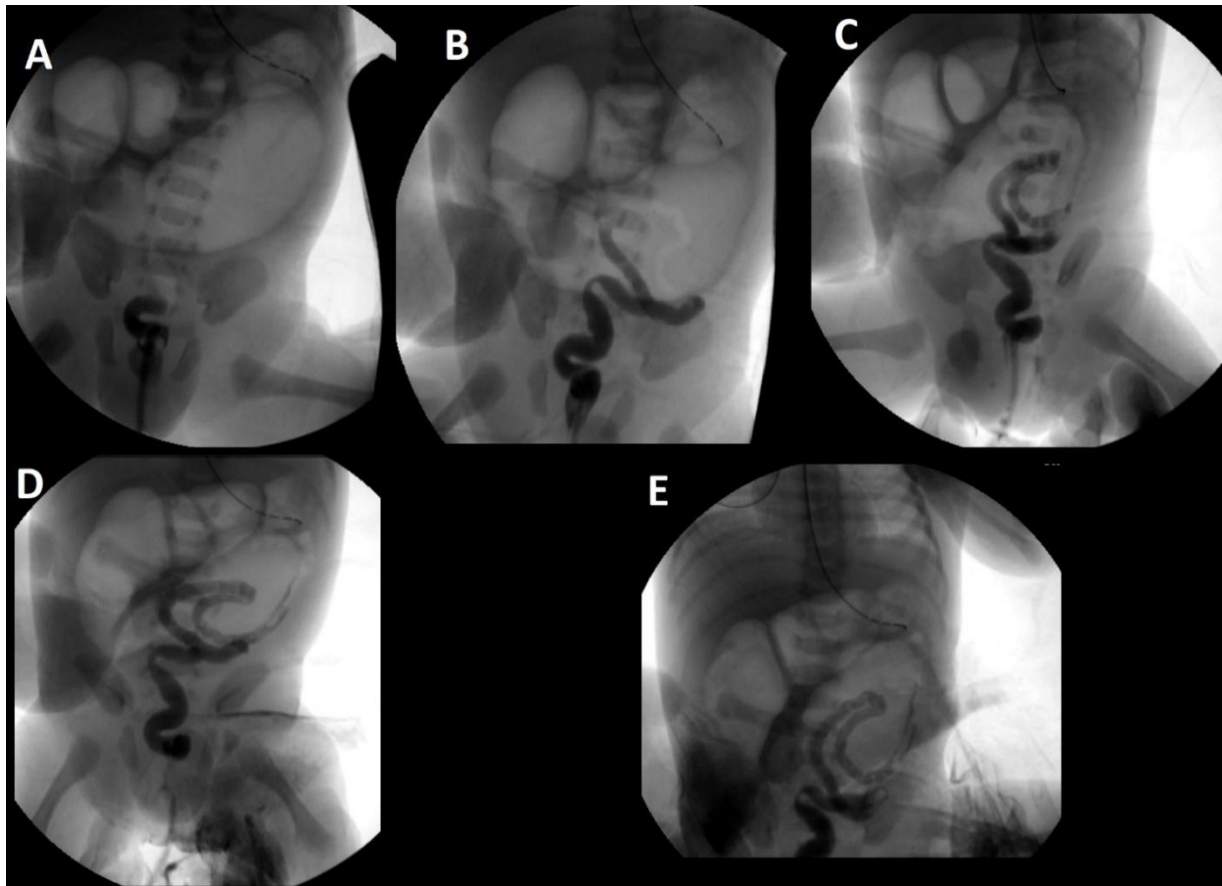
**Table 1:** Physical Examination and Neurological Examination

<b>Physical Exam:</b>
GENERAL: Lying on bed in mild distress. Followed simple commands.
HEAD: Atraumatic and Normocephalic
EYES: Intact extraocular movements, no nystagmus, or no eye deviation.
Throat: Oropharynx clear. No lymphadenopathy.
CARDIOVASCULAR: S1+S2+0, regular rate, and rhythm, no murmurs audible.
ABDOMEN: Soft, non-tender, and non-distended bowel sounds.
RESPIRATORY: Clear to auscultation, Symmetrical Chest expansion, No respiratory distress, saturating well on monitor.
SKIN: No rash or skin deformity noted.
<b>Neurological Exam:</b>
MENTAL STATUS EXAM: Orientation: Alert, awake, and oriented x 3. Memory: Intact, follows simple commands. Attention/concentration: Attention span and concentration are normal. Language/Speech: No dysarthria/ No Aphasia.
CRANIAL NERVES (CN): CN 2 (Optic): Intact CN 3,4,6: Pupils equal and reactive to light and near full eye movement without nystagmus. CN 5 (Trigeminal): Facial sensation is normal, no weakness of masticatory muscles. CN 7 (Facial): No facial asymmetry noted. CN 8 (Auditory): Auditory acuity seemingly grossly normal. CN 9,10 (Glossopharyngeal/Vagus): The uvula is midline, the palate elevates symmetrically. CN 11 (spinal access): Normal sternocleidomastoid and trapezius strength. CN 12 (Hypoglossal): The tongue is midline. No atrophy or fasciculation.
MOTOR: Muscle Strength: 5/5. Muscle Tone: No hypotonia/atonia/hypertonia. Muscle bulk: Normal.
REFLEXES: Deep tendon reflexes - 2+ and symmetrical in all four extremities, plantar response present B/L, Clonus Absent, Hoffman: Absent, Cross Adductor: Not present.
SENSATION: Intact to light touch, vibration, proprioception, vibration, fine touch
COORDINATION: No tremor, no dysmetria.
GAIT: Mild gait instability.
SPINE: No Spinal Tenderness Appreciated. Neck Movements not painful and Range of motion intact.

**Table 2:** Pertinent Findings and Laboratory Workup.

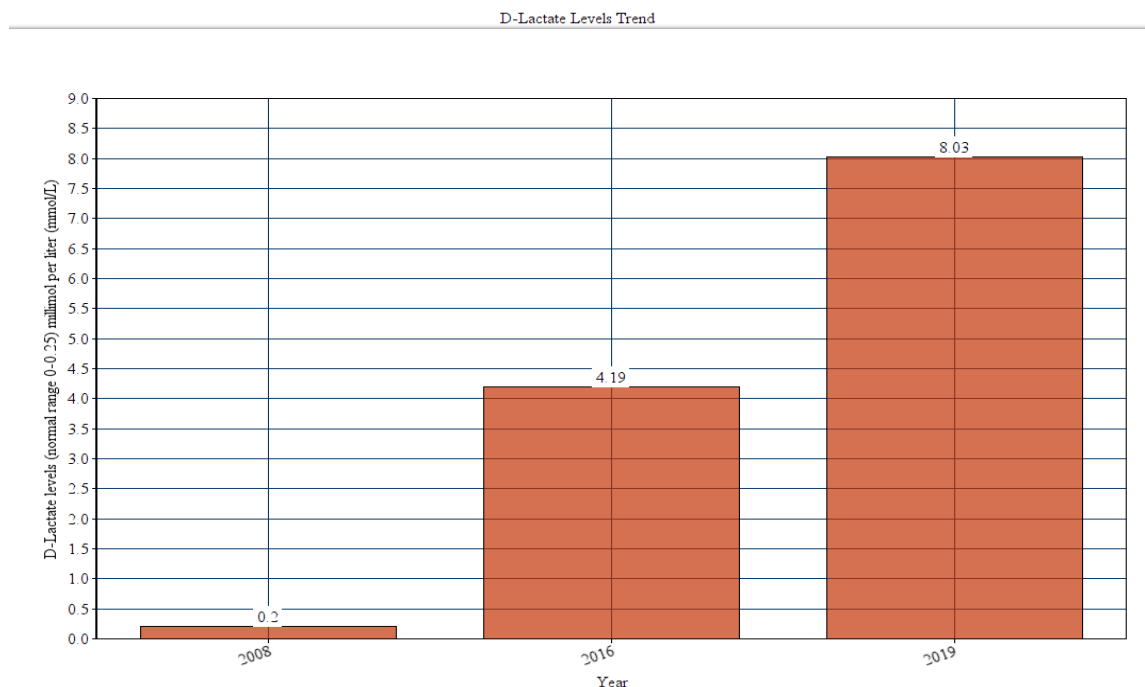
Variables	Values	Normal Range
Vitamin B1 (Thiamine)	153.7	66.5-200 nanomol per liter (nmol/L)
Vitamin B2 (Riboflavin)	177	137-370 microgram / liter ( $\mu\text{g/L}$ )
Vitamin B3 Nicotinic Acid	<5.0	0-5 nanogram/milliliter (ng/mL)
Vitamin B3 Nicotinamide	18.8	5.2-72.1 nanogram/milliliter (ng/mL)
Vitamin B6 (Pyridoxine)	28.8	5.3-46.7) microgram per liter ( $\mu\text{g/L}$ )
D-Lactate	8.03	0-0.2 millimol per liter (mmol/L)
Anion gap	19	5-14
Thyroid-stimulating hormone	3.69	0.3-3.7 milli-international units per liter (mIU/L)
Serum chloride	116	98-108 milliequivalents per liter (mEQ/L)
Serum zinc	73	56-134 microgram / liter ( $\mu\text{g/L}$ )

The mother told the medical team about an episode of confusion and episodes of slurred speech at home. He denies any focal sensory or motor weakness except broad-based gait, which started on the day of the presentation. The patient also denies any urinary or bowel incontinence, vision changes, speech, or swallowing difficulties. Historically, the patient had seen a pediatric neurologist in 2018 when he was weaned off of levetiracetam after a normal electroencephalogram (EEG). Magnetic resonance imaging (MRI) of the brain showed no acute abnormality. The cerebrospinal fluid analysis was also non-contributory. In the past, the patient was diagnosed with a congenital condition of short gut syndrome with barium enema shown in Figure 1.



**Figure 1 [A-E]** Microcolon with gas-filled dilated loops of probable small bowel versus proximal colon and completed bowel obstruction.

The patient was using a percutaneous endoscopic gastrostomy (PEG) tube for feeding and had persistent ileus with chronic constipation. The patient had low bicarbonate levels and low pH of 7.3 in serum. Pediatric gastroenterology team recommended continuing the metronidazole with dextrose 5% in water (D5W) 1,000 milliliter (mL) + sodium bicarbonate 8.4% 150 milliequivalent (mEq) + potassium chloride 20 mEq. The patient took a high calorie, high protein, low carbohydrate diet along with vitamin B12, and zinc therapy. The laboratory workup showed a persistent rising trend of D-lactate levels over the years (Figure 2).



**Figure 2:** Rising Trend of D-lactic Acidosis with Short Bowel Syndrome

Over the years, the patient has been admitted multiple times in the hospital with this condition, with the rising trend observed in D-lactate levels. His sodium levels were high on admission due to dehydration and were normalized after intravenous hydration. The patient had normal pyruvic acid levels. Mentation and anion gap improved after hydration and the patient was discharged with metronidazole for the next three weeks. The patient's gait instability and ataxia improved after one week upon discharge.

## Discussion

Short bowel syndrome (SBS) has an incidence of two persons per million per year. It causes lactic acidosis due to resection of the intestine, such as Roux-en-Y gastric bypass surgery.<sup>1</sup> SBS is defined as surgical resection, congenital disability, or a diseased portion of the small intestine, which results in the inability to maintain nutrient balances on a healthy diet.<sup>2</sup> The small intestine is responsible for most of the digestion and absorption of ingested food.<sup>3</sup> Naturally, if it were to get damaged, the consequences would be dire. One such effect is the accumulation of lactic acid. There are two different optical isomers of lactic acid; D-lactate, which results due to microbial flora in the intestine, and L-lactate produced from glycolysis.<sup>3</sup> The accumulation of lactic acid can result from overproduction or under-excretion of the substrate. There is a wide array of symptoms that patients experience; these include altered mental status, neurological symptoms, ataxia, and slurred speech. These symptoms usually start after a high carbohydrate diet due to malabsorption in a patient with SBS.<sup>4</sup>

The diagnostic criteria for lactic acidosis are a pH level of less than 7.35 and a lactate level higher than 5-6 mM/L.<sup>5</sup> The accumulation of lactate results due to the undigested carbohydrates that reach the colon and are fermented. It can lower the intestinal pH, alter the healthy flora of the region, and cause an overgrowth of species, such as from the lactobacillus family. These

bacteria are the cause of D-lactic acidosis. To date, there is no definitive treatment for lactic acidosis, although recommendations include avoiding antibiotics, taking bicarbonate while maintaining hydration, and following a low carbohydrate diet.

Another way to manage the refractory D-lactic acidosis is by administering insulin, vancomycin, neomycin, or hemodialysis.<sup>6</sup> The report we mentioned is unique because of the refractory and resistant nature of lactobacillus over the year, and the rising trend of D-lactate levels in the body which may lead to end-organ damage and permanent neurological injury. The patient in our reports also falls under the metabolic encephalopathy with anion gap metabolic acidosis with non-contributory serum ammonia, liver, and renal profile. The metabolic encephalopathy occurred as a result of the accumulation of D-lactic acidosis and nutritional deficiency over the years with gastrointestinal problems. The limitation of our study was not collecting the gut microbiota for cultures since the patient was treated clinically based on diagnosis with SBS. There was no concern of seizure or post-ictal confusion during the current presentation with the past medical problem with GTC with antiepileptics weaned off almost two years ago.

The definite management for chronic recurrent D-lactic acidosis leading to encephalopathy is still an area of debate and matter of future research. We conclude that in patients with short gut syndrome and chronic recurrent D-lactic acidosis, supportive care should improve the neurological symptoms and prevent irreparable damage.

## References

1. Buchman AL. Etiology and initial management of short bowel syndrome. *Gastroenterology*. 2006;130(2 Suppl 1):5-15.
2. O'Keefe SJ, Buchman AL, Fishbein TM, Jeejeebhoy KN, Jeppesen PB, Shaffer J. Short bowel syndrome and intestinal failure: consensus definitions and overview. *Clinical Gastroenterology and Hepatology*. 2006;4(1):6-10.
3. Kang KP, Lee S, Kang SK. D-lactic acidosis in humans: review of update. *Electrolyte & Blood Pressure*. 2006;4(1):53-56.
4. Kowlgi NG, Chhabra L. D-lactic acidosis: an underrecognized complication of short bowel syndrome. *Gastroenterol Res Pract*. 2015;2015:476215.
5. Cross SA, Callaway CW. D-lactic acidosis and selected cerebellar ataxias. *Mayo Clin Proc*. 1984;59:202-5.
6. Halperin ML, Kamel KS. D-lactic acidosis: turning sugar into acids in the gastrointestinal tract. *Kidney Int*. 1996;49:1-8.