

2020

## Case Report on Leiomyosarcoma of the Vulva: A Rare Pathology

Samantha A. Smith, Nadim Bou Zgheib, Andrea M. Vallejos, and Jonathan D. Cuda

### Author Affiliations

Samantha A. Smith (*Marshall University Joan C. Edwards School of Medicine, Huntington, West Virginia*)

Nadim Bou Zgheib (*Marshall University Joan C. Edwards School of Medicine, Huntington, West Virginia*)

Andrea M. Vallejos (*Valley Health Systems OB/GYN, Huntington, West Virginia*)

Jonathan D. Cuda (*Marshall University Joan C. Edwards School of Medicine, Huntington, West Virginia*)

### Corresponding Author


Samantha A. Smith

Marshall University Joan C. Edwards School of Medicine

Huntington, West Virginia

Email: [smith2028@marshall.edu](mailto:smith2028@marshall.edu)

Follow this and additional works at: <https://mds.marshall.edu/mjm>

 Part of the [Medical Pathology Commons](#), [Obstetrics and Gynecology Commons](#), and the [Oncology Commons](#)



This work is licensed under a [Creative Commons Attribution 4.0 License](#).

## Recommended Citation

Smith, Samantha A.; Bou Zgheib, Nadim; Vallejos, Andrea M.; and Cuda, Jonathan D. (2020) "Case Report on Leiomyosarcoma of the Vulva: A Rare Pathology," *Marshall Journal of Medicine*: Vol. 6: Iss. 3, Article 6.

DOI: [10.33470/2379-9536.1294](https://doi.org/10.33470/2379-9536.1294)

Available at: <https://mds.marshall.edu/mjm/vol6/iss3/6>

DOI: [10.33470/2379-9536.1294](https://doi.org/10.33470/2379-9536.1294)

Open Access |

## Case report on leiomyosarcoma of the vulva: a rare pathology

### Abstract

Leiomyosarcoma (LMS) of the vulva is rare. However it is the most common histologic subtype of vulvar sarcoma, accounting for approximately 1% of all vulvar malignancies.<sup>1-8</sup> Whether genetics and epigenetics play a role in pathogenesis is unclear.<sup>1</sup> The tumor is slow-growing with non-specific symptoms, has high metastatic potential, and follows a bimodal age distribution.<sup>1-8</sup> Diagnosis and prognosis are based upon immunohistochemical expression and criteria from early literature.<sup>1,3,5-7</sup> The most common therapeutic approach involves radical vulvectomy with lymph node resection. The value of adjuvant chemotherapy and radiation remains unknown.<sup>1,3,5-8</sup> Our case describes a 46-year-old Caucasian gravida 2, para 2 (G2P2) female with LMS of the left labia.

### Keywords

Leiomyosarcoma, Vulva, Immunohistochemical

### Background

Sarcomas of the vulva are relatively rare, accounting for only 1-3% of all vulvar malignancies.<sup>1-8</sup> They are of mesenchymal origin and constitute a vast array of histologic subtypes.<sup>1,5</sup> Reported histologic variants include leiomyosarcoma, rhabdomyosarcoma, liposarcoma, angiosarcoma, malignant peripheral nerve sheath tumor, malignant fibrous histiocytoma, and epithelioid sarcoma.<sup>1,3,6</sup>

Of the above, leiomyosarcoma (LMS) is the most common sarcoma subtype to involve the vulva. It follows a bimodal age distribution with an average age of 30-40 years old. The first mode represents ages 20-30.<sup>1,3,5,6</sup> Cases within this age group are becoming increasingly prevalent, and whether this has any correlation with reproductive hormones is in question.<sup>1,5</sup> The second mode affects a more elderly population.<sup>1,2,8</sup>

The tumor is slow-growing with non-specific symptoms and has high metastatic potential.<sup>2,3,8</sup> Tumors may originate from the smooth muscle of blood vessels, tissue of the round ligament, myoepithelium of Bartholin glands, or arrector-pili muscles.<sup>1,3,5</sup> Pathogenesis related to genetic predisposition and lifestyle are speculative due to the prevalence of LMS in western countries.<sup>1</sup> The following case describes a 46-year-old female with LMS of the left labia. The rarity of LMS and this patient's deviation from the usual bimodal age distribution makes this case of particular interest.

### Case report

Our case is a 46-year-old Caucasian female, gravida 2, para 2, who presented with a painless mass of the left labia majora situated between the left Bartholin gland area and the posterior fourchette and measuring around three cm with a solid consistency. The patient's medical history

included menarche at age ten and menopause at age 39 following a partial hysterectomy for menorrhagia. Family history included primary relatives with breast cancer and melanoma. Several distant relatives were also diagnosed with breast cancer, cervical cancer, and prostate cancer. Genetic testing for the presence of alterations in 67 different cancer predisposition genes associated with hereditary cancer syndromes only revealed a variant of unknown significance, despite her extensive family history of cancer. She denied any history of smoking or previous contact with hazardous materials.

She underwent an excisional procedure of her left vulvar mass measuring a 3 x 2.5 cm with a solid consistency. The pathology showed a mitotically active malignant spindle cell neoplasm with smooth muscle actin and desmin expression (Figures 1-3). Tumor cells were negative for cytokeratin AE1/AE3, p40, S100, myogenin, myo-D1, caldesmon, CD34, STAT-6, and TLE1. The histologic findings in conjunction with the immunohistochemical profile supported a diagnosis of leiomyosarcoma with positive margins.

Following the initial excision, a PET-CT scan revealed no evidence of metastatic disease or pulmonary nodules. Uptake was only present at the level of the labia. Further surgery was indicated to excise the residual disease. A left partial radical vulvectomy was performed and the vulvar scar was removed with 1-2 cm of margin down to the endopelvic fascia. No evidence of macroscopic disease was noted. However, the pathology revealed few foci of residual leiomyosarcoma associated with procedural scar and persistently positive margins. The final pathology was consistent with FIGO stage 1B vulvar leiomyosarcoma.

She was given eight weeks to recover from this procedure and then underwent a third surgical procedure which included examination under anesthesia, bilateral inguinofemoral lymph node dissection, and posterior radical vulvectomy. Specimens obtained included bilateral inguinofemoral lymph nodes and a radical excision of the posterior vulva and scar with 1-2 cm margins down to endopelvic fascia. No macroscopic evidence of inguinofemoral lymph node involvement was noted during the operation. Pathology revealed a focus of residual leiomyosarcoma with negative margins and no evidence of regional lymph node disease. The patient's postoperative course was uncomplicated.

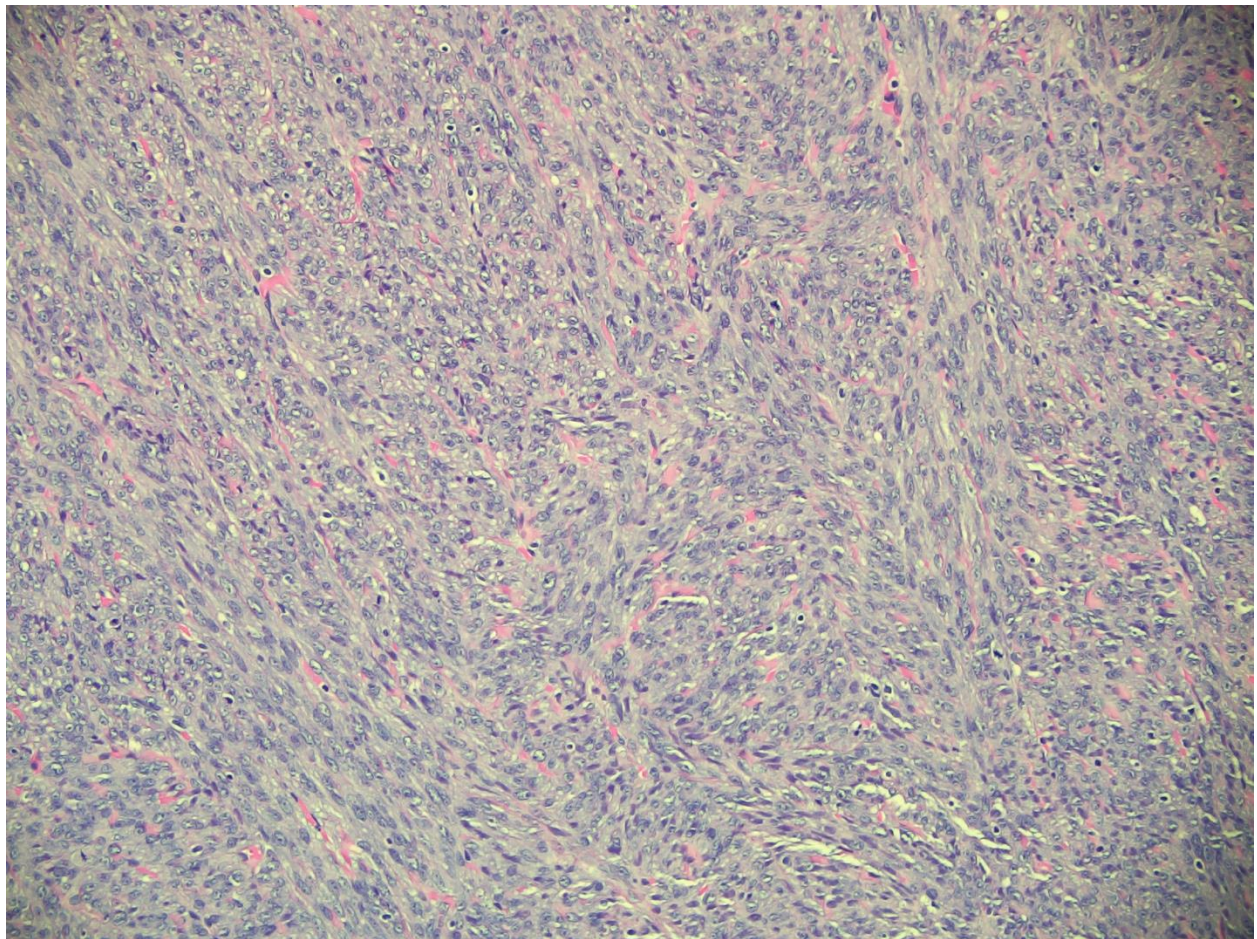


Figure 1. Cellular malignant spindle cell proliferation arranged in intersecting fascicles (200x magnification).

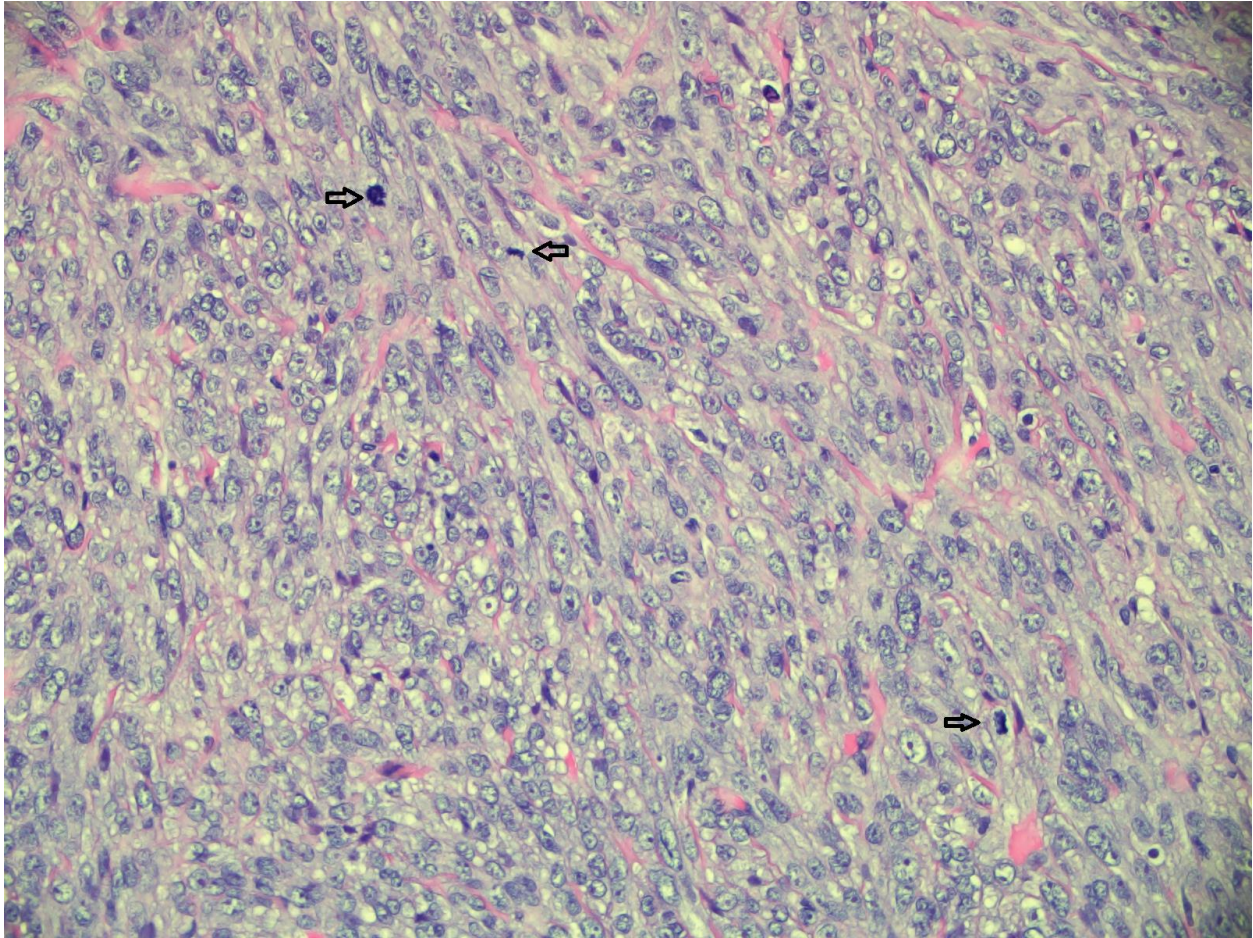


Figure 2. Tumor cells demonstrate moderate cytologic atypia in this high power field. Arrows mark three mitotic figures (400x magnification).

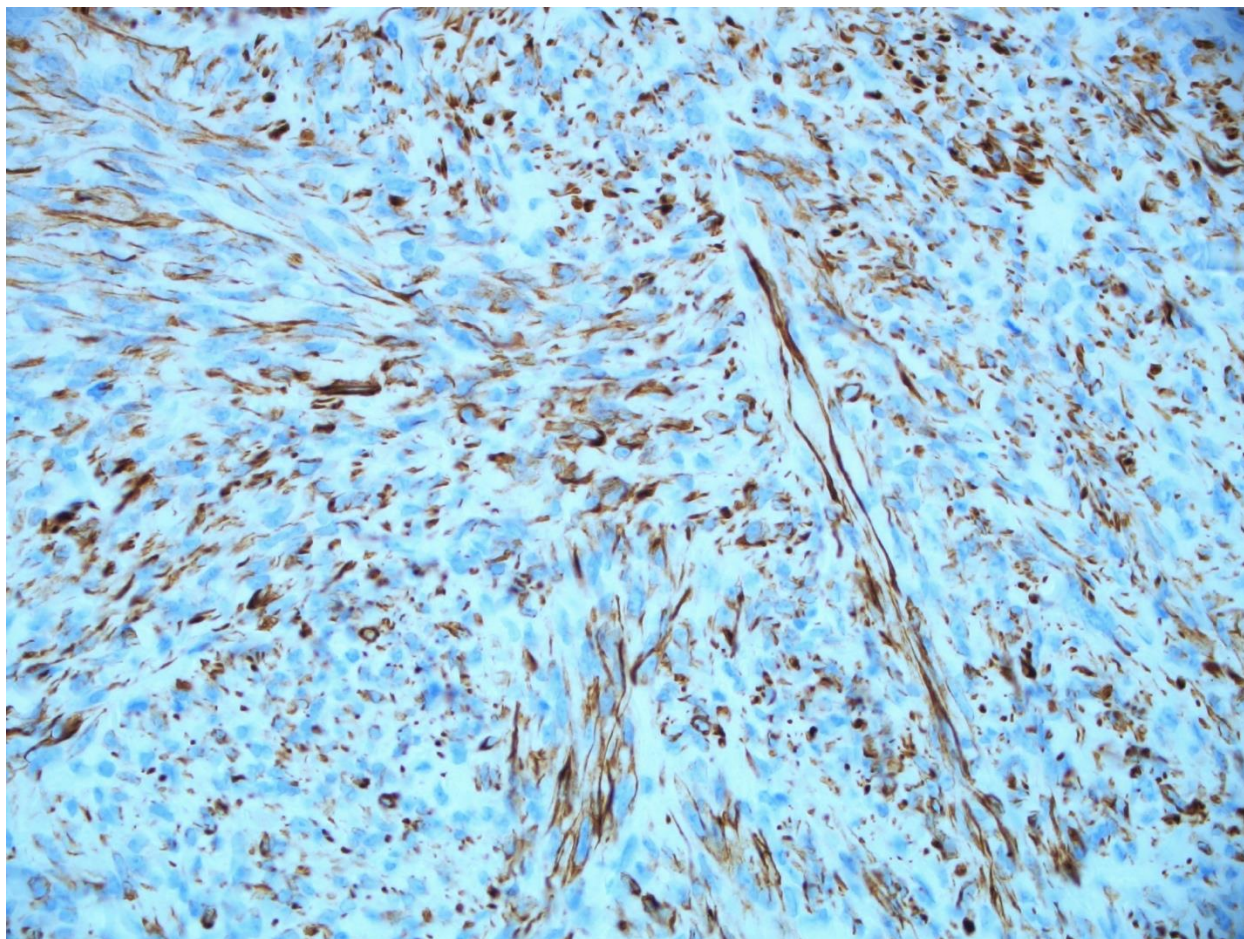


Figure 3. Spindled tumor cells show immunoreactivity for Desmin (400x magnification).

## Discussion

Onset of vulvar LMS is often insidious. It may arise from an existing leiomyoma, but most are *de novo*.<sup>8</sup> LMS presents clinically as a painless, asymptomatic mass in early stages. The mass is solid, ranging between 1.5 to 16 cm, and may precipitate pain, bleeding, and voiding difficulty with increased infiltration and size.<sup>1,3,5,6</sup> The most common localization is the labia majora, followed by Bartholin gland, clitoris, and labia minora.<sup>3,5,6,7,8]</sup> Due to the clinical presentation, LMS is often mistaken for a more benign pathology: Bartholin gland cyst, leiomyoma, lipoma, fibroma, infectious granuloma, or myoma.<sup>2,3,5,6,7</sup> Misdiagnosis delays treatment and may provide potential for metastatic spread, so considering LMS is always important.<sup>1,3,6,7</sup>

Diagnosis of LMS requires at least three of four criteria, according to Nielsen et al.: (1) infiltrative margins, (2) diameter  $\geq 5$  cm, (3) moderate-to-severe (grade 2 or 3) cytologic atypia, or (4)  $\geq 5$  mitotic figures per 10 high-power fields.<sup>1,3,5-7</sup> Patients with one or two of the above criteria meet the diagnoses of leiomyoma and atypical leiomyoma, respectively.<sup>3,6,7</sup> Recent evidence suggests uterine criteria for LMS is equally sensitive and more specific for classifying vulvovaginal smooth muscle tumors according to patient outcome.<sup>9</sup> In this study, tumor necrosis was also assessed as a valuable feature for determining malignant potential.

Prognostication is based on mitotic activity, tumor size and grade, pattern of tumor interface, necrosis, and metastatic spread.<sup>1,3,6,8,9</sup>

Muscle immunohistochemical markers such as desmin and actin are expressed in LMS, as exhibited by our patient case. Other markers which may be expressed include HHF-35, caldesmon, and estrogen receptor (ER). Ki-67 proliferation index is often elevated. Primary therapeutic recommendation is complete surgical excision of the lesion with negative margins, although there is no consensus on surgical approach.<sup>1,3,5-8</sup> The most common approach involves radical vulvectomy with occasional lymph node resection, which was performed in this case.<sup>3</sup> The value of lymphadenectomy in vulvar leiomyosarcoma remains questionable and there is no data supporting the routine performance of lymphadenectomy in these cases.

Some case reports state that low-grade tumors may require only wide local excision of the lesion with negative margins.<sup>3,5</sup> Other cases describe the importance of radiation following radical vulvectomy for tumors > 5 cm.<sup>3,5,6</sup> Additional measures may include radiation or chemotherapy at the discretion of the oncologist. Necessity of adjuvant therapy is unknown at this time, although it may decrease risk of relapse and further metastatic spread.<sup>3,5,7</sup> Recurrence and metastases have been reported following radical vulvectomy with lymph node resection.<sup>8</sup>

## Conclusion

Leiomyosarcoma (LMS) is rare and insidious. Incorporating this pathology into a differential diagnosis is key when evaluating subcutaneous vulvar lesions. Established diagnostic criteria and immunohistochemical stains aid in proper identification. Early surgical excision with negative margins and close follow-up decreases but does not eliminate risk of metastasis and recurrence of LMS. Further study is needed to better prognosticate and adjunctively treat this potentially aggressive tumor.

## References

1. Chokoeva A, Tchernev G, Cardoso J et al. Vulvar sarcomas: hort guideline for histopathological recognition and clinical management. Part 1. *International Journal of Immunopathology and Pharmacology*. 2015;28(2):168-177.
2. Sameeta F, Haque M, Akbar S, Zotto V, Kahn A. 2019. Leiomyosarcoma: a rare tumor of the vulva. *American Journal of Clinical Pathology*. 2019;152(Supplement 1):S46-S46.
3. Teramae M, Fukuda T, Imai K, Yamauchi M, Hashiguchi Y, Ichimura T, Yasui T, Sumi T. Leiomyosarcoma of the vulva: a case report. *International Journal of Reproduction, Contraception, Obstetrics and Gynecology*. 2014;3(1):225-228.
4. Suh M, Park D. Leiomyosarcoma of the vagina: a case report and review from the literature. *Journal of Gynecologic Oncology*. 2008;19(4):261.
5. Lösch A, Joura EA, Stani J et al. Leiomyosarcoma of the vulva. A case report. *Journal of Reproductive Medicine*. 2001;46:609–612.
6. Salehin D, Haugk C, William M et al. Leiomyosarcoma of the vulva. *European Journal of Gynaecological Oncology*. 2012;33:306–308.
7. Nielsen GP, Rosenberg AE, Koerner FC, Young RH, Scully RE. Smooth-muscle tumors of the vulva. *American Journal of Surgical Pathology*. 1996: 20(7):779-793.
8. Shankar S, Todd PM, Rytina E et al. Leiomyosarcoma of the vulva. *Journal of the European Academy of Dermatology and Venereology*. 2006;20(1):116–117.
9. Sayeed S, Xing D, Jenkins SM, Weisman PS et al. Criteria for risk stratification of vulvar and vaginal smooth muscle tumors: an evaluation of 71 cases comparing proposed classification systems. *American Journal of Surgical Pathology*. 2018;42(1):84-94.