

University of Groningen

Three cases of non-atopic hyperkeratotic hand eczema treated with dupilumab

Loman, Laura; Diercks, Gilles F H; Schuttelaar, Marie L A

Published in:
CONTACT DERMATITIS

DOI:
[10.1111/cod.13693](https://doi.org/10.1111/cod.13693)

IMPORTANT NOTE: You are advised to consult the publisher's version (publisher's PDF) if you wish to cite from it. Please check the document version below.

Document Version
Publisher's PDF, also known as Version of record

Publication date:
2020

[Link to publication in University of Groningen/UMCG research database](#)

Citation for published version (APA):

Loman, L., Diercks, G. F. H., & Schuttelaar, M. L. A. (2020). Three cases of non-atopic hyperkeratotic hand eczema treated with dupilumab. *CONTACT DERMATITIS*. <https://doi.org/10.1111/cod.13693>

Copyright

Other than for strictly personal use, it is not permitted to download or to forward/distribute the text or part of it without the consent of the author(s) and/or copyright holder(s), unless the work is under an open content license (like Creative Commons).

Take-down policy

If you believe that this document breaches copyright please contact us providing details, and we will remove access to the work immediately and investigate your claim.

Downloaded from the University of Groningen/UMCG research database (Pure): <http://www.rug.nl/research/portal>. For technical reasons the number of authors shown on this cover page is limited to 10 maximum.

Three cases of non-atopic hyperkeratotic hand eczema treated with dupilumab

Laura Loman¹  | Gilles F.H. Diercks²  | Marie L.A. Schuttelaar¹ 

¹Department of Dermatology, University of Groningen, University Medical Center Groningen, Groningen, The Netherlands

²Department of Pathology, University of Groningen, University Medical Center Groningen, Groningen, The Netherlands

Correspondence

Marie L.A. Schuttelaar, Department of Dermatology, University Medical Center Groningen, P.O. Box 30.001, 9700 RB Groningen, The Netherlands.

Email: m.l.a.schuttelaar@umcg.nl

KEYWORDS: dupilumab, hand dermatitis, hand eczema, hyperkeratotic hand eczema, treatment

Dupilumab, a monoclonal antibody inhibiting interleukin (IL)-4 and IL-13 signaling, is currently approved for the treatment of atopic dermatitis (AD). Effective treatment of hand eczema with dupilumab has been reported previously in case series, two small retrospective cohorts, and one prospective observational study including atopic, irritant and vesicular hand eczema subgroups.¹⁻⁴ However, the effect of dupilumab on isolated hyperkeratotic hand eczema (HHE) has not yet been described.

METHODS

Three patients with moderate to severe HHE were treated with dupilumab 600 mg subcutaneously on day 1, followed by 300 mg subcutaneously every 14 days. A minimum washout of topical treatment of 2 weeks was applied. All patients underwent patch testing and no relevant contact allergies were detected. Concomitant fungal infections were ruled out and the diagnosis HHE was confirmed by histopathology.

Age, sex, disease duration, occupation, smoking status, treatment history, exposure to irritants, atopic comorbidities, and specific immunoglobulin E (IgE) inhalant allergens were assessed at baseline. Therapeutic response was evaluated every 4 weeks up to 16 weeks of treatment by the hand eczema severity index (HECSI),⁵ the photographic guide,⁶ clinical photographs, Quality of Life in Hand Eczema Questionnaire (QOLHEQ),⁷ and the weekly average of the number rating scale (NRS) for pain and pruritus (0–10, with 10 being the worst pruritus/pain).

RESULTS

Two males and one female, of respectively 65, 47 and 65 years of age, were treated (Appendix S1). All of them were previously treated with ultra-potent topical corticosteroids and at least two different systemic therapies, alitretinoin, among others. Case 1 had an inadequate response to alitretinoin, Cases 2 and 3 were intolerant to alitretinoin. None of the patients had a history of AD. Case 1 was a current smoker with 88 pack-years and experienced occupational exposure to irritants as a bricklayer by friction and wearing gloves during part of the day. All lesional skin biopsies presented identical histopathologic features (Appendix S2).

Two patients (case 2 and 3) had already major improvement after 4 weeks and symptoms cleared completely after 16 weeks of treatment. Case 1 noticed minimal clinical improvement, however, there was an improvement in itch and quality of life (Figure 1).

DISCUSSION

The pathogenesis of HHE remains largely unclear. A previous study on the gene and protein expression of hand eczema, including 15 patients with chronic hyperkeratotic-fissured hand eczema showed, among others, increased proliferative cell activity indicated by Ki-67, and a decreased expression of the terminal differentiation marker loricrin in palmar lesional skin biopsies, which was normalised following alitretinoin treatment.⁸ Another study showed an upregulation in keratinocyte host defence mechanism proteins

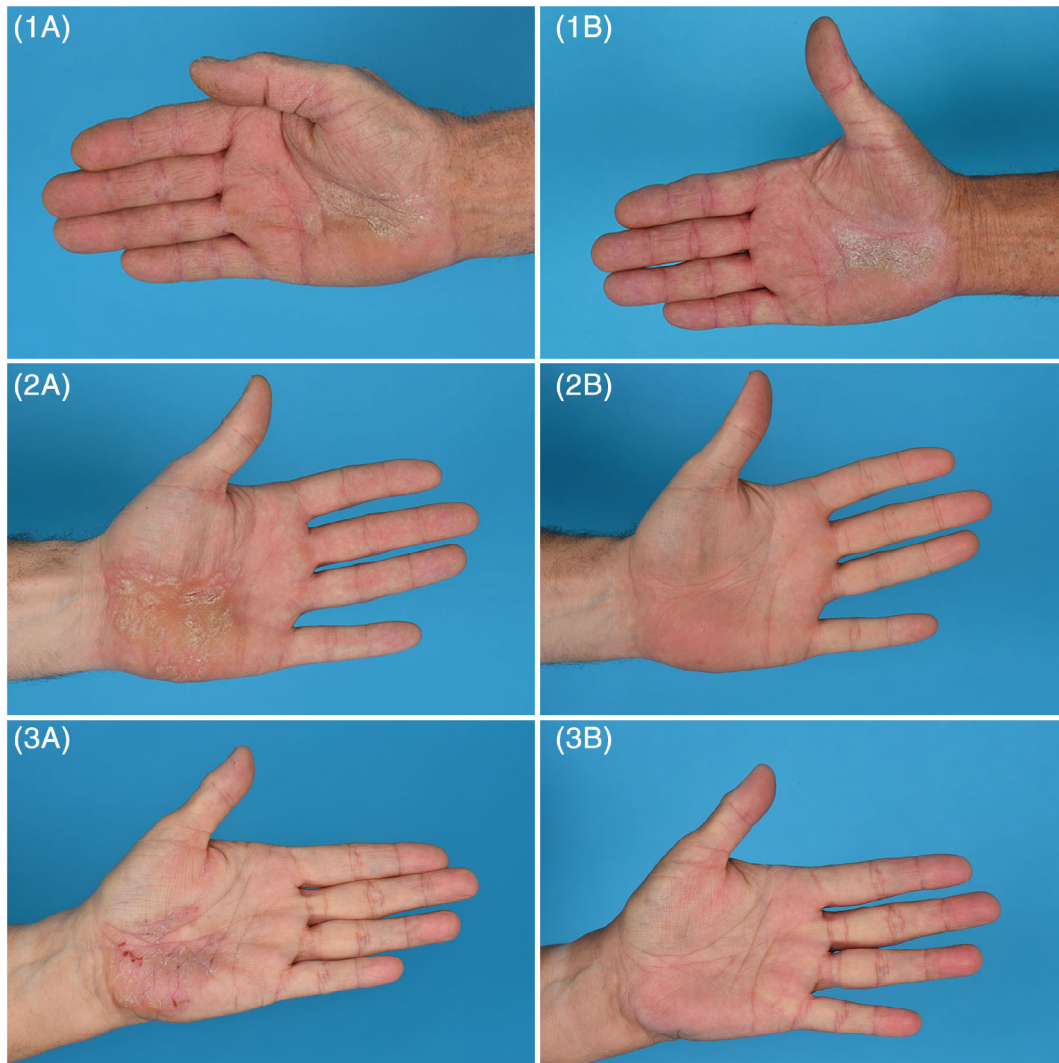


FIGURE 1 Clinical improvement of the three cases after 16 weeks of dupilumab treatment. (1A, 2A,3A) case 1, 2 and 3 at baseline, (1B, 2B, 3B) case 1, 2, 3 after 16 weeks of treatment

(S100A7/S100A8/S100A9) in six patients with chronic hand eczema, including different subtypes, compared to healthy control skin.⁹ A study on protein expression in seven patients with HHE, showed also increased proliferative cell activity indicated by Ki-67 and a strong upregulation of keratin (K)16 with, in addition, a decreased expression of loricrin in lesional palmar skin compared to perilesional skin and healthy control skin.¹⁰ In patients with AD treated with dupilumab a significantly reduced gene expression of K16 and MKi67, a reduced expression of S100As genes, and an increase in loricrin expression is seen after treatment.¹¹ Therefore, the good effect of dupilumab on HHE could be explained by the similarities in the epidermal pathology in patients with AD and HHE, including epidermal hyperproliferation and an impaired epidermal barrier.

Lack of clinical improvement in Case 1 might be explained by his occupational activities as a bricklayer, whereby hand eczema is also caused by exposure to irritants and friction. To date, no consensus has been reached on the classification system of hand eczema. It depends on the classification system if HHE is classified as an

endogenous subtype without identifiable cause¹² or if it could have contributing identifiable causes such as exposure to irritants.¹³ However, only one case report published the successful dupilumab treatment of occupational irritant hand dermatitis¹⁴ However, it is possible that the role of different cytokines (including IL-4) is affected by several other factors, such as the identity of the topical irritant or to what extent the irritant factor contribute to the etiology. Another contributing factor to the lack of clinical effect could be that the patient was smoking.

Previous literature has showed successful results of dupilumab on hand eczema in patients treated for AD¹ and in individuals with isolated vesicular hand eczema.^{2,4} In view of the good effect of dupilumab on HHE as well, it might be hypothesized that, despite the differences in phenotype, there are similarities in endotype and underlying pathogenesis with an IL-4/IL-13 driven inflammation between different subtypes of hand eczema. Therefore, dupilumab could be considered as an effective treatment of severe hand eczema, regardless of subtype. This should be investigated in future studies.

CONFLICTS OF INTEREST

Dr Schuttelaar is a member of advisory boards and received consultancy fees and fees for arranging education from Sanofi-Genzyme and Regeneron. The other authors declare no conflicts of interest.

AUTHOR CONTRIBUTIONS

Laura Loman: Conceptualization; data curation; formal analysis; investigation; methodology; project administration; visualization; writing-original draft; writing-review and editing. **Gilles Diercks:** Visualization; writing-review and editing. **Marie Schuttelaar:** Conceptualization; formal analysis; investigation; methodology; supervision; writing-original draft; writing-review and editing.

ORCID

Laura Loman  <https://orcid.org/0000-0003-2731-9284>

Gilles F.H. Diercks  <https://orcid.org/0000-0001-8053-216X>

Marie L.A. Schuttelaar  <https://orcid.org/0000-0002-0766-4382>

REFERENCES

- Oosterhaven JAF, Voorberg AN, Romeijn GLE, de Bruin-Weller MS, Schuttelaar MLA. Effect of dupilumab on hand eczema in patients with atopic dermatitis: an observational study. *J Dermatol*. 2019;46(8):680-685.
- Waldman RA, DeWane ME, Sloan B, Grant-Kels JM, Lu J. Dupilumab for the treatment of dyshidrotic eczema in 15 consecutive patients. *J Am Acad Dermatol*. 2020;82(5):1251-1252.
- Lee N, Chipalkatti N, Zancanaro P, Kachuk C, Dumont N, Rosmarin D. A retrospective review of Dupilumab for hand dermatitis. *Dermatology*. 2019;235(3):187-188.
- Halling AS, Zachariae C, Thyssen JP. Severe treatment-resistant acute and recurrent vesicular chronic hand eczema successfully treated with dupilumab. *Contact Dermatitis*. 2020;83(1):37-38.
- Held E, Skoet R, Johansen JD, Agner T. The hand eczema severity index (HECSI): a scoring system for clinical assessment of hand eczema. A study of inter- and intraobserver reliability. *Br J Dermatol*. 2005;152(2):302-307.
- Coenraads PJ, Van Der Walle H, Thestrup-Pedersen K, et al. Construction and validation of a photographic guide for assessing severity of chronic hand dermatitis. *Br J Dermatol*. 2005;152(2):296-301.
- Oosterhaven JAF, Ofenloch RF, Schuttelaar MLA. Validation of the Dutch quality of life in hand eczema questionnaire (QOLHEQ). *Br J Dermatol*. 2019;183(1):86-95.
- Kumari V, Timm K, Kuhl AA, Heine G, Worm M. Impact of systemic alitretinoin treatment on skin barrier gene and protein expression in patients with chronic hand eczema. *Br J Dermatol*. 2016;175(6):1243-1250.
- Molin S, Merl J, Dietrich KA, et al. The hand eczema proteome: imbalance of epidermal barrier proteins. *Br J Dermatol*. 2015;172(4):994-1001.
- Politiek K, Loman L, Pas HH, et al. Hyperkeratotic hand eczema: eczema or not? *Contact Dermatitis*. 2020;83(3):196-205.
- Guttman-Yassky E, Bissonnette R, Ungar B, et al. Dupilumab progressively improves systemic and cutaneous abnormalities in patients with atopic dermatitis. *J Allergy Clin Immunol*. 2019;143(1):155-172.
- Agner T, Aalto-Korte K, Andersen KE, et al. Classification of hand eczema. *J Eur Acad Dermatol Venereol*. 2015;29(12):2417-2422.
- Menné T, Johansen JD, Sommerlund M, Veien NK. Hand eczema guidelines based on the Danish guidelines for the diagnosis and treatment of hand eczema. *Contact Dermatitis*. 2011;65(1):3-12.
- Zhu GA, Honari G, Ko JM, Chiou AS, Chen JK. Dupilumab for occupational irritant hand dermatitis in a nonatopic individual: a case report. *JAAD Case Rep*. 2020;6(4):296-298.

SUPPORTING INFORMATION

Additional supporting information may be found online in the Supporting Information section at the end of this article.

How to cite this article: Loman L, Diercks GFH, Schuttelaar MLA. Three cases of non-atopic hyperkeratotic hand eczema treated with dupilumab. *Contact Dermatitis*. 2020;1-3. <https://doi.org/10.1111/cod.13693>