



# Osteonecrosis of the Jaw during Lenvatinib Therapy: A Case Report Based on Surgical Management

著者名	UDAGAWA Gen, OKAMOTO Toshihiro, KAIBUCHI Nobuyuki, SANGU Noriko, KAGAWA Chie, ANDO Tomohiro
journal or publication title	Tokyo Women's Medical University Journal
volume	3
page range	78-82
year	2019-12-20
URL	<a href="http://hdl.handle.net/10470/00032483">http://hdl.handle.net/10470/00032483</a>

doi: <https://doi.org/10.24488/twmuj.2019002>|[10.24488/twmuj.2019002](https://doi.org/10.24488/twmuj.2019002)

## Osteonecrosis of the Jaw during Lenvatinib Therapy: A Case Report Based on Surgical Management

Gen Udagawa,<sup>1,2</sup> Toshihiro Okamoto,<sup>1,2</sup> Nobuyuki Kaibuchi,<sup>2</sup>  
Noriko Sangu,<sup>2</sup> Chie Kagawa,<sup>2</sup> and Tomohiro Ando<sup>2</sup>

<sup>1</sup>Department of Dentistry and Oral Surgery, Tokyo Women's Medical University Yachiyo Medical Center, Chiba, Japan

<sup>2</sup>Department of Oral and Maxillofacial Surgery, School of Medicine, Tokyo Women's Medical University, Tokyo, Japan

(Accepted September 17, 2019)

(Advance Publication by J-STAGE November 25, 2019)

Lenvatinib is a molecular targeted drug used in the treatment of patients with unresectable thyroid cancer. We present a case of medication-related osteonecrosis of the jaw (MRONJ), which occurred in a patient receiving lenvatinib therapy and which was treated by surgical management. The objectives of this paper are to highlight the possibility of MRONJ being associated with lenvatinib and to accumulate knowledge regarding the management and treatment of MRONJ associated with antiangiogenic drugs. The patient's past medical history included thyroid follicular carcinoma with multiple bone metastasis diagnosed in 2013. Lenvatinib was used on the patient in July 2015 for the treatment of thyroid follicular carcinoma. Three months after the start of the lenvatinib drug holiday, a sequestrectomy involving the extraction of the lower right canine and upper left first premolar was performed under general anesthesia. The patient maintained lenvatinib therapy and when a follow-up was made five months after sequestrectomy, the wound showed complete mucosal healing. Lenvatinib is related to MRONJ and its developmental mechanism might be caused by inhibition of angiogenesis targeting vascular endothelial growth factor receptor.

**Key Words:** MRONJ, lenvatinib, antiangiogenic drug, drug holiday

### Introduction

Lenvatinib is a molecular targeted drug used in the treatment of patients with unresectable thyroid cancer. It acts by inhibiting the multiple receptor tyrosine kinases, targeting vascular endothelial growth factor receptors, fibroblast growth factor receptors, and platelet growth factor receptor  $\alpha$ .<sup>1,2</sup> Currently, various molecular targeted drugs have been developed and put into practical use for the clinical management of unresectable cancers. More

than ten years have passed since the first reported bisphosphonate-related osteonecrosis of the jaw (BRONJ) case in 2003.<sup>3</sup> Afterwards, denosumab-related osteonecrosis of the jaw (DRONJ) was also reported.<sup>4</sup> Although denosumab has entirely different mechanisms in preventing osteoclast-mediated bone resorption from the bisphosphonates, osteonecrosis of the jaw (ONJ) cases have also been described in patients taking denosumab at approximately the same frequency as BRONJ.<sup>5,6</sup>

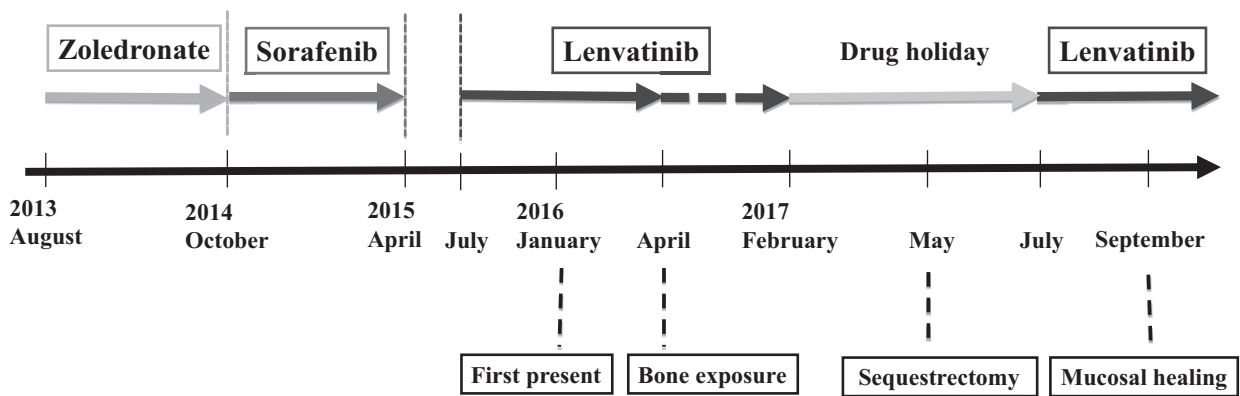
The American Association of Oral Maxillofacial Sur-

---

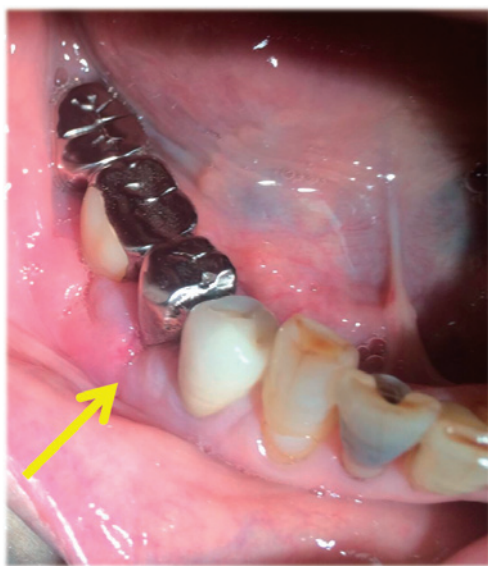Corresponding Author: Gen Udagawa, Department of Dentistry and Oral Surgery, Tokyo Women's Medical University Yachiyo Medical Center, 477-96 Oowada-Shinden, Yachiyo-shi, Chiba 276-8524, Japan. [udagawa.gen@twmu.ac.jp](mailto:udagawa.gen@twmu.ac.jp)

doi: 10.24488/twmuj.2019002

Copyright © 2019 Society of Tokyo Women's Medical University. This is an open access article distributed under the terms of Creative Commons Attribution License (CC BY), which permits unrestricted use, distribution, and reproduction in any medium, provided the original source is properly credited.



**Figure 1** Schematic timeline of medication history and oral symptoms.



**Figure 2** An intraoral finding during the first inspection. A dental fistula on the buccal surface of the lower right premolar region (indicated by an arrow).

gery (AAOMS) defined medication-related osteonecrosis of the jaw (MRONJ) to accommodate the growing number of osteonecrosis cases involving the maxilla and mandible associated with other antiresorptive and antiangiogenic therapies.<sup>7</sup> Recent reports have demonstrated that molecular targeted drugs have the potential to contribute to the development of ONJ, but reported cases of MRONJ are insufficient.<sup>8-13</sup> The long-term side effects of new molecular targeted drugs should be explored.

The objectives of this paper are to highlight the possibility of MRONJ being associated with lenvatinib and to accumulate knowledge regarding the management and treatment of MRONJ associated with antiangiogenic drugs. We present a case of MRONJ in a patient receiv-

ing lenvatinib therapy which was successfully treated by surgical management.

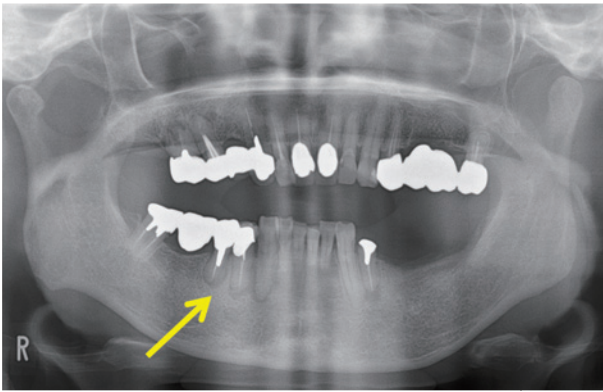
### Case report

A 62-year-old woman presented to the Department of Oral and Maxillofacial Surgery at Tokyo Women's Medical University Hospital with complaints of swelling and pain of gingiva involving the lower right first and second premolar region in January 2016. The patient's past medical history included thyroid follicular carcinoma with multiple bone metastasis diagnosed in 2013, postoperative treatment of sigmoid colon cancer in 2015, and hypertension. The patient had been treated with lenvatinib in July 2015 for the thyroid follicular carcinoma. Furthermore, the patient had been treated once with zoledronate from August 2013 to October 2014 and with sorafenib from October 2014 to April 2015. There was no history of radiation therapy on the head and neck region (**Figure 1**). Approximately fifteen months have passed since the start of the lenvatinib treatment.

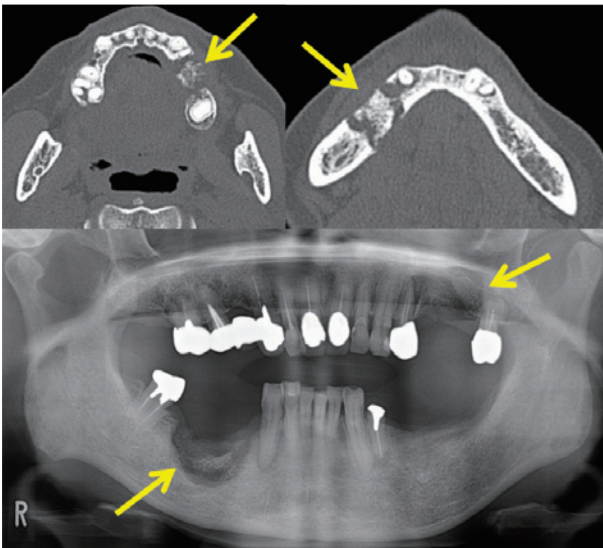
Upon physical examination, there was neither facial swelling or neck lymphadenopathy.

Examination of the oral cavity revealed a dental fistula on the buccal surface of the lower right premolar region, but there was no obvious pus discharge (**Figure 2**). This lesion had a swelling of gingiva and was painful on palpation. Panoramic radiograph examination revealed the presence of radiolucencies around the tooth roots of the lower right premolars and canine (**Figure 3**).

Three months after the initial presentation, exposed bone and pus discharge were observed in the left maxilla.



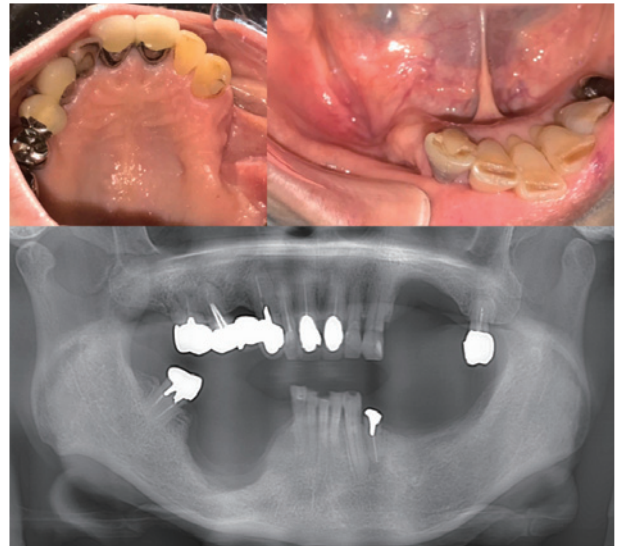
**Figure 3** A panoramic radiograph revealed the presence of radiolucencies around tooth roots of the lower right premolars and canine (indicated by an arrow).



**Figure 4** Computed tomography (CT) images and the panoramic radiograph of extensive osteolysis with sequestrum in the right mandible and left maxilla (indicated by arrows).

Five months after the bone exposure appearance, the patient presented to our department for acute swelling and pain of the right mandible. The patient's oncologist had suspended the lenvatinib therapy until the patient could be dentally cleared.

Under local anesthesia, extraction of the lower right first and second premolars was performed and the necrotic bone parts surrounding the premolars were removed. The lenvatinib therapy restarted one month later. However, due to the exacerbation of swelling and pus discharge in the right mandible lesion, it was suspended again. Three months after the drug holiday, computed tomography (CT) scan revealed extensive osteolysis with



**Figure 5** Intraoral findings and a panoramic radiograph six months after tumor resection. The mucosa is healed without bone exposure.

sequestrum in the right mandible and left maxilla (**Figure 4**). Sequestrectomy involving the extraction of the lower right canine and upper left first premolar was performed under general anesthesia. Two months post-operation, the lenvatinib therapy was restarted. The patient has maintained the lenvatinib therapy and when a follow-up was made four months after the sequestrectomy, the wound showed complete mucosal healing (**Figure 5**).

## Discussion

AAOMS defines MRONJ as a mucosal lesion of the maxillofacial region with necrotic bone exposure. This exposure should be at least eight weeks old and occur in patients receiving antiresorptive or antiangiogenic agents.<sup>7</sup> The patient here had necrotic bone exposure for more than eight weeks and had no history of radiation therapy on the head and neck region.

Therefore, the case was considered as MRONJ. Furthermore, the staging and treatment strategies of MRONJ were defined by AAOMS<sup>7</sup>: in the present case, the exposed necrotic bone extending beyond the region of the alveolar bone, ramus in the right mandible, osteolysis extending to the inferior border of the mandible by the radiographs. As a stage-specific treatment of stage 3 MRONJ, debridement in combination with antibiotic

therapy is recommended.<sup>7</sup> Moreover, sequestrectomy and antibiotic therapy were also performed.

There are several case reports regarding MRONJ patients who received novel antiangiogenic drug therapies for cancer, such as tyrosine kinase inhibitors and monoclonal antibody-targeting vascular endothelial growth factor (VEGF).<sup>7-13</sup> In the present case, the patient was exposed to three kinds of medicine which were considered to have contributed to the development of MRONJ: (1) zoledronate from August 2013 to October 2014, (2) sorafenib from October 2014 to April 2015, and (3) lenvatinib from July 2015 until the time of this writing. Lenvatinib is an oral inhibitor of multiple receptor tyrosine kinases targeting vascular endothelial growth factor receptor (VEGFR) 1-3, fibroblast growth factor receptor (FGFR) 1-4, and platelet growth factor receptor (PDGFR)  $\alpha$ .<sup>1</sup> Tyrosine kinase inhibitors have anticancer potency to treat solid tumors, including gastrointestinal stromal tumors, small cell lung cancer, thyroid carcinoma and hematologic malignancies.<sup>14</sup> To the best of our knowledge, no case of MRONJ occurring during lenvatinib therapy has been reported so far.

On the other hand, sorafenib is also a small molecule that inhibits the receptor tyrosine kinase activity of VEGFRs 1-3 and PDGFR  $\beta$ .<sup>8</sup> Some cases of osteonecrosis observed during sorafenib therapy have been reported in mandibular and femoral heads.<sup>9</sup> In the present case, the sorafenib therapy was performed for six months and was completed ten months before the first visit to our department. As a unique feature of the present case report, the patient received two types of antiangiogenic drug treatment (lenvatinib and sorafenib) after zoledronate treatment for ten months. Although the patient did not undergo any surgical dental treatment during either antiangiogenic drug therapies, the MRONJ developed by multiple influence of the medications.

In a previous report, the risk of ONJ in patients with cancer exposed to bevacizumab, a molecular targeted drug and an antiangiogenic agent, was 0.2% (20 cases per 10,000), but the risk in patients exposed to bevacizumab and zoledronate was higher (0.9%; 90 cases per 10,000).<sup>15</sup> Therefore, in the present case, the highly potent multi-kinase inhibitors were the probable agents to have been responsible for the development of osteonecrosis of the jaw. Osteonecrosis is classically considered

as an interruption in vascular supply or avascular necrosis thus, it is not surprising that inhibition of angiogenesis is a leading hypothesis in ONJ pathophysiology.<sup>7</sup>

In the present case, the patient had a perioperative drug holiday three months before and two months after the sequestrectomy under general anesthesia. This drug holiday was not only for the surgical operation, but also because of the side effects of lenvatinib and the radiation therapy for bone metastasis. Four months after the sequestrectomy, the soft tissue healing was completed in the upper and lower jaws (**Figure 5**). Until the time of this writing, while the patient is still on lenvatinib medication, there is no evidence of recurrence. We believe that surgical intervention was appropriate after a drug holiday, considering sequestrum had formed.

In conclusion, similar to many other molecular targeted drugs for cancer, lenvatinib is related to MRONJ and its developmental mechanism might be caused by inhibition of angiogenesis targeting vascular endothelial growth factor receptor.<sup>7,9,11,14</sup> In addition, there is a possibility that lenvatinib therapy can independently contribute to the development of MRONJ, like sunitinib and sorafenib.<sup>9,11,13</sup> Further investigation is needed to evaluate a possible relationship between lenvatinib and MRONJ. In recent years, a wide variety of molecular targeted drugs have been put to practical use for cancer treatment, but their long-term side effects are still unclear. Specifically, there is a possibility that new molecular targeted drugs can induce ONJ when combined with antiresorptive agents. It is important to report the side effects of new molecular targeted drugs and strive to quickly identify and prevent them.

**Conflicts of Interest:** None of the authors have any conflict of interests to declare.

#### References

1. Tohyama O, Matsui J, Kodama K et al: Antitumor activity of lenvatinib (e7080): an angiogenesis inhibitor that targets multiple receptor tyrosine kinases in preclinical human thyroid cancer models. *J Thyroid Res* 2014: 638747, 2014
2. Yamamoto Y, Matsui J, Matsushima T et al: Lenvatinib, an angiogenesis inhibitor targeting VEGFR/FGFR, shows broad antitumor activity in human tumor xenograft models associated with microvessel density and pericyte coverage. *Vasc Cell* 6: 18, 2014

3. Marx RE: Pamidronate (Aredia) and zoledronate (Zometa) induced avascular necrosis of the jaws: a growing epidemic. *J Oral Maxillofac Surg* 61: 1115–1117, 2003
4. Aghaloo TL, Felsenfeld AL, Tetradis S: Osteonecrosis of the jaw in a patient on denosumab. *J Oral Maxillofac Surg* 68: 959–963, 2010
5. Baron R, Ferrari S, Russell RG: Denosumab and bisphosphonates: different mechanisms of action and effects. *Bone* 48: 677–692, 2011
6. Saad F, Brown JE, Van Poznak C et al: Incidence, risk factors, and outcomes of osteonecrosis of the jaw: integrated analysis from three blinded active-controlled phase III trials in cancer patients with bone metastases. *Ann Oncol* 23: 1341–1347, 2012
7. Ruggiero SL, Dodson TB, Fantasia J et al: American Association of Oral and Maxillofacial Surgeons position paper on medication-related osteonecrosis of the jaw - 2014 update. *J Oral Maxillofac Surg* 72: 1938–1956, 2014
8. Llovet JM, Ricci S, Mazzaferro V et al: Sorafenib in advanced hepatocellular carcinoma. *N Engl J Med* 359: 378–390, 2008
9. Garuti F, Camelli V, Spinardi L et al: Osteonecrosis of the jaw during sorafenib therapy for hepatocellular carcinoma. *Tumori* 102: S69–S70, 2016
10. Brunello A, Saia G, Bedogni A et al: Worsening of osteonecrosis of the jaw during treatment with sunitinib in a patient with metastatic renal cell carcinoma. *Bone* 44: 173–175, 2009
11. Koch FP, Walter C, Hansen T et al: Osteonecrosis of the jaw related to sunitinib. *Oral Maxillofac Surg* 15: 63–66, 2011
12. Nicolatou-Galitis O, Migkou M, Psyri A et al: Gingival bleeding and jaw bone necrosis in patients with metastatic renal cell carcinoma receiving sunitinib: report of 2 cases with clinical implications. *Oral Surg Oral Med Oral Pathol Oral Radiol* 113: 234–238, 2012
13. Fleissig Y, Regev E, Lehman H: Sunitinib related osteonecrosis of jaw: a case report. *Oral Surg Oral Med Oral Pathol Oral Radiol* 113: e1–e3, 2012
14. Arora A, Scholar EM: Role of tyrosine kinase inhibitors in cancer therapy. *J Pharmacol Exp Ther* 315: 971–979, 2005
15. Guarneri V, Miles D, Robert N et al: Bevacizumab and osteonecrosis of the jaw: incidence and association with bisphosphonate therapy in three large prospective trials in advanced breast cancer. *Breast Cancer Res Treat* 122: 181–188, 2010