



# A Case of Effective Use of Diagnostic Laparoscopy on Intestinal Obstruction Caused by Adhesion

著者名	SUGA Hiroyasu, NAKAGAWA Takao, SATO Takayuki, SHOKO Tomohisa
journal or publication title	Tokyo Women's Medical University Journal
volume	3
page range	63-68
year	2019-12-20
URL	<a href="http://hdl.handle.net/10470/00032480">http://hdl.handle.net/10470/00032480</a>

doi: <https://doi.org/10.24488/twmuj.2018015>|[10.24488/twmuj.2018015](https://doi.org/10.24488/twmuj.2018015)

## A Case of Effective Use of Diagnostic Laparoscopy on Intestinal Obstruction Caused by Adhesion

Hiroyasu Suga,<sup>1,2</sup> Takao Nakagawa,<sup>1</sup> Takayuki Sato,<sup>1,2</sup> and Tomohisa Shoko<sup>2</sup>

<sup>1</sup>Department of Emergency and Critical Care Medicine, Iseaki Sawa Medical Association Hospital, Gunma, Japan

<sup>2</sup>Department of Emergency and Critical Care Medicine, Tokyo Women's Medical University Medical Center East, Tokyo, Japan

(Accepted March 11, 2019)

(Advance Publication by J-STAGE May 9, 2019)

Although intestinal obstruction is a relatively common condition to be seen in daily clinical practice, cases with no history of laparotomy can often create difficulties in determining its diagnosis and surgical indication. This is a case report of a recurrent intestinal obstruction, with no surgical history, treated successfully using laparoscopy for both diagnosis and surgical operation.

The patient, 62-year-old male, was hospitalized about a year ago due to abdominal pain and diarrhea likely caused by acute enteritis. As the inflammation had reduced and X-Ray image no longer indicated any gas patterns in the small intestine, he was later discharged from the hospital. However, the symptoms recurred after seven months which included abdominal pain, diarrhea as well as bloating. The patient was then introduced to our hospital through a local clinic for further diagnosis.

The results resembled patient's previous hospitalization observing a formation of niveau, or mirror-image, in the upper abdomen as well as a sentinel loop with some swelling on computed tomography (CT) image. With conservative treatment, the patient showed rather a quick recovery soon after his admission. The inflammation and the intestinal obstruction had reduced. However, as recurrence had appeared in a similar area as his previous experience, the patient underwent diagnostic laparoscopy for further inspection of its underlying cause.

Adhesion of the ileum and the sigmoid colon was observed. After diagnosis, laparoscopic adhesiolysis was performed in order to divide the adhesion and to remove the inflated part of the small intestine. The postoperative course was positive and the patient was discharged from the hospital 13 days after the surgery. There has been no report of recurrence thereafter.

Technological development of CT scanners in recent years has enabled new levels of information. However, cases with no surgical history and fluctuating symptoms, such as the patient mentioned in this paper, requires direct observation of the tract. Doing so also helps determine the possibility of an internal hernia. Furthermore, laparoscopy enables a smooth shift from diagnosis to treatment, with the assistance of laparoscope, which avoids unnecessary invasion and requires only small incisions; serving it as a very effective approach to certain cases of intestinal obstruction.

**Key Words:** intestinal obstruction, laparoscopy, surgical indication, no history of laparotomy

---

Corresponding Author: Hiroyasu Suga, Department of Emergency Medicine TMG Asaka Medical Center, 1340-1 Mizonuma, Asaka-shi, Saitama 351-0023, Japan. hiro@kib.biglobe.ne.jp

doi: 10.24488/twmuj.2018015

Copyright © 2019 Society of Tokyo Women's Medical University. This is an open access article distributed under the terms of Creative Commons Attribution License (CC BY), which permits unrestricted use, distribution, and reproduction in any medium, provided the original source is properly credited.

## Introduction

Although intestinal obstruction is a relatively common condition to be seen in daily clinical practice, cases with no history of laparotomy can often create difficulties in determining its diagnosis and surgical indication.<sup>1</sup> This is a case report of a recurrent intestinal obstruction, with no surgical history, diagnosed and treated successfully using laparoscopy for both diagnosis and surgical operation.

## Case Example

**Patient:** 62-year-old Man.

**Past medical history:** Hepatitis C, diabetes, high blood pressure, liver hemangioma.

**Case history:** The patient was hospitalized about a year ago due to abdominal pain and diarrhea caused by acute enteritis. As the inflammation reduced and X-Ray image no longer indicated any gas patterns in the small intestine, he was discharged from the hospital. However, the symptoms recurred after seven months which included abdominal pain, diarrhea as well as bloating. The patient was then introduced to our hospital through a local clinic for further diagnosis. His condition on arrival was as shown: blood pressure: 96/88 mm Hg, heart rate: 84 bottles per minute (BPM), body temperature: 37.0°C. Abdominal examination revealed bloating, mild epigastric pain and lack of intestinal peristalsis.

**Blood test on admission:** No other than C-reactive protein (CRP) and a rise in blood glucose level were observed. Stool culture was also negative and revealed only normal flora (**Table 1**).

**Abdominal X-Ray and CT:** The results resembled patient's previous hospitalization observing a formation of "niveau (mirror-image)" in the upper abdomen (**Fig-**

**ure 1**), and in CT it indicated sentinel loop with some swelling and thickening, along with a small amount of ascitic fluid (**Figure 2**).

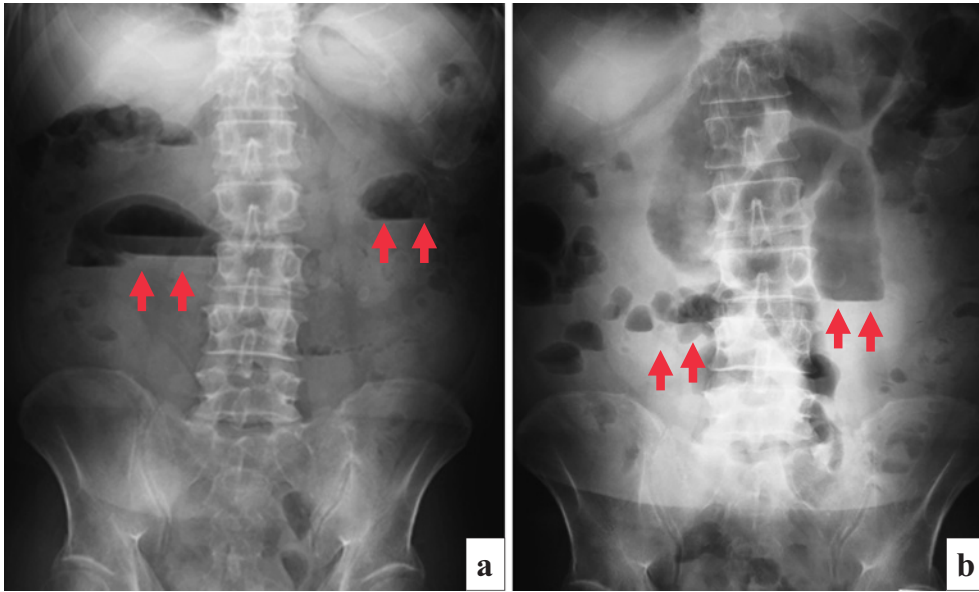
**The course of treatment:** Based on abdominal examination and radiographic images, the patient was hospitalized with the diagnosis of intestinal obstruction. Following a similar path of his previous hospitalization, the inflammation had already reduced by the third day, and the images (**Figure 3-a**) also showed improvement of intestinal obstruction. However, the same part in the intestinal tract from his previous hospitalization showed some swelling in CT images (**Figure 3-b**). Also, due its recurrence, it was suggested that the patient received a more thorough observation of the intestinal wall. Since the symptoms showed a rather swift improvement, the patient was hesitant towards long-term hospitalization. Therefore, a direct and effective method such as laparoscopy was chosen for both diagnostic, and if needed, surgical purposes. Diagnostic laparoscopy took place on the 8<sup>th</sup> day of hospitalization.

The operation started off with extending the first incision through which an adhesion of the ileum and the sigmoid colon was observed. Forming a lump, the same region also had an inflammatory stenosis (**Figure 4**). A laparoscopic adhesiolysis was performed in order to divide the adhesion. Again, extending the incision, laparoscopic adhesiolysis was performed in the lower abdomen in order to divide the adhesion on the sigmoid colon. The adhesion was due to a perforated diverticulitis of the sigmoid colon, and after the diverticulum was sutured, partial resection of the small intestine was conducted.

Pathological findings did not indicate any malignancy. As a possible effect of perforated diverticulitis of the sigmoid colon, increase in fiber, swelling and inflammatory cell infiltration were observed. The postoperative course

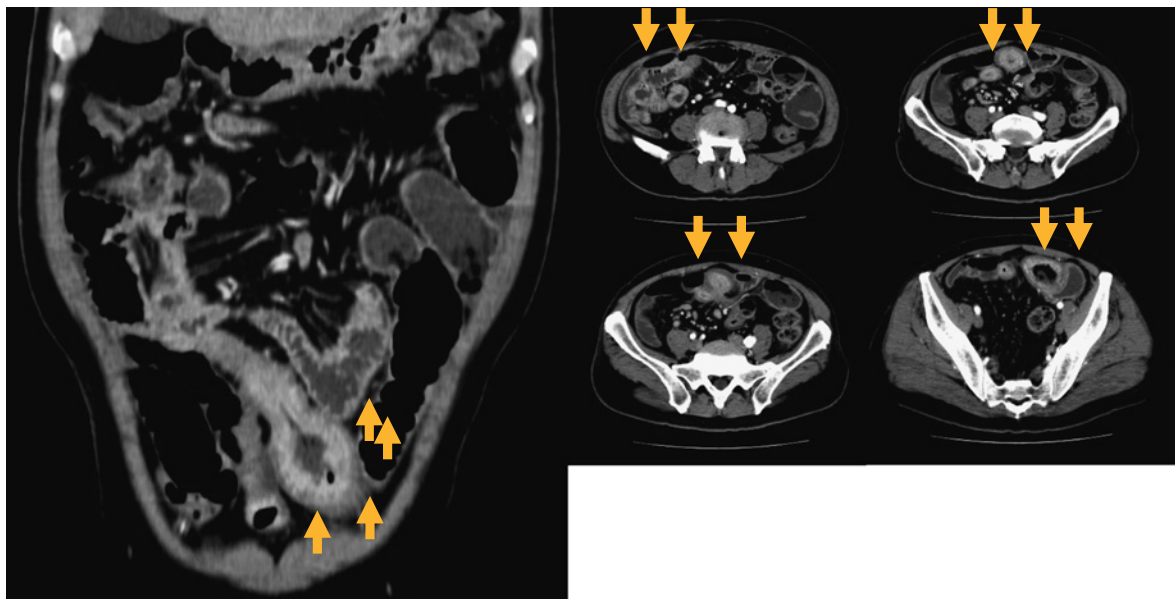
**Table 1** Blood test on admission.

TP	8.3 g/dL	BUN	19.4 mg/dL	WBC	89×10 <sup>2</sup> /μL
Alb	3.8 g/dL	Cre	0.97 mg/dL	RBC	47.3×10 <sup>4</sup> /μL
CRP	3.76 mg/dL	Cl	106 mEq/L	Hb	14.1 g/dL
AST	14 IU/L	Na	140 mEq/L	Ht	42 %
ALT	12 IU/L	K	4.52 mEq/L	Plt	19.9×10 <sup>4</sup> /μL
T-Bil	0.9 mg/L	BS	149 mg/dL		
LDH	169 IU/L				
AMY	101 IU/L				
CPK	27 IU/L				



**Figure 1** Plain X-ray.

- a. On admission: Gas in the large intestine and the formation of niveau (mirror-image) in the upper abdomen were observed (↑).
- b. Previous hospitalization had also observed a niveau formation in similar region (↑).



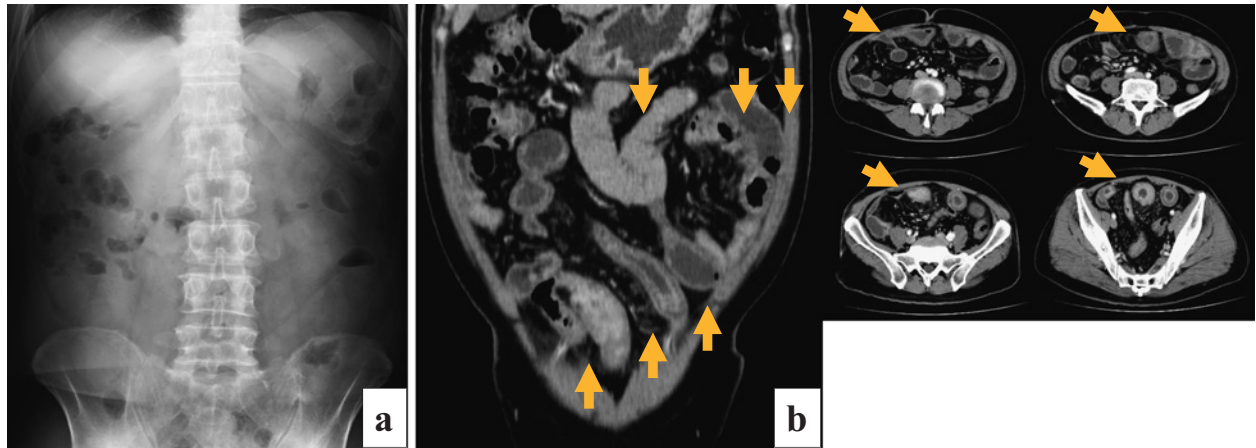
**Figure 2** CT Scanning.

CT examination on admission revealed bowel wall thickening, stagnation of bowel contents, and a small amount of ascitic fluid (↑). Previous hospitalization had also observed intestinal wall thickening (↑), stagnation of small intestinal contents, as well as a small amount of ascitic fluid. There were no signs of vascular ischemia as indicated by contrast enhancement.

was positive and the patient was discharged from the hospital 13 days after the surgery. There were no reports of recurrence thereafter.

## Discussion

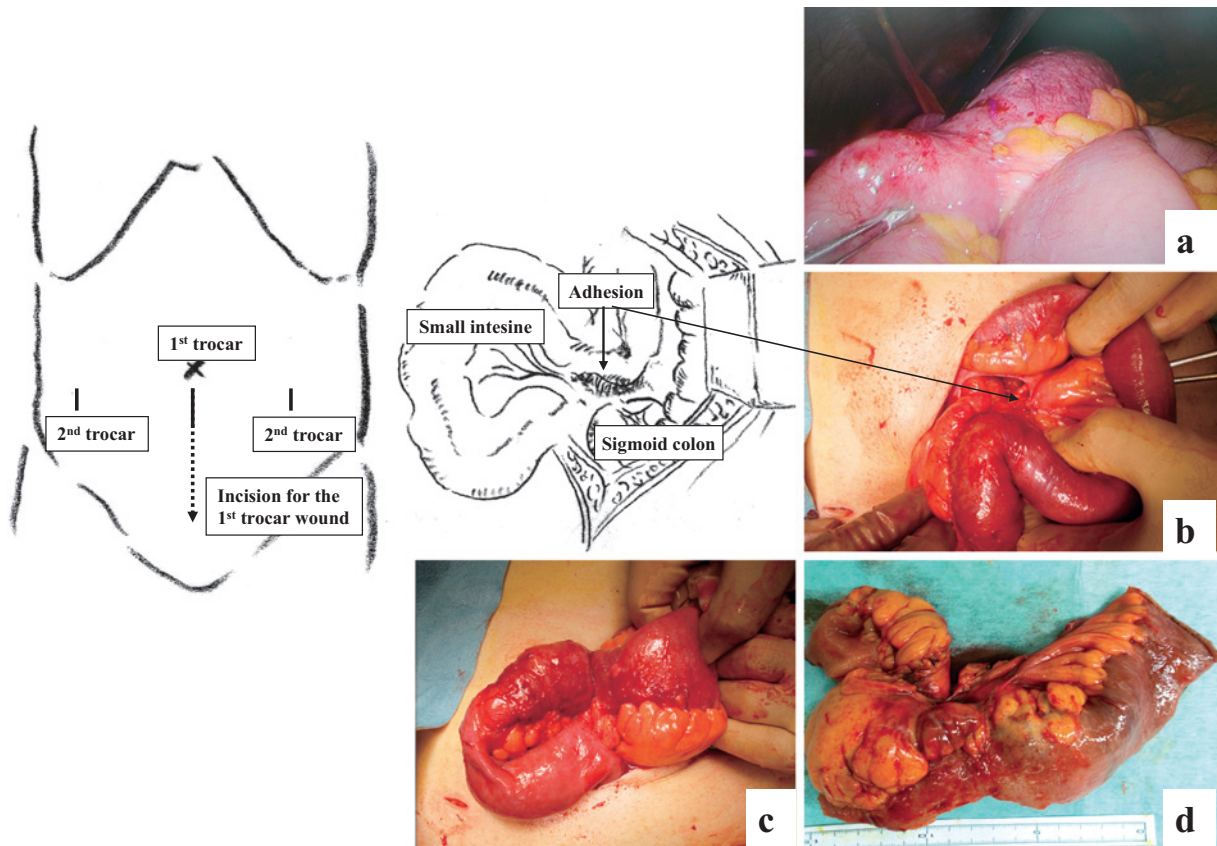
Although intestinal obstruction is a relatively common condition to be seen in daily clinical practice, methods of treatment and diagnosis can vary depending on the un-



**Figure 3** Image inspection on the second day of illness.

a. Most of the gas in the small intestine seemed to have disappeared on plain X-ray.

b. Bowel wall thickening remained in the lower midline with slight improvement (↑). There were no signs of vascular ischemia as indicated by contrast enhancement.



**Figure 4** Intraoperative findings.

a. First, 10 mm trocar for laparoscopic surgery was placed. Next, 5 mm trocar for forceps was placed. Entering abdominal cavity revealed redness and swelling of the small intestine with partial scarring and stiffness.

b & c. Incision for the 10 mm trocar wound was extended for easier control (10 cm laparostomy was conducted). The lesion was taken out of abdominal cavity; the part with adhesion due to perforated diverticulitis of the sigmoid colon was forming a lump, suggesting higher risk of recurrence. Operative treatment included adhesiotomy on the sigmoid colon and resection of the inflated part of the small intestine.

d. About 20 cm of enterectomy. Adhesion showed mucosal hypertrophy, increase in fiber, and inflammatory cell infiltration.

derlying cause and/or primary illnesses. It is often caused by postoperative adhesion after laparotomy. However,<sup>2,5</sup> cases with no history of laparotomy can create difficulties in determining the course of diagnosis, treatment and surgery.<sup>1,6,7</sup> Causes can vary especially for patients with no surgical history such as internal hernia or cicatricial stenosis due to inflammation of the intestinal wall.<sup>5,8-10</sup>

Regardless of history in laparotomy, recovery process also varies; while some show improvement only from gastrointestinal decompression using a nasogastric tube,<sup>6</sup> some require emergency surgery. In particular, cases with strangulation ileus involving impeded blood flow require precise diagnosis as it can quickly develop intestinal necrosis also leading to peritonitis as well as sepsis.<sup>10,11</sup>

Technological development of CT scanners in recent years has enabled new levels of information in which the mechanism, region and degree of intestinal obstruction can be identified through diagnostic imaging.<sup>3,11,12</sup> However, determining the underlying cause could still be a challenge.<sup>3,13</sup> In case of enteritis, there could be limitations to determining the exact condition and affected area of the intestinal wall. There are methods such as enema or colonoscopy when the illness is focused in the large intestine. However, cases found in small intestine tend to be more difficult to diagnose despite having methods such as small bowel follow-through, capsule endoscopy or enteroscopy.<sup>12-17</sup>

Meanwhile, laparoscopy has also been serving as an effective tool for both diagnosis and treatment processes especially with its current innovations.<sup>8,18</sup> The approach allows direct entry to abdominal cavity and provides a smooth shift from diagnosis to operative treatment if and when necessary.<sup>19</sup> Although there are risks surrounding trocar placement depending on the level of intestinal expansion and whether or not an adequate surgery workspace can be secured, large number of reports suggests laparoscopy as an effective means.<sup>6,7</sup> According to Fujiwara et al.,<sup>6</sup> laparoscopy is suitable for cases with no history of laparotomy as the responsible lesion of intestinal obstruction is usually limited to one location, in comparison to adhesive types.

The patient in this particular case report showed recovery in his symptoms soon after hospitalization as a result of fasting and so forth. Nonetheless, it was a recurrence,

and considering that a niveau had formed in a similar location and wall thickening of the intestine was observed on CT images, it suggested the need for a thorough diagnosis of the lesioned part for which diagnostic laparoscopy was performed. Images from the CT scanner did reveal small intestinal wall thickening as well as suggesting that the responsible lesion may have reoccurred in the same location. Meanwhile, due to the quick recovery of his symptoms, the patient was rather hesitant in undergoing laparoscopy. However, as it was revealed that the patient had gone through a similar condition two times prior to his hospitalization at our hospital, laparotomic approach seemed most appropriate for diagnosis which then led to operative treatment.

Although, clinically, the symptoms of intestinal obstruction had reduced, redness and swelling of the small intestine was observed. Furthermore, the part with adhesion due to perforated diverticulitis of the sigmoid colon was forming a lump, which suggested higher risk of recurrence. Operative treatment included adhesiotomy on the sigmoid colon and partial resection of the inflated area of the small intestine. Postoperative course was positive without any recurrence of the symptoms thereafter.

Laparoscopy avoids unnecessary invasion and requires only small incisions, optimizing the efficiency of the surgical procedure. It serves as an effective tool for both diagnosis and treatment especially when dealing with recurrent intestinal obstruction -including the case presented in this paper- with no definitive identification of the underlying cause.

## Conclusion

1. This paper shares the experience and/or case example of an effective use of diagnostic laparoscopy on intestinal obstruction with no surgical history.
2. Laparoscopy enables direct observation from which a smooth and prompt transition from diagnosis to treatment can be made accordingly. As a result, the patient is treated with a minimally invasive approach.
3. When dealing with intestinal obstruction with no history of laparotomy which often creates difficulties in determining its diagnosis, laparoscopy has proven to be an effective approach as demonstrated in this case example.

## References

1. Fujiwara H, Yasuda K, Hidaka T et al: The efficacy of laparoscopic procedures for the intestinal obstructions without a history of laparotomy. *J Abdom Emerg Med* 28 (1): 41–45, 2008 (in Japanese)
2. Townsend CM Jr, Beauchamp RD, Evers BM et al: Small intestine. *In Sabiston Textbook of Surgery*, 20th ed. pp1237–1254, Elsevier, Philadelphia (2017)
3. Onda M, Takasaki H, Furukawa K et al: Nationwide investigation of 21,899 cases of intestinal obstruction. *J Abdom Emerg Med* 20 (5): 629–636, 2000 (in Japanese)
4. Kinoshita M, Kato A, Kataoka M et al: Minimally invasive surgery using laparoscopy for intestinal adhesion. *J Abdom Emerg Med* 26 (1): 31–36, 2006 (in Japanese)
5. Menzies D, Ellis H: Intestinal obstruction from adhesions - how big is the problem? *Ann R Coll Surg Engl* 72: 60–63, 1990
6. Murakami M, Kato H, Kusano M: Selection of the tube therapy and indications for surgical therapy for adhesive small bowel obstruction. *J Abdom Emerg Med* 19 (7): 863–868, 1999 (in Japanese)
7. Tomita R, Tanjoh K, Fujisaki S et al: Shikatas Classification on selective enteroclysis for treatment principle of intestinal obstruction due to adhesions. *Nippon Kyumei Iryo Gakkai Zasshi* 27: 15–18, 2013 (in Japanese)
8. Suga H, Nakagawa T, Sato T et al: A case of constrictive ischemic colitis necessitating a surgery due to delayed cicatricial stenosis. *TWMUJ* 2: 31–36, 2018
9. Brower RA, Freeman LD: Ballon catheter dilation of a rectal stricture. *Gastrointest Endosc* 30: 95–97, 1984
10. Nolan DJ: Enteroclysis of non-neoplastic disorders of the small intestine. *Eur Radiol* 10: 342–353, 2000
11. Kawase H, Uemura S, Senmaru N et al: Diagnostic accuracy and treatment outcome of strangulated intestinal obstruction. *J Abdom Emerg Med* 35 (5): 543–548, 2015 (in Japanese)
12. Hirai C, Inoue T: Assessment of bowel obstruction on CT. *Rinsho Geka* 73 (7): 786–789, 2018 (in Japanese)
13. Fukami Y, Kaneoka Y, Maeda A et al: Clinical effect of water-soluble contrast agents for small bowel obstruction in the virgin abdomen. *World J Surg* 42: 88–92, 2018
14. Takeuchi K, Arai N, Miyamura M et al: CT enterography and CT colonography for inflammatory bowel diseases. *Intestine* 18 (2): 167–173, 2014 (in Japanese)
15. Li L, Chen C, Li Y et al: The role of capsule endoscopy in the diagnosis and treatment of obscure gastrointestinal bleeding in older individuals. *Eur J Gastroenterol Hepatol* 28: 1425–1430, 2016
16. Duda JB, Bhatt S, Dogra VS: Utility of CT whirl sign in guiding management of small-bowel obstruction. *AJR Am J Roentgenol* 191: 743–747, 2008
17. Mallo RD, Salem L, Lalani T et al: Computed tomography diagnosis of ischemia and complete obstruction in small bowel obstruction: a systematic review. *J Gastrointest Surg* 9: 690–694, 2005
18. Ikeda Y, Hirota M, Hatakeyama K: Laparoscopic adhesiolysis for bowel obstruction: analysis of surgical outcome in 25 patients. *JSES* 15 (1): 53–57, 2010 (in Japanese)
19. Johna S, Lefor AT: Laparoscopic evaluation of lymphoma. *Semin Surg Oncol* 15: 176–182, 1998