



# Clinical Experience on a Digital Low-Pressure Continuous Suction Unit Having a Trend Forecasting Function for Evaluating Lung Air-Leak

著者名	ISAKA Tamami, OGIHARA Akira, MITSUBOSHI Shota, MATSUMOTO Takako, KANZAKI Masato
journal or publication title	Tokyo Women's Medical University Journal
volume	3
page range	29-33
year	2019-12-20
URL	<a href="http://hdl.handle.net/10470/00032475">http://hdl.handle.net/10470/00032475</a>

doi: <https://doi.org/10.24488/twmuj.2018014>|[10.24488/twmuj.2018014](https://doi.org/10.24488/twmuj.2018014)

## Clinical Experience on a Digital Low-Pressure Continuous Suction Unit Having a Trend Forecasting Function for Evaluating Lung Air-Leak

Tamami Isaka, Akira Ogihara, Shota Mitsuboshi,  
Takako Matsumoto, and Masato Kanzaki

Departments of Thoracic Surgery, Tokyo Women's Medical University, Tokyo, Japan

(Accepted February 27, 2019)

(Advance Publication by J-STAGE April 24, 2019)

Lung air-leak (LAL) is an unavoidable complication after thoracoscopic lung resections. Generally postoperative LALs are managed with a digital low-pressure continuous suction device (DCSD) with three bottles. Since the management is performed by information obtained visually, sharing the data among medical staff becomes difficult, resulting in an issue. Fourteen consecutive surgical cases underwent thoracoscopic lung wedge resection. Intraoperative LALs were detected in 6 patients. Immediately after surgery, as postoperative management, a DCSD was used. Postoperative LALs were found in 12 cases; the periods of drainage were 2 to 15 days with a mean of  $5.0 \pm 3.6$  days. Twelve hours' air-bubble time before clamp test was 0.01 - 2.29 s/60 s with a mean of  $0.74 \pm 1.12$  s/60 s. After clamp test, lung collapse identified by chest X-ray examination was found in 2 cases, and in 1 case, lung collapse was caused by sucking air through the inserting port of drain tube without LAL. In medical staff conference, necessary information was shared by using a large liquid crystal display.

**Key Words:** lung air-leak, digital low-pressure continuous suction unit

### Introduction

Lung air-leak (LAL) is an unavoidable complication and common after thoracoscopic lung resections. Generally postoperative LALs are managed with a thoracic drainage system, and digital low-pressure continuous suction devices (DCSDs) with three bottles have been used as a drainage system.<sup>1,3</sup> In the system, the third bottle is used as a water-seal bottle where air-bubbles are monitored visually. Because the management is performed by information obtained visually, difficulty in sharing the data among medical staff becomes an issue, which is one of

reasons prolonging the durations of drainage and postoperative hospital stay.<sup>4</sup> In this study, postoperative LAL management was performed with a new DCSD having a trend forecasting function, and the efficacy and usability of the device are reported here.

### Patients and Methods

Between October 2016 and March 2017, 14 consecutive surgical cases underwent thoracoscopic lung wedge resection at The Tokyo Women's Medical University (**Table 1**). In 14 cases, 11 male and 3 female patients were

---

Corresponding Author: Masato Kanzaki, Departments of Thoracic Surgery, Tokyo Women's Medical University, 8-1 Kawada-cho, Shinjuku-ku, Tokyo 162-8666, Japan. kanzaki.masato@twmu.ac.jp  
doi: 10.24488/twmuj.2018014

Copyright © 2019 Society of Tokyo Women's Medical University. This is an open access article distributed under the terms of Creative Commons Attribution License (CC BY), which permits unrestricted use, distribution, and reproduction in any medium, provided the original source is properly credited.

**Table 1** Characteristics of the patients.

Number of patients (%)	14 (100)
Gender, n* (%)	
Male	11 (78.6)
Female	3 (21.4)
Age, mean $\pm$ SD (years)	63.1 $\pm$ 17.5
Clinical diagnoses, n (%)	
Primary lung cancer	3 (21.4)
Metastatic lung tumors	4 (28.6)
Bullaous diseases	6 (42.9)
Benign lung tumor	1 (7.1)
Air-bubbling time, mean $\pm$ SD (s/60s)	0.74 $\pm$ 1.11
Re-suction, n (%)	2 (8.3)

The letter "n" indicates number.

included, and the average age and its standard deviation (SD) were 63.1 and 17.5 years, respectively. In the cases, 3 primary lung cancers, 4 metastatic lung cancers, 6 spontaneous pneumothorax with bullae, and 1 pulmonary arteriovenous malformation case were found. Five of these patients had combined with chronic obstructive pulmonary disease (COPD). Thoracoscopic lung wedge resection was performed mainly by a surgical stapler. Intraoperative LALs were detected in 6 patients and closed with by polyglycolic-acid sheets and fibrin glue. Immediately after surgery, as postoperative management, a DCSD (MERA SUCCUM 009: MS009-T<sup>®</sup>, Senko Medical Instrument, Tokyo, Japan) was used (**Figure 1A, B**). This study was approved by the ethics committee of Tokyo Women's Medical University (approval No.4351).

#### Detection mechanism of air-bubbles

In **Figure 1C**, the graph shows the time-course of change in negative pressure within an observation period of 60 s, and the data are extracted from the continuously recorded negative pressure data in the suction flow path shown on a personal computer. On the x-axis, the 60 s observation period shown from the left to the right corners. The emergence of air-bubbles due to LAL in the water-seal compartment instantaneously brings negative pressure in the suction flow path close to atmospheric pressure. This decrease in negative pressure is detected by a pressure sensor equipped in the device, which quickly starts a suction pump. The flow rates of air flowed through the suction flow path and exhausted from the pump are unstable, and after the emergence of air-bubbles, the pressure in the suction flow path fluctuates

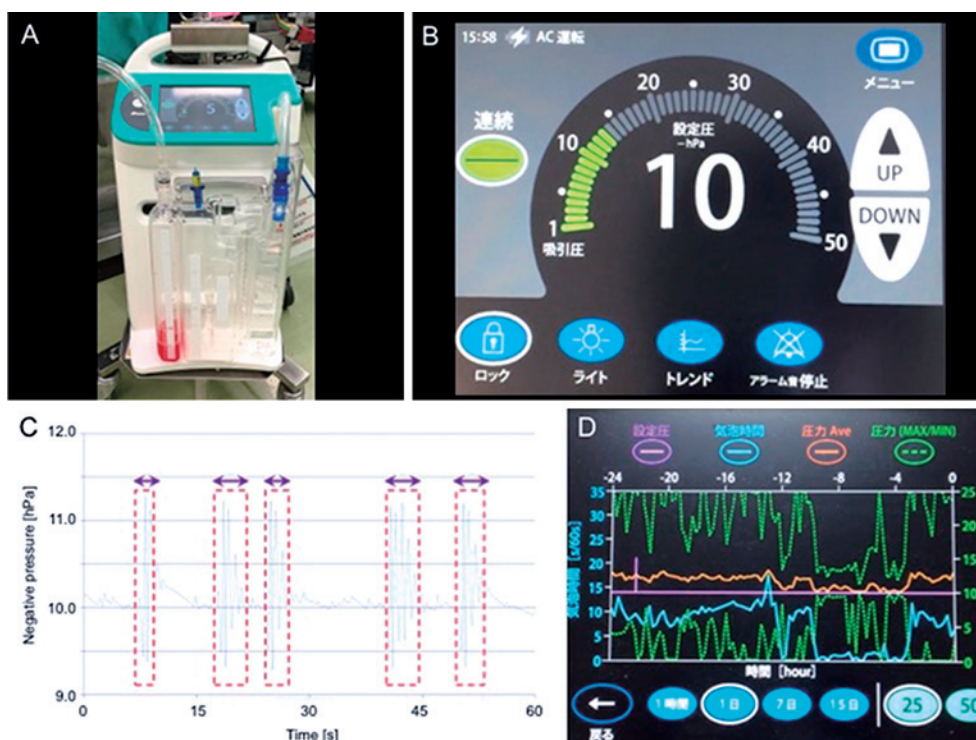
quickly and greatly until convergence at a pressure near to the set pressure. For detecting the emergence of air-bubbles by quick pressure change, a pressure fluctuation without air-bubbles is distinguished from quick and large fluctuation observed after the emergence of air-bubbles in the suction flow path. The duration of the large pressure fluctuation is recognized as air-bubble emerging time, and the duration of the observation of air-bubbles every 60 s is recognized as air-bubbling time. For example, in the time-course graphs, the air-bubbling times are measured from the start of a series of quick pressure changes surrounded with the red-dash-lines and the dual headed arrows.

#### Removal of drain tube

When no LAL was confirmed visually and air-bubbling time was confirmed to be less than 3 s/60 s, the tube was clamped overnight. After no collapsed lung and no subcutaneous emphysema on chest X-ray image were confirmed, the drain was removed. When dyspnea, chest pain, or subcutaneous emphysema were found during tube clamping, the tube was declamped, and suction was immediately re-started.

### Results

In cases of primary lung cancer, all cases were adenocarcinomas and 0 stage of the pathological stage. The primary sites of metastatic lung tumors were 2 cases of renal cancer, and each 1 case of cecum cancer and esophagus cancer. Resected site of lung was 10 cases of left and 4 cases of right. The operative time ranged from 63 to 312 min, (mean  $\pm$  SD, 129.8  $\pm$  73.7 min). The blood loss ranged from 1 to 30 mL (mean, 6.2  $\pm$  8.6 mL). Postoperative LAL were found in 12 cases; the periods of drainage were 2 to 15 days with a mean of 5.0  $\pm$  3.6 days. Twelve hours' air-bubble time before clamp test was 0.01 - 2.29 s/60 s with a mean of 0.74  $\pm$  1.12 s/60 s. In 12 cases (85.7%), drain was removed on the following day after drain tube was clamped. After clamp test, lung collapse identified by chest X-ray examination was found in 2 cases. In one of them lung collapse was caused by sucking air through the inserting port of drain tube without LAL (**Table 1**). In another case, air-leak from the lung was found. This study was unable to investigate the



**Figure 1** A digital low-pressure continuous suction device, temporal changes in the negative pressure in the suction flow path, and the definition of the air-bubbling time.

(A) A digital low-pressure continuous suction device (DCSD) with three bottles, MERA SUCCUM 009 (MS009-T®) (Senko Medical Instrument, Tokyo, Japan).

(B) A touch-panel liquid-crystal display of DCSD. Four buttons are at the bottom row. From left, the first bottom is a lock button for avoiding wrong pressing, a button for lighting a 3-bottle bag, a button for displaying the trend screen, and a button for turning off alarm.

(C) The graph shows the time-course of change in negative pressure within an observation period of 60 s, and the data are extracted from the continuously recorded negative pressure data in the suction flow path shown on a personal computer. For detecting the emergence of air-bubbles by quick pressure change, a pressure fluctuation without air-bubbles is distinguished from quick and large fluctuation observed after the emergence of air-bubbles in the suction flow path. The duration of the large pressure fluctuation is recognized as air-bubble emerging time, and the duration of the observation of air-bubbles every 60 s is recognized as air-bubbling time.

(D) On the actual display of the device, the left y-axis shows the air-bubbling time (s/60 s), and the light-blue line shows the time-course of change in the air-bubbling time. The right y-axis shows the pressure in the suction flow path the horizontally running purple straight-line shows the set pressure, the upper and lower green dash-lines show the maximum and minimum pressures, respectively, and the red line shows the averaged pressure.

effects of underlying diseases on collapse because of the insufficient number of cases. All five COPD patients had no LAL after clamp test.

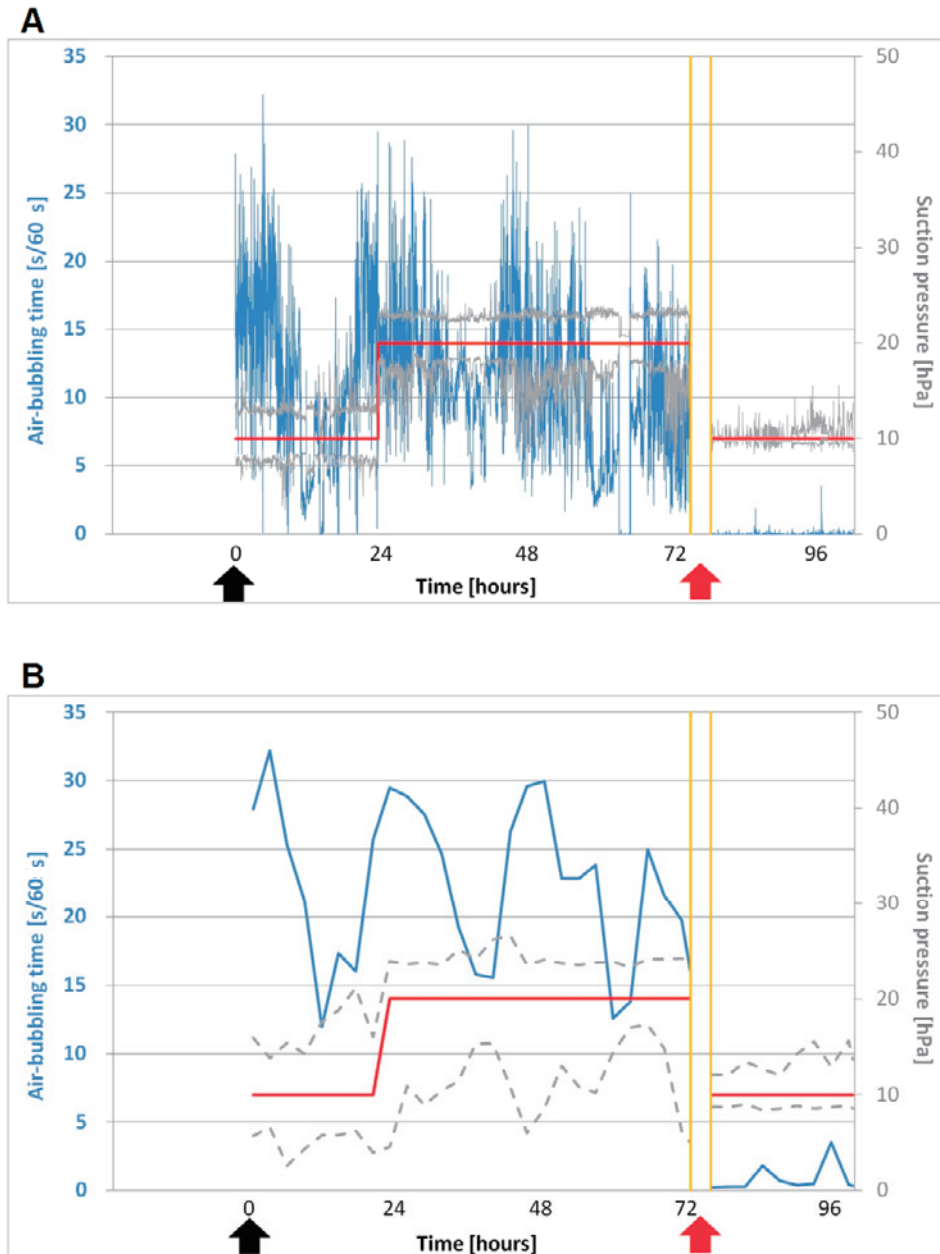
### Case presentation

In a case of spontaneous pneumothorax, no LAL was observed after thoracic drainage visually (**Figure 2**). However, at 11 hours after drain insertion, LAL appeared again and continued, and therefore, thoracoscopic lung wedge resection was performed on the third day of hospi-

talization. No LAL was recognized after operation. On the display of DCSD, the difference between the maximum and the minimum suction pressures decreased, and the suction pressure became equal to the set pressure.

### Discussion

The authors have preferred to use a thoracic drainage system with three bottles for managing postoperative LAL.<sup>2,3</sup> The third bottle of the suction device serves as a



**Figure 2** Relation between air-bubbling times and continuously monitored suction pressure. Graphs (A) and (B) show the air-bubbling time and continuously monitored suction pressure, respectively. On the x-axis, the red and black arrows indicate times when a drain tube was inserted and operation was performed, respectively. The blue and gray lines show air-bubbling time and suction pressure, respectively. The red line shows the set suction pressure. (A) The graph specifically shows air-bubbling time observed in a case of spontaneous pneumothorax and expresses and bubbles displayed at a rate of approx 4,000 points per 60 s. Air-bubbling time becomes shorter, and the suction pressure becomes equal to as the set suction pressure. (B) The graph shows bubbles displayed at a rate of 60 points per 60 s.

water-seal device where air-bubbles is monitored visually. Although some DCSDs, which can express the appearances of LALs by continuously monitoring air leakage and pleural pressure, are commercially available, the DCSDs are unable to detect air-bubbles.<sup>1,5</sup> For medical staffs who are familiar to use one of the DCSDs with

three bottles, recognizing the appearances of LALs is quite difficult by reading the air-flow-rate digital values showed in mL/min on the display panel of the devices. On the other hand, conventional LAL detection is performed visually by doctors and nurses. As a result, important information regarding the appearance of LAL and

exhausted air volume from the lung is unable to be shared among medical staff, resulting in drainage troubles. The greatest reason why no common drain management has been found among hospitals is because LAL never be evaluated quantitatively.<sup>6</sup> Although conventional DCSDs are unable to detect air-bubbles and give a difficulty in recognizing the appearance of LALs to medical staff, this study's DCSD was able to measure air-bubbling time and allowed medical staff to detect LALs easily, indicating that the DCSD had a higher efficacy other conventional DCSDs. In this study's DCSD, LAL was detected by monitoring a pressure fluctuation in the suction flow-path caused by air-bubbles.<sup>7</sup> After the relationship between LAL volume and air-bubbling time was obtained, LAL volume could be estimated by both air-bubbling time and the setting suction pressure. Since LAL was detected by measuring air-bubbling time, this DCSD was effective, and air-bubbling time less than 2 s showed the removal timing of the drain tube. Ideally, after confirming no air-leak, immediately the drain tubes could be removed without clamp test, and the duration of drainage could be shortened, resulting in the reduction of hospitalization. The limitations of this study, which showed an early experience with a small number of patients, are the relatively short follow-up period and a single institutional study. Therefore, the results of this study need to be confirmed in a multicenter study with a larger number of patients.

### Conclusions

The authors reported the high efficacy of new DCSD, which equips a digital drainage system. After thora-

scopic lung wedge resection, postoperative LAL was able to be detected by continuously monitoring air leakage, and the management was performed by information obtained visually, and the data were shared by medical staff.

**Conflicts of Interest:** The authors confirm no conflicts of interest.

### References

1. Takamochi K, Nojiri S, Oh S et al: Comparison of digital and traditional thoracic drainage systems for postoperative chest tube management after pulmonary resection: A prospective randomized trial. *J Thorac Cardiovasc Surg* 155: 1834–1840, 2018
2. Brunelli A, Cassivi SD, Salati M et al: Digital measurements of air leak flow and intrapleural pressures in the immediate postoperative period predict risk of prolonged air leak after pulmonary lobectomy. *Eur J Cardiothorac Surg* 39: 584–588, 2011
3. Cerfolio RJ, Bass C, Katholi CR: Prospective randomized trial compares suction versus water seal for air leaks. *Ann Thorac Surg* 71: 1613–1617, 2001
4. Abolhoda A, Liu D, Brooks A et al: Prolonged air leak following radical upper lobectomy: an analysis of incidence and possible risk factors. *Chest* 113: 1507–1510, 1998
5. Miller DL, Helms GA, Mayfield WR: Digital drainage system reduces hospitalization after video-assisted thoracoscopic surgery lung resection. *Ann Thorac Surg* 102: 955–961, 2016
6. Lang P, Manickavasagar M, Burdett C et al: UK Cardiothoracic Trainees' Research Collaborative; UK Cardiothoracic Trainees' Research Collaborative: Suction on chest drains following lung resection: evidence and practice are not aligned. *Eur J Cardiothorac Surg* 49: 611–616, 2016
7. Ogihara A, Isaka T, Katagiri S et al: Usefulness of continuous suction unit in detecting air leakage for pneumothorax. *Kyobu Geka* 71: 94–97, 2018