



NIH PUBLIC ACCESS

Author Manuscript

Mov Disord. Author manuscript; available in PMC 2011 August 15.

Published in final edited form as:

Mov Disord. 2010 August 15; 25(11): 1538–1549. doi:10.1002/mds.23088.

DEFINITION AND CLASSIFICATION OF HYPERKINETIC MOVEMENTS IN CHILDHOOD

Terence D. Sanger, MD, PhD, Daofen Chen, PhD, Darcy L. Fehlings, MD MSc FRCPC, Mark Hallett, MD, Anthony E. Lang, MD, Jonathan W. Mink, MD, PhD, Harvey Singer, MD, Katharine Alter, MD, Hilla Ben-Pazi, MD, Erin Butler, MS, Robert Chen, MA, MBBChir, MSc, FRCPC, Abigail Collins, MD, Sudarshan Dayanidhi, MS, PT, Hans Forssberg, MD PhD, Eileen Fowler, PhD, PT, Donald L. Gilbert, MD, MS, Sharon L. Gorman, PT, DPTSc, GCS, Mark E. Gormley Jr., MD, H. A. Jinnah, MD, PhD, Barbara Kornblau, JD, OT/L, FAOTA, ABDA, DAAPM, CDMS, CCM, Kristin Krosschell, PT, MA, PCS, Rebecca K. Lehman, MD, Colum MacKinnon, PhD, C. J. Malanga, MD, PhD, Ronit Mesterman, MD, Margaret Barry Michaels, PhD, PT, PCS, Toni S. Pearson, MD, Jessica Rose, PhD, Barry Russman, MD, Dagmar Sternad, PhD, Kathy Swoboda, MD, PhD, and Francisco Valero-Cuevas, PhD

Abstract

Hyperkinetic movements are unwanted or excess movements that are frequently seen in children with neurologic disorders. They are an important clinical finding with significant implications for diagnosis and treatment. However, the lack of agreement on standard terminology and definitions interferes with clinical treatment and research. We describe definitions of dystonia, chorea, athetosis, myoclonus, tremor, tics, and stereotypies that arose from a consensus meeting in June 2008 of specialists from different clinical and basic science fields. Dystonia is a movement disorder in which involuntary sustained or intermittent muscle contractions cause twisting and repetitive movements, abnormal postures, or both. Chorea is an ongoing random-appearing sequence of one or more discrete involuntary movements or movement fragments. Athetosis is a slow, continuous, involuntary writhing movement that prevents maintenance of a stable posture. Myoclonus is a sequence of repeated, often non-rhythmic, brief shock-like jerks due to sudden involuntary contraction or relaxation of one or more muscles. Tremor is a rhythmic back-and-forth or oscillating involuntary movement about a joint axis. Tics are repeated, individually recognizable, intermittent movements or movement fragments that are almost always briefly suppressible and are usually associated with awareness of an urge to perform the movement. Stereotypies are repetitive, simple movements that can be voluntarily suppressed. We provide recommended techniques for clinical examination and suggestions for differentiating between the different types of hyperkinetic movements, noting that there may be overlap between conditions. These definitions and the diagnostic recommendations are intended to be reliable and useful for clinical practice, communication between clinicians and researchers, and for the design of quantitative tests that will guide and assess the outcome of future clinical trials.

Introduction

Hyperkinetic movements are unwanted or excess movements that are frequently seen in children with neurologic disorders. These movement disorders are given descriptive terms that are often overlapping and ambiguous. Consistent terminology to describe these movements will clearly be helpful. Hyperkinetic movements in children are associated with

dysfunction of the basal ganglia, cerebral cortex, cerebellum, and other motor pathways due to static or progressive injury 1. Such movements are commonly seen in the dyskinetic form of cerebral palsy, but they also are important features of congenital, acquired, and degenerative diseases. Benign hyperkinetic movements can be seen in children who have no other neurological complaints. A significant impediment to medical treatment and research has been the lack of a consistent terminology. Current terminology is derived from analogous signs in adult disorders, and these definitions may not reflect the specific features of childhood movement disorders.

The Taskforce on Childhood Movement Disorders met at the National Institutes of Health in June, 2008 in order to develop an initial consensus on terminology for hyperkinetic signs and symptoms in childhood. The long-term purpose of the taskforce is to establish consensus definitions for childhood motor impairments, assess current technology for quantification of these impairments, and identify needs for further research in order to validate definitions and develop new quantification technologies. In previous meetings, the taskforce developed consensus definitions for hypertonic disorders 2 and for negative signs 3. This document describes the results of the June 2008 meeting. Participants included international representatives from multiple fields, including Developmental Pediatrics, Neurology, Occupational Therapy, Physical Medicine and Rehabilitation, Physical Therapy, and researchers in Movement Science and Motor Control.

The National Center for Medical Rehabilitation Research (NCMRR) proposed a hierarchy of elements of chronic disease composed of (1) Pathophysiology (underlying disease process), (2) Impairment (clinically observable signs and symptoms), (3) Functional Ability (effect on task performance), (4) Disability (effect on daily activities), and (5) Societal Participation (effect on lifetime opportunities) 4. More recently, the World Health Organization has proposed the International Classification of Function (ICF) that includes interactions between Health Condition, Body Functions and Structure, Activity, and Participation 5. While both classification systems appropriately emphasize the relationship between the disease process and functional outcome, clinical decisions and medical research depend upon the ability to link clinically observable signs and symptoms to the underlying pathophysiology. Therefore the primary goal in this document is to define hyperkinetic disorders at the level of clinical impairment in the NCMRR framework and Body Functions and Structure in the ICF framework.

Accurate terminology is essential for communication between clinicians, selection of appropriate medical and rehabilitative therapies, classification of subjects for inclusion in clinical research trials, quantification of research outcome, and categorization for epidemiological studies. Terminology is most successful when it captures essential elements of the underlying pathophysiology and differentiates between different pathophysiological processes. A complicating feature of childhood motor disorders is the frequent co-existence of multiple impairments in the same child 1-6. For example, individual children with cerebral palsy may display combinations of weakness, spasticity, dystonia, choreoathetosis, and ataxia. It is therefore essential that definitions permit distinction between impairments and that they be measurable in the presence of other impairments (e.g. weakness and spasticity). Therefore the definitions should meet the goals of earlier consensus meetings of the Taskforce:

- Utility: the ability to test a child easily in both a routine clinical setting and in a laboratory setting and to assign appropriate labels that differentiate between hyperkinetic impairments even when more than one is present simultaneously

- Reliability: the likelihood that different examiners will assign the same label to the manifestations of any given child (interobserver reliability) and that the same label will be assigned at different times by the same examiner (intraobserver reliability)
- Validity: the likelihood that the clinical definitions will agree with the assessments of expert clinicians (face validity), predict criterion (gold-standard) measurements (criterion validity), and predict the response to therapy (predictive validity).

We propose definitions for seven clinical hyperkinetic movements: dystonia, chorea, athetosis, myoclonus, tremor, tics, and stereotypies. The definitions proposed here are based upon consensus opinion and the best currently available evidence, yet we recognize that validation of these definitions will require further research.

Hyperkinetic Movements

We define hyperkinetic movements as any unwanted excess movement.

Together with hypertonia 2 and negative signs 3, hyperkinetic movements contribute to a taxonomy of childhood motor disorders. Hypertonia is abnormally increased resistance to externally imposed movement 2. Negative signs are insufficient muscle activity or insufficient control of muscle activity 3. Hyperkinetic signs differ from hypertonia because hypertonia is appreciated only during movement imposed by the examiner (passive movement), whereas hyperkinetic movements are appreciated during movements made (voluntarily or involuntarily) by the child (active movement). Hyperkinetic signs differ from negative signs because excessive movement or muscle activity is present with hyperkinetic movements. Thus hyperkinetic movements constitute a distinct category of motor disorder in children. Hyperkinetic movements, negative signs, and hypertonia may be present in the same child.

Hyperkinetic movements are among the motor abnormalities associated with the concept of “extrapyramidal” movement disorders in adults. While we recognize that the use of the term “extrapyramidal” has historical significance and is common in the literature, it is important to note that this term has only a weak link to the neuroanatomic localization of motor disorders in children and adults. We do not recommend the use of the term “extrapyramidal” to describe movement disorders in children.

Dystonia

The taskforce previously defined dystonia in the context of hypertonia as “*a movement disorder in which involuntary sustained or intermittent muscle contractions cause twisting and repetitive movements, abnormal postures, or both.*” 2

This definition can also be applied to dystonia in the context of hyperkinetic movements. The presence of abnormal postures that are superimposed upon or substitute for voluntary movements is a characteristic feature of dystonia. Dystonic postures are repeated, and particular patterns or postures are characteristic of each child at a given point in time. Similar dystonic postures may occur in different children. For example, foot inversion, wrist ulnar deviation, or lordotic trunk postures are common. Postures can be sustained or may occur during very brief intervals. Dystonic postures are often triggered by attempts at voluntary movement or voluntary posture, and in some cases they are triggered only in particular body positions or by particular movements as may occur in task-specific dystonia. With the exception of certain seizure disorders 7, dystonic-like movements or postures are not seen during sleep, possibly due to inhibition of movements by spinal mechanisms 8. Postures tend to occur at intervals determined by voluntary movement and can be sustained for variable lengths of time. Relaxation may be impaired so that the dystonic posture may be

maintained well beyond the end of the attempted voluntary movement that triggered it. There may be multiple dystonic postures in the same child, so that different dystonic postures may be combined.

The relationship between dystonia, hypertonia, and other hyperkinetic signs may be difficult to determine on routine clinical examination. When a dystonic posture is maintained against resistance, it can cause hypertonia. However, dystonic postures do not necessarily imply the presence of hypertonia, since postures may be held with only sufficient force to resist gravity. When dystonic postures occur only briefly, then it may not be possible to determine whether or not hypertonia is present. When dystonic postures are frequent and rapid, it may be difficult to distinguish hyperkinetic dystonia from chorea or myoclonus.

Although dystonia is associated with hyperkinetic movements, the mechanisms that relate dystonia to hyperkinetic movements are not currently known. Dystonia could potentially cause hyperkinetic movements by inserting dystonic postures that result in movement of a part of the body away from the intended position. If multiple brief dystonic postures are inserted in voluntary movements, this could result in variable, jerky, or tremulous movement. If sustained dystonic postures are inserted in voluntary movements, this could result in the prevention of movement, substitution of an unwanted posture for an intended posture, or slow movement in an attempt to overcome the inserted dystonic posture.

Overflow is the close association of an unwanted movement with an intended movement, or in many circumstances the spread of the motor command to surrounding or distant muscles different from those normally appropriate for a goal-directed action. Overflow may represent the triggering of a dystonic posture by a voluntary movement, although there are not yet data to support the relation between overflow and postures in dystonia. Nevertheless, overflow is commonly associated with other features of dystonia. For example, attempts to move the hands may lead to neck extension suggesting an “overflow” from the muscles of the forearm to the posterior cervical muscles. The mechanism of overflow is not understood, but theoretical models and some neurophysiological data suggest that it could be due to poor focusing of muscle activity such that related but unwanted muscles or motor programs are not suppressed adequately⁹⁻¹¹.

Although co-contraction is frequently identified as a feature of dystonia^{12, 13}, co-contraction is not necessary for the maintenance of stable posture, either for voluntary postures or for dystonic postures. Co-contraction may not be as frequently present in children with dystonia as originally thought¹⁴, and in some cases co-contraction could represent voluntary compensation. For example, if the wrist flexion muscles are activated as part of a dystonic posture, the child may activate the extensor muscles voluntarily in an attempt to overcome the posture. It would be difficult to distinguish this situation from involuntary dystonic co-activation of the flexors and extensors.

Dystonia has been associated with injury to the basal ganglia, in particular the putamen and globus pallidus. In many cases, however, no basal ganglia injury can be identified and recent evidence from both human disease and animal models suggests that other brain areas including cerebellum¹⁵⁻¹⁸, brainstem¹⁹, or sensory cortex^{20, 21} can be causes of dystonia. Corticospinal injury can produce fixed postures similar to dystonia that may be due to a combination of active contraction and weakness of opposing muscles. Currently, dyskinesic cerebral palsy is probably the most common cause of dystonia in children, with injury to the basal ganglia, thalamus, brainstem, and cerebellum occurring due to hypoxic-ischemic injury in the prenatal, perinatal, or infantile period. Other causes include encephalitis, vascular diseases, autoimmune disorders, cerebral malformations, metabolic disease, and neurodegenerative disease. Primary dystonia in children is mostly genetic. In

children, dystonia is frequently accompanied by bradykinesia, perhaps due to a common etiology.

Chorea

Chorea is an ongoing random-appearing sequence of one or more discrete involuntary movements or movement fragments.

Movements appear random due to variability in timing, duration, direction, or anatomic location. Each movement may have a distinct start and end point, although these may be difficult to identify since movements are often strung together one immediately following or overlapping with another. Movements may therefore appear to flow randomly from one muscle group to another, and can involve trunk, neck, face, tongue, and extremities.

Chorea is distinguished from dystonia due to the apparently random, unpredictable, and continuously ongoing nature of the movements, compared with the more predictable and stereotyped movements or postures of dystonia. The movements of chorea often appear more rapid than those associated with dystonia. Although chorea may be worsened by movement, attempts at movement, or stress, particular movements are not triggered by voluntary attempts with the same degree of temporal specificity as in dystonia. Therefore chorea does not appear as a temporally linked overflow from a voluntary movement, and it usually does not stop with attempted relaxation. As a result, children with chorea appear to be in constant motion or fidgety. Chorea sometimes results in “parakinesias”, in which children may incorporate the involuntary movement into a more purposeful movement in an attempt to hide the disorder. Unlike dystonia, chorea is not characterized by specific inserted postures, but rather by inserted movements. This distinction may not always be meaningful when a dystonic posture is brief or a choreatic movement involves pulling a limb toward an unwanted posture, but the fundamental distinction is that chorea includes repeated recognizable movements without necessarily any repeated postures.

Chorea is distinguished from athetosis by the ability to identify discrete movements or movement fragments within the ongoing sequence of chorea. The individual movement fragments in chorea are brief and often appear jerky. In contrast, the ongoing movement in athetosis is not composed of discrete movements, and athetosis thus appears to be a sinuous, continuously flowing, ongoing, random movement as opposed to a sequence of randomly selected brief movements.

Chorea is distinguished from tremor by its lack of rhythmicity and predictability. Chorea is distinguished from myoclonus by the fact that in myoclonus all the movements are quick, whereas in chorea only some are. Movements due to myoclonus may appear more stereotyped, as a consistent pattern of muscles is often involved. In some cases chorea and myoclonus may appear very similar when myoclonus is non-synchronous and multifocal. Chorea is distinguished from tics by the fact that chorea is usually not voluntarily suppressible. In addition, tics are more commonly stereotyped in appearance (see below). Chorea is distinguished from tremor associated with ataxia by the fact that abnormal movements in ataxia increase near a target (intention tremor and dysmetria) and improve with stabilization of proximal joints or other interventions that lower the degrees of freedom for movement.

We define ballism as chorea that affects proximal joints such as shoulder or hip. This leads to large-amplitude movements of the limbs, sometimes with a flinging or flailing quality.

Chorea is associated with disorders of the cerebral cortex, basal ganglia, cerebellum, and thalamus. Different causes of chorea often lead to different phenomenology. For instance,

streptococcal-associated chorea as seen in Sydenham's chorea often causes a distal "piano-playing" chorea with movements of the metacarpophalangeal joints of both hands 22, 23. Lesions in the subthalamic nucleus are associated with chorea and ballism 24. Encephalitis with diffuse gray-matter destruction is associated with a combination of chorea and myoclonus that affects proximal and distal muscles of the limbs as well as the neck, trunk, and face 25. Chorea can be caused by other disorders, including hyperthyroidism, anticholinergic toxicity, and genetic and metabolic diseases 25. Motor impersistence (the inability to maintain a voluntary posture such as tongue protrusion, arm extension, or grip) is a common association 26.

Athetosis

Athetosis is a slow, continuous, involuntary writhing movement that prevents maintenance of a stable posture.

Athetosis involves continuous smooth movements that appear random and are not composed of recognizable sub-movements or movement fragments. The term "athetosis" derives from the Greek meaning "without position or place," reflecting the inability to maintain a stable posture 27. In contrast to chorea, in athetosis the same regions of the body are repeatedly involved. As with dystonia and chorea, athetosis may worsen with attempts at movement or posture, but it can also occur at rest. Athetosis typically involves the distal extremities (hands or feet) more than the proximal and it can also involve the face, neck, and trunk.

Athetosis is distinguished from dystonia by the lack of sustained postures, although it is frequently associated with dystonia so the distinction can be difficult in practice. Athetosis differs from chorea by the lack of identifiable movement fragments. Although athetotic movements are typically slower and less jerky than the movements in chorea, this is not always the case and the distinction is made more by the nature of the movement rather than by their speed or rhythmicity. Athetosis is distinguished from tremor and stereotypies by the lack of rhythmicity and repeatability, and from myoclonus by the smooth, sinuous, flowing quality to the movements in contrast to rapid shock-like movements.

In children, athetosis rarely occurs in isolation but is much more commonly associated with chorea and dystonia. The combination of chorea and athetosis is called "choreoathetosis", but we note that choreoathetosis is most often caused by the dyskinetic form of cerebral palsy in which dystonia is a frequent associated movement disorder. Choreoathetosis is also associated with kernicterus and other causes of basal ganglia injury.

We note that the term "athetosis" has been used in the past to indicate a particular form of cerebral palsy 28. We recommend instead using the term "athetosis" only to indicate a particular type of movement independent of etiology, while using the term "dyskinetic cerebral palsy" to indicate the syndrome of abnormal involuntary movements seen in children with early brain injury.

In adults, athetosis can be due to a severe distal sensory loss in which case it is called "pseudoathetosis" 29. Whether a similar syndrome occurs in children is unknown.

Myoclonus

Myoclonus is a sequence of repeated, often non-rhythmic, brief shock-like jerks due to sudden involuntary contraction or relaxation of one or more muscles.

Myoclonus may be synchronous (several muscles contracting simultaneously), spreading (several muscles contracting in a predictable sequence) or asynchronous (several muscles

contracting with varying and unpredictable relative timing). When myoclonus affects more than one muscle in an apparently random and varying pattern it is called “multifocal”, and it is called “generalized” when many muscles are involved simultaneously. Myoclonus is characterized by a sudden uni-directional movement due to muscle contraction (“positive myoclonus”). Similar movements due to sudden brief muscle relaxation are termed “negative myoclonus”. There is a subsequent recovery phase where the limb will return to a voluntary posture or rest. When myoclonus is repeated rhythmically it is called “myoclonic tremor”. Myoclonic tremor is characterized by alternating fast phase and slow phase movements so that the rapid phase of the jerking occurs in a single direction with subsequent slower recovery following every jerk. The fast phase may be due to either contraction or relaxation of the involved muscle. Myoclonic tremor can be considered a particular cause of tremor, or a particular manifestation of myoclonus, and therefore it can be included in both categories.

Myoclonus can be caused or worsened by movement. Myoclonus can sometimes occur during sleep. Myoclonus can be categorized as “action myoclonus”, “postural myoclonus”, or “rest myoclonus” based on the condition when it is observed 30-31. It can also be categorized based on presumed anatomic origin as “cortical”, “subcortical”, “brainstem”, “propriospinal”, or “spinal”. Because of the frequent involvement of pharyngeal musculature in one form of brainstem myoclonus this type is sometimes referred to as “palatal” myoclonus. The rhythmical nature of these movements has encouraged the designation of “palatal tremor” for this specific movement disorder 32-33.

Myoclonus is distinguished from dystonia by the lack of identifiable postures, from athetosis by the sudden jerks and lack of smooth flowing movements, and from tremor by the asymmetric velocity of the jerk/relax cycle (or, for negative myoclonus, the relax/restore cycle). Myoclonus is distinguished from tics by the lack of suppressibility and the lack of a premonitory urge. Synchronous and rhythmic myoclonus (“myoclonic tremor”) is distinguished from chorea by the predictable timing of movements. Distinction from chorea is more difficult for asynchronous multifocal myoclonus, but this distinction is sometimes possible due to the simpler, shock-like, unidirectional movements of myoclonus compared to the more complex and often slower movement fragments commonly seen in chorea.

Although in adults myoclonus is sometimes a relatively benign sign associated with reversible acquired metabolic dysfunction, in children it is often more ominous. However, benign forms of myoclonus do occur in children as well. Myoclonus in children can be caused by disease processes that destroy or irritate gray matter, including tumors, metabolic disease, neurodegenerative disease, and acute infectious processes such as encephalitis 34-35. It is frequently associated with seizures, delirium or dementia, and other signs of neuronal dysfunction 36. Epilepsia partialis continua is unilateral rhythmic myoclonus associated with contralateral cortical injury including infection, tumor, and Rasmussen’s encephalitis 37-39.

Tremor

Tremor is a rhythmic back-and-forth or oscillating involuntary movement about a joint axis.

By “back-and-forth” we mean that there is a relatively symmetric velocity in both directions about a mid-point of the movement, and the velocity or oscillation may appear sinusoidal. Tremor is often but not always due to rhythmic alternating contraction of agonist and antagonist muscles. Tremor is labeled as a “rest tremor”, “postural tremor” or “action tremor” according to the condition of greatest severity. “Intention tremor” is a specific movement associated with cerebellar dysfunction that is characterized by worsening tremor on approach to a target. Inaccurate movements in cerebellar disease are termed “dysmetria”

and can lead to corrective movements that repeatedly overshoot and then overcorrect on attempts to contact a target. This can have the appearance of an intention tremor. The definition does not encompass certain specific tremor syndromes including palatal tremor or orthostatic tremor since these types of tremor are extremely rare or nonexistent in children.

Tremor is distinguished from myoclonus by the symmetric velocity in both directions, the lack of an obvious jerk-and-release cycle, and the existence of a mid-point of the movement. We recommend use of the term “rhythmic myoclonus” rather than “myoclonic tremor” since the former is more specific to the likely etiology. Tremor can be associated with dystonia, but when prominent features of dystonia are present it is then classified as “dystonic tremor” which is best thought of as a type of dystonia. Dystonic tremor is often less rhythmic or more irregular than other forms of tremor and may involve multiple joints or different joints depending on the posture of the limb. In some cases of dystonic tremor, there may be a “null point”, a particular posture in which the tremor is minimized. Clonus is usually easily distinguished due to the ability to trigger it on examination, but clonus may be associated with symmetric movements about a mid-point and alternating contraction of agonists and antagonists.

Tremor is not as common in children as in adults, but there are many different possible causes 40. These include hereditary disorders (essential tremor), metabolic causes (hyperthyroidism, electrolyte abnormalities), degenerative diseases (Wilson’s disease), focal lesions (“rubral” or “Holmes” tremor), medications (e.g., valproic acid), psychogenic tremor, and normal function (enhanced physiologic tremor) 41–45. Tremor is not commonly associated with bradykinetic rigid syndromes in childhood.

Tics

Tics are repeated, individually recognizable, intermittent movements or movement fragments that are almost always briefly suppressible and are usually associated with awareness of an urge to perform the movement.

Characteristic features include *predictability* of both the nature of the movement and its onset, *triggerability* by suggestion, demonstration, stress, or excitement, and brief voluntary *suppressibility*. The movements are predictable by an observer in the sense that there often is a small and identifiable number of different tic movements, and they are predictable by the child due to the presence of a premonitory urge to move. The duration of each tic movement is characteristic of that tic, and the duration does not vary between different repetitions. It is rare for children to fall, drop objects, or inadvertently injure themselves due to tic movements. However, self-injurious tics are reported in 10–15% of Tourette Syndrome. In younger children who are unable to describe the urge to move or the ability to suppress the movement, it may be more difficult to distinguish tics from other movement disorders. A characteristic feature of tics is intervening periods of normal movement.

Each child has one or more recognizable tics that are repeated in a varying sequence. Individual tics have very little variability between repetitions. The sequence may appear random, but particular movements can often be identified and counted. Tics can be classified as simple motor tics (a single brief stereotyped movement or movement fragment), complex motor tics (a more complex or sequential movement involving multiple muscle groups), or phonic tics (including simple, brief phonations or vocalizations). Children can often describe the need to tic as a requirement for “getting it just right” or “evening out”. This is particularly true of the more involved movement sequences that occur in complex motor tics. There is a high co-morbidity of tics and obsessive compulsive disorder, and such co-morbidity can make distinction between complex motor tics and compulsions difficult.

In many children, attempts at suppression of a tic lead to an increasing build-up of an urge to make the movement, often accompanied by a sensory premonition. Sometimes multiple repetitions must be made after a period of prolonged voluntary suppression. Tics wax and wane over months to years, with different tic movements appearing at different times and with different severities, and others disappearing completely. The frequency of tics may change during a single day, and often tics are more frequent during stress, fatigue, anxiety, or excitement.

Tics can include briefly sustained postures, in which case they are classified as “dystonic tics” although it is unlikely that this phenomenon shares pathophysiology with other forms of dystonia. Tics can include brief sudden jerky or shock-like movements in which case they could be termed “myoclonic tics”, which similarly are unlikely to share pathophysiology with other forms of myoclonus. However, in disorders for which tics and dystonia can co-occur (such as in neuroacanthocytosis) it can be difficult to distinguish clinically between a dystonic tic and dystonia. One possible distinction is that dystonia is usually triggered by and interferes with voluntary movement, whereas tics are usually suppressed by and do not interfere with voluntary movement.

Tics can be distinguished from athetosis, chorea, and myoclonus by the lack of continuity of the movement, the intervening periods of normal movement, and the lack of interference with ongoing tasks. Tics are also distinguished from chorea and myoclonus by the predictability and repeatability of the movements. Tics can be distinguished from tremor and stereotypies by the clear initiation and termination of each individual tic movement, and by the lack of rhythmicity in the timing of initiation of movement (although individual tics may include rhythmic shaking).

Tics are present in up to 5% of the population, with a lifetime prevalence of 20% or more among boys 46–48. Tics are a sign of pathology in rare cases, sometimes involving inflammatory or degenerative diseases of the basal ganglia 49.

Stereotypies

Stereotypies are repetitive, simple movements that can be voluntarily suppressed.

Stereotypies are typically a simple back-and-forth movement such as waving or flapping the hands or arms, and they do not typically involve more complex sequences or movement fragments. Movement is often but not always rhythmic and may involve fingers, wrists, or more proximal portions of the upper extremity. The lower extremity is not typically involved. Stereotypies can be unilateral or bilateral but are more commonly bilateral. There is probably no premonitory urge, and the movements tend to occur when the child is stressed, excited, distracted or engrossed. Stereotypies can be stopped by distraction or initiation of another activity. They do not usually interfere with the ability to perform tasks, although they can occur during excited play and briefly interrupt the ongoing activity. The stereotypy involves a single movement performed repeatedly, rather than a set of different recognizable movements. Although stereotypies have a clear beginning and ending with intervening periods of more normal movement, the duration of the stereotypy is variable and can continue for many minutes at a time if the child is not distracted by another activity.

Stereotypies are distinguished from tremor and myoclonus by the ability of the child to suppress the movement voluntarily in those cases where the child is aware of the movements or an observer attempts to interrupt them. Movements in stereotypy often involve more than one joint and can have a twisting or circular quality that is not usually present in tremor (which often affects only a single joint or muscle group). Stereotypies are distinguished from tics by the lack of a clear premonitory urge (although this is not known in children with

developmental delays). While stereotypies may sometimes contain sustained postures, they can be distinguished from dystonia by the absence of predictable worsening with attempted movement and by the long periods of normal movement between episodes. Stereotypies are distinguished from chorea and athetosis by the predictability of the phenomenology and triggers of the movement. Stereotypies do not necessarily hold the child's attention, so that they will often occur while the child is engrossed in another activity 50.

Stereotypies often accompany developmental syndromes including autism spectrum disorders 51. However, it is important to reassure parents that they can occur in the absence of any other neurological findings, and they appear to be common in healthy children throughout the preschool years 52. Therefore the presence of stereotypies by themselves does not predict any neurological diagnosis, and their value in predicting neurological outcome or narrowing a differential diagnosis in developmental disorders is minimal.

Clinical distinction between hyperkinetic impairments

Fundamental distinctions between the clinically observable aspects of different hyperkinetic movements are made on the basis of whether movement is discrete, rhythmic, random, or repetitive. Formal definitions of these concepts have been presented in the context of human movement by Hogan and Sternad 53. They define "posture" as a period of non-zero (but possibly very short) duration in which minimal movement occurs. A "discrete" movement is any movement that departs from and subsequently resumes a posture with no intervening postures. They define several concepts of "rhythmic" movement, all of which require periodic or cyclic behavior with similar movements on successive cycles. Finally, "repetitive" movements (also called "recurrent" or "reciprocal") include movements or movement elements that may revisit spatial positions or joint configurations but without a cyclic or rhythmic timing.

Thus in our definitions, dystonia is characterized by one or more repeated postures. Chorea is characterized by multiple repeated but not rhythmic movements. Athetosis is characterized by non-rhythmic movements without intervening postures. Myoclonus is characterized by repetitive and possibly rhythmic brief asymmetric shock-like movements. Tremor is characterized by rhythmic symmetric movements without intervening postures. Tics are characterized by multiple repetitive but not rhythmic movements with intervening postures that are predictable, triggerable, and suppressible. Stereotypies are characterized by intervals of rhythmic movements without intervening postures, and stereotypies are suppressible (see table 1).

Electrophysiological studies in hyperkinetic impairments

There are very few studies of the electrophysiological signature of hyperkinetic movements in children. From adult studies, we can make predictions about possible results in children but confirmation will have to await testing in this population.

The classical electrophysiological signature of dystonia consists of normal motor unit recruitment with co-contraction and overflow 54–58. However, recent studies suggest that co-contraction is not always present and, when present, does not necessarily lead to dystonic postures 14–59. Overflow of muscle activity from voluntary contraction of unrelated muscles does occur and may be more specific to dystonia than other features 57–60. An interesting feature sometimes seen in dystonia due to dyskinetic cerebral palsy is contraction of the antagonist prior to the agonist during attempts at voluntary movement, so that movement is involuntarily resisted and can occur only following antagonist relaxation. Occasionally rapid rhythmic bursting can be detected. Almost all features of the EMG in dystonia can be produced voluntarily.

Myoclonus is characterized by brief and sometimes rhythmic bursts or pauses of EMG activity 61. Bursts less than 50msec in duration are typical of cortical myoclonus, but longer bursts up to 200msec are possible, particularly in brainstem or spinal myoclonus 62. Bursts can occur synchronously in multiple muscles, including antagonists about a joint. In some forms of myoclonus, the bursts will occur in a very rapid orderly sequence progressing through different muscles, but this can only be appreciated when recording with high time resolution. Myoclonus of cortical origin may be associated with enlarged somatosensory evoked potentials and increased long-latency reflexes 62. It may also be associated with a brief potential in scalp electroencephalographic activity that is time-locked to the myoclonic jerk or negative myoclonic relaxation and that can be identified using EEG back-averaging 62, 63.

Tremor is characterized by rhythmic contractions usually of longer duration than myoclonus, but certain types of tremor may have short duration in the range typically seen for myoclonus 64. In most cases, there are alternating bursts in the agonists and antagonists about a joint, but synchronous contractions of agonists and antagonists may also occur 65.

There are very few EMG or kinematic studies of chorea, athetosis, tics, or stereotypies 66. Tics and stereotypies would be expected to have an EMG that resembles voluntary movement. The EMG in chorea consists of bursts of variable duration, amplitude, and timing.

Recommendation for clinical examination

Examination of a child with a hyperkinetic movement disorder must include a full examination for associated neurological findings. It must also include an assessment of the effect of the movement disorder on overall motor function and quality of life. It is also essential to recognize that, since movement disorders can interfere with speech, assessment of intellectual function must be performed carefully and in a manner that optimally tests the child's abilities since many children with movement disorders will have normal intelligence.

We recommend that observation of the disorder itself include several components, including the phenomenology of the disorder, the time-course, triggers and suppressibility, and the affected body parts. The phenomenology should be described in terms of duration, speed, amplitude, jerkiness, repeatability or stereotyped quality, and the number of different identifiable movements or postures. The time-course should be described in terms of rhythmicity, whether it is intermittent with intervening more normal movement, whether movements are sustained or ongoing, and whether there are discrete sub-movements or movement fragments or whether the movement appears to be continuously flowing. Possible triggers should be assessed from the history and examination, including attempted movement, posture, rest, and emotional state. Suppressibility can be tested in clinic or assessed from the history, and the presence of an urge to move can be determined in children who are able to describe it. "Distractibility" tests another aspect of suppressibility: whether unrelated mental or physical tasks (as opposed to asking the patient to voluntarily suppress) result in movement suppression. Distractibility can be seen in tics, stereotypies, and psychogenic movements.

Movements should also be described by their temporal features: are they repetitive or intermittent, uniformly patterned or variable, paroxysmal or sustained, rhythmic or non-rhythmic, and what is the frequency or rate of repetition? They can be described by the effect of volition: are they modifiable by cognitive decisions (suppressible), by sensory tricks (*geste antagoniste*) or by restraint (e.g., sitting on the hands to keep them from moving)? Is the child consciously aware of the movements, and is there any awareness or premonition of their onset? Is there a premonitory urge or a sense of release once the

movement is made? Movements can be described by the context in which they occur: postural, rest, action, or associated with specific tasks. The quality of the movement can be described: does it appear to be a normal movement or movement fragment, or are there postures or movements that exceed the normal joint range or are significantly different from voluntary movement patterns?

It is important to realize that pure forms of individual movement disorders are rare in children, particularly those with cerebral palsy. More commonly, an individual child with cerebral palsy will have a combination of two or more disorders. This is particularly true for dystonia, chorea, and athetosis that frequently coexist. For example, choreoathetosis (the combination of chorea and athetosis) is commonly seen in dyskinetic cerebral palsy, and in fact most of these children also have dystonia (see figure 1). In some cases, it may not be possible to characterize particular movements, in which case we recommend that the movement be described in terms of the features noted above with all possible classifications given. For example, a particular child might have non-rhythmic hyperkinetic movements with repeated postures and movement fragments that share elements of dystonia and chorea and might represent a combination of both.

Conclusion

We have provided a set of definitions for common hyperkinetic movements that occur in childhood. Together with previous consensus definitions of hypertonic disorders and negative signs, this provides additional taxonomy of childhood motor disorders. We hope that these definitions will be useful for communication between clinicians, for performing clinical research, and for relating the results of the research to measurable elements of the clinical examination. In the future, it will be important to establish valid and reliable clinical rating scales and quantitative measurement tools based on these definitions. Use of such tools may provide new insights and data that we hope will lead to continued refinement of the definitions. The ultimate goal is to facilitate research and clinical treatment to optimize motor function and thereby improve the lives of children with disorders of movement.

Acknowledgments

We are grateful for the support of the National Institute for Neurological Disorders and Stroke, the National Institute for Child Health and Development, the Office of Rare Disorders, the Don and Linda Carter Foundation, the Crowley Carter Foundation, and an unrestricted educational grant from Allergan Inc.

References

1. Sanger TD. Pediatric movement disorders. *Curr Opin Neurol*. 2003; 16(4):529–535. [PubMed: 12869814]
2. Sanger TD, Delgado MR, Gaebler-Spira D, Hallett M, Mink JW. Classification and definition of disorders causing hypertonia in childhood. *Pediatrics*. 2003; 111(1):e89–e97. [PubMed: 12509602]
3. Sanger TD, Chen D, Delgado MR, Gaebler-Spira D, Hallett M, Mink JW. Definition and classification of negative motor signs in childhood. *Pediatrics*. 2006; 118(5):2159–2167. [PubMed: 17079590]
4. Campbell SK. Quantifying the effects of interventions for movement disorders resulting from cerebral palsy. *J Child Neurol*. 1996; 11 Suppl 1:S61–S70. [PubMed: 8959463]
5. World Health Organization. Towards a common language for functioning, disability, and health: The International Classification of Functioning, Disability, and Health (ICF). 2002.
6. Sanger, TD.; Mink, JW. Movement Disorders. In: Swaiman, KF.; Ashwal, S.; Ferriero, DM., editors. *Pediatric Neurology: Principles and Practice*. 4th edition. Philadelphia: Mosby; 2006. p. 1271-1311.

7. Meierkord H, Fish DR, Smith SJ, Scott CA, Shorvon SD, Marsden CD. Is nocturnal paroxysmal dystonia a form of frontal lobe epilepsy? *Mov Disord.* 1992; 7(1):38–42. [PubMed: 1557065]
8. Fish DR, Sawyers D, Smith SJ, Allen PJ, Murray NM, Marsden CD. Motor inhibition from the brainstem is normal in torsion dystonia during REM sleep. *J Neurol Neurosurg Psychiatry.* 1991; 54(2):140–144. [PubMed: 2019839]
9. Mink JW. The basal ganglia: focused selection and inhibition of competing motor programs. *Prog Neurobiol.* 1996; 50(4):381–425. [PubMed: 9004351]
10. Sanger TD. Childhood onset generalised dystonia can be modelled by increased gain in the indirect basal ganglia pathway. *J Neurol Neurosurg Psychiatry.* 2003; 74(11):1509–1515. [PubMed: 14617707]
11. Sanger TD, Kaiser J, Placek B. Reaching movements in childhood dystonia contain signal-dependent noise. *J Child Neurol.* 2005; 20(6):489–496. [PubMed: 15996397]
12. Sitburana O, Jankovic J. Focal hand dystonia, mirror dystonia and motor overflow. *J Neurol Sci.* 2008; 266(1–2):31–33. [PubMed: 17888455]
13. Liu X, Taylor J, Wang S, et al. Reversal of hypertonic co-contraction after bilateral pallidal stimulation in generalised dystonia: a clinical and electromyogram case study. *Mov Disord.* 2004; 19(3):336–340. [PubMed: 15022191]
14. Malfait N, Sanger TD. Does dystonia always include co-contraction? A study of unconstrained reaching in children with primary and secondary dystonia. *Exp Brain Res.* 2007; 176(2):206–216. [PubMed: 16850323]
15. Le Ber I, Clot F, Vercueil L, et al. Predominant dystonia with marked cerebellar atrophy: a rare phenotype in familial dystonia. *Neurology.* 2006; 67(10):1769–1773. [PubMed: 17130408]
16. Jinnah HA, Hess EJ. A new twist on the anatomy of dystonia: the basal ganglia and the cerebellum? *Neurology.* 2006; 67(10):1740–1741. [PubMed: 17130402]
17. Pizoli CE, Jinnah HA, Billingsley ML, Hess EJ. Abnormal cerebellar signaling induces dystonia in mice. *J Neurosci.* 2002; 22(17):7825–7833. [PubMed: 12196606]
18. LeDoux MS, Lorden JF. Abnormal spontaneous and harmaline-stimulated Purkinje cell activity in the awake genetically dystonic rat. *Exp Brain Res.* 2002; 145(4):457–467. [PubMed: 12172657]
19. Loher TJ, Krauss JK. Dystonia Associated with pontomesencephalic lesions. *Mov Disord.* 2008
20. Blake DT, Byl NN, Cheung S, et al. Sensory representation abnormalities that parallel focal hand dystonia in a primate model. *Somatosens Mot Res.* 2002; 19(4):347–357. [PubMed: 12590836]
21. Sanger TD, Merzenich MM. Computational model of the role of sensory disorganization in focal task-specific dystonia. *J Neurophysiol.* 2000; 84(5):2458–2464. [PubMed: 11067988]
22. Swedo SE. Sydenham's chorea. A model for childhood autoimmune neuropsychiatric disorders. *Jama.* 1994; 272(22):1788–1791. [PubMed: 7661914]
23. Paz, Z.; Shoenfeld, Y.; Chapman, J. Autoimmune Chorea. In: Shoenfeld, Y.; Cervera, R.; Gershwin, ME., editors. *Diagnostic Criteria in Autoimmune Disorders.* Totowa, NJ: Humana Press; 2008. p. 445–448.
24. Benabid AL, Benazzouz A, Limousin P, et al. Dyskinesias and the subthalamic nucleus. *Ann Neurol.* 2000; 47(4 Suppl 1):S189–S192. [PubMed: 10762147]
25. Janavs JL, Aminoff MJ. Dystonia and chorea in acquired systemic disorders. *J Neurol Neurosurg Psychiatry.* 1998; 65(4):436–445. [PubMed: 9771763]
26. Cardoso F, Eduardo C, Silva AP, Mota CC. Chorea in fifty consecutive patients with rheumatic fever. *Mov Disord.* 1997; 12(5):701–703. [PubMed: 9380051]
27. Morris, et al. Athetosis I: Historical Considerations. *Movement Disorders.* 2002; 17:1278–1280. [PubMed: 12465068]
28. Foley J. The athetoid syndrome. A review of a personal series. *J Neurol Neurosurg Psychiatry.* 1983; 46(4):289–298. [PubMed: 6341510]
29. Spitz M, Costa Machado AA, Carvalho Rdo C, et al. Pseudoathetosis: report of three patients. *Mov Disord.* 2006; 21(9):1520–1522. [PubMed: 16817195]
30. Caviness JN, Brown P. Myoclonus: current concepts and recent advances. *Lancet Neurol.* 2004; 3(10):598–607. [PubMed: 15380156]

31. Hallett, M.; Shibasaki, H. Myoclonus and Myoclonic Syndromes. In: Engel, J.; Pedley, TA., editors. *Epilepsy: A Comprehensive Textbook*. Philadelphia: Lippincott Williams & Wilkins; 2008. p. 2765-2770.
32. Deuschl G, Toro C, Valls-Sole J, Zeffiro T, Zee DS, Hallett M. Symptomatic and essential palatal tremor. 1. Clinical, physiological and MRI analysis. *Brain*. 1994; 117(Pt 4):775-788. [PubMed: 7922465]
33. Deuschl G, Wilms H. Clinical spectrum and physiology of palatal tremor. *Mov Disord*. 2002; 17 Suppl 2:S63-S66. [PubMed: 11836758]
34. Berkovic SF, Cochiuș J, Andermann E, Andermann F. Progressive myoclonus epilepsies: clinical and genetic aspects. *Epilepsia*. 1993; 34 Suppl 3:S19-S30. [PubMed: 8500430]
35. Reutens DC, Puce A, Berkovic SF. Cortical hyperexcitability in progressive myoclonus epilepsy: a study with transcranial magnetic stimulation. *Neurology*. 1993; 43(1):186-192. [PubMed: 8423883]
36. Berkovic SF, Andermann F, Carpenter S, Wolfe LS. Progressive myoclonus epilepsies: specific causes and diagnosis. *N Engl J Med*. 1986; 315(5):296-305. [PubMed: 3088452]
37. Bien CG, Widman G, Urbach H, et al. The natural history of Rasmussen's encephalitis. *Brain*. 2002; 125(Pt 8):1751-1759. [PubMed: 12135966]
38. Pandian JD, Thomas SV, Santoshkumar B, et al. *Epilepsia partialis continua--a clinical and electroencephalography study*. *Seizure*. 2002; 11(7):437-441. [PubMed: 12237069]
39. Thomas JE, Reagan TJ, Klass DW. *Epilepsia partialis continua. A review of 32 cases*. *Arch Neurol*. 1977; 34(5):266-275. [PubMed: 404996]
40. Uddin MK, Rodnitzky RL. Tremor in children. *Semin Pediatr Neurol*. 2003; 10(1):26-34. [PubMed: 12785745]
41. Louis ED, Dure LSt, Pullman S. Essential tremor in childhood: a series of nineteen cases. *Mov Disord*. 2001; 16(5):921-923. [PubMed: 11746623]
42. Brewer GJ. Recognition, diagnosis, and management of Wilson's disease. *Proc Soc Exp Biol Med*. 2000; 223(1):39-46. [PubMed: 10632959]
43. Tan H, Turanli G, Ay H, Saatci I. Rubral tremor after thalamic infarction in childhood. *Pediatr Neurol*. 2001; 25(5):409-412. [PubMed: 11744318]
44. Karas BJ, Wilder BJ, Hammond EJ, Bauman AW. Valproate tremors. *Neurology*. 1982; 32(4):428-432. [PubMed: 6801541]
45. Marshall J. Physiological tremor in children. *J Neurol Neurosurg Psychiatry*. 1959; 22(1):33-35. [PubMed: 13642074]
46. Lanzi G, Zambrino CA, Termine C, et al. Prevalence of tic disorders among primary school students in the city of Pavia, Italy. *Arch Dis Child*. 2004; 89(1):45-47. [PubMed: 14709503]
47. Khalifa N, von Knorring AL. Prevalence of tic disorders and Tourette syndrome in a Swedish school population. *Dev Med Child Neurol*. 2003; 45(5):315-319. [PubMed: 12729145]
48. Kurlan R, McDermott MP, Deeley C, et al. Prevalence of tics in schoolchildren and association with placement in special education. *Neurology*. 2001; 57(8):1383-1388. [PubMed: 11673576]
49. Swedo SE, Leonard HL, Garvey M, et al. Pediatric autoimmune neuropsychiatric disorders associated with streptococcal infections: clinical description of the first 50 cases. *Am J Psychiatry*. 1998; 155(2):264-271. [PubMed: 9464208]
50. Kennedy CH, Meyer KA, Knowles T, Shukla S. Analyzing the multiple functions of stereotypical behavior for students with autism: implications for assessment and treatment. *J Appl Behav Anal*. 2000; 33(4):559-571. [PubMed: 11214031]
51. Lewis MH, Bodfish JW. Repetitive Behavior Disorders in Autism. *Mental Retardation and Developmental Disabilities Research Reviews*. 1998; 4(2):80-89.
52. Mahone EM, Bridges D, Prahme C, Singer HS. Repetitive arm and hand movements (complex motor stereotypies) in children. *J Pediatr*. 2004; 145(3):391-395. [PubMed: 15343197]
53. Hogan N, Sternad D. On rhythmic and discrete movements: reflections, definitions and implications for motor control. *Exp Brain Res*. 2007; 181(1):13-30. [PubMed: 17530234]
54. Berardelli A, Rothwell JC, Hallett M, Thompson PD, Manfredi M, Marsden CD. The pathophysiology of primary dystonia. *Brain*. 1998; 121(Pt 7):1195-1212. [PubMed: 9679773]

55. Farmer SF, Sheean GL, Mayston MJ, et al. Abnormal motor unit synchronization of antagonist muscles underlies pathological co-contraction in upper limb dystonia. *Brain*. 1998; 121(Pt 5):801–814. [PubMed: 9619186]
56. Hallett M. The neurophysiology of dystonia. *Arch Neurol*. 1998; 55(5):601–603. [PubMed: 9605716]
57. Quartarone A, Rizzo V, Morgante F. Clinical features of dystonia: a pathophysiological revisit. *Curr Opin Neurol*. 2008; 21(4):484–490. [PubMed: 18607211]
58. Berardelli A, Hallett M, et al. Single Joint Rapid Arm Movements in Normal Subjects and in Patients with Motor Disorders. *Brain*. 1996; 119:661–674. [PubMed: 8800955]
59. MacKinnon CD, Velickovic M, Drafta C, Hesquijarosa A, Brin MF. Corticospinal excitability accompanying ballistic wrist movements in primary dystonia. *Mov Disord*. 2004; 19(3):273–284. [PubMed: 15022181]
60. van der Kamp W, Berardelli A, Rothwell JC, Thompson PD, Day BL, Marsden CD. Rapid elbow movements in patients with torsion dystonia. *J Neurol Neurosurg Psychiatry*. 1989; 52(9):1043–1049. [PubMed: 2795073]
61. Chang VC, Frucht SJ. Myoclonus. *Curr Treat Options Neurol*. 2008; 10(3):222–229. [PubMed: 18579026]
62. Shibasaki H, Hallett M. Electrophysiological studies of myoclonus. *Muscle Nerve*. 2005; 31(2):157–174. [PubMed: 15547927]
63. Oguni H, Mukahira K, Uehara T, Matsuzaki M, Osawa M. Electrophysiological study of myoclonic seizures in children. *Brain Dev*. 1997; 19(4):279–284. [PubMed: 9187479]
64. Deuschl G, Krack P, Lauk M, Timmer J. Clinical neurophysiology of tremor. *J Clin Neurophysiol*. 1996; 13(2):110–121. [PubMed: 8849966]
65. Fusco C, Valls-Sole J, Iturriaga C, Colomer J, Fernandez-Alvarez E. Electrophysiological approach to the study of essential tremor in children and adolescents. *Dev Med Child Neurol*. 2003; 45(9):624–627. [PubMed: 12948330]
66. Newell KM, Inledon T, Bodfish JW, Sprague RL. Variability of stereotypic body-rocking in adults with mental retardation. *Am J Ment Retard*. 1999; 104(3):279–288. [PubMed: 10349469]

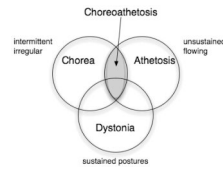


Figure 1. Schematic illustration of the overlap between several types of hyperkinetic movements. It is important to realize that the relative areas of the regions are not to scale, and the combination of chorea, athetosis, and dystonia may be more common than either of the three alone.

Table 1

Key features of hyperkinetic disorders.

	Rhythmic	Repeated posture	Repeated stereotyped movement	Suppressible
Dystonia	Rarely	Yes	Sometimes	Partial, or only briefly
Chorea	No	No	Rarely	No
Athetosis	No	No	No	No
Myoclonus	Sometimes	Sometimes	Usually	No
Tremor	Yes	No	Yes	Sometimes briefly
Tics	No	Yes	Yes	Usually
Stereotypies	Yes	Sometimes	Yes	Yes

Table 2

Elements of the clinical examination and their relation to specific hyperkinetic disorders. Distractibility = altered by irrelevant stimuli or tasks. Suppressibility = ability to suppress movements when asked. Duration = duration of individual movements. Speed = typical speed of the individual movements. Jerkiness = presence of sudden starts, stops, or changes in velocity within movements. Stereotyped = individual movements or postures are repeated and recognizable. Rhythmic = identifiable frequency of repetition of ongoing movements. Intermittent = individual movements are separated by variable intervals without abnormal movements or postures. Ongoing = absence of pauses between abnormal movements. Flowing = smooth ongoing movements without jerkiness. Submovements = abnormal movements include brief elements of recognizable intentional movements. Context = relationship to rest and voluntary movement. Predictable = the child or examiner's ability to predict the nature or timing of movement at least shortly before onset or change in movement. Normal pattern = the movement can be accurately mimicked voluntarily.

	Dystonia	Chorea	Athetosis	Myo-clonus	Tremor	Tics	Stereotypes
Distractibility	No	No	No	No	No	Yes	Yes
Suppressibility	Partial	No	No	No	Briefly	Usually	Yes
Duration	Variable	Ongoing	Ongoing	Shock-like	Ongoing	Variable	Variable
Speed	Variable	Medium-fast	Slow-medium	Very fast (<1sec)	2-14Hz	Variable	2-6Hz
Jerkiness	Sometimes	Sometimes	No	Very	Sometimes	Sometimes	Rare
Stereotyped	Often	No	No	Usually	Yes	Yes	Yes
Rhythmic	Sometimes	No	No	Sometimes	Yes	Usually not	Yes
Intermittent	Sometimes	Sometimes	No	Sometimes	Sometimes	Yes	Yes
Ongoing	Sometimes	Yes	Yes	Sometimes	Yes	No	Yes
Flowing	No	Yes	Yes	No	No	Sometimes	Sometimes
Sub-movements	No	Yes	Maybe	No	No	Sometimes	No
Context	Movement > rest	Movement > rest	Rest > movement	All	Variable	Rest	Rest
Predictable	Sometimes	No	No	No	No	Yes	Often not aware
Normal pattern	Sometimes	Yes	Yes	No	Yes	Yes	Yes