



Published in final edited form as:

J Oral Maxillofac Surg. 2008 July ; 66(7): 1439–1445. doi:10.1016/j.joms.2008.01.037.

Modified Miniplates for Temporary Skeletal Anchorage in Orthodontics: Placement and Removal Surgeries

Marie A. Cornelis, DDS, PhD, MS^{*}, Nicole R. Scheffler, DDS, MS[†], Pierre Mahy, DDS, MD[‡], Sergio Siciliano, DDS, MD[§], Hugo J. De Clerck, DDS, PhD^{||}, and J.F. Camilla Tulloch, BDS, FDS, DOrth[¶]

^{*} Consultant, Experimental Morphology Unit and Department of Orthodontics, Université Catholique de Louvain, Brussels, Belgium

[†] Private Practice, Boone, NC, and Adjunct Assistant Professor, Department of Orthodontics, University of North Carolina, Chapel Hill, NC

[‡] Consultant, Department of Oral and Maxillofacial Surgery, Université Catholique de Louvain, Cliniques Universitaires St-Luc, Brussels, Belgium

[§] Private Practice and Clinique Ste-Elisabeth, Brussels, Belgium

^{||} Private Practice, Brussels, Belgium; and Adjunct Professor, University of North Carolina, Chapel Hill, NC

[¶] Professor and Chair, Department of Orthodontics, University of North Carolina, Chapel Hill, NC

Abstract

Purpose—Skeletal anchorage systems are increasingly used in orthodontics. This article describes the techniques of placement and removal of modified surgical miniplates used for temporary orthodontic anchorage and reports surgeons' perceptions of their use.

Patients and Methods—We enrolled 97 consecutive orthodontic patients having miniplates placed as an adjunct to treatment. A total of 200 miniplates were placed by 9 oral surgeons. Patients and surgeons completed questionnaires after placement and removal surgeries.

Results—Fifteen miniplates needed to be removed prematurely. Antibiotics and anti-inflammatories were generally prescribed after placement but not after removal surgery. Most surgeries were performed with the patient under local anesthesia. Placement surgery lasted on average between 15 and 30 minutes per plate and was considered by the surgeons to be very easy to moderately easy. The surgery to remove the miniplates was considered easier and took less time. The patients' chief complaint was swelling, lasting on average 5.3 ± 2.8 days after placement and 4.5 ± 2.6 days after removal.

Conclusions—Although miniplate placement/removal surgery requires the elevation of a flap, this was considered an easy and relatively short surgical procedure that can typically be performed with the patient under local anesthesia without complications, and it may be considered a safe and effective adjunct for orthodontic treatment.

One of the most challenging problems in orthodontics is to find sufficient anchorage to achieve planned tooth movements. Conventional approaches take advantage of the differential anchorage potential in the dentition, where a larger number of teeth can resist movement of a smaller number. This often requires the additional use of compliance-dependent auxiliary

devices such as intermaxillary elastics and/or headgear. In many adult patients with partial or periodontally compromised dentition, the available anchorage is further reduced. To widen orthodontic treatment possibilities or reduce the need for compliance-dependent devices, first prosthetic implants¹ and later retromolar² and palatal implants³ were incorporated into orthodontic treatment. These devices are relatively expensive, require a healing period before orthodontic loading, and often provide only indirect anchorage. More recently, temporary skeletal anchorage devices (TSADs),⁴ which are smaller and cheaper and require shorter healing periods, have been specifically designed for orthodontic use. A miniscrew or micro-screw is a small bone screw, usually made of titanium or titanium alloy, between 1.2 and 2.2 mm in diameter and 5 to 15 mm in length. These screws are placed transmucosally with an attachment mechanism exposed in the oral cavity.⁵ Miniscrews are very popular because of their ease of placement, often by orthodontists themselves. However, miniscrews have been associated with a high risk of failure when placed in unattached gingiva,⁶ root injury can occur when they are placed in keratinized mucosa, and their position can limit the amount and direction of tooth movement. In addition, moments on the miniscrews should be avoided because they may cause screw loosening.⁵ Miniplates,⁷⁻⁹ which are modified osteosynthesis fixation devices, by contrast, present an advantage because their fixation screws are generally placed apical to the roots and so do not interfere with tooth movement: the roots can easily slide past the anchorage device.¹⁰ The connection bar of the miniplate passes through the attached gingiva, and the attachment unit is close to the dental arch (Fig 1). Miniplates may provide more secure anchorage when higher forces, such as orthopedic forces, are needed.¹¹ However, miniplates should be placed by a surgeon because this is a technique-sensitive surgery requiring flap elevation and strict asepsis. The patients' and orthodontists' perceptions of the healing process and the orthodontic treatment were previously reported.¹² However, the surgical technique and surgeon's opinion have thus far not been detailed in the existing literature. The purpose of this article is to describe the surgical technique for placement and removal of miniplates for temporary skeletal anchorage and report the surgeons' perceptions of these procedures.

Patients and Methods

Consecutive patients having miniplates placed as TSADs as part of their orthodontic treatment were identified at 2 university-based orthodontic departments. Inclusion criteria only required the subjects (and the parents of minors) to comprehend and complete a series of questionnaires. The study was approved by the institutional review boards at both the University of North Carolina at Chapel Hill (UNC) and Université Catholique de Louvain, Brussels, Belgium (UCL).

A total of 101 patients were identified; 3 declined to participate, and 1 was excluded because of problems understanding the forms. The remaining 97 patients, 30 from UNC and 67 from UCL, were enrolled (Table 1). One third of the patients were considered to be growing still. Patients completed questionnaires, in their preferred language (English or French), about swelling and medications taken after TSAD placement and removal. All patients completed the initial questionnaires; 53 patients had had their plates removed by the end of the data collection period, and 49 of these completed the removal questionnaires.

In all, 200 miniplates of 2 designs were placed (Table 1). Both devices are made of titanium. The Bollard device (Surgi-Tec, Bruges, Belgium) has either 2 (mandibular model) or 3 (maxillary model) fixation holes, a round connecting bar that perforates the mucosa, and an orthodontic attachment unit with a locking screw (Fig 2). The C-tube (KLS Martin, Umkirch, Germany) is a 2-hole titanium miniplate with a flat connection bar and a tube to allow attachment to the orthodontic appliance (Fig 2). Different types of fixation screws were used, but all were self-tapping and made of uncoated titanium (none were sandblasted or acid-etched)

and were between 5 and 7 mm in length. In the maxilla the plates were centered on the infrazygomatic crest. In the mandible the miniplates were positioned parallel to and between the roots of neighboring teeth.

Surgical placement of the TSADs in the maxilla and mandible was carried out according to the following protocol:

- L-shaped incisions were made with the horizontal part of the incision located 1 mm into the attached gingiva (Fig 3A).
- Mucoperiosteal flaps were elevated for bone exposure (Fig 3B).
- The plate was bent to fit the bone surface; importantly, the connection bar must be slightly bent at the lower limit of the plate (Fig 4, arrow a) to ensure tight contact with the bone surface where the bar emerges through the mucosa (Fig 4, arrow b), as well as good soft tissue healing.
- The hole for the middle screw for the 3-hole plates, or the screw located closest to the attachment unit for the 2-hole plates, was drilled first (Fig 3C).
- The first screw was not completely seated to allow some rotation and adjustment of the plate to an ideal position, before placement of the other screws (Fig 3D).
- All screws were subsequently tightened with a hand driver without torque control.
- After rinsing with saline solution, closure was obtained in 1 plane with resorbable sutures (Fig 3E).

Bollard devices were placed with the attachment units facing anteriorly in the posterior maxilla and mandible. In the anterior mandible (between lateral incisor and canine), the attachment units faced distal to reduce cheek and lip irritation (Fig 3F).

Miniplate placement was never combined with extractions near the TSAD placement site. If extractions had to be performed close to the site, they were performed at least 2 weeks before TSAD placement.

Patients were instructed to brush their TSADs at least twice a day. Chlorhexidine mouth rinses were recommended during the first week after placement. TSADs were loaded approximately 1 month after surgery (23.0 ± 19.6 days at UNC and 34.7 ± 26.1 days at UCL).

Miniplate removal required a short mucoperiosteal incision to expose the plate and the screws. The incision was sutured after removal and rinsing with saline solution. Patients were instructed to use chlorhexidine mouth rinses again for 3 days after surgery.

The devices were placed by 9 different oral surgeons (4 residents and 5 attending faculty). The surgeons were asked to complete a questionnaire as soon as possible after placement and removal. The questionnaires addressed the procedure complexity, the time necessary, and any complications that occurred, as well as specific details on anesthesia and medications prescribed. In addition, at removal, the surgeons evaluated the TSAD mobility, bone covering the miniplates, inflammatory response, and resistance of the screws removed. The total time that the TSADs were in place was noted. Questionnaires were completed for all placements and for 45 of 53 removals.

The surgeons' and patients' perceptions were obtained by use of 4-point categorical scales and are reported as frequencies.

The patients at UNC were paid \$20 upon completion of the last questionnaire.

Results

The success rate was 92.5%: 15 bone plates were removed prematurely. Of these failures, 11 occurred in growing patients. Of the 200 miniplates placed, 100 (15 at UNC and 85 at UCL) were removed during the study period, on average 1.5 years after placement (1.5 ± 0.7 years at UNC and 1.5 ± 0.6 years at UCL).

The medications taken by the patients are summarized in Table 2. Although antibiotics were often prescribed after the placement surgery, some patients did not follow these recommendations. Anti-inflammatories and painkillers were prescribed for over half of the patients, and again not all patients followed these recommendations.

Most of the surgeries were performed with the patient under local anesthesia, with a few being performed with intravenous sedation, or general anesthesia, typically for younger patients having more than 2 TSADs placed (Table 2).

The percentage of patients having swelling is shown in Fig 5A, with the intensity of swelling on a 4-point scale. Swelling was reported to last on average 5.3 ± 2.8 days after placement and 4.5 ± 2.6 days after removal.

Surgical complexity (Fig 5B) was reported on a scale from very easy to very difficult. More than 80% of the placement surgeries were considered by the surgeons to be very easy to moderately easy. This percentage was higher for removal. Problems were reported in less than 1 in 5 of the placement surgeries (2 Bollard devices fractured during placement manipulation, 4 mandibular Bollard devices were reported to be too long for the patients' anatomy, and patient compliance was a problem twice when the TSADs were being placed under local anesthesia). Encounters with unexpectedly thin bone at the zygomatic buttress and failure to exit the bone anchor attachment arm at the mucogingival junction did occur, which all required relocation of the miniplate and hence extended surgical time. Problems were reported in 6 of 45 removal surgeries; in 3 patients bone overgrowth over the miniplate was reported to be a problem when the screws were being removed. In 1 of those patients, the screws were partially left inside the bone. One plate fractured during removal. The surgical time, recorded in 10- or 15-minute increments, is given in Table 2.

At removal, miniplate mobility, overlying bone, inflammation, and screw resistance were evaluated, and these were scored on a 4-point scale (Fig 6). Most of the plates were stable, with very little or no bone overlying the plates and no inflammation. However, more than half of the screws exhibited at least mild to moderate resistance to removal.

Discussion

The role of a TSAD is to provide reliable stability when loaded with orthodontic forces, without damage to the adjacent structures, and allow easy connection to orthodontic appliances with minimal discomfort to patients. From this investigation, it would seem that miniplates do respect the peri-implant structures and roots while providing an orthodontic attachment unit close to the dental arch. The soft tissue irritation generated by the anchorage devices was usually very mild,¹² with the location of the connecting bar emerging at the mucogingival junction or within the attached gingiva being a key factor for good soft tissue management.¹³ Both plate systems used in this study allowed easy connection to orthodontic appliances, unlike some indirect anchorage systems (eg, soldered transpalatal arch with palatal implants), and could easily be adapted for a large range of orthodontic applications and varied during treatment. The Bollard device, which is designed to accept auxiliary wires, may perhaps provide greater flexibility in the point and direction of orthodontic force application than the C-tube (Fig 7), but it is a little more bulky. Regarding patient discomfort, although miniplate

placement does require a mucoperiosteal flap, the surgery appears to be associated with minimal perioperative pain and inconvenience,¹² but postoperative swelling was a problem that was frequently encountered.

Most of the placement surgeries can be performed with the patient under local anesthesia, with occasional use of intravenous sedation in combination with local anesthesia to aid in comfort for both adults and young children. However, it was apparent that general sedation was preferred in very young children for whom 4 miniplates must be placed for orthopaedic tractions. Removal surgeries can routinely be performed under local anesthesia alone.

This article aims to describe the surgical technique and includes a summary of several important surgical parameters necessary for miniplate success. Locating the horizontal component of the incision at the mucogingival junction, or 1 mm within the attached gingiva, appears to be important (Fig 3). If the connecting bar emerges through the unattached mucosa, it may predispose the site to inflammation and subsequent failure.¹³ However, to avoid interference with the orthodontic appliance, this incision should not be too close to the teeth. This is particularly so if tooth intrusion is intended. Good adaptation of the connecting bar to the bone at the exit point into the oral cavity is highly recommended (Fig 4). This prevents dehiscence exposing the connecting bar, which can lead to peri-implant inflammation. In the posterior maxilla, centering the miniplate on the zygomatic buttress ensures the best stability.¹⁰ The Bollard device's attachment unit allows the orthodontist to vary the point of force application by means of the auxiliary wire configuration (Fig 7). Varying the plate's position on the buttress is not recommended.

To reduce cheek irritation, the attachment units of the Bollard device should always be bent parallel to the dental arch. In the anterior mandible, attachment units facing posteriorly generated less cheek irritation than those facing anteriorly, probably because of reduced protrusion in the region of the orbicularis oris musculature.

The question as to whether self-drilling or self-tapping screws should be used cannot be answered by this study because most of the miniplates' screws were inserted after drilling. However, recently, animal data have shown that drill-free screw insertion procedures have better success rates than drilling procedures.¹⁴ For this reason, a drill-free technique should be evaluated in the future. In this sample, combining miniplate placement with extractions in the same area was avoided to reduce the risks of infection at the TSAD's site. This seems prudent because the inflammation around the extraction socket may interfere with bone and soft tissue healing. Finally, in agreement with several authors,¹⁵ excellent oral hygiene is mandatory for success. Recently, crevices around titanium orthodontic plates have been shown to be supportive of anaerobic growth of bacteria, likely stimulating peri-implant inflammation and possibly implant loosening.¹⁶

From this survey, although antibiotic coverage appeared to be the preferred protocol after placement surgery, patient compliance was inconsistent. The high success rate even without antibiotics suggests that antibiotic prophylaxis might not be so important. Clinical trials should be conducted to confirm this hypothesis. Concentration on surgical asepsis would probably further reduce the risk of introducing inflammatory pathogens at the surgical site. One quarter of the patients did not take any postoperative anti-inflammatories and/or painkillers, even when prescribed. While this may suggest that pain was not intense, swelling was a rather consistent problem, reported by the majority of the patients as mild or moderate after placement, and only slightly less of a problem after removal. Swelling is likely a side effect of the surgical flap and tissue retraction. Anti-inflammatories were given before surgery to some patients to reduce edema, but whether this goal was obtained cannot be deduced from this study. It can be hypothesized that a more systematic use of perioperative anti-inflammatories and aids such as

ice packs could reduce edema. If so, this would reduce the negative sequelae that patients report.

The surgical placement was considered very easy to moderately easy by the surgeons, even recognizing that for one third of the surgeries, this was one of the surgeon's first 10 TSAD placements. As with all surgical techniques, there seemed to be a learning curve. The removal surgery appeared both easier and less time-consuming, the main difficulty encountered being bone overgrowth over the plates. Bone covering 25% or more of the plate was reported for more than 1 in 10 of the patients, but it did not seem to be correlated with the location of the plate (maxilla or mandible, anterior or posterior) or with the age of the patient. As long as titanium is used, even uncoated, some degree of bone-screw contact does occur⁴ and might even extend to the plate. In our study the degree of bone overgrowth varied considerably from one patient to another. The reason why this phenomenon happens unequally in patients is unexplained. It is known from the experimental literature that osseointegration increases with time.¹⁷ It is thus recommended that these plates be removed as soon as they are no longer needed. Although bone overgrowth complicated the access to the screws, resistance of the screws themselves was not reported to be a problem (resistance was only mild to moderate). Whether this would be so if the devices were left in place for a long time, as might occur in young children having orthopaedic corrections, is not yet known.

In conclusion, the aim of this study was to describe the surgical placement and removal of orthodontic miniplates. Most of the surgeries were simple and performed with the patient under local anesthesia. At removal, there was no or only a mild inflammatory response. The screws did not show a high resistance during removal, but almost half of the plates were partially covered by bone overgrowth, and this was reported to be a problem during removal for 3 of 45 patients. Additional efforts to control postoperative swelling are advisable because this was the most frequent complication reported.

Acknowledgments

The authors acknowledge Dr Calix De Clercq (St-Jan's Hospital, Bruges, Belgium) and Dr Ramon Ruiz (University of North Carolina, Chapel Hill, NC), who contributed to the development of the surgical technique. They also thank Debbie Price for data management of both sites.

This study was supported in part by a grant from the Southern Association of Orthodontics, Dental Foundation of the University of North Carolina, and Fonds Spéciaux de Recherche 2004 from the Université Catholique de Louvain.

References

1. Willems G, Carels CE, Naert IE, et al. Interdisciplinary treatment planning for orthodontic-prosthetic implant anchorage in a partially edentulous patient. *Clin Oral Implants Res* 1999;10:331. [PubMed: 10551076]
2. Roberts WE, Marshall KJ, Mozsary PG. Rigid endosseous implant utilized as anchorage to protract molars and close an atrophic extraction site. *Angle Orthod* 1990;60:135. [PubMed: 2344070]
3. Wehrbein H, Feifel H, Diedrich P. Palatal implant anchorage reinforcement of posterior teeth: A prospective study. *Am J Orthod Dentofacial Orthop* 1999;116:678. [PubMed: 10587603]
4. Cornelis MA, Scheffler NR, De Clerck HJ, et al. Systematic review of the experimental use of temporary skeletal anchorage devices in orthodontics. *Am J Orthod Dentofacial Orthop* 2007;131:S52. [PubMed: 17448386]
5. Costa A, Raffaini M, Melsen B. Miniscrews as orthodontic anchorage: A preliminary report. *Int J Adult Orthodon Orthognath Surg* 1998;13:201. [PubMed: 9835819]
6. Cheng SJ, Tseng IY, Lee JJ, et al. A prospective study of the risk factors associated with failure of mini-implants used for orthodontic anchorage. *Int J Oral Maxillofac Implants* 2004;19:100. [PubMed: 14982362]

7. Umemori M, Sugawara J, Mitani H, et al. Skeletal anchorage system for open-bite correction. *Am J Orthod Dentofacial Orthop* 1999;115:166. [PubMed: 9971928]
8. Jenner JD, Fitzpatrick BN. Skeletal anchorage utilising bone plates. *Aust Orthod J* 1985;9:231. [PubMed: 3870084]
9. De Clerck H, Geerinckx V, Siciliano S. The Zygoma Anchorage System. *J Clin Orthod* 2002;36:455. [PubMed: 12271935]
10. De Clerck HJ, Cornelis MA. Biomechanics of skeletal anchorage. Part 2: Class II nonextraction treatment. *J Clin Orthod* 2006;40:290. [PubMed: 16804241]
11. Kircelli BH, Pektas ZO, Uckan S. Orthopedic protraction with skeletal anchorage in a patient with maxillary hypoplasia and hypodontia. *Angle Orthod* 2006;76:156. [PubMed: 16448286]
12. Cornelis MA, Scheffler NR, Nyssen-Behets C, et al. Patients' and orthodontists' perceptions of miniplates used for temporary skeletal anchorage: A prospective study. *Am J Orthod Dentofacial Orthop* 2008;133:18. [PubMed: 18174066]
13. Turley PK, Kean C, Schur J, et al. Orthodontic force application to titanium endosseous implants. *Angle Orthod* 1988;58:151. [PubMed: 3164593]
14. Kim JW, Ahn SJ, Chang YI. Histomorphometric and mechanical analyses of the drill-free screw as orthodontic anchorage. *Am J Orthod Dentofacial Orthop* 2005;128:190. [PubMed: 16102403]
15. Choi BH, Zhu SJ, Kim YH. A clinical evaluation of titanium miniplates as anchors for orthodontic treatment. *Am J Orthod Dentofacial Orthop* 2005;128:382. [PubMed: 16168336]
16. Sato R, Sato T, Takahashi I, Sugawara J, et al. Profiling of bacterial flora in crevices around titanium orthodontic anchor plates. *Clin Oral Implants Res* 2007;18:21. [PubMed: 17224019]
17. Melsen B, Lang NP. Biological reactions of alveolar bone to orthodontic loading of oral implants. *Clin Oral Implants Res* 2001;12:144. [PubMed: 11251664]

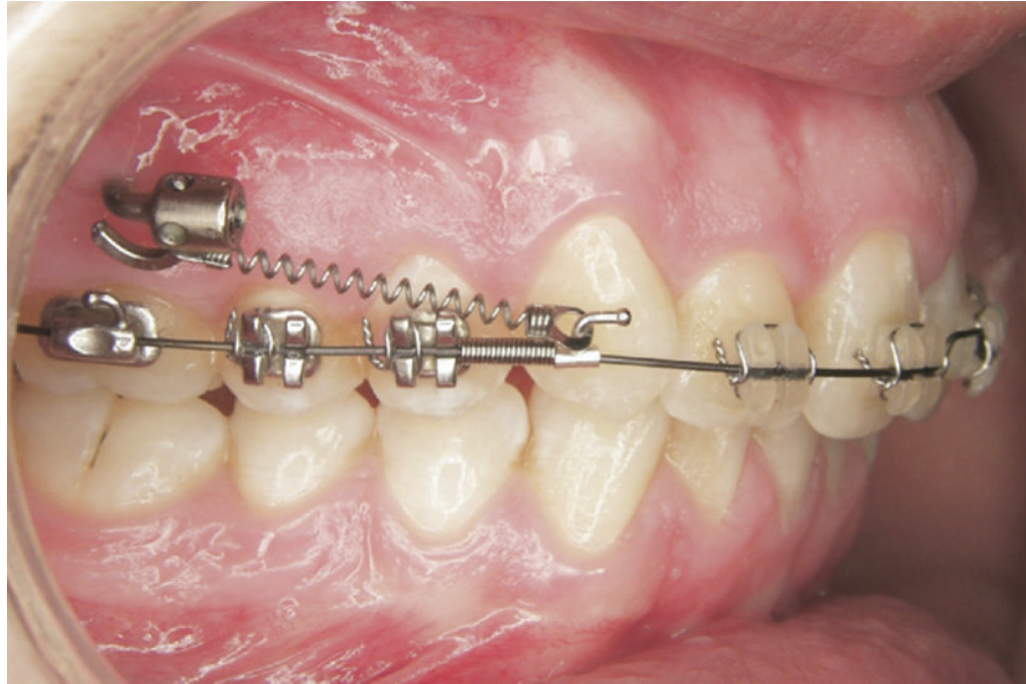

FIGURE 1. Miniplate with connection bar coming through gums at mucogingival junction. The attachment unit, located close to the dental arch, serves as anchorage to move the premolars and molars to the distal with a coil spring.

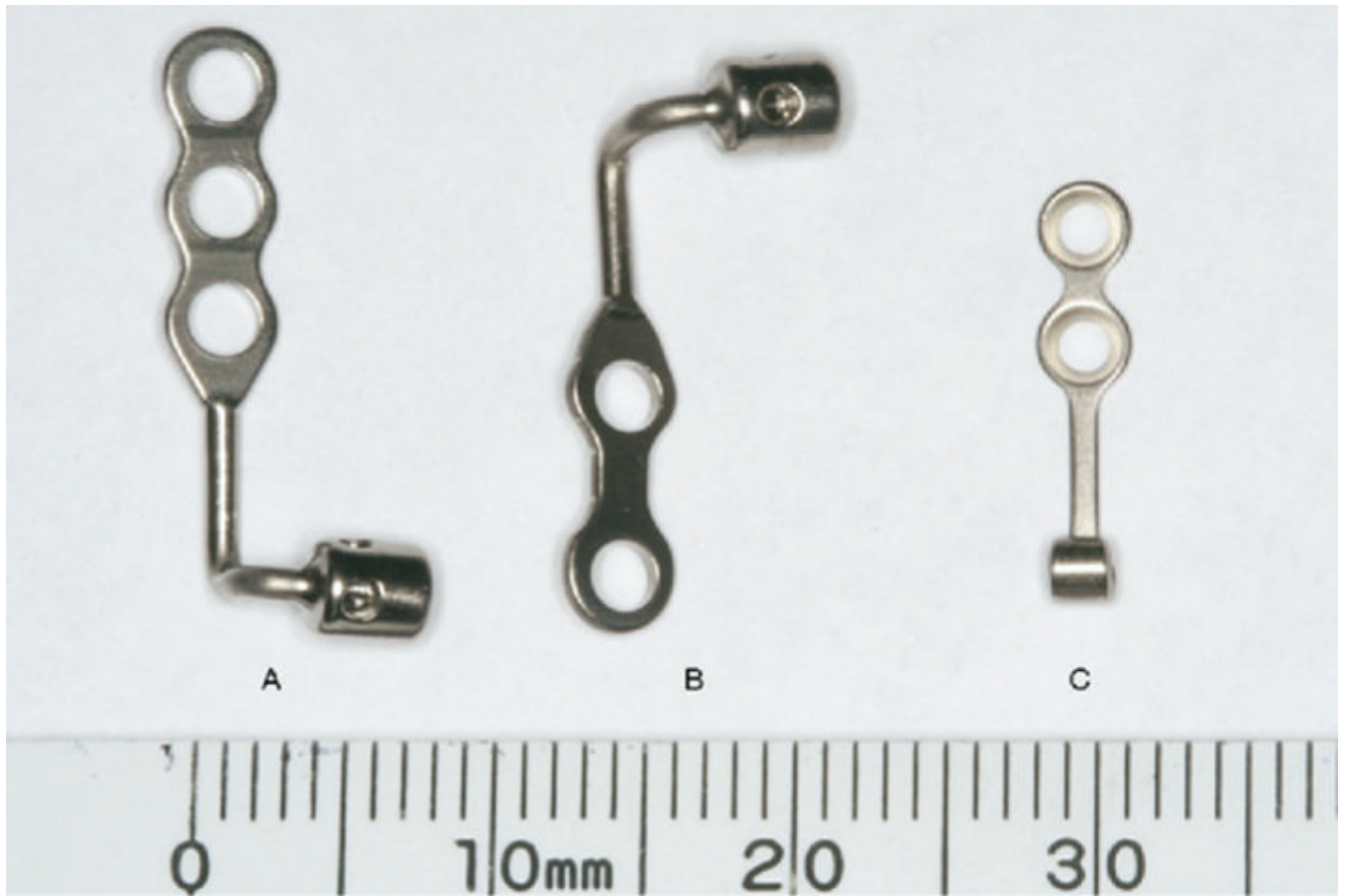


FIGURE 2.
Miniplates: Maxillary (A) and mandibular (B) Bollard device and C-tube (C).

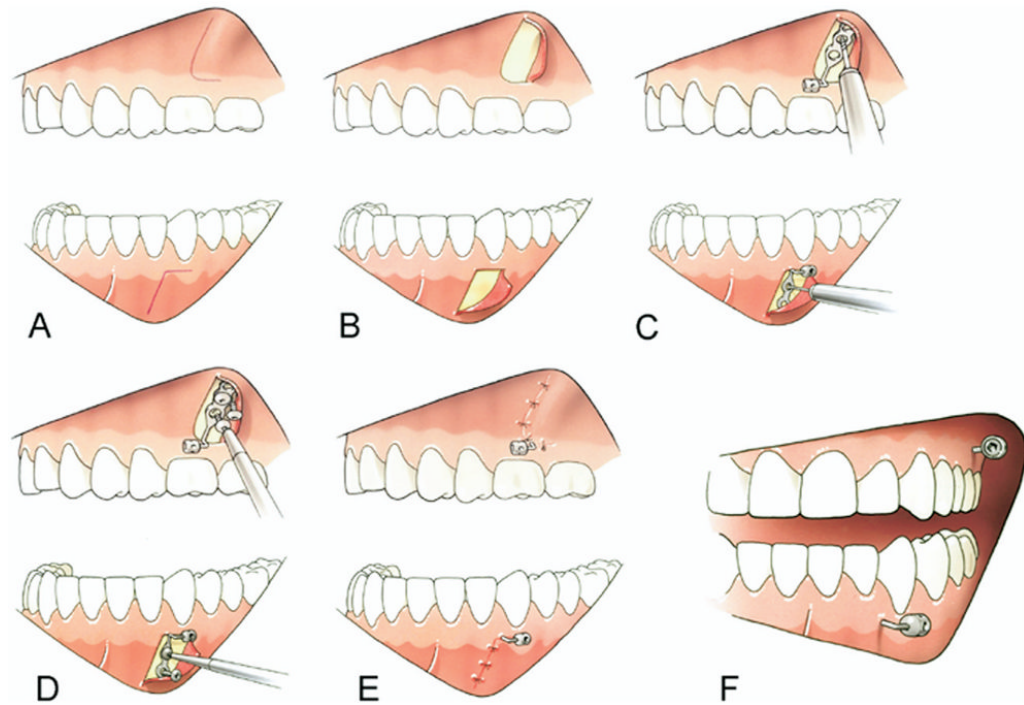


FIGURE 3.

Placement surgery in maxilla and mandible: L-shaped incisions with horizontal part of the incision being 1 mm into attached gingiva (A), mucoperiosteal flap (B), drilling of middle hole (for 3-hole plates) or hole located closest to attachment unit (for 2-hole plates) (C), insertion of screws (D), and closure with resorbable sutures (E). F, Bollard device with attachment units facing anterior in posterior maxilla and posterior in anterior mandible.

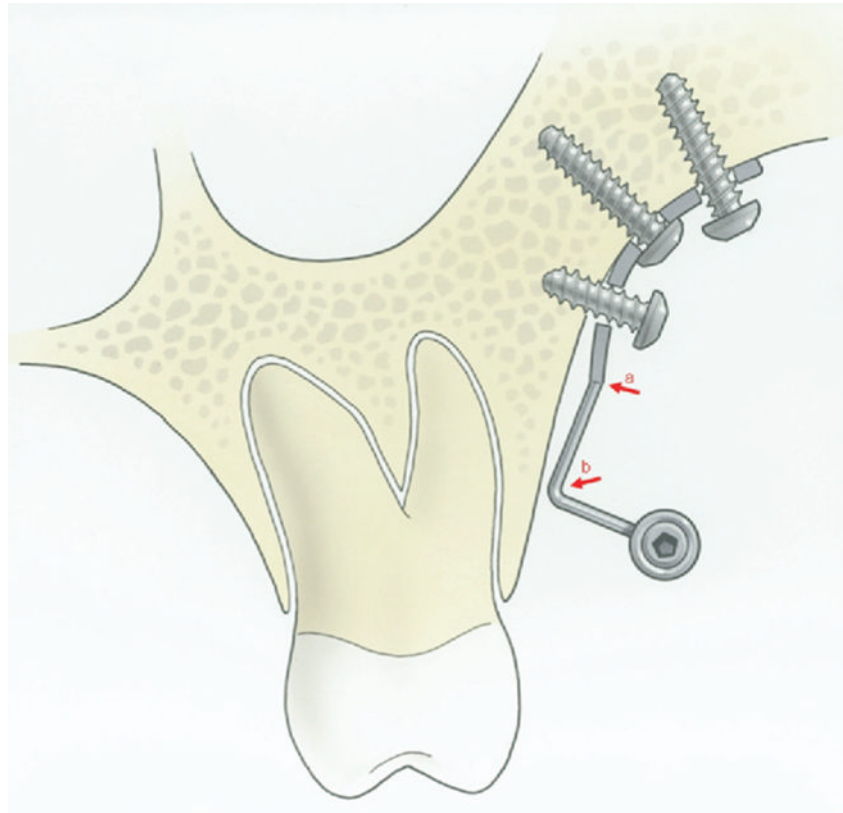


FIGURE 4. Schematic cross section through miniplate placed on infrazygomatic crest. The connection bar is slightly bent at the lower limit of the plate (*arrow a*) to ensure tight contact between the end of the connecting bar and the bony surface at the emergence point through the mucosa (*arrow b*).

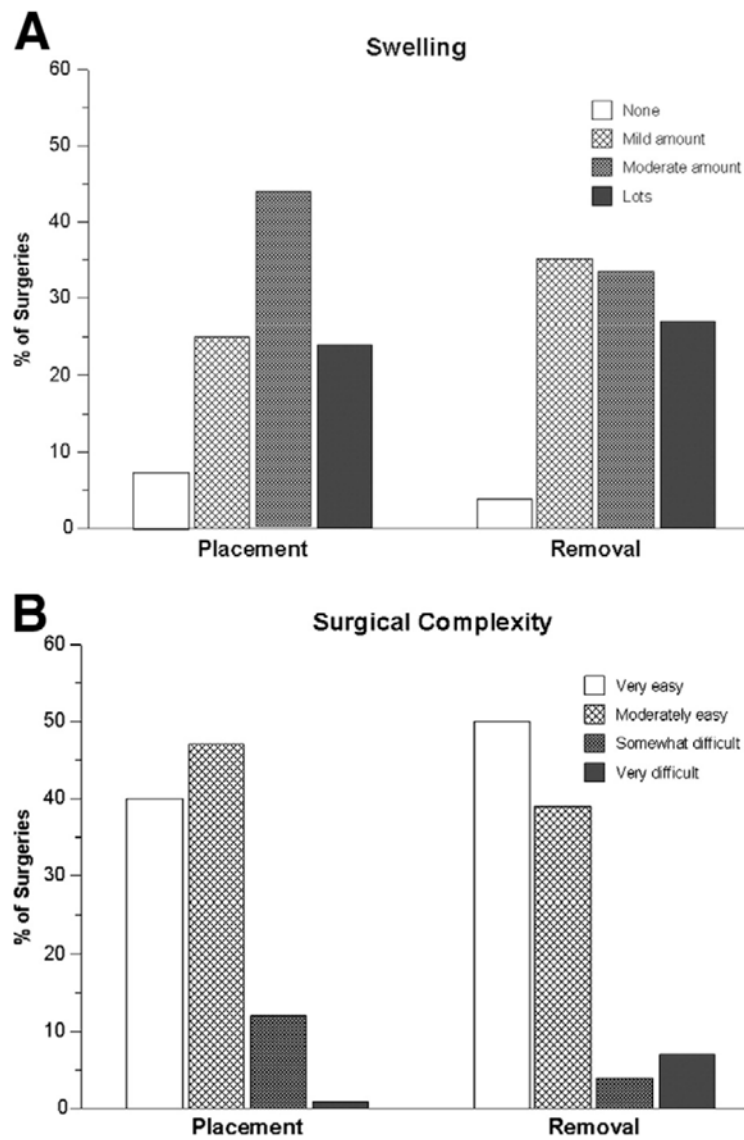


FIGURE 5. *A*, Swelling reported by patients. *B*, Surgeons' perceptions of surgical complexity: Frequencies for both placement and removal surgeries.

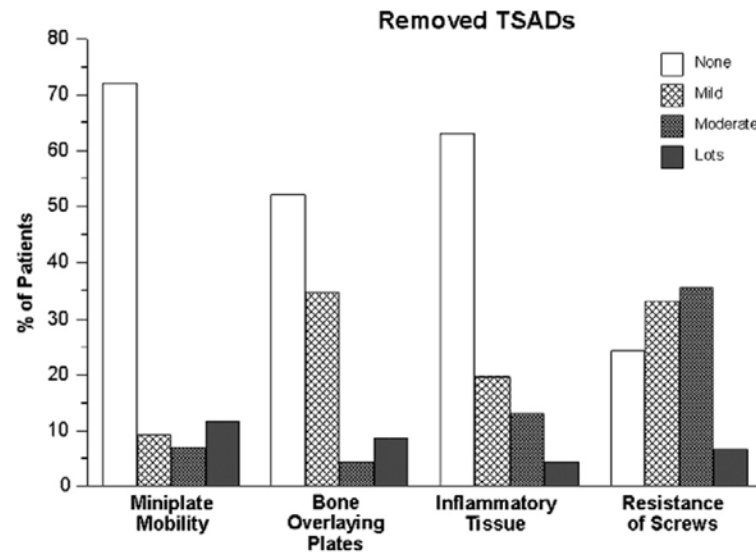


FIGURE 6. Evaluation of TSADs at removal surgery. Frequencies for mobility of miniplate, bone overlaying plates, inflammatory tissue, and resistance of screws.

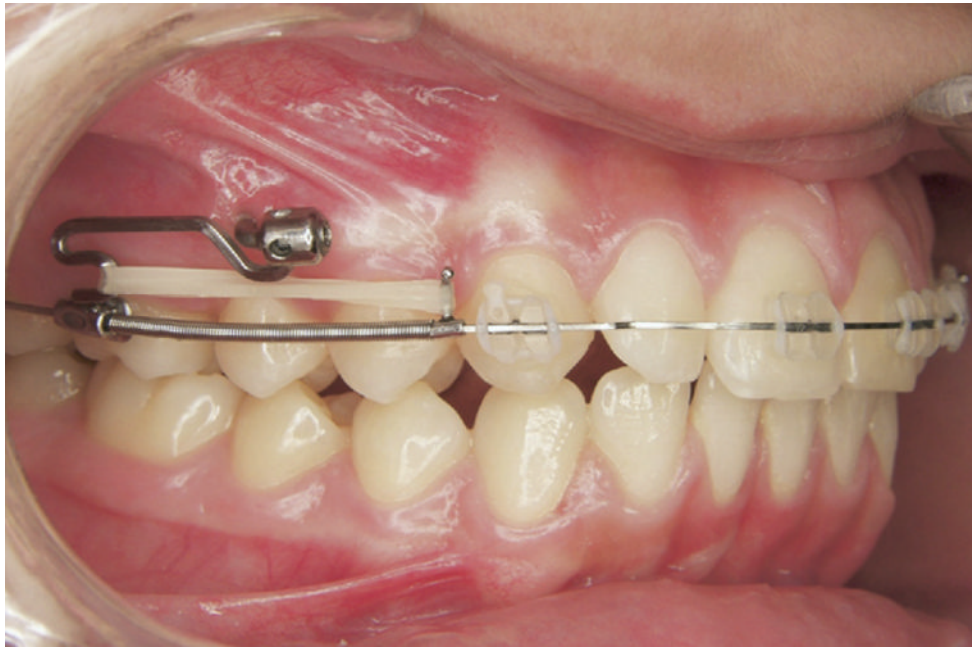


FIGURE 7. Bollard device's attachment unit with slots for insertion of wires, allowing displacement of the point of application of the force distally in this case.

Table 1
DEMOGRAPHIC DATA FOR PATIENTS AND TSADS

	UNC (n = 30)	UCL (n = 67)
Patients		
Mean age (range) (yrs)	24.0 (12.2–48.1)	23.5 (9.8–46.9)
Female (%)	73	73
Growing patients (%) *	27	36
Patients completing		
placement		
questionnaire	30	67
Patients completing		
removal		
questionnaire	7	42
Type of miniplate		
Bollard device	39	141
C-tube	20	0
Miniplate location		
Posterior maxilla	49	104
Anterior mandible	6	32
Posterior mandible	4	5

* Age 15 years or younger in female patients and age 19 years or younger in male patients.

Table 2
MEDICATIONS, ANESTHESIA, AND LENGTH OF SURGERY

	Placement (%)	Removal (%)
Medications		
Before surgery		
Antibiotics	30.9	6.5
Anti-inflammatories	17.5	13
After surgery		
Antibiotics prescribed	92.8	19.6
Antibiotics taken	71.9 (for 5.2 ± 1.7 d)	10.2 (for 3.6 ± 1.8 d)
Anti-inflammatories prescribed	72.2	58.7
Painkillers prescribed	61.9	67.4
Anti-inflammatories and/or painkillers taken	76.3 (for 6.5 ± 5.3 d)	30.9 (for 5.2 ± 4.3 d)
Anesthesia		
Local anesthesia	82.5	100
Intravenous sedation and local anesthesia	5.1	0
General sedation	12.4	0
Length of surgery		
<15 min	57.5	81.4
15–30 min	37.2	14
30–40 min	5.3	4.6