

Published in final edited form as:

Invest Ophthalmol Vis Sci. 2008 May ; 49(5): 1745–1752.

Comparison of Time-Domain OCT and Fundus Photographic Assessments of Retinal Thickening in Eyes with Diabetic Macular Edema

Matthew D. Davis¹, Susan B. Bressler², Lloyd Paul Aiello³, Neil M. Bressler², David J. Browning⁴, Christina J. Flaxel⁵, Donald S. Fong^{6,7}, William J. Foster^{8,9}, Adam R. Glassman¹⁰, Mary Elizabeth R. Hartnett¹¹, Craig Kollman¹⁰, Helen K. Li¹², Haijing Qin¹⁰, Ingrid U. Scott¹³, and the Diabetic Retinopathy Clinical Research Network Study Group¹⁴

¹Department of Ophthalmology and Visual Sciences, University of Wisconsin, Madison, Wisconsin ²Wilmer Eye Institute, Johns Hopkins University, Baltimore, Maryland ³Beetham Eye Institute, Joslin Diabetes Center, Harvard Medical School, Boston, Massachusetts ⁴Charlotte Eye, Ear, Nose and Throat Associates, Charlotte, North Carolina ⁵Casey Eye Institute, Oregon Health and Science University, Portland, Oregon ⁶Department of Ophthalmology, Kaiser Permanente Southern California, Baldwin Park, California ⁷Department of Research and Evaluation, Kaiser Permanente Southern California, Pasadena, California ⁸Department of Ophthalmology, Weill Cornell Medical College at The Methodist Hospital, Houston, Texas ⁹Department of Physics, The University of Houston, Houston, Texas ¹⁰Jaeb Center for Health Research, Tampa, Florida ¹¹Department of Ophthalmology, University of North Carolina School of Medicine, Chapel Hill, North Carolina ¹²Department of Ophthalmology and Visual Sciences, University of Texas Medical Branch School of Medicine, Galveston, Texas ¹³Department of Ophthalmology and Public Health Sciences, Penn State College of Medicine, Hershey, Pennsylvania.

Abstract

Purpose—To explore the correlation between optical coherence tomography (OCT) and stereoscopic fundus photographs (FP) for the assessment of retinal thickening (RT) in diabetic macular edema (DME) within a clinical trial.

Methods—OCT, FP, and best corrected visual acuity (VA) measurements were obtained in both eyes of 263 participants in a trial comparing two photocoagulation techniques for DME. Correlation coefficients (*r*) were calculated comparing RT measured by OCT, RT estimated from FP, and VA. Principal variables were central subfield retinal thickness (CSRT) obtained from the OCT fast macular map and DME severity assessed by a reading center using a seven-step photographic scale combining the area of thickened retina within 1 disc diameter of the foveal center and thickening at the center.

Results—Medians (quartiles) for retinal thickness within the center subfield by OCT at baseline increased from 236 (214, 264) μm in the lowest level of the photographic scale to 517 (455, 598)

Corresponding author: Adam R. Glassman, c/o Jaeb Center for Health Research, 15310 Amberly Drive, Suite 350, Tampa, FL 33647; drcrnet@jaeb.org.

¹⁴The most recently published list of the Diabetic Retinopathy Clinical Research Network can be found in *Arch Ophthalmol.* 2007; 125(4):469 – 480, with a current list available at www.dr-cr.net.

Disclosure: **M.D. Davis**, Eli Lilly (F), Novartis (F); **S.B. Bressler**, Genentech (C, R), Pfizer (C, R), Oxigene (C, R), Notal Vision (C, R), AstraZeneca (C, R), Potentia (C, R); **L.P. Aiello**, Alcon (C, F, R) and Eli Lilly (C, R), OSI Pharmaceuticals (C, R); **N.M. Bressler**, Acucele (F), Bausch and Lomb (F), Carl Zeiss Meditech (F), Genentech (F), Notal Vision (F), Novartis (F), OSI (F), Othera (F), QLT (F), Regeneron (F), Targegen (F); **D.J. Browning**, None; **C.J. Flaxel**, Genentech (F, R), OSI Pharmaceuticals (C, R); **D.S. Fong**, None; **W.J. Foster**, None; **A.R. Glassman**, None; **M.E.R. Hartnett**, None; **C. Kollman**, None; **H.K. Li**, Eli Lilly (R); **H. Qin**, None; **I.U. Scott**, Genentech (C)

μm in the highest level ($r = 0.67$). However, CSRT interquartile ranges were broad and overlapping between FP scale levels, and there were many outliers. Correlations between either modality and VA were weaker ($r = 0.57$ for CSRT, and $r = 0.47$ for the FP scale). OCT appeared to be more reproducible and more sensitive to change in RT between baseline and 1 year than was FP.

Conclusions—There was a moderate correlation between OCT and FP assessments of RT in patients with DME and slightly less correlation of either measure with VA. OCT and FP provide complementary information but neither is a reliable surrogate for VA.

The location and severity of retinal thickening and hard exudates (lipid deposits) are defining features of diabetic macular edema (DME) and correlate with concurrent visual acuity (VA) and future VA loss.^{1–3} Clinically, these abnormalities have traditionally been assessed by ophthalmoscopy and slit lamp biomicroscopy with contact or noncontact lenses. Stereoscopic fundus photographs (FP), can provide similar information and have been the standard method for documentation of diabetic retinopathy severity and DME in clinical trials.⁴

Optical coherence tomography (OCT) provides quantitative estimates of retinal thickness at multiple points within the macular region, from which a retinal thickness map can be constructed. The OCT instruments manufactured by Carl Zeiss Meditec (Dublin, CA), which were used in our trial, provide estimates of mean retinal thickness within each of nine subdivisions of the macular area and display them on a grid similar to that used in photographic grading (Fig. 1) except that the largest OCT grid (using 6-mm scans) is somewhat smaller than the photographic grid.^{4–6} Previous studies have found good agreement between clinical examination and OCT on the presence or absence of definite retinal thickening at or near the center of the macula (agreement 80%–85%, $\kappa = 0.60$ – 0.70), but considerable disagreement in eyes with more subtle thickening.^{5,7,8} Strom et al.⁹ reported good agreement (89%, $\kappa = 0.69$) on location of retinal thickening within the macular grid between FP and OCT in eyes with mild DME that in most cases was located outside of the central subfield of the grid.⁹ To our knowledge, no other studies have compared OCT and FP estimates of retinal thickening in DME.

The extent of agreement between OCT and FP may be helpful in designing future clinical studies and for developing practice guidelines. We therefore assessed the correlation between retinal thickness measured by OCT and estimated from FP with a modification of the ETDRS DME scale (see Appendix online at <http://www.iovs.org/cgi/content/full/49/5/1745/DC1>) in a randomized multicenter clinical trial comparing two photocoagulation strategies for DME. In addition, the correlation of these measures with VA was evaluated.

Methods

The design, methods, and results of the trial have been published and are summarized briefly herein.¹⁰ Best corrected electronic-ETDRS VA measurements, OCT, and FP were performed on both eyes at baseline and at follow-up visits scheduled 3.5, 8, and 12 months thereafter. Photocoagulation was performed at baseline and repeated during follow-up, according to study guidelines if DME persisted or recurred. The trial adhered to the tenets of the Declaration of Helsinki.

Participants were at least 18 years old and had type 1 or 2 diabetes mellitus. One or both eyes met the following criteria to be a study eye in the trial: (1) best corrected VA score ≥ 19 letters ($\sim 20/400$ or better), (2) definite retinal thickening (RT) due to previously untreated DME (and not primarily due to vitreoretinal interface abnormalities as determined by the investigator) within 500 μm of the macular center on clinical examination, and (3) mean OCT retinal thickness of ≥ 250 μm in the central subfield or ≥ 300 μm in at least one of the four inner subfields.

A total of 263 participants were enrolled in the trial. In 60 of these individuals, both eyes were eligible, and thus there were 323 study eyes and 203 non-study eyes. Of the non-study eyes, 58 had had prior treatment for DME and 6 had a baseline VA score of <19 letters. The remaining 139 non-study eyes, many of which had DME that was less severe than that required for eligibility, or no DME at all, were included as candidates for analysis in this report, to broaden the severity range of DME studied and to increase the dataset available for analysis. Of the 462 eyes that were candidates for analysis, 27 (6%) were excluded because of missing or ungradable images (OCT 10 eyes, FP 15 eyes, both 2 eyes) leaving a total of 435 eyes (309 study eyes and 126 non-study eyes) of 257 participants. These 435 eyes were eligible for all baseline analyses comparing OCT measurements and FP gradings. Additional analyses of relationships between these morphologic measures and VA excluded 24 eyes with ocular abnormalities other than DME identified by the reading center or by the investigator as likely to be sufficient to cause decreased VA.

Only study eyes (all of which had been treated with photocoagulation at baseline) with gradable baseline and 12-month visit photographs and OCTs were eligible for analyses examining change between baseline and 12 months ($n = 256$ study eyes; 38 eyes were excluded because of missing 12-month visits, and 15 eyes were excluded because of missing or ungradable 12-month images [3 eyes missing/7 eyes ungradable by FP; 2 eyes missing/0 ungradable by OCT; and 2 eyes missing/1 ungradable by both image types]).

The mean age of the 257 participants included in these analyses was 59 years; 40% were women. The cohort was 65% white, 18% African American, 9% Hispanic, and 8% other races. Type 2 diabetes was present in 93% of the participants. The mean duration of diabetes was 14 years and mean HbA1c was 8.1% (range, 4.6%–15.0%). Mean baseline E-ETDRS VA score for the 435 eyes included in the baseline analyses was 76 letters (~20/32). Visual acuity was 20/20 or better in 31%, 20/25 to 20/40 in 49%, 20/50 to 20/100 in 17%, and worse than 20/100 in 3% of eyes. The median (quartiles) OCT central subfield thickness of the 435 eyes was 273 (233, 364) μm . Fundus photograph gradings classified 37% of eyes in level 1 on the ETDRS DME severity scale (center of macula not involved or threatened by RT), 22% in levels 2 or 3 (center threatened or mildly involved), and 41% in levels 4 or 5 (center moderately or severely involved; see Appendix online). Retinopathy severity was graded as nonproliferative in 90% of eyes (32% mild to moderate, 46% moderately severe, and 11% severe) and as proliferative in 8% (retinopathy severity could not be assessed in 2% of the images). Eighty-eight percent of eyes were phakic, and 3% had previous scatter photocoagulation.

Procedures

OCT—After pupillary dilation radial 6 mm scans were obtained from each eye by a certified operator. The OCT 3 fast macular scan pattern was used for all measurements in 240 participants, the OCT 2 for some or all measurements in the remaining 17. Additional high-resolution (512 A scan density) cross-hair scans (6–12 and 9–3 o'clock through the center of the macula) were obtained for assessment of presence/absence of cystoid spaces, serous retinal detachment, and vitreoretinal surface abnormalities. The six radial scans were assessed by the reading center for quality, which was categorized as “good” if three criteria were met: (1) the scans were centered on the macular center, (2) the SD of the mean of the six center point values was not greater than 10%, and (3) there were no deviations of the anterior or posterior retinal borders drawn by the software in any subfield that were estimated to produce an error of greater than 10% in the thickness measurement calculated by the software for that subfield. If only the first two criteria were met, quality was considered “fair,” and any subfield failing the third criterion was designated ungradable, as was retinal volume for the eye. If the SD of the center point was greater than 10% of its value, or if obvious errors were observed in centration of the scans, the center point was measured manually, as long as other scan quality problems (e.g.,

poor signal strength) did not preclude this possibility, and the overall quality of the OCT was considered “borderline.” The manually measured center point thickness was used to impute the value for the central subfield using a regression equation, since the correlation of the two measures is 0.98.^{10,11} and only these two values were used in analysis. If a manual measurement of the center point was not possible, the OCT was considered ungradable for quantitative measures. Of the 435 eyes analyzed at baseline, OCT quality was good in 65%, fair in 20%, borderline in 15%, and ungradable in <1%. Scans of both eyes were graded concurrently by a single grader who was free to consult with a senior grader or reading-center ophthalmologist regarding difficult cases. Reproducibility of retinal thickness in the central subfield was analyzed in a previous DRCR.net report (different data set using the same methods) in which the half widths of the 95% confidence intervals for absolute and relative change between two measures were 38 μm and 11%, respectively.¹¹

The standard output from the OCT radial line pattern provides retinal thickness (inclusive of subretinal fluid, when present) in micrometers at the center point, mean thickness in each of the nine subfields, and retinal volume within the grid as a whole. Additional measures used in this report are mean *measured retinal thickness* in the inner zone (the average of the means of the central and four inner subfields, weighted by subfield area), maximum *calculated retinal thickening* in the inner zone (maximum thickening among the five subfields), and in the grid as a whole (maximum thickening among all nine subfields). *Calculated retinal thickening* was defined as measured retinal thickness minus normal thickness, using unpublished data provided by Carl Zeiss Meditec from a 2005 OCT 3 study of 260 eyes of nondiabetic individuals with normal macula in which the following mean \pm SD thicknesses were determined: central subfield, 202 \pm 22 μm ; inner superior, 269 \pm 16 μm ; inner nasal, 267 \pm 17 μm ; inner inferior, 271 \pm 16 μm ; inner temporal, 267 \pm 17 μm ; outer superior, 232 \pm 15 μm ; outer nasal, 235 \pm 23 μm ; outer inferior, 231 \pm 15 μm ; and outer temporal 237 \pm 24 μm . We have emphasized maximum calculated retinal thickening in the inner zone and measured retinal thickness in the central subfield in this report, the former because it is most congruent with the eligibility criteria for DME severity in the trial and corresponds most closely with the ETDRS DME severity scale, and the latter because it is commonly used clinically and was the principal OCT variable used in this trial.¹⁰

Fundus Photographs—ETDRS 7-standard-field FP were obtained using color film by certified photographers and sent to the reading center for grading.^{4,12} Grading methods for DME were the same as those used in the ETDRS, except that areas of retinal thickening and hard exudates were estimated as continuous variables rather than on ordinal scales.¹³ FP and OCT were evaluated independently of each other and independently of visits preceding or after the visit being graded.

Creation of Photographic DME Severity Scale—In the ETDRS, poorer VA at baseline and poorer visual outcomes were associated with larger area of retinal thickening within 1 disc diameter of the center of the macula and with greater degree of thickening at the center assessed photographically at study entry.³ ETDRS eyes were cross classified by the baseline values of each of these measures, and mean baseline VA was calculated for each cell (see Appendix online). Cells with similar VA were combined using cluster analysis and clinical judgment to produce a nine-level DME severity scale (Gangnon R, et al. *IOVS* 2005;46:ARVO E-Abstract 3269). For use in this report, the scale was modified slightly. The scale and its modifications and the reproducibility of the gradings are shown in the Appendix online (weighted κ for the scale was 0.58).

Statistical Methods

Correlations were calculated in repeated measures models (to account for the correlation between eyes) based on the likelihood ratio as defined by Magee.¹⁴ Distributions of OCT measures and VA were slightly skewed; however, truncating outliers at ± 3 SD from the mean gave similar results (data not shown). The simple κ statistic was used to describe the association between two dichotomous variables. Statistical analyses were performed with commercial software (SAS software ver. 9.1; SAS, Cary, NC).

Result

Correlations among OCT Measures at Baseline

Table 1 presents correlations among several OCT measures. Thickness at the center point and mean thickness within the central subfield correlated highly ($r = 0.99$), reflecting the central location of the center point within the relatively small area of the central subfield (< 0.5 disc area) and the tendency for retinal thickening to have a broad, gently sloping configuration. As expected, correlations between the center point and surrounding areas of retina decreased as area for comparison increased ($r = 0.88$ for mean inner zone thickness and $r = 0.69$ for retinal volume). The central subfield thickness and maximum subfield thickening in the inner zone ($r = 0.97$) and in the grid ($r = 0.95$) correlated highly, in part because the central subfield provided the maximum value for the inner zone in 60% of eyes and for the grid in 50%.

Correlations between OCT and FP

Figure 2 presents the distribution of central subfield thickness measured with OCT at baseline within each level of the modified ETDRS DME scale. The median (quartiles) for thickness increased from 236 (214, 264) μm in level 1 of the photographic scale to 517 (455, 598) μm in level 5C ($r = 0.67$). From level 2 upward, retinal thickness by OCT increased with each increase on the scale, but interquartile ranges were broad and overlapped substantially and there were many outliers.

Additional correlations between OCT and photographic measures are presented in Table 2. The first three columns are limited to measures that provide comparisons between the two methods at comparable locations: the entire grid (retinal volume versus area of thickened retina in the grid, $r = 0.74$), the inner zone (mean inner zone thickness versus area of thickened retina in the inner zone, $r = 0.69$), and at the center of the macula (center point thickness versus degree of retinal thickening at the center of the macula, $r = 0.61$). For retinal volume, the 0.74 correlation with area of thickened retina in the grid by photographic grading appeared somewhat better than the 0.59 correlation with the ETDRS DME severity scale, as would be expected since retinal volume is based on the total area within the grid, whereas the DME severity scale is restricted to the smaller inner zone. Correlations between the ETDRS DME severity scale and the various OCT measures ranged from 0.59 for retinal volume to 0.71 for maximum thickening in the grid. In the final column, which presents information for the 47 eyes in which both the OCT and the photographs were of good quality, correlations appeared to be somewhat stronger. The small number of eyes in which both photographs and OCT were graded as being of good quality was limited primarily by photographic quality (quality good, fair, and borderline, respectively, in 15%, 63%, and 20% of photographs and in 65%, 20%, and 15% of OCT scans).

No notable relationships were found with regard to correlations between the ETDRS DME severity scale and any of the OCT retinal thickness measures examined within subgroups based on area of hard exudate in fundus photographs, degree of retinal thickening, presence of cystoid spaces in OCT scans, or VA (data not shown). Serous retinal detachment and vitreo-retinal

surface abnormalities were too infrequent for meaningful analyses (7% and 3% of eyes, respectively).

Detection of Retinal Thickening in Individual Subfields: OCT versus Photography

Agreement on presence of retinal thickening within individual subfields of the grid between OCT and photography is shown in Table 3 (for OCT, retinal thickness ≥ 2 SD greater than normal; for photographs $\geq 25\%$ of the subfield thickened). With these definitions, the most frequently involved subfield was the central subfield (64% by OCT and 57% by photography; there was agreement in 73% of eyes, $\kappa = 0.44$). Involvement of the remaining subfields ranged from 34% to 61% by OCT and from 16% to 55% by photography; agreement ranged from 66% to 80% and $\kappa = 0.31$ – 0.58 . Thickening was observed more often by OCT than by photography in seven of the nine subfields. When the presence of retinal thickening detected by photography was redefined as $\geq 5\%$ of the subfield thickened, thickening was observed more often by photography than by OCT in five of the nine subfields; however, the percent of agreement and κ values were similar to those in Table 3 (data not shown).

OCT–FP Correlations at 12 Months and for Change between Baseline and 12 Months

Figure 3 presents information comparable to that in Figure 2 for 256 study eyes at the 12-month visit. The correlation between central subfield thickness and the photographic DME scale appeared somewhat weaker than that observed at baseline ($r = 0.49$ vs. $.67$). In addition, as previously shown in Figure 2, interquartile ranges were broad and overlapped substantially, and there were many outliers.

Change between baseline and 12 months as measured by OCT and estimated on the photographic DME scale for these same eyes showed a correlation of similar strength to the comparison at 12 months ($r = 0.52$; Fig. 4). Approximately 82% of the 45 eyes with improvement by three or more levels on the photographic DME scale had a decrease of at least $40 \mu\text{m}$ in central subfield thickness by OCT ($>38 \mu\text{m}$ half width of the 95% CI for replicate measures of absolute change) but agreement between the two methods appeared to be less in each of the other photographic change categories. Among the 76 eyes with no change on the photographic scale, OCT demonstrated a decrease of $40 \mu\text{m}$ or more in 30 eyes and an increase of this magnitude in six eyes.

Correlations with VA

Correlations of central subfield thickness and maximum inner zone thickening by OCT and of the ETDRS DME severity scale with VA at the baseline and 12-month visits and with change in VA between these visits are shown in Table 4. For both baseline and 12-month cohorts, baseline correlations between VA and either OCT or FP were similar (0.47 – 0.59 , first two rows of the table). For OCT the correlations with VA at 12 months and with change in VA between baseline and 12 months (0.48 – 0.55) were similar to those with VA at baseline, but for the photographic scale, they appeared weaker (0.27 and 0.29). Corresponding correlations for other OCT measures with VA (not shown in Table 4) were similar, except correlations were weakest for retinal volume ($r = 0.50$ at baseline, 0.24 at 12 months, and 0.35 for change in VA between these visits).

Discussion

The correlations between the OCT measures of retinal thickness and the photographic DME severity scale analyzed in this report ($r = 0.59$ – 0.71 , Table 2) may be characterized as moderate at best. Several factors may contribute to this result. First, in all parts of the grid except at its center point, OCT and photography assess different dimensions of retinal thickening: mean thickness by OCT, and area of thickened retina by photography. Although greater degrees of

retinal thickening are usually accompanied by greater areas of thickened retina, this is not necessarily the case. Furthermore, within any given area of retinal thickening, except at the center of the macula, the photographic grading does not distinguish between degrees of thickening. Second, photographic estimates of retinal thickening are highly dependent on good quality stereoscopic photographs. Correlations increased from the range of 0.59 to 0.71 when analyzing all the eyes in the cohort to the range of 0.71 to 0.82 when the analysis was limited to those eyes in which both the OCT and the photographs were graded as being of good quality. Finally, estimation of retinal thickness, even in good-quality photographs, depends on detection of the inner surface of the retina, which may be invisible in and near the foveal avascular zone if normal retinal transparency is maintained and hard exudates are absent.

Agreement between OCT and photography on presence or absence of retinal thickening within each subfield of the grid (Table 3) was fair to moderate, according to the guidelines suggested by Landis and Koch.¹⁵ Several factors may contribute to this result: The subfields of the OCT and photographic grids do not match exactly (Fig. 1); the density of OCT A-scans in the outer subfields is low, with 1-clock-hour wide spaces between each of the six scan lines (B-scans); the cut points for presence or absence differ, in that for OCT all A-scans in each subfield are averaged, decreasing the contribution of small focal areas of thickening, whereas in photographs such areas have full weight (and often are easily recognized). Scanning patterns that provide a greater density of A-scans in the outer subfields and algorithms that average them over smaller areas could be used to overcome some of these problems.¹⁶

Comparison of OCT and photography in assessing change between baseline and follow-up suggested that change in retinal thickness measured by OCT may be a more sensitive measure than change on the ETDRS DME scale (Fig. 4). Given the limited reliability of change by only one step on the photographic scale (see Appendix online), it seems appropriate to pool the no-change, one-level-improved and one-level-worsened categories in Figure 4 as no definite change. If this concept had been applied, 134 eyes would have been considered stable by the photographic measure; however, 53 (40%) of these eyes had a decrease in retinal thickening of $\geq 40 \mu\text{m}$ by OCT assessment, an amount sufficient to make measurement error an unlikely explanation.

The correlations of OCT measurements of central subfield thickness and maximum thickening in the inner zone with concurrent VA were only modest ($r = 0.53\text{--}0.59$, Table 4) and similar to those reported previously for OCT center point and visual acuity.¹⁷ Correlation between photographic gradings and VA were similar ($r = 0.47\text{--}0.50$) at baseline to those between OCT measurements and VA, but tended to be lower at 1 year ($r = 0.29$) than that between OCT and VA.

Overall, these analyses support the use of OCT as the principal method for documenting retinal thickness and particularly for observing change in retinal thickness in eyes with DME in clinical trials. OCT provides quantitative estimates of change that appear to be more sensitive and more reproducible than change on the ordinal ETDRS DME severity scale. OCT also has practical advantages. Acquisition of good-quality OCT scans is generally easier for the OCT operator to accomplish, easier for the patient to undergo given the more limited light exposure, and less time consuming for both patient and operator. In addition, the scan quality is less likely to be compromised by mild lens opacities or limited pupillary dilation.

Our study is limited by exclusion of assessment of OCT and FP information on most aspects of DME other than retinal thickness. It is well known, however, from clinical experience that time domain OCT is less suitable than fundus photography for documenting location and severity of other morphologic features of DME, such as hard exudates, retinal hemorrhages,

microaneurysms, and vascular abnormalities. Furthermore, OCT cannot provide information on overall retinopathy severity, for which FP remains the gold standard.

In summary, in our analyses there was a moderate correlation between OCT measurements of retinal thickness and a DME severity scale based on gradings of retinal thickening in stereoscopic fundus photographs and between these measures and VA. OCT provides a more sensitive and reproducible measure of retinal thickening but is less suitable for documenting other morphologic features of diabetic retinopathy and DME than is FP. However, changes in these measures do not necessarily reflect changes in VA, particularly for a specific individual. The decision to use either, both, or neither of these modalities in a particular clinical research study depends largely on the focus of the study and the primary study question.

Acknowledgements

Supported by a cooperative agreement from the National Eye Institute, Grants EY14231, EY14269, and EY14229.

References

1. Early Treatment Diabetic Retinopathy Study research group. Photocoagulation for diabetic macular edema. Early Treatment Diabetic Retinopathy Study report number 1. *Arch Ophthalmol* 1985;103:1796–1806. [PubMed: 2866759]
2. Early Treatment Diabetic Retinopathy Study Research Group. Photocoagulation for diabetic macular edema: ETDRS report number 4. *Int Ophthalmol Clin* 1987;27:265–272. [PubMed: 3692708]
3. Early Treatment Diabetic Retinopathy Study Research Group. Focal photocoagulation treatment of diabetic macular edema: relationship of treatment effect to fluorescein angiographic and other retinal characteristics at baseline. ETDRS report no. 19. *Arch Ophthalmol* 1995;113:1144–1155. [PubMed: 7661748]
4. Early Treatment Diabetic Retinopathy Study Research Group. Grading diabetic retinopathy from stereoscopic color fundus photographs: an extension of the modified Airlie House classification. ETDRS report number 10. *Ophthalmology* 1991;98:786–806. [PubMed: 2062513]
5. Hee M, Puliafito C, Duker J, et al. Topography of diabetic macular edema with optical coherence tomography. *Ophthalmology* 1998;105:360–370. [PubMed: 9479300]
6. Massin P, Erginay A, Haouchine B, Mehidi AB, Paques M, Gaudric A. Retinal thickness in healthy and diabetic subjects measured using optical coherence tomography mapping software. *Eur J Ophthalmol* 2002;12:102–108. [PubMed: 12022281]
7. Brown JC, Solomon SD, Bressler SB, Schachat AP, DiBernardo C, Bressler NM. Detection of Diabetic Foveal Edema: contact lens biomicroscopy compared with optical coherence tomography. *Arch Ophthalmol* 2004;122:330–335.
8. Browning DJ, McOwen MD, Bowen RM, O'Marah TL. Comparison of the clinical diagnosis of diabetic macular edema with diagnosis by optical coherence tomography. *Am Acad Ophthalmol* 2004;111:712–715.
9. Strom C, Sander B, Larsen N, Larsen M, Lund-Andersen H. Diabetic macular edema assessed with optical coherence tomography and stereo fundus photography. *Invest Ophthalmol Vis Sci* 2002;43:241–245. [PubMed: 11773037]
10. Diabetic Retinopathy Clinical Research Network. Comparison of the modified early treatment diabetic retinopathy study and mild macular grid laser photocoagulation strategies for diabetic macular edema. *Arch Ophthalmol* 2007;125:469–480. [PubMed: 17420366]
11. Diabetic Retinopathy Clinical Research Network. Reproducibility of macular thickness and volume using Zeiss optical coherence tomography in patients with diabetic macular edema. *Ophthalmology* 2007;114:520–525. [PubMed: 17141315]
12. Early Treatment Diabetic Retinopathy Study Research Group. Fundus photographic risk factors for progression of diabetic retinopathy. ETDRS report number 12. *Ophthalmology* 1991;98:823–833. [PubMed: 2062515]

13. Gardner TW, Sander B, Larson ML, et al. An extension of the early treatment diabetic retinopathy study (EDTRS) system for grading of diabetic macular edema in the astemizole retinopathy trial. *Curr Eye Res* 2006;31:535–547. [PubMed: 16769613]
14. Magee L. R^2 measures based on Wald and likelihood ratio joint significance tests. *Am Stat* 1990;44:250–253.
15. Lanids JR, Koch GG. The measurement of observer agreement for categorical data. *Biometrics* 1977;33(1):159–174. [PubMed: 843571]
16. Sadda SR, Tan O, Walsh AC, Schuman JS, Varma R, Huang D. Automated detection of clinically significant macular edema by grid scanning optical coherence tomography. *Ophthalmology* 2006;113:1187–1196. [PubMed: 16647123]
17. Diabetic Retinopathy Clinical Research Network. Relationship between optical coherence tomography-measured central retinal thickness and visual acuity in diabetic macular edema. *Ophthalmology* 2007;114:525–536. [PubMed: 17123615]

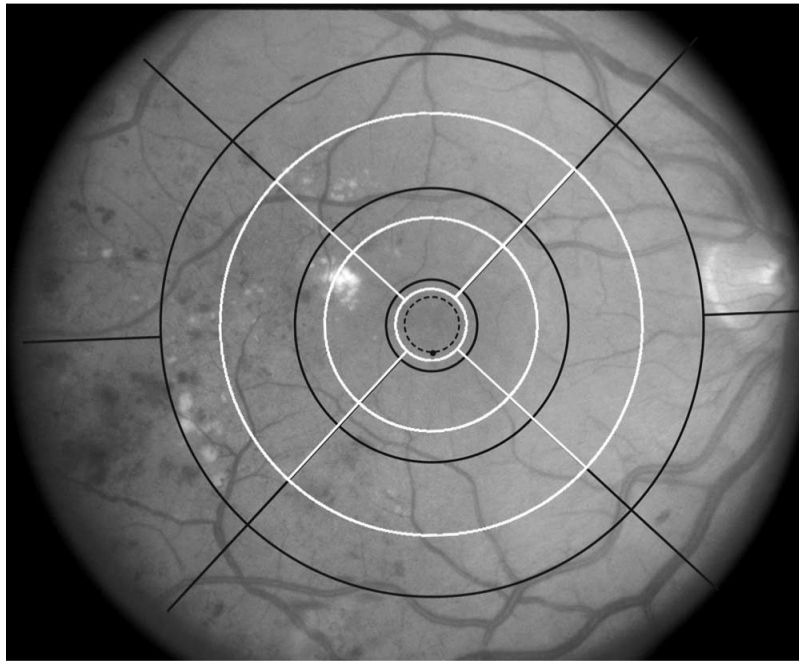


Figure 1.

Comparison of ETDRS (*black*) and OCT (*white*) macular grids. When centered on the macula, the *solid circles* and *radial lines* divide the area within the grid into nine subdivisions (subfields): one central, four inner, and four outer. The central and four inner subfields combined comprise the inner zone. The diameter of the ETDRS grid is four standard disc diameters, and its area is 16 disc areas. In the ETDRS, the historical precedent for considering the diameter of the average normal disc to be 1500 μm was adopted, resulting in designations of 6000, 3000, and 1000 μm for the diameters of the three *solid circles*. With the advent of photodynamic therapy and digital fundus photography, 1800 μm has been adopted as a more realistic estimate of the diameter of the average normal disc. With this convention, the diameters of the ETDRS grid may be expressed as 7200, 3600, and 1200 μm , whereas those of the OCT grid remain 6000, 3000, and 1500 μm .

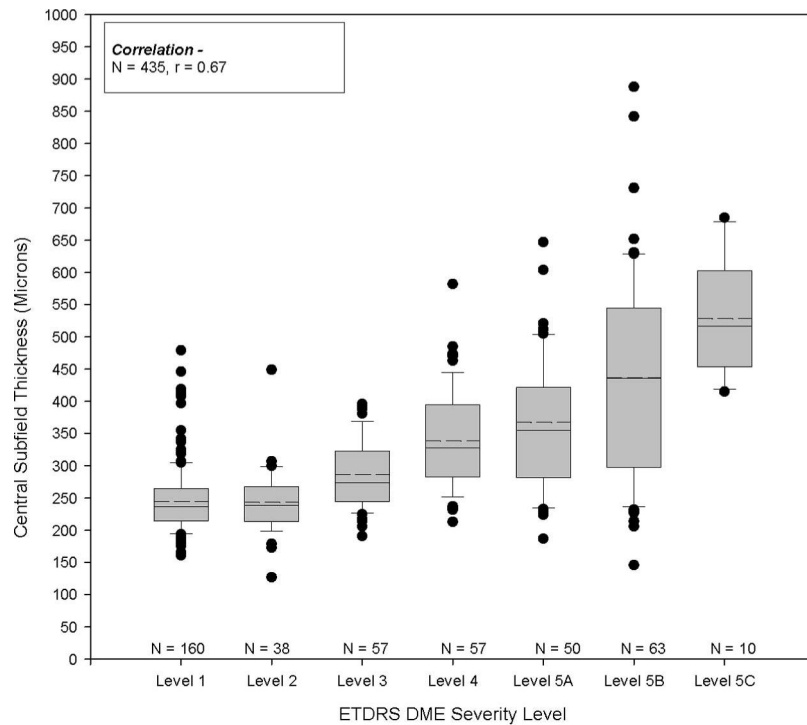


Figure 2. Distribution of retinal thickness in the central subfield by ETDRS DME severity level at baseline. The *boxes* indicate 25th to 75th percentiles and the *whiskers* the 10th and 90th percentiles. *Solid line*: median; *dashed line*: mean.

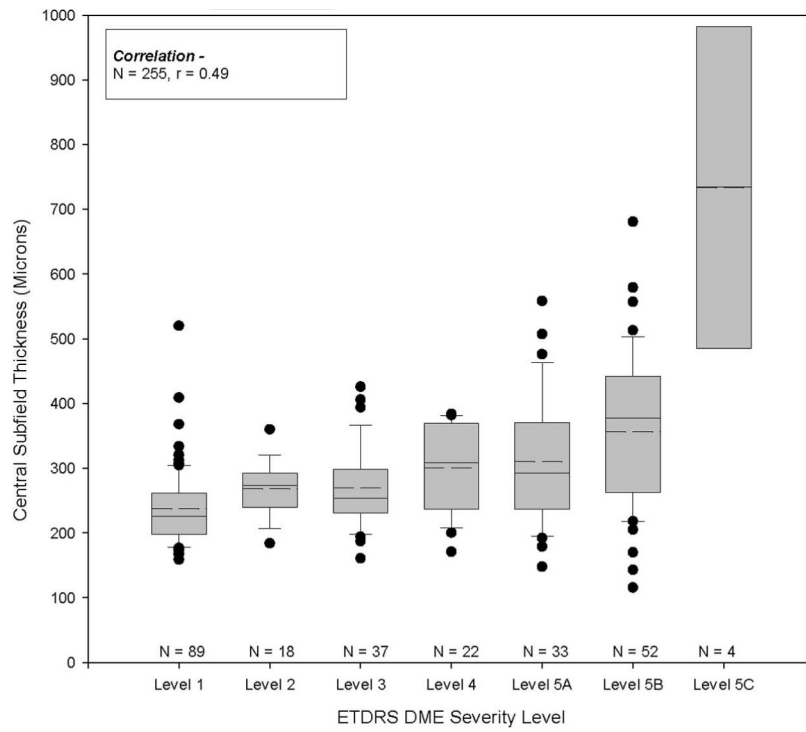


Figure 3. Distribution of retinal thickness in the central subfield by ETDRS DME severity level at 12 months. The plots are as described in Figure 2.

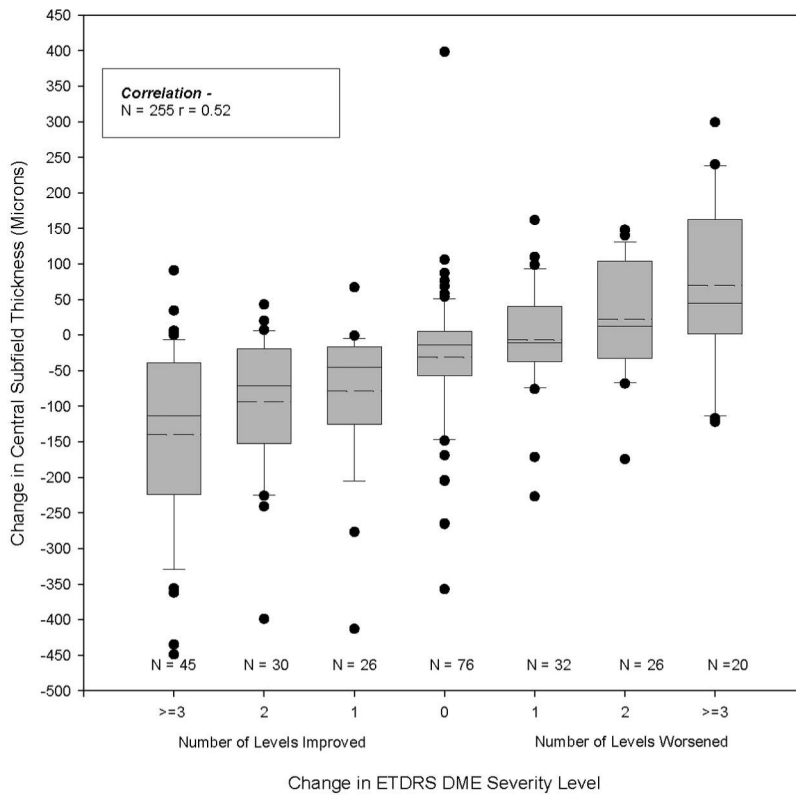


Figure 4. Distribution of baseline to 12-month change in retinal thickness in the central subfield by change in ETDRS DME severity level. Negative change in OCT values indicates decrease in thickening.

Table 1

Correlation between OCT Measures

	Center Point Thickness	Central Subfield Thickness	Maximum Subfield Thickening in the Inner Zone	Maximum Subfield Thickening in the Grid	Mean Inner Zone Thickness	Retinal Volume
Center point thickness	1					
Central subfield thickness	—	0.99	0.95	0.92	0.88	0.69
Maximum thickening in the inner zone*	—	—	0.97	0.95	0.93	0.76
Maximum thickening in the grid*	—	—	1	0.99	0.95	0.82
Mean inner zone thickness [†]	—	—	—	1	0.95	0.85
Retinal volume [‡]	—	—	—	—	1	0.92
						1

N = 435.

* Thickening was defined as observed thickness minus mean normal thickness (normal thickness from Carl Zeiss Meditec, Dublin, CA).

[†] Average weighted inner zone thickness = central subfield weighted 1 and each of 4 inner subfields weighted 2. Data missing for 15 eyes.

[‡] Data missing for 71 eyes.

Correlation between OCT and Photographic Measures at Baseline

Table 2

OCT Measures	Photographic Measures			ETDRS DME Severity Scale, OCT and Photos Good Quality (n = 47)
	Area of Thickened Retina in the Grid	Area of Thickened Retina in Inner Zone	Degree of Retinal Thickening at Center of Macula	
Center point thickness			0.61	0.79
Central subfield thickness				0.79
Maximum thickening in the inner zone*				0.80
Maximum thickening in the grid*		0.69		0.82
Mean inner zone thickness [†]	0.74			0.76
Retinal volume [‡]				0.71

N = 435.

* Thickening defined as observed thickness minus mean normal thickness (normal thickness from Carl Zeiss Meditec, Dublin, CA).

[†] Average weighted inner zone thickness = central subfield weighted and each of 4 inner subfields weighted 2. Data missing for 15 eyes.

[‡] Data missing for 71 eyes.

Summary of Agreement between OCT and Fundus Photographs on Presence of Retinal Thickening in Each Subfield of the Macular Grid*

Table 3

Subfield	Agreement		Disagreement		κ	Agreement (%)
	OCT Thick/ Photo Thick ^{†‡}	OCT Not Thick/ Photo Not Thick [§]	OCT Thick/Photo Not Thick	OCT Not Thick/ Photo Thick		
Central	205	112	73	42	0.44	73
Inner superior	167	134	82	27	0.47	73
Inner nasal	111	164	116	22	0.35	67
Inner inferior	127	166	82	30	0.45	72
Inner temporal	174	133	49	50	0.51	76
Outer superior	120	148	127	14	0.36	66
Outer nasal	57	226	118	10	0.31	69
Outer inferior	70	222	109	10	0.37	71
Outer temporal	118	207	21	60	0.58	80

* Excludes eyes with ungradable OCTs or photos: 3 for central (3 OCTs, 0 photos), 25 for inner superior (21 OCTs, 4 photos), 22 for inner nasal (19 OCTs, 3 photos), 30 for inner inferior (23 OCTs, 7 photos), 29 for inner temporal (22 OCTs, 7 photos), 26 for outer superior (25 OCTs, 1 photo), 24 for outer nasal (20 OCTs, 4 photos), 24 for outer inferior (20 OCTs, 4 photos), 29 for outer temporal (27 OCTs, 2 photos).

[†] OCT thick in specified subfield means measurement is \geq mean normal thickness + 2 SD (mean normal thickness defined by Zeiss OCT 3; Carl Zeiss Meditec, Dublin, CA).

[‡] Photo thick in specified subfield means an area of thickened retina exists and occupies $\geq 25\%$ of subfield.

[§] OCT not thick in specified subfield means measurement is $<$ normal thickness + 2 SD (mean normal thickness defined by Zeiss using OCT 3; Carl Zeiss Meditec).

^{//} Photo not thick in specified subfield means any area of thickened retina is $< 25\%$ of subfield.

Table 4

Correlation of Visual Acuity with OCT Measurements and with the ETDRS DME Severity Scale*

Visual Acuity	<i>n</i>	Fundus Photographs ETDRS DME Severity Scale (<i>r</i>)	OCT Measurements	
			Central Subfield Thickness (<i>r</i>)	Maximum Thickening in the Inner Zone [†] (<i>r</i>)
Baseline (primary cohort)	411	0.47	0.57	0.59
Baseline (follow-up cohort)	223	0.50	0.54	0.57
12 Months	223	0.29	0.53	0.55
Change from baseline to 12 months	223	0.27	0.48	0.50

* Excludes eyes with abnormality other than DME on clinical examination, reducing acuity by three lines according to the investigator's opinion, and eyes with moderate or worse lens opacity with acuity worse than 20/32: 24 eyes at baseline and 33 eyes at 12 months.

[†] Defined as observed thickness minus the mean normal thickness.