

Available online at www.sciencedirect.com

journal homepage: <http://Elsevier.com/locate/radcr>

Gastrointestinal

Gallbladder agenesis mimicking cholelithiasis in an adult

Andrew M. Moon MD, MPH^{a,*}, J. Hamilton Howe MD^b, Katrina A. McGinty MD^b,
David A. Gerber MD^{c,d}

^a Division of Gastroenterology and Hepatology, University of North Carolina School of Medicine, 130 Mason Farm Rd, Bioinformatics Building CB# 7080, Chapel Hill, NC 27599-7080, USA

^b Department of Radiology, University of North Carolina School of Medicine, Chapel Hill, NC, USA

^c Department of Surgery, University of North Carolina School of Medicine, Chapel Hill, NC, USA

^d Lineberger Cancer Center, University of North Carolina, Chapel Hill, NC, USA

ARTICLE INFO

Article history:

Received 10 December 2017

Accepted 8 March 2018

Available online 4 April 2018

Keywords:

Ultrasound

Magnetic resonance

cholangiopancreatography

Gallbladder agenesis

Cholelithiasis

ABSTRACT

We present the case of a 24-year-old woman with morbid obesity who came to the emergency department with right upper quadrant abdominal pain associated with nausea and vomiting. Her workup included a right upper quadrant ultrasound suggestive of a small gallbladder with cholelithiasis without sonographic evidence of acute cholecystitis. She underwent attempted laparoscopic cholecystectomy with no identifiable gallbladder during surgery. Post-surgical cross-sectional imaging confirmed gallbladder agenesis. This case provides an example of a rare but convincing clinical and radiologic mimic of cholelithiasis. In certain cases of biliary colic and imaging revealing a small gallbladder, a magnetic resonance cholangiopancreatography may be warranted to evaluate gallbladder agenesis and avoid unnecessary surgery.

© 2018 the Authors. Published by Elsevier Inc. under copyright license from the University of Washington. This is an open access article under the CC BY-NC-ND license (<http://creativecommons.org/licenses/by-nc-nd/4.0/>).

Introduction

Gallbladder agenesis occurs in 10–65 per 100,000 people, presents predominantly in women (ratio 3:1), and results from either failure of the cystic bud to develop into the gallbladder and cystic duct in utero or failed recanalization of the cystic duct and gall-

bladder [1]. Its presentation is variable—it is asymptomatic in an estimated 35% of patients, later being discovered incidentally during abdominal surgery or at autopsy, presents with other fatal fetal anomalies in 15%–16%, and is accompanied by typical symptoms in 50% [1]. Typical symptoms include right upper quadrant pain, fatty food intolerance, nausea, and jaundice, making it a convincing mimic of cholecystitis and biliary colic.

Competing Interests: The authors have declared that no competing interests exist.

Disclaimer: This material has not been previously published or presented at a scientific meeting and is not under consideration elsewhere. Informed consent was obtained by the patient included in this manuscript.

Authors' Contributions: All authors approved the final version of this manuscript. Andrew M. Moon is the guarantor of this paper. Andrew M. Moon, J. Hamilton Howe, Katrina A. McGinty, and David A. Gerber are responsible for the design and concept, drafting, and revision of manuscript.

* Corresponding author.

E-mail address: Andrew.Moon@unchealth.unc.edu (A.M. Moon).

<https://doi.org/10.1016/j.radcr.2018.03.002>

1930-0433/© 2018 the Authors. Published by Elsevier Inc. under copyright license from the University of Washington. This is an open access article under the CC BY-NC-ND license (<http://creativecommons.org/licenses/by-nc-nd/4.0/>).

The median age of gallbladder agenesis diagnosis is reported to be 46 years old [2]. However, given the rarity of gallbladder agenesis and the significant heterogeneity in clinical presentation, the age of diagnosis is likely to be highly variable. It is reasonable to assume that cases of gallbladder agenesis associated with fetal anomalies are diagnosed in childhood, whereas asymptomatic patients are only diagnosed incidentally if abdominal ultrasound or cross-sectional imaging of their abdomen is obtained. Gallbladder agenesis has been reported in association with trisomy 18, Klippel-Feil syndrome, and both fatal and nonfatal fetal anomalies including imperforate anus, duodenal atresia, biliary atresia, ventricular septal defects, intestinal malrotation, choledochal cyst, and choledochectasia [1,3].

It has been proposed that biliary dyskinesia and choledocolithiasis are the primary causes of pain in patients with gallbladder agenesis, similar to postcholecystectomy syndrome [4]. For cases in which gallbladder agenesis is confirmed and choledocolithiasis is excluded, conservative management with smooth muscle relaxants or biliary sphincterotomy for refractory cases can be considered [5].

The following case report demonstrates how gallbladder agenesis can potentially mimic a small gallbladder with cholelithiasis on limited right upper quadrant ultrasound, which could potentially expose a patient to unnecessary surgery. It is important for radiologists to be aware of gallbladder agenesis and to recommend alternative imaging in cases where gallbladder agenesis is suspected.

Case report

We present the case of a recently treated 24-year-old woman with a medical history of morbid obesity (body mass index of 43.6 kg/m²) who came to the emergency department with 1-2 weeks of right upper quadrant pain described as sharp, intermittent, radiating to the back, and associated with nausea and vomiting. The pain was not exacerbated or alleviated by eating and she denied changes in bowel habits or urinary symptoms. She also described distinct substernal burning pain worse when lying down and at night. She denied other medical history or family history of gastrointestinal diseases. She had a surgical history of tonsillectomy. She reported smoking a half pack per day of tobacco and denied alcohol or illicit drug use. Her only medication was occasional ibuprofen use for menstrual cramps. On examination, she had normal vital signs and mild abdominal pain in the upper abdomen. Laboratory tests were notable for white blood cell count of 17,400 cells/ μ L with normal differential percentages and platelet count of 439,000 cells/ μ L. She had a normal basic metabolic panel, bilirubin, aspartate transaminase (AST), alanine transaminase (ALT), and lipase. She underwent a limited right upper quadrant ultrasound, which was interpreted as having multiple gallstones but without sonographic Murphy's sign, gallbladder wall thickening (2 mm), pericholecystic fluid, or intra- or extrahepatic biliary duct dilatation (Fig. 1). She was discharged with a diagnosis of cholelithiasis and a plan to follow up in surgery clinic.

Two weeks later, she was seen in general surgery clinic where she was prescribed a proton pump inhibitor for presumed

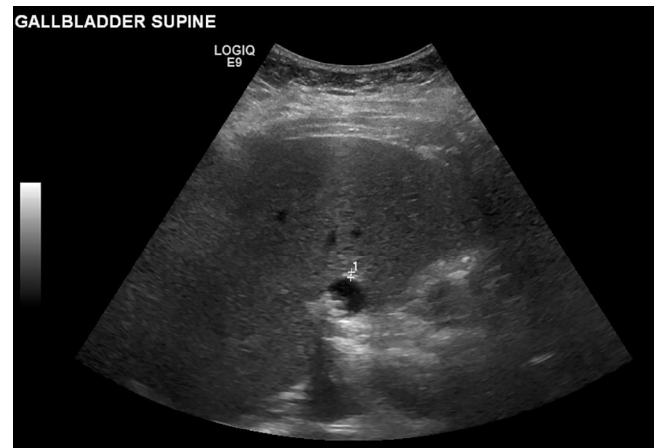

Fig. 1 – Right upper quadrant ultrasound read as a 2-mm gallbladder wall and echogenic gallstones without pericholecystic fluid, Murphy's sign, or common bile duct (CBD) dilation (3-mm CBD).

gastroesophageal reflux disease and offered elective cholecystectomy. A week later, she presented for laparoscopic cholecystectomy. Intraoperatively, there was no visible gallbladder, but the surgeon identified the common bile duct and a dilated tubular structure consistent with either infundibulum of a completely intrahepatic gallbladder or bifurcation of intrahepatic ducts. Subsequent computed tomography (CT) scan of the abdomen and pelvis with contrast was consistent with gallbladder agenesis, showing a 9-mm structure in the gallbladder fossa likely representing a remnant cystic duct, no biliary obstruction, and unremarkable hepatic anatomy (Figs. 2 and 3).

The patient was reported to have continued abdominal pain for the next 2-3 months associated with occasional nonbloody

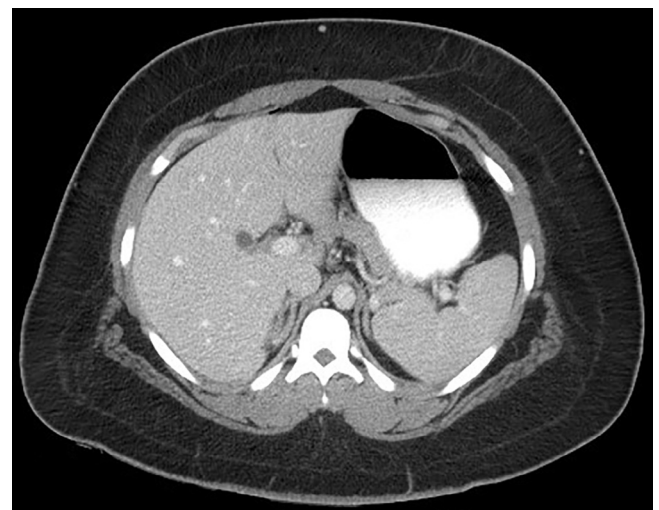

Fig. 2 – Axial view of computed tomography scan of abdomen and pelvis with contrast showing a small 9-mm structure in the gallbladder fossa likely related to gallbladder agenesis with no biliary obstruction and normal hepatic anatomy.

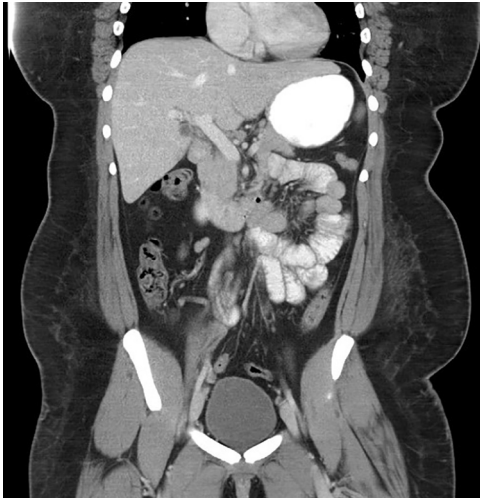


Fig. 3 – Coronal views of computed tomography scan of abdomen and pelvis with contrast showing a small 9-mm structure in the gallbladder fossa likely related to gallbladder agenesis with no biliary obstruction and normal hepatic anatomy.

emesis and rare loose stools without hematochezia, fever, urinary changes, or vaginal discharge. Repeat laboratory tests were notable for improvement in her white blood cell count to 12,000 cells/ μ L and platelet count to 430,000 cells/ μ L. Subsequently, she had a magnetic resonance cholangiopancreatography (MRCP) that revealed normal liver anatomy, absence of the gallbladder, no common bile duct dilation, and a 6-mm T1 hypointense tubular structure at the liver hilum, consistent with dilated cystic duct remnant (Figs. 4 and 5). Over the subsequent month, the patient had dramatic improvement in her abdominal pain without further intervention.

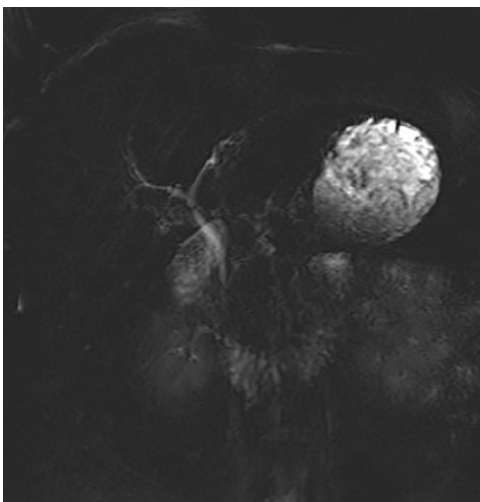


Fig. 4 – Magnetic resonance cholangiopancreatography showing normal liver anatomy, absence of the gallbladder, no common bile duct dilation, and a 6-mm T1 hypointense tubular structure at the liver hilum, consistent with dilated cystic duct remnant.

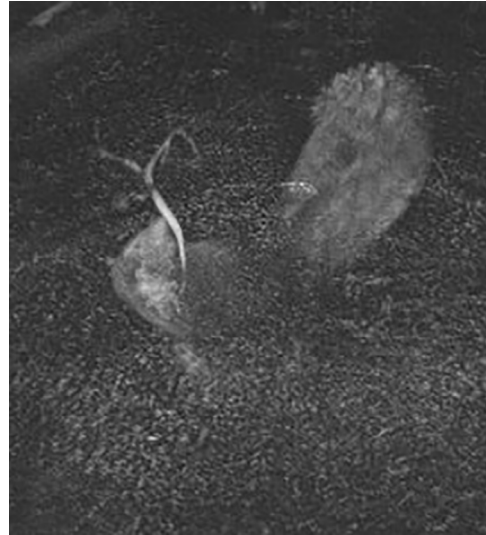

Fig. 5 – Magnetic resonance cholangiopancreatography showing normal liver anatomy, absence of the gallbladder, no common bile duct dilation, and a 6-mm T1 hypointense tubular structure at the liver hilum, consistent with dilated cystic duct remnant.

Discussion

This 24-year-old woman presented with “biliary colic-like symptoms” and initial imaging suggestive of small gallbladder with cholelithiasis. Despite imaging that was not entirely convincing for cholelithiasis, this diagnosis was made in light of the patient’s symptom profile, lack of previous cholecystectomy, and the limitations imposed by her body habitus (Fig. 1).

Based on intraoperative findings, it was clear that the patient did not have an extrahepatic gallbladder given that a dilated tubular structure was seen. In the immediate postsurgical period, a CT scan was obtained to assess for a completely intrahepatic gallbladder. Given that the patient was continuing to have symptoms 2 months later, further imaging was obtained to assess bile duct stones, which can occur in approximately 25%-60% of symptomatic patients with gallbladder agenesis. Therefore, a dedicated MRCP was performed and confirmed a dilated cystic duct remnant without bile duct stones. We cannot definitively conclude what caused the patient’s right upper quadrant pain. However, these symptoms could be attributable to congenital gallbladder agenesis, which can cause right upper quadrant pain, fatty food intolerance, nausea, and jaundice in up to 50% of patients [1].

Multiple case reports describe congenital gallbladder agenesis [6] including several prompting surgery for cholecystectomy [7-10]. This suggests that sonographic findings of a “small gallbladder with gallstones,” even in patients with biliary colic, could represent gallbladder agenesis. In select clinical settings, one could consider MRCP to avoid unnecessary surgery. This may be especially helpful in patients with technically difficult ultrasounds secondary to body habitus or other factors. In cases of gallbladder agenesis, hepatobiliary (HIDA) scans will be unhelpful as both cystic duct obstruction and gallbladder agenesis are likely to be interpreted as nonvisualization of the gallbladder.

Our patient's images differ in many important ways from the typical appearance of cholelithiasis. Although imaging appeared to have echogenic and shadowing stones, the proposed gallbladder was diminutive in size. No identifiable neck, body, or fundus could be identified. Additionally, there was no gallbladder wall thickening present, which is typically seen with a contracted gallbladder. It is possible that the interpreting radiologist assumed visualization was limited by the patient body habitus. Interestingly, this differentiates our case of gallbladder agenesis from previously reported cases. In the majority of previous case reports, the gallbladder was assumed to be poorly visualized due to chronic gallbladder fibrosis or impaction with stones [7,8,11]. In our case, there is a clearly identified structure containing stones. However, this structure does not match the expected anatomic conformation and may represent a rudimentary cystic duct.

In summary, this case of a young woman with biliary colic-like symptoms found to have gallbladder agenesis serves as a cautionary tale for a rare but convincing mimic of cholelithiasis, both clinically and radiographically.

REFERENCES

- [1] Bennion RS, Thompson JE Jr, Tompkins RK. Agenesis of the gallbladder without extrahepatic biliary atresia. *Arch Surg* 1988;123(10):1257–60.
- [2] Pierro A, Martucci M, Maselli G, Farchione A. Agenesis of the gallbladder with the presence of a small dysmorphic cyst: role of magnetic resonance cholangiopancreatography. *J Clin Imaging Sci* 2012;2:17.
- [3] Senecail B, Texier F, Kergastel L, Paton-Philippe L. Anatomic variability and congenital anomalies of the gallbladder and biliary tract: ultrasonographic study of 1823 patients. *Morphologie* 2000;84:35–9.
- [4] Toouli J, Geenen JE, Hogan WJ, Dodds WJ, Arndorfer RC. Sphincter of Oddi motor activity: a comparison between patients with common bile duct stones and controls. *Gastroenterology* 1982;82(1):111–17.
- [5] Malde S. Gallbladder agenesis diagnosed intra-operatively: a case report. *J Med Case Rep* 2010;4:285.
- [6] Yener O, Buldanli MZ, Eksioğlu H, Leblebici M, Alimoğlu O. Agenesis of the gallbladder diagnosed by magnetic resonance cholangiography: report of a case and review of the literature. *Prague Med Rep* 2015;116(1):52–6.
- [7] Al-Hakkak SMM. Agenesis of gall bladder in laparoscopic cholecystectomy—a case report. *Int J Surg Case Rep* 2017;39:39–42.
- [8] Rajkumar A, Piya A. Gall bladder agenesis: a rare embryonic cause of recurrent biliary colic. *Am J Case Rep* 2017;18:334–8.
- [9] McCallum I, Jones MJ, Robinson SJ. Gallbladder agenesis. *Ann R Coll Surg Engl* 2014;96(6):e28–9.
- [10] Haoues N, Zairi S, Zaafouri H, Ben Maamer A, Noomene R, Oueslati A, et al. Gallbladder agenesis intraoperatively diagnosed: a case report. *Tunis Med* 2014;92(2):168–9.
- [11] Tagliaferri E, Bergmann H, Hammans S, Shiraz A, Stuber E, Seidlmayer C. Agenesis of the gallbladder: role of clinical suspicion and magnetic resonance to avoid unnecessary surgery. *Case Rep Gastroenterol* 2016;10(3):819–25.