

## Case Report: Calcified Neurocysticercus, Perilesional Edema, and Histologic Inflammation

Theodore E. Nash, Luther A. Bartelt, Poonum S. Korpe, Beatriz Lopes, and Eric R. Houpt\*

National Institute of Allergy and Infectious Diseases, Bethesda, Maryland; Division of Infectious Diseases and International Health, University of Virginia; Department of Pathology, University of Virginia, Charlottesville, Virginia

**Abstract.** Here, we present the second report of the histopathology of a *Taenia solium* calcification giving rise to perilesional edema. This has important implications, because if perilesional edema lesions are inflammatory in character, immunosuppressive or anti-inflammatory medications, not just antiepileptic drugs alone, may be useful to prevent or treat recurring episodes in such patients.

Calcified *Taenia solium* cysts are the most common radiological finding in neurocysticercosis (NCC), with between 10% and 20% of the population in endemic populations exhibiting this feature on head computed tomography (CT).<sup>1</sup> Although most individuals with calcified cysts never experience seizures, they are commonly foci of seizure activity. The most persuasive evidence is the intermittent appearance of perilesional edema around a small subset of calcifications in persons presenting with seizures.<sup>1–11</sup> Reports have documented the phenomenon in many endemic regions. Of 110 persons followed prospectively in Lima, Peru who had a history of seizures, only calcifications as defined by imaging, and a positive cysticercosis serology, 50% of those with recurring seizures showed perilesional edema.<sup>5</sup> In most endemic regions, relatively few persons with epilepsy show viable degenerating cysts leaving calcified cysts as the most common radiological finding associated with epilepsy caused by NCC,<sup>1</sup> amounting to about 29% of all epilepsies in affected areas.<sup>12</sup>

The pathophysiology of perilesional edema is unclear mostly because of the paucity of direct examination of calcifications involved. The most favored hypothesis is that perilesional edema is caused by inflammation, perhaps as a result of intermittent release and/or recognition of enmeshed parasite antigen.<sup>13</sup> However, others hypothesize perilesional edema is a result of seizure activity or release of ionic calcium.<sup>13</sup> This is an important distinction, as therapies could differ, with immunosuppressive medications or antiepileptic drugs alone, respectively.

To our knowledge there is only one full report of the histopathology of a *T. solium* calcification giving rise to perilesional edema<sup>14</sup>; the calcified lesion showed considerable inflammation associated with a degenerated cysticercus, which favored an inflammatory pathophysiology as the cause of perilesional edema. Here, we report the histopathology of a second case of an excised calcified cyst associated with perilesional edema.

### CASE REPORT

A 22-year-old previously well Hispanic female presented to her local emergency department after a witnessed seizure at work on November 2012. In the hours preceding the development of tonic-clonic jerking, she recalled two episodes of hot/cold flashes and a diffuse headache. There was no accompanying aura, photophobia, phonophobia, weakness, or numbness.

She was amnesic of the subsequent events and next recalled awakening in the hospital. She denied any personal or family history of seizure or prior head trauma. There was no positional component to her headache, recent vision changes, nausea or vomiting. Although she denied chronic headaches, she recalled a severe diffuse headache 6 months prior of several hours duration that spontaneously resolved.

The patient immigrated from Honduras to the United States in 2004 and from that date lived in an apartment in central Virginia. There was no other history of international travel. She lived with roommates born in the United States. She denied tobacco or alcohol use, and was primarily a vegetarian. As a child in Honduras she played with neighborhood pigs, however there was no known history of tapeworm infection or ingestion of undercooked pork, and living conditions in Honduras included indoor plumbing and running water.

The initial evaluation in the emergency department identified no focal neurological abnormalities. A head CT revealed a right frontal anterior medial ring-enhancing lesion with edema and a punctate calcification (Figure 1A) and a third ventricular 6×8 mm colloid cyst. A magnetic resonance imaging (MRI) image showed an area of edema surrounding a void with circumferential enhancement consistent with perilesional edema around the calcified cyst (Figure 1B). Other diagnostic considerations included primary tumors such as ganglioglioma, oligodendroglioma, pleomorphic xanthoastrocytoma, or dysembryoplastic neuroepithelial tumor. Levetiracetam 750 mg orally twice daily and dexamethasone 10 mg intravenously was administered preoperatively, followed by a dexamethasone taper thereafter. Serum *Strongyloides* IgG, cysticercosis antibody, Quantiferon, cerebrospinal fluid (CSF) cysticercosis antibody, and CSF cysticercosis antigen (Center for Diseases Control and Prevention [CDC]) were all negative. She underwent resection of the right frontal mass.

Histopathology shows a circular structure with specific layering (Figures 2A and 3A). There is a central eosinophilic mass, which is spuriously retracted from the surrounding encircling host-derived capsule consisting of a concentric layer of collagen, with inner and outer regions of dense infiltrates (Figures 2A and 3A). The central mass consists of a degenerated but still recognizable cyst (Figure 2A and C) consisting of a scolex with suckers (Figure 3C) and structures consistent with hooklets and a neck (Figures 2A[\*], 3C[\*]). The latter is a mass arising from the scolex consisting of folds of recognizable tegument (Figures 2A[\*], 3C[\*]) that contain many calcareous corpuscles, calcium-laden bodies pathognomonic for cestodes (Figure 3B). The surrounding host-derived wall (Figure 2A, perpendicular line) or capsule consists of a collagenous layer (Figure 2B and E) and an exterior layer

\* Address correspondence to Eric R. Houpt, MR6, 1716, Charlottesville, VA 22908. E-mail: erh6k@virginia.edu, ERH6K@hscmail.mcc.virginia.edu

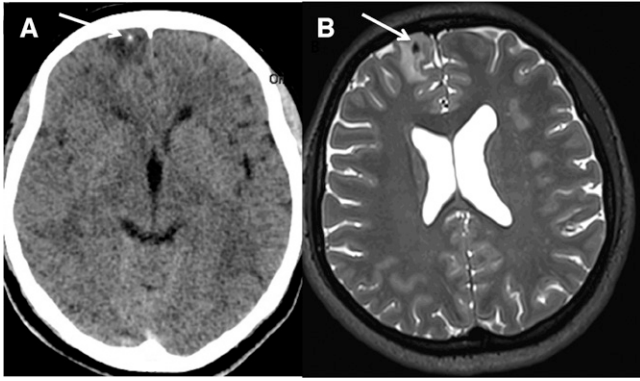


FIGURE 1. (A) A computed tomography (CT) image showing a calcified lesion in the right frontal lobe with surrounding edema as indicated by the arrow. (B) The corresponding T2 weighted magnetic resonance imaging (MRI) image showing a void, which is a calcification as shown by the arrow and surrounding edema.

containing dense mononuclear host infiltrates (Figure 2D and E) consisting of plasma cells, lymphocytes, monocytes, and limited numbers of eosinophils. Inflammatory regions are also seen interior to the collagenous layer. In some places, masses of calcareous corpuscles form hematoxylin staining crescents adjoining the inner wall of the capsule, just inside the outer cyst tegument (Figure 3A and B). In other areas the inner capsule is lined mostly with cellular debris (Figure 2B and E). Amorphous calcifications are not present. The fibrous

capsule is surrounded by gliotic cortical parenchyma with exuberant reactive astrocytosis as highlighted by dense staining by immunohistochemistry for glial fibrillary acidic protein (GFAP)(\*\*\*\*) (Figure 3D).

Postoperatively the patient did well and a follow-up MRI scan 3 months later revealed an unchanged cystic structure in the third ventricle, which, based upon its continued appearance (isointense T1/hypointense T2) was felt to be most compatible with a colloid cyst, although the possibility of NCC mimicking a colloid cyst was considered and remains possible.<sup>15,16</sup>

## DISCUSSION

This is the second case describing the histopathology of a calcified cysticercus causing a well-documented episode of perilesional edema associated with a seizure. The histopathology is that of a degenerated cysticercus with considerable intracystic and intense capsular inflammatory response, consisting of mononuclear cells, some plasma cells, and a few eosinophils. The relative lack of eosinophils is likely caused by preoperative administration of high dose corticosteroids. The overall structure of the degenerated cysts and the inflammatory nature of the lesion are very similar to the findings of the first case report of an excised calcified cyst associated with perilesional edema<sup>14</sup>; both show a degenerated cysticercus and a surrounding capsule with intense inflammation.

What is responsible for the calcification seen in CT and MRI imaging? Both cases showed dense aggregates of calcareous corpuscles of a surprising degree in the degenerated

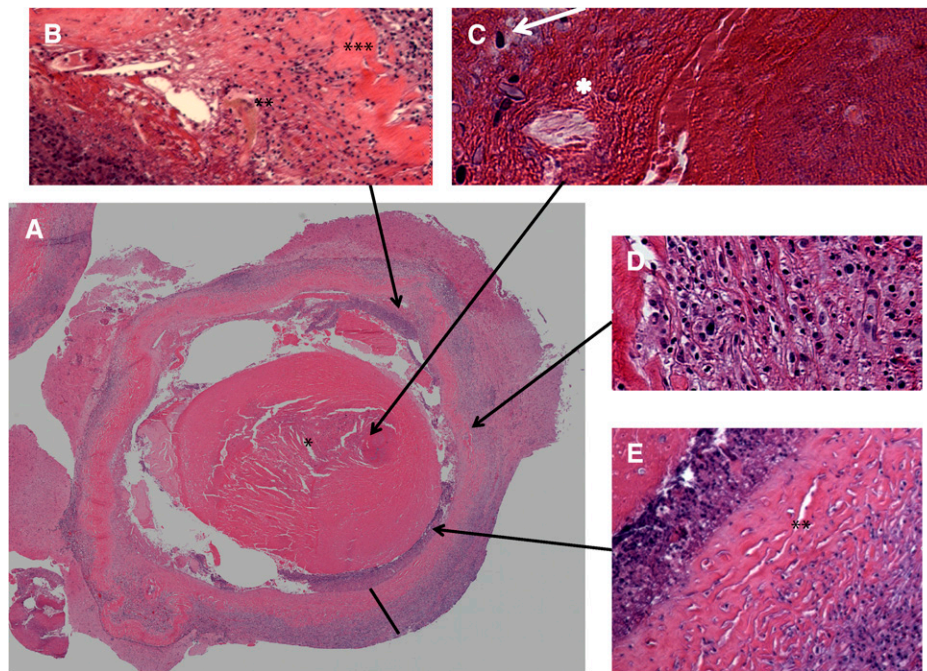


FIGURE 2. A low power view of the cross section of the cyst with higher power views of the indicated regions in the letter panels (A–E). Please see the text for a full description. The (\*) marks the neck of the cysticercus. (A) A low power view of a cross section of the lesion showing the central cyst and surrounding capsule (black line perpendicular to the cyst wall). (B) A higher power view showing an intracapsular region of inflammation at the lower left of the figure and an adjacent moderate inflammation in the capsule (\*\*). A middle layer of collagen is seen at the extreme right of the micrograph (\*\*\*). (C) A higher power view of the scolex on the right side of the image and the neck (\*), emanating from the scolex, and containing hematoxylin staining calcareous corpuscles (arrow). (D) A higher magnification of the capsular inflammation exterior to the collagen layer. (E) A higher magnification of the layers of the capsule. There is an intracapsular region of hematoxylin stained degenerated cells occupying the left of the image, the middle layer of collagen (\*\*\*) and the outer layer consisting of a mononuclear infiltrate at the lower right of the image.



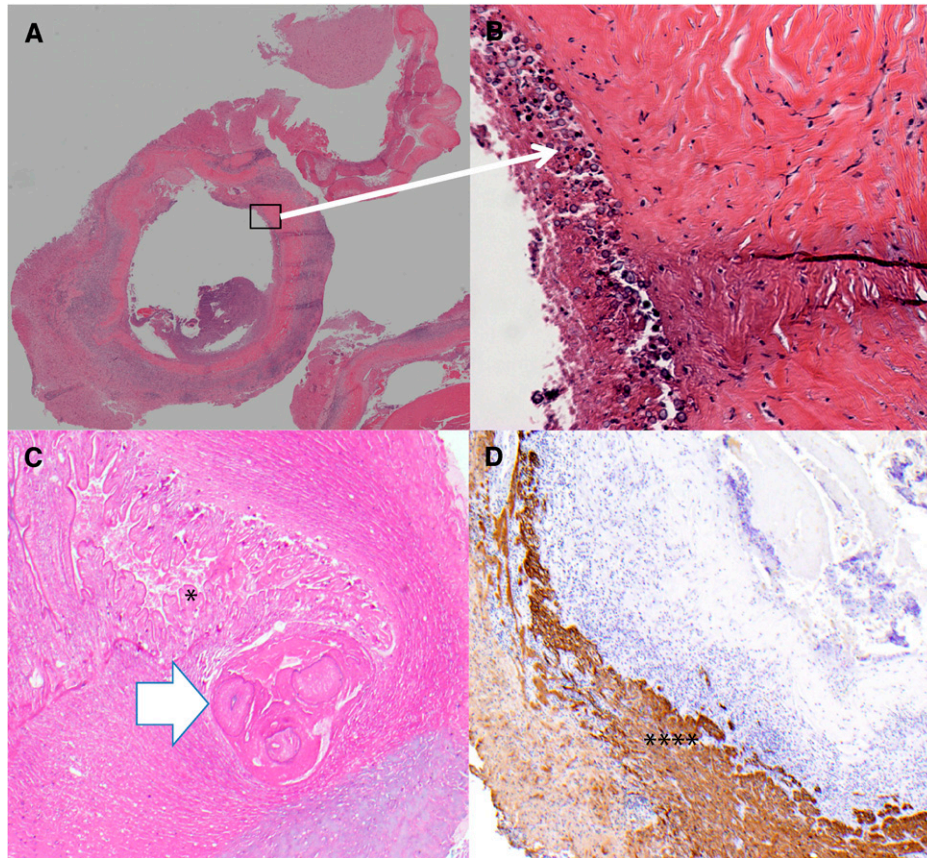


FIGURE 3. (A) Low power view of another cross section of the cyst again showing the capsule and spuriously empty the central cavity once occupied by the cyst. (B) The rectangular region in (A) is enlarged showing a linear array of masses of calcareous corpuscles. (C) A third cross section showing the scolex with suckers (white arrow) and likely hooklets in the middle of two of the suckers and the neck with pleated sheets of tegument (\*). (D) Immunostaining for glial fibrillary acidic protein (GFAP) in the adjacent brain tissue (\*\*\*\*) showing extensive astrogliosis.

cysticerci. In this case, dense concentrations of calcareous corpuscles were present in the neck and aggregates were also present adjoining the inner surface of the capsule. Little or no amorphous calcification was seen.

The histopathology of calcified cysts is barely mentioned in the literature and to our knowledge no systematic histopathological study exists. Descriptions of the few pictured and/or mentioned calcified cysts, mostly in older texts, are of thin-walled cysts with little inflammation in the wall<sup>17–20</sup>; the interior is composed of amorphous calcified debris some with cholesterol clefts. There is variable but usually little recognizable cestode-specific tissue. The lack of inflammation in the older descriptions contrasts with the significant presence of inflammation in the calcifications associated with perilesional edema. Although there are only a few pathological descriptions of calcifications, thus far the findings suggest there are at least two types of calcifications, those that consist of amorphous calcifications and little accompanying inflammation and those consisting of degenerated but still recognizable cysts accompanied by an intense inflammatory response. Whether the lesions associated with perilesional edema are younger and not yet fully evolved into the calcifications described in the older literature is not known. There are no clinical correlates for the described calcifications in the older literature, presumably they were obtained at autopsy and no

pertinent history exists. It is highly unlikely that these calcifications were associated with seizure episodes.

Understanding the pathophysiology of seizures associated with calcified cysts is important to devise better prevention, treatment, and prognostic strategies besides the usual anti-seizure medications. Because perilesional edema lesions appear to be inflammatory in character, the potential use of immunosuppressive or anti-inflammatory medications, not just antiepileptic drugs alone, may warrant consideration to prevent or treat intractable recurring episodes in such patients.

Received October 11, 2013. Accepted for publication November 26, 2013.

Published online January 6, 2014.

Financial support: The support for this study was in part received from the Intramural National Institutes of Allergy and Infectious diseases at the National Institutes of Health.

Authors' addresses: Theodore E. Nash, National Institutes of Health, Laboratory of Parasitic Diseases, Bethesda, MD, E-mails: tnash@niaid.nih.gov or tnash@nih.gov. Luther A. Bartelt, University of Virginia, Infectious Disease, Charlottesville, VA, E-mails: lab2za@virginia.edu or luther.bartelt@gmail.com. Poonum S. Korpe, University of Virginia, Department of Medicine, Charlottesville, VA, E-mail: psk9p@virginia.edu. Beatriz Lopes and Eric R. Houpt, University of Virginia, Pathology, Charlottesville, VA, E-mails: MSL2E@virginia.edu and erh6k@virginia.edu or ERH6K@hscmail.mcc.virginia.edu.

## REFERENCES

- Nash TE, Del Brutto OH, Butman JA, Corona T, Delgado-Escueta A, Duron RM, Evans CA, Gilman RH, Gonzalez AE, Loeb JA, Medina MT, Pietsch-Escueta S, Pretell EJ, Takayanagui OM, Theodore W, Tsang VC, Garcia HH, 2004. Calcific neurocysticercosis and epileptogenesis. *Neurology* 62: 1934–1938.
- Antoniuk SA, Bruck I, Dos Santos LH, Pintarelli VL, Navolar FB, Brackmann PC Jr, de Moraes RL, 2001. Seizures associated with calcifications and edema in neurocysticercosis. *Pediatr Neurol* 25: 309–311.
- Gupta RK, Kumar R, Chawla S, Pradhan S, 2002. Demonstration of scolex within calcified cysticercus cyst: its possible role in the pathogenesis of perilesional edema. *Epilepsia* 43: 1502–1508.
- Nash TE, Patronas NJ, 1999. Edema associated with calcified lesions in neurocysticercosis. *Neurology* 53: 777–781.
- Nash TE, Pretell EJ, Lescano AG, Bustos JA, Gilman RH, Gonzalez AE, Garcia HH, 2008. Perilesional brain oedema and seizure activity in patients with calcified neurocysticercosis: a prospective cohort and nested case-control study. *Lancet Neurol* 7: 1099–1105.
- Nash TE, Pretell J, Garcia HH, 2001. Calcified cysticerci provoke perilesional edema and seizures. *Clin Infect Dis* 33: 1649–1653.
- Park SY, Barkovich AJ, Weintraub PS, 2000. Clinical implications of calcified lesions of neurocysticercosis. *Pediatr Infect Dis J* 19: 581–583.
- Poeschl P, Janzen A, Schuierer G, Winkler J, Bogdahn U, Steinbrecher A, 2006. Calcified neurocysticercosis lesions trigger symptomatic inflammation during antiparasitic therapy. *AJNR Am J Neuroradiol* 27: 653–655.
- Sheth TN, Lee C, Kucharczyk W, Keystone J, 1999. Reactivation of neurocysticercosis: case report. *Am J Trop Med Hyg* 60: 664–667.
- Del Brutto OH, 1994. Prognostic factors for seizure recurrence after withdrawal of antiepileptic drugs in patients with neurocysticercosis. *Neurology* 44: 1706–1709.
- Garg RK, Karak B, Mohan Kar A, 1998. Neuroimaging abnormalities in Indian patients with uncontrolled partial seizures. *Seizure* 7: 497–500.
- Ndimubanzi PC, Carabin H, Budke CM, Nguyen H, Qian YJ, Rainwater E, Dickey M, Reynolds S, Stoner JA, 2010. A systematic review of the frequency of neurocysticercosis with a focus on people with epilepsy. *PLoS Negl Trop Dis* 4: e870.
- Nash T, 2012. Edema surrounding calcified intracranial cysticerci: clinical manifestations, natural history, and treatment. *Pathog Glob Health* 106: 275–279.
- Ooi WW, Wijemanne S, Thomas CB, Quezado M, Brown CR, Nash TE, 2011. Short report: a calcified *Taenia solium* granuloma associated with recurrent perilesional edema causing refractory seizures: histopathological features. *Am J Trop Med Hyg* 85: 460–463.
- Gupta A, Nadimpalli SP, Cavallino RP, 2002. Intraventricular neurocysticercosis mimicking colloid cyst. Case report. *J Neurosurg* 97: 208–210.
- Wray SD, Ellis TL, Bianco S, 2001. Migratory neurocysticercosis mimicking a third ventricular colloid cyst: case report. *J Neurosurg* 95: 122–123.
- Hennenberg R, 1912. Die tierischen Parasiten des Zentralnervensystems. Lewandowsky M, ed. *Handbuch der Neurologie*, 642–683.
- Escobar A, Weidenheim K, 2002. The pathology of neurocysticercosis. Singh G, Prabhakar S, eds. *Taenia solium Cysticercosis: From Basics to Clinical Science*. Wallingford, Oxon, UK: CABI Publishing, 289–305.
- Marquez-Monter H, 1971. Cysticercosis. Marcial-Rojas R, ed. *Pathology of Protozoal and Helminthic Diseases*. Baltimore, MD: Williams & Wilkins Company, 592–617.
- Rabiela MT, Rivas A, Flisser A, 1989. Morphological types of *Taenia solium* cysticerci. *Parasitol Today* 5: 357–359.