



AALBORG UNIVERSITY
DENMARK

Aalborg Universitet

The top 10 cosmeceuticals for facial hyperpigmentation

Searle, Tamara; Al-Niaimi, Firas; Ali, Faisal R

Published in:
Dermatologic Therapy

DOI (link to publication from Publisher):
[10.1111/dth.14095](https://doi.org/10.1111/dth.14095)

Creative Commons License
CC BY-NC 4.0

Publication date:
2020

Document Version
Accepted author manuscript, peer reviewed version

[Link to publication from Aalborg University](#)

Citation for published version (APA):
Searle, T., Al-Niaimi, F., & Ali, F. R. (2020). The top 10 cosmeceuticals for facial hyperpigmentation. *Dermatologic Therapy*, 33(6), [e14095]. <https://doi.org/10.1111/dth.14095>

General rights

Copyright and moral rights for the publications made accessible in the public portal are retained by the authors and/or other copyright owners and it is a condition of accessing publications that users recognise and abide by the legal requirements associated with these rights.

- ? Users may download and print one copy of any publication from the public portal for the purpose of private study or research.
- ? You may not further distribute the material or use it for any profit-making activity or commercial gain
- ? You may freely distribute the URL identifying the publication in the public portal ?

Take down policy

If you believe that this document breaches copyright please contact us at vbn@aub.aau.dk providing details, and we will remove access to the work immediately and investigate your claim.



The top ten cosmeceuticals for facial hyperpigmentation

Article type: Review

Tamara Searle¹; Firas Al-Niaimi² Faisal R. Ali^{3,4*}

Institutions: ¹University of Birmingham Medical School, Birmingham, UK

²Department of Dermatology, Aalborg University Hospital, Aalborg, Denmark.

³Dermatological Surgery & Laser Unit, St John's Institute of Dermatology,

Guy's Hospital Cancer Centre, London, UK

⁴Vernova Healthcare CIC, Macclesfield, UK

*Corresponding author: Dr Faisal Ali. Email: f.r.ali.01@cantab.net

Running title: Top ten cosmeceuticals for hyperpigmentation

Word count (excluding title page and references): 3177

Keywords: Arbutin, ferulic acid, kojic acid, melasma, nicotinamide, pigmentation, resorcinol, retinol, thiamidol, vitamin C

This article has been accepted for publication and undergone full peer review but has not been through the copyediting, typesetting, pagination and proofreading process which may lead to differences between this version and the Version of Record. Please cite this article as doi: 10.1111/dth.14095

Consent for publication: All authors have approved this final submitted version of the manuscript and consent to its submission for consideration of publication

Funding sources: None

Conflicts of Interest: None declared.

Abstract

Disorders of facial hyperpigmentation including melasma, post-inflammatory hyperpigmentation and solar lentigines are common cutaneous conditions which can have a huge impact on patients' quality of life and often prove difficult to treat. The nascent market of cosmeceutical options provides a potentially safer and efficacious alternative for treating these challenging conditions. These can be used alone or in combination with other established treatments. Many cosmeceutical products are thought to work through inhibition of tyrosinase, a key enzyme of melanogenesis. We discuss the mode of action and provide an up-to-date review of the underlying evidence base for the top ten cosmeceutical products for hyperpigmentation and melasma. Possible safer and more efficacious cosmeceutical therapies we discuss include thiamidol, kojic acid, vitamin C, arbutin, retinol, nicotinamide, ferulic acid, resorcinol, licorice root extract and soy.

Background

Disorders of facial hyperpigmentation are common and can have a profound impact upon patients' quality of life. Melasma is one of the most common hyperpigmentary dermatoses with a prevalence estimated to be up to 20% in South Asians.¹ Due to its high prevalence, it is frequently used as the disease paradigm through which treatment of hyperpigmentation is explored. Effective treatments for hyperpigmentation disorders are limited with stringent photoprotection being the mainstay of prevention. Common treatments include hydroquinone, chemical peels, and laser treatments all with varying success rates and associated risks.

Cosmeceuticals are cosmetic products that aim to deliver physiologically relevant benefits without the incorporation of prescription drugs.²

Cosmeceuticals are used in disorders of hyperpigmentation, including melasma, to target hyperactive melanocytes and impede fundamental steps in melanogenesis.¹ Cosmeceuticals have gained increased interest with the public and dermatological community although their effectiveness and modes of actions are not always fully understood. We discuss ten of the most commonly used cosmeceuticals for melasma and hyperpigmentation disorders,¹ reviewing their mode of action and underlying evidence base for therapeutic benefit.

Melanin is the main pigment in skin produced by melanocytes.³ Tyrosinase is an enzyme with a fundamental role in melanogenesis and is a copper-containing metalloenzyme with dinuclear copper ions, which is fundamental as the rate-limiting step in melanogenesis.³ Controlling tyrosinase action is therefore necessary for the treatment of hyperpigmentation disorders.³

Thiamidol

Human tyrosinase is fundamental in the formation of melanin. Once processed, they become integrated in the melanosomal membrane and are therefore responsible for the conversion of tyrosine into melanin.⁴ Many tyrosinase inhibitors have been made available, yet many have variable efficacy owing to their discovery based on mushroom tyrosinase as a target.⁴ The newly discovered resorcinyll thiazole derivative, thiamidol® (Figure 1a) (Beiersdorf AG, Hamburg, Germany) is a powerful human tyrosinase competitive inhibitor (table 2), found both *in vitro* and *in vivo* to potently, but reversibly, inhibit production of melanin.⁴ Thiamidol® was found to be the most potent inhibitor of human tyrosinase and was most efficacious compared with 50,000 other possible tyrosinase inhibitors tested.⁴ Thiamidol® potently and reversibly inhibits melanogenesis.⁴ When compared to hydroquinone (2.0%) in a double-blind randomised study, thiamidol® (0.2% in an oil-in-water emulsion) was found to be significantly more efficacious than hydroquinone

(79% improvement versus 61% improvement respectively) measured using the Melasma Area and Severity Index Score (MASI) ($p < 0.001$) ($n = 80$). Self-assessment of pigmentation was also improved in both groups with no reported adverse effects.⁵ (Table 1)

A separate study investigated the use of thiamidol® in two different trials.⁶ A split-face double blind randomised controlled trial in 34 patients used two thiamidol® containing products twice or four times daily on one half of the face and SPF30 on the whole face.⁶ The second trial was a separate single-arm observational study ($n = 83$) in which patients were treated with SPF30 in the day and at night thiamidol® serum and night care cream.⁶ At 12-weeks, hyperpigmentation, skin roughness and MASI all improved significantly compared with baseline (-0.78 ± 0.52 , -0.87 ± 0.45 ; $p < 0.001$) in the split-face study, whilst in the observational real-life study, skin condition and chromametry improved significantly compared to baseline. Self-assessment scores also improved significantly from baseline. The four-times daily thiamidol® regimen improved facial hyperpigmentation significantly more than the two-times group and was well-tolerated.⁶ More extensive randomised clinical trials that also include males, with post-study follow-ups following cessation of treatment are required.⁵

Kojic acid

Kojic acid (KA) (5-hydroxy-2-hydroxymethyl-4-pyrone; Figure 1b) is a natural organic acid and fungal byproduct of some species of *Acetobacter*, *Aspergillus* and *Penicillium*.⁷ KA acts to inhibit tyrosinase genesis with additional antioxidant effects and exhibits antimicrobial and anti-ageing properties.⁷ KA can inhibit NF- κ B in keratinocytes, whose activation might be related to melanogenesis.⁷ Tyrosinase enzymes contain copper ions in their active site and on exposure to ultraviolet radiation (UVR), the copper enhances the activity of tyrosinase.⁸ KA captures this copper ion, preventing enhancement of tyrosinase's activity, thus preventing melanin synthesis.⁸ Side-effects associated with hydroquinone have made KA a desirable alternative. Currently the European Union's Scientific Committee on Consumer Safety recommends KA to be used at concentrations of 1.0% topically.⁹ Previous studies have used KA at concentrations ranging between 1-4%; KA was found to be irritant at higher doses.⁷

Combination treatment of hydroquinone and KA could enhance the inhibition of tyrosinase in melasma.¹⁰ KA 2% gel (containing 10% glycolic acid (GA) and 2% hydroquinone) was used on one side of the face of 40 women, whilst the other side of the face was treated with the same gel (10% GA and 2%

hydroquinone) without KA.¹⁰ The addition of KA to the combination gel enhanced clearance to 60%, compared to 47.5% without the KA.¹⁰

GA is also thought to enhance penetration of KA increasing its effectiveness. Garcia and colleagues reported GA and KA combinations to be as efficacious as GA and hydroquinone preparations in reducing pigmentation, although the authors found KA to be more irritant ($n=39$).¹¹

KA has proven efficacious in treating photodamage, lentigines and hyperpigmented scars.⁷ Adverse reactions should be considered, with contact dermatitis being the main side-effect of KA, as well as increased risk of sunburn in individuals with sensitive skin.⁷ There is some evidence from animal studies that ingestion and systemic absorption of KA may be carcinogenic, but this has not been reported with topical formulations;⁷ it remains prudent to avoid applying KA to broken skin. Future studies are required to fully evaluate the safety profile of KA as a lightening treatment.⁷

Vitamin C

Humans rely solely on external supplementation to get supplies of vitamin C such as through oral intake or in cutaneous applications through topical administration in cosmeceutical products.¹² Vitamin C (Figure 1c) is available in several formulations. L-ascorbic acid is the most biological active form and

is used in many cosmeceutical products.¹² Other common vitamin C derivatives include: ascorbyl-6-palmitate, magnesium ascorbyl phosphate, disodium isostearyl 2-O L-ascorbyl phosphate, ascorbic acid sulphate and tetra-isopalmitoyl ascorbic acid.¹²

One of the main difficulties with vitamin C products is instability.¹² The most stable formulation of vitamin C is L-ascorbic acid with a *pH* of 3.5, as acidity improves its penetration and stability. Vitamin C is most efficacious at concentrations greater than 8% and at concentrations greater than 20% was found to cause irritation.¹²

Vitamin C is thought to inhibit tyrosinase by interacting with copper ions at tyrosinase active sites, decreasing melanogenesis.¹² A lipophilic pro-vitamin C, tetra-isopalmitoyl ascorbic acid (VC-IP), was found to have antioxidant properties and was able to suppress melanocyte proliferation from UVB-irradiated keratinocytes *in vitro*.¹² C'ensil® (Sage Pharmaceuticals Inc., Shreveport, LA) containing 25% L-ascorbic acid was developed to promote absorption of L-ascorbic acid into the skin, since it is normally rapidly oxidised into an aqueous solution.¹³ Melasma patients treated with C'ensil (*n*=40) had a significant decrease in their MASI scores and an increase in their quality of life scores.¹³

In a separate study, 5% L-ascorbic acid was compared with 4% hydroquinone cream in 16 women with melasma. Hydroquinone was superior in subjective measurements than ascorbic acid (93% good and excellent results versus 62.5% respectively, $p < 0.05$).¹⁴ There was no statistical difference in colorimetric measures, but side-effects were much greater in the hydroquinone group (68.5% versus 6.2% respectively).¹⁴ A combination of procyanidin (24mg) and vitamins A (6mg), C (60mg) and E (15IU) was found to be safe and efficacious among 80 women with melasma in a randomised, double-blind, placebo-controlled trial.¹⁵

In a split-face comparative study of 30 melasma patients,¹⁶ 20% Vitamin C with microneedling on one side of the face was compared with tranexamic acid (4mg/mL) and microneedling on the other side, given twice a month for eight weeks.¹⁶ Both treatments were effective and safe and microneedling ensured that there is uniform delivery of ingredients.¹⁶

Another study of 30 patients found microneedling (six sessions) with topical vitamin C to be a significantly effective and safe treatment, particularly for those of Fitzpatrick skin types I-III.¹⁷

In a separate study, patients were treated with full-face iontophoresis mask and vitamin C (ascorbyl glucoside) preparation.¹⁸ Patients had one treatment

and 12-24 home treatments over 1-2 months with sun avoidance advised.¹⁸

This treatment produced a mean improvement of 73% in abnormal pigmentation with a mean improvement of MASI of 15.7.¹⁸

Vitamin C appears to be an effective treatment option for patients suffering from melasma or post-inflammatory hyperpigmentation.¹⁸ Its long-term efficacy remains unknown and large randomised controlled trials with longer follow-ups are required to see if any benefits of treatment can be maintained.¹⁸ Sunscreens are only partially efficacious for blocking free radicals released upon UV exposure. Vitamin C works synergistically with sunscreens to enhance their photoprotective effect.¹²

Arbutin

Alpha and β -arbutin (Figure 1d) are derivatives of hydroquinone extracted from the bearberry plant leaves with smaller quantities found in smaller quantities in cranberry and blueberry leaves.¹⁹ Arbutin is a natural gluconopyranoside which reduces tyrosinase activity in addition to inhibition of melanocyte maturation in the absence of toxicity.²⁰ The tyrosinase inhibitor deoxyArbutin inhibits tyrosine hydroxylase in a dose dependent way, inhibiting melanogenesis hence its use in skin-lightening of hyperpigmented skin.²⁰

Serratulae quinquefoliea folium, plant extract is a new source of β -arbutin and was used in a randomised controlled trial of 102 women with melasma and solar lentigines.²¹ A cream containing 2.51% arbutin was applied twice a day for eight weeks and lightening and skin tone homogenisation was found in 66% of patients.²¹ In a separate study, 66.67% patients treated with Nd:YAG laser and topical 7% alpha arbutin solution had good or excellent clearance of their melasma.²²

Retinol

Vitamin A and its derivatives (retinoids) are used as topical formulations in anti-ageing.²³ Non-prescribed, cosmeceutical retinoids are natural or synthetic products such as retinol, retinyl-palmitate, retinyl-acetate, and retinaldehyde.²³

Retinoids exert their effects in pigmentation through a number of mechanisms which include: inhibition of matrix metalloproteinase activation, inhibition of oxidative stress, decreased melanosome transfer, and through regeneration of the extracellular matrix.²³ In addition, retinoids regulate keratinocyte differentiation aiding in accelerated exfoliation and consequently affects melanin count in the epidermis.²³ Thinning of the stratum corneum through use of retinoids can increase the permeability and hence penetration of

depigmenting products in the epidermis, increasing their bioavailability, thus promoting depigmentation.²³

Improvements in the MASI were found after four weeks treatment in melasma and photodamaged skin, with a 4% hydroquinone and cosmetic 1% retinol combination ($n=31$).²⁴ In a small study ($n=21$), 10% all-trans retinol gel, 5% hydroquinone and 7% lactic acid produced a 89% clinical improvement in patients with skin pigmentation.²⁵

Retinyl-acetate and retinyl-palmitate are vitamin A ester derivatives, thought to be the least effective of the topical retinoids. Retinyl propionate and retinyl palmitate have been trialled in photoaging creams with inconclusive findings.²⁶⁻²⁷ Retinol (Figure 1e) is a precursor of retinaldehyde and is derived from the hydrolysis of beta-carotene; the molecule exhibits a depigmenting action and its use is supported by a weak evidence base.

Retinaldehyde (Figure 1f) is a retinoic acid precursor, found to have depigmenting properties.²³ Retinaldehyde has been used in anti-aging treatments to reduce wrinkles at concentrations of 0.05%, which appears effective and more tolerable, with less irritation compared to tretinoin.²³

In animal studies, retinaldehyde decreased melanin concentration in guinea pig ears and mice tails by 54% and 74% respectively, decreasing the active

melanocyte count by 42% and 77% respectively. The authors hypothesise this action is likely due to disruption of melanocyte pathways rather than direct melanocyte toxicity.²⁸ Studies which demonstrate the effects of retinaldehyde in melasma are lacking. Large randomised controlled trials are necessary to explore cosmeceutical retinols and retinaldehydes in patients with melasma and pigmentation. From the current available evidence, retinyl-acetate and retinyl palmitate are unlikely to have significant efficacy in pigmentation, retinaldehydes need further research and retinol appears promising in treating pigmentation.²³

Bakuchiol is a purified mereoterpene phenol found in seed and plant sources recently found to have anti-proliferative and anti-inflammatory properties.²⁹ In a randomised, double-blind 12-week study ($n=44$), patients were given either bakuchiol 0.5% cream twice daily or retinol 0.5% cream.²⁹ Both treatments significantly decreased hyperpigmentation and wrinkle surface area with no statistically significant difference between compounds. The retinol treatment led to greater facial skin scaling and stinging.²⁹ As further evidences accrues, bakuchiol may be considered as a future alternative to retinol.

Nicotinamide

Nicotinamide (Figure 1g), also referred to as niacinamide, is a water-soluble amide of vitamin B3.³⁰ Nicotinamide is thought to act as an antioxidant through polyadenosine diphosphate-ribose polymerase inhibition in addition to melanosome transfer inhibition.³⁰

A cream containing a combination of nicotinamide 4%, arbutin 3%, bisabolol 1% and retinaldehyde 0.05% was found to be successful in reducing MASI and total melasma surface area ($n=35$) at 30 days with a further decrease at 60 days ($p=0.001$).¹⁹ Patient satisfaction was also improved significantly, 75.8% of participants were dissatisfied with their skin appearance at baseline versus 15.2% at day 60.¹⁹

A separate study randomised 27 patients to receive 4% nicotinamide cream on one side of the face and 4% hydroquinone on the other side for four weeks.³¹ All patients had improvements in their pigmentation and MASI score decreased by 70% and 62% in the hydroquinone and nicotinamide groups respectively, but this difference was not statistically significant.³¹ Nicotinamide reduced mast cells infiltrates and improved solar elastosis in patients with melasma with a lower side-effect profile.³¹

Nicotinamide is gaining increasing attention due to its skin-lightening effects and stimulation of DNA repair as well as its ability to inhibit UV photocarcinogenesis.³⁰ Further research is required to substantiate its use as monotherapy in pigmentary disorders in large trials.

Ferulic acid

Ferulic acid (FA) (Figure 1h) is part of the phenolic acid group found in plants and is a cinnamic acid derivative.³² It is commonly found in whole grains, spinach, parsley, grapes, apples, rhubarb, oats, rye and barley.³² FA has antioxidant properties with low irritancy.³² Human endothelial cells and keratinocytes treated with FA prior to UVA radiation were less vulnerable to free radical damage through prevention of UV-induced cell cycle modifications and regulation of DNA repair genes supporting its anti-oxidant effects.³² FA is used in skin lightening formulations because of its ability to inhibit tyrosinase and inhibit melanocyte proliferation.³² FA can maintain a high local concentration with low metabolism, penetrating deep into the skin.³² Its high penetrating ability is likely due to the lipophilic properties of this acid.³² Its recommended cosmeceutical concentration is 0.5-1%.³²

Several studies have found FA to be useful in combination formulations, such as with oral vitamin C, E, azelaic acid, mandelic acid, phytic acid, and 4N-butyl resorcinol.³⁴⁻³⁶ A combination of 20% azelaic acid, mandelic acid, phytic

acid, 4N-butyl resorcinol, and FA was found to be the most effective combination in treating pigmentation in 60 women with melasma.³⁵ Overall, FA's potent antioxidant properties make it a desirable treatment option for pigmentation due to its high bioavailability properties and low side-effect profile.³²

Resorcinol

Resorcinols are effective tyrosinase inhibitors.³⁷ 4-n-Butylresorcinol (Figure 1i), is a derivative of resorcinol and has been used in depigmentation treatments. Okubo and colleagues reported that 4-n-butylresocinol has inhibitory effects on melanogenesis through direct inhibition of tyrosinase activity and synthesis.³⁸ Subsequent *in vitro* studies have revealed 4-n-butylresocinol's ability to inhibit melanin synthesis and activation of tyrosinase and tyrosinase-related protein-1.³⁹ This inhibition was found to be more potent than hydroquinone, arbutin and KA monotherapy.³⁷

In a study, patients treated with 4-n-butylresocinol had significantly lower pigmentation scores than vehicle-treated skin ($n=32$), with a baseline pigmentation score of 7.5 ± 1.9 reduced to a score of 6.2 ± 2.3 at 12-weeks in the treated group ($p=0.027$).⁴⁰ This efficacy was replicated in a separate study in which melasma patients were given 4-n-butylresocinol cream 0.1%, to apply to each side of the face twice daily for eight weeks ($n=20$).⁴¹ A

statistically significant decrease in the mean melanin index was found in those treated with 4-*n*-butylresorcinol (3.43%) compared with vehicle treated skin (0.15%) ($p=0.006$).⁴¹ Reported side-effects included mild erythema and itching seen in two patients.⁴¹

Madan Mohan and colleagues also treated melasma patients with twice daily 4-*n*-butylresorcinol 0.3% cream for eight weeks ($n=52$).⁴² MASI score significantly decreased from baseline score of 14.73 ± 0.59 to 11.09 ± 0.53 after week four ($p<0.001$) and 6.48 ± 0.43 at week eight ($p<0.001$), with no adverse events reported.⁴² Overall, 4-*n*-butylresorcinol appears to be a safe and efficacious treatment option for melasma.

Resorcinol, combined with salicylic acid and lactic acid in ethanol is commonly used in chemical peels for lightening often in combination with Trichloroacetic acid (TCA), called Jessner's solution. This combination allows more uniform penetration, better peeling with a smaller and safer concentration of TCA.⁴³

Licorice root extract

Licorice (*Glycyrrhiza glabra*) has been shown to contain hydrophobic fractions, with flavonoids which partially inhibit melanogenesis, likely due to tyrosinase inhibition.⁴⁴ Glabridin is the main component of the hydrophobic part of liquorice extract with cutaneous activity, which has shown to inhibit

tyrosinase activity in animal models.⁴⁵ Another active ingredient of licorice root, liquiritin, reduces UV-induced erythema, has an anti-inflammatory effect and has an inhibitory effect on melanosomes.⁴⁶

The efficacy of topical 2% liquiritin, topical 4% liquiritin, and topical 4% hydroquinone was compared ($n=90$). Topical 4% liquiritin was reported as being more effective than 2% liquiritin and 2% topical liquiritin was reportedly more efficacious than 4% hydroquinone.⁴⁶ In a separate study, melasma patients were treated with liquiritin on one side of their face and vehicle cream on the other twice daily for four weeks ($n=20$). 80% of patients showed an excellent response to treatment on the liquiritin side.⁴⁷

A subsequent study, compared hydroquinone 2% cream used once a day with emblica, licorice and belides combination cream used twice daily.⁴⁷ A similar improvement in melasma was seen in both groups (88.9%, and 78.3% respectively) which were statistically significant from baseline ($p<0.001$).⁴⁸ There were similar improvements in both groups in terms of the MASI.⁴⁷ This study suggests that combination treatment of emblica, licorice and belides, might be a safe and efficacious alternative to hydroquinone.⁴⁸

Overall, licorice extracts might be a natural beneficial treatment for hyperpigmentation and larger randomised controlled trials are required to support this.

Soy

Natural soybeans contain the small proteins Bowman-Birk inhibitor and soybean trypsin inhibitor in addition to isoflavanes and serine proteases which have demonstrated anti-senescent, antioxidant, pigment attenuating, photoprotecting and melanosome transfer inhibiting properties.⁴⁹ It possibly exerts its effects through interaction with the protease-activated receptor 2 (PAR-2).⁴⁹ Inhibition of this pathway reduced melanosome phagocytosis by keratinocytes leading to reduced melanin transfer leading to reduced skin pigmentation.⁴⁹ A randomised controlled trial found a soy containing moisturiser to be significantly more efficacious than a vehicle product in 65 women with facial pigmentation damage after 12 weeks of treatment with improvements in pigmentation, blotchiness, dullness, fine lines, overall texture, skin tone and overall appearance.⁵⁰ Hermanns *et al* found soybean extract to have skin-lightening effects in men suffering from facial hyperpigmentation after three weeks of treatment ($n=44$).⁵¹ Pierard and colleagues also beneficial effects of soy extract for 16 melasma patients after once daily application for three months.⁵² Treated lesions demonstrated an average reduction in hyperpigmentation by 12% and 87.5% of patients had improvements in their pigmentation.⁵²

Conclusion

Management of hyperpigmentation disorders including melasma is often challenging, requiring protracted treatments with various agents. The use of cosmeceuticals has the potential to treat hyperpigmentation in a perceptibly more 'natural' way, with fewer adverse effects associated with more established treatments such as hydroquinone. Whilst we acknowledge our list is not exhaustive, thiamidol, KA, vitamin C, arbutin, retinol, nicotinamide, FA and resorcinol have promising potentials in the treatment of melasma and disorders of pigmentation and are suitable as monotherapy or in combination with other treatment modalities. These substances appear both efficacious and safe with only minor side-effects reported with supportive evidence for their use from small *in vivo* and *in vitro* studies. However, large randomised controlled trials with long follow-ups are lacking. Future research should focus on the exploitation of natural substances with hypopigmentary properties to circumvent side-effects associated with currently available treatments.

Accepted Article

References

- (1) Sarkar R, Arora P, Garg KV. Cosmeceuticals for Hyperpigmentation: What is Available? *J Cutan Aesthet Surg*. 2013;6(1):4-11.
- (2) Draelos ZD. Cosmeceuticals: What's Real, What's Not. *Dermatol Clin*. 2019;37(1):107-115.
- (3) Zolghadri S, Bahrami A, Hassan Khan MT, *et al*. A comprehensive review on tyrosinase inhibitors. *J Enzyme Inhib Med Chem*. 2019;34(1):279-309.
- (4) Mann T, Gerwat W, Batzer J *et al*. Inhibition of human tyrosinase requires molecular motifs distinctively different from mushroom tyrosinase. *J Invest Dermatol* . 2018;138(7):1601-8.
- (5) Arrowitz C, Schoelermann AM, Mann T, Jiang LI, Weber T, Kolbe L. Effective tyrosinase inhibition by thiamidol results in significant improvement of mild to moderate melasma. *J Invest Dermatol*. 2019;139(8):1691-8.
- (6) Philipp-Dormston WG, Vila Echagüe A, Pérez Damonte SH, *et al*. Thiamidol containing treatment regimens in facial hyperpigmentation: An international multi-center approach consisting of a double-blind, controlled, split-face study and of an open label, real-world study [published online ahead of print, 2020 May 10]. *Int J Cosmet Sci*. 2020;10.1111/ics.12626. doi:10.1111/ics.12626.
- (7) Saeedi M, Eslamifar M, Khezri K. Kojic acid applications in cosmetic and pharmaceutical preparations. *Biomed Pharmacother*. 2019;110:582-93.

(8) Saghaie L, Pourfarzam M, Fassihi A, Sartippour B. Synthesis and tyrosinase inhibitory properties of some novel derivatives of kojic acid. *Res Pharm Sci*. 2013;8(4):233-42.

(9) Scientific Committee on Consumer Safety. European Commission. Opinion on kojic acid. [Internet]. (updated 26-27 June 2012; cited 12 June 2020). Available from:

https://ec.europa.eu/health/sites/health/files/scientific_committees/consumer_safety/docs/sccs_o_098.pdf

(10) Lim JT. Treatment of melasma using kojic acid in a gel containing hydroquinone and GA. *Dermatol Surg*. 1999;25(4):282- 284.

(11) Garcia A, Fulton JE Jr. The combination of GA and hydroquinone or kojic acid for the treatment of melasma and related conditions. *Dermatol Surg*. 1996;22(5):443- 447.

(12) Al-Niaimi F, Chiang NYZ. Topical Vitamin C and the Skin: Mechanisms of Action and Clinical Applications. *J Clin Aesthet Dermatol*. 2017;10(7):14-17.

(13) Hwang SW, Oh DJ, Lee D, Kim JW, Park SW. Clinical efficacy of 25% L-ascorbic acid (C'ensil) in the treatment of melasma. *J Cutan Med Surg*. 2009;13(2):74- 81.

(14) Espinal-Perez LE, Moncada B, Castanedo-Cazares JP. A double-blind randomized trial of 5% ascorbic acid vs. 4% hydroquinone in melasma. *Int J Dermatol*. 2004;43(8):604- 607.

- (15) Handog EB, Galang DA, De Leon- Godinez MA, Chan GP. A randomized, double- blind, placebo- controlled trial of oral procyanidin with vitamins A, C, E for melasma among Filipino women. *Int J Dermatol*. 2009;48(8):896-901.
- (16) Menon A, Eram H, Kamath PR, Goel S, Babu AM. A Split Face Comparative Study of Safety and Efficacy of Microneedling with Tranexamic Acid versus Microneedling with Vitamin C in the Treatment of Melasma. *Indian Dermatol Online J*. 2019;26;11(1):41-45.
- (17) Ismail ESA, Patsatsi A, Abd EI-Maged WM, Nada EEAE. Efficacy of microneedling with topical vitamin C in the treatment of melasma [published online ahead of print, 2019 Feb 15]. *J Cosmet Dermatol*. 2019;10.1111/jocd.12878.
- (18) Taylor MB, Yanaki JS, Draper DO, Shurtz JC, Coglianese M. Successful short-term and long-term treatment of melasma and postinflammatory hyperpigmentation using vitamin C with a full-face iontophoresis mask and a mandelic/malic acid skin care regimen. *J Drugs Dermatol*. 2013;12(1):45- 50.
- (19) Crocco EI, Veasey JV, Boin MF, Lellis RF, Alves RO. A novel cream formulation containing nicotinamide 4%, arbutin 3%, bisabolol 1%, and retinaldehyde 0.05% for treatment of epidermal melasma. *Cutis*. 2015;96(5):337- 342.

- (20) Ethnic skin and pigmentation. In: Draeos ZD. *Cosmetics and Dermatologic Problems and Solutions*. 3rd ed. Boca Raton, FL: CRC Press; 2011:52-55.
- (21) Morag M, Nawrot J, Siatkowski I, *et al* A double-blind, placebo-controlled randomized trial of *Serratulae quinquefoliae folium*, a new source of β -arbutin, in selected skin hyperpigmentations. *J Cosmet Dermatol*. 2015;14(3):185-90.
- (22) Polnikorn N. Treatment of refractory melasma with the MedLite C6 Q-switched Nd: YAG laser and alpha arbutin: a prospective study. *J Cosmet Laser Ther*. 2010;12(3):126-31.
- (23) Zasada M, Budzisz E. Retinoids: active molecules influencing skin structure formation in cosmetic and dermatological treatments. *Postepy Dermatol Alergol*. 2019;36(4):392-397.
- (24) Rendon MI, Barkovic S. Clinical Evaluation of a 4% Hydroquinone + 1% Retinol Treatment Regimen for Improving Melasma and Photodamage in Fitzpatrick Skin Types III-VI. *J Drugs Dermatol*. 2016;15(11):1435-1441.
- (25) Yoshimura K, Momosawa A, Aiba E, *et al*. Clinical trial of bleaching treatment with 10% all-trans retinol gel. *Dermatol Surg*. 2003;29(2):155-160.
- (26) Green C, Orchard G, Cerio R, *et al*. A clinicopathological study of the effects of topical retinyl propionate cream in skin photoageing. *Clin Exp Dermatol*. 1998;23:162-167.

- (27) Watson REB, Long SP, Bowden JJ, *et al.* Repair of photoaged dermal matrix by topical application of a cosmetic 'antiageing' product. *Br J Dermatol.* 2008;158: 472-477.
- (28) Sorg O, Kasraee B, Salomon D, Saurat JH. The potential depigmenting activity of retinaldehyde. *Dermatology.* 2013;227(3):231-7.
- (29) Dhaliwal S, Rybak I, Ellis SR, *et al.* Prospective, randomized, double-blind assessment of topical bakuchiol and retinol for facial photoageing. *Br J Dermatol.* 2019;180(2):289-96.
- (30) Forbat E, Al - Niimi F, Ali FR. Use of nicotinamide in dermatology. *Clin Exp Dermatol.* 2017;42(2):137-44.
- (31) Navarrete-Solís J, Castanedo-Cázares JP, Torres-Álvarez B *et al.* A Double-Blind, Randomized Clinical Trial of Niacinamide 4% versus Hydroquinone 4% in the Treatment of Melasma. *Dermatol Res Pract.* 2011;2011:379173.
- (32) Zduńska K, Dana A, Kolodziejczak A, Rotsztein H. Antioxidant properties of FA and its possible application. *Skin Pharmacol Phys.* 2018;31(6):332-6.
- (33) Ichihashi M, Funasaka Y, Ohashi A, *et al.* The inhibitory effect of DL-alpha-tocopheryl ferulate in lecithin on melanogenesis. *Anticancer Res.* 1999;19(5A):3769- 3774.
- (34) Funasaka Y, Komoto M, Ichihashi M. Depigmenting effect of alpha-tocopheryl ferulate on normal human melanocytes. *Pigment Cell Res.* 2003;13 Suppl 8:170- 174.

- (35) Mazurek K, Pierzchała E. Comparison of efficacy of products containing azelaic acid in melasma treatment. *J Cosmet Dermatol*. 2016;15(3):269-82.
- (36) Kim J, Kim J, Lee YI, Almurayshid A, Jung JY, Lee JH. Effect of a topical antioxidant serum containing vitamin C, vitamin E, and FA after Q-switched 1064-nm Nd: YAG laser for treatment of environment-induced skin pigmentation. *J Cosmet Dermatol*. 2020;doi: 10.1111/jocd.13323.
- (37) Kolbe L, Mann T, Gerwat W *et al*. 4-n-butylresorcinol, a highly effective tyrosinase inhibitor for the topical treatment of hyperpigmentation. *J Eur Acad Dermatol Venereol*. 2013;27:19-23.
- (38) Okubo T, Oyohikawa M, Futaki K, Matsukami M, Fujii A. The inhibitory effects of 4-N-butyl-resorcinol on melanogenesis [abstract]. *J Dermatol Sci*. 1995;10:88.
- (39) Kim DS, Kim SY, Park SH *et al*. Inhibitory effects of 4-n-butylresorcinol on tyrosinase activity and melanin synthesis. *Biol Pharm Bull*. 2005;28:2216–2219.
- (40) Khemis A, Kaiafa A, Queille-Roussel C, Duteil L, Ortonne JP. Evaluation of efficacy and safety of rucinol serum in patients with melasma: a randomized controlled trial. *Br J Dermatol*. 2007;156(5):997-1004.
- (41) Huh SY, Shin JW, Na JI, Huh CH, Youn SW, Park KC. The Efficacy and Safety of 4-n-butylresorcinol 0.1% Cream for the Treatment of Melasma: A Randomized Controlled Split-face Trial. *Ann Dermatol*. 2010;22(1):21-5.

- (42) Madan Mohan NT, Gowda A, Jaiswal AK *et al.* Assessment of efficacy, safety, and tolerability of 4-n-butylresorcinol 0.3% cream: an Indian multicentric study on melasma. *Clin Cosmet Investig Dermatol.* 2016;9:21-7.
- (43) Sarkar R, Bansal S, Garg VK. Chemical peels for melasma in dark-skinned patients. *J Cutan Aesthet Surg.* 2012 Oct;5(4):247-53.
- (44) Simmler C, Pauli GF, Chen SN. Phytochemistry and biological properties of glabridin. *Fitoterapia.* 2013;90:160-84.
- (45) Yokota T, Nishio H, Kubota Y, Mizoguchi M. The inhibitory effect of glabridin from licorice extracts on melanogenesis and inflammation. *Pigment Cell Res.* 1998;11(6):355-361.
- (46) Zubair S, Mujtaba G. Comparison of efficacy of topical 2% liquiritin, topical 4% liquiritin and topical 4% hydroquinone in the management of melasma. *J Pakistan Assoc Dermatologist.* 2009;19:158–163.
- (47) Amer M, Metwalli M. Topical liquiritin improves melasma. *Int J Dermatol.* 2000;39:299–301.
- (48) Costa A, Silva C, Arruda L, Zaniboni M, Cordero T, Moisés T. The association of emblica, licorice, and belides is an effective alternative to hydroquinone for the clinical treatment of melasma: P3205. *J Am Acad Dermatol.* 2010;62(3).
- (49) Seiberg M, Paine C, Sharlow E, *et al.* The protease-activated receptor 2 regulates pigmentation via keratinocyte-melanocyte interactions. *Exp Cell Res.* 2000;254:25-32.

(50) Wallo W, Nebus J, Leyden JJ. Efficacy of a soy moisturizer in photoaging: a double-blind, vehicle-controlled, 12-week study. *J Drugs Dermatol*. 2007;6(9):917-922.

(51) Hermanns JF, Petit L, Martalo O, *et al*. Unraveling the patterns of subclinical pheomelanin-enriched facial hyperpigmentation: effect of depigmenting agents. *Dermatology*. 2000;201(2):118–122.

(52) Pierard G, Graf R, Gonzalez R, Cauwenbergh W. Effects of soy on hyperpigmentation in Caucasian and Hispanic populations. 59th Annual Meeting of the American Academy of Dermatology; March 2-7, 2001; Washington, DC.

Table 1. Cosmeceutical Treatment of Melasma

Study	Authors	Year	Study Type	Number of Patients	Intervention	Outcome	Adverse Effects
Thiamidol	Arrowitz C, Schoelermann AM, Mann T, Wang LI, Weber T, Kolbe L ⁵	2019	Double-blinded, randomised split-face	80	Females were treated with either thiamidol on one cheek and a control substance on the other or thiamidol one cheek and	Thiamidol (0.2% oil-in-water emulsion) improvement was found to be significantly more efficacious than	None reported

			hydroquinone on the other cheek for 12 weeks	hydroquinone (2.0%)(79% versus 61% respectively improvement) measured using the Melasma Area and Severity Index Scores ($p<0.001$). Self-assessment of pigmentation was also improved in both groups	
Philipp-Formston WG, Vila Echagüe A, Pérez Damonte SH, <i>et al.</i> ⁶	2020	Multi-Center Approach Consisting of a Double-Blind, Controlled, Split-Face Study and of an Open Label, Real-World Study	A split-face double blind randomised controlled trial in 34 patients used two thiamidol containing products twice or four times daily on one half of the face and a normal SPF30 on the whole face The second trial was a separate single arm observational study (n=83) in which patients were treated with SPF30 in the day and at night thiamidol serum and night care cream	After 12 weeks, hyperpigmentation, skin roughness and MASI all improved significantly compared with baseline (-0.78±0.52, -0.87±0.45; $p<0.001$) in the split-face study, whilst in the observational real-life study, skin condition and chromametry improved significantly compared to baseline. Self-assessment	None reported

scores also improved significantly from baseline. The four-times daily thiamidol improved facial hyperpigmentation significantly more than the two-times group and was well tolerated.

Kojic Acid (KA)

Lim JT¹⁰

1999 Double blinded right/left comparison study 40

KA 2% gel (containing 10% GA and 2% hydroquinone was used on one side of the face of 40 women, whilst the other side was treated with the same gel without KA

All patients had an improvement on both sides of the face, but patients treated with KA had 60% clearance versus 47.5% without the KA

Redness, stinging and exfoliation

Garcia A, Fulton JE Jr¹¹

1996 Right/Left comparison study 39

Patients were treated with KA on one side of the face and hydroquinone on the other side of the face

There was no statistically significant difference between the treatments. Neither treatment cleared the melasma completely

KA was reported to be more irritating

Vitamin C

Wang SW, Oh DJ, Lee D, Kim JW, Park SW¹³

2009 Open-label clinical trial 40

C'ensil containing 25% L-ascorbic acid was used twice

Patients treated with C'ensil had a significant

30 patients experiences stinging, 23 had burning

				daily for 16 weeks in melasma patients	decrease in their MASI scores and in increase in quality of life scores	and 6 had pruritus, 8 had erythema and 5 had scaling
Espinal-Perez E, Moncada B, Castanedo-Cazares JP ¹⁴	2004	Double-blind randomized trial	16	5% ascorbic acid (vitamin C) was used on one side of the face and 4% hydroquinone cream used on the other, every night for 16 weeks	Hydroquinone was superior from subjective measurements than ascorbic acid (93% good and excellent results versus 62.5% respectively, $p < 0.05$). There was no statistical difference in colorimetric measures	Irritation (11 patients with hydroquinone and 1 taking ascorbic acid)
Mandog EB, Galang DA, De Leon-Godinez MA, Chan GP ¹⁵	2009	Randomized, double-blind, placebo-controlled trial	80	Patients were treated with combination of procyanidin (24mg) and vitamin A (6mg), C (60mg), E (15IU) or a placebo twice daily for 8 weeks	The MASI score improved for both placebo and treatment groups ($p = 0.001$)	One subject reported a metallic taste

Menon A, Eram H, Kamath PR, Goel S, Babu AM ¹⁶	2020	Split-face comparative study	30	20% Vitamin C with microneedling on one side of the face was compared with tranexamic acid (4mg/mL) and microneedling on the other side, given twice a month for 8 weeks	Both treatments produced a significant improvement. The improvement with the tranexamic acid was more than with vitamin C, although this was not statistically significant	10 had mild itching and a burning sensation which resolved spontaneously
Ismail ESA, Tatsatsi A, Abd El-Maged WM, Nada EEAE ¹⁷	2019	Prospective clinical trial	30	Melasma patients were given sessions of microneedling with the addition of vitamic C (topical) every two weeks	All patients had improvement after each session. Mean MASI score was significantly reduced ($p<0.0001$)	Tolerable pain during microneedling and mild erythema
Taylor MB, Yanaki JS, Draper DO, Snurtz JC, Coglianese M ¹⁸	2013	Open label clinical trial	35	Patients treated with full face iontophoresis mask and vitamic C (ascorbyl glucoside preparation). Patients had one treatment and 12-24 home treatments over 1-2 months with sun avoidance behaviour	A mean improvement of 73% in abnormal pigmentation was reported and MASI improved by 15.7 from baseline	None reported

ArbutinMorag M, Nawrot J, Siatkowski I, *et al.*²¹

2014 Randomised, placebo-controlled, double-blind 102

A cream containing 2.51% arbutin was applied twice a day for eight weeks

Lightening and evening of skin tone was found in 66.67% of patients

None reported

Polnikorn N²²

2010 Prospective study 35

Patients were treated with Nd:YAG laser (weekly for 10 sessions and two monthly follow-up sessions and 7% topical alpha arbutin solution

66.67% patients had good or excellent clearing of their melasma

Discomfort during treatment, erythema, whitening of fine hair and urticarial, three cases of mottling hypopigmentation and two cases of melasma recurrence were reported.

RetinolRendon MI, Markovic S²⁴

2016 Open-label clinical trial 31

A hydroquinone and cosmetic retinol combination were used in melasma and photodamaged patients for 24 weeks

Improvements in the MASI were found after four week's treatment

No significant adverse effects

Yoshimura K, Momosawa A, Ueba E, *et al.*²⁵

2010 Open-label clinical trial 21

10% retinol, 5% hydroquinone and 7% lactic acid gel was given to patients with skin pigmentation for 6 weeks

Clinical improvements were found in 88.9% of patients

Erythema and scaling

Dhaliwal S, Rybak I, Ellis SR, <i>et al</i> ⁹	2019	Randomized controlled trial	44	Patients were given either bakuchiol 0.5% cream twice daily or retinol 0.5% cream	Both treatments significantly decreased hyperpigmentation and wrinkle surface area with no statistically significant difference between compounds	The retinol treatment led to greater facial skin scaling and stinging
Nicotinamide Crocco EI, Measey JV, Boin MF, Lellis RF, Alves RO ¹⁹	2015	Single-center, single-arm, prospective, open-label study	35	A cream containing combinations of nicotinamide 4%, arbutin 3%, bisabolol 1% and retinaldehyde 0.05% was used once a day for 30 days	MASI scores were reduced significantly. The total melasma surface area was reduced from 1398.5mm ² at baseline to 1116.9mm ² at day 30 ($p=0.001$) and 923.4 at day 60 ($p=0.001$). Patient satisfaction was improved significantly, 75.8% were dissatisfied with their skin appearance at baseline versus 15.2% at day 60.	Burning in 10 patients at day 30, and in 4 at day 60.
Navarrete-Solís J, Castanedo-	2011	Double-Blind, Randomi	27	4% nicotinamide cream on one side of the face	All patients had pigmentary	18% of patients treated with

Cázares JP *et al.*³¹

sed
Clinical
Trial

and 4%
hydroquinone
on the other
side for four
weeks

improvements,
and no
statistically
significant
difference was
observed
between the
groups.
Nicotinamide
reduced mast
cells infiltrates
and improved
solar elastosis
in patients with
melasma

nicotinamid
e reported
side effects
versus 29%
treated with
hydroquinon
e. Most
frequently,
erythema,
pruritus and
burning
were
observed.

Ferulic Acid

Mazurek K,
Pierzchała E³⁵

2016

Open-
label
clinical
trial

60

Melasma
patients were
given different
combinations
containing
azelaic acid to
apply twice a
day for 6
months

A combination
of 20% azelaic
acid, mandelic
acid, phytic
acid, 4N-butyl
resorcinol and
FA was most
efficacious in
reducing
melasma after
6 months of
treatment

None
reported

Kim J, Kim J,
Lee YI,
Aimurayshid A,
Jung JY, Lee
SH³⁶

2020

Single
blinded,
prospecti
ve,
randomi
sed
split-
face trial

18

Topical
antioxidant
serum
containing
vitamin C, E and
FA after post-
laser
hyperpigmentati
on was given to
patients to apply
on one side of
the face twice
daily for two
weeks

The side of the
face treated
with this
regimen had a
significantly
greater
reduction in
the melanin
index than the
untreated side
and a global
improvement
score of 2.06
weeks

None
reported

± 0.0.87
(*p*<0.05)

Resorcinol

Khemis A,
Kaiafa A,
Queille-Roussel
C, Duteil L,
Ortonne JP⁴⁰

2007 Randomi 32

sed
controlle
d trial

Rucinol serum
0.3% (4-n-
butylresocinol)
was compared
to a vehicle
treatment in
patients with
melasma.
Patients applied
the serum twice
daily for 12
weeks

After 12
weeks, the
mean
pigmentation
score was
found to be
significantly
lower with
rucinol than
with the
vehicle
(*p*=0.027), with
a baseline
score of 7.5±
1.9 to a score
of 6.2± 2.3 at
12 weeks

Mild
stinging,
burning or
pruritus
(very few
reports) and
a low
frequency of
erythema,
dryness,
peeling and
desquamati
on

Huh SY, Shin
JW, Na JI, Huh
CH, Youn SW,
Park KC⁴¹

2010 Randomi 20

sed,
double
blind,
vehicle-
controlle
d, split-
face
compara
tive
study.

Melasma
patients were
given 4-n-
butylresocinol
cream 0.1%, to
apply to each
side of the face
twice daily for
eight weeks

A statistically
significant
decrease in
the mean
melanin index
was found in
those treated
with 4-n-
butylresocinol
(-3.43%)
compared with
placebo (-
0.15%)
(*p*=0.006)

Mild
erythema
and itching
seen in two
patients

Madan Mohan
M T, Gowda A,
Jaiswal AK, et
⁴²

2016 Open- 52

label,
single
arm,
observati
onal
study.

Patients were
treated twice
daily with 4-n-
butylresocinol
0.3% cream for
eight weeks

MASI score
significantly
decreased a
from
baseline score
of 14.73±0.59
to 11.09±0.53

None
reported

Licorice rootZubair S,
Mujtaba G⁴⁶

2016

Double
blind
clinical
trial

90

The efficacy of topical 2% liquiritin, topical 4% liquiritin, and topical 4% hydroquinone was compared. Patients were given one of these three treatments and instructed to apply the cream once daily for eight weeks

after week four ($p<0.001$) and 6.48 ± 0.43 at week eight ($p<0.001$)

Topical 4% liquiritin was significantly more effective than 2% liquiritin and 2% topical liquiritin was significantly more efficacious than 4% hydroquinone

Two patients reported contact dermatitis and one hyperpigmentation with use of 4% hydroquinone use

Amer M,
Metwalli M⁴⁷

2000

Open
label
clinical
trial

20

Melasma patients were treated with liquiritin one side of their face and vehicle cream on the other twice daily for four weeks

80% of patients showed an excellent response to treatment

Mild irritation

Costa A, Silva C, Arruda L, Zaniboni M, Cordero T, Moisés T ⁴⁸	2010	Open label clinical trial	55	Patients were treated with hydroquinone 2% cream used once a day or treated with emblica, licorice and belides combination cream used twice daily.	A similar improvement in melasma was seen in both groups 88.9%, and 78.3% respectively) which were statistically significant from baseline ($p < 0.001$). There were similar improvements in both groups in terms of the MASI score.	None reported
Soy Wallo W, Nebus J, Leyden JJ ⁵⁰	2007	Randomised controlled trial	65	A soy containing moisturiser was compared with a vehicle cream	A soy containing moisturiser was significantly more efficacious than a vehicle product in women with facial pigmentation damage after 12 weeks of treatment with improvements in pigmentation, blotchiness, dullness, fine lines, overall texture, skin tone and	None reported

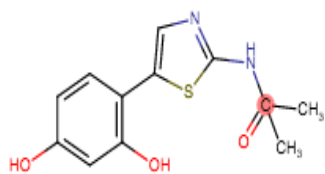
Hermanns JF, Petit L, Martalo O, <i>et al</i> ⁵¹	2000	44	Azelaic acid, glycolic acid and soy extract were tested in patients	overall appearance Soybean extract to have skin-lightening effects in men suffering from facial hyperpigmentation after three weeks of treatment	None reported
Pierard G, Graf R, Gonzalez R, Cauwenbergh W ⁵²	2001	16	Soy extract was given once daily for three months	Treated lesions demonstrated an average reduction in hyperpigmentation by 12% and 87.5% of patients had improvements in their pigmentation	None reported

Table 2. Mechanism of action of cosmeceuticals

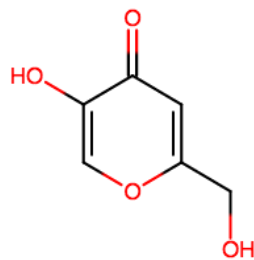
Cosmeceutical	Mechanism of Action	References
Thiamidol	Human tyrosinase competitive inhibitor	4-6
Kojic Acid	Inhibits tyrosinase genesis with antioxidant effects	7-11
Vitamin C	Tyrosinase inhibition through interaction with copper ions at tyrosinase active sites,	12-18

	decreasing melanogenesis Antioxidant effects	
Arbutin	Reduces tyrosinase activity and inhibits melanocyte maturation	19-22
Retinol	Inhibition of matrix metalloproteinase activation inhibition of oxidative stress decreased melanosome transfer. Through regeneration of the extracellular matrix and regulation of keratinocyte differentiation, accelerates exfoliation and reduces epidermal melanin	23-28
Nicotinamide	Antioxidant through polyadenosine diphosphate-ribose polymerase inhibition. Melanosome transfer inhibition	29-30
Ferulic acid	Antioxidant properties	31-34
Resorcinol	Tyrosinase inhibition	36-42
Licorice root extract	Glabridin inhibits tyrosinase. Liquiritin, reduces UV-induced erythema, is anti-inflammatory and has inhibitory effect on melanosomes	43-47

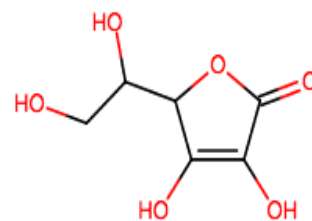
Soybean	Contains isoflavanes and serine proteases which have anti-senescent, antioxidant, pigment attenuating, photoprotecting and melanosome transfer inhibiting properties	48-51
---------	--	-------



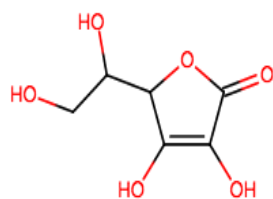
1a. Thiamidol



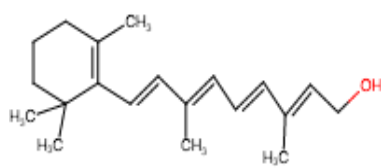
1b. Kojic Acid



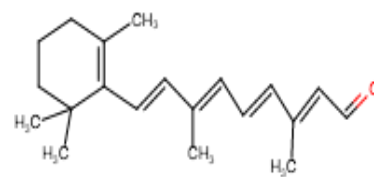
1c. Vitamin C



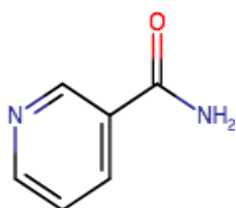
1d. Arbutin



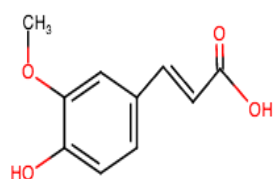
1e. Retinol



1f. Retinaldehyde



1g. Nicotinamide



1h. Ferulic acid

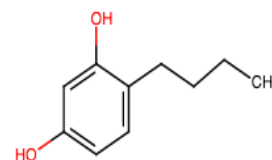
1i. 4-*n*-butylresorcinol

Figure 1. Chemical structures of cosmeceuticals. Adapted from (4). Images created using <https://chem-space.com/search>