



Aalborg Universitet

AALBORG UNIVERSITY  
DENMARK

## Moyamoya disease in a European setting

*A Danish population-based study*

Birkeland, Peter; Tharmabalan, Vinosha; Lauritsen, Jens; Ganesan, Vijeya; Bjarkam, Carsten  
Reidies; von Weitzel-Mudersbach, Paul

*Published in:*  
European Journal of Neurology

*DOI (link to publication from Publisher):*  
[10.1111/ene.14439](https://doi.org/10.1111/ene.14439)

*Publication date:*  
2020

*Document Version*  
Accepted author manuscript, peer reviewed version

[Link to publication from Aalborg University](#)

*Citation for published version (APA):*  
Birkeland, P., Tharmabalan, V., Lauritsen, J., Ganesan, V., Bjarkam, C. R., & von Weitzel-Mudersbach, P. (2020). Moyamoya disease in a European setting: A Danish population-based study. *European Journal of Neurology*, 27(12), 2446-2452. <https://doi.org/10.1111/ene.14439>

### General rights

Copyright and moral rights for the publications made accessible in the public portal are retained by the authors and/or other copyright owners and it is a condition of accessing publications that users recognise and abide by the legal requirements associated with these rights.

- ? Users may download and print one copy of any publication from the public portal for the purpose of private study or research.
- ? You may not further distribute the material or use it for any profit-making activity or commercial gain
- ? You may freely distribute the URL identifying the publication in the public portal ?

### Take down policy

If you believe that this document breaches copyright please contact us at [vbn@aub.aau.dk](mailto:vbn@aub.aau.dk) providing details, and we will remove access to the work immediately and investigate your claim.

DR. PETER BIRKELAND (Orcid ID : 0000-0003-2385-5418)

Article type : Original Article

## MOYAMOYA DISEASE IN A EUROPEAN SETTING: A DANISH POPULATION-BASED STUDY

Peter Birkeland MD<sup>1</sup>, Vinosha Tharmabalan<sup>1</sup>, Jens Lauritsen MD, PhD<sup>2,3</sup>, Vijeya Ganesan MD<sup>4</sup>, Carsten Reidies Bjarkam MD, PhD<sup>1</sup>, Paul von Weitzel-Mudersbach MD, PhD<sup>5</sup>

<sup>1</sup>Department of Neurosurgery, Aalborg University Hospital, Denmark

<sup>2</sup>Department of Orthopaedic Surgery, Odense University Hospital, Denmark

<sup>3</sup>Department of Clinical Research, University of Southern Denmark, Denmark

<sup>4</sup>Department of Paediatric Neurology, The Great Ormond Street Hospital, London, UK

<sup>5</sup>Department of Neurology, The Danish Stroke Center, Aarhus University Hospital, Aarhus, Denmark

Total word count: 2.505

Running title: Moyamoya disease in Denmark

Corresponding author:

Peter Birkeland

Department of Neurosurgery

This article has been accepted for publication and undergone full peer review but has not been through the copyediting, typesetting, pagination and proofreading process, which may lead to differences between this version and the Version of Record. Please cite this article as doi: 10.1111/ene.14439

This article is protected by copyright. All rights reserved

Aalborg University Hospital  
Hobrovej 18-22  
DK-9000 Aalborg  
Denmark  
Email: Peter@Birkeland.dk  
Fax: +45 97662462

## Abstract

**Background:** The incidence of Moyamoya disease (MMD) in Europe is not well known. In those affected, the risk of brain hemorrhage is considered low. The present study aimed to investigate the incidence and clinical presentation of MMD in the Danish population.

**Methods:** Eligible patients were identified in the Danish National Patient Register from 1994 to 2017. We collected clinical and radiological data from individual patient records from neurological, neurosurgical, and pediatric units across Denmark. The diagnosis was validated according to established criteria. We also extracted basic demographic data on the cohort from the Danish Civil Registration System.

**Results:** A total of 52 patients fulfilled the diagnostic criteria for MMD. Most cases were native Danes and only 15% of cases had an East Asian background. The ratio of female to male patients was 1.8, and the incidence had two peaks: one in childhood and another in young middle age.

Until 2007, MMD was only diagnosed sporadically. From 2008 onwards, the incidence rate was 0.07 per 100 000 person-years (95% confidence interval 0.05-0.09 per 100 000 person-years). The most common mode of presentation was ischemic stroke (33%), followed by hemorrhage (23%), headache (17%), and transitory ischemic attack (14%).

**Conclusions:** MMD is rare in Denmark, but associated with a considerable risk of hemorrhage. Thus, MMD should be considered in the workup for ischemic as well as hemorrhagic stroke in children and middle-aged Caucasians.

## Introduction

Moyamoya disease (MMD) is an idiopathic cerebrovascular disease characterized by progressive stenosis and occlusion of the distal intracranial internal carotid artery and its proximal branches<sup>1</sup>.

As the disease progresses, small collaterals - so-called moyamoya vessels - develop at the base of the brain. Affected patients carry an increased risk of stroke: Ischemic lesions are a result of the narrowed vessels, whereas rupture of fragile collaterals may cause hemorrhage. No known causal treatment exists. Current management aims to reduce the risk of stroke, and unlike stroke of other origins, surgical revascularization plays an important role in preventing a future stroke.

Moyamoya disease (MMD) was first reported in Japan<sup>1,2</sup>, where it remains a well-known cause of stroke in children as well as adults, with a reported overall incidence of 0.94 per 100 000 person-years<sup>3</sup>. The disease occurs less frequently in other parts of the world: population-based data are available from the U.S<sup>4</sup>, but the epidemiology of MMD in Europe is not well described due to a paucity of population-based data<sup>5</sup>. Being a rare disease in Europe, affected patients are at risk of going undiagnosed, thus delaying appropriate treatment. Additionally, observations from Japan are not necessarily directly applicable to European practice, as MMD may have distinct clinical features in a European population<sup>6</sup>. In particular, the likelihood of hemorrhage is thought to be much less than in East Asia.

Using nationwide registers, the present study aims to shed light on this rare disease and describe its epidemiology and clinical presentation in Denmark. In a preliminary paper<sup>7</sup>, we reported an overall incidence of 0.047 per 100 000 person-years between 1994 and 2015. However, it was exclusively based on anonymous register data, which neither allowed us to validate the register diagnosis nor provided us with useful information on the clinical presentation of the disease. For the present paper, we obtained permission to access individual patient charts and radiology reports to address these shortcomings. The study period was also extended to cover the period from 1994 to 2017.

## Methods

All patients with a diagnosis of MMD (I67.5) between 1994 and 2017 were identified in the Danish National Patient Register. This register covers all hospital contacts in Denmark and is often used for scientific research. Discharge diagnoses and dates of discharges from all Danish hospitals have been recorded in the register since 1977, and from 1994, information on visits to outpatient clinics has been included as well<sup>8</sup>. In this way, eligible cases would be detected regardless of variations in referral and treatment pathways for MMD in Denmark during the study period. 1994 was chosen because the diagnosis first appeared in the Danish disease classification when *the International Classification of Diseases version 10* (ICD-10) was introduced that year<sup>8</sup>. Furthermore, patients are registered with their unique and permanent personal identification number, which allowed us to extract information on all admissions and outpatient visits to Danish hospitals for this patient population. Among all hospital contacts, we identified the neurological, neurosurgical, and/or pediatric department in which the diagnosis of MMD was first made. Whenever a patient had been treated at a referral center, we selected the referral center for record review, as only referral centers (i.e., university hospitals) have a neuroradiological service with access to catheter angiography. From the Civil Registration System (established in 1968), we extracted basic demographic data (including sex, date, and place of birth) as well as information on whether a person is native, immigrant or descendant and, in the latter case, country of origin. One author (VT) visited key hospital departments and reviewed all clinical notes, clinical letters, and radiology reports. Data were collected on data sheets using the EpiData Entry Software ([www.epidata.dk](http://www.epidata.dk), The EpiData Association). Items included the date of angiography as well as changes in vessel caliber for individual artery segments in both the anterior and posterior cerebral circulation as well as the presence of moyamoya collaterals, if any. Next, the mode of presentation was established, and underlying conditions, if any, were recorded. Two authors (PB, consultant neurosurgeon with an interest in vascular neurosurgery, and PvW-M, consultant neurologist with an interest in vascular neurology) independently reviewed the datasheets. We used the definition of MMD as stated by the Research Committee on Spontaneous Occlusion of the circle of Willis (Moyamoya disease) in Japan<sup>9</sup>. In accordance with this definition, patients were classified as having definite MMD (dMMD) when having bilateral stenoses and moyamoya vessels (in children, unilateral moyamoya vessels would suffice). Patients were diagnosed as having

probable MMD (pMMD) when having stenosis and moyamoya vessels on one side or bilateral stenoses alone (i.e., Suzuki grade I) if we could rule out alternative diagnoses on clinical and radiological grounds. Patients with similar vascular changes in association with an underlying condition were classified as having moyamoya syndrome (MMS). When available, we reviewed the radiographic films before making a definite diagnosis. If the register diagnosis could not be confirmed, patients were excluded from further analysis. Disagreements were resolved in a consensus meeting. A case was defined as incident on the date of the first angiography fulfilling the diagnostic criteria for MMD. For the calculation of incidence, person-years were approximated by the number of persons at 1 January at any given calendar year. These data are accessible at Statistics Denmark ([www.statistikbanken.dk](http://www.statistikbanken.dk)). The prevalence at 1 Jan 2018 was also calculated. We did a pooled analysis of pMMD and dMMD. Separately, we also reported data on patients with MMS.

#### *Statistical analysis*

Analyses were performed using EpiData Analysis software ([www.epidata.dk](http://www.epidata.dk)) and OpenEpi software ([www.openepi.com](http://www.openepi.com)). For statistics, we used the Fisher exact test and *chi*<sup>2</sup> test with a significance level of 0.05.

#### *Standard Protocol Approvals, Registration, and Patient Consents*

The study was approved by the Danish Data Protection Agency and The Danish Patient Safety Authority. Patient consent was not required.

#### *Data Availability Statement*

The data that support the findings of this study are available from the corresponding author upon reasonable request.

## Results

### *Case validation*

Seventy-six eligible patients were identified in the Danish National Patient Register (see figure 1). Register data from 2121 admissions or outpatient visits (including 340 contacts with a primary or secondary diagnosis of MMD) to Danish hospitals were reviewed. Subsequently, 13 clinical departments in 6 different hospitals were visited. Four additional patients were presented to us during site visits. Those patients were not registered with the specific code for MMD (and therefore they were not retrieved from the register). Of these 80 patients, two were excluded because the patient records could not be retrieved. Thus, charts and radiology reports from 78 patients were available for review. A total of 52 patients fulfilled the diagnostic criteria for MMD. Further, 16 patients had findings consistent with MMS. In 10 cases, a diagnosis of MMD could not be confirmed. Two were known to have an ACTA2 gene mutation<sup>10</sup>, and two cases were investigated due to affected first-degree relatives, but the diagnosis was eventually ruled out; one patient presented with TIA and had unilateral stenosis that did not meet the diagnostic criteria, one patient with Fanconi anemia had an isolated stenosis of the left middle cerebral artery, and four cases were probably coding errors because there were no clinical features suggestive of MMD.

### *Demographic characteristics*

There were 34 females and 18 males. A record review revealed that four of the patients were diagnosed with MMD before 1994. These patients were excluded from the calculation of incidence but were included in the other analyses. Forty patients were native Danes, 2 patients originated from other European countries, 8 originated from East Asia, 1 patient originated from Asia, and 1 patient originated from South America. Eighteen patients (35%) were younger than 18 years at diagnosis. The age at diagnosis showed a bimodal distribution with a peak in childhood and another in middle-aged adults. The average age at presentation was 7 years and 40 years in children and adults respectively.

### *Incidence and prevalence*

Until 2007, MMD was only diagnosed sporadically (figure 2). From 2008 onwards, the incidence rate was 0.07 per 100 000 person-years (95% confidence interval 0.05-0.09 per 100 000 person-years). Five patients had died as of 31 December 2017. Thus, the prevalence at 1 Jan 2018 was 0.8 per 100 000.

#### *Angiographic features*

Of the 52 patients with confirmed MMD, 36 patients had catheter angiography either at diagnosis or at follow-up. Fifteen patients underwent magnetic resonance angiography, whereas one patient underwent computed tomographic angiography. At the latest available imaging, 24 patients (46%) had bilateral stenoses and bilateral moyamoya vessels, 8 (15%) had bilateral stenoses and unilateral moyamoya vessels (5 adults and 3 children), 13 (25%) had unilateral stenosis and moyamoya vessels, and the remaining 7 patients (13%) had bilateral stenoses without moyamoya vessels. Thus, 27 patients and 25 patients were classified as having dMMD and pMMD, respectively (figure 1). In 11 cases (21%), posterior circulation involvement was reported.

#### *Clinical presentation*

The most common mode of presentation was ischemic stroke (33%), followed by hemorrhage (23%), headache (17%), and transitory ischemic attack, TIA (14%). Only one patient was asymptomatic at diagnosis. 8 of 12 patients with hemorrhage had bilateral disease and in 10 of 12 patients, moyamoya vessels were detected. There was no significant difference in the mode of presentation between males and females. In patients younger than 18 years, more than half had TIA (11%) or ischemic stroke (39%) at presentation, while 11% had hemorrhage. Among patients 18 years or older, 29% and 15% presented with ischaemic stroke and TIA, respectively, while 29% presented with hemorrhage (figure 3). However, the difference in clinical presentation between the two age groups was not statistically significant.

#### *Characteristics of cases with an East Asian background*

Eight cases (4 children and 4 adults) descended from East Asia. They were equally distributed between the sexes. 3 cases had pMMD, and 5 had dMMD. 2 cases presented with ischemia, 2 presented with hemorrhage, 3 presented with headache, and 1 patient presented with seizures.

#### *Characteristics of cases with MMS*



Although MMD was the main focus of this study, we also collected data on 16 patients later categorized as having MMS. There were 7 children and 9 adults, and 11 of the 16 patients were females. Neurofibromatosis was the most common associated condition, followed by Down's syndrome, multiple sclerosis, Grange syndrome, Noonan syndrome, and atherosclerosis. The most common mode of presentation was headache (4 cases), followed by transitory ischemic attack (3 cases), ischemic stroke (3 cases), and hemorrhage (2 cases). The indication for angiography was not clear in two cases, of which one was asymptomatic at diagnosis. 13 of 16 patients had bilateral arterial stenoses at angiography, and 14 patients had moyamoya vessels detected.

## Discussion

The incidence of MMD in Europe is not well known. We know a lot more about the clinical features of MMD in Europeans from hospital-based surgical series<sup>11,12</sup>. However, such studies may be subjected to referral bias. To improve our understanding of MMD in a European setting we conducted a population-based study in Denmark using nationwide registers.

We found an increase in diagnosed cases between 1994 and 2017. Adopted children from East Asia and their descendants account partly from the rise. However, the main reason is probably an increased detection rate due to an increased awareness as well as improved imaging. Accessibility to and quality of MR imaging has improved tremendously during the study period. Also, the senior authors (PB and PvW-M) have given presentations on the topic in several national meetings in recent years. The incidence rate from 2008 onwards was 0.07 per 100 000 person-years and is our best estimate of the true incidence. The incidence appears to be less than one-tenth of the incidence of 0.94 per 100 000 person-years in Japan<sup>3</sup> but comparable to the incidence of 0.086 per 100 000 person-years reported in Washington state and California (U.S.A.)<sup>4</sup>. As in Japan, we found a bimodal age distribution.

Twenty-three percent of our cases presented with hemorrhage which is comparable to data from East Asia. This represents our most surprising finding. In the majority of those presenting with hemorrhage, bilateral diseases and moyamoya vessels were detected at angiography. Previous European studies have noted a striking lower proportion of cases reported to have a hemorrhagic presentation (8.5%)<sup>11</sup>. However, there may have been a referral bias at play: Some of those

patients may have been in a poor clinical state, precluding them from referral to a large tertiary center. These patients will be included in a population-based study.

Migration patterns vary among European countries. This introduces a bias in the interpretation of our data as the incidence and possibly also the clinical features vary by race and ethnicity. We were able to take migration into account thanks to comprehensive nationwide registers. It should come as no surprise that descendants from East Asia were overrepresented in our cohort. Still, this group comprised only 15% of our cases and has only a modest impact on the incidence and prevalence of MMD in Denmark. The clinical features of these patients did not stand out from the rest of the cohort, so our study reflects the occurrence of MMD in a Caucasian population. Consequently, it should also apply to other European populations.

This work is the first population-based study on MMD in Europe. We used comprehensive nationwide registers and validated the diagnosis and time of onset by reviewing individual patient charts. The positive predictive value of the register diagnosis I67.5 (MMD *and* MMS) was 86%. The utility of the register also depends on whether a given diagnosis is coded correctly. The fact that we only discovered four additional cases during site visits that were not listed in the register suggests a high grade of completeness of the Danish National Patient Register. We included those cases in the cohort, so our study should include virtually all patients in Denmark diagnosed with MMD.

There are still a few limitations. First, we primarily evaluated and categorized cases based on radiology reports rather than original films. Unlike films, reports were readily accessible, moreover, films are only kept for a maximum of ten years. Different radiologists use descriptive terms differently, which may impact cohort homogeneity. However, we were able to find and systematically review radiological films of patients from one of four Danish university hospitals. We found consistency between the radiological films, radiology reports, and available clinical data and a similar proportion of included cases as among all patients eligible for the study. Second, some patients may still go undetected (false negatives). This includes asymptomatic cases, of which we saw only two. In Japan, asymptomatic cases comprised 17.8% of patients<sup>3</sup>. Third, further studies are needed to establish the clinical course and outcome of surgical intervention of MMD in the Danish population.

## Conclusions

MMD is rare in Denmark, but associated with a considerable risk of hemorrhage. Thus, MMD should be considered in the workup for ischemic as well as hemorrhagic stroke in children and middle-aged Caucasians.

## Acknowledgements

We wish to thank the following colleagues for kind assistance with data collection: Rigshospitalet (Jannick Brennum, Allan Andersen, Karen Vitting Andersen), Bispebjerg Hospital (Lise Korbo), Aarhus University Hospital (Jens Christian Sørensen, Rune Weis Næraa), Odense University Hospital (Mogens Tange, Mads Ravnborg, Marianne Skytte Jakobsen) & Hospital of Southern Jutland (Harald Floer).

## Sources of funding

None

## Disclosures

None

## Bibliography

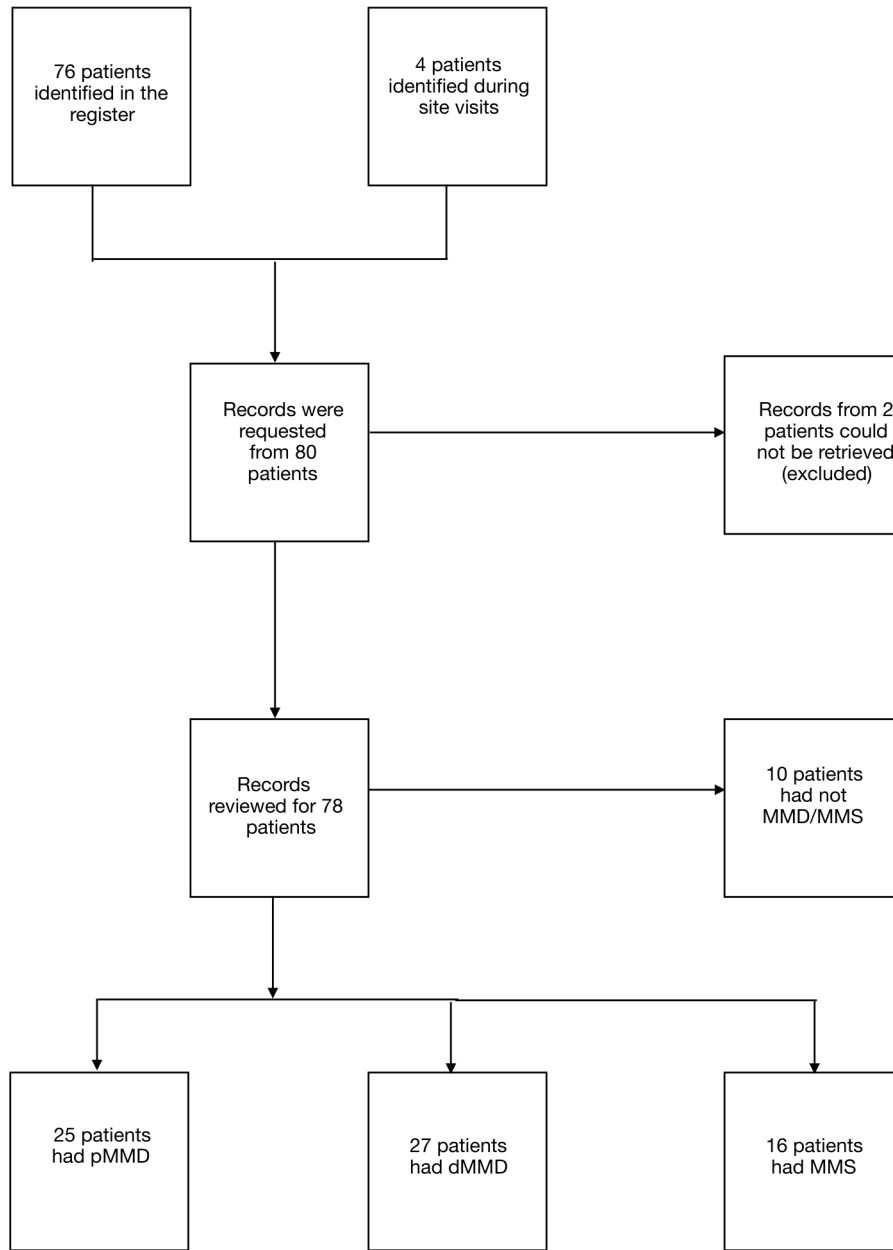
1. Scott RM and Smith ER. Moyamoya disease and moyamoya syndrome. *N Engl J Med*, 2009. 360(12): p. 1226-1237.
2. Suzuki J and Takaku A. Cerebrovascular "moyamoya" disease. Disease showing abnormal net-like vessels in base of brain. *Arch Neurol*, 1969. 20(3): p. 288-299.
3. Baba T, Houkin K, and Kuroda S. Novel epidemiological features of moyamoya disease. *J Neurol Neurosurg Psychiatry*, 2008. 79(8): p. 900-904.
4. Uchino K., Johnston SC, Becker KJ, and Tirschwell DL. Moyamoya disease in Washington State and California. *Neurology*, 2005. 65(6): p. 956-958.
5. Kleinloog R, Regi L, Rinkel GJE, and Klijn CJM. Regional differences in incidence and patient characteristics of moyamoya disease: a systematic review. *J Neurol Neurosurg Psychiatry*, 2012. 83(5): p. 531-536.
6. Hever P, Alamri A, and Tolia C. Moyamoya angiopathy - Is there a Western phenotype? *Br J Neurosurg*, 2015. 29(6): p. 765-771.
7. Birkeland P and Lauritsen J. Incidence of Moyamoya Disease in Denmark: A Population-Based Register Study. *Acta Neurochir Suppl*, 2018. 129: p. 91-93.
8. Schmidt M, Schmidt SA Sandegaard JL, Ehrenstein V, Pedersen L, and Sørensen HT. The Danish National Patient Registry: a review of content, data quality, and research potential. *Clin Epidemiol*, 2015. 7: p. 449-490.
9. Guidelines for diagnosis and treatment of moyamoya disease (spontaneous occlusion of the circle of Willis). *Neurol Med Chir (Tokyo)*, 2012. 52(5): p. 245-266.
10. Munot P, Saunders DE, Milewicz DM et al. A novel distinctive cerebrovascular phenotype is associated with heterozygous Arg179 ACTA2 mutations. *Brain*, 2012. 135(Pt 8): p. 2506-2514.
11. Acker G, Goerdes S, Schneider UC, Schmiedek P, Czabanka M and Vajkoczy P. Distinct clinical and radiographic characteristics of moyamoya disease amongst European Caucasians. *Eur J Neurol*, 2015. 22(6): p. 1012-1017.
12. Saarela M, Mustanoja S, Pekkola J et al. Moyamoya vasculopathy - Patient demographics and characteristics in the Finnish population. *Int J Stroke*, 2017. 12(1): p. 90-95.

Legends

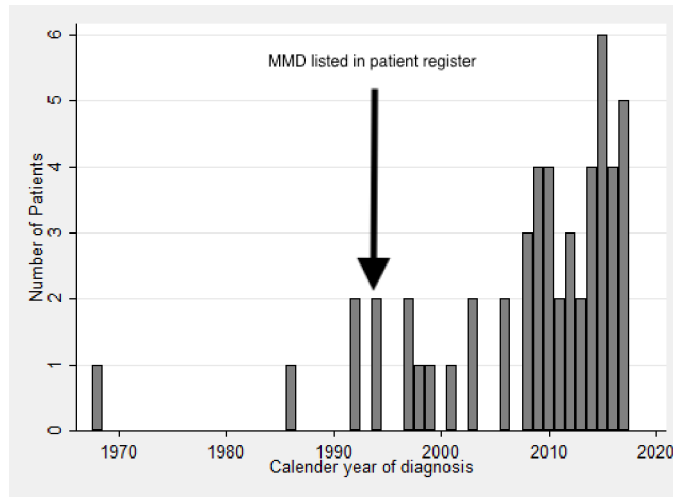
Figure 1: Study flow chart

Figure 2: Annual number of incident cases

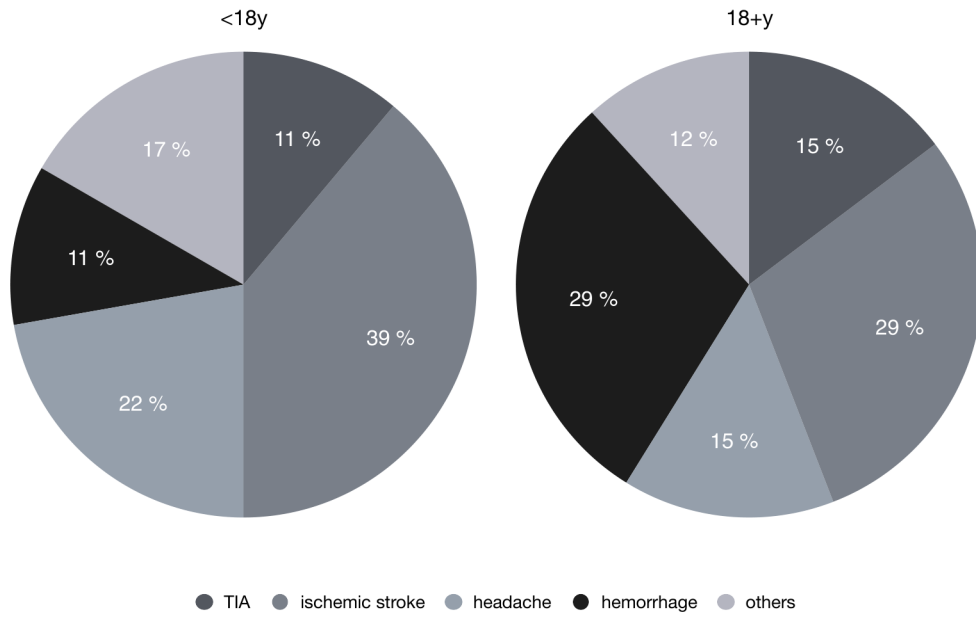
Figure 3: Disease pattern at onset



ene\_14439\_f1.tiff



ene\_14439\_f2.tiff



ene\_14439\_f3.tiff