

University of Vermont

ScholarWorks @ UVM

Larner College of Medicine Fourth Year
Advanced Integration Teaching/Scholarly
Projects

Larner College of Medicine

2020

Pediatric Chest X-rays

Liam du Preez
ldupreez@uvm.edu

Follow this and additional works at: <https://scholarworks.uvm.edu/m4sp>



Part of the [Diagnosis Commons](#), [Medical Education Commons](#), [Other Analytical, Diagnostic and Therapeutic Techniques and Equipment Commons](#), [Pediatrics Commons](#), and the [Radiology Commons](#)

Recommended Citation

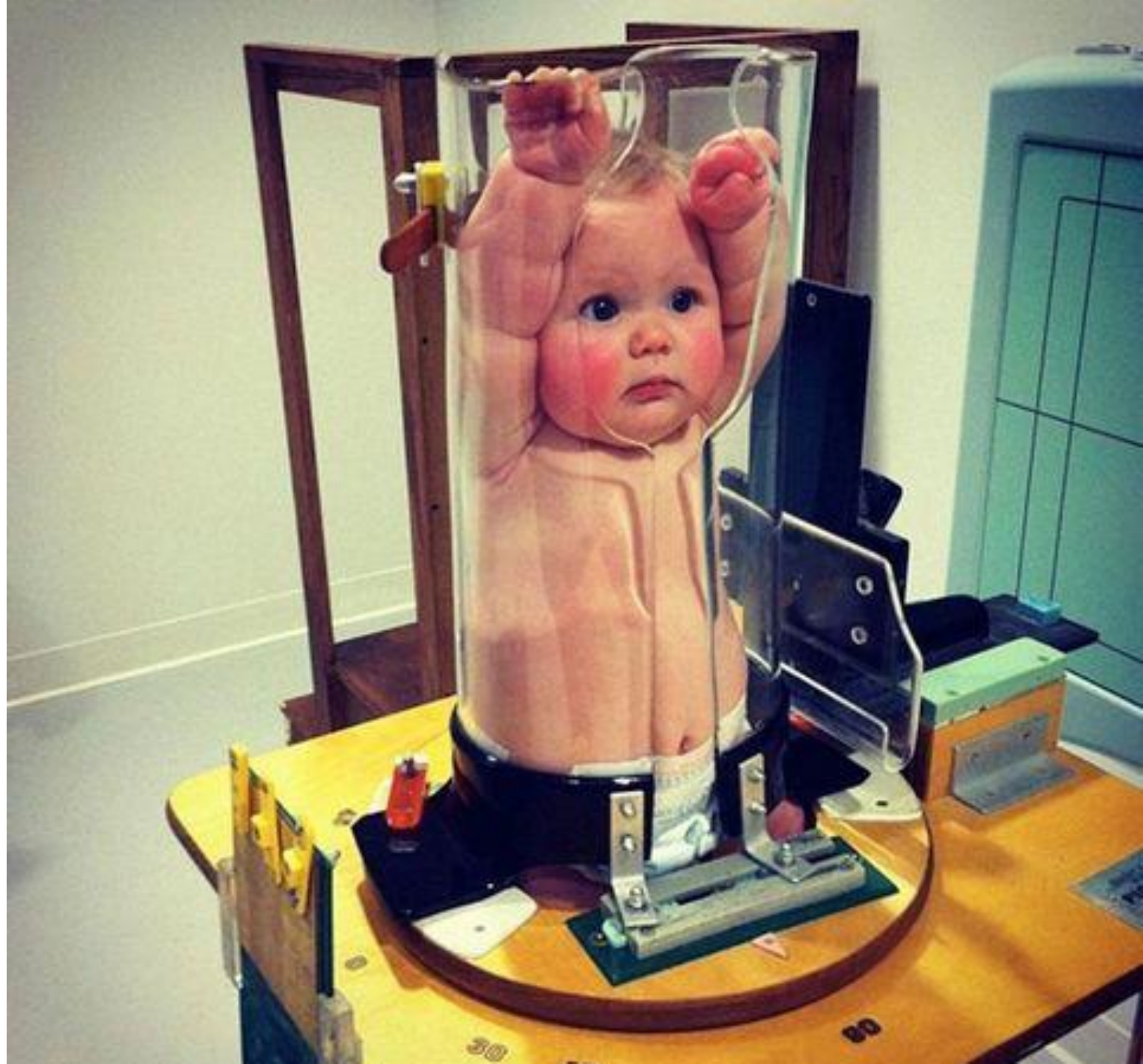du Preez, Liam, "Pediatric Chest X-rays" (2020). *Larner College of Medicine Fourth Year Advanced Integration Teaching/Scholarly Projects*. 11.
<https://scholarworks.uvm.edu/m4sp/11>

This Curriculum Material is brought to you for free and open access by the Larner College of Medicine at ScholarWorks @ UVM. It has been accepted for inclusion in Larner College of Medicine Fourth Year Advanced Integration Teaching/Scholarly Projects by an authorized administrator of ScholarWorks @ UVM. For more information, please contact donna.omalley@uvm.edu.

Pediatric Chest X-rays

Liam du Preez

UVM LCOM, Class of 2021



Objectives

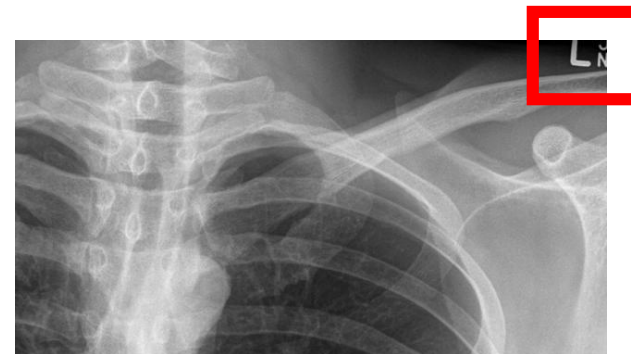- To provide general approaches to pediatric chest x-rays including:
 - Overview of crucial x-ray principles
 - ABCDEFG systematic approach for reading x-rays
 - Common shadow patterns
 - Thymus
 - Breast
 - Scapula
 - Terminology overview
 - Pneumothorax
 - Consolidation
 - Atelectasis
 - Pleural effusion
 - Unique imaging findings that indicate certain pathologies
 - Respiratory distress syndrome (RDS)
 - Community acquired pneumonia (CAP)
 - Bronchiolitis
 - Asthma
 - Rib fracture
 - Foreign body aspiration

XR Principles

- Black
 - XR able to pass through → radiolucent
 - Aka hyperlucent
 - Think “see-through”
- White
 - Dense so XR can’t pass through → radiopaque
 - Aka hypolucent
 - Think “obscuring”
- Examples
 - Fracture:
 - Disruption in bone is seen as a black crack because there is now an area of decreased density for XR to pass through
 - Vessels vs bronchioles:
 - Vessels: filled with liquid which is denser than air → lumen of pulmonary vasculature will appear grey
 - Bronchioles: filled with air → lumen of structures will appear black

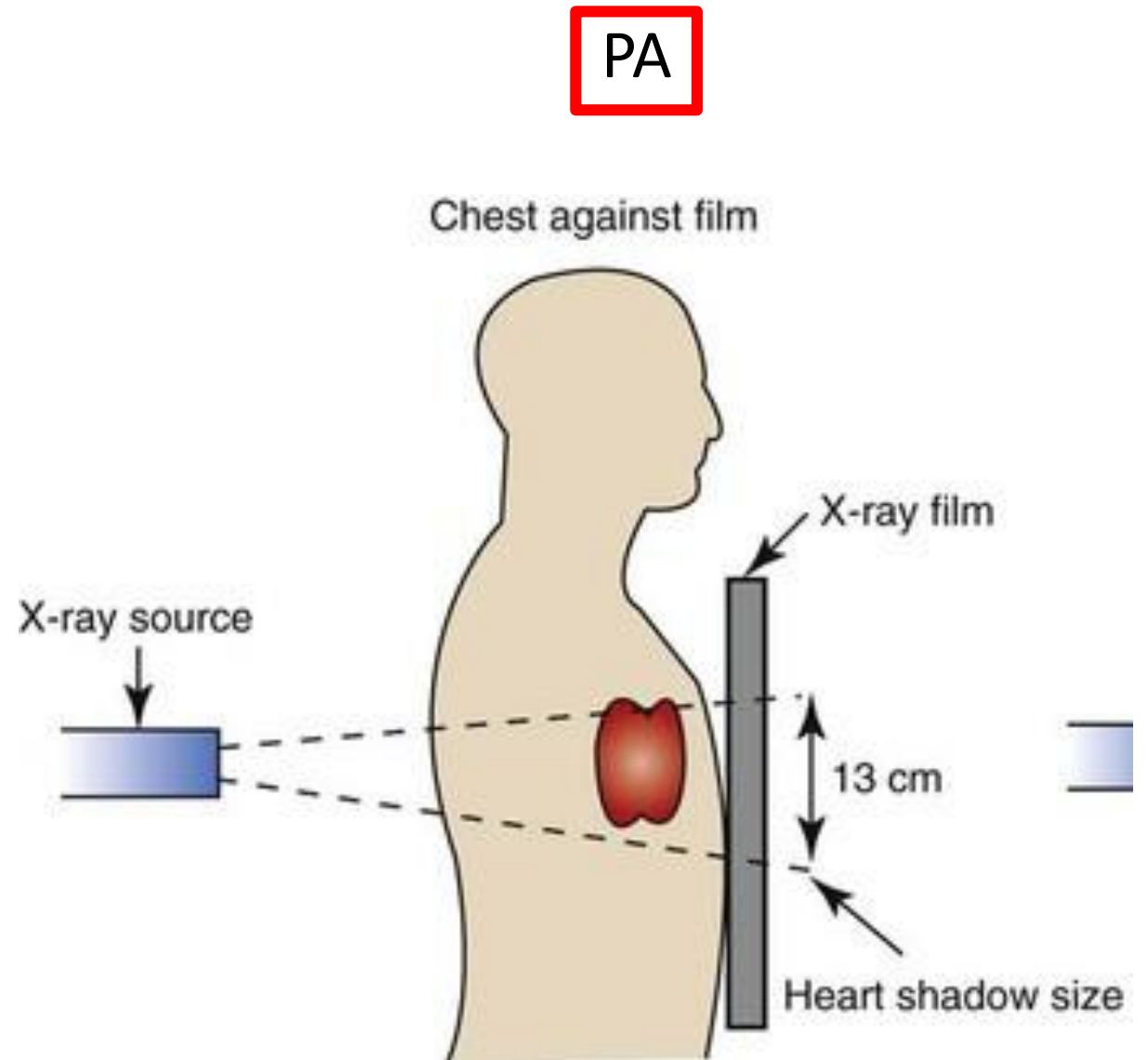
XR Principles

- Technical quality depends on:
 - Penetration (won't cover in this module)
 - Rotation
 - Can happen in all 3D planes (XYZ)
 - Picture will appear differently if the patient is sitting upright vs laying with head of bed at 45 degrees
 - Inspiration
 - 9-10 posterior ribs visible → adequate inspiration
 - Inadequate inspiration → condensed lung structures → can simulate pathological findings
- Confirm laterality with the marker



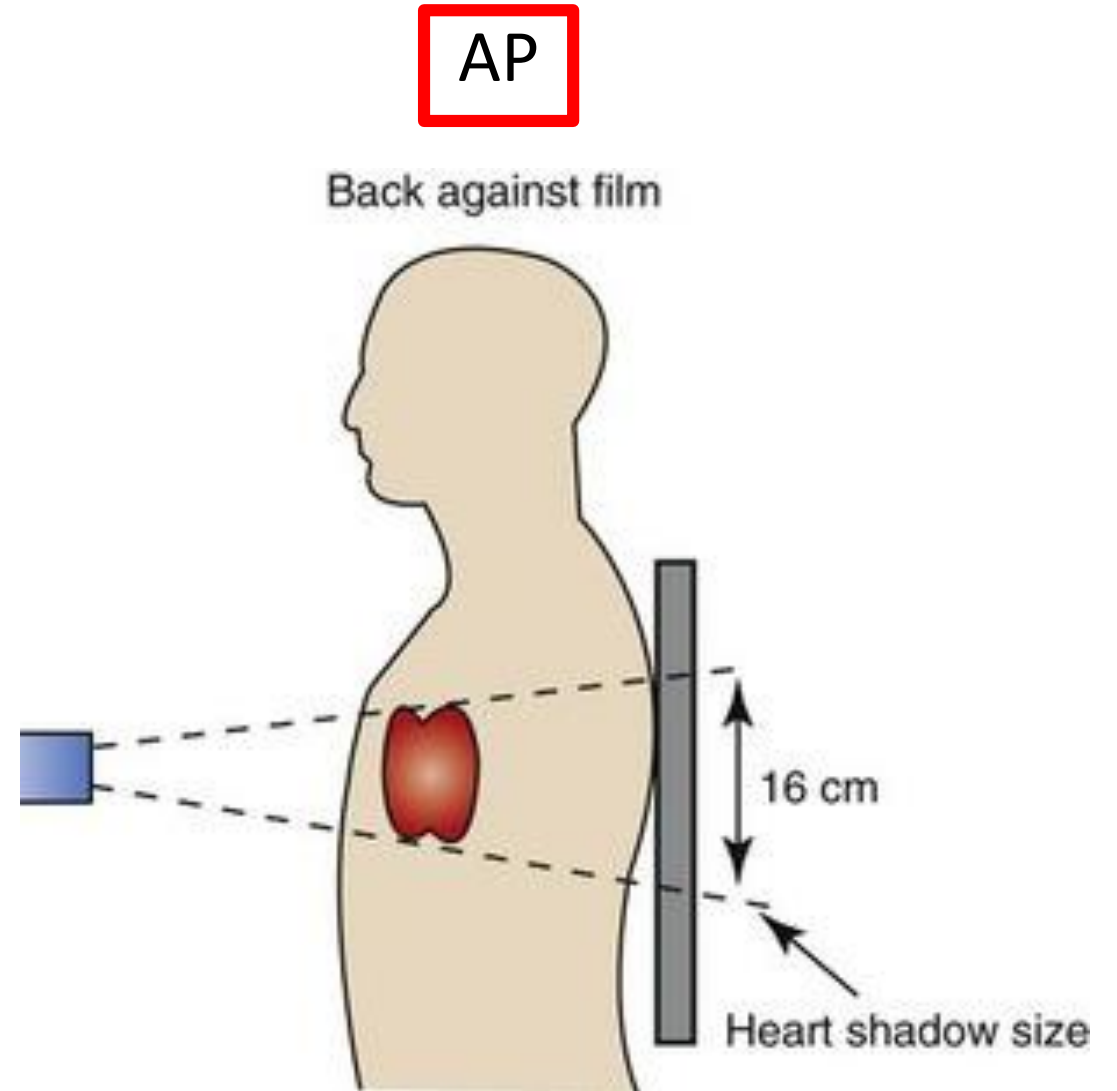
CXR Views

- PA
 - Posterior – anterior
 - Radiograph taken from back of patient standing upright
 - Usually leads to better “technical quality”
 - More accurate size of heart
- Lateral
 - View from the side

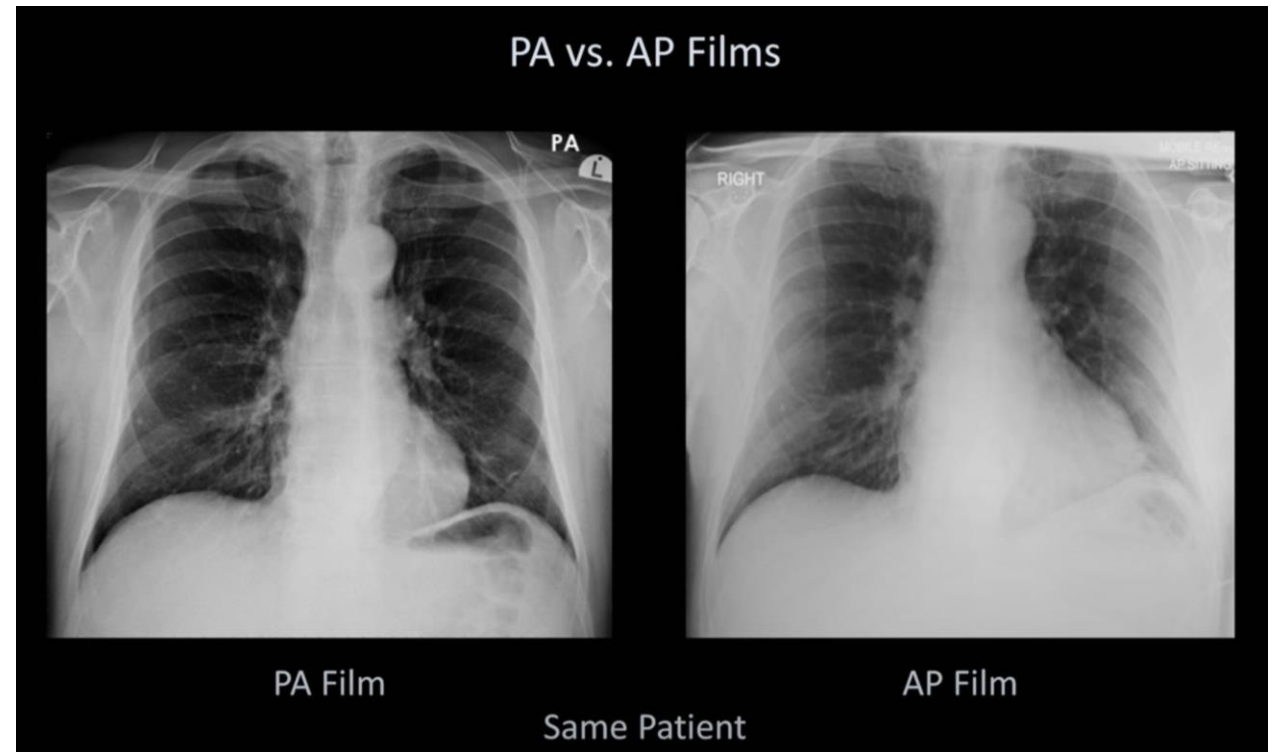
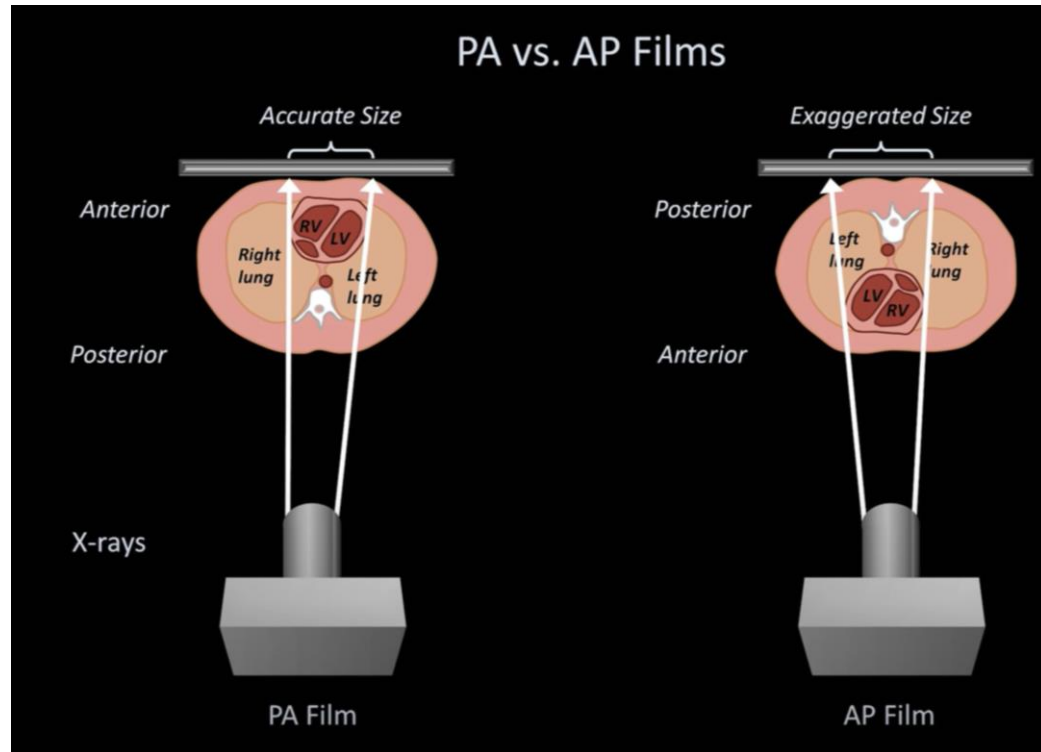


CXR Views

- AP
 - Anterior – posterior
 - Radiograph taken from front of patient
 - Reserved for patients too unstable to move
 - Usually patient not fully upright in hospital bed with lines & leads so can be decreased “technical” quality



CXR Views

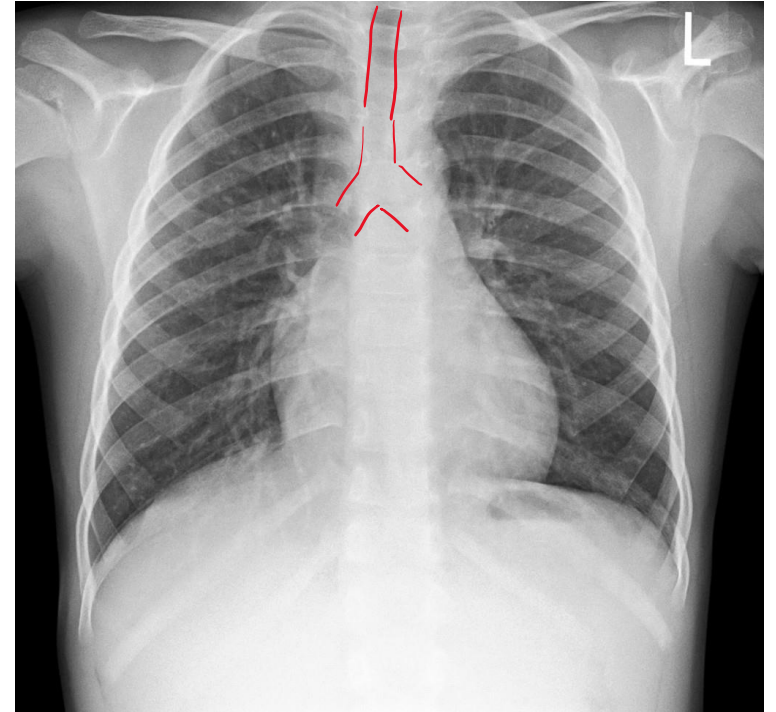
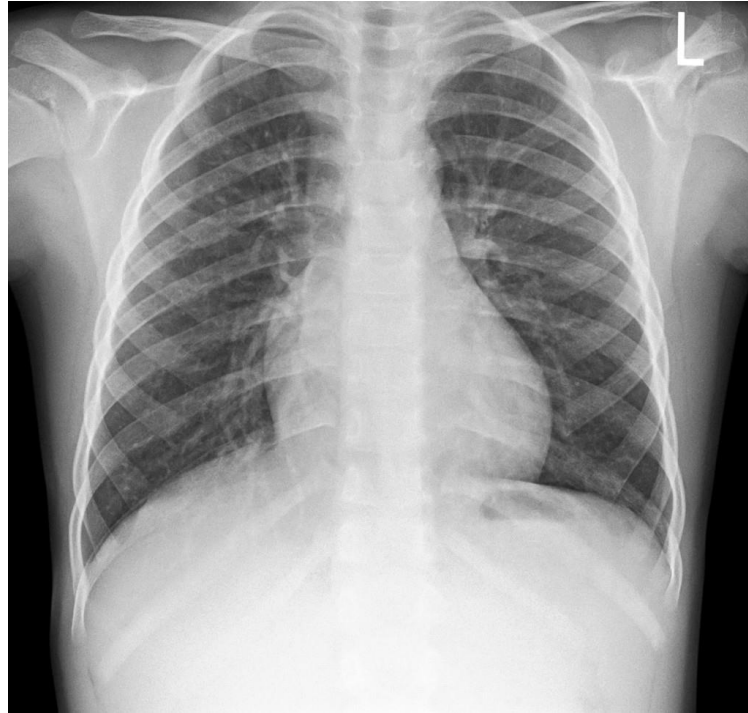


ABCDEFG

- Following a set system can be helpful as you're learning to read CXRs
- Airways
- Bones
- Cardiac
- Diaphragm
- Equipment
- Fields
- Great Vessels

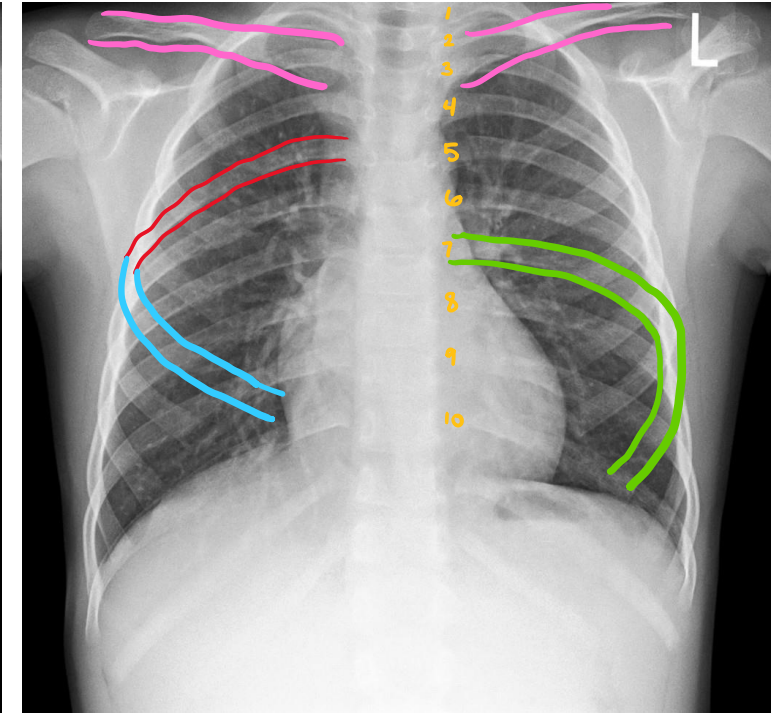
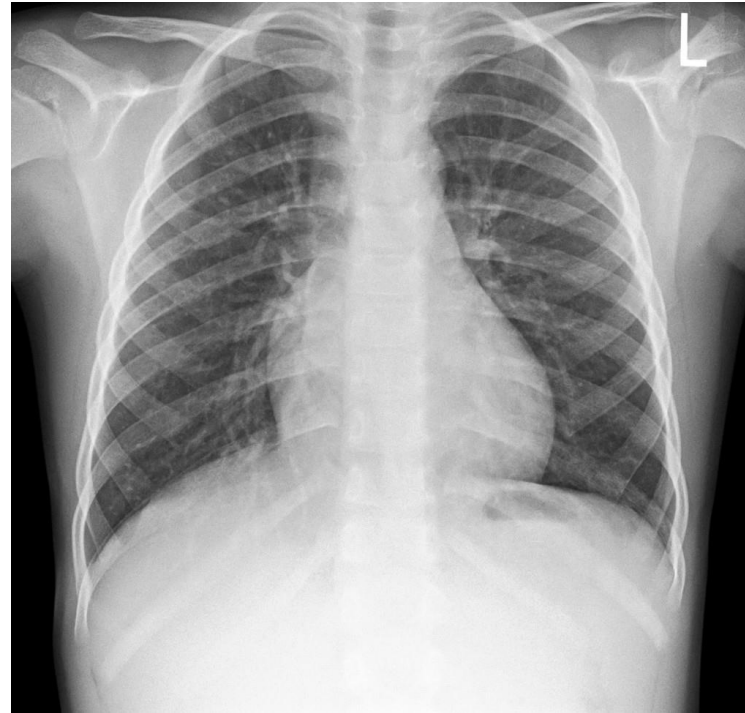
ABCDEFGFG

- **Airways**
- Is **trachea** midline or deviated?
- Is anything collapsed or plugged?
- Angle of the carina?
 - Normal: $\sim 90^\circ$



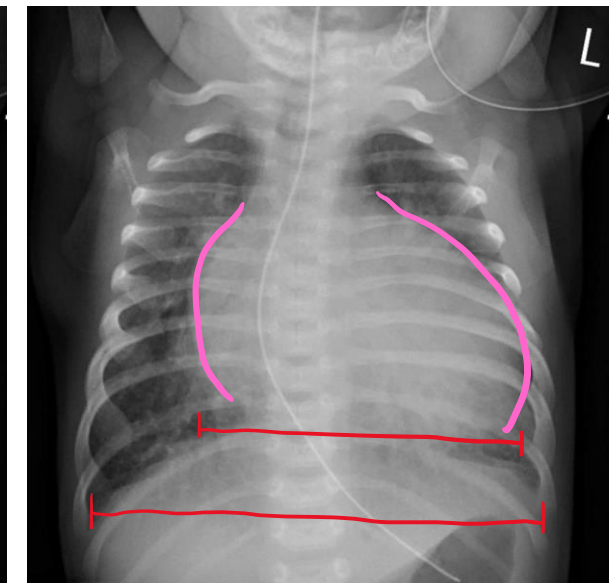
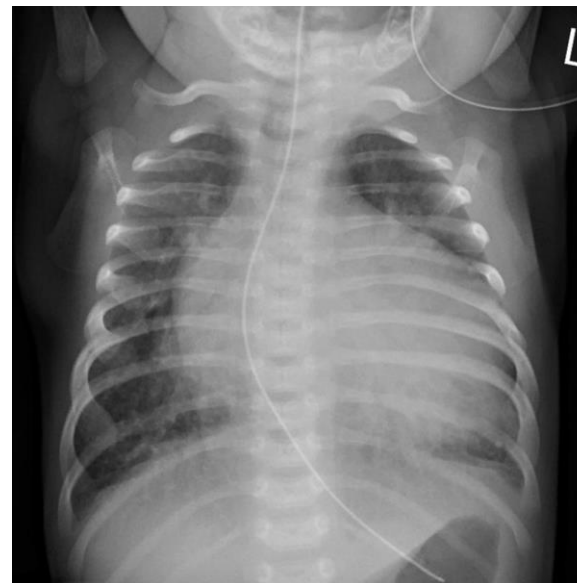
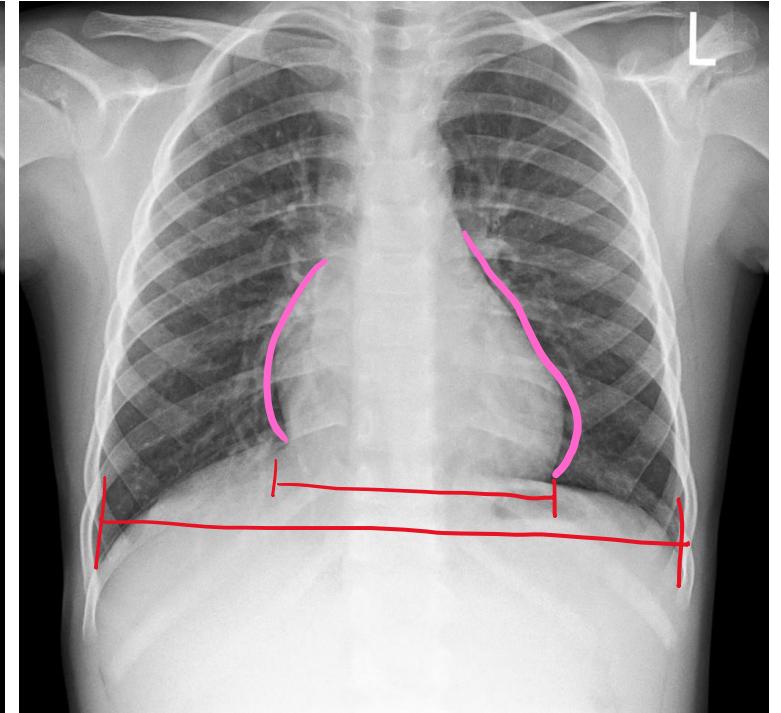
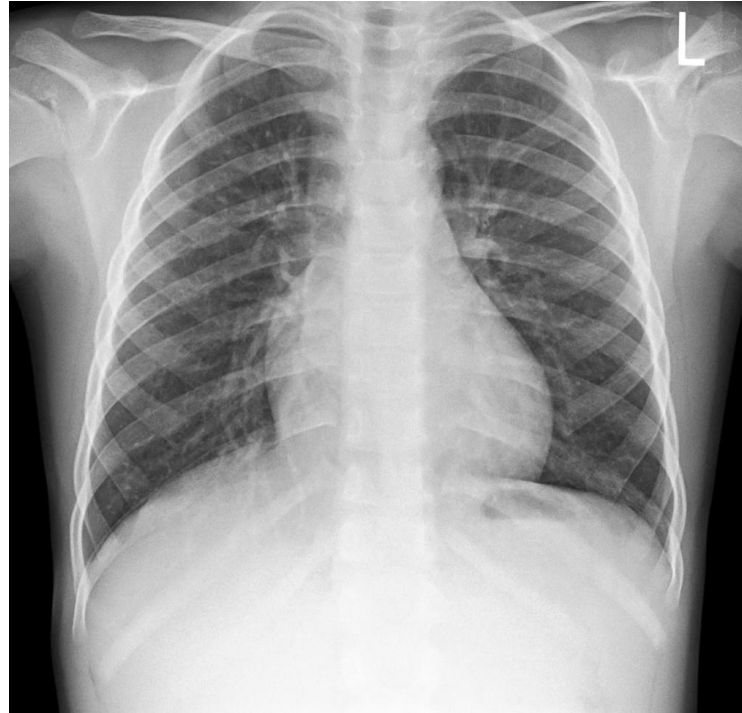ABCDEFGFG

- **Bones**
- Trace outlines of **clavicles** & **full ribs** for fractures
- Follow the curves of ribs
 - **Posterior** ribs: more horizontal
 - **Anterior** ribs: more curved
- How many visible ribs?



ABCDEFGFG

- **Cardiac**
- Size and positioning of the heart?
 - Cardiomegaly: width of heart $>1/2$ of rib cage width
 - Dextrocardia
- Abnormal silhouette?

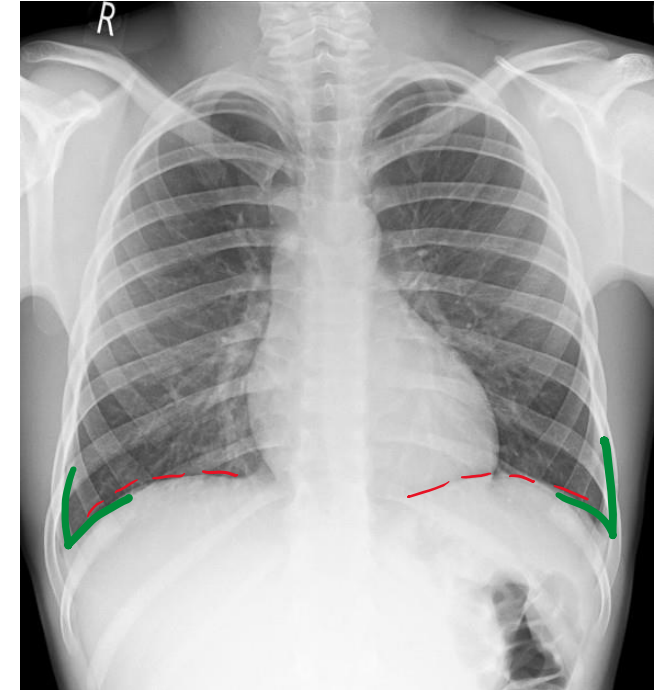
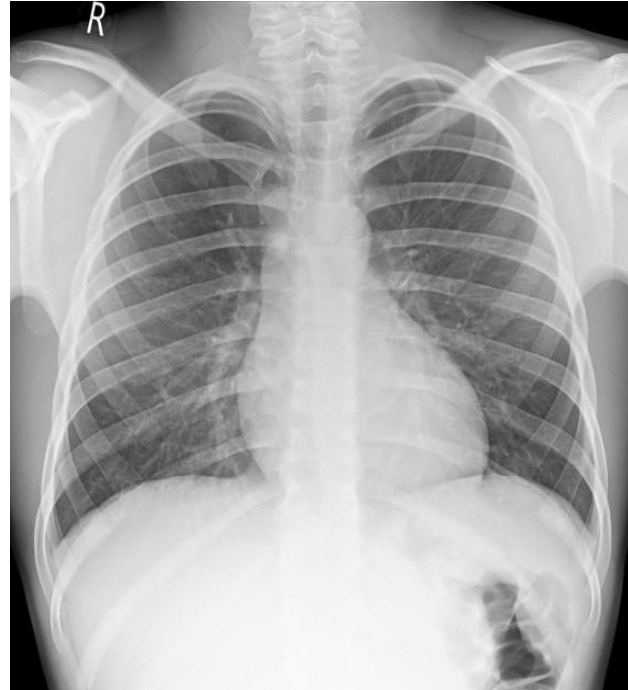

<https://radiopaedia.org/cases/normal-chest-6-year-old?lang=us>

<https://radiopaedia.org/cases/cardiomegaly-5?lang=us>

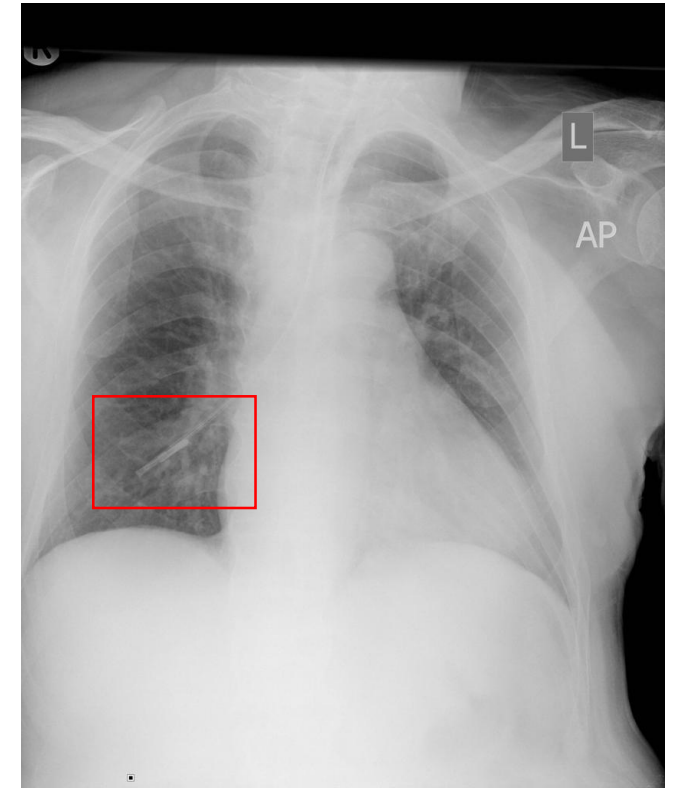
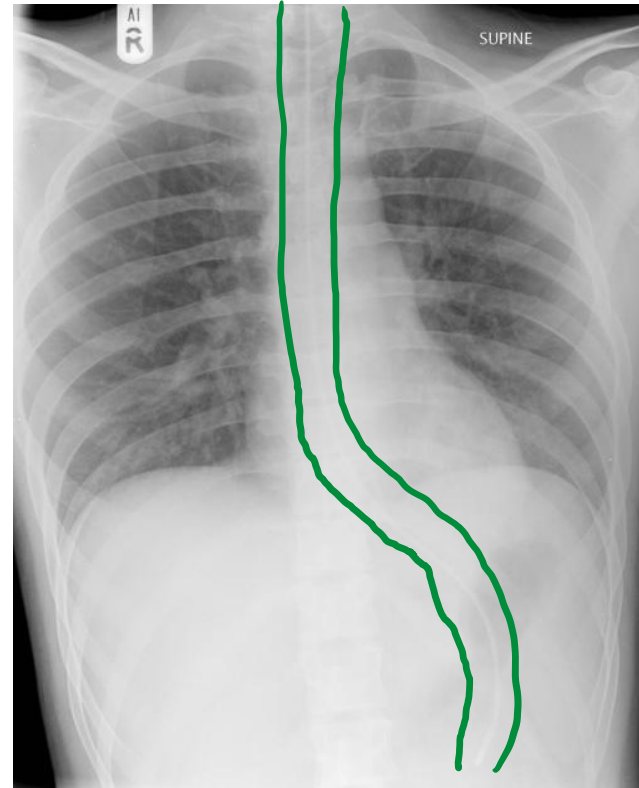
ABCDEFGFG

- **Diaphragm**
- Does it appear symmetric?
 - **Normal** for right hemidiaphragm to be slightly superior compared to left
- Is the **costophrenic angle** sharp?
- Is there free air inferior to diaphragm?



ABCDEFGFG

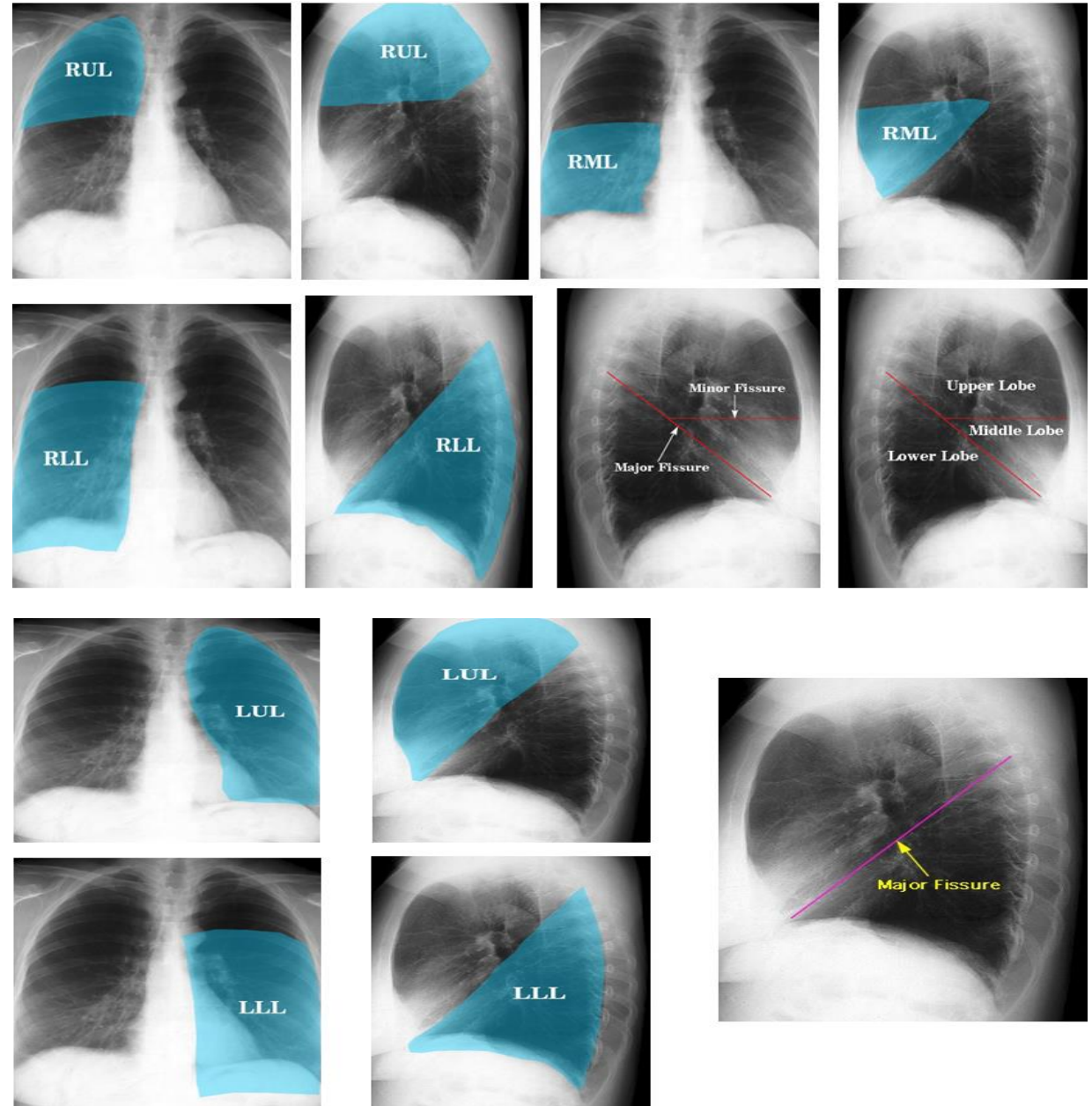
- **Equipment**
- What equipment is actually visible?
 - Leads, tubes, wires
- Is everything in the correct place?
 - **Nasogastric tube**
 - Tip should end in stomach (not esophagus or bronchi)
 - **Endotracheal tube**
 - Should end >2cm superior to carina (not right or left main bronchus)



<https://radiopaedia.org/articles/nasogastric-tube-position-on-chest-x-ray-summary?lang=us>

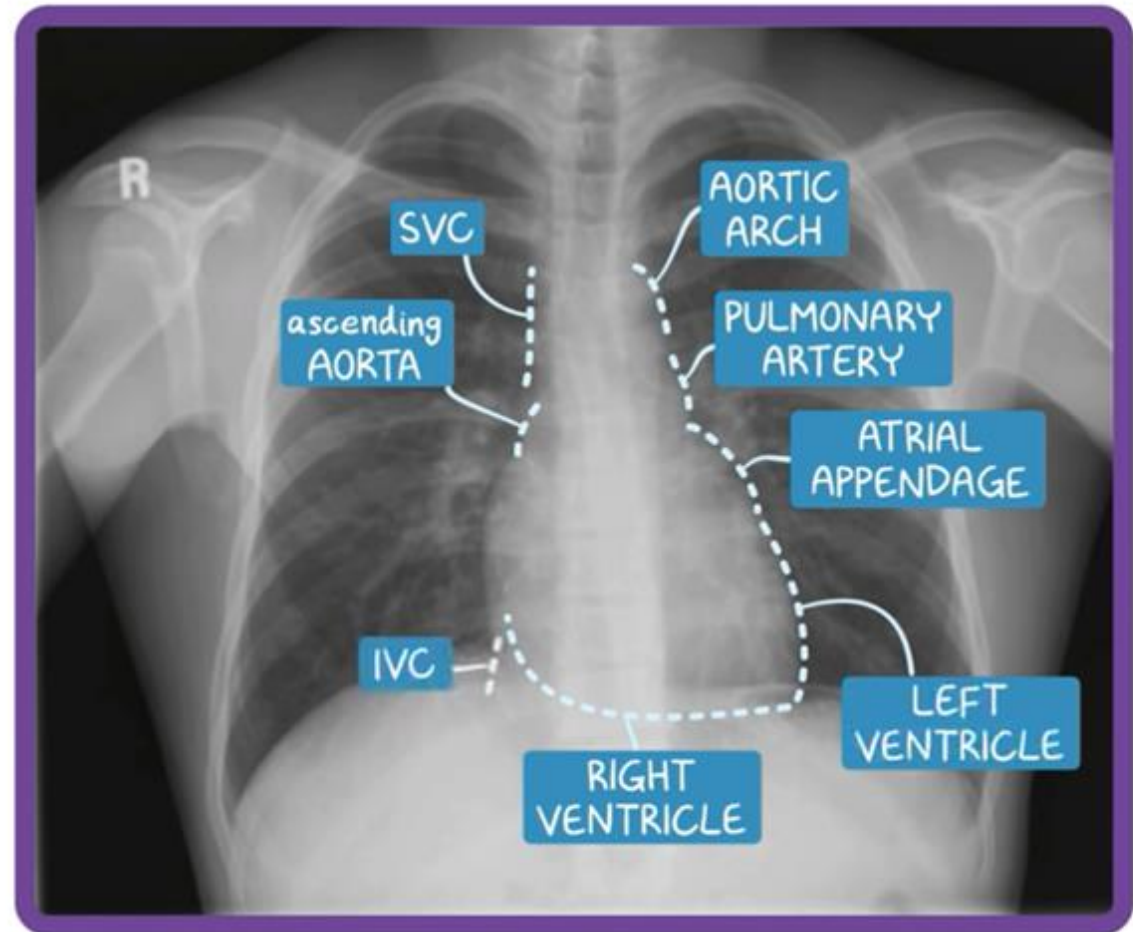
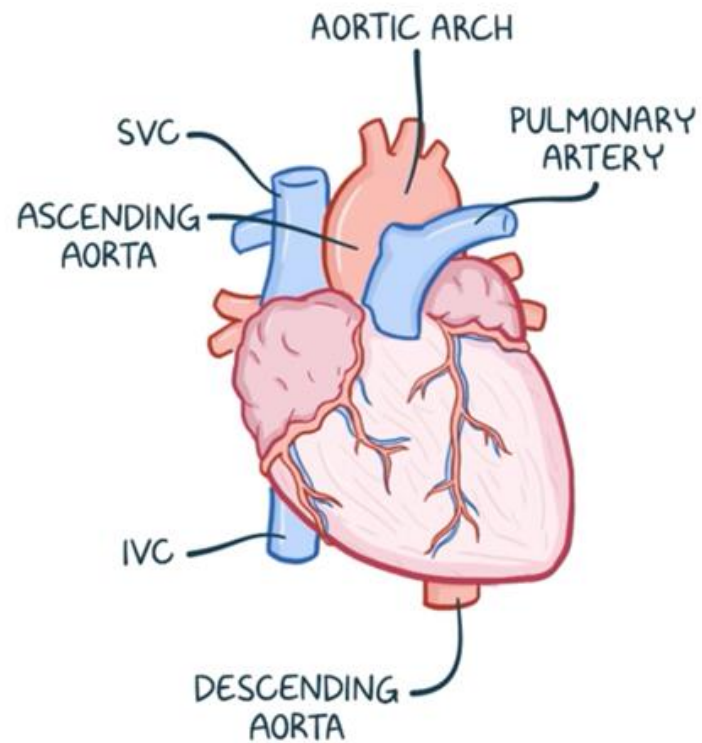
ABCDEFGFG

- **Fields**
- Which lung and lobe? Multiple?
- Unilateral? Bilateral?
- Dependent?



ABCDEFGG

- **Great vessels**

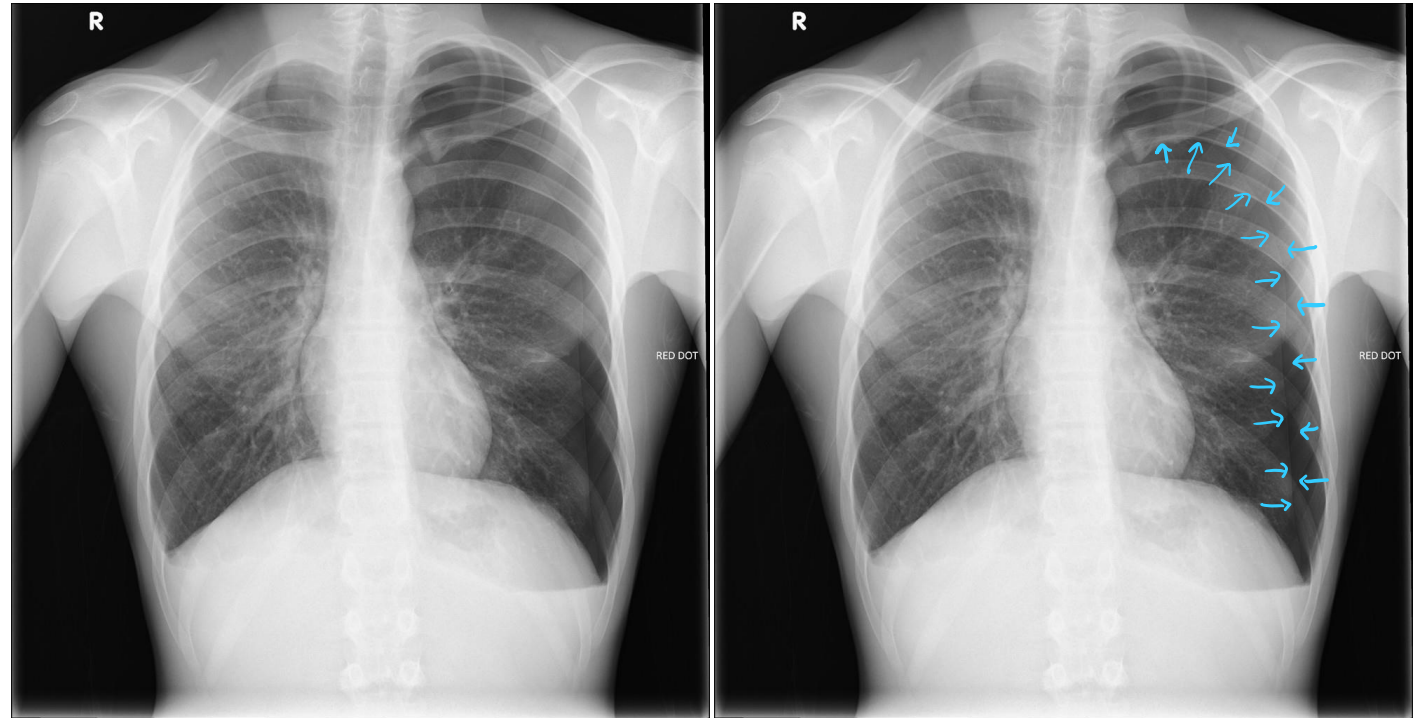


Terminology Review

- **Pneumothorax:** air between lungs and chest wall
 - Air where it shouldn't be (darkness where it shouldn't be)
- **Consolidation:** filled with tissue/fluid debris
 - Junk where it shouldn't be (radiopacity where it shouldn't be)
- **Atelectasis:** partial or complete lung collapse
- **Effusion:** accumulation of fluid in confined space
 - Pleural, pericardial

Pneumothorax

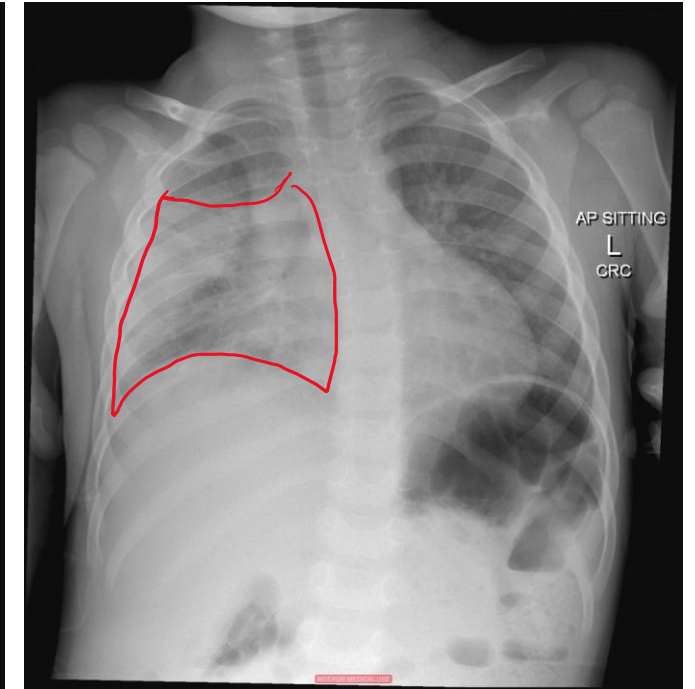
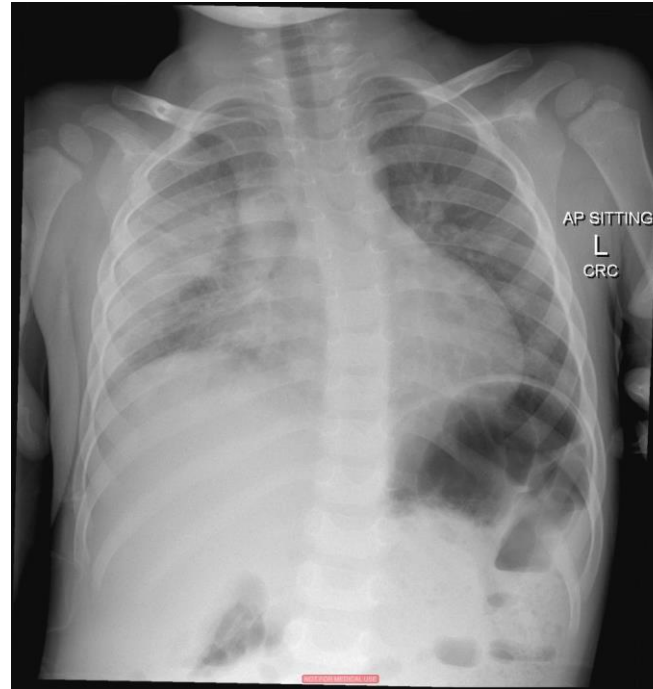- Air between the pleura and chest wall
 - Usually a **fine edge** demarcates it
 - Uniformly distributed
 - Watch for pathologic site of damage (burst apical blebs)
 - Almost always unilateral
- In pediatrics, can be associated with connective tissue conditions, but can also appear spontaneously in tall, thinner patients



<https://radiopaedia.org/cases/pneumothorax-paediatric-1?lang=us>

Consolidation

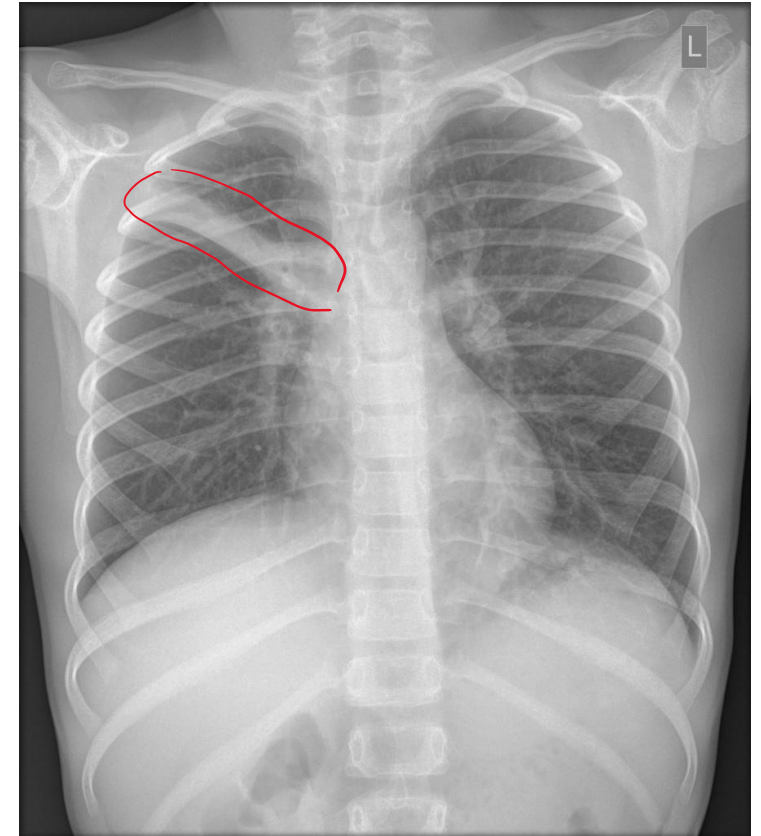
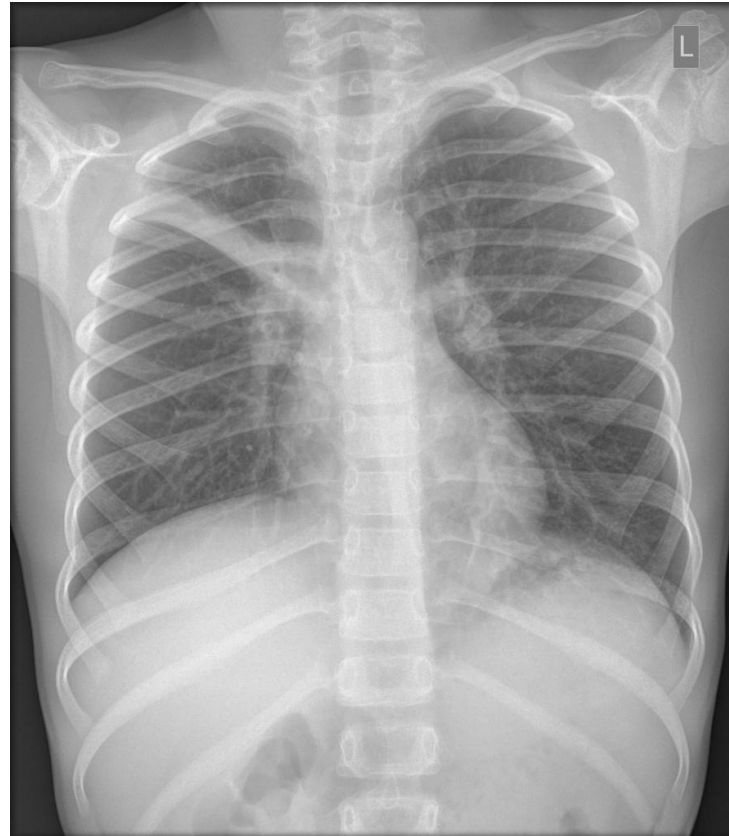- Think about WHAT the consolidation is with respect to your patient's pathophysiology
 - Is it blood, chyle, pus/infection?
 - Is it bilateral, unilateral?
 - Can be very heterogenous, difficult to assess anatomy/distribution
- In pediatrics, the overall assessment of the patient is crucial



<https://radiopaedia.org/cases/multilobar-pneumonia-paediatric?lang=us>

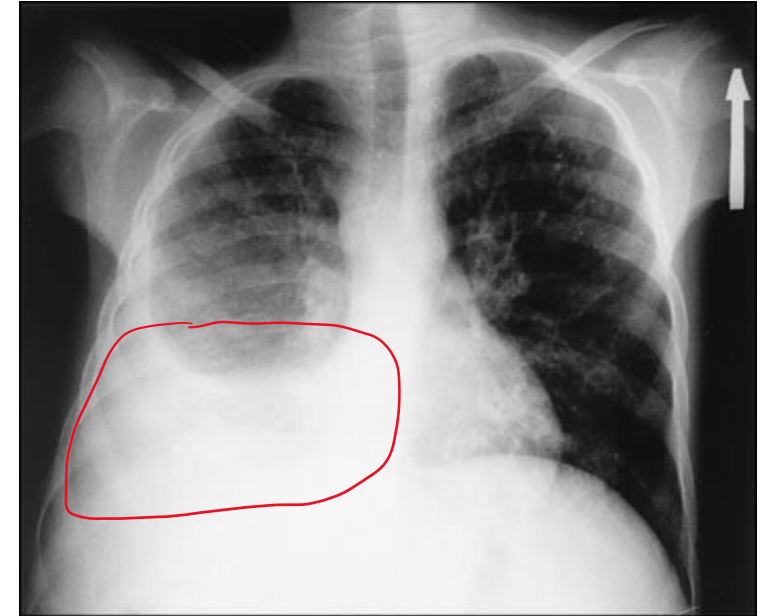
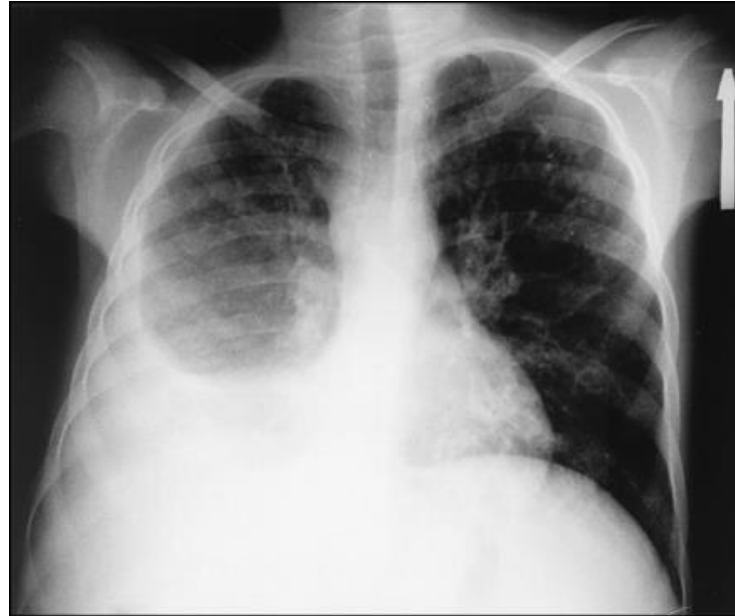
Atelectasis

- Loss of lung volume secondary to collapse
- Volume loss = most important radiographic sign of collapse
 - Less air inflating lung → less black
 - **Linear increased density** on chest x-ray
- Most common cause:
 - Bronchial obstruction → distal gas resorption → reduced volume of gas → alveolar walls collapse → size of area reduced
 - Can sometimes see the obstructing lesion on XR

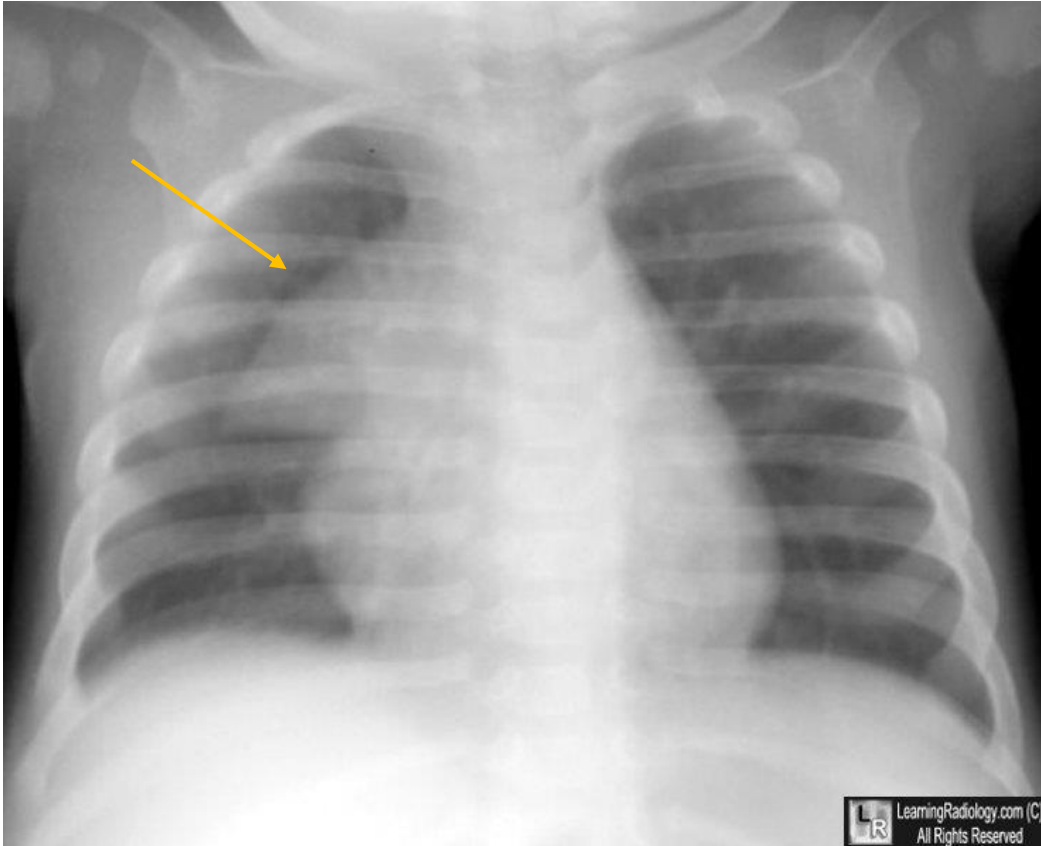


Pleural Effusion

- More liquid now adding another layer x-rays must pass through → less black
- Transudative
 - Caused by fluid shifts
 - ↑ hydrostatic pressure or ↓ oncotic pressure
- Exudative
 - Caused by disruption of pleural membrane → ↓ ability to absorb pleural fluid
 - Can be secondary to infection, inflammation, or neoplasm

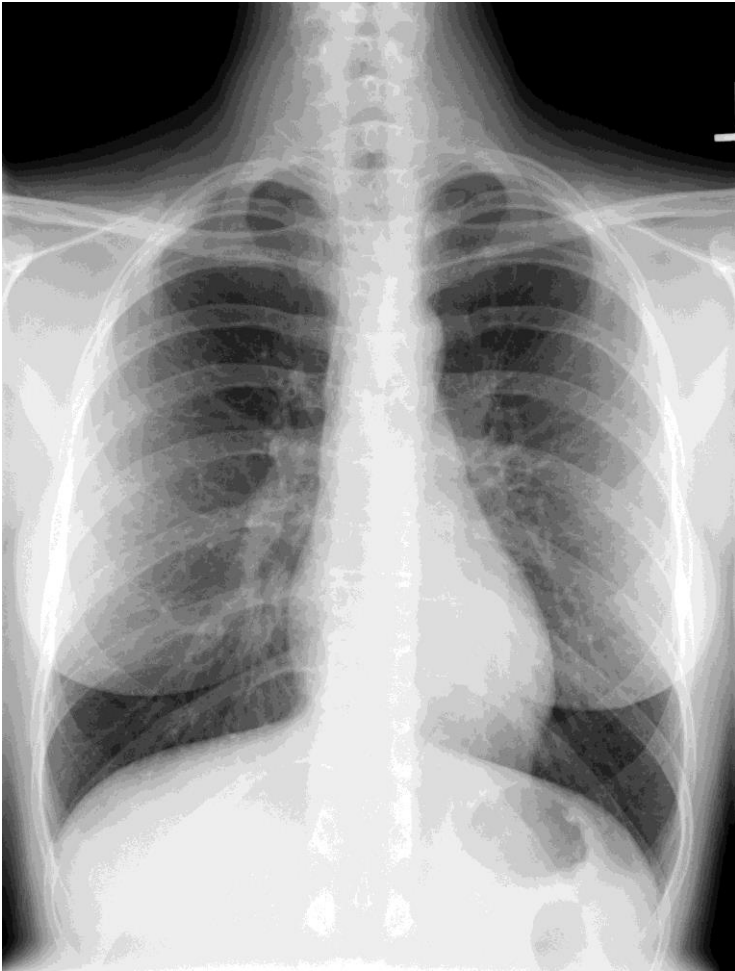


Shadows - Thymus



- Classic, normal sign of developing thymus
- Can be very large, “sail sign”; benign
- If no sign of thymus in the context of severe immunodeficiency, consider DiGeorge syndrome

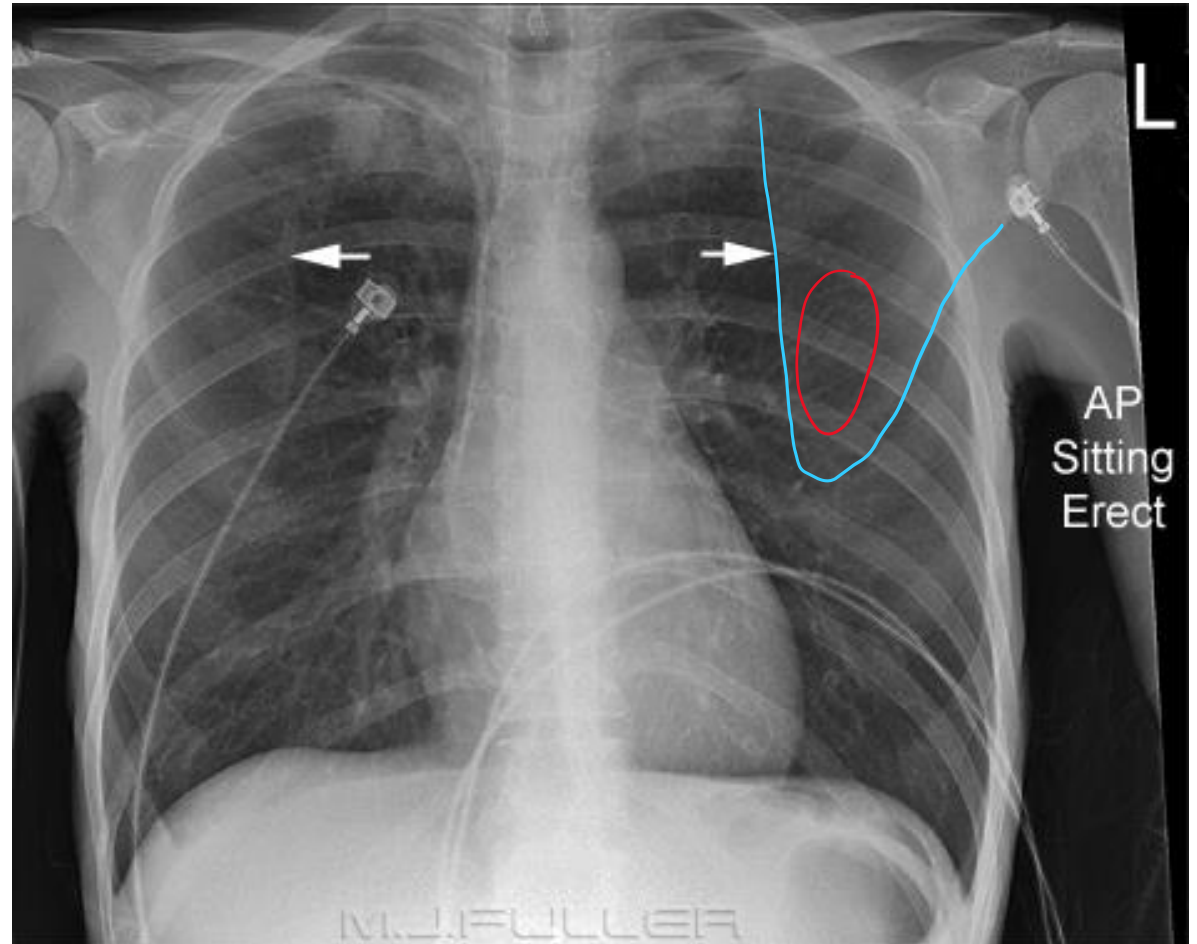
Shadows - Breast



- Always keep in mind
- Thelarche can be radiologically evident from as early as 8-9 y.o.

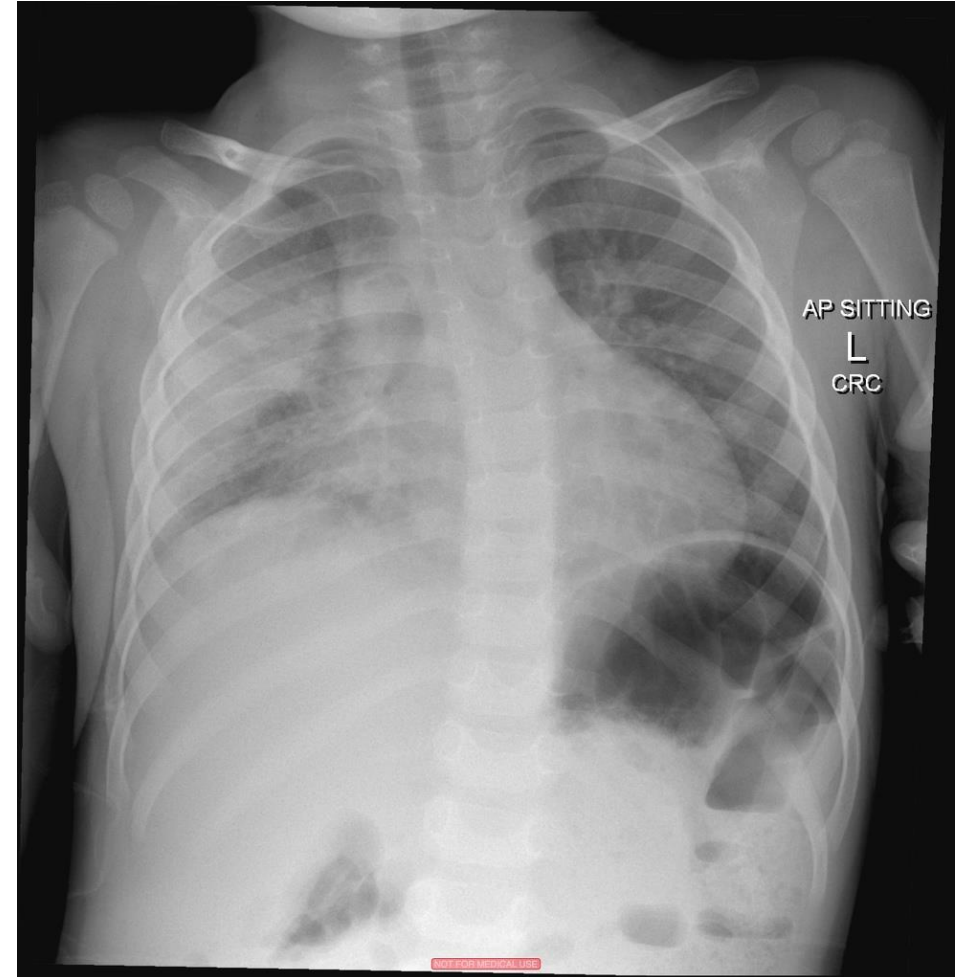
Shadows - Scapula

- Don't jump to pneumothorax simply because you see a line
- Look BEYOND it, do you still see lung tissue?
- If scapula, hypolucent lateral to demarcating line
 - Can trace outline of scapula
- If pneumothorax, hyperlucent beyond the line



CAP

- Community Acquired Pneumonia
- Cause
 - Inflammation of the lung parenchyma due to viral or bacterial infection
- Clinical Picture
 - Child with fever, productive (not always) cough
 - Timeline: viral-ish cough (symptoms of a few days) then turning for the worst
 - Breathing difficulties
 - Pain can be abdominal, non-specific

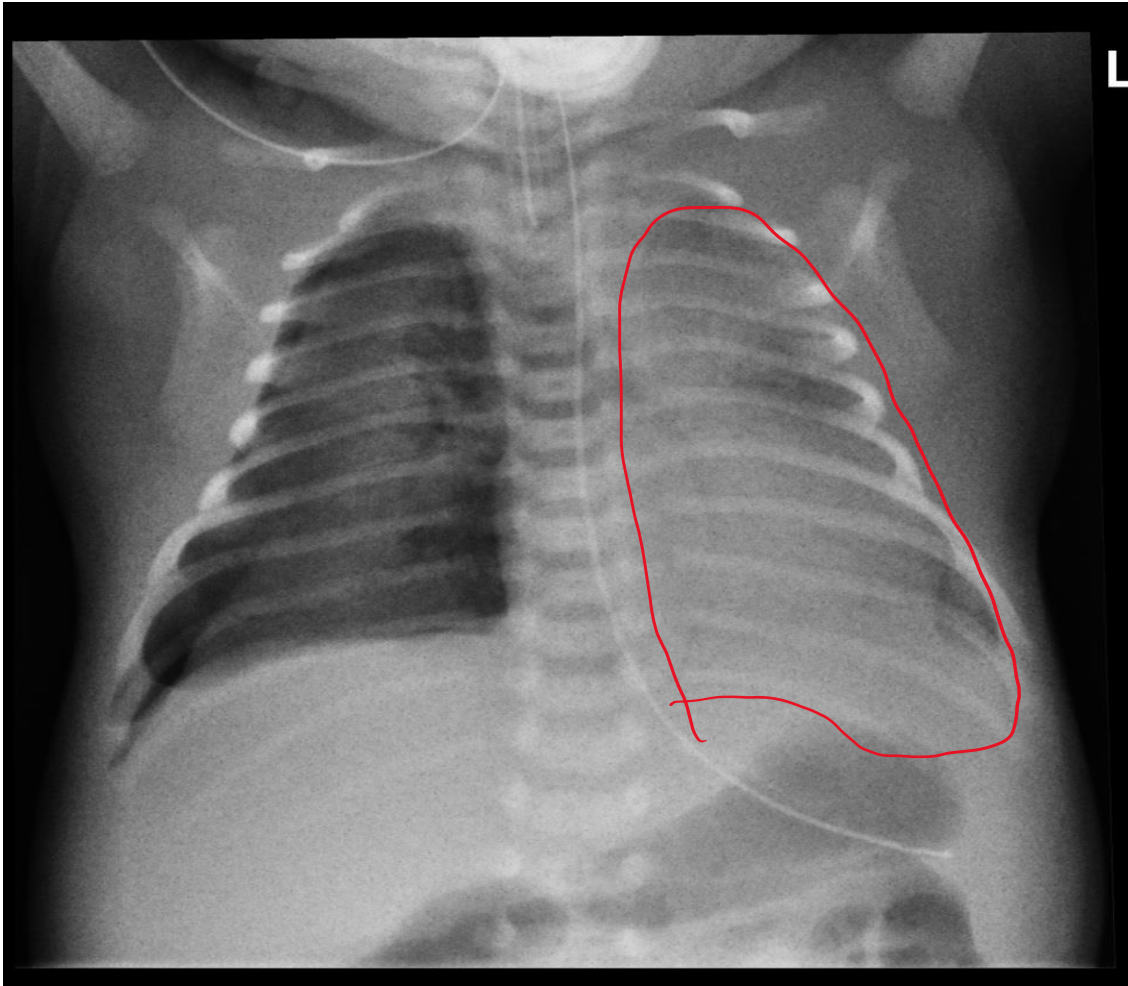


<https://radiopaedia.org/cases/multilobar-pneumonia-paediatric?lang=us>

RDS

- Cause
 - ↓ surfactant → ↑ surface tension → alveolar collapse
- Clinical picture
 - First few hours of life, preterm neonates
 - Tachypnea, expiratory grunting, nasal flaring, cyanosis, substernal and/or intercostal retractions
- Plain radiograph
 - Mandatory for dx: low lung volumes (atelectasis - lung collapse)
 - **Diffuse granular opacities** (ground glass), bilateral and symmetrical
 - hyperinflation excludes the diagnosis

RDS



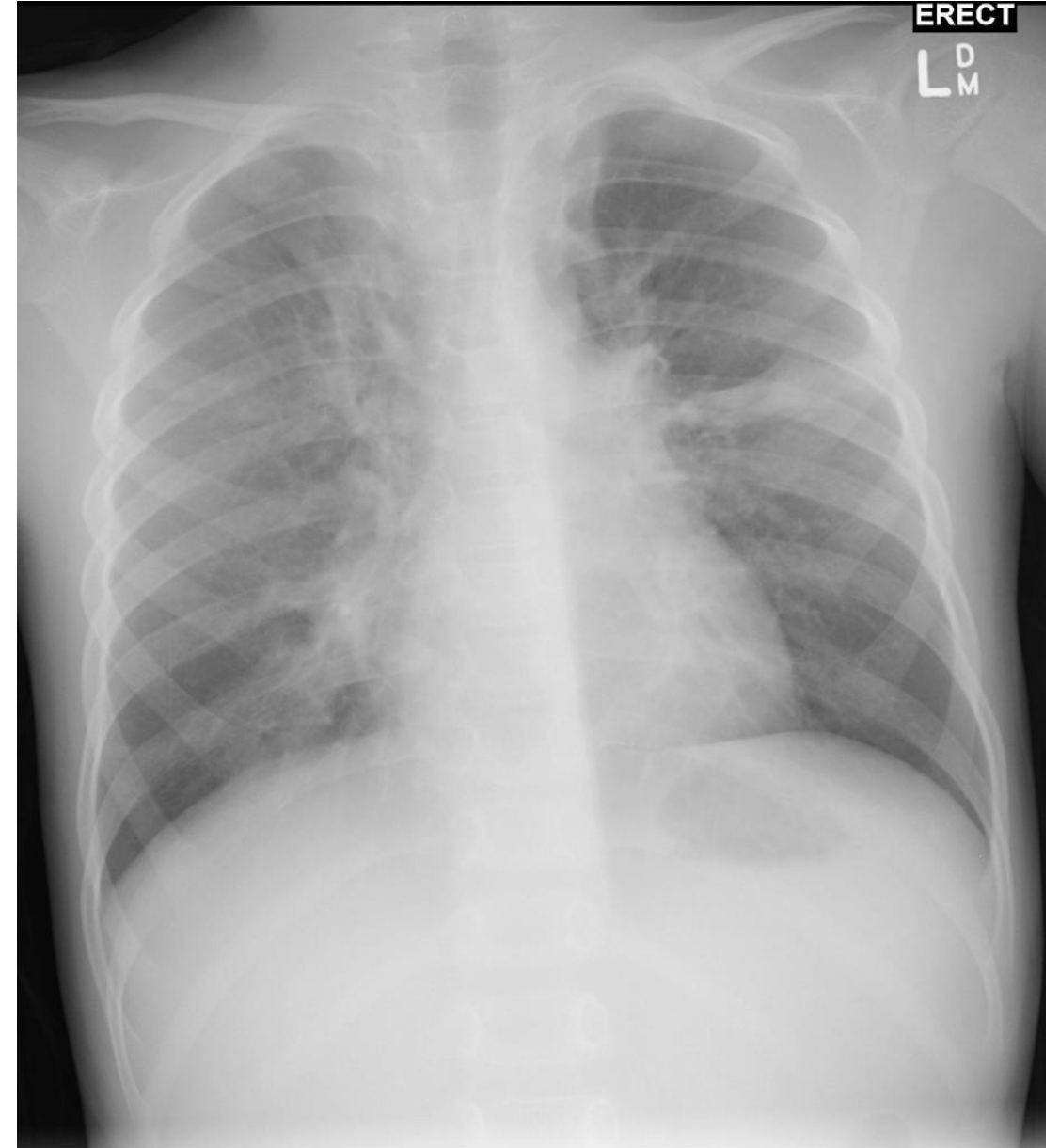
- Think of the “ground glass” as absence of air
 - Less air → less black
- No alveoli so no ability to hold air
 - Tissue in the area will appear lighter than properly inflating lung
- Bonus: Can you see what has happened in the contralateral lung?
- (Hint: It is a condition already mentioned earlier in this module)

Bronchiolitis

- Cause
 - Inflammation of smaller airways (<2mm)
 - Commonly RSV
- Clinical picture
- Plain radiograph
 - Usually not detected with CXR
 - **Nonspecific** findings
 - Ill-defined small or hazy clustered nodules
 - Areas of air trapping characterized by hyperlucency

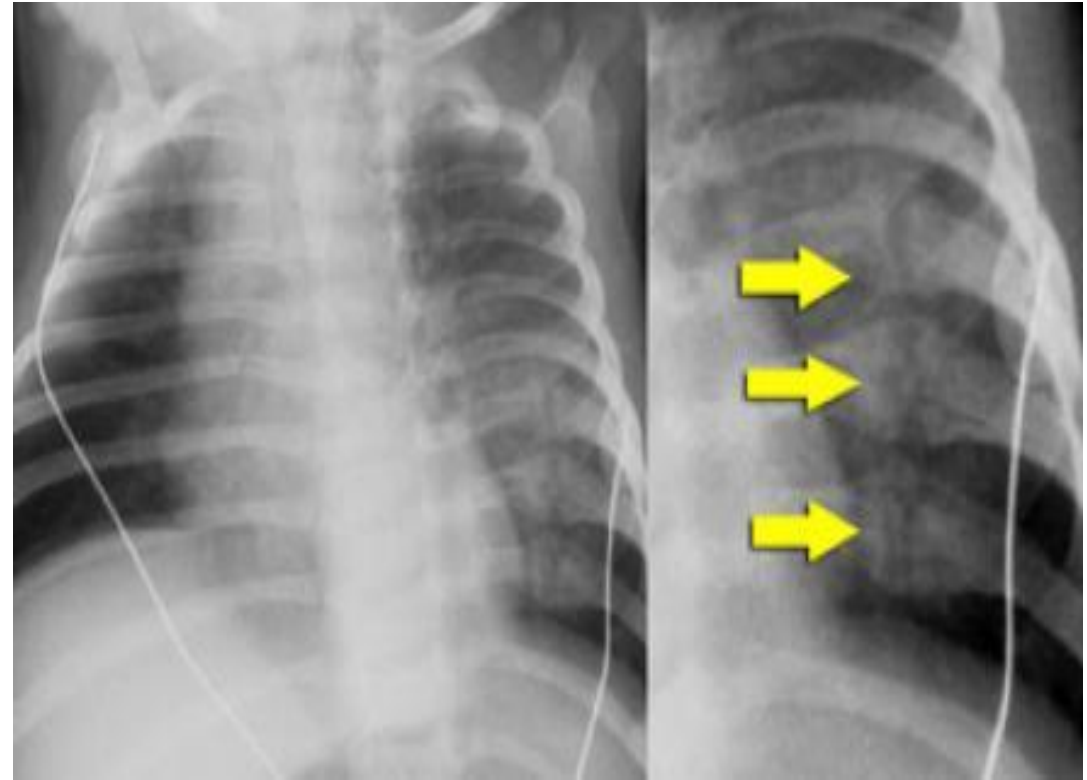
Asthma

- **CXR not recommended**, but still routinely obtained
- Hyperinflation
 - >9-10 ribs visible
 - Think more lung SIZE in relationship to rib count, not just 'real estate'
 - How many ribs can you see?
- Diaphragm flattening



Rib fracture

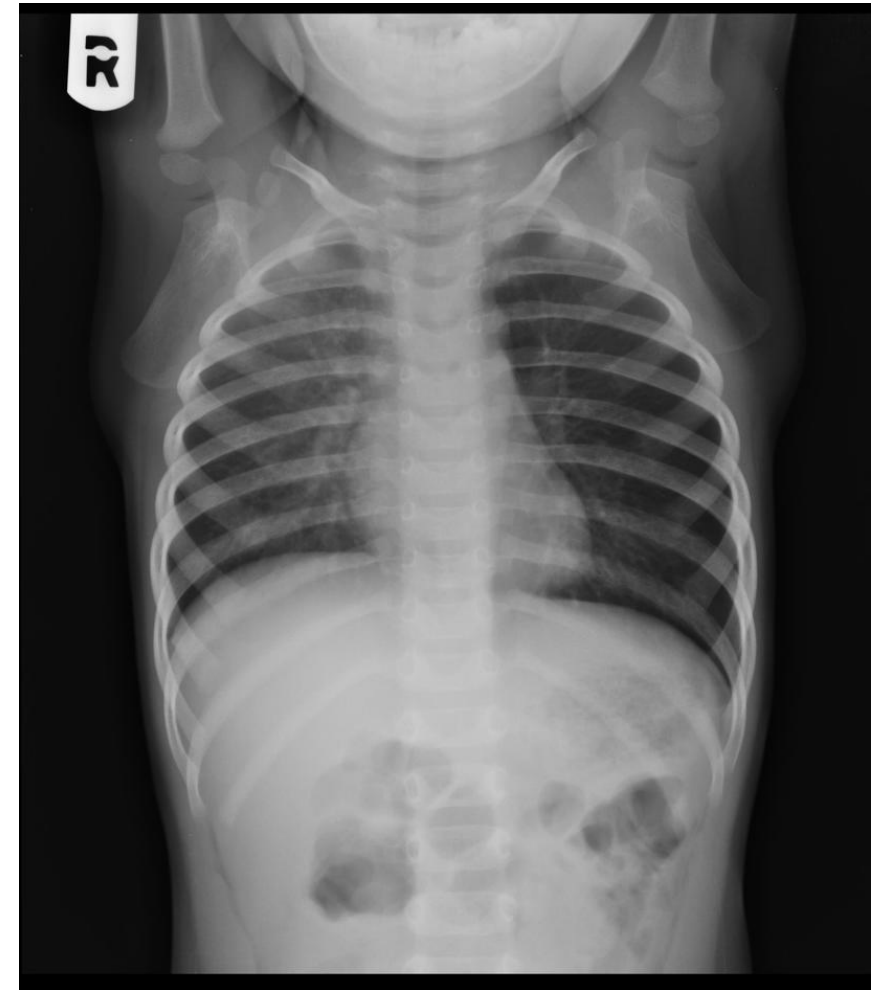
- Start at posterior rib and trace it anteriorly
- Go rib by rib
- Look for signs of prior fracture (bony callous)
- Variable fracture age, often found incidentally



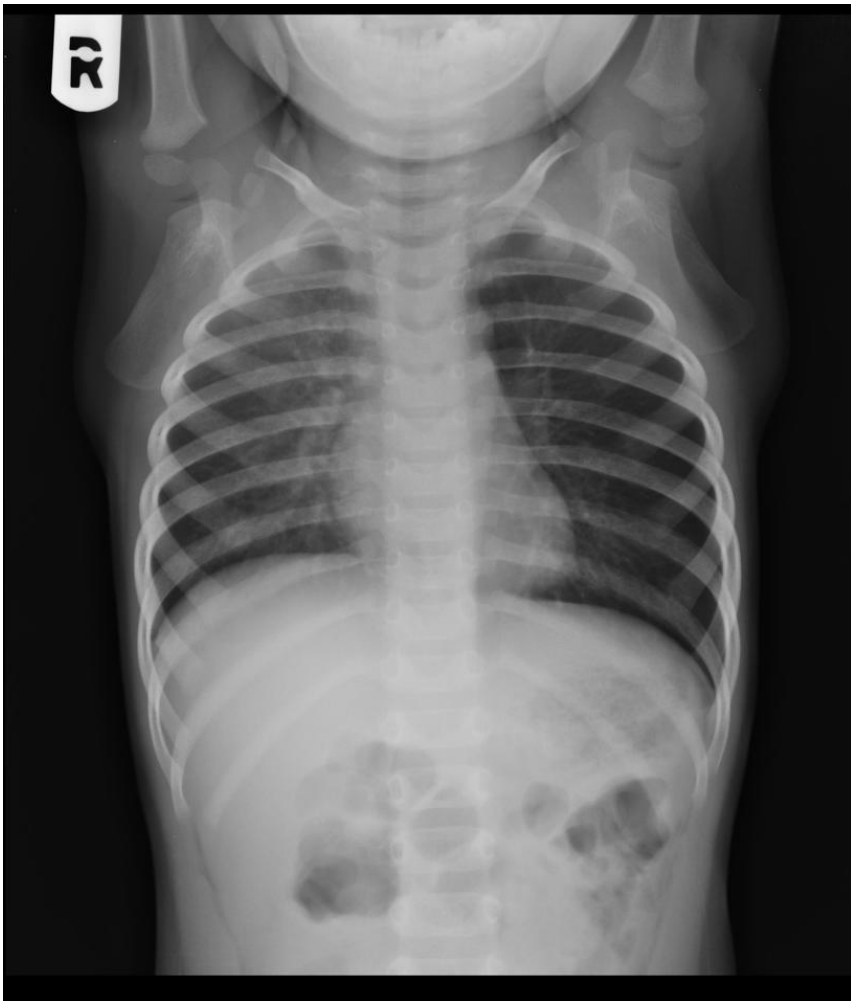
• <https://radiologyassistant.nl/pediatrics/child-abuse-diagnostic-imaging>

Foreign Body Aspiration

- Not always visualized
 - Metal usually visualized (nails, coins, etc.)
 - Look for signs of air trapping
-
- Go through the ABCDEFG for this x-ray
 - Think about what might have happened



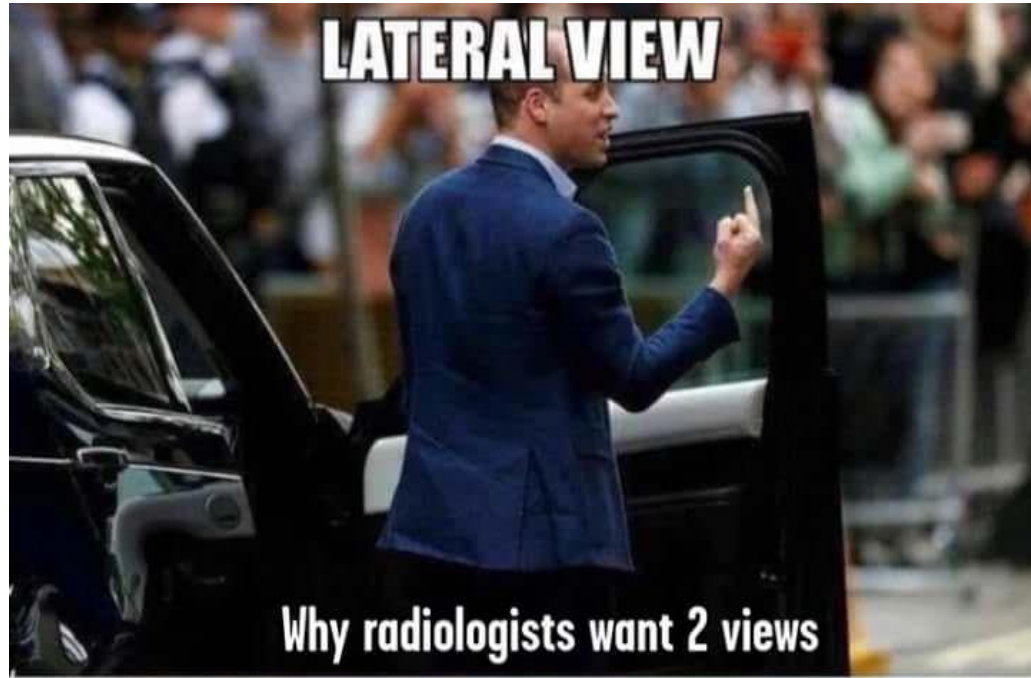
Foreign Body Aspiration



- A – trachea midline, normal carina angle
- B – no visible fractures
- C – no cardiomegaly, prominent heart borders
- D – sharp costophrenic angles, hemidiaphragms asymmetric
- E – no visible equipment
- F – Left lung appears **hyperlucent** and **more inflated** compared to right lung
- G – vessels appear normal
- No apparent radiopaque foreign body

Almond removed from left bronchus

<https://radiopaedia.org/cases/airway-foreign-body-in-child-1?lang=us>



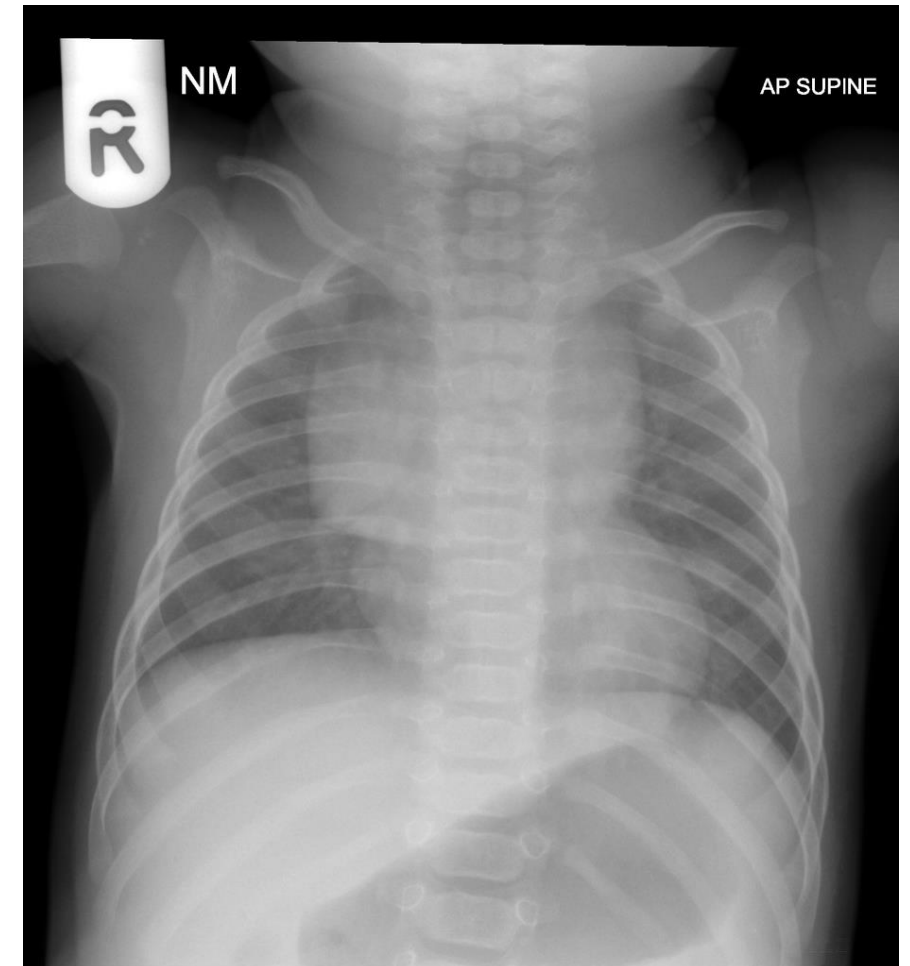
<https://imgur.com/a/zmA8CHB>

Post Test

1. A 4 month old child presents with 3 days of cough, rhinorrhea, and fever. Family history is positive for asthma with his mother. The patient has been seen to cough during breast feeding, but he completed his feeds after nasal suctioning today. He has had 2 similar episodes. His chest x-ray is shown.

What is the diagnosis at this time?

- a. Di George Syndrome
- b. Lobar pneumonia
- c. Thymoma
- d. Viral upper respiratory infection

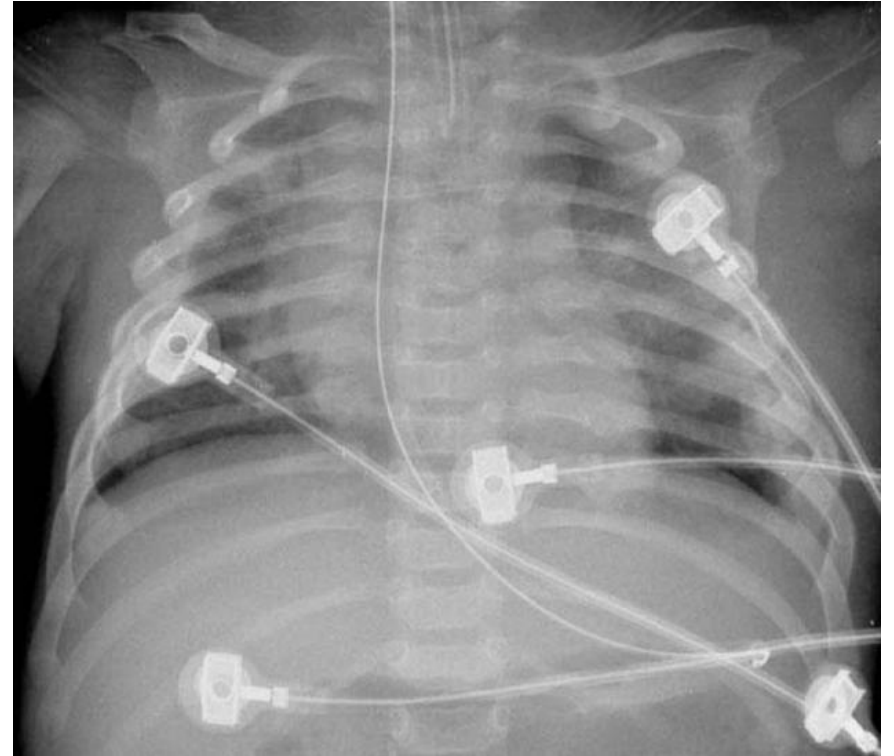


Post Test

2. A 10 month old infant is brought in to the ED by his mother due to rapid onset of coughing and breathing difficulties. They were concerned that he had 'swallowed and choked on something'. He has had multiple bouts of candidal dermatitis and has not yet begun to say words apart from 'dada' and 'mama'. He has a temperature of 99 F, blood pressure of 92/71, and pulse of 95/min. A chest x-ray was collected.

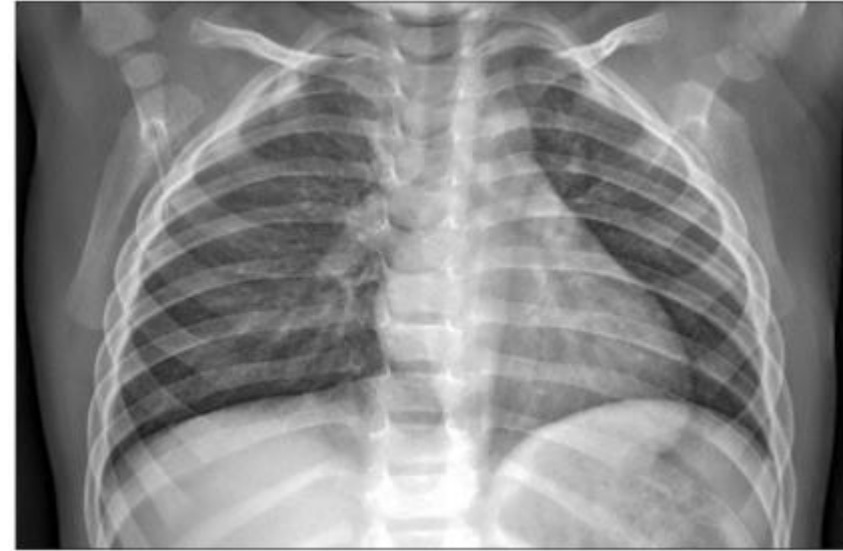What is the primary diagnosis?

- a. Community acquired pneumonia
- b. Foreign body aspiration
- c. Non-accidental trauma
- d. Vitamin D deficiency



Post Test

3. A 14 month old male with a history of VSD arrives to the ED for a possible seizure. He has had repeated infections of Streptococcal pneumonia and recurrent episodes of thrush since 6 months of age. This evening, his parents noted an episode of body stiffness, jerking of all extremities, and upward rolling of his eyes lasting one minute. An ambulance was called. His face was described as blue toward the end of the episode. Paramedics noted him to be breathing spontaneously with no cyanosis. He was transported to the ED. An IV was attempted en route, but was not successful. A chest x-ray is collected soon after arriving to the ED.



What will be evident upon further testing?

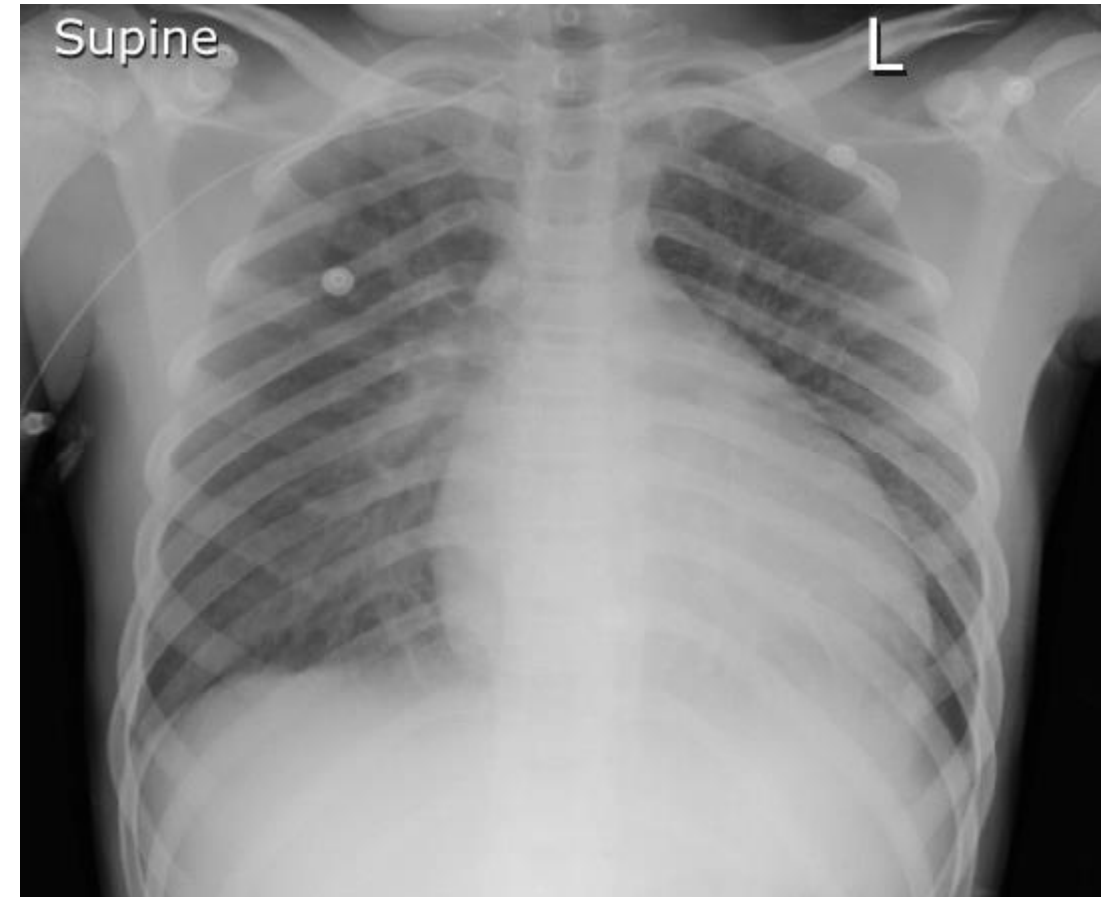
- a. Trisomy 21
- b. 22q11 microdeletion
- c. XO
- d. 11p15 microdeletion

Post Test

4. 13-year-old boy with muscular dystrophy presents to his primary care provider for difficulty breathing for the past month. He reports that he now feels out of breath after moving from his bed to his wheelchair. His vitals are 37C, 92bpm, 105/76, 94% on room air, and respiratory rate of 18. His chest x-ray taken in the office is shown.

What is the likely cause of his dyspnea?

- a. Aspiration
- b. Asthma
- c. Dilated cardiomyopathy
- d. Respiratory muscle fatigue

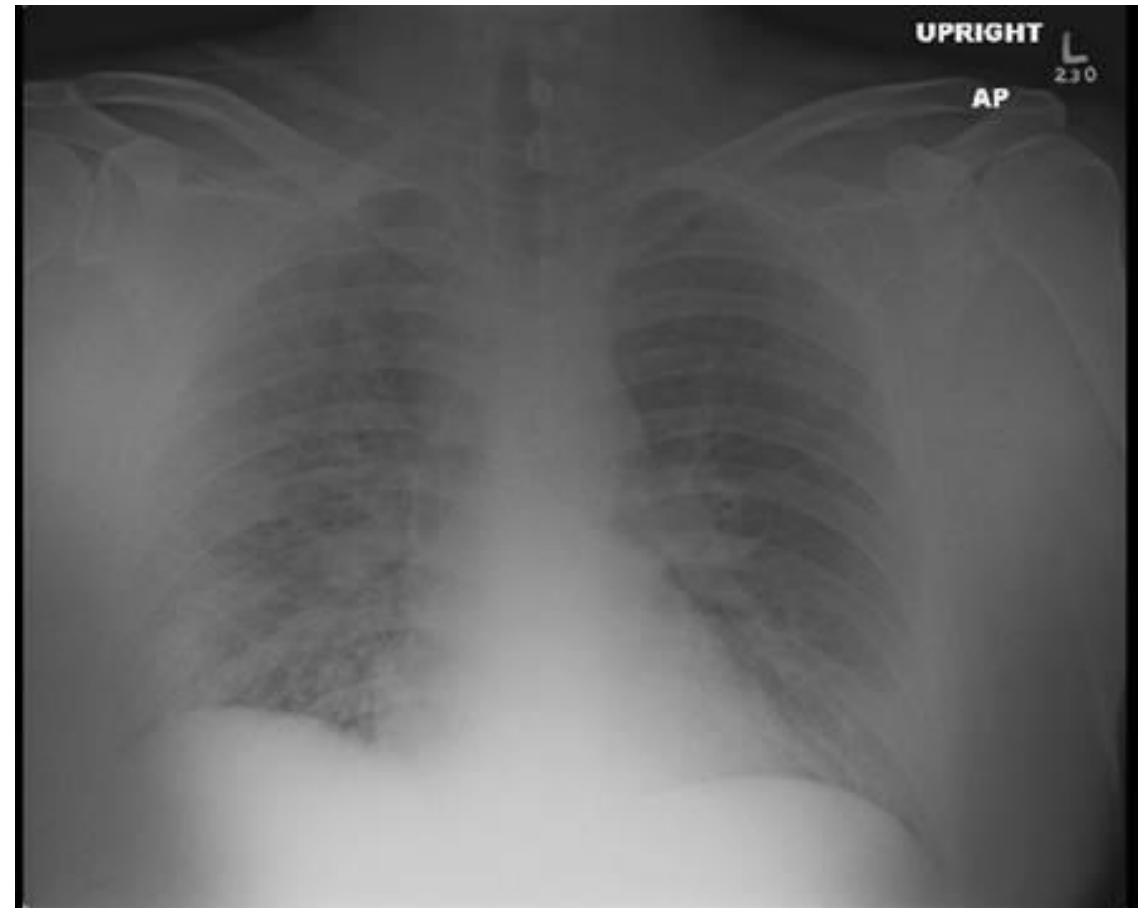


Post Test

5. A 10-year-old boy presents to the ED with severe shortness of breath following an episode of severe, dry coughing and dizziness 20 minutes ago. The patient has difficulty speaking and is sitting at the edge of the bed with his hands on his knees in a tripod position. Family history is significant for asthma in both parents. His temperature is 98.8 F, his blood pressure is 132/79, O2 sat is 88%, and his pulse is 130/min. A chest x-ray is shown.

What is the likely diagnosis?

- a. Asthma exacerbation
- b. Bronchiolitis
- c. Eosinophilic esophagitis
- d. Pneumonia



<https://seureservercdn.net/166.62.112.193/b0i.868.myftpupload.com/wp-content/uploads/2018/12/V4I1-April-2018.pdf>

References

- <https://www.ncbi.nlm.nih.gov/pmc/articles/PMC4120922/>
- <https://radiopaedia.org/articles/thymus>
- <https://radiologyassistant.nl/pediatrics/child-abuse-diagnostic-imaging>
- <https://www.parents.com/baby/all-about-babies/the-reason-this-adorable-baby-is-squeezed-into-a-glass-tube/>