




Contents lists available at ScienceDirect

Taiwanese Journal of Obstetrics & Gynecology

journal homepage: www.tjog-online.com

Original Article

Sclerotherapy with 6% polidocanol solution in patients with placenta accreta



Ricardo Mauricio Malagón Reyes^a, Rubén Castorena de Ávila^a,
 María de Jesús Ángeles Vázquez^a, César Augusto Núñez Monteagudo^b,
 Hugo Mendieta Zerón^{b, c, d, *}

^a Hospital Materno Perinatal "Mónica Pretelini Sáenz", Instituto de Salud del Estado de México, Toluca, Estado de México, Mexico

^b Faculty of Medicine, Autonomous University of the State of Mexico, Toluca, Estado de México, Mexico

^c Asociación Científica Latina Asociación Civil (ASCILA), Toluca, Estado de México, Mexico

^d Ciprés Grupo Médico, Toluca, Estado de México, Mexico

ARTICLE INFO

Article history:

Accepted 3 November 2015

Keywords:

hypogastric artery ligation
 placenta accreta
 polidocanol
 sclerotherapy

ABSTRACT

Objective: Placenta accreta is one of the main obstetrical complications worldwide. The aim of this study was to report the experience of managing placenta accreta with a 6% polidocanol solution sclerotherapy. **Materials and Methods:** We selected patients between 37 weeks of gestation and 38 weeks of gestation, diagnosed with placenta accreta, treated at the Maternal Perinatal Hospital "Monica Pretelini Sáenz", Toluca, Mexico, during the period from November 2013 to August 2014. The surgical technique has two steps: (1) fundic-arciform caesarean section followed by a 6% polidocanol sclerosing solution through a 6Fr neonatal feeding tube upon its reaching the placental bed; (2) total abdominal hysterectomy with internal hypogastric artery ligation.

Results: Data were collected from 11 patients with a mean age of 33.9 years (range, 26–42 years) and 2.8 ± 0.6 days of hospitalization in the obstetrical intensive care unit. The majority of patients were classified as having pregnancies at an advanced age. All women were multigravidas. Bleeding volume exhibited a range between 2.5 L and 3 L without any case of neonatal death but one mother died because of coagulopathy.

Conclusion: We conclude that the technique that we are reporting is feasible for implementation in obstetric hospitals, with technical and economic feasibility.

Copyright © 2016, Taiwan Association of Obstetrics & Gynecology. Published by Elsevier Taiwan LLC. This is an open access article under the CC BY-NC-ND license (<http://creativecommons.org/licenses/by-nc-nd/4.0/>).

Introduction

Maternal mortality in Mexico remains high, with an annual report in 2009 of 1207 deaths and a maternal death rate (MDR) of 62.2/100,000 live births. In 2011 the State of Mexico, Mexico, reported 131 deaths with an MDR of 50.2, which, following a linear prospective, yields 98 projected deaths for the year 2015 with an MDR of 38.2, falling short of the target of millennium development goals, which established an MDR of 22/100,000 live births for 2015 [1].

The World Health Organization reports that there are 536,000 maternal deaths worldwide annually, of which 140,000 are caused

by obstetric hemorrhage, representing 25% of all maternal deaths, and >50% of these take place in the first 24 hours postpartum [2]. In the U.S., placenta accreta has become an increasingly important contributor to repeated cesarean delivery morbidity [3]. In Mexico, obstetric hemorrhage is the second leading cause of maternal death, causing an MDR of 14.3 in 2008. Uterine sluggishness continues to comprise the leading cause of obstetric hemorrhage in developing countries [4], followed by placenta accreta, which can range from one case per 2510 patients up to one case per 533 patients [5]. In a 20-year study conducted between 1982 and 2002, placenta accreta accounted for 39% of the causes of obstetric hemorrhage [6].

The main risk factors identified for placenta accreta include age (>30 years), multiparity, placenta previa with prior cesarean section (35% of cases), placenta previa with a history of three or more cesareans (67% of cases), history of curettage (18–60% of cases), a

* Corresponding author. Felipe Villanueva sur 1209, Colonia Rancho Dolores, 50170 Toluca, Mexico.

E-mail address: mez_74@yahoo.com (H. Mendieta Zerón).

precedent of manual placental removal, a history of placental retention, and antecedents of intraamniotic infection [6].

Placenta accreta may lead to massive obstetric hemorrhage and, as a consequence, to coagulation disorders. The need for total hysterectomy, especially when associated with placenta previa and insertion in previous caesarean scars, can influence the risk of surgical damage to ureters, bladder, and other neighboring pelvic structures, as well as respiratory distress syndrome in adults, and even maternal death. Blood loss during birth fluctuates between 3000 mL and 5000 mL, thus having an institution with a blood bank is essential [7]. Fetal morbidity is affected by prematurity in up to 50–70% cases, mainly in emergencies.

Prenatal diagnosis of placenta accreta allows for a treatment plan based on a multidisciplinary and individualized approach. The two most important decisions are time of pregnancy resolution and whether radical or conservative management must be followed [8]. In the case of previous uterine surgery, the following study protocol is started: color Doppler ultrasound, magnetic resonance imaging, and cystoscopy.

The conservative decision is to leave the placenta *in situ*, with or without the use of drugs for expulsion or reabsorption, such as oxytocin or methotrexate. Sclerotherapy has been utilized since 1939 for the treatment of reticular veins or telangiectasias (veins ≤ 3 mm in diameter) and since 1944 for these mixed with air (Tessari three-way tap technique), with an increasing number of medical applications in diseases involving blood vessels of different sizes.

In relation to the previously mentioned method, polidocanol (hydropolyethoxydodecane) is a mixture of dextrose and sodium chloride that acts as a sclerosing liquid detergent, causing vascular damage by altering surface tension in endothelial cells. The foam preparation increases the duration and the surface area of contact between the sclerosant and the vein wall, producing effective sclerosis (fibrosis) by endothelial destruction and exposure of endothelial subsclerosing collagen fibers, activating the intrinsic

pathway of coagulation through factor XII and turning the vessel into a fibrous cord. The foam has early recanalization rates of up to 32%, suggesting that the primary mode of action of these agents is to promote thrombotic occlusion instead of producing permanent damage to the vein wall. The aim of this study was to report the experience of managing placenta accreta with polidocanol sclerotherapy.

Materials and methods

This was a prospective and descriptive study. We used a continuous collection method to select patients between 37 weeks of gestation and 38 weeks of gestation, diagnosed with placenta accreta by ultrasound, treated at the Maternal Perinatal Hospital “Monica Pretelini Sáenz”, Health Institute of the State of Mexico, during the period from November 2013 to August 2014.

Surgical technique

First surgical procedure: Fundic-arciform caesarean section

The patient is in supine position and ready for a caesarean section (C-section), with permeable transurethral catheter and under regional anesthesia. A midline extended supraumbilical incision is made about 10 cm above the umbilicus, habitual dissection by planes is done, and an intentional macroscopic exploration for bladder-invasive placenta is carried out when entering the abdominal cavity. If the diagnosis is confirmed, a fundic-arciform hysterectomy is performed on the infiltrated surface (Figure 1A), extracting the fetus. Thereafter, an umbilical vein is identified, phlebotomy is performed using a scalpel, and then this is cannulated with a 6Fr neonatal feeding tube upon its reaching the placental bed, with a prior 3-mL dilution of the polidocanol-type sclerosing solution, and 10 mL of room air mixing for about 20 seconds (Figures 1B and 1C). This is then applied directly into the vein through the tube previously placed in the umbilical vein.

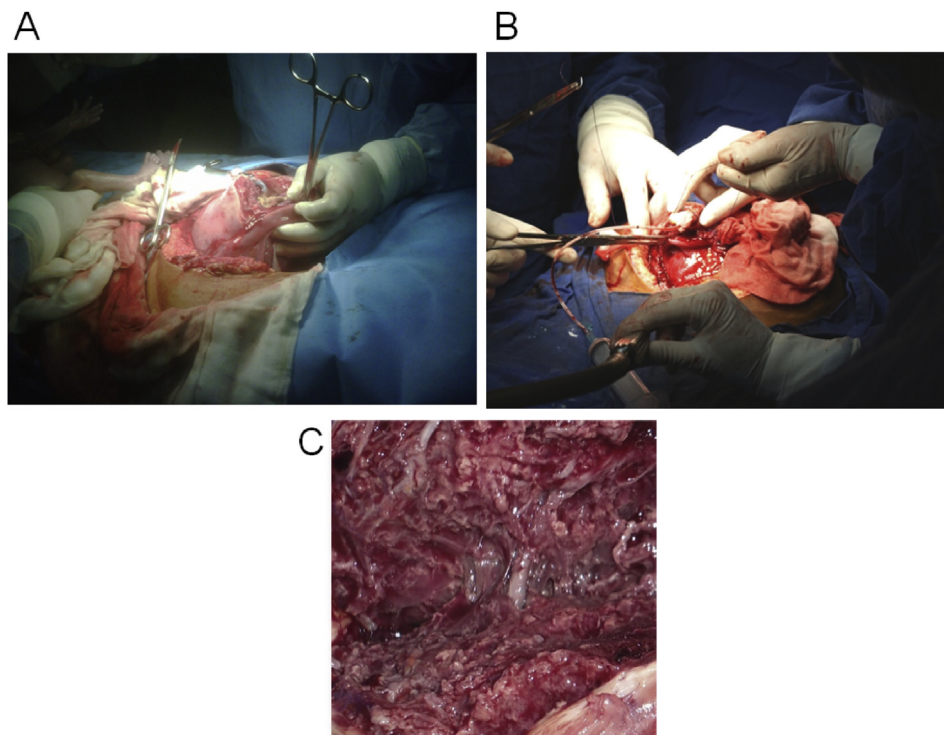


Figure 1. (A) Fundic-arciform cesarean incision; (B) polidocanol instillation; (C) tissular visualization after polidocanol instillation.

Afterwards, the umbilical cord is ligated. Hysterorrhaphy is performed in a single plane with continuous suturing utilizing absorbable sutures.

Second surgical procedure: Total abdominal hysterectomy with internal hypogastric artery ligation

The sacral promontory is identified on searching for bifurcation of the iliac artery. Once this is palpable, the internal hypogastric artery is identified and then a retroperitoneal incision with scalpel is performed. The fat plane is dissected; the artery, ureter, and vein are identified, moving the ureter laterally and externally. Dissection begins of the periarterial soft tissue using a Lahey forceps (90°) with gentle mobilization to avoid tearing the artery and acute bleeding. After dissection, and with the artery exposed, two spoons of silk or absorbable suture (number 0) are set in place for arterial ligation, with the cephalic extreme knotted about 2 cm from the bifurcation and separated 1 cm from the caudal extreme. The procedure is repeated on the contralateral side (Figures 2A and 2B). At the end, the retroperitoneum is closed using absorbable suture 000. Ligation of the hypogastric arteries is known to diminish uteroplacental blood flow by up to 30%, decreasing the risk of the sclerosing solution migrating into the systemic circulation, ensuring the uteroplacental application. The next step is the uterine artery ligation as habitually conducted, and with care to avoid damaging the ureter. With ligation of these vascular structures that supply the uterus to a great degree, the surgeon proceeds with the gentle dissection of the vesicouterine fold, in some cases with ligation of bleeding vessels with thin, absorbable suture (000) using an electrocautery or harmonic scalpel to cauterize vascular structures. On noting a small bladder injury, we proceed to the performance of primary closure on two planes with absorbable suture at continuous points without anchoring these, as this produces ischemia of bladder tissue, predisposing to necrosis of a segment of the repair, in turn causing urine leakage with the consequent formation of a vesicovaginal fistula.

Statistical analysis

Data analysis was performed using Excel (Microsoft, Redmond, Washington, USA). Frequency distribution tables were constructed, calculating measures of central trend and dispersion for quantitative variables.

Ethics

Ethical clearance was granted by the Research Committee of the Maternal Perinatal Hospital “Monica Pretelini Sáenz” (code:

217B500402015067), Toluca, Mexico, and followed the General Health Research Law of Mexico and the Declaration of Helsinki (Fortaleza, Brazil). All patients were asked to sign written informed consent.

Results

During the study period, 274 obstetric patients were admitted to the intensive care unit. Fifteen patients fulfilled the entry criteria for this protocol, with four of these being discarded due to incomplete medical information. Final data was collected from 11 patients with a mean age of 33.9 years (range, 26–42 years).

The majority of patients were classified as having pregnancies at an advanced age. As recommended, all patients received prenatal care, with a median number of three consultations. Regarding the number of gestations, all were at least in the third pregnancy with a minimum of two previous C-sections recorded. Regarding the history of abortions, less than half of the participants had experienced this misfortune.

Of note is the fact that the 11 patients were submitted to globular package, fresh frozen plasma, and cryoprecipitate transfusions. Bleeding volume ranged between 2.5 L and 3 L (Table 1). There were no cases of neonatal death but one mother died due to coagulopathy.

Discussion

There is limited data to guide optimal management of placenta accreta. The existing literature is predominantly comprised of case reports and retrospective studies based on reviews of medical records over a number of years in a single or in a small number of tertiary-care institutions. Such studies have a number of limitations, including limited generalization and a lack of statistical power [9].

Worldwide, the usual treatments are administration of methotrexate, embolization of the internal iliac vessels, and resection of the affected uterine segment, use of uterine compression sutures, and oversuturing of the placental bed [7]. In a review of 60 cases of placenta accreta, partial removal of the placenta ($n = 26$), *in situ* administration of methotrexate ($n = 22$), and uterine embolization ($n = 12$) were the most common techniques employed. Treatment failure occurred in 4/26, 5/22, and 3/12 of patients, respectively; 11/60 women had serious infectious complications, 21/60 had significant vaginal bleeding, and 4/60 developed disseminated intravascular coagulation. The percentage of hysterectomy was 20%. The conclusion was that the use of methotrexate and embolization generates uncertain results [10].

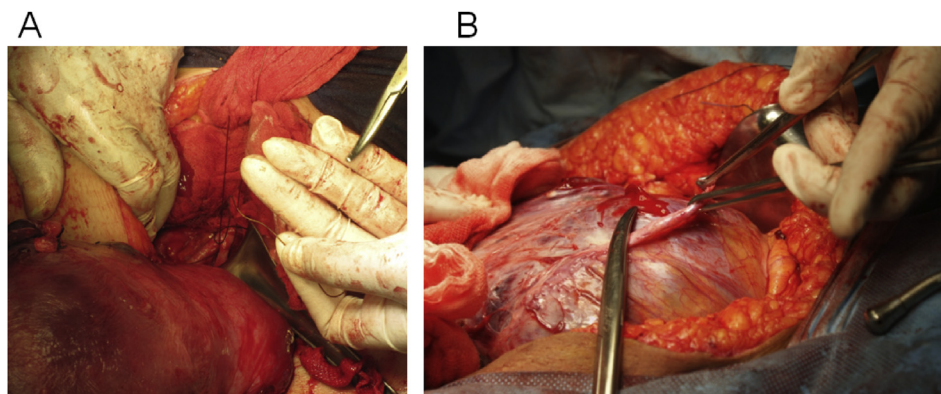


Figure 2. (A) Uterine artery ligation; (B) vesicouterine pouch dissection.

Table 1
General characteristics of the patients.

Variable	Case											Mean ± SD
	1	2	3	4	5	6	7	8	9	10	11	
Age (y)	33	37	42	35	36	26	30	32	30	35	37	33.9 ± 4.3
Gestations	4	4	6	3	3	3	4	4	5	3	3	3.8 ± 0.9
Vaginal deliveries	1	0	0	1	0	0	0	0	0	0	0	0.1 ± 0.4
Caesarean sections	2	2	3	2	2	2	3	3	3	2	2	2.3 ± 0.5
Curettage	0	1	2	1	1	1	0	0	0	0	0	0.5 ± 0.6
Surgery time (min)	90	100	120	100	90	120	150	100	120	100	130	110.9 ± 18.6
Anesthetic time (min)	40	35	35	35	30	30	30	35	35	35	35	34 ± 3
Bleeding (L)	2.5	3	2.5	2.5	2.5	3	3	2.5	3	3	3	2.7 ± 0.261
Globular package transfusions (units)	4	5	5	5	5	5	5	5	5	5	5	4.9 ± 0.3
Fresh frozen plasma (units)	2	3	3	3	3	3	3	3	3	3	3	2.9 ± 0.3
Cryoprecipitates (units)	1	2	2	2	2	2	2	2	2	2	2	1.9 ± 0.3
Hospitalization time (d)	5	7	7	7	5	5	5	6	8	5	5	5.9 ± 1.1
Days in the O-ICU	2	3	3	3	3	3	2	2	4	3	3	2.8 ± 0.6

SD = standard deviation; O-ICU = obstetrical intensive care unit.

Indications for sclerotherapy according to the guidelines of the German Society of Phlebology include venous malformations, with the known absolute contraindications of allergy to the sclerosing agent, severe systemic disease, deep vein thrombosis, severe generalized infection, permanent immobility and confinement to bed, peripheral occlusive arterial disease (Stage III or IV), and contraindications for chronic complications of diabetes, arterial occlusive disease Stage II, asthma, patent foramen ovale and thrombophilia, or hypercoagulable state with or without a history of deep vein thrombosis [11].

Compared with other sclerosing agents, polidocanol offers a wide safety margin against necrosis by extravasation. Its application is painless and possesses an anesthetic effect. The accepted safety dose for sclerotherapy is 2 mg/kg, and the suggested dose is 10–20 mL of 3% solution in large veins.

Matsuoka et al [12] studied cases involving stepwise treatment versus intraaortic balloon occlusion (IAOB), and reported a blood loss of between 840 mL and 1150 mL in the first, and of between 2400 mL and 5200 mL in the second. We propose that with our technique, the bleeding is less than in the second option, but higher than with the stepwise treatment.

Uterine artery embolization has been employed to treat placenta previa plus placenta accreta in gestation in an attempt to avoid C-section [13]. Duan et al [14] have published the amount of blood loss and blood transfusion, and the surgical procedure time of 586 ± 355 mL, 422 ± 83 mL, and 65.5 ± 10.6 min, respectively, using C-section combined with temporary IABO followed by uterine artery embolization for the management of placenta accreta. In this same study, mean postoperative hospital stay, occlusion time, and fetal radiation dose were 5.5 ± 2.6 days, 22.4 ± 7.2 min, and 4.2 ± 2.9 mGy, respectively. Evidently, with uterine artery embolization, blood loss, blood transfusion, and surgical procedure times are lower than with sclerotherapy with polidocanol, but the total days of hospitalization were more than with the technique we are reporting.

The most important fact observed in our study was the decreased bleeding, explained mainly by the following factors: (1) the sclerosing solution tends to form a fibrous cap around the uteroplacental vascular bed; (2) limitation of vascular flow by two large vessels supplying the uterus: hypogastric arteries and uterine arteries; and (3) the uterus itself, with the pharmacological action of oxytocin or other uterotonic drugs such as carbetocin.

Some pharmacological effects must be taken into account when administering polidocanol. For example, hemoglobinuria has been reported after its application in venous malformations, the incidence of nonfatal allergic phenomena ranges from 0.01–0.91%, and

there is also a reversible negative inotropic effect, reducing atrioventricular and intraventricular conduction in a dose-dependent manner, resulting in hypotension and bradycardia, particularly when combined with other local anesthetics [15]. The possibility of “big bubble” microembolism associated with stroke, transient ischemic attacks, and vision problems remains hypothetical, but there are reports in publications of case series [16,17].

While a limitation of this report is the small number of cases, the results are promising, especially when conservative management of placenta accreta is not feasible [18].

We conclude that it is possible to implement our technique in obstetric hospitals, with technical and economic feasibility. A comparative study with other wide-domain techniques is mandatory.

Conflicts of interest

The authors have no conflicts of interest relevant to this article.

Acknowledgments

The authors are grateful for the support of the authorities of the Maternal-Perinatal Hospital “Mónica Pretelini Sáenz” and to Maggie Brunner, MA, for the English style correction.

References

- [1] Lawson GW, Keirse MJ. Reflections on the maternal mortality millennium goal. *Birth* 2013;40:96–102.
- [2] American College of Obstetricians & Gynecologists. ACOG practice bulletin no. 76: postpartum hemorrhage. *Obs Gynecol* 2006;108:1039–47.
- [3] Creanga AA, Bateman BT, Butwick AJ, Raleigh L, Maeda A, Kuklina E, et al. Morbidity associated with cesarean delivery in the United States: is placenta accreta an increasingly important contributor? *Am J Obstet Gynecol* 2015. <http://dx.doi.org/10.1016/j.ajog.2015.05.002>.
- [4] México. Centro Nacional de Equidad de Género y Salud Reproductiva. Prevención, diagnóstico y manejo de la hemorragia obstétrica. Lineamiento técnico. <http://www.clacaidigital.info:8080/xmlui/bitstream/handle/123456789/67/CNEGR%20Lineamiento%20Hemorragia%20Obstetrica.pdf?sequence=1>. [Accessed 10 Jun 2015].
- [5] Clark SL, Yeh SY, Phelan JP, Bruce S, Paul RH. Emergency hysterectomy for obstetric hemorrhage. *Obstet Gynecol* 1984;64:376–80.
- [6] Wu S, Kocherginsky M, Hibbard JU. Abnormal placentation: twenty-year analysis. *Am J Obstet Gynecol* 2005;192:1458–61.
- [7] Oyelese Y, Smulian JC. Placenta previa, placenta accreta, and vasa previa. *Obstet Gynecol* 2006;107:927–41.
- [8] Eller AG, Porter TF, Soisson P, Silver RM. Optimal management strategies for placenta accreta. *BJOG* 2009;116:648–54.
- [9] Fitzpatrick KE, Sellers S, Spark P, Kurinczuk JJ, Brocklehurst P, Knight M. The management and outcomes of placenta accreta, increta, and percreta in the UK: a population-based descriptive study. *BJOG* 2014;121:62–70.

- [10] Timmermans S, van Hof AC, Duvekot JJ. Conservative management of abnormally invasive placentation. *Obstet Gynecol Surv* 2007;62:529–39.
- [11] Rabe E, Pannier F. Sclerotherapy of varicose veins with polidocanol based on the guidelines of the German Society of Phlebology. *Dermatologic Surg* 2010;36(2):968–75.
- [12] Matsuoka K, Kawabata T, Yoza K. Anesthetic management of patients with placenta previa accreta for cesarean section: a 7-year single-center experience. *Masui* 2015;64:70–6 [Article in Japanese].
- [13] Huang L, Awale R, Tang H, Zeng Z, Li F, Chen Y. Uterine artery embolization, not cesarean section, as an option for termination of pregnancy in placenta previa. *Taiwan J Obstet Gynecol* 2015;54:191–3.
- [14] Duan XH, Wang YL, Han XW, Chen ZM, Chu QJ, Wang L, et al. Cesarean section combined with temporary aortic balloon occlusion followed by uterine artery embolisation for the management of placenta accreta. *Clin Radiol* 2015. <http://dx.doi.org/10.1016/j.crad.2015.03.008>.
- [15] Duffy DM. Sclerosants: a comparative review. *Dermatologic Surg* 2010;36(2):1010–25.
- [16] Guex JJ. Complications and side-effects of foam sclerotherapy. *Phlebology* 2009;24:270–4.
- [17] Morrison N, Neuhardt DL. Foam sclerotherapy: cardiac and cerebral monitoring. *Phlebology* 2009;24:252–9.
- [18] Fox KA, Shamsheer AA, Carusi D, Secord AA, Lee P, Turan OM, et al. Conservative management of morbidly adherent placenta: expert review. *Am J Obstet Gynecol* 2015. pii: S0002-9378(15) 00398-1.