



Journal of Community Hospital Internal Medicine Perspectives

ISSN: (Print) 2000-9666 (Online) Journal homepage: <https://www.tandfonline.com/loi/zjch20>

Unremitting chronic skin lesions: a case of delayed diagnosis of glucagonoma

Hameem I. Kawsar, Alma Habib, Azhar Saeed & Anwaar Saeed

To cite this article: Hameem I. Kawsar, Alma Habib, Azhar Saeed & Anwaar Saeed (2019) Unremitting chronic skin lesions: a case of delayed diagnosis of glucagonoma, Journal of Community Hospital Internal Medicine Perspectives, 9:5, 425-429, DOI: [10.1080/20009666.2019.1671574](https://doi.org/10.1080/20009666.2019.1671574)

To link to this article: <https://doi.org/10.1080/20009666.2019.1671574>



© 2019 The Author(s). Published by Informa UK Limited, trading as Taylor & Francis Group on behalf of Greater Baltimore Medical Center.



Published online: 01 Nov 2019.



Submit your article to this journal [↗](#)



Article views: 419



View related articles [↗](#)



View Crossmark data [↗](#)

CASE REPORT



Unremitting chronic skin lesions: a case of delayed diagnosis of glucagonoma

Hameem I. Kawsar, Alma Habib, Azhar Saeed and Anwaar Saeed

Division of Medical Oncology, Department of Internal Medicine, University of Kansas Medical Center, Kansas City, KS, USA

ABSTRACT

A 54-year-old Caucasian male with history of hypertension, hyperlipidemia, insulin-dependent diabetes mellitus, and chronic skin rash of 4 years presented to the emergency department with worsening rash and weight loss. Physical examination revealed diffuse erythematous rash, skin ulceration, bullae with associated paresthesia in the lower extremities, trunk, bilateral upper extremities, and palms and soles. A computed tomography (CT) scan with contrast showed a large, heterogeneously enhancing pancreatic mass measuring 9.4 × 3.8 cm with surrounding low-attenuation soft tissue thickening. Blood tests showed hemoglobin A1C of 10.0%. Glucagon level was elevated to 2,178 (normal < 80 pg/dl). Endoscopic ultrasound (EUS)-guided fine needle aspiration (FNA) from the pancreatic mass was suggestive of pancreatic endocrine tumor. The tumor cells were positive for synaptophysin, chromogranin, CD56, and pan-cytokeratin with focal positivity for glucagon, suggestive of glucagonoma. The patient underwent distal pancreatectomy along with splenectomy and cholecystectomy. The glucagon level normalized to 25 pg/dl within a week of tumor resection, and during his 6-week outpatient follow up, skin rash had completely resolved.

ARTICLE HISTORY

Received 24 June 2019

Accepted 19 September 2019

KEYWORDS

Glucagonoma; Necrolytic Migratory Erythema (NME); neuroendocrine tumor; MEN-1; alpha cell tumor

1. Introduction

Necrolytic migratory erythema (NME) is a rare cutaneous paraneoplastic manifestation of glucagonoma. Glucagonoma is a tumor of alpha cells of pancreas that secrete glucagon, and plays a major role in blood glucose hemostasis. Elevated glucagon level due to glucagonoma can cause a variety of clinical manifestations including weight loss, diabetes, and NME. Misdiagnosis of paraneoplastic cutaneous manifestation could delay the diagnosis of glucagonoma. Here, we present an interesting case of chronic skin rash which was treated as eczema for more than 4 years, and recently as urticarial vasculitis, which was actually NME of glucagonoma. The skin rash has resolved completely with resection of the tumor.

2. Case description

A 54-year-old Caucasian male with past medical history of hypertension, hyperlipidemia, insulin-dependent diabetes mellitus, and chronic skin rash presented to the emergency department (ED) with skin rash of 4-year duration that had worsened over the preceding 2 weeks. He was diagnosed with eczematous skin disease about 4 years ago and treated with topical steroid intermittently with variable response. About 2 months ago, he was started on doxycycline and oral prednisone for unremitting skin lesions. However, he had poor glycemic control with use of prednisone, and hemoglobin A1c

(HbA1c) increased from 6.0% to 10.0%. A skin biopsy was done for a definitive diagnosis of this chronic skin lesion, and it was reported as urticarial vasculitis. Prednisone was discontinued for poor glycemic control, and dapsone was added. During the following 2 weeks, the rash progressed to involve both lower extremities, upper extremities, and trunk with swelling and bullae with no other identifiable trigger. In the ED, he reported of unintentional weight loss of 30 lbs in the preceding 3 months and denied any family history of malignancy or autoimmune disease. He also denied history of smoking, anorexia, or abdominal pain. On examination, the affected area of the skin was warm with diffuse erythema and edema throughout both lower extremities. Ulceration was prominent in the right lower extremity, trunk, bilateral upper extremities, and palms and soles (Figure 1). There were bullae with associated paresthesia. The patient was unable to bear weight and experienced sharp shooting pain in his bilateral feet. Further work up was directed to rule out other etiologies of skin rash and weight loss, including nutritional deficiency, infection, autoimmune disease, and occult malignancy. He had elevated erythrocyte sedimentation rate (ESR) and C-reactive protein (CRP) at 32 (reference range 0–20 mm/h) and 8.05 (reference range <1.0 mg/dl), respectively. Comprehensive work up for autoimmune disease and infectious etiology were negative. Because of his recent significant weight loss, a computed tomography (CT) scan of chest, abdomen, and pelvis with contrast was done to rule out occult malignancy, which

CONTACT Anwaar Saeed ✉ asaeeed@kumc.edu 📍 Division of Medical Oncology, Department of Medicine, University of Kansas Medical Center, Kansas City, KS 66205, USA

© 2019 The Author(s). Published by Informa UK Limited, trading as Taylor & Francis Group on behalf of Greater Baltimore Medical Center.

This is an Open Access article distributed under the terms of the Creative Commons Attribution-NonCommercial License (<http://creativecommons.org/licenses/by-nc/4.0/>), which permits unrestricted non-commercial use, distribution, and reproduction in any medium, provided the original work is properly cited.

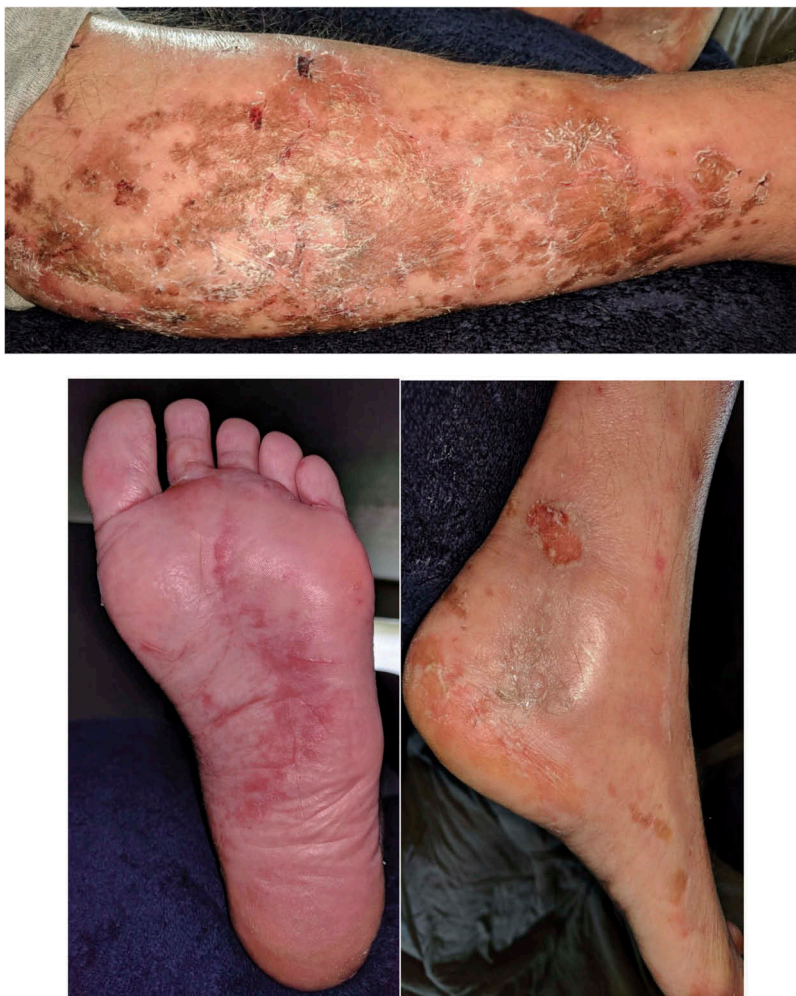

Figure 1. Affected area of the skin showed desquamation, erythema, and ulceration in lower extremities and sole.

showed a large, heterogeneously enhancing mid to distal pancreatic mass measuring 9.4×3.8 cm with surrounding low-attenuation soft tissue thickening (Figure 2). Tumor marker, CA 19-9 was 2.0 (reference range < 35 U/ml); however, glucagon was elevated to 2,178 (normal < 80 pg/dl). Prolactin, T4, and TSH levels were within normal range. Hemoglobin and hematocrit were low at 12.2 (reference range 13.5–16.5 gm/dl) and 36.1 (reference range 40–50%), respectively. Liver enzymes were within normal limit. There was no leukocytosis or fever, indicating cellulitis less likely.

An endoscopic ultrasound (EUS) was done which showed an isoechoic mass (6.5 cm \times 3.8 cm) in the body/tail area of the pancreas, and fine needle aspiration (FNA) samples were obtained from the mass. Immunohistochemical stains were positive for synaptophysin, chromogranin, CD56, pancytokeratin, and focal positivity for glucagon suggestive of glucagonoma. He underwent distal pancreatectomy with splenectomy and cholecystectomy. Tissue specimens showed a pancreatic well-differentiated neuroendocrine tumor, WHO grade 1. The tumor cells were positive for chromogranin and synaptophysin and negative for nuclear beta-catenin. Resected margins were free of malignant involvement. None of the 26

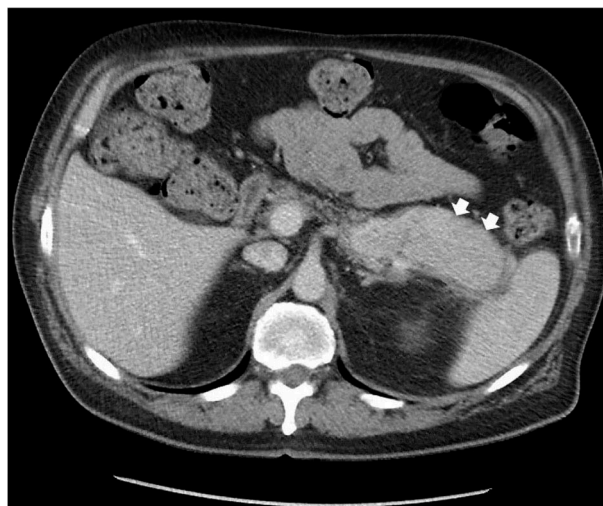


Figure 2. A CT scan with contrast of abdomen showed a large, heterogeneously enhancing mid to distal pancreatic mass measuring 9.4×3.8 cm with surrounding low-attenuation soft tissue thickening (white arrows).

lymph nodes collected during surgery were positive. The punch biopsy of the skin lesion showed psoriasiform inflammatory reaction and confluent parakeratosis (Figure 3). The glucagon level normalized to 25 pg/ml (from 2,718 pg/ml) 5 days after the surgical

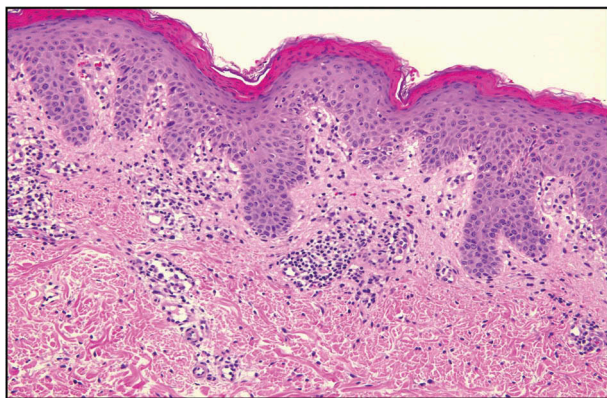


Figure 3. A biopsy of skin lesion showing psoriasiform inflammatory reaction and confluent parakeratosis.

resection of tumor. Dapsone and doxycycline were discontinued and the patient was discharged home. During 6-week outpatient follow up, he had complete resolution of the skin lesions.

3. Discussion

In 1942, Dr. Becker and his colleagues described a 45-year-old female who was hospitalized with a history of widespread pruritic erythematovesicular skin eruptions for 8 months that was unresponsive to roentgen irradiation, ultraviolet irradiation, systemic iodides, ferrous sulfate, and high vitamin diet. She died of circulatory collapse and respiratory failure due to ‘shock phenomenon’. Postmortem examination revealed a pancreatic tumor replacing the tail and body of the pancreas. This is the first known reported case of association of pancreatic cancer with cutaneous manifestations [1]. This characteristic skin lesion is now known as necrolytic migratory erythema (NME) due to its migratory nature, erythematous appearance, and histological findings of necrosis of the upper spinous layer [2]. However, this finding in biopsy is nonspecific and can be absent or focally present on biopsy [3]. In 1966, Dr. McGavran and his colleagues described the first case of glucagonoma in a 42-year-old female who presented with bullous and eczematoid dermatitis of the hands, feet, and legs [4]. The diagnosis of glucagonoma is made based on increased serum glucagon level and presence of glucagon secreting tumor in the pancreas. Glucagonoma presenting with constellation of symptoms, known as glucagonoma syndrome, was described in 1974 based on the findings in nine patients presenting with NME, stomatitis, weight loss, and diabetes in seven patients [5]; however, this syndrome was extensively reviewed in 1978 by Dr. Swenson and his colleagues [6]. While NME is described as a characteristic cutaneous manifestation of glucagonoma, it has been reported in other diseases, such as other malignancies (e.g., hepatocellular carcinoma, bronchial carcinoma, jejunal adenocarcinoma, etc.),

celiac disease, chronic pancreatitis, liver cirrhosis, inflammatory bowel disease, and nutritional deficiencies [7].

NME is a cutaneous paraneoplastic manifestation of glucagonoma, and can be the only presenting feature in approximately 70% of patients [8]. This rash is commonly pruritic, painful, erythematous, and well-demarcated plaques [9,10], and may involve the face, trunk, extremities, and perineum [11]. The biopsy of the skin lesion may show superficial epithelial necrosis of the spinous layer of epidermis and vacuolated keratinocytes; however, overlapping dermatoses such as pemphigoid, psoriasis, or eczema can sometime make the diagnosis challenging [2]. High serum glucagon level due to glucagonoma has glucagon-like peptide (GLP-1) activity that causes a shift in catabolic state and caloric consumption resulting in weight loss. Direct or indirect effect of catabolic state induced by glucagon with resultant deficiency of fatty acids, amino acids, and minerals essential for epidermal growth and turnover results in the development of the characteristic findings of NME [12–15]. Intermittent amino acids and fatty acid infusion via peripheral vascular access has been reported to be successfully used to treat NME in the glucagonoma syndrome. However, other symptoms related to glucagonoma syndrome does not improve by this infusion [16]. Treatment of glucagonoma with octreotide or surgical resection of tumor results in resolution of NME.

There are published reports of characteristic skin lesions that aid in diagnosis of underlying glucagonoma [17–19]; however, there are also reports of delayed diagnosis of glucagonoma due to misdiagnosis or delayed diagnosis of skin lesions (Table 1). Oftentimes, the patients with glucagonoma presents with skin lesions that is diagnosed as dermatitis, psoriasis, or eczema and treated with topical and/or oral steroid with variable responses. Our patient had diabetes and skin rash for more than 4 years. His diabetes was treated with insulin, and skin rash was diagnosed as eczema by his dermatologist, and treated with topical steroid with variable response. Due to the chronicity of the rash, and not resolving in 4 years, he was treated with doxycycline and oral steroid, which caused poor glycemic control requiring discontinuation of steroid therapy. Dapsone was added by his physician due to skin biopsy findings of urticarial vasculitis; however, his rash worsened with significant weight loss requiring ED visit. His skin rash completely resolved within 6 weeks of surgical resection of the glucagonoma. This case illustrates a delayed diagnosis of glucagonoma for approximately 4 years due to misdiagnosis of his skin lesion, and not initiating further investigation of the underlying etiology in a timely manner.

In conclusion, unremitting skin lesions associated with diabetes/hyperglycemia and/or weight loss needs further investigations to rule out other etiologies

Table 1. Delayed diagnosis of glucagonoma in patients initially presenting with skin rash [3,20–24].

Age, gender	Initial presenting symptom(s)	Initial diagnosis of skin lesion	Initial treatment for skin lesion	Glucagon level at diagnosis of glucagonoma	Treatment of glucagonoma and outcome of skin lesion(s)	Delay in diagnosis of glucagonoma from initial presentation
53 yo, Female	Skin rash in extremities, genitalia and oral cavity.	Erosive and bullous skin lesion	Topical steroids	2,040 ng/l	Resection of the tumor, but patient died after 28 days due to comorbidities.	1 year
55 yo, Male	Skin rash in the face, upper and lower extremities and perianal area.	Eczema	Oral prednisone	1,625 ng/l	Resection of tumor and disappearance of skin lesion 1 week after surgery	2 years
63 yo, Female	Pruritic skin rash in groin, abdomen, axilla, gluteal region, calves and ankles	Spongiotic dermatitis, zinc deficiency dermatitis	Topical steroid, zinc supplement	3,000 ng/l	Resection of tumor, disappearance of skin lesions	3 years
60 yo, Male	Skin rash in lower legs, thighs, abdomen, lower back, head, face, hands and feet	Systemic pruritus and erythema, dermatitis	Symptomatic treatment	648 ng/l	Resection of the tumor, resolution of the skin lesions	3 years
54 yo, Male	Pruritic macule and bullae in the scalp, scrotum, perineum and distal extremities	Psoriasis	Vitamin supplement, corifodermia, ozonotherapy	490 ng/l	Resection of the tumor, complete resolution of skin lesion 2 days postoperatively.	2 years

including nutritional deficiencies, specially zinc, vitamins, and iron; infectious etiology and occult malignancies. If glucagon level is elevated, an abdominal imaging is needed to localize the source of glucagon-secreting tumor. A high degree of clinical suspicion is necessary for early diagnosis of glucagonoma because of the rarity of the disease as well as association with nonspecific skin lesions.

Disclosure statement

No potential conflict of interest was reported by the authors.

References

- [1] Becker SW, Kahn D, Rothman S. Cutaneous manifestations of internal malignant tumors. *JAMA Dermatol.* 1942;45(6):1069–1080.
- [2] Lobo I, Carvalho A, Amaral C, et al. Glucagonoma syndrome and necrolytic migratory erythema. *Int J Dermatol.* 2010;49(1):24–29.
- [3] Halvorson SA, Gilbert E, Hopkins RS, et al. Putting the pieces together: necrolytic migratory erythema and the glucagonoma syndrome. *J Gen Intern Med.* 2013;28(11):1525–1529.
- [4] McGavran MH, Unger RH, Recant L, et al. A glucagon-secreting alpha-cell carcinoma of the pancreas. *N Engl J Med.* 1966;274(25):1408–1413.
- [5] Mallinson CN, Bloom SR, Warin AP, et al. A glucagonoma syndrome. *Lancet.* 1974;2(7871):1–5.
- [6] Swenson KH, Amon RB, Hanifin JM. The glucagonoma syndrome. A distinctive cutaneous marker of systemic disease. *Arch Dermatol.* 1978;114(2):224–228.
- [7] Mullans EA, Cohen PR. Iatrogenic necrolytic migratory erythema: a case report and review of nonglucagonoma-associated necrolytic migratory erythema. *J Am Acad Dermatol.* 1998;38(5 Pt 2):866–873.
- [8] Wermers RA, Fatourehchi V, Wynne AG, et al. The glucagonoma syndrome. Clinical and pathologic features in 21 patients. *Medicine (Baltimore).* 1996;75(2):53–63.
- [9] Chastain MA. The glucagonoma syndrome: a review of its features and discussion of new perspectives. *Am J Med Sci.* 2001;321(5):306–320.
- [10] van Beek AP, de Haas ERM, van Vloten WA, et al. The glucagonoma syndrome and necrolytic migratory erythema: a clinical review. *Eur J Endocrinol.* 2004;151(5):531–537.
- [11] Vinik A, et al. Glucagonoma syndrome. In: Feingold KR, editor. *Endotext.* South Dartmouth (MA); 2000.
- [12] Silva JA, Mesquita KDC, Igreja ACDSM, et al. Paraneoplastic cutaneous manifestations: concepts and updates. *An Bras Dermatol.* 2013;88(1):9–22.
- [13] Pipkin CA, Lio PA. Cutaneous manifestations of internal malignancies: an overview. *Dermatol Clin.* 2008;26(1):1–15, vii.
- [14] Klein S, Jahoor F, Baba H, et al. In vivo assessment of the metabolic alterations in glucagonoma syndrome. *Metabolism.* 1992;41(11):1171–1175.

- [15] Norton JA, Kahn CR, Schiebinger R, et al. Amino acid deficiency and the skin rash associated with glucagonoma. *Ann Intern Med.* 1979;91(2):213–215.
- [16] Alexander EK, Robinson M, Staniec M, et al. Peripheral amino acid and fatty acid infusion for the treatment of necrolytic migratory erythema in the glucagonoma syndrome. *Clin Endocrinol (Oxf).* 2002;57(6):827–831.
- [17] Mountjoy L, Kollmorgen D. Glucagonoma-Associated Rash. *N Engl J Med.* 2017;376(10):e18.
- [18] Rodriguez G, Vargas E, Abaúnza C, et al. Necrolytic migratory erythema and pancreatic glucagonoma. *Biomedica.* 2016;36(2):176–181.
- [19] Al-Faouri A, et al. Glucagonoma and glucagonoma syndrome: a case report with review of recent advances in management. *Case Rep Surg.* 2016;2016:1484089.
- [20] Afsharfard A, et al. Necrolytic migratory erythema as the first manifestation of glucagonoma. *Case Rep Surg.* 2012;2012:974210.
- [21] Fang S, Li S, Cai T. Glucagonoma syndrome: a case report with focus on skin disorders. *Onco Targets Ther.* 2014;7:1449–1453.
- [22] Wu SL, Bai J-G, Xu J, et al. Necrolytic migratory erythema as the first manifestation of pancreatic neuroendocrine tumor. *World J Surg Oncol.* 2014;12:220.
- [23] Han X, Wang D, Kuang T, et al. Glucagonoma syndrome: report of one case. *Transl Gastroenterol Hepatol.* 2016;1:70.
- [24] Cruz-Bautista I, Lerman I, Perez-Enriquez B, et al. Diagnostic challenge of glucagonoma: case report and literature review. *Endocr Pract.* 2006;12(4):422–426.