

Original paper

The assessment of microcirculation architecture in keloids and hypertrophic scars: videocapillaroscopy

Magdalena Nastątek, Anna Wojas-Pelc

Department of Dermatology, Jagiellonian University Medical College, Krakow, Poland
Head: Prof. Anna Wojas-Pelc MD, PhD

Post Dermatol Alergol 2011; XXVIII, 6: 423–427

Abstract

Aim: The aim of the study was the evaluation *in vivo* of the differences between the microcirculatory characteristics of the scars (keloids and hypertrophic scars) and healthy skin.

Material and methods: Twenty three patients with keloids and twenty with hypertrophic scars were included in the study, evaluating fifty six scar areas and twenty healthy skin areas by means of contact optical probe videocapillaroscopy. Capillary density, length and capillary distribution pattern (punctiform, reticular, directional) together with the presence of microhemorrhages and neoangiogenesis were studied.

Results: Capillary length, capillary distribution pattern and presence of neoangiogenesis were found to be significantly increased in keloids and hypertrophic scars compared with controls. There were also significant differences between scars at the active stage and the ones in the atrophic phase as regards capillary length and the degree of neoangiogenesis.

Conclusions: Patients with keloids and hypertrophic scars showed in videocapillaroscopy a variety of microcirculatory changes, often clustered in a characteristic pattern of abnormally oriented, dilated capillaries and neoangiogenesis phenomena. This methodology is highly likely to be of value in the assessment and prognostication of keloids and hypertrophic scars outcome.

Key words: keloid, hypertrophic scar, capillaries, videocapillaroscopy, neoangiogenesis.

Introduction

Keloid, a specific type of human skin scar, is a benign, exuberant, autonomous growth of dense connective tissue, which formation represents an abnormal wound healing process. Despite the high prevalence in the general population (4-16%), keloidal scarring is one of the most challenging condition to be managed in dermatology. More than a cosmetic nuisance, keloids are severely symptomatic and can have a significant psychosocial burden for patients, decreasing their quality of life [1-3].

Keloid appears only in human skin, although corneal keloids were also described [4]. The feature may develop in the place of insignificant injury or may even occur spontaneously in genetically predisposed patients. Frequently keloids can be formed in inflammatory areas, especially in post acne lesions. For unknown reasons, keloids occur more frequently among black people and Asians, and rarely in Caucasians. They were not seen in albinos [5].

Clinically, keloids are firm irregular nodules, which can be erythematous and reddish-blue colored, extending beyond the original borders of the wound (Figure 1).

Contrary to the hypertrophic scars, keloids are predominantly symptomatic, experienced pruritus and burn, pain, reporting especially in the early phase of their formation. Additionally, keloids can grow even many months after scar developing, never outgoing spontaneously, and the treatment answer is usually poor [6, 7].

The pathogenesis of keloids is complex and not fully known. The disturbed balance between extracellular matrix (ECM) production and its catabolism, particularly increased proliferation of collagen and a lower rate of apoptosis in activated fibroblasts, seems to be crucial in keloids evolution [8]. Increased vascular density, microvascular obstruction, and malformed vessels have been described in keloids and hypertrophic scar tissues [9]. Local microcirculation modifications, referred to as angiogenesis, play a key role in the formation of keloids and hypertrophic scars. Angiogenesis is an essential process

Address for correspondence: Magdalena Nastątek MD, Department of Dermatology, Jagiellonian University Medical College, 8 Skawska, 31-066 Krakow, Poland, phone: +48 12 430 52 66 ext 74-00, e-mail: m.skucha@wp.pl

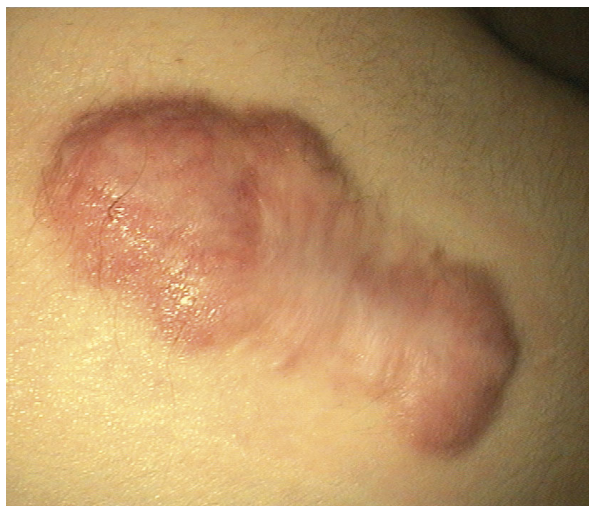

Fig. 1. Keloid (own material)

Table 1. Vancouver Scar Scale (VSS)

A. Vascularity	
0.	Normal
1.	Pink
2.	Red
3.	Purple
B. Pigmentation	
0.	Normal
1.	Hypopigmentation
2.	Mixed
3.	Hyperpigmentation
C. Pliability	
0.	Normal
1.	Supple
2.	Yielding
3.	Firm
4.	Ropes
5.	Contracture
D. Height	
0.	Flat
1.	< 2 mm
2.	2-5 mm
3.	> 5mm
Scale: 0-14	
0	Normal skin

in many physiological advances, such as development and tissue repairs as well as in disease states, including inflammatory diseases, where a modification of the local microcirculation architecture would depend on the degree of inflammation [10].

The diagnosis of the pathological scar type is mainly based on clinical evaluation and is seldom supported by histopathologic features. Traditional clinical rating, represented by the Vancouver Scar Scale (VSS) (Table 1) or the Patient and Observer Scar Assessment Scale, is limited by subjectivity [11]. In recent years, several objective diagnostic methods have been proposed: tissue ultrasound palpation system (TUPS), laser Doppler ultrasound monitors to check blood flow, photographic planimetry assisted by computer image analysis, assessment of pigmentation using a dermaspectrometer, pliability assessment by means of a pneumatometer and a durometer [12].

Videocapillaroscopy is a diagnostic tool that obtains a sensitive and specific assessment of scar evolution in time. It is a non-invasive and *in vivo* device for direct observation of the microcirculation architecture. Capillary microscopy is recognized as a diagnostic method and to monitor the course of skin diseases, such as connective tissue diseases, particularly systemic sclerosis [13], Raynaud's syndrome, dermatomyositis [14], primary antiphospholipid syndrome [15], as well as psoriasis [16] and lichen planus [17].

Aim

The aim of the study was the evaluation *in vivo* of the differences between the microcirculatory characteristics of the keloids together with hypertrophic scars and healthy skin controls using videocapillaroscopy.

Material and methods

We studied 43 patients (21 males (48.8%) and 22 females) so far untreated for the primary illness, recruited from the outpatient dermatology clinic, 23 patients with single or multiple keloids (mean age 33.3 years) and 20 patients with single or multiple hypertrophic scars (mean age 36.2 years) (Table 2). We evaluated 56 scar areas (31 keloids, 25 hypertrophic scars), where 77.4% were located on the trunk and the remaining 22.6% on the upper limbs (Table 2). More than 70% of patients demonstrated III skin phototype by Fitzpatrick. As controls we studied 20 healthy skin areas from a margin site patients treated for other cutaneous diseases in the Surgical Room in Dermatology Clinic UJ CM.

In all cases and controls, a representative area of 2 cm × 2 cm was chosen. Firstly, scars were evaluated with the VSS obtaining on average 9 points (range 4-17) for keloids, and 5 points (range 1-12) for hypertrophic scars (Table 2). Then, based on clinical evaluation and activity rank, particularly scar growth in the last 3 months,

Table 2. Clinical features of the study population

	Keloid (n = 31)	Hypertrophic scar (n = 25)	Control (n = 20)	Value of p
Age, median (IQR) [years]	33.3 (19-65)	36.2 (21-43)	35.4 (23-54)	NS
Males, n (%) (n = 21)	7 (30.4%)	14 (70%)	10 (50%)	NS
Females, n (%) (n = 22)	16 (69.6%)	6 (30%)	10 (50%)	
Scar age, median (IQR) [months]	12 (4-48)	28 (9-52)	0	0.03
Multiple scars, (< 2), n (%)	8 (25.8%)	5 (20%)	0	NS
VSS, median (IQR)	9 (4-14)	5 (1-11)	0	0.05

IQR – interquartile range, VSS (Vancouver Scar Scale): scale 0-14, $p < 0.05$ is considered statistically significant

Table 3. Capillaroscopic features of the study population

Scar stage	Active (n = 26)	Stationary (n = 19)	Atrophic (n = 11)	Control	Value of p
Capillary density, median (IQR) [no/mm ²]	44 (28-51)	19 (11-26)	12 (8-21)	8 (7-10)	< 0.01 0.04 < 0.01
Capillary length, median (IQR) [μm]	498.8 (271.1-756.9)	256.3 (222.3-345.8)	411.3 (288.3-497.5)	163.4 (138.2-266.5)	< 0.05
Capillary distribution pattern [%]					
Punctiform	7.7	15.8	9.1	75	< 0.01
Reticular	69.2	31.6	63.6	25	< 0.01
Directional	23.1	52.6	27.3	0	< 0.0001
Neovascularization (0-5), mean (SD)					
Vascular ramifications	4.05 (2.15)	2.29 (1.78)	2.6 (1.7)	0.39 (0.61)	< 0.01
Arboriform vessels	3.21 (1.56)	1.02 (0.29)	1.3 (0.6)	0.11 (0.33)	< 0.01
Microhemorrhage, mean (SD)	1.48 (1.65)	0.23 (0.34)	0.56 (0.87)	0.13 (0.28)	NS

IQR – interquartile range, SD – standard deviation, $p < 0.05$ is considered statistically significant

all scars were classified at stages: active – ACS (26 cases), atrophic – ATS (11 cases) and stationary – SS (19 cases) (Table 3).

Next the analysis of scars' microcirculation was performed using videocapillaroscopy (DermaScope Net Ver. 3.0, MediciMedical System, Castelfranco Emilia, Modena, Italy; magnification 300×). The videocapillaroscope was specifically calibrated. The investigation was always carried out by two operators and at least 3 photos for each examined area were stored.

The following parameters were used: capillary density (no/mm²); capillary length (μm); capillary distribution pattern (punctiform – Figure 2 A – presence of dilated capillaries with a pointed form; reticular – Figure 2 B – net-like distribution; directional – Figure 2 C – capillaries orientated along a single direction); microhemorrhages (0 – absent; 1 – 4 – from 1 to 4/mm²; 5 – 5 or more per square millimeter); neoangiogenesis (0 – absent; 1-4 – from 1/mm² to 4/mm²; 5 – 5 or more per square millimeter). The presence of “bush-like” capillaries pattern (arbori-

form vessels) or “deer horn-like” capillaries pattern (vascular ramifications) was the features that characterized neoangiogenesis at the videocapillaroscopy.

All values were obtained from average of all the observations for each examined area of the scar. The statistical significance of the differences between the scars (keloids and hypertrophic scars) and healthy controls was checked with Student's *t*-test for independent samples with regard to parametric data, with χ^2 test with regard to categorical data and with Mann-Whitney test for unpaired samples with regard to nonparametric data. The level of significance was set at $p < 0.05$. Data analysis was performed using SPSS 12.01 system.

Results

In the healthy skin from controls (C) typical comma shaped capillaries, with a punctiform or reticular pattern, and regular vessels and collagen fiber distribution were seen. No angiogenesis features were found. Despite sta-

tistically significant differences between scars and controls, no unique and specific microcirculatory pattern was detected.

Capillary density was significantly higher in active scars compared to stationary and atrophic scars (mean ACS 44/mm² vs. SS 12/mm², $p < 0.01$; vs. ATS 19/mm², $p < 0.01$) and controls (ACS 44/mm² vs. C 8/mm², $p < 0.01$; ATS 19/mm² vs. C 8/mm², $p < 0.01$) (Table 3).

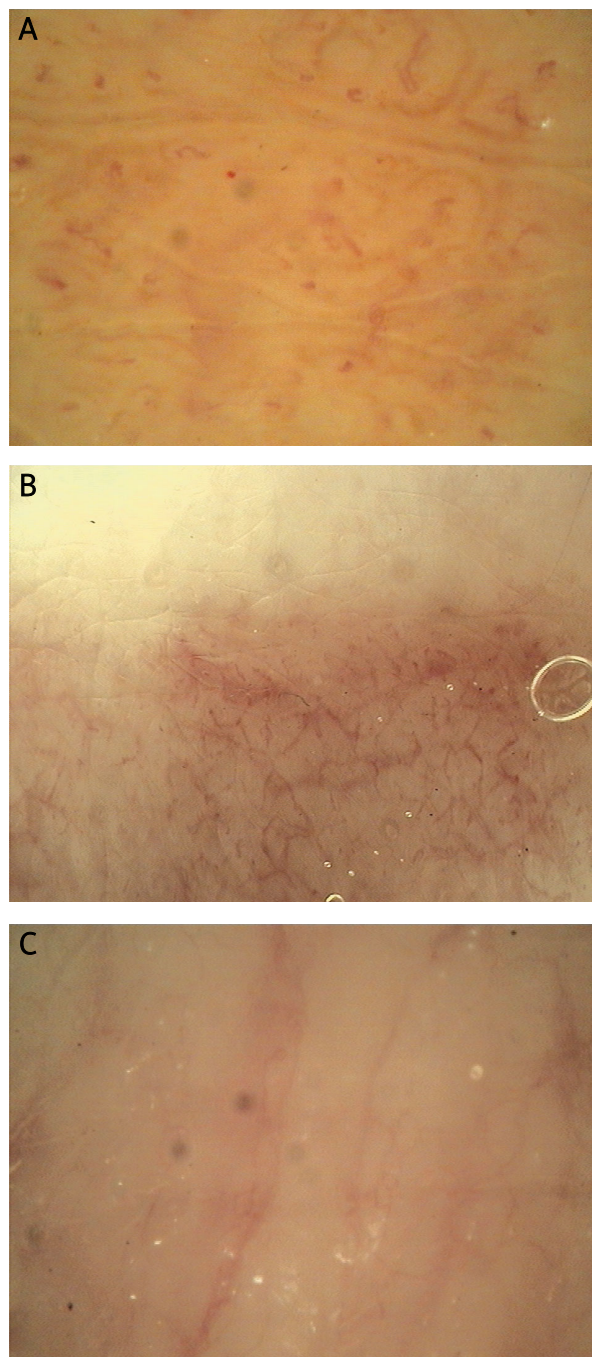


Fig. 2. Capillary distribution patterns: **A** – punctiform, **B** – reticular, **C** – directional

Concerning capillary length, significant p -value was found for all three scar types in comparison to controls, and the longest mean value was observed in active scars (ACS 498 μm vs. C 163.4 μm , $p < 0.05$) (Table 3). In active and atrophic scars, the reticular pattern was the commonest (ACS 69.2%; ATS 63.6%, respectively). Comparing to controls, the reticular pattern was significantly frequent in active scars ($p < 0.01$), while presence of the directional pattern in the studied population was specific of keloids and hypertrophic scars because it was not found in the control group ($p < 0.0001$) (Table 3).

Neoangiogenesis was significantly frequent expressed as arboriform capillaries (Figure 3 A) or as ramificated and tortuous loops (Figure 3 B) in patients with scars than in controls ($p < 0.01$) (Table 3). In the active phase of scarring (ACS), the process of angiogenesis was significantly increased compared to the atrophic stage (ATS) ($p < 0.01$) (Table 3).

Discussion

Keloids and hypertrophic scars appear as raised, red and stiff tumors. Because of high recurrence, systemati-

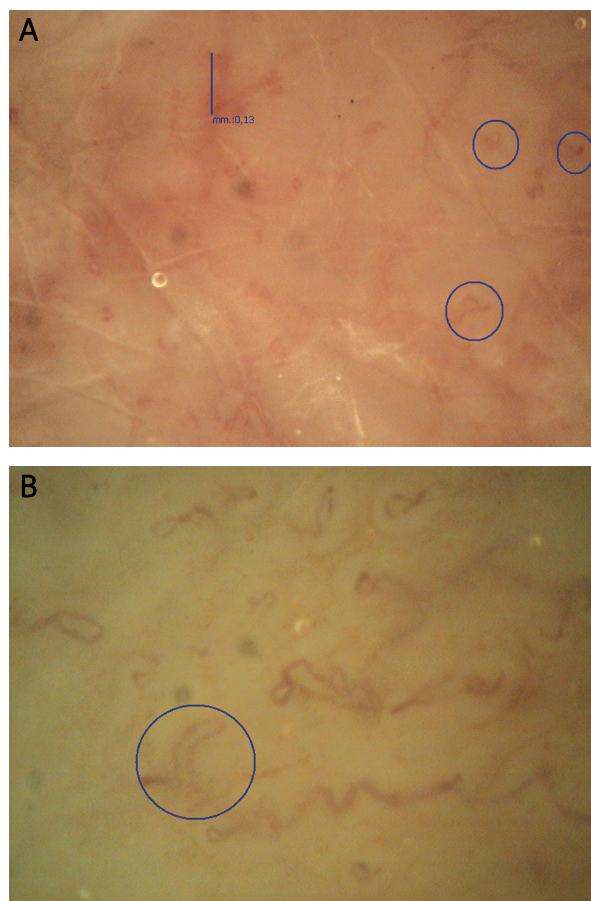


Fig. 3. Neoangiogenesis patterns: **A** – arboriform vessels, **B** – vascular ramifications

cal lesion increase, frequent adjunctive symptoms, keloids cause long disability [7].

The presence of prolonged inflammatory state in keloids and hypertrophic scars has been advocated as relevant to one of etiopathological hypotheses where damaged pile-glandular structure and excessive tumor growth factor β (TGF- β) production through crucial skin immune system cells, lymphocytes T, are responsible for the maintenance of a continuous inflammatory state [18, 19]. On histologic examination, keloids are found to have not only increased deposits of collagen bundles but also large number of microcapillaries. Due to immoderate proliferation of endothelium and increased vascular endothelial growth factor (VEGF) expression, which is a major player in wound healing angiogenesis, more capillaries in keloids are crushed with dilated, partly or fully closed light [20]. The presence of closed microcapillaries may be responsible for tissue ischemic status appearing in the injury area and may promote pathological scar evolution [21]. The microcirculatory changes occurring in keloids might be related to ischemic events due either to rheological disturbances or to perivascular leukocyte infiltration of small- or medium-sized tributary vessels. Therefore, neoangiogenesis is an attempt to compensate for the defective nutritional circulation, manifested as giant capillaries, vascular ramifications and tortuosity. The capillary proliferation may stretch the nervous fibers altering local sensitivity, with the itchiness, pain, burn and dysesthesia as the consequences.

The scar scales used in clinical settings for a long time, are not an objective tool. Also in our study, VSS was not able to clearly assess the maturity of the scars (Table 2). The videocapillaroscopy technique allows for *in vivo* examination of morphological and functional changes of microcirculation in a totally non-traumatic, non-invasive and immediate way. From this point of view, videocapillaroscopy might become a very useful diagnostic tool and allows for monitoring the course of keloids and hypertrophic scars. Videocapillaroscopy confirms the presence of a specific capillary pattern, the increased capillary density and length, and neoangiogenesis in scars, especially in ASC, compared with controls (Table 3).

What is more, this technique has permitted to identify two parameters, such as the capillary length and degree of neoangiogenesis as crucial for the definition of scars evolution from the active to the atrophic stage. This method can be helpful to check the effectiveness of the selected therapeutic protocol. Symptoms decrease could be directly associated with parallel reduction of neoangiogenesis in videocapillaroscopy examination.

Our study should be considered as a novel and preliminary work confirming that videocapillaroscopy constitutes a new option of microcirculatory evaluation in patients with keloids and hypertrophic scars, although further future studies are required to optimize this method.

References

- Braun Falco O, Plewing G, Wolff HH, et al. *Dermatologia Czelej, Lublin* 2004; 1464.
- Robles DT, Berg D. Abnormal wound healing: keloids. *Clin Dermatol* 2007; 25: 26-32.
- Marneros AG, Krieg T. Keloids: clinical diagnosis, pathogenesis, and treatment options. *J Dtsch Dermatol Ges* 2004; 2: 905-13.
- Jung JJ, Wojno TH, Grossniklaus HE. Giant corneal keloid: case report and review of the literature. *Cornea* 2010; 29: 1455-8.
- Shah SK, Alexis AF. Acne in skin of color: practical approaches to treatment. *J Dermatol Treat* 2010; 21: 206-11.
- Seifert O, Mrowietz U. Keloid scarring: bench and bedside. *Arch Dermatol Res* 2009; 301: 259-72.
- Brudnik U, Podolec-Rubiś M, Wojas-Pelc A. Therapeutic problems connected with keloid treatment: new treatment possibilities. *Przegl Lek* 2000; 63: 803-6.
- Bran GM, Goessler UR, Hormann K, et al. Keloids: current concepts of pathogenesis. *Int J Mol Med* 2009; 24: 283-93.
- Kim Gira A, Brown LF, Washington CV, et al. Keloids demonstrate high-level epidermal expression of vascular endothelial growth factor. *J Am Acad Dermatol* 2005; 53: 1097-9.
- Kischer CW. The microvessels in hypertrophic scars, keloids and related lesions: a review. *J Submicrosc Cytol Pathol* 1992; 24: 281-96.
- Draaijers LJ, Tempelman FR, Botman YA, et al. The patient and observer scar assessment scale: a reliable and feasible tool for scar evaluation. *Plast Reconstr Surg* 2004; 113: 1960-7.
- Perry DM, McGrouther DA, Bayat A. Current tools for non-invasive objective assessment of skin scars. *Plast Reconstr Surg* 2010; 126: 912-23.
- Ohtsuka T, Hasegawa A, Nakano A, et al. Nailfold capillary abnormality and pulmonary hypertension in systemic sclerosis. *Int J Dermatol* 1997; 36: 116-22.
- Mariq HR, Spencer-Green G, LeRoy EC. Skin capillary abnormalities as indicators of organ involvement in scleroderma (systemic sclerosis). Raynaud's syndrome and dermatomyositis. *Am J Med* 1976; 61: 862-70.
- Vaz JLP, Dancour MAA, Bottino DA, et al. Nailfold videocapillaroscopy in primary antiphospholipid syndrome (PAPS). *Rheumatology* 2004; 43: 1025-7.
- Zaric D, Clemmensen OJ, Worm AM, et al. Capillary microscopy of the nailfold in patients with psoriasis and psoriatic arthritis. *Dermatologica* 1982; 164: 10-4.
- Scardina GA, Picone V, Cacioppo A, et al. Study of microcirculation in oral lichen planus by video-capillaroscopy. *Oral Surg Oral Med Oral Pathol Oral Radiol Endod* 2007; 103: e30-4.
- Castagnoli C, Trombotto C, Ondei S, et al. Characterization of T-cell subsets infiltrating post-burn hypertrophic scar tissues. *Burns* 1997; 28: 565-72.
- Tsujita-Kyutoku M, Uehara N, Matsuoka Y. Comparison of transforming growth factor-beta/ Smad signaling between normal dermal fibroblasts and fibroblasts derived from central and peripheral areas of keloid lesions. *In Vivo* 2005; 19: 959-63.
- Ong CT, Khoo YT, Tan EK. Epithelial-mesenchymal interaction in keloid pathogenesis modulate vascular endothelial growth factor expression and secretion. *Pathology* 2007; 211: 95-108.
- Steinbrech DS, Mehrara BJ. Hypoxia upregulates VEGF production in keloid fibroblasts. *Ann Plast Surg* 1999; 42: 514-9.