



Thomas Jefferson University
Jefferson Digital Commons

Department of Radiation Oncology Faculty
Papers

Department of Radiation Oncology

8-21-2020

Dosimetric differences between cesium-131 and iodine-125 brachytherapy for the treatment of resected brain metastases


Menachem Yondorf
Thomas Jefferson University

Shahdabul Faraz
Weill Medical College of Cornell University

Andrew Smith
University of Rochester School of Medicine and Dentistry

Albert Sabbas
Weill Medical College of Cornell University

Bhupesh Parashar
Follow this and additional works at: <https://jdc.jefferson.edu/radoncfp>
Weill Medical College of Cornell University

 Part of the [Oncology Commons](#), and the [Radiation Medicine Commons](#)

[Let us know how access to this document benefits you](#)

See next page for additional authors

Recommended Citation

Yondorf, Menachem; Faraz, Shahdabul; Smith, Andrew; Sabbas, Albert; Parashar, Bhupesh; Schwartz, Theodore; and Wernicke, Gabriella, "Dosimetric differences between cesium-131 and iodine-125 brachytherapy for the treatment of resected brain metastases" (2020). *Department of Radiation Oncology Faculty Papers*. Paper 138.
<https://jdc.jefferson.edu/radoncfp/138>

This Article is brought to you for free and open access by the Jefferson Digital Commons. The Jefferson Digital Commons is a service of Thomas Jefferson University's [Center for Teaching and Learning \(CTL\)](#). The Commons is a showcase for Jefferson books and journals, peer-reviewed scholarly publications, unique historical collections from the University archives, and teaching tools. The Jefferson Digital Commons allows researchers and interested readers anywhere in the world to learn about and keep up to date with Jefferson scholarship. This article has been accepted for inclusion in Department of Radiation Oncology Faculty Papers by an authorized administrator of the Jefferson Digital Commons. For more information, please contact: JeffersonDigitalCommons@jefferson.edu.

Authors

Menachem Yondorf, Shahdabul Faraz, Andrew Smith, Albert Sabbas, Bhupesh Parashar, Theodore Schwartz, and Gabriella Wernicke

Dosimetric differences between cesium-131 and iodine-125 brachytherapy for the treatment of resected brain metastases

Menachem Z. Yondorf, BA^{1,2}, Shahdabul Faraz, BS¹, Andrew W. Smith, BA³, Albert Sabbas, PhD¹, Bhupesh Parashar, MD¹, Theodore H. Schwartz, MD⁴, A. Gabriella Wernicke, MD, MSc^{1,4}

¹Department of Radiation Oncology, Weill Medical College of Cornell University, New York, USA, ²Department of Radiation Oncology,

Thomas Jefferson University Hospital, Philadelphia, USA, ³University of Rochester School of Medicine and Dentistry, Rochester, New York, USA,

⁴Department of Neurosurgery, Weill Medical College of Cornell University, New York, NY, USA

Abstract

Purpose: To compare treatment plans and evaluate dosimetric characteristics of permanent cesium-131 (¹³¹Cs) vs. iodine-125 (¹²⁵I) implants used in brain brachytherapy.

Material and methods: Twenty-four patients with ¹³¹Cs implants from a prospective phase I/II trial were re-planned with ¹²⁵I implants. In order to evaluate the volume of brain tissue exposed to radiation therapy (RT), the dose volume histogram was generated for both radioisotopes. To evaluate the dosimetric differences of the two radioisotopes we compared homogeneity (HI) and conformity indices (CI), and dose covering 100% (D₁₀₀), 90% (D₉₀), 80% (D₈₀), and 50% (D₅₀) of the clinical target volume (CTV).

Results: At the 100%, 90%, 80%, and 50% isodose lines, the ¹³¹Cs plans exposed less mean volume of brain tissue than the ¹²⁵I plans ($p < 0.001$). The D₁₀₀, D₉₀, D₈₀, and D₅₀ were smaller for ¹³¹Cs ($p < 0.001$). The HI and CI for ¹³¹Cs vs. ¹²⁵I were 19.71 vs. 29.04 and 1.31 vs. 1.92, respectively ($p < 0.001$).

Conclusions: Compared to ¹²⁵I, ¹³¹Cs exposed smaller volumes of brain tissue to equivalent doses of radiation and delivered lower radiation doses to equivalent volumes of the CTV. ¹³¹Cs exhibited a higher HI, indicating increased uniformity of doses within the CTV. Lastly, ¹³¹Cs presented a CI closer to 1, indicating that the total volume receiving the prescription dose was closer to the desired CTV volume. These results suggest that ¹³¹Cs is dosimetrically superior to ¹²⁵I and may explain the reason for the 0% incidence of radiation necrosis (RN) in our previously published prospective study using ¹³¹Cs.

J Contemp Brachytherapy 2020; 12, 4: 311-316

DOI: <https://doi.org/10.5114/jcb.2020.98109>

Key words: cesium-131 (¹³¹Cs), iodine-125 (¹²⁵I), brachytherapy, metastases, recurrence, radiation necrosis.

Purpose

Over the last decade, the rise in the length of survival for cancer patients has led to an increased incidence of brain metastases. Brain metastases have now been shown to occur in up to 40% of cancer patients and are the most common cause of intracranial tumors [1]. Without treatment, the prognosis is grim, with survival of only 1-2 months [2]. Surgical resection of the metastases has been shown to increase overall survival [3]. Resection, however, often requires adjuvant irradiation in the form of stereotactic radiosurgery (SRS) or whole-brain radiotherapy (WBRT) in order to prevent local recurrence. Due to WBRT's quality of life concerns, its late toxicity profile and the fact that it offers no overall survival benefit compared to more local therapy, recent focus has shifted

towards the potential of local post-resection options, such as SRS and intra-operative brachytherapy [4,5,6,7]. Brachytherapy, in particular, has received considerable interest as it offers some advantages even over SRS, namely its absence of a long-time frame that can allow tumor cell repopulation [4,8]. A recent study that our group has published has shown that surgical resection and intra-operative brachytherapy is more cost-effective compared to surgical resection and SRS in the treatment of brain metastasis [9]. Additionally, it is known that SRS does not achieve optimal local control for large (greater > 3 cm) and irregularly-shaped cavities [9].

Intra-operative brachytherapy implants have been utilized for the prevention of local recurrence in cases of brain metastases. Brachytherapy has historically utilized the iodine-125 (¹²⁵I) radioisotope for both permanent and

Address for correspondence: A. Gabriella Wernicke, Assoc. Prof. of Clinical Radiation Oncology, Weill Medical College of Cornell University, 1300 York Avenue, NY 10065, USA, phone: +1 212-746-3641, +1 212-746-8749, ✉ e-mail: gaw9008@med.cornell.edu

Received: 15.08.2017

Accepted: 29.06.2020

Published: 21.08.2020

temporary seed implants [10]. The commonly used radioisotope ^{125}I has a $T_{1/2}$ of 59.4 days and has an average energy of 28.4 keV. These physical properties make ^{125}I convenient for storage, with limited shielding. The clinical results have revealed that although ^{125}I has been shown to confer local control comparable to that of post-operative SRS, the high rates of radiation necrosis (RN) associated with ^{125}I brachytherapy have been criticized [11].

Cesium-131 (^{131}Cs) is a relatively novel radioisotope, the Food and Drug Administration cleared in 2003, which presents both physical and radio-biological advantages when compared to ^{125}I brachytherapy. ^{131}Cs has a shorter $T_{1/2}$ of 9.69 days compared to 59.4 days for ^{125}I . ^{131}Cs is more likely to be biologically efficient for the destruction of tumor cells, as the initial dose rate from ^{131}Cs (23.9 cGy/h) is 4 times higher than that of ^{125}I (5.8 cGy/h) [9,10]. Our institution was the first to report the results of a prospective phase I/II trial demonstrating the effective use of intra-operative application of ^{131}Cs brachytherapy for patients with newly diagnosed brain metastases [4]. In that study, we reported a 0% incidence of clinical RN. This contrasts with the results reported by many studies that used permanent ^{125}I seeds, which has been associated with an average RN rate of 14.4% (range, 0-26%) [12]. In the present study, we investigated the dosimetric profile of ^{131}Cs brachytherapy compared to that of ^{125}I in order to understand this disparity in RN rates.

Material and methods

Patient characteristics

There were 24 patients in total, 14 females and 10 males, with a median age of 65 years (range, 45-84 years). The brain metastases were located in the frontal (10), parietal (7), cerebellar (4), occipital (2), and temporal (1) regions. The histology from the metastases was lung (16), breast (2), kidney (2), melanoma (2), colon (1), and cervix (1).

Implantation procedure

Between 2010 and 2015, following Institutional Review Board approval, 24 patients were enrolled on a prospective trial at the New York Presbyterian/Weill Cornell Medical Center, and underwent neurosurgical resection and intra-operative ^{131}Cs brachytherapy for newly diagnosed brain metastases. The metastases were detected in each patient using a magnetic resonance imaging (MRI) or computerized tomography (CT) scan. As described previously [4], directly after resection, ^{131}Cs stranded seeds (IsoRay, Inc., Richland, WA, USA) with an activity of 3-5 mCi were implanted, with a planned dose of 80 Gy to a 5 mm depth from the surface of the resection cavity. At the time of resection, the seeds were secured with Surgicel® (Ethicon, Inc., a Johnson & Johnson Company, Somerville, NJ, USA) to prevent seed migration and alteration of dosimetry. Lastly, Tisseel® (Baxter International, Inc., Deerfield, IL, USA), a fibrin glue, was also placed within the cavity to limit cavity shrinkage and further prevent seed dislodgement. Post-operative CT scans (GE LightSpeed averaging 36.85 mGy) were performed within 48 hours after surgery to determine dose distribution.

Follow-up physical evaluation and MRIs were performed every 2 months thereafter. For the simulated ^{125}I isotope implants, the prescribed dose was 80 Gy as well. The exact implant scheme for ^{131}Cs was used for the simulated ^{125}I cases. Finally, RN was detected on follow-up MRIs and confirmed by a combination of clinical judgement and further imaging including perfusion, spectroscopy, and positron emission tomography (PET) scans.

Dosimetric comparison of ^{131}Cs vs. ^{125}I

Dosimetric comparison was carried out for all included 24 patients. Post-operative dosimetry plans were generated using BrachyVision (Varian Medical Systems, Palo Alto, CA, USA) for ^{131}Cs seed model ^{131}Cs Rev 2, and the same CT data set was re-planned with ^{125}I seeds using model No 6711 (TG43). The mean air kerma strength for the ^{131}Cs and ^{125}I seeds was 2.4 U (3.768 mCi) and 0.6985 U (0.55 mCi), respectively. The dose volume histogram (DVH) was generated and from it, the volume of brain tissue (cc) exposed to radiation at the 100%, 90%, 80%, and 50% isodose lines were compared for both radioisotopes. From the DVH, the D_{100} , D_{90} , D_{80} , and D_{50} were obtained as well. Lastly, the homogeneity and conformity indices were calculated for each individual patient. The equations used for HI and CI were as follows:

$$\text{HI} = D_{100} - D_{150}/D_{100}$$

where D_{100} - volume enclosed by prescribed dose rate and D_{150} - volume enclosed by 1.5 times prescribed dose rate.

$$\text{CI} = \text{TV}/\text{CTV},$$

where TV - total volume receiving prescription dose and CTV equals clinical target volume.

The different mean values between ^{131}Cs and ^{125}I were compared using the Wilcoxon rank-sum test.

Results

Dosimetric comparison of ^{131}Cs vs. ^{125}I

The median volume of resected tumor based on pre-operative MRI was 10.31 cc (range, 1.77-87.11 cc), intra-operative measurements of the cavity revealed a median volume of 3.13 cc (range, 1.00-17.00 cc), and median number of seeds employed was 12 (range, 4-35 seeds). The clinical data from these patients resulted in 100% local control, with median overall survival of 9.9 months, and 0% incidence of RN. Table 1 shows the mean volume of brain tissue exposed to radiation for each of the four isodose lines from both ^{131}Cs and ^{125}I . At the 100% isodose line, the mean volume of brain tissue exposed was 15.44 cc (range, 2.50-52.78 cc) and 9.84 cc (range, 1.22-32.87 cc) for ^{125}I and ^{131}Cs , respectively ($p < 0.001$). At the 90% isodose line, the mean volume exposed was 17.51 cc (range, 2.90-59.05 cc) and 11.31 cc (range, 1.47-37.59 cc) for ^{125}I and ^{131}Cs , respectively ($p < 0.001$). At the 80% isodose line, the mean volume exposed was 19.96 cc (range, 3.30-67.20 cc) and 13.61 cc (range, 1.73-43.4 cc) for ^{125}I and ^{131}Cs , respectively ($p < 0.001$). At the 50% isodose line,

the mean volume exposed was 33.40 cc (range, 6.30-109.70 cc) and 23.38 cc (range, 3.39-76.14 cc) for ¹²⁵I and ¹³¹Cs, respectively ($p < 0.001$). Consistently, for each isodose line, the mean volume of brain tissue exposed to radiation was significantly higher (on average, 52.0% higher) for ¹²⁵I than for ¹³¹Cs. Figure 1 displays three isodose lines for both ¹²⁵I and ¹³¹Cs seeds and superimposes them, allowing the clear visualization of the contrasting volumes of brain tissue exposed to radiation.

As Table 2 shows, the D₁₀₀ was 64.96 Gy (range, 46.46-10.90 Gy) and 43.99 Gy (range, 26.19-74.09 Gy) for ¹²⁵I and ¹³¹Cs, respectively ($p < 0.001$). The D₉₀ was 119.02 Gy (range, 73.44-174.36 Gy) and 78.64 Gy (range, 40.31-136.36 Gy) for ¹²⁵I and ¹³¹Cs, respectively ($p < 0.001$).

Table 1. Mean volume of brain tissue exposed to radiation doses at different isodose lines by ¹³¹Cs and ¹²⁵I isotopes

| Isodose line | Mean volume of brain tissue (cc) ¹³¹ Cs | Mean volume of brain tissue (cc) ¹²⁵ I | p-value |
|--------------|--|---|---------|
| 100% | 9.84 | 15.44 | < 0.001 |
| 90% | 11.31 | 17.51 | < 0.001 |
| 80% | 13.61 | 19.96 | < 0.001 |
| 50% | 23.38 | 33.40 | < 0.001 |

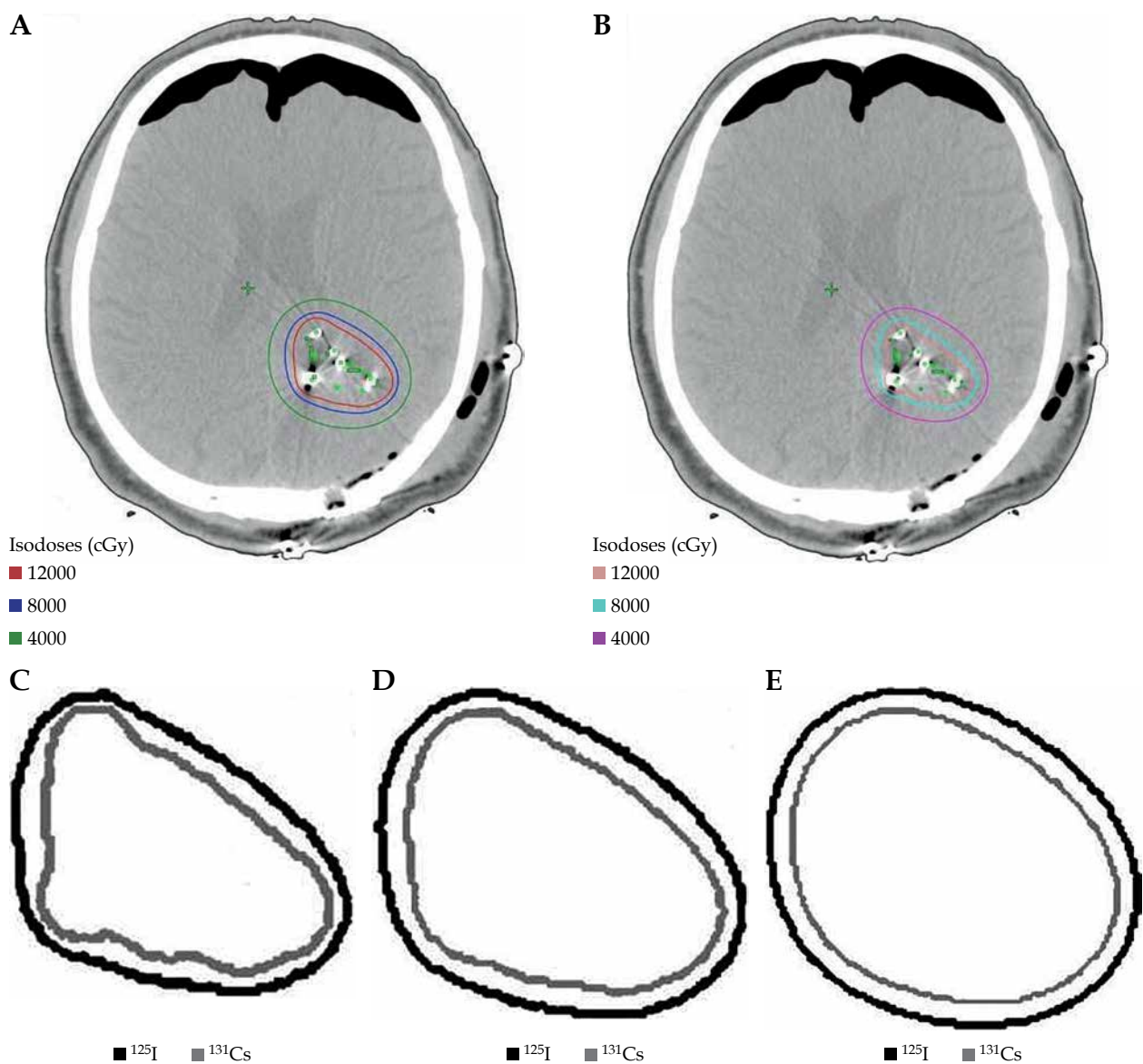


Fig. 1. Axial images of a patient who underwent neurosurgical resection and intra-operative brachytherapy demonstrating volume of brain tissue exposed to radiation across multiple isodose lines for each radioisotope and superimposed comparison between ¹³¹Cs and ¹²⁵I isodose lines: A) plan using ¹²⁵I, B) plan using ¹³¹Cs, C) 120 Gy isodose line, D) 80 Gy isodose line, E) 40 Gy isodose line

Table 2. Absolute doses of radiation delivered to certain percent volume of CTV by ^{131}Cs and ^{125}I isotopes

| Percent volume of CTV | Dose of radiation (Gy) ^{131}Cs | Dose of radiation (Gy) ^{125}I | <i>p</i> -value |
|-----------------------|--|---|-----------------|
| 100% (D_{100}) | 43.99 | 64.96 | < 0.001 |
| 90% (D_{90}) | 78.64 | 119.02 | < 0.001 |
| 80% (D_{80}) | 93.09 | 141.78 | < 0.001 |
| 50% (D_{50}) | 134.79 | 206.17 | < 0.001 |

Table 3. Comparison of homogeneity and conformity indices for ^{131}Cs and ^{125}I

| Index | ^{131}Cs | ^{125}I | <i>p</i> -value |
|-------------------|-------------------|------------------|-----------------|
| Homogeneity index | 0.315 | 0.113 | < 0.001 |
| Conformity index | 1.31 | 1.92 | < 0.001 |

The D_{80} was 141.78 Gy (range, 84.02-203.02 Gy) and 93.09 Gy (range, 45.80-161.16 Gy) for ^{125}I and ^{131}Cs , respectively ($p < 0.001$). The D_{50} was 206.17 Gy (range, 113.69-289.32 Gy) and 134.79 Gy (range, 61.85-228.86 Gy) for ^{125}I and ^{131}Cs , respectively ($p < 0.001$). At each percent volume of the CTV, the dose delivered by ^{125}I was significantly higher (on average, 51.0% higher) than for ^{131}Cs .

The HI with respect to ^{131}Cs and ^{125}I were 0.312 (range, 0.15-0.50) and 0.113 (range, 0-0.34), respectively ($p < 0.001$). The CI for ^{131}Cs and ^{125}I were 1.31 (range, 0.71-4.12) and 1.92 (range, 0.90-3.92), respectively ($p < 0.001$). These results are summarized in Table 3.

Discussion

The use of permanent brachytherapy seed implants for the treatment of brain metastases is advantageous, since it can provide a treatment to a highly localized area. This benefit allows the physician to precisely target a defined treatment volume and to avoid the surrounding tissues from potential damage. Permanent brachytherapy offers several more advantages compared to WBRT and SRS. The use of post-operative SRS may require a timeframe of 2-6 weeks after surgical resection in order to facilitate wound healing and stabilization of the cavity [4]. This delay in treatment may facilitate tumor cell repopulation. Similarly, concerns regarding the non-localized nature of WBRT and its toxicity profile have likely contributed to the modest decrease in WBRT use. For instance, WBRT's acute toxicity profile includes fatigue, edema, nausea, vomiting, and decreased appetite [13]. While these acute effects are typically resolved spontaneously or can be effectively treated, the late toxic effects of WBRT are potentially more dangerous. This includes potentially irreversible neurocognitive damage, leukoencephalopathy, and radiation necrosis [12]. Permanent brachytherapy also offers a quality of life benefit that must be considered. Both the tumor resection and subsequent seed implantation occurs during one procedure,

which is likely to increase patient satisfaction and convenience. These reasons, along with its cost benefits, provide justification for the increased interest in permanent brachytherapy. Given this context, we believe our results have a widespread applicability and may inform future clinical decisions.

There have been several studies reported in the literature employing the use of brachytherapy seeds for the treatment of brain metastases in the post-resection setting. Several studies have focused on the use of temporary ^{125}I seeds, which allow for high-dose-rate delivery; however, many of these studies were performed after biopsy alone, and patients did not receive maximal possible resection. The more recent studies have used permanent brachytherapy seeds, of which the majority of them employed ^{125}I . Unfortunately, most of these studies are retrospective in nature, and therefore encompass a diverse patient cohort and may be influenced by selection bias. Furthermore, these studies often include patients with both newly diagnosed brain metastases and those with recurrences. Taking these factors into account, the reported median survival for the treatment of newly diagnosed brain metastases ranges from 9.3-17.8 months and is associated with local control rates of 60-100%, with radiation necrosis rates of 0-26% [11]. These data compare favorably to surgical resection plus SRS in terms of both the median survival of 14 months as well as the local control rates of 85% [14].

The main criticism against the widespread adaptation of brachytherapy for the treatment of brain metastases is the high incidence of RN that has historically been associated with this technique [9]. Rogers *et al.* reported 23% rate of radiation necrosis when using high-dose temporary brachytherapy, such as the IsoRay Gliasite balloon [15]. Using continuous low-dose permanent ^{125}I brachytherapy, Bogart *et al.* reported 0% rates of radiation necrosis, yet only achieved 80% rate of local control [16]. Alternatively, Huang *et al.* reported 26% rate of radiation necrosis, also using permanent ^{125}I brachytherapy, while achieving 95% local control rate [12]. The disparity in results between these two series can be understood if attention is given to the activity and dose prescribed in each case. Bogart *et al.* employed seeds with activity of 0.32-0.45 mCi and a cumulative dose of 80-160 Gy [15], while Huang *et al.* implanted seeds with a median activity of 0.79 mCi and delivered a median dose of 400 Gy to a depth of 5 mm [12]. Based on these data, Huang *et al.* concluded that decreasing both the seed activity as well as the prescription dose will likely result in a decrease of RN, while minimally impacting local control rates. The prospective trial for ^{131}Cs was carefully designed to take into account the aforementioned factors in an attempt to limit the incidence of RN while maintaining local control. The lowered seed activity of ^{131}Cs and our utilized dose prescription not only achieved a high-rate of local control (100%), but also resulted in zero incidences of RN [8].

In addition to the study design that was used when employing ^{131}Cs , the physical characteristic of creating more lower dose gradient isodose lines to the source has likely contributed to its success. In this analysis, we have shown that even when using the same prescription dose

parameters as ¹³¹Cs, ¹²⁵I allows for significantly higher amount of brain tissue being exposed to radiation. Apart from irradiating lower volumes of brain tissue, ¹³¹Cs also delivers significantly lower doses to equivalent volumes of CTV when compared to ¹²⁵I. Additionally, the higher HI of ¹³¹Cs indicated more uniform dosing within the CTV. Lastly, the CI of ¹³¹Cs was closer to 1, indicating that the prescription dose was delivered more accurately to the desired volume of CTV. With ¹²⁵I, not only was there less uniformity of dosing within the CTV, but the total volume receiving the prescription dose was also nearly double the desired volume of CTV. We believe that these factors may be particularly pertinent when looking at RN as an endpoint. Dagnew *et al.* stated that in their study, both patients who presented with symptomatic RN had lesions that exceeded 3 cm in diameter [11]. Due to the size of their lesions, a greater number of seeds were required to cover the cavity, resulting in a total radiation activity greater than 40 mCi. These results suggest a dose-dependent risk of RN. More recently, Petr *et al.* reported 6% incidence of RN while using permanent ¹²⁵I brachytherapy seeds in the setting of post-resected brain metastases [17]. It was noted that the patients in the study had relatively large metastases, and specifically all the patients that developed RN had lesions larger than 3 cm. Therefore, when compared to ¹²⁵I, ¹³¹Cs limits the surrounding brain tissue from additional radiation, restricts dose delivery within the CTV, provides more uniform dosing within CTV, and accurately targets the desired area. These factors, in turn, may contribute to minimizing the incidences of RN. These characteristic of ¹³¹Cs probable allow it to be utilized even when dealing with cavities > 3 cm.

Some studies have demonstrated an improved control with dose escalation [18,19,20], particularly in tumors receiving an equivalent dose in 2 Gy fractions (EQD₂) > 35 Gy ($\alpha/\beta = 10$) or biological effective dose using an $\alpha/\beta = 12$ (BED 12) > 40 Gy (linear quadratic cubic model). There are newer prospective reports of using GammaTile (a ¹³¹Cs radioisotope embedded into collagen), which utilizes very high doses of radiation, similar to our studies. The doses of 80 Gy prescribed to 5 mm depth are extracted from the use of ¹³¹Cs in the prostate. Dose escalation in brain metastases and primary brain tumors appear promising in the radiation literature. We have utilized a conversion from dose from low-dose-rate to high-dose-rate, using a dose factor of 0.54 [21].

It must be noted that dosimetric superiority may not always translate into better clinical outcomes. Prospective studies, comparing the long-term clinical outcomes of ¹³¹Cs and ¹²⁵I, need to be performed to elucidate this point. Despite this, our RN levels of 0% with ¹³¹Cs are very encouraging and may provide a glimpse into its potential long-term clinical benefits compared to ¹²⁵I. It must also be noted that RN is a multifactorial complication and likely depends not only on the inherent dosimetric characteristics of the radioisotope, but also on study-specific factors, such as the prescribed dose levels, seed activity levels, etc. It should also be mentioned, that because the strength and position of the ¹²⁵I sources were not optimized, it could contribute to the quality of its dosimetry.

Another feature that impacts the incidence of RN is the length of time, over which the seed can deliver its intended dose as well as the dynamics of the cavity during that time. It was recently reported that the cavity size is not significantly reduced in size during the 33-day period, during which ¹³¹Cs delivers 90% of its intended dose [22,23]. However, when dealing with an isotope, such as ¹²⁵I, which takes 120 days to deliver the equivalent dose, a cavity may undergo significant shrinkage. When the cavity does undergo shrinkage, this means that the prescription dose is being delivered to a larger volume of surrounding tissue over time rather than the intended CTV volume. We believe that this fact may also contribute to the increased incidence of RN, when employing ¹²⁵I compared to ¹³¹Cs.

Conclusions

In this study, we report that ¹³¹Cs permanent brachytherapy for the treatment of brain metastases exposes lower volumes of brain tissue to radiation, provides more uniform dosing within CTV, and targets the desired CTV volume more accurately, when compared to ¹²⁵I. These findings coupled with advantageous physical characteristics of ¹³¹Cs, namely a shorter T_{1/2}, shorter time of dose delivery, minimal volume of cavity shrinkage, and more compact dose distribution, provide a dosimetric superiority to ¹²⁵I. The results of this analysis may provide a rationale for the 0% incidence of RN, when treated with maximally safe neurosurgical resection and intra-operative ¹³¹Cs implantation in patients with newly resected brain metastases.

Disclosure

The authors report no conflict of interest.

References

1. Bradley KA, Mehta MP. Management of brain metastases. *Semin Oncol* 2004; 31: 693-701.
2. Lang EF, Slater J. Metastatic brain tumors. Results of surgical and nonsurgical treatment. *Surg Clin North Am* 1964; 44: 865-872.
3. Patchell RA, Tibbs PA, Walsh JW *et al.* A randomized trial of surgery in the treatment of single metastases to the brain. *N Engl J Med* 1990; 322: 494-500.
4. Wernicke AG, Yondorf MZ, Peng L *et al.* Phase I/II study of neurosurgical resection and intra-operative Cesium-131 radio-isotope brachytherapy in patients with newly diagnosed brain metastases. *J Neurosurg* 2014; 121: 338-348.
5. Nieder C, Schwerdtfeger K, Steudel WI *et al.* Patterns of relapse and late toxicity after resection and whole-brain radiotherapy for solitary brain metastases. *Strahlenther Onkol* 1998; 174: 275-278.
6. Chow E, Davis L, Holden L *et al.* Prospective assessment of patient-rated symptoms following whole brain radiotherapy for brain metastases. *J Pain Symptom Manage* 2005; 30: 18-23.
7. Aoyama H, Shirato H, Tago M *et al.* Stereotactic radiosurgery plus whole-brain radiation therapy vs stereotactic radiosurgery alone for treatment of brain metastases: a randomized controlled trial. *JAMA* 2006; 295: 2483-2491.
8. Suwinski R, Sowa A, Rutkowski T *et al.* Time factor in post-operative radiotherapy: a multivariate locoregional control

- analysis in 868 patients. *Int J Radiat Oncol Biol Phys* 2003; 56: 399-412.
9. Wernicke AG, Yondorf MZ, Parashar B et al. The cost-effectiveness of surgical resection and cesium-131 intraoperative brachytherapy versus surgical resection and stereotactic radiosurgery in the treatment of metastatic brain tumors. *J Neurooncol* 2016; 127: 145-153.
 10. Gutin PH, Phillips TL, Wara WM et al. Brachytherapy of recurrent malignant brain tumors with removable high-activity iodine-125 sources. *J Neurosurg* 1984; 60: 61-68.
 11. Dagnew E, Kanski J, McDermott MW et al. Management of newly diagnosed single brain metastasis using resection and permanent iodine-125 seeds without initial whole-brain radiotherapy: a two institution experience. *Neurosurg Focus* 2007; 22: E3.
 12. Huang K, Sneed PK, Kunwar S et al. Surgical resection and permanent iodine-125 brachytherapy for brain metastases. *J Neurooncol* 2009; 91: 83-93.
 13. McTyre E, Scott J, Chinaiyan P. Whole brain radiotherapy for brain metastasis. *Surg Neurol Int* 2013; 4 (Suppl 4): S236-244.
 14. Ravi A, Keller BM, Pignol JP. A comparison of postimplant dosimetry for (103)Pd versus (131)Cs seeds on a retrospective series of PBSI patients. *Med Phys* 2011; 38: 6046-6052.
 15. Rogers LR, Rock JP, Sills AK et al. Results of a phase II trial of the GliaSite radiation therapy system for the treatment of newly diagnosed, resected single brain metastases. *J Neurosurg* 2006; 105: 375-384.
 16. Bogart JA, Ungureanu C, Shihadeh E et al. Resection and permanent I-125 brachytherapy without whole brain irradiation for solitary brain metastasis from non-small cell lung carcinoma. *J Neurooncol* 1999; 44: 53-57.
 17. Petr MJ, McPherson CM, Breneman JC et al. Management of newly diagnosed single brain metastasis with surgical resection and permanent I-125 seeds without upfront whole brain radiotherapy. *J Neurooncol* 2009; 92: 393-400.
 18. Märten B, Janssen S, Werner M, et al. Hypofractionated stereotactic radiotherapy of limited brain metastases: a single-centre individualized treatment approach. *BMC Cancer* 2012; 12: 497.
 19. Wiggeraad R, Kanter AV, Kal HB, et al. Dose-effect relation in stereotactic radiotherapy for brain metastases. a systematic review. *Radiother Oncol* 2011; 3: 292-297.
 20. Aoyama H, Shirato H, Onimaru R et al. Hypofractionated stereotactic radiotherapy alone without whole-brain irradiation for patients with solitary and oligo brain metastasis using noninvasive fixation of the skull. *Int J Radiat Oncol Biol Phys* 2003; 3: 793-800.
 21. Brachman DG, Youssef E, Dardis CJ, et al. Resection and permanent intracranial brachytherapy using modular, biocompatible cesium-131 implants: results in 20 recurrent, previously irradiated meningiomas. *J Neurosurg* 2018; 6: 1819-1828.
 22. Yondorf M, Nedialkova L, Parashar B et al. Resection cavity dynamics following implantation of cesium-131 (Cs-131) brachytherapy for resection brain metastases based on CT-planning. *Int J Radiat Oncol Biol Phys* 2013; 87: S161-S162.
 23. Lazow SP, Yondorf M, Kovanlikaya I et al. Temporal changes in MRI edema and resection cavity dynamics subsequent to implantation of cesium-131 (Cs-131) brachytherapy in patients with brain metastases: a volumetric analysis from a prospective study. *Int J Radiat Oncol Biol Phys* 2013; 87: S256-S257.