



Thomas Jefferson University
Jefferson Digital Commons

Cardeza Foundation for Hematologic Research

Sidney Kimmel Medical College

9-2020

How I Treat Acute and Persistent Sickle Cell Pain.

Samir K. Ballas
Thomas Jefferson University

Follow this and additional works at: https://jdc.jefferson.edu/cardeza_foundation

 Part of the [Hematology Commons](#)

[Let us know how access to this document benefits you](#)

Recommended Citation

Ballas, Samir K., "How I Treat Acute and Persistent Sickle Cell Pain." (2020). *Cardeza Foundation for Hematologic Research*. Paper 59.

https://jdc.jefferson.edu/cardeza_foundation/59

This Article is brought to you for free and open access by the Jefferson Digital Commons. The Jefferson Digital Commons is a service of Thomas Jefferson University's [Center for Teaching and Learning \(CTL\)](#). The Commons is a showcase for Jefferson books and journals, peer-reviewed scholarly publications, unique historical collections from the University archives, and teaching tools. The Jefferson Digital Commons allows researchers and interested readers anywhere in the world to learn about and keep up to date with Jefferson scholarship. This article has been accepted for inclusion in Cardeza Foundation for Hematologic Research by an authorized administrator of the Jefferson Digital Commons. For more information, please contact: JeffersonDigitalCommons@jefferson.edu.



How I Treat

How I Treat Acute and Persistent Sickle Cell Pain

Samir K. Ballas.

Cardeza Foundation for Hematologic Research, Department of Medicine, Sidney Kimmel Medical College, Thomas Jefferson University, Philadelphia, PA, USA.

Competing interests: The authors declare no conflict of Interest.

Abstract. Sickle pain is the hallmark of sickle cell disease (SCD). It could be acute, persistent/relapsing, chronic, or neuropathic. Although there is a general consensus that pain is a major manifestation of SCD, there is a controversy as to the types of pain and their interrelationship between acute, chronic, relapsing, persistent, etc. This report first reviews the general approach to the management of acute vaso-occlusive crisis (VOC) pain, including education, counseling, pharmacotherapy, non-pharmacotherapy, and fluid therapy. This is followed by the presentation of five patients that represent typical issues that are commonly encountered in the management of patients with SCD. These issues are: individualized treatment of pain, bilaterality of pain, use of illicit drugs, tolerance to opioids, opioid-induced hyperalgesia, and withdrawal syndrome. The clinical aspects and management of each of these issues are described. Moreover, such complications as tolerance and withdrawal may persist after discharge and may be mistaken as chronic pain rather than resolving, persistent or relapsing pain.

Keywords: Sickle cell disease; Sickle cell anemia; Pain; Vaso-occlusive crisis.

Citation: Ballas S.K. How I treat acute and persistent sickle cell pain. *Mediterr J Hematol Infect Dis* 2020, 12(1): e2020064, DOI: <http://dx.doi.org/10.4084/MJHID.2020.064>

Published: September 1, 2020

Received: June 16, 2020

Accepted: August 13, 2020

This is an Open Access article distributed under the terms of the Creative Commons Attribution License (<https://creativecommons.org/licenses/by-nc/4.0>), which permits unrestricted use, distribution, and reproduction in any medium, provided the original work is properly cited.

Correspondence to: Samir K. Ballas MD FACP. Cardeza Foundation, Department of Medicine, Sidney Kimmel Medical College, Thomas Jefferson University, 1020 Locust Street, Philadelphia, PA 19107. Tel: 856 745 6380, Fax: 856 795 0809. E-Mail: Samir.ballas@jefferson.edu

Introduction. The hallmark of sickle cell disease (SCD) is the recurrent acute painful vaso-occlusive crises (VOCs) and the persistent pain (PP) in between crises in about 50% of adults and 9% of children.¹⁻³ These types of pain are unique to patients with SCD and punctuate the quality of their life with uncertainty, suffering, poor education, poverty, dysfunctional family life, and dependence on a fragile medical support system. The frequency, severity, location, and duration of both the VOCs and PP vary considerably among patients and longitudinally in the same patient. The reasons for these fluctuations are not well known.⁴ Moreover, most patients present with neither obvious precipitating factors nor objective signs.⁵⁻⁷ This state of affairs creates suspicion among some providers about the authenticity of the VOCs and the resulting accusations of

maladaptive behavior.⁸

The PP between crises has been labeled as chronic pain by some providers.¹ By doing so, the uniqueness of sickle cell pain is undermined, and the patients with SCD are lumped with other chronic pain syndromes in the general population. This lumping rendered the PP subject to the rules, regulations, and guidelines for the treatment of chronic pain.⁹ Moreover, since patients with SCD use relatively frequent and large doses of opioids, they have been assumed to be associated with the opioid epidemic. Consequently, patients with SCD and pain became often unfairly undertreated with opioids.

The purpose of this report is to describe patients with SCD who presented with different pain characteristics that were addressed and resolved in a manner based on

the changing reality of pain among patients over the dimensions of space and time.¹⁰

Overview of Treatment

Education and counseling. Educating and counseling patients with SCD is a continuous process that starts when first seen and continues through future follow-ups. I explain the beneficial and harmful effects of prescribed medications, including opioids. Prescriptions are given as needed. Vaccines are administered when required.¹¹ Patients, parents, and other family members are instructed on what to expect regarding sickle cell syndromes by making them aware of the signs and symptoms of VOCs, infection, acute chest syndrome (ACS), etc. The adoption of good health habits is reinforced, and the avoidance of situations and factors that could precipitate a VOC is emphasized.^{5,11}

This process of education and counseling results in a written consent form and individualized treatment plan with the patient or parents if long-term opioids are indicated.¹² The agreement lists the patient's rights and responsibilities, and the treatment plan contains the type, amount, and route of administration of the opioid in question, including random drug urine testing.

Pharmacotherapy of Pain. I use nonsteroidal anti-inflammatory drugs (NSAIDs), short-acting opioids, and adjuvants to treat acute pain.^{13,14} The use of NSAIDs is limited to patients whose serum creatinine is ≤ 1.0 mg/dL, and they have no proteinuria or albuminuria. The adjuvants include antihistamines, antiemetics, laxatives, antidepressants, and gabapentinoids as needed. I go over the personal side effects of opioids listed in **Table 1**. The use of opioids by patients with SCD is not as problematic as it is in the general population. A review of data from the Centers for Disease Control and Prevention (CDC) between 1999 and 2013 showed that less than 1% of deaths among patients with SCD was due to opioid overdose, and this low rate of mortality did not change significantly over the 15-year data.¹⁵

Fluid Therapy. I encourage my patients to use water for oral hydration and avoid soft drinks as often as possible. Signs and symptoms of dehydration include dry mouth, tongue, and lips, decreased skin turgor, flat neck veins, and serum creatinine level higher than steady-state values. I do not use normal saline for intravenous hydration but use 5% DW or other crystalloids. I monitor the status of hydration by determining daily fluid intake and output, daily weight, and check if edema develops.¹⁶⁻¹⁸ Overhydration, like over blood transfusion, could be fatal.¹⁹⁻²¹

Beyond Pharmacotherapy. With the help of our social workers, we address the psychosocial factors that pertain to each patient and recommend solutions. We

Table 1. Opioid Risks.

1. Mild/Moderate Side Effects:
<ul style="list-style-type: none">• Sedation• Confusion• Nausea• Dizziness• Constipation
2. Serious Medical Side Effects:
<ul style="list-style-type: none">• Gonadal suppression• Respiratory suppression• Sleep apnea• Dental complications
3. Serious Neurological and Behavioral Side Effects:
<ul style="list-style-type: none">• Physical dependence• Withdrawal• Tolerance• Hyperalgesia• Addiction• Pseudo addiction• Abuse, misuse, diversion

also recommend nonpharmacologic therapies such as meditation, yoga, massage, relaxation, tai chi, etc.^{22,23}

Neuropathophysiology of Pain. This was previously reported¹⁰ and summarized in **Table 2** and **Figure 1**.²⁴

Table 2. Pathways of the Transmission of painful Stimuli.

1. Peripheral nervous system
<ul style="list-style-type: none">– Peripheral nerves<ul style="list-style-type: none">• Voltage gated sodium channels• Nav1.7 – Na v1.9• Dorsal root ganglion
2. Central nervous system
<ul style="list-style-type: none">– Dorsal horn of the spinal cord<ul style="list-style-type: none">• Voltage gated sodium channels• α-Amino-3-hydroxy-5-methyl-4-isoxazolepropionic acid (AMPA)– Voltage Gated Calcium Channels<ul style="list-style-type: none">• N-methyl-D-aspartate (NMDA) Receptor• alpha2-delta (α2-δ) subunit– Opioid Receptors: μ, κ, δ
3. Central Sensitization
4. Glial Activation

Patient 1: A woman with Hb SC disease and VOC that went amiss. A 39-year old African American woman known to have hemoglobin (Hb) SC disease was admitted to the hospital with the diagnosis of VOC. The pain involved the left shoulder and the upper/lower back and was constant, sharp and throbbing in nature with an intensity score of 10 on a scale from 0 (no pain) to 10 (most severe pain). Past medical history was significant for VOCs at a rate of 2-3 VOCs per year with no pain between VOCs, avascular necrosis (AVN) of the left humeral joint, pneumonia, urinary tract infection, and a remote history of allergy to morphine. In the emergency department (ED), she was given meperidine 125 mg intravenously (IV) every two hours. She did not achieve adequate pain relief after receiving 3 doses of

Figure 1.

Molecular Mechanism of Pain

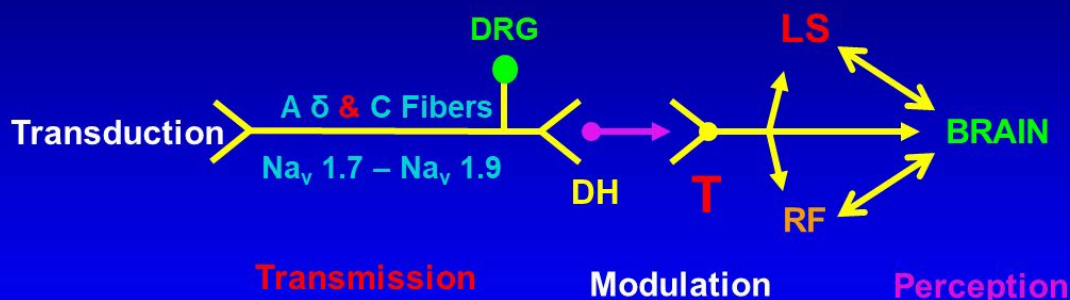


Figure 1. Pathways through which pain stimuli are transmitted from the periphery to the brain. Nav1.7 - Nav1.9 are peripheral voltage-gated sodium channels; DRG: Dorsal root ganglion; DH: Dorsal horn of the spinal cord; T: Thalamus; RF: Reticular formation; LS: Limbic system. Adapted from Semin Hematol 2001; 38(4):307-314. Used with permission.

meperidine and, hence, was admitted to the hospital. The attending provider decided to start her on patient-controlled analgesia (PCA) pump using morphine lockout dose 1 mg, lockout interval 10 minutes, and a one-hour dose limit of 8 mg morphine. The patient indicated that she is allergic to morphine and usually receives meperidine for pain, but she could not give details about the nature of the allergy to morphine. About 8 hours after starting the PCA, she experienced hallucinations, disorientation, fever 103° F, chest oppression, and difficulty breathing with pulse Oximetry of 86%. She was transferred to the intensive care unit and intubated. The chest x-ray was normal. She recovered within 24 hours, and management of pain was resumed with meperidine and was discharged 7 days after admission.

Comments on patient 1. Management of patients with sickle cell pain should be individualized. Patients with SCD are authorities on their disease. They know what helps them most. Accordingly, providers should listen, believe, and respect patients unless proven otherwise. The selection of a specific opioid and its dose should be based on the patient's previous experience. No opioid or a specific dose of an opioid applies to all patients all the time. Opioids are ligands that bind to receptors and slow the transmission of painful stimuli along the central nervous system pathways. The binding to and activation of a specific receptor by an opioid vary considerably among patients. Opioid receptors are G protein-coupled

with exogenous and endogenous opioids as ligands.²⁵ Recent studies²⁵⁻²⁷ have revealed a helical structure of the opioid receptors, which forms pockets in which the corresponding ligand (opioid) fits snugly. Not all opioids fit snugly into the same receptor's pocket. This explains why some patients may have better analgesia with a certain opioid but not with another opioid.

Patient 2: A man with SCA and urine drug screen positive for cannabis and phencyclidine. A 22 year-old-African American man with sickle cell anemia (SCA) whose past medical history was significant for frequent VOCs that required hospitalizations > 5 times per year with intermittent pain between VOCs. Pain during crises was usually constant, sharp, and throbbing in nature with a score of 8-10/10 and involved the low back, right shoulder, knees, and legs. Complications of his disease included ACS, AVN of hips and right shoulder, priapism, and frequent blood transfusions. In addition, he had asthma as a child and heparin-induced thrombocytopenia. He refused to take hydroxyurea. Social history was positive for tobacco, cannabis, and alcohol use. Lab data in the steady-state included Hb that varied between 8 and 10 g/dL, Hb F 11%, reticulocyte count 10-15%, WBC count 8 - 14 B/L, normal platelet count, mildly elevated total bilirubin level and normal hepatic and renal parameters. Pain management included morphine and ketorolac during hospitalizations and oxycodone/ acetaminophen (Percocet) as an outpatient.

When first seen in our center, agreement, and consent forms that included random urine drug testing were discussed and signed by the patient and the provider. The first random urine drug testing done was positive for opiates and cannabinoids. Intensive counseling indicated that he smoked cannabis because Percocet did not give him adequate pain relief. The issue was resolved by replacing Percocet with morphine for the treatment of pain as an outpatient with the patient affirmation that he will discontinue using cannabis subject to confirmation by random urine drug testing. Indeed, random urine drug testing one year later was negative for cannabis and positive for the opiates (morphine) he was taking. Unfortunately, the random urine drug testing done later when he was 24 years old was positive for opiates and phencyclidine.

Another round of counseling revealed that phencyclidine gave him much better pain relief than morphine used to do. Accordingly, pain management was modified to use methadone up to 60 mg orally/day instead of morphine and 5% lidocaine patches to apply over the most painful area for a maximum of 8 hours per day as needed. Electrocardiogram (EKG) before and after using methadone showed no prolongation of the QTC interval. Methadone was chosen because, like phencyclidine, it inhibits the N-methyl-D-aspartate (NMDA) channel but less severely. This approach resulted in the discontinuation of phencyclidine and repeating urine drug test at the age of 25 years and again at the age of 26 years when he was last seen was positive for opiates only and negative for cannabinoids and phencyclidine.

Comment on patient 2. This patient is a typical example of opioid tolerance that leads to the use of illicit drugs. It is defined as reduced potency of the analgesic effect of an opioid after repeated administration or the need for higher doses to maintain the same result. It shifts the dose-response curve to the right (**Figure 2A**).²⁸ The binding of an opioid to its receptor generates a series of reactions that could culminate in tolerance, as shown in **Figure 3**.²⁹

Recent studies in mice have shown that tolerance to morphine seems to be modulated by the gut-microbiome-central nervous system interactions.³⁰⁻³²

Management of opioid tolerance entails the use of NMDA inhibitors. Actually, the illicit phencyclidine used by this patient is a potent inhibitor of the NMDA (**Figure 4**) not only at the level of the spinal cord but in all other tissues and organs and, hence, could be lethal.³³

The NMDA channel is a complex structure.³⁴ It is both a receptor and a calcium-gated channel.^{35,36} Therapeutic inhibitors of NMDR include ketamine, clonidine, Lidocaine, dextromethorphan, nitrous oxide, zinc, and methadone.^{29,37,38} More recently, rosuvastatin, B vitamins, and inhibition of platelet-derived growth factor- β (PDGFR- β) have been shown to attenuate or

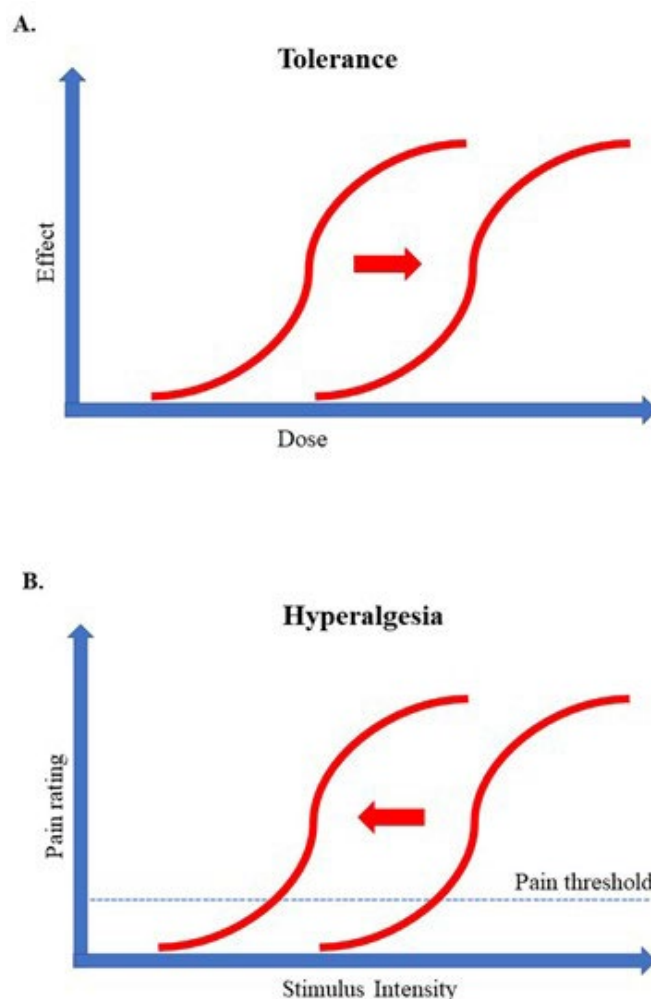


Figure 2. Tolerance and hyperalgesia. Tolerance in A shows a higher dose of an opioid is required to achieve the desired pain relief. Hyperalgesia in B shows that prolonged administration of opioids results in a paradoxical increase in severe pain after minor stimuli. Adapted from Best Pract Res Clin Anaesthesiol 2007; 21:65-83. Used with permission.

eliminate the development of tolerance to morphine in rats and mice.³⁹⁻⁴² Donica et al. reported that combining imatinib with a previously ineffective dose of morphine led to complete pain relief in male Sprague-Dawley rats.⁴² In addition, imatinib was effective in treating sickle cell VOC in patients with chronic myeloid leukemia and SCA, probably by inhibiting PDGFR- β .^{43,44}

Patient 3: A woman with Hb SC and VOC after C-section that became symmetrically bilateral. A 26-year-old pregnant African American woman Hb SC disease had a Cesarean section (C-section) at week 37 gestation due to signs of fetal distress with abnormal fetal heart tracing. The surgery was uneventful, and the fetus survived with a normal APGAR score. Past medical history was significant for relatively infrequent VOCs (< 2 per year) and splenic sequestration during infancy that did not require splenectomy. During pregnancy, she took oxycodone 5 mg plus acetaminophen 325 mg (Percocet) prn for pain. The

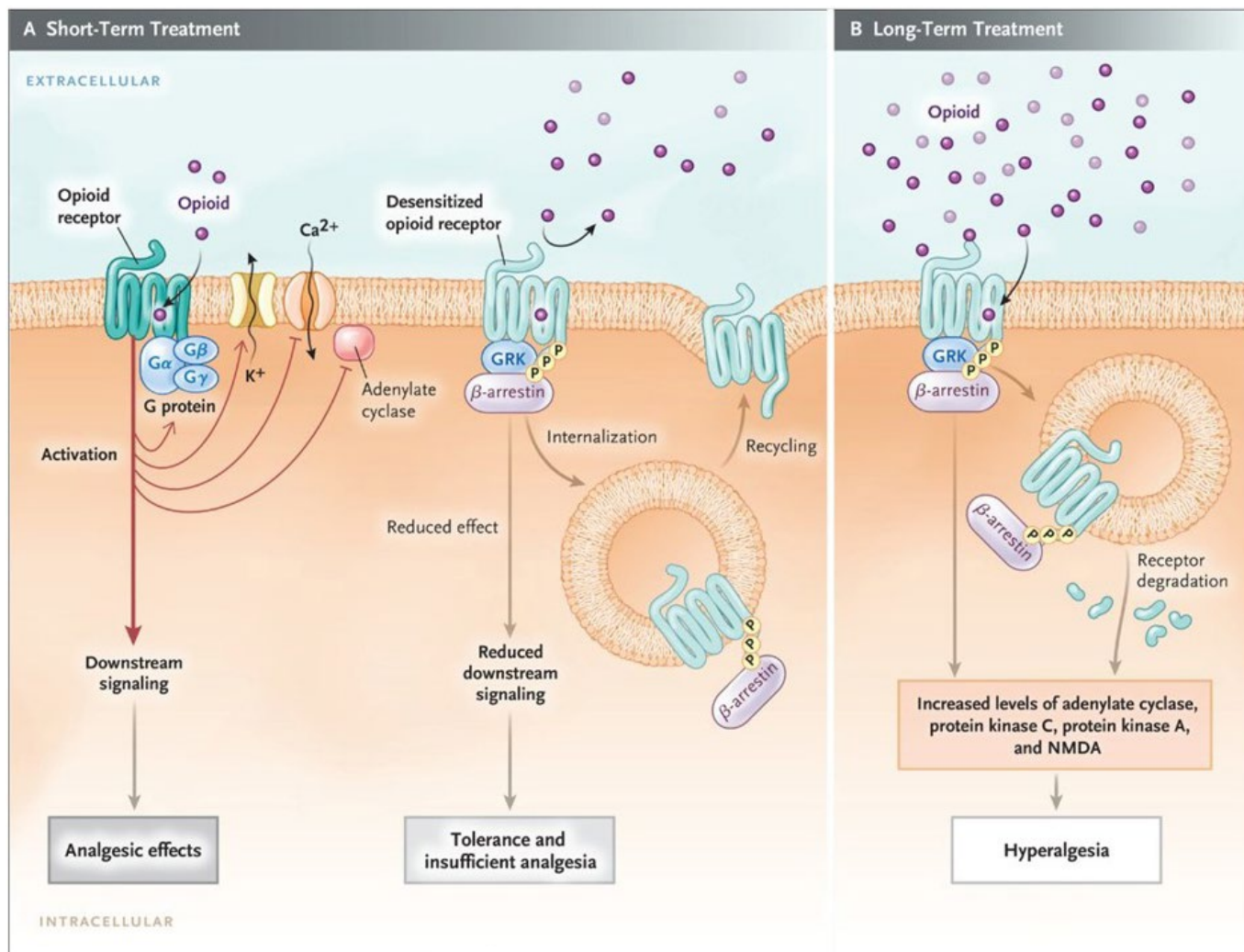


Figure 3. The effect of short- and long-term opioid therapy on opioid-receptor signaling. (A) Binding of an opioid to cell membrane μ -receptors activates the receptor's G protein that dissociates into $G\alpha$ and $G\beta\gamma$ subunits. These, in turn, inhibit voltage-gated calcium channels and activate potassium channels resulting in K^+ loss causing membrane hyperpolarization and decreased transmission of painful stimuli and opioid-analgesia. However, soon after the opioid binds to its receptor it is subject to phosphorylation by GRK (G-protein-coupled receptor kinase) culminating in the recruitment and binding of β -arrestin protein to the receptor. This results in desensitization of the receptor thus decreasing the response to the opioid inducing insufficient analgesia and tolerance. (B) Long term therapy with an opioid associated with sustained β -arrestin binding to the receptor often leads to internalization and degradation of the receptor. This, in turn, initiates a series of reactions that culminate in the activation of the N-methyl-D-aspartate (NMDA) receptor which result in diminishing the analgesic effect, increasing tolerance and opioid-induced-hyperalgesia. From *N Engl J Med* 2019; 380:365-378. Used with permission.

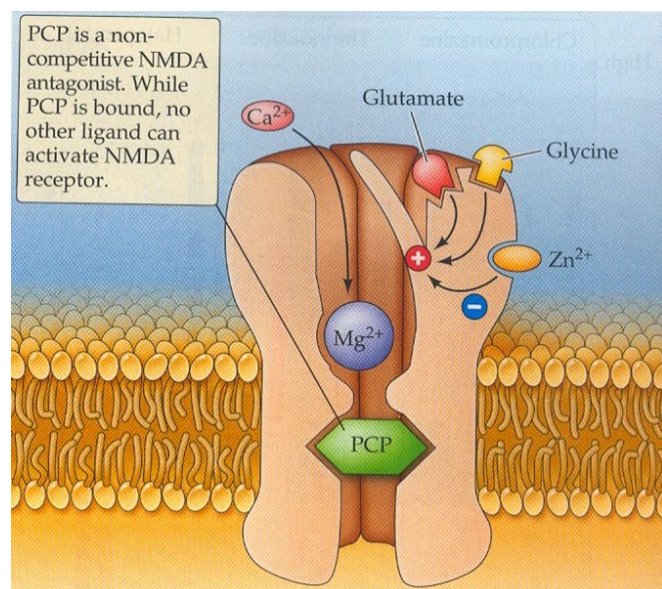


Figure 4. The effect of phencyclidine (PCP) on the N-methyl-D-aspartate (NMDA) receptor. PCP acts as a noncompetitive antagonist at NMDA receptor. As long as it is bound it renders the NMDA receptor nonfunctional. From Breedlove S.M., Watson N.V. *Behavioral Neuroscience*, Eighth Edition. Oxford University Press New York, NY; 2018. Used with permission.

newborn infant had no signs/symptoms of neonatal abstinence syndrome. She was advised not to breastfeed her baby. On the 4th post-operative day, she had a sudden onset of severe pain, swelling, and tenderness in her right ankle. She achieved partial relief with morphine, 6 mg IV every 2 hours. About 24 hours later, she had the same severe "mirror image" pain in her left ankle. Some providers questioned the validity of the symmetrical pain in the left ankle due to the unlikely possibility of having vaso-occlusion in such a symmetrical pattern. Physical exam, however, revealed the presence of

similar swelling and tenderness over both ankles. Better pain relief was achieved by increasing the dose of morphine to 8 mg IV every 2 hours. She continued to improve gradually and was discharged with her infant ten days after admission.

Comment on patient 3. This patient illustrates two important issues in SCD: postpartum breastfeeding and the pathophysiology of the incidence of symmetrical bilateral pain.

Women with SCD who take opioids during pregnancy must not breastfeed their infants to prevent newborn withdrawal syndrome that could be fatal. Codeine used to be considered a safe opioid analgesic for pain during breastfeeding. This changed after a tragic case report that pertains to an infant who died at the age of 13 days from morphine poisoning; the source of morphine was the codeine that the mother was taking. Further studies showed that the mother was an ultra-rapid metabolizer of codeine, due to duplication of the CYP2D6 enzyme that metabolized codeine into morphine.^{45,46} The recommendation changed, indicating that women, in general, must not take opioids during the breastfeeding period.

Symmetrical bilaterality of pain, such as both hips, both knees, was common in more than 60% of patients enrolled in the PiSCES study⁴⁷ and was also reported by others.⁴⁸ The ankles and feet were the most common locations of bilaterality. The pathophysiology of this bilaterality is not known. One possibility is that it is referred pain to a site different than the original site of pathology.⁴⁹ Shunting of the blood away from the bone marrow, the steal syndrome, is another possibility.⁴⁸ Another explanation of bilaterality is that it is due to central sensitization at the level of the spinal cord, as described by Woolf⁵⁰ in rats. The convergence of nerve fibers from two different sites at the same level in the spinal cord is perceived as pain in both sites (**Figure 5**).⁵¹

Most recently, bilaterality seems to be due to a phenomenon called "bioelectric injury mirroring".⁵² This extends our knowledge about the electrophysiology of regenerative response and identifies a novel communication process via a long-range spread of injury signaling (**Figure 6**).⁵²

Patient 4: A woman with Hb S- β^0 -thalassemia whose pain worsened after increasing the dose of morphine.

A 29-year-old African American woman with sickle β^0 -thalassemia was admitted to the hospital with VOC involving her low back, chest, and knees. The pain was typical of her VOCs and was constant and sharp/throbbing in nature with an intensity score of 10/10. She also complained of fatigue, malaise, nausea, and vomiting.

Past medical history was significant for frequent VOCs (≥ 5 per year) that required treatment in the ED

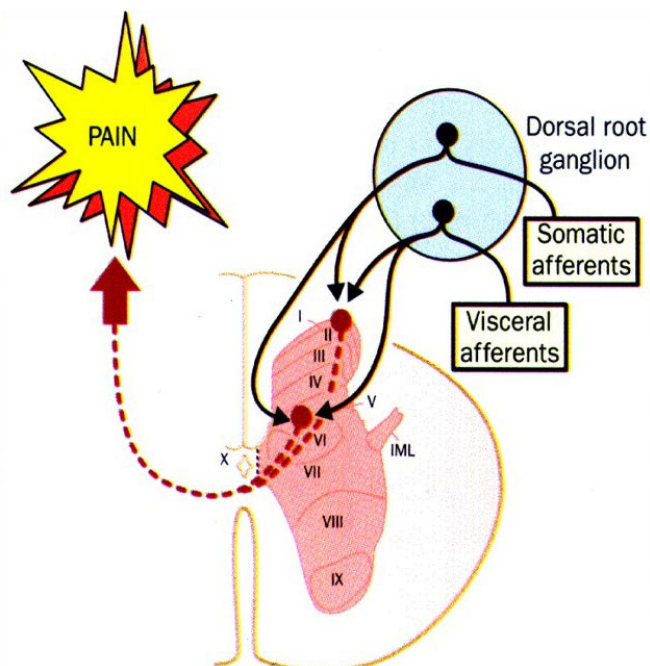


Figure 5. Viscero-somatic convergence of primary afferent fibers on neurons of lamina I and lamina V of the dorsal horn. IML: intermediolateral cell column. From Lancet 1999; 353: 2145-2148. Used with permission.

or in the hospital, cholecystectomy, splenectomy, ACS, repeated blood transfusions, iron overload, deep vein thrombosis, migraine headache, urinary tract infection, and C-section at 34 weeks gestation due to twin pregnancy with both babies in the breech position.

Pain management in this admission included a morphine PCA pump with a basal rate of 4 mg/h and 1 mg lockout every 10 minutes with a one-hour dose limit of 10 mg and ibuprofen. Emesis was controlled with ondansetron IV. Adjuvants included antihistamines and laxatives. She required two units of RBC transfusion to keep her Hb > 8 g/dL. She was also given heparin for deep vein thrombosis prophylaxis. She continued to complain of severe pain that required increasing the dose limit of morphine to 16 mg/hour. At the same time, the distribution and the descriptors of the pain changed; it became worst in her legs and deep burning in nature. Examination showed severe allodynia where a superficial touch of her legs caused severe pain, and she avoided covering her legs with the blanket to prevent pain. The diagnosis of morphine-induced hyperalgesia was made. The dose of morphine was gradually decreased and replaced with an equianalgesic dose of hydromorphone, up to 8 mg iv q2hour. Eventually, adequate relief was achieved with hydromorphone. She was discharged on the 24th hospital day on hydromorphone and ibuprofen.

Comment on patient 4. This patient's pain is a typical example of opioid-induced hyperalgesia (OIH). It is defined as increased sensitivity to pain stimuli (hyperalgesia) and pain caused by ordinarily nonpainful stimuli (referred to as allodynia). Typically,

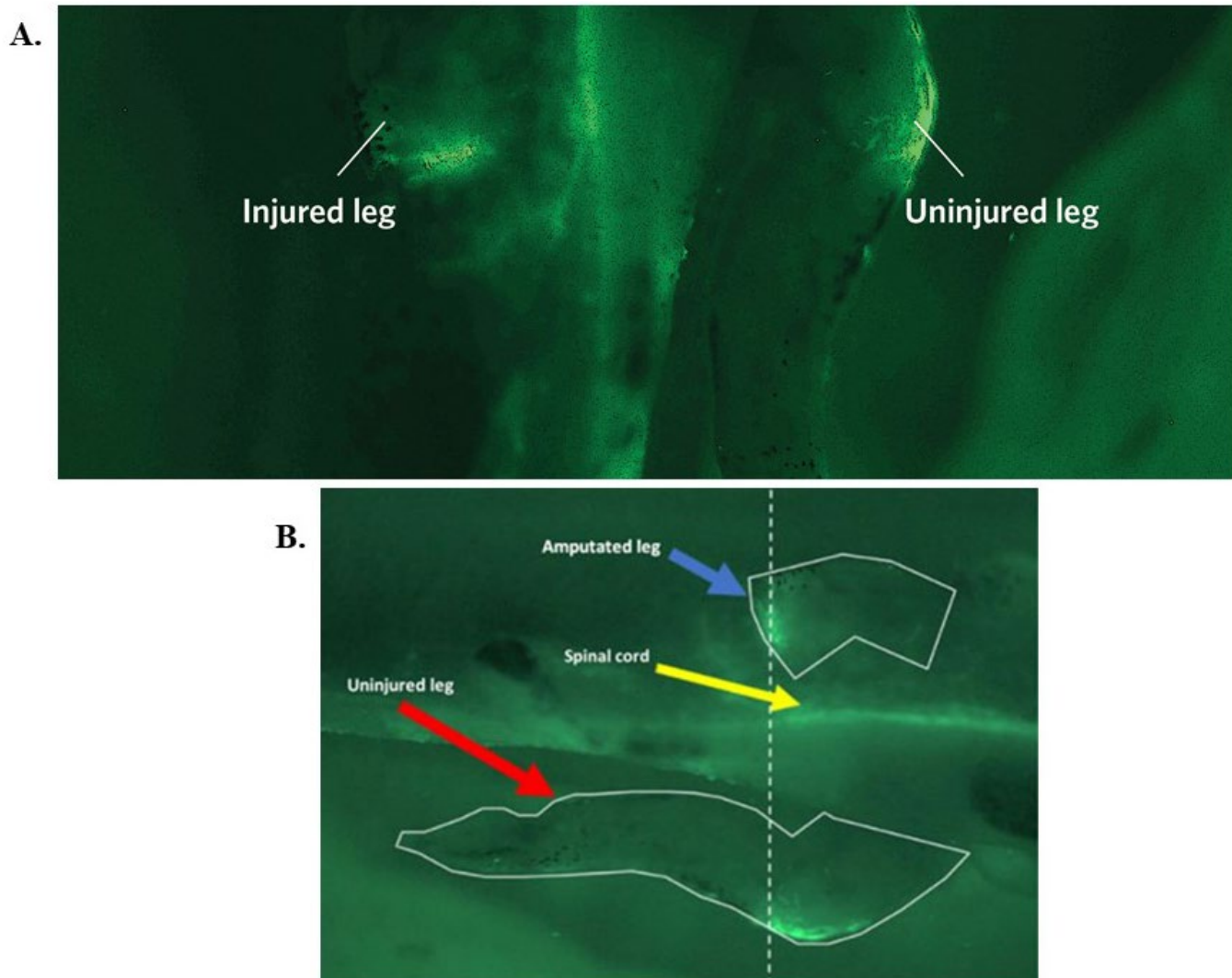


Figure 6. Frogs Have a Bioelectric Mirror. (A) Amputation of one limb triggers a rapid electric response that reflects the injury in the opposite not injured one. From *Development* 2018; 145: dev164210. (B) Depolarization patterns (brighter green) in the uninjured leg (bottom) occur within seconds of amputation of the opposing leg (top). From *Tufts Now*. Amputation injury is communicated to opposing limbs. *Tufts Now*; 2019. Used with permission.

hyperalgesia is noted in parts of the body different from the site of the original pain complaint, and the descriptors of the pain change with some similarity to certain aspects of neuropathic pain such as burning sensation. Unlike tolerance, OIH worsens with higher doses of opioids (**Figure 2B**).⁵³⁻⁵⁵

The pathophysiology of OIH is not well understood. A proposed mechanism is the activation of the NMDA receptor.^{33,53} This activation results in calcium influx, which in turn enhances the excitability of neurons, which facilitates further transmission of painful stimuli.³³

Studies in rats showed that morphine hyperalgesia appears to be secondary to the activation of specific receptors within microglia since the ablation of the microglia prevented OIH.⁵⁶ **Figure 7** illustrates how glia interact with neurons and the surrounding blood vessels.⁵⁷

Management of OIH involves weaning from opioids, opioid rotation, and the use of NMDA inhibitors such as

methadone, clonidine, Lidocaine, or ketamine as needed. Weaning and rotation are usually done together, as was described in this patient.

Patient 5: A man with SCA and recurrent severe pain between VOCs.

A 42-year-old African American man with SCA presented to the ED with severe diarrhea and nausea/vomiting of five-days duration. These signs and symptoms were associated with nasal congestion, rhinorrhea, cough, and severe crampy abdominal pain and a VOC with severe pain involving his low back, arms, and legs that brought him to the ED. Medications included Hydroxyurea 1500 mg/day and hydromorphone 4 mg by mouth q 2h as needed.

Other complications of his SCA included a history of cholecystectomy, obstructive sleep apnea treated at home with oxygen, AVN of the right hip that required arthroplasty, and pneumonia.

Physical exam included a temperature of 99.6°F, RR 30/min heart rate 130/min, pulse oximetry 99% on 2

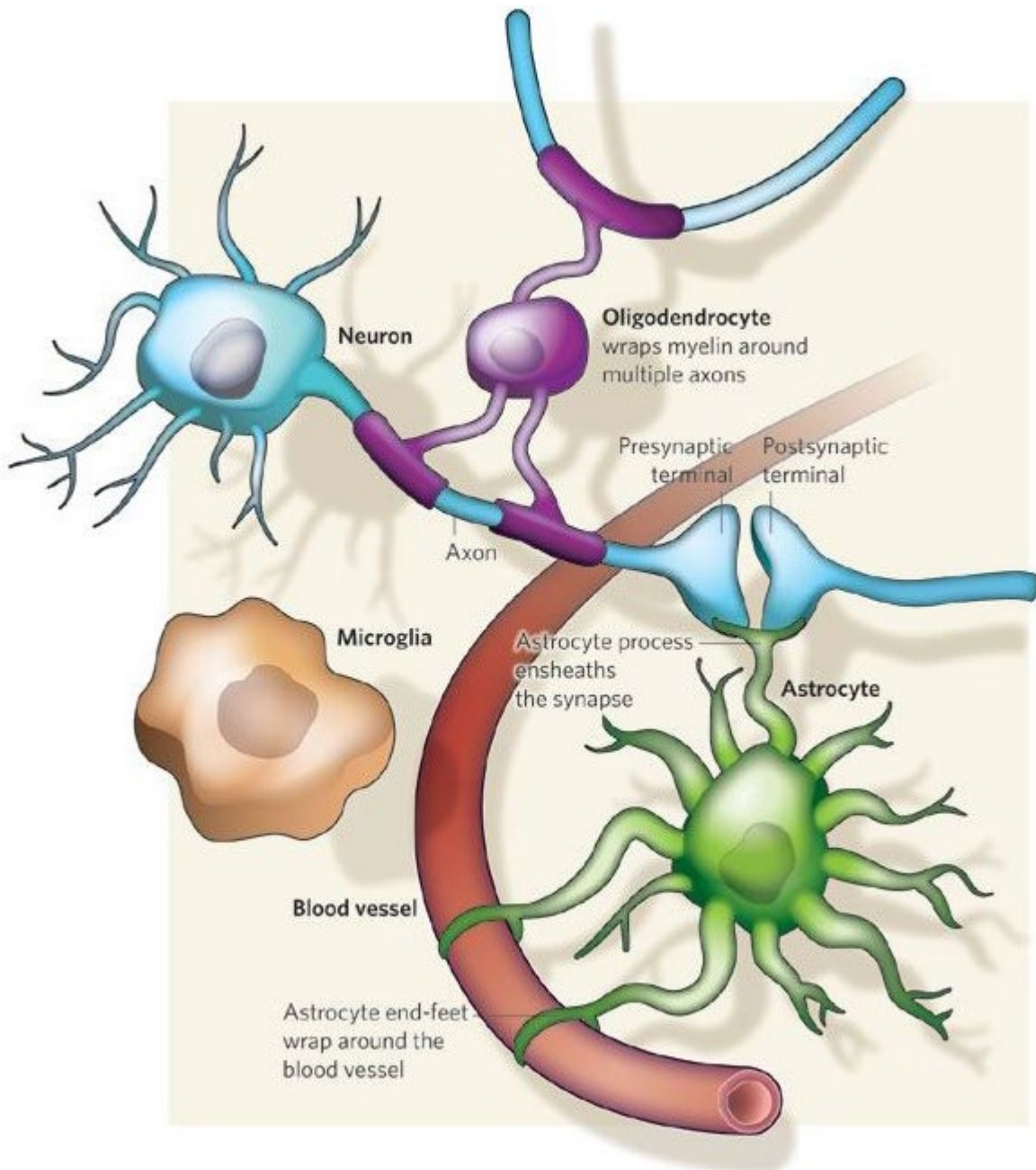


Figure 7. Different types of glia interact with neurons and the surrounding blood vessels. Oligodendrocytes wrap myelin around axons to speed up neuronal transmission. Astrocytes extend processes that ensheath blood vessels and synapses. Microglia keep the brain under surveillance for damage or infection. From Nature 2009; 457: 675-677. Used with permission.

liters oxygen. The patient was restless, anxious, and sweaty. Heart and lung exams were normal. A large ulcer over the left lateral ankle and a smaller ulcer over the right medial ankle were both clean and healing gradually.

Lab data included Hb 7.7 g/dL, reticulocyte count 7.9%, mean corpuscular volume (MCV) 120 fL, serum creatinine 1.0 mg/dL and normal serum electrolytes and liver function tests. A diagnosis of VOC precipitated by viral gastroenteritis was made and treated accordingly. Cultures of stools, urine, and blood were all negative. Chest X-ray and EKG were within normal. Treatment included hydration, opioid analgesia with hydromorphone up-to 8mg q 2h IV plus hydroxyzine as

an adjuvant, antiemetics with ondansetron, and anti-laxatives with loperamide. He improved gradually, and after 15 days of hospitalization, he was discharged on hydromorphone 4 mg by mouth q2h and acetaminophen 325 mg/oxycodone 5 mg three times daily as needed.

During the six months after this hospitalization, he was readmitted about once every month with similar signs and symptoms. The diagnosis was changed to gastroenteritis of unknown etiology. The home treatment of pain was changed up to 16 mg hydromorphone po every 2 hours. At this point, he was referred to our center for advice.

A detailed review of the history and the physical exam revealed that the patient had adequate pain relief

with hydromorphone used at home for 3-4 days. After that, he gradually developed diarrhea, nausea/vomiting, running nose, abdominal cramps, followed by typical symptoms of VOC. This sequence of events recurred before the frequent hospital admissions mentioned above. This sequence of events was typical of withdrawal signs and symptoms, and which was treated with clonidine (0.2 mg three times daily) and methadone (30 mg daily that was increased gradually to a maximum of 60 mg/day). The patient improved gradually and the gastrointestinal and respiratory signs and symptoms resolved. He was advised to continue taking clonidine and methadone for 3-4 weeks, after which he will be reevaluated for possible changes.

Comment on patient 5. Withdrawal syndrome is a conglomerate of physical and behavioral signs and symptoms after the discontinuation or decreasing the dose of an opioid or other addictive drug. The severity of the symptoms depends on the drug in question and its dosage. These include yawning, sweating, lacrimation, rhinorrhea, anxiety, irritability, restlessness, insomnia, dilated pupils, piloerection, chills, tachycardia, hypertension, nausea/vomiting, cramping abdominal

pains, diarrhea, and muscle aches and pains.

The incidence and management of withdrawal in SCD have not been well studied. It is often confused with acute or chronic pain, infection, or other comorbidities. It is a cause for hospital readmission within one-two weeks after discharge.⁵⁸

Treatment of severe opioid withdrawal includes methadone plus clonidine either orally (0.1- 0.2 mg every 4-6 hours prn or by using transdermal clonidine patch 0.1 mg daily). Other drugs that may be used to treat withdrawal include buprenorphine plus naloxone orally.^{59,60} Recently, the FDA approved oral lofexidine to treat the symptoms of withdrawal.⁶¹ Lofexidine is a structural analog of clonidine. Clinical trials comparing the two medications showed comparable efficacy, though the severity of adverse events was less than those with clonidine. This decreased risk for adverse effects could potentially make lofexidine a safer option for detoxification.⁶²⁻⁶⁴

Persistent Sickle Cell Pain. The word "chronic" in SCD is problematic and subject to different explanations. Thus, SCD itself is a chronic disease that is usually symptomatic from childhood through adulthood.

Table 3. Emergency Room Data for Patient 1 – 5.

Patient	Crisis Day	Pain Site Location	Pain Score	Hospital Admission
Patient 1	1	Chest	10	Yes
	33	Right Thigh Right Knee Right Leg	10	No
	75	Upper Arms Elbows Forearms Wrists Hands Fingers	10	No
	114	Lower Back Hip	10	No
Patient 2	1	Left Side Chest	10	No
	50	Thighs Legs Upper Back Lower Back Neck	10	No
	76	Right Shoulder	10	No
Patient 3	1	Chest	9	No
	37	Right Foot	8.5	No
	76	Abdomen	8.0	No
Patient 4	1	Chest	Not Given	Yes
	60	Legs	Not Given	Yes
	87	Abdomen	Not Given	Yes
Patient 5	1	Knees	7	No
	33	Lower Back	8	No
	54	Arms Forearms Shoulders	Not Given	Yes

Typically, SCD pain is either acute, which is the hallmark of the disease or chronic. The latter includes such complications as leg ulcers, AVN of humeral or femoral heads, and bone infarcts.⁶⁵⁻⁶⁷

These chronic pain syndromes are localized and last for months or years. Recently chronic pain in SCD has been defined as ongoing pain that is present in at least 50% of days over 3 or 6 months in a single or multiple locations.^{6,68} The problem with this definition is that during the period of 3- or 6-months, patients with SCD may have been treated for acute pain in the ED or hospital, thus confounding this definition. Another definition of chronic pain that was initially introduced by surgeons is acute pain that becomes chronic. This definition applies well to post-operative pain that is acute after surgery but, in some patients, continues in the same operative field for months or years.⁶⁹

Actually, this definition applies to the chronic complications of SCD. Thus, AVN of the hips may start acutely but persists for months or years in the same location. A new definition of chronic pain in SCD is the pain that persists or occurs between VOCs, the so-called chronic on acute pain.⁷⁰ Although this may occur in disorders other than SCD, it is not typical of SCD because the sickle pain between VOCs is not the same: it varies in location, severity, and outcome, as shown in **Table 3**. Other patients with chronic pain syndromes such as fibromyalgia, osteoarthritis, rheumatoid arthritis, low back pain, migraine, etc. are rarely treated in the ED and rarely require hospital admissions. Sickle cell

disease and sickle cell pain are unique and should be considered as such.

Patients discharged from the hospital after treatment of uncomplicated VOCs may have:

1. No pain.
2. Resolving mild pain as the VOC continues to resolve gradually.
3. Persistent pain after discharge that requires continued therapy with oral analgesics, (due to tolerance, OIH or withdrawal).
4. Relapsing pain that occurs after a period with no pain (new mild VOC)

I consider the pain that occurs between VOCs is most likely due to tolerance to opioids, withdrawal syndrome, OIH, resolving, or acute relapsing pain. These are specific diagnoses that have specific recommended treatments rather than treating them as chronic pain. Accordingly, it seems the use of Buprenorphine/Naloxone is potentially a good candidate to treat these syndromes as recently reported by Osunkwo et al.⁷¹

Summary. The acute painful VOC is a unique and hallmark clinical entity of SCD. Recurrent VOCs are not identical but usually vary considerably among patients and longitudinally in the same patient. This is unlike chronic pain that tends to be essentially the same from time to time. The pain between VOCs could be due to tolerance, OIH, withdrawal, resolving, or relapsing VOC.

References:

1. Smith WR, Penberthy LT, Bovbjerg VE, McClish DK, Roberts JD, Dahman B, et al. Daily assessment of pain in adults with sickle cell disease. *Ann Intern Med.* 2008;148(2):94-101. <https://doi.org/10.7326/0003-4819-148-2-200801150-00004> PMID:18195334
2. Dampier C, Ely B, Brodecki D, O'Neal P. Characteristics of pain managed at home in children and adolescents with sickle cell disease by using diary self-reports. *J Pain.* 2002;3(6):461-70. <https://doi.org/10.1054/jpai.2002.128064> PMID:14622732
3. Ballas SK, Bauserman RL, McCarthy WF, Castro OL, Smith WR, Waclawiw MA. Hydroxyurea and acute painful crises in sickle cell anemia: effects on hospital length of stay and opioid utilization during hospitalization, outpatient acute care contacts, and at home. *J Pain Symptom Manage.* 2010;40(6):870-82. <https://doi.org/10.1016/j.jpainsymman.2010.03.020> PMID:20864308 PMCID:PMC3005988
4. Ballas SK. *Sickle Cell Pain*, 2nd Edition. Washington DC: International Association for the Study of Pain; 2014.
5. Ballas SK, Gupta K, Adams-Graves P. Sickle cell pain: a critical reappraisal. *Blood.* 2012;120(18):3647-56. <https://doi.org/10.1182/blood-2012-04-383430> PMID:22923496
6. Yawn BP, Buchanan GR, Afenyi-Annan AN, Ballas SK, Hassell KL, James AH, et al. Management of sickle cell disease: summary of the 2014 evidence-based report by expert panel members. *JAMA.* 2014;312(10):1033-48. <https://doi.org/10.1001/jama.2014.10517> PMID:25203083
7. Ballas SK, Smith ED. Red blood cell changes during the evolution of the sickle cell painful crisis. *Blood.* 1992;79(8):2154-63. <https://doi.org/10.1182/blood.V79.8.2154.2154>
8. Pentin PL. Drug seeking or pain crisis? Responsible prescribing of opioids in the emergency department. *Virtual Mentor.* 2013;15(5):410-5. <https://doi.org/10.1001/virtualmentor.2013.15.5.ecas2-1305> PMID:23680561
9. Dowell D, Haegerich TM, Chou R. CDC Guideline for Prescribing Opioids for Chronic Pain - United States, 2016. *MMWR Recomm Rep.* 2016;65(1):1-49. <https://doi.org/10.15585/mmwr.rr6501e1> PMID:26987082
10. Ballas SK. Pathophysiology and principles of management of the many faces of the acute vaso-occlusive crisis in patients with sickle cell disease. *Eur J Haematol.* 2015;95(2):113-23. <https://doi.org/10.1111/ejh.12460> PMID:25288149
11. Ballas SK. More definitions in sickle cell disease: steady state v base line data. *Am J Hematol.* 2012;87(3):338. <https://doi.org/10.1002/ajh.22259> PMID:22190068
12. Expert Panel Report. Evidence-Based Management of Sickle Cell Disease Bethesda MD: National Heart, Lung, and Blood Institute; 2014 [Available from: <http://www.nhlbi.nih.gov/health-pro/guidelines/sickle-cell-disease-guidelines/>].
13. Ballas SK. Pain management of sickle cell disease. *Hematol Oncol Clin North Am.* 2005;19(5):785-802. <https://doi.org/10.1016/j.hoc.2005.07.008> PMID:16214644
14. Ballas SK. Update on pain management in sickle cell disease. *Hemoglobin.* 2011;35(5):520-9. <https://doi.org/10.3109/03630269.2011.610478> PMID:21910604
15. Ruta NS, Ballas SK. The Opioid Drug Epidemic and Sickle Cell Disease: Guilt by Association. *Pain Med.* 2016;17(10):1793-8. <https://doi.org/10.1093/pm/pnw074>

- PMid:27152018
16. Carden MA, Fay M, Sakurai Y, McFarland B, Blanche S, DiPrete C, et al. Normal saline is associated with increased sickle red cell stiffness and prolonged transit times in a microfluidic model of the capillary system. *Microcirculation*. 2017;24(5). <https://doi.org/10.1111/micc.12353> PMid:28106307
 17. Carden MA, Fay ME, Lu X, Mannino RG, Sakurai Y, Ciciliano JC, et al. Extracellular fluid tonicity impacts sickle red blood cell deformability and adhesion. *Blood*. 2017;130(24):2654-63. <https://doi.org/10.1182/blood-2017-04-780635> PMid:28978568 PMCid:PMC5731085
 18. Ballas SK. Of pools, oceans, and the Dead Sea. *Blood*. 2017;130(24):2578-9. <https://doi.org/10.1182/blood-2017-10-811091> PMid:29242205
 19. Gardner JW. Death by water intoxication. *Mil Med*. 2002;167(5):432-4. <https://doi.org/10.1093/milmed/167.5.432> PMid:12053855
 20. Gutmann FD, Gardner JW. Fatal water intoxication of an Army trainee during urine drug testing. *Mil Med*. 2002;167(5):435-7. <https://doi.org/10.1093/milmed/167.5.435>
 21. Serjeant G. Blood transfusion in sickle cell disease: a cautionary tale. *Lancet*. 2003;361(9369):1659-60. [https://doi.org/10.1016/S0140-6736\(03\)13293-X](https://doi.org/10.1016/S0140-6736(03)13293-X)
 22. Ballas SK. Self-management of sickle cell disease: a new frontier. *J Natl Med Assoc*. 2010;102(11):1042-3. [https://doi.org/10.1016/S0027-9684\(15\)30722-7](https://doi.org/10.1016/S0027-9684(15)30722-7)
 23. Tanabe P, Porter J, Creary M, Kirkwood E, Miller S, Ahmed-Williams E, et al. A qualitative analysis of best self-management practices: sickle cell disease. *J Natl Med Assoc*. 2010;102(11):1033-41. [https://doi.org/10.1016/S0027-9684\(15\)30730-6](https://doi.org/10.1016/S0027-9684(15)30730-6)
 24. Ballas SK. Sickle cell disease: current clinical management. *Semin Hematol*. 2001;38(4):307-14. [https://doi.org/10.1016/S0037-1963\(01\)90024-1](https://doi.org/10.1016/S0037-1963(01)90024-1)
 25. Waldhoer M, Bartlett SE, Whistler JL. Opioid receptors. *Annu Rev Biochem*. 2004;73:953-90. <https://doi.org/10.1146/annurev.biochem.73.011303.073940> PMid:15189164
 26. Manglik A, Kruse AC, Kobilka TS, Thian FS, Mathiesen JM, Sunahara RK, et al. Crystal structure of the micro-opioid receptor bound to a morphinan antagonist. *Nature*. 2012;485(7398):321-6. <https://doi.org/10.1038/nature10954> PMid:22437502 PMCid:PMC3523197
 27. Cox BM. Recent developments in the study of opioid receptors. *Mol Pharmacol*. 2013;83:723-8. <https://doi.org/10.1124/mol.112.083279> PMid:23249538
 28. Koppert W, Schmelz M. The impact of opioid-induced hyperalgesia for post-operative pain. *Best Pract Res Clin Anaesthesiol*. 2007;21(1):65-83. <https://doi.org/10.1016/j.bpa.2006.12.004> PMid:17489220
 29. Martyn JAJ, Mao J, Bittner EA. Opioid Tolerance in Critical Illness. *N Engl J Med*. 2019;380(4):365-78. <https://doi.org/10.1056/NEJMr1800222> PMid:30673555 PMCid:PMC6897318
 30. Kang M, Mischel RA, Bhawe S, Komla E, Cho A, Huang C, et al. The effect of gut microbiome on tolerance to morphine mediated antinociception in mice. *Sci Rep*. 2017;7:42658. <https://doi.org/10.1038/srep42658> PMid:28211545 PMCid:PMC5314392
 31. Akbarali HI, Dewey WL. The gut-brain interaction in opioid tolerance. *Curr Opin Pharmacol*. 2017;37:126-30. <https://doi.org/10.1016/j.coph.2017.10.012> PMid:29145012 PMCid:PMC5725258
 32. Mischel RA, Dewey WL, Akbarali HI. Tolerance to Morphine-Induced Inhibition of TTX-R Sodium Channels in Dorsal Root Ganglia Neurons Is Modulated by Gut-Derived Mediators. *iScience*. 2018;2:193-209. <https://doi.org/10.1016/j.isci.2018.03.003> PMid:29888757 PMCid:PMC5993194
 33. Breedlove S.M., Watson N.V. Behavioral Neuroscience, Eighth Edition. Oxford University Press New York, NY; 2018.
 34. CNS Forum. NMDA Receptor. *CNS Forum*2002.
 35. de Vos JW, Ufkes JG, Kaplan CD, Tursch M, Krause JK, van Wilgenburg H, et al. L-Methadone and D,L-methadone in methadone maintenance treatment: a comparison of therapeutic effectiveness and plasma concentrations. *Eur Addict Res*. 1998;4(3):134-41. <https://doi.org/10.1159/000018936> PMid:9742275
 36. Wedekind D, Jacobs S, Karg I, Luedecke C, Schneider U, Cimander K, et al. Psychiatric comorbidity and additional abuse of drugs in maintenance treatment with L- and D,L-methadone. *World J Biol Psychiatry*. 2010;11(2 Pt 2):390-9. <https://doi.org/10.3109/15622970802176487> PMid:20218800
 37. Zhang Y, Tao GJ, Hu L, Qu J, Han Y, Zhang G, et al. Lidocaine alleviates morphine tolerance via AMPK-SOCS3-dependent neuroinflammation suppression in the spinal cord. *J Neuroinflammation*. 2017;14(1):211. <https://doi.org/10.1186/s12974-017-0983-6> PMid:29096659 PMCid:PMC5667445
 38. Swe KM, Abas AB, Bhardwaj A, Barua A, Nair NS. Zinc supplements for treating thalassaemia and sickle cell disease. *Cochrane Database Syst Rev*. 2013;6:CD009415. <https://doi.org/10.1002/14651858.CD009415.pub2> PMid:23807756
 39. Li Y, Shu Y, Ji Q, Liu J, He X, Li W. Attenuation of morphine analgesic tolerance by rosuvastatin in naive and morphine tolerance rats. *Inflammation*. 2015;38(1):134-41. <https://doi.org/10.1007/s10753-014-0015-y> PMid:25261133
 40. Deng XT, Han Y, Liu WT, Song XJ. B Vitamins Potentiate Acute Morphine Antinociception and Attenuate the Development of Tolerance to Chronic Morphine in Mice. *Pain Med*. 2017;18(10):1961-74. <https://doi.org/10.1093/pm/pnw358> PMid:28379583
 41. Wang Y, Barker K, Shi S, Diaz M, Mo B, Gutstein HB. Blockade of PDGFR-beta activation eliminates morphine analgesic tolerance. *Nat Med*. 2012;18(3):385-7. <https://doi.org/10.1038/nm.2633> PMid:22344297 PMCid:PMC3296828
 42. Donica CL, Cui Y, Shi S, Gutstein HB. Platelet-derived growth factor receptor-beta antagonism restores morphine analgesic potency against neuropathic pain. *PLoS One*. 2014;9(5):e97105. <https://doi.org/10.1371/journal.pone.0097105> PMid:24820332 PMCid:PMC4018247
 43. Stankovic Stojanovic K, Thioliere B, Garandeau E, Lecomte I, Bachmeyer C, Lionnet F. Chronic myeloid leukaemia and sickle cell disease: could imatinib prevent vaso-occlusive crisis? *Br J Haematol*. 2011;155(2):271-2. <https://doi.org/10.1111/j.1365-2141.2011.08670.x> PMid:21488859
 44. Murphy M, Close J, Lottenberg R, Rajasekhar A. Effectiveness of imatinib therapy for sickle cell anemia and chronic myeloid leukemia. *Am J Med Sci*. 2014;347(3):254-5. <https://doi.org/10.1097/MAJ.0000000000000228> PMid:24553361
 45. Koren G, Cairns J, Chitayat D, Gaedigk A, Leeder SJ. Pharmacogenetics of morphine poisoning in a breastfed neonate of a codeine-prescribed mother. *Lancet*. 2006;368(9536):704. [https://doi.org/10.1016/S0140-6736\(06\)69255-6](https://doi.org/10.1016/S0140-6736(06)69255-6)
 46. Sajantila A. Editors' pick: codeine toxicity prediction in young infants - genotype the mothers. *Investig Genet*. 2012;3(1):24. <https://doi.org/10.1186/2041-2223-3-24> PMid:23186321 PMCid:PMC3528413
 47. McClish DK, Smith WR, Dahman BA, Levenson JL, Roberts JD, Penberthy LT, et al. Pain site frequency and location in sickle cell disease: the PiSCES project. *Pain*. 2009;145(1-2):246-51. <https://doi.org/10.1016/j.pain.2009.06.029> PMid:19631468 PMCid:PMC2771372
 48. Serjeant GR, Chalmers RM. Current concerns in haematology. 1. Is the painful crisis of sickle cell disease a "steal" syndrome? *J Clin Pathol*. 1990;43(10):789-91. <https://doi.org/10.1136/jcp.43.10.789> PMid:1699977 PMCid:PMC502823
 49. Rathmell J.P., Fields HL. Pain: pathophysiology and management. In: Longo DL, Fauci AS, Kasey S, Hauser R, Jameson LS, Loscaizo JL, editors. *Harrison's Principles of Internal Medicine*. New York, NY: McGraw Hill; 2012. p. 93-101.
 50. Woolf CJ. Evidence for a central component of post-injury pain hypersensitivity. *Nature*. 1983;306(5944):686-8. <https://doi.org/10.1038/306686a0> PMid:6656869
 51. Cervero F, Laird JM. Visceral pain. *Lancet*. 1999;353(9170):2145-8. [https://doi.org/10.1016/S0140-6736\(99\)01306-9](https://doi.org/10.1016/S0140-6736(99)01306-9)

52. Busse SM, McMillen PT, Levin M. Cross-limb communication during *Xenopus* hindlimb regenerative response: non-local bioelectric injury signals. *Development*. 2018;145(19). <https://doi.org/10.1242/dev.164210> PMID:30126906
53. Youssef F, Pater A, Shehata M. Opioid-induced Hyperalgesia. *J Pain Relief*. 2015;4:183-5.
54. Benjamin LJ, Payne R. Pain in sickle cell disease: a multidimensional construct. In: Pace B, editor. *Renaissance of Sickle Cell Disease Research in the Genomic Era*. London: Imperial College Press; 2007. p. 99-118. https://doi.org/10.1142/9781860947964_0007
55. de Montalembert M, Ferster A, Colombatti R, Rees DC, Gulbis B. ENERCA clinical recommendations for disease management and prevention of complications of sickle cell disease in children. *Am J Hematol*. 2011;86(1):72-5. <https://doi.org/10.1002/ajh.21865> PMID:20981677
56. Ferrini F, Trang T, Mattioli TA, Laffray S, Del'guidice T, Lorenzo LE, et al. Morphine hyperalgesia gated through microglia-mediated disruption of neuronal Cl(-) homeostasis. *Nat Neurosci*. 2013;16:183-92. <https://doi.org/10.1038/nn.3295> PMID:23292683 PMCid:PMC4974077
57. Allen NJ, Barres BA. Neuroscience: Glia - more than just brain glue. *Nature*. 2009;457(7230):675-7. <https://doi.org/10.1038/457675a> PMID:19194443
58. Ballas SK, Lusardi M. Hospital readmission for adult acute sickle cell painful episodes: frequency, etiology, and prognostic significance. *Am J Hematol*. 2005;79(1):17-25. <https://doi.org/10.1002/ajh.20336> PMID:15849770
59. Burma NE, Kwok CH, Trang T. Therapies and mechanisms of opioid withdrawal. *Pain Manag*. 2017;7(6):455-9. <https://doi.org/10.2217/pmt-2017-0028> PMID:29125396
60. Kenna GA, Nielsen DM, Mello P, Schiesl A, Swift RM. Pharmacotherapy of dual substance abuse and dependence. *CNS Drugs*. 2007;21(3):213-37. <https://doi.org/10.2165/00023210-200721030-00003> PMID:17338593
61. NIDA. FDA approves first medication to reduce opioid withdrawal symptoms National Institute on Drug Abuse website2018 [Available from: <https://www.drugabuse.gov/news-events/news-releases/2018/05/fda-approves-first-medication-to-reduce-opioid-withdrawal-symptoms>].
62. Gish EC, Miller JL, Honey BL, Johnson PN. Lofexidine, an α 2-receptor agonist for opioid detoxification. *Ann Pharmacother*. 2010;44(2):343-51. <https://doi.org/10.1345/aph.1M347> PMID:20040696
63. Gorodetzky CW, Walsh SL, Martin PR, Saxon AJ, Gullo KL, Biswas K. A phase III, randomized, multi-center, double blind, placebo controlled study of safety and efficacy of lofexidine for relief of symptoms in individuals undergoing inpatient opioid withdrawal. *Drug Alcohol Depend*. 2017;176:79-88. <https://doi.org/10.1016/j.drugalcdep.2017.02.020> PMID:28527421
64. Law FD, Diaper AM, Melichar JK, Coulton S, Nutt DJ, Myles JS. Buprenorphine/naloxone versus methadone and lofexidine in community stabilisation and detoxification: A randomised controlled trial of low dose short-term opiate-dependent individuals. *J Psychopharmacol*. 2017;31(8):1046-55. <https://doi.org/10.1177/0269881117711710> PMID:28631527
65. Ballas SK, Talacki CA, Rao VM, Steiner RM. The prevalence of avascular necrosis in sickle cell anemia: correlation with alpha-thalassemia. *Hemoglobin*. 1989;13(7-8):649-55. <https://doi.org/10.3109/03630268908998842> PMID:2634666
66. Milner PF, Kraus AP, Sebes JI, Sleeper LA, Dukes KA, Embury SH, et al. Sickle cell disease as a cause of osteonecrosis of the femoral head. *N Engl J Med*. 1991;325(21):1476-81. <https://doi.org/10.1056/NEJM199111213252104> PMID:1944426
67. Minniti CP, Eckman J, Sebastiani P, Steinberg MH, Ballas SK. Leg ulcers in sickle cell disease. *Am J Hematol*. 2010;85(10):831-3. <https://doi.org/10.1002/ajh.21838> PMID:20872960 PMCid:PMC2953786
68. Dampier C, Palermo TM, Darbari DS, Hassell K, Smith W, Zempsky W. AAPT Diagnostic Criteria for Chronic Sickle Cell Disease Pain. *J Pain*. 2017;18(5):490-8. <https://doi.org/10.1016/j.jpain.2016.12.016> PMID:28065813
69. Chapman CR, Vierck CJ. The Transition of Acute Postoperative Pain to Chronic Pain: An Integrative Overview of Research on Mechanisms. *J Pain*. 2017;18(4):359.e1-.e38. <https://doi.org/10.1016/j.jpain.2016.11.004> PMID:27908839
70. Kent ML, Tighe PJ, Belfer I, Brennan TJ, Bruehl S, Brummett CM, et al. The ACTION-APS-AAPM Pain Taxonomy (AAAPT) Multidimensional Approach to Classifying Acute Pain Conditions. *J Pain*. 2017;18(5):479-89. <https://doi.org/10.1016/j.jpain.2017.02.421> PMID:28495013 PMCid:PMC7323793
71. Osunkwo I, Veeramreddy P, Arnall J, Crawford R, Symanowski JT, Olaosebikan R, et al. Use of Buprenorphine/Naloxone in Ameliorating Acute Care Utilization and Chronic Opioid Use in Adults with Sickle Cell Disease. *Blood*. 2019;134 (Suppl 1):790. <https://doi.org/10.1182/blood-2019-126589>