



Thomas Jefferson University
Jefferson Digital Commons

Department of Obstetrics and Gynecology
Faculty Papers

Department of Obstetrics and Gynecology

6-2020

Phrenic nerve injury secondary to extracorporeal membrane oxygenation in pregnancy: A case report

Cheryl Godcharles

Thomas Jefferson University

Melody Safarzadeh

Thomas Jefferson University

Emily A. Oliver


Thomas Jefferson University

Amanda Roman

Thomas Jefferson University

Huda B. Al-Kouatly

Follow this and additional works at: <https://jdc.jefferson.edu/obgynfp>


 Part of the [Obstetrics and Gynecology Commons](#)

[Let us know how access to this document benefits you](#)

Recommended Citation

Godcharles, Cheryl; Safarzadeh, Melody; Oliver, Emily A.; Roman, Amanda; and Al-Kouatly, Huda B., "Phrenic nerve injury secondary to extracorporeal membrane oxygenation in pregnancy: A case report" (2020). *Department of Obstetrics and Gynecology Faculty Papers*. Paper 63.
<https://jdc.jefferson.edu/obgynfp/63>

This Article is brought to you for free and open access by the Jefferson Digital Commons. The Jefferson Digital Commons is a service of Thomas Jefferson University's [Center for Teaching and Learning \(CTL\)](#). The Commons is a showcase for Jefferson books and journals, peer-reviewed scholarly publications, unique historical collections from the University archives, and teaching tools. The Jefferson Digital Commons allows researchers and interested readers anywhere in the world to learn about and keep up to date with Jefferson scholarship. This article has been accepted for inclusion in Department of Obstetrics and Gynecology Faculty Papers by an authorized administrator of the Jefferson Digital Commons. For more information, please contact: JeffersonDigitalCommons@jefferson.edu.



Phrenic nerve injury secondary to extracorporeal membrane oxygenation in pregnancy: A case report

Cheryl Godcharles | Melody Safarzadeh | Emily A. Oliver | Amanda Roman |
Huda B. Al-Kouatly

Department of Obstetrics and Gynecology,
Sidney Kimmel Medical College, Thomas
Jefferson University, Philadelphia, PA, USA

Correspondence

Huda B. Al-Kouatly, Department of
Obstetrics and Gynecology, Division of
Maternal-Fetal Medicine, Thomas Jefferson
University, 833 Chestnut Street, First Floor,
Philadelphia, PA 19107.
Email: Huda.Al-Kouatly@jefferson.edu

Abstract

Extracorporeal membrane oxygenation (ECMO) is used to provide acute respiratory and/or hemodynamic support to patients with severe, refractory respiratory failure. Phrenic nerve injury with subsequent hemidiaphragm paralysis should be included in the differential diagnosis of pregnant women with persistent hypoxia after ECMO cannulation.

KEYWORDS

diaphragm, extracorporeal membrane oxygenation, hypoxia, injury, phrenic nerve, pregnancy

1 | INTRODUCTION

Extracorporeal membrane oxygenation (ECMO) is being used more frequently to provide acute respiratory and/or hemodynamic support to patients with severe, refractory respiratory or cardiac failure.¹ A literature review of ECMO in pregnancy revealed that ECMO is safe and effective for both mother and fetus in cases of acute severe respiratory or cardiopulmonary collapse.² The most common indications for ECMO in pregnancy were ARDS secondary to viral infection, peripartum cardiomyopathy, cardiogenic shock, and/or cardiac arrest.^{2,3} The use of ECMO in pregnancy will likely rise in response to the increasing prevalence of cardiopulmonary disease in the pregnant population.

Veno-venous ECMO (VV ECMO) provides respiratory support while a patient recovers from a reversible lung disease. Generally, a double lumen catheter is placed in the right internal jugular (IJ) vein. Blood is extracted from one lumen, circulated through a pump and an oxygenator, and returned to the body through the second lumen of the catheter.⁴

The sympathetic chain, brachial plexus, and phrenic nerve are all susceptible to injury during IJ and subclavian (SCV) catheterization. Nerve injury may result from either

compression secondary to hematoma or direct trauma from the needle or catheter.^{5,6} Compression injuries usually improve with resolution of the associated hematoma, while direct injury may take much longer to resolve.⁷ Total incidence of nerve injury from central line placement is 1.6%, although the specific incidence of phrenic nerve paralysis from ECMO cannulation is not quoted in the current literature.⁵

The phrenic nerve arises from spinal nerve roots C3, C4, and C5 and innervates the diaphragm.⁸ Figure 1 demonstrates the close proximity of the phrenic nerve to the IJ and SCV veins. Phrenic nerve injury is clinically significant because it results in hemidiaphragm paralysis and subsequent respiratory distress and hypoxia. Patients with hemidiaphragm paralysis typically report dyspnea on exertion and/or orthopnea.⁹

We describe the first reported case of a pregnant patient with right hemidiaphragm paralysis secondary to phrenic nerve injury likely occurring during ECMO cannulation.

2 | CASE

The patient is a 29-year-old G6P3023 who presented to an outside hospital at 25 weeks gestation reporting chest

This is an open access article under the terms of the Creative Commons Attribution-NonCommercial-NoDerivs License, which permits use and distribution in any medium, provided the original work is properly cited, the use is non-commercial and no modifications or adaptations are made.

© 2020 The Authors. *Clinical Case Reports* published by John Wiley & Sons Ltd.

and back pain, as well as shortness of breath. She had a past medical history of asthma, opioid use disorder, bipolar disorder, anxiety, seizures, anemia, hypothyroidism, herpes simplex virus, hepatitis C, rheumatoid arthritis, and fibromyalgia. Her past surgical history included three cesarean sections, two dilation and curettages, and an adenoidectomy. Her medications included buprenorphine, gabapentin, quetiapine, alprazolam, levetiracetam, and albuterol. Her social history was significant for tobacco use (one pack per day) and a history of heroin use (last use was four years ago). Chest X-ray on initial presentation revealed bilateral infiltrates and no signs of hemidiaphragm paralysis. Although she was initially hemodynamically stable, she quickly developed an increasing oxygen requirement and was diagnosed with ARDS. She required transfer to the intensive care unit and intubation. Following intubation, the patient was tachycardic to the 130s, which was thought to be due to sepsis. She was started on vancomycin, piperacillin-tazobactam, and stress-dose steroids empirically for suspected pneumonia. She required large doses of propofol, fentanyl, and midazolam for sedation, and subsequently developed hypotension requiring norepinephrine and initiation of ECMO. A repeat chest X-ray was notable for extensive multifocal airspace opacification. She was placed on single lumen VV ECMO and sedated due to persistent desaturation while awake. Bronchoscopy revealed purulent secretions and diffuse alveolar hemorrhage. Her respiratory viral panel was positive for rhinovirus, which is generally self-limited and treated conservatively for symptom relief. Her hospital course was also complicated by enterobacter pneumonia and MRSA pneumonia. Throughout her hospitalization, she was treated with multiple broad-spectrum

antibiotics including azithromycin, capsosfungin, cefepime, ceftriaxone, meropenem, piperacillin-tazobactam, and vancomycin. She received a total of thirty days of antibiotic therapy before her pneumonia resolved.

The patient was on ECMO for thirteen days prior to decannulation. She had daily chest X-rays that demonstrated right hemidiaphragm elevation on hospital day 16, one day after ECMO decannulation (Figure 2). A tracheostomy was performed, and the patient was maintained on the tracheostomy collar until she was stable for tracheostomy decannulation. She initially required 2L of oxygen therapy via nasal cannula; however, four days later she was able to maintain oxygen saturation on room air. CT chest showed resolving pneumonia, but persistent elevation of the right hemidiaphragm.

The patient experienced benzodiazepine and opiate withdrawal, and was treated with a midazolam and hydromorphone drip, respectively. She continued to have symptoms of opiate withdrawal whenever attempts were made to taper the hydromorphone PCA. Therefore, she was transferred to our hospital for methadone stabilization in pregnancy. Her methadone dose was titrated per protocol until she no longer experienced withdrawal symptoms. She was able to maintain her oxygen saturation on room air for only a few days before requiring 2L nasal cannula to maintain saturations >95%. This was initially thought to be due to the sedative effects of her medications. She was started on a benzodiazepine taper per psychiatry's recommendations, and attempts were made to wean her oxygen. On our hospital day 6, she had an episode of desaturation to 75% on room air. She required 3L nasal cannula to maintain saturations >95%. The patient reported increasing dyspnea on exertion and was

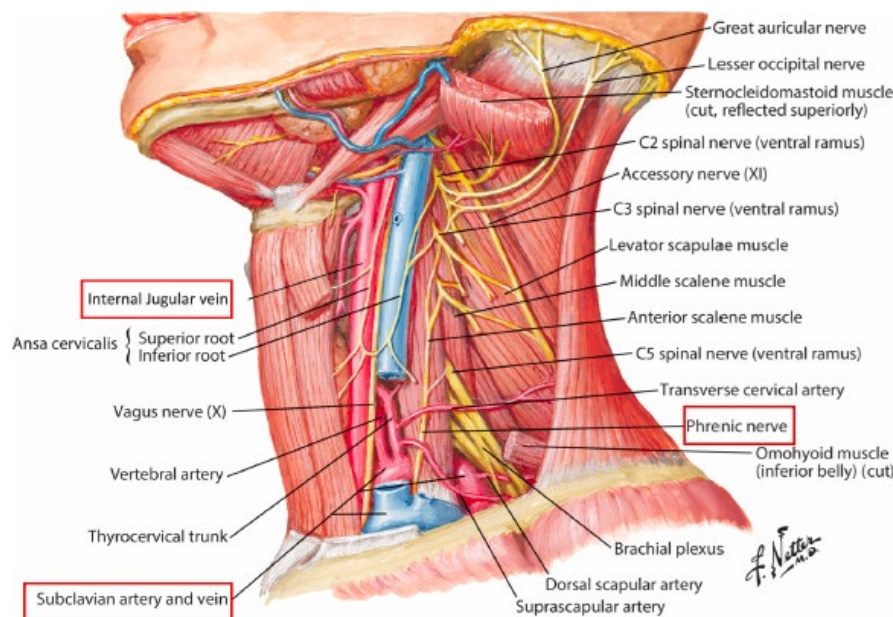


FIGURE 1 Proximity of the phrenic nerve to the internal jugular and subclavian veins. Netter illustration used with permission of Elsevier Inc. All rights reserved. www.netterimages.com

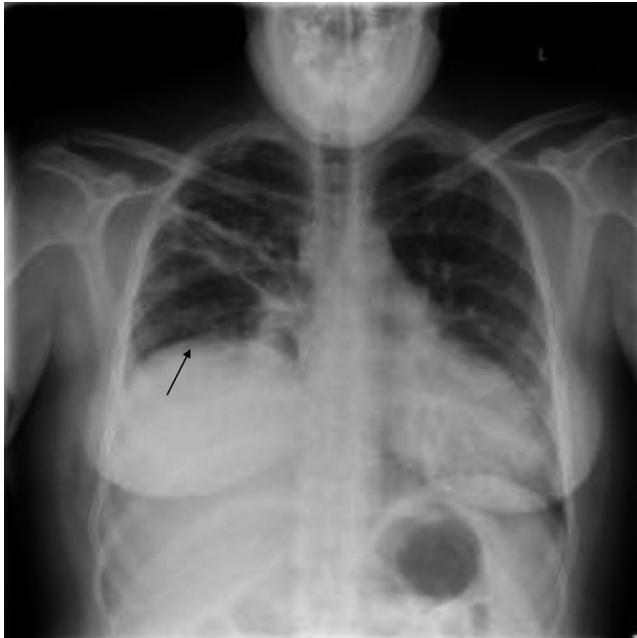

FIGURE 2 Chest X-ray demonstrating right hemidiaphragm elevation (identified by arrow) on hospital day 16, one day after extracorporeal membrane oxygenation decannulation

noted to have decreased breath sounds in the right lower lobe. Echocardiogram was within normal limits. Pulmonology diagnosed her with shunting past her post-pneumonia injury, central hypoventilation due to narcotics, and peripheral hypoventilation secondary to hemidiaphragm weakness. These diagnoses were supported by a chest X-ray demonstrating markedly elevated right hemidiaphragm with adjacent atelectasis and mild left perihilar opacity. At 33 weeks gestation, the patient was discharged home on 2L oxygen via nasal cannula, after an 8-week admission.

The patient continued to have an increasing oxygen requirement throughout the third trimester, requiring home oxygen therapy from 33 weeks gestation until her delivery at 37 weeks gestation. There was no evidence of persistent pneumonia. She was delivered via repeat cesarean section. Her postpartum course was significant for an oxygen requirement of 3L nasal cannula in order to maintain oxygen saturation >95%. The patient was seen by pulmonology and had a CT that was negative for pulmonary embolism. She also had a fluoroscopic “sniff” test that diagnosed right-sided diaphragm paralysis. The fluoroscopic “sniff” test involves patients breathing in and out while diaphragmatic motion is observed under fluoroscopy. In patients with unilateral paralysis, the corresponding side of the diaphragm either moves paradoxically or does not move at all.^{9,10} Pulmonology recommended continued deep breathing exercises and home oxygen therapy. Her postpartum course was otherwise uncomplicated. She was discharged home in stable condition and received a Nexplanon for contraception.

3 | DISCUSSION

The differential diagnosis for dyspnea in pregnancy is broad. It is important to thoroughly evaluate any patient with shortness of breath, particularly those requiring oxygen therapy at home. The workup should start with a history and physical examination. Radiographic studies typically include a chest X-ray and/or CT. An elevated hemidiaphragm is suggestive, although not diagnostic, of hemidiaphragm paralysis and should prompt further investigation with fluoroscopy.¹⁰ Fluoroscopy is not recommended in pregnancy unless it will significantly change management and is expected to improve maternal and/or fetal outcomes. Causes of hemidiaphragm elevation include lung disease, trauma, and congenital causes including diaphragmatic hernia.

Management of hemidiaphragm paralysis from phrenic nerve injury is typically conservative. Patients typically compensate for the paralysis with a number of supportive mechanisms, and the phrenic nerve usually recovers in one to two years.¹⁰ Patients can do respiratory physical therapy in order to improve the strength in the affected portion of the diaphragm. If conservative measures fail, there are a number of surgical management options, including implantation of a diaphragmatic pacer, diaphragmatic plication with video-assisted thoracoscopy, and nerve transplantation.¹⁰

In our case, the patient had a chest X-ray and CT shortly after her ECMO decannulation showing right hemidiaphragm elevation. She quickly became dependent on oxygen; however, her increasing oxygen requirement was thought to be due to her growing gravid uterus and her multiple comorbidities. Her worsening dyspnea was far beyond what would be expected in a normal pregnant patient, and the fact that her symptoms and oxygen requirements did not resolve with delivery were suggestive of a cause other than pregnancy. She had a normal echocardiogram and CT that ruled out pulmonary embolism. We believe that our patient sustained a phrenic nerve injury during VV ECMO cannulation as her initial CXR on admission did not show hemidiaphragm elevation (elevation was first documented one day after ECMO decannulation).

An extensive search of the literature was performed via PubMed and Scopus through March 31, 2020. Relevant articles describing phrenic nerve injury in pregnancy were identified from the previously mentioned databases without any time, language, or study limitations. We used the following search terms: (hemidiaphragm or phrenic nerve or diaphragm or diaphragmatic or hemidiaphragmatic) and (paralysis or paralyzed or paresis or injury) and ((pregnant or pregnancy or maternal) or (antepartum or antenatal or prenatal or labor or delivery or peripartum or postpartum)). This search yielded 776 articles on PubMed and 508 on Scopus when limited to studies in humans. Additionally, we searched PubMed and Scopus using the following parameters: (hemidiaphragm or

phrenic nerve or diaphragm or diaphragmatic or hemidiaphragmatic) and (paralysis or paralyzed or paresis or injury) and (ECMO or extra-corporeal membrane oxygenation) and (respiratory failure or hypoxia or hypoxemic or hypoxemia or hypoxic). This search yielded 16 results on PubMed and 27 results on Scopus. All titles were screened, and articles were reviewed when appropriate; no reports of phrenic nerve injury in pregnancy were identified.

4 | CONCLUSION

Extracorporeal membrane oxygenation is used to provide acute respiratory and/or hemodynamic support to patients with severe, refractory respiratory or cardiac failure. The use of ECMO in pregnancy will likely rise in response to the increasing prevalence of cardiopulmonary disease in the pregnant population. As ECMO use in pregnancy increases, it is important to become familiar with the diagnosis and treatment of potential complications. This case demonstrates the importance of considering phrenic nerve injury and hemidiaphragm paralysis as a cause of hypoxia in pregnancy, especially after procedures such as ECMO. This is the first reported case of phrenic nerve injury in pregnancy, most likely due to ECMO.

ACKNOWLEDGMENTS

Published with written consent of the patient. No financial support was received for this study.

CONFLICT OF INTEREST

None declared.

AUTHOR CONTRIBUTIONS

CG: conceived the idea for the study and wrote the article. MS, EO, and AR: critically revised drafts of the article for important intellectual content. HAK: critically revised drafts of the article for important intellectual content and gave final approval of the version to be published.

ORCID

Huda B. Al-Kouatly  <https://orcid.org/0000-0003-2922-0333>

REFERENCES

1. Peek GJ, Mugford M, Tiruvoipati R, et al. Efficacy and economic assessment of conventional ventilatory support versus extracorporeal membrane oxygenation for severe adult respiratory failure (CESAR): a multicentre randomised controlled trial. *Lancet*. 2009;374:1351-1363.
2. Moore SA, Dietl CA, Coleman DM. Extracorporeal life support during pregnancy. *J Thorac Cardiovasc Surg*. 2016;151:1154-1160.
3. Anselmi A, Ruggieri VG, Letheulle J, et al. Extracorporeal membrane oxygenation in pregnancy. *J Card Surg*. 2015;30(10):781-786.
4. Pacheco LD, Saade GR, Hankins GDV. Extracorporeal membrane oxygenation (ECMO) during pregnancy and postpartum. *Semin Perinatol*. 2017;42:21-25.
5. Kornbau C, Lee KC, Hughes GD, Firstenberg MS. Central line complications. *Int J Crit Illn Inj Sci*. 2015;5(3):170-178.
6. Depierraz B, Essinger A, Morin D, Goy JJ, Buchser E. Isolated phrenic nerve injury after apparently atraumatic puncture of the internal jugular vein. *Intensive Care Med*. 1989;15:132-134.
7. Topaz O, Sharon M, Rechavia E, Mager A, Chetboun I. Traumatic Internal Jugular Vein Cannulation. *Ann Emerg Med*. 1987;16:1394-1395.
8. Paraskevas GK, Raikos A, Chouliaras K, Papaziogas B. Variable anatomical relationship of phrenic nerve and subclavian vein: clinical implication for subclavian vein catheterization. *Br J Anaesth*. 2011;106:348-351.
9. Gibson G. Diaphragmatic paresis: pathophysiology, clinical features, and investigation. *Thorax*. 1989;44:960-970.
10. Qureshi A. Diaphragm paralysis. *Semin Respir Crit Care Med*. 2009;30:315-320.

How to cite this article: Godcharles C, Safarzadeh M, Oliver EA, Roman A, Al-Kouatly HB. Phrenic nerve injury secondary to extracorporeal membrane oxygenation in pregnancy: A case report. *Clin Case Rep*. 2020;00:1-4. <https://doi.org/10.1002/ccr3.3053>