

A Case Report of Carcinoma Originating from Aberrant Breast Tissue

Kuniki AMANO, Masayuki NISHIKI, Motoi YAMANE, Toshiya MATSUYAMA,
Tsuyoshi KATAOKA, Tsuneo TANAKA and Haruo EZAKI

*The Second Department of Surgery, Hiroshima University School of Medicine, 1-2-3, Kasumi,
Minami-ku, Hiroshima 734, Japan*

(Received October 19, 1984)

Key words: Aberrant breast carcinoma, Treatment strategy

ABSTRACT

A case of breast cancer originating from accessory breast gland tissue is to be presented. Treatment included the subcutaneous removal of the upper half of the mammary gland and the dissection of axillary lymphnodes. As the incidence of aberrant breast carcinoma is rare, a definite prognostic conclusion can not be made at this point. But follow up (5 years) in our case without recurrence will prove that it is enough when the masses were not palpable within the breast.

It is often difficult to judge whether an axillary tumor, exhibiting malignant tissues, is primary or metastatic one. The case reported here is one example in which a mass appearing in the right axilla was identified by histological examinations as breast cancer originating in the accessory mammary gland.

As the possibility of occult breast cancer could not be completely neglected, upper half of mammary gland and the axillary lymphnodes were subcutaneously excised. As a result, it was reconfirmed that the tumor was a breast cancer originating in right accessory breast.

It is widely known that breast cancer occurring in accessory mammary gland is very rare⁴⁾, and we introduce the case with some reviews on concerning published papers.

CASE REPORT

The patient is a 42-year-old female, who found by herself a mass on her right axilla and visited her neighbourhood clinician. She did not feel any pain.

A biopsy was carried out at the clinic, but only fluid was collected. She was left untreated until a mass reappeared and suddenly enlarged 2 months later. A biopsy was carried out again.

It was histologically identified as "mucinous

carcinoma, there being a few normal mammary gland tissues and aberrant tissues in the area around the mass". It was suspected that this was a carcinoma originating in the accessory mammary gland (Fig.1).

However, it was claimed that metastatic breast cancer should still be suspected, and the patient was referred to our department for scrutiny and further treatment.

At the time of the patient's hospitalization, a biopsy scar was found but no masses on either breast or axillary lymphnodes were detected.

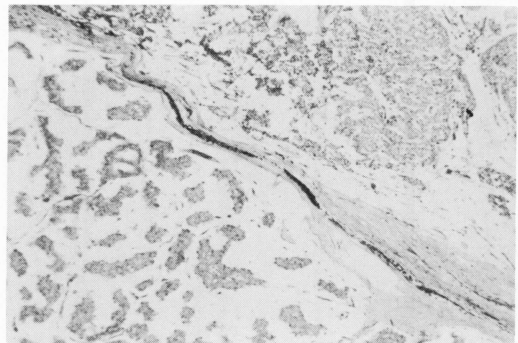


Fig.1. Microscopic appearance
Polygonadal, middle sized cells with pleomorphic round hyperchromatic nuclei can be seen. They grow partially invasive into the normal breast tissue.

EXAMINATIONS

In the mammography, no abnormalities such as the increase in density of the tumor/duct shadows or calcification were detected (Fig.2).

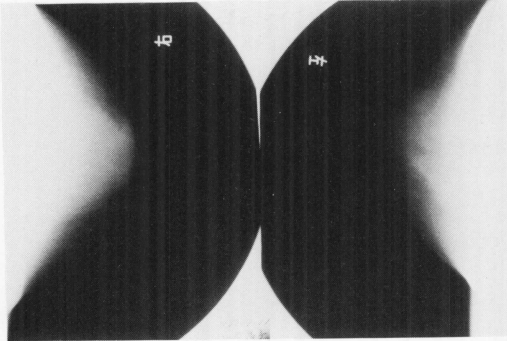


Fig.2. Mammography
No tumor shadow or calcification can be detected.

TREATMENT STRATEGY

The treatment was initiated by the partial removal of the mammary gland and the dissection of the axillary lymphnodes. Taking the possibility of metastasis of occult breast cancer to the axillary lymph nodes into consideration and also for the purpose of proving the mass was breast cancer originating in the accessory mammary gland (Fig.3).

In the excised specimen, 1) there were no metastatic lymphnodes among any of the 16 axillary lymphnodes, but 2) mammary gland tissue was detected on the biopsy scar where cancer cells exhibiting medullary-tubular pattern remained without any continuity with the normal mammary gland tissues (Photograph 1).

At the present time, which is the 5th year of the follow up, the patient is surviving free of disease.

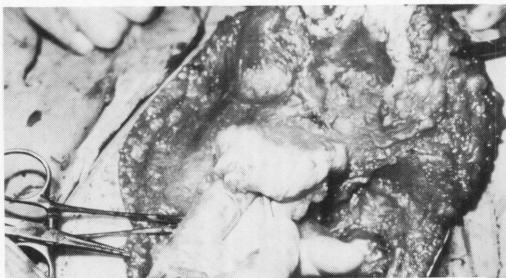


Fig.3. Breast-conserving treatment
The method of removing the upper half of the breast tissue and subsequently all axillary lymphnodes.

DISCUSSION

A distinction must be drawn between supernumerary breasts that have either nipple or areola (or both), in combination with persistent or atrophic gland tissue, and aberrant breast tissue that is without nipple or areola⁵.

Although the incidence of aberrant breast tissue is about 1-2%⁹, it is said to be more prone to malignant change than normal breast parenchyma². And carcinoma occurs more frequently than benign tumors⁵. However, in review of literatures, carcinoma of the accessory breast is rarely reported¹. Chiari⁴ found only 3 cases in a series of 918 patients who were operated on for breast cancer over a 10-year period.

From the pathologic findings in twenty eight cases of axillary breast tissue, Decholnoky⁶ reported that the most common finding was cystic disease and normal tissue. Only one scirrhous carcinoma was observed. And the most common erroneous clinical diagnosis was lipoma.

The case we presented was first clinically diagnosed as lipoma. After the tumor had been excised and examined histologically, it was proved that the carcinoma originated from accessory breast tissue.

The misdiagnosis can be made unless it is borne in mind that the cancer may occur whenever an unusual swelling is seen in the area around the breast during pregnancy or lactation.

The symptoms included swelling, tenderness, and pain or discomfort in using the arm.

Most carcinoma of aberrant breast tissue occurs near the axilla. Copeland and Geshickter⁵ noted seven of nine cases did occur in the axilla and two occurred in the sternal region.

Definite prognostic conclusions cannot be made for want of experience. But the prognosis is thought to be poor, because an early diagnosis is difficult and the tumor exists near the axillary lymphnodes which metastasize earlier than carcinoma of normal breasts do. Copeland and Geshickter⁵ noted only one patient in nine who survived for more than five years. Chiari⁴, however, concluded no differences exists in prognosis between carcinoma in aberrant and normal breast tissue in a review of sixty patients including three cases of his own.

The treatment of aberrant breast tissue consists of exploration for diagnosis followed by sur-

gical treatment with or without X-ray irradiation when cancer is found. At least the radical removal of an adjacent breast should be done if there is any doubt concerning the origin of the carcinoma in aberrant breast tissue.

Smith and Greening⁸⁾ treated by local excision with an additional axillary lymphadenectomy followed by radiotherapy. But the removal of the breast is usually recommended on the basis that lymphatic spread into the breast is likely to occur. Interlandi⁷⁾ experienced a case who had a masked carcinoma of the breast in association with a carcinoma on aberrant breast tissue. The breast-conserving treatment³⁾ we performed was an alternative method to mastectomy. The cosmetic results are better. The method of removing the upper half of the breast tissue which is located adjacent to the tumor and subsequent axillary lymphadenectomy will remain radicality. Follow up to date (5 years) in our case revealed no tumor recurrence and it will be enough when the masses were not palpable within the breast.

REFERENCES

1. **Abedi, K., Salazer, L., Raneri, A.J. and Novin, N.** 1979. Aberrant breast carcinoma: Case report and review of the literature. *MD State Med. J.* May:55-56
2. **Biancheri, T.** 1932. Carcinoma in a node of aberrant accessory mammary tissue. *Pathologica* 24:401-405.
3. **Cedermark, B., Askergrén, J., Alveryd, A., Glas, U., Karnström, L., Somell, A., Theve, N-O. and Wallgren, A.** 1984. Breast-Conserving treatment for breast cancer in Stockholm, Sweden, 1977 to 1981. *Cancer* 53:1253-1255.
4. **Chiari, T.** 1958. Zur Frage des Karzinomas in Aberrantem Brustdrüsengewebe. *Bruns Beitr. Klin. Chir.* 197:307-314.
5. **Copeland, M. M. and Geschickter, C.F.** 1950. Diagnosis and treatment of premalignant lesions of the breast. *Surg. Clins. N. Am.* 30:1717-1741.
6. **De Cholnoky, T.** 1951. Accessory breast tissue in the axilla. *NY State J. Med.* 51:2245-2248.
7. **Interlandi, G. and Minchio, C.** 1979. Carcinoma mammario aberrante. *Min. Chir.* 34:1539-1546.
8. **Smith, G.M.R. and Greening, W.P.** 1972. Carcinoma of aberrant breast tissue, a report of three cases. *Year British J. Surg.* 59:89-90.
9. **Speert, H.** 1942. Supernumerary mammae, with special reference to the rhesus monkey. *Quar. J.* 17:59-68.