

University of Massachusetts Medical School  
eScholarship@UMMS

---

COVID-19 Publications by UMMS Authors

---

2020-07-24

## Sarcoid-like reaction in a patient recovering from coronavirus disease 19 pneumonia

Sara Behbahani  
*Rutgers University - Newark*

*Et al.*

Let us know how access to this document benefits you.

Follow this and additional works at: <https://escholarship.umassmed.edu/covid19>



Part of the [Dermatology Commons](#), [Infectious Disease Commons](#), [Medical Immunology Commons](#), [Pathological Conditions, Signs and Symptoms Commons](#), [Skin and Connective Tissue Diseases Commons](#), and the [Virus Diseases Commons](#)

---

### Repository Citation

Behbahani S, Baltz J, Droms R, Deng AC, Amano SU, Levin NA, O'Brien MC, Wiss K. (2020). Sarcoid-like reaction in a patient recovering from coronavirus disease 19 pneumonia. COVID-19 Publications by UMMS Authors. <https://doi.org/10.1016/j.jdcr.2020.07.026>. Retrieved from <https://escholarship.umassmed.edu/covid19/101>

Creative Commons License



This work is licensed under a [Creative Commons Attribution-NonCommercial-No Derivative Works 4.0 License](#). This material is brought to you by eScholarship@UMMS. It has been accepted for inclusion in COVID-19 Publications by UMMS Authors by an authorized administrator of eScholarship@UMMS. For more information, please contact [Lisa.Palmer@umassmed.edu](mailto:Lisa.Palmer@umassmed.edu).

# Sarcoid-like reaction in a patient recovering from coronavirus disease 19 pneumonia



Sara Behbahani, MS,<sup>a</sup> Julia O. Baltz, MD,<sup>b,c</sup> Rebecca Droms, MD,<sup>b</sup> April C. Deng, MD,<sup>d</sup> Shinya U. Amano, MD, PhD,<sup>d</sup> Nikki A. Levin, MD, PhD,<sup>b</sup> Mary Callery O'Brien, MD,<sup>e</sup> and Karen Wiss, MD<sup>b,f</sup>  
*Newark, New Jersey; Worcester, Massachusetts; East Greenwich, Rhode Island*

**Key words:** coronavirus disease 2019; COVID-19; dermatologic manifestations of disease; sarcoidosis; sarcoid-like reactions; SARS-CoV-2; severe acute respiratory syndrome coronavirus 2.

## INTRODUCTION

As coronavirus disease 2019 (COVID-19) cases continue to increase, so do the reported extrapulmonary manifestations of this disease. To date, described dermatologic manifestations of COVID-19 include pernio-like acral nodules, dengue fever-like petechiae, vesiculobullous eruptions, pityriasis rosea and viral-like exanthems, retiform purpura, and livedo reticularis.<sup>1</sup> We describe a patient with new-onset, biopsy confirmed sarcoid-like reaction in the setting of COVID-19 pneumonia and postulate a role for this immunologic reaction in hastening disease recovery.

## CASE REPORT

A 72-year-old white woman with a medical history of asthma, hypertension, hyperlipidemia, obstructive sleep apnea, and seizure disorder was seen in the dermatology department describing a 2-day history of painful, violaceous nodules on the anterior shins, lateral thighs, submental neck, and glabella. Two weeks prior, she was admitted for treatment of polymerase chain reaction –positive COVID-19–associated pneumonia with no associated skin findings. Upon discharge, her pulmonary symptoms and fatigue resolved, and she subsequently tested negative for severe acute respiratory syndrome coronavirus 2 (SARS-CoV-2). Clinical examination was notable for tender, indurated nodules on the right shin and bilateral lateral thighs and nontender nodules noted on the glabella and submental chin. The anterior shin lesions were suspicious for

### Abbreviations used:

ACE:	angiotensin-converting enzyme
COVID-19:	coronavirus disease 2019
SARS-CoV-2:	severe acute respiratory syndrome coronavirus 2

erythema nodosum (Fig 1). As facial involvement is atypical for this process, biopsies were taken of both the leg and chin. Pathologic findings from both specimens included well-formed noncaseating granulomas in the subcutaneous tissue, suspicious for granulomatous panniculitis and suggestive of sarcoidosis. Erythema nodosum was not favored as the panniculitis was predominantly lobular (Fig 2). Acid-fast, periodic acid–Schiff, and Gram stains were negative, and no evidence of vasculitis was observed.

At one-week follow-up, the patient reported significant simultaneous improvement in size and tenderness of the nodules after twice daily application of clobetasol ointment. The lesions continued to improve but were still present at the last follow-up visit after 25 days from initial onset. A comprehensive workup was unremarkable, including complete blood count, serum angiotensin-converting enzyme (ACE) levels, complete metabolic panel, serum and urine calcium, chest radiograph, and electrocardiogram.

## DISCUSSION

Noncaseating granulomas, often called *sarcoidal granulomas* or a *sarcoid-like immune reaction*, are

From Rutgers New Jersey Medical School, Newark<sup>a</sup>; the Departments of Dermatology,<sup>b</sup> Pathology,<sup>d</sup> Internal Medicine,<sup>e</sup> and Pediatrics,<sup>f</sup> University of Massachusetts Medical School; and Dermatology Professionals, Inc. East Greenwich.<sup>c</sup>

Funding sources: None.

Conflicts of interest: None disclosed.

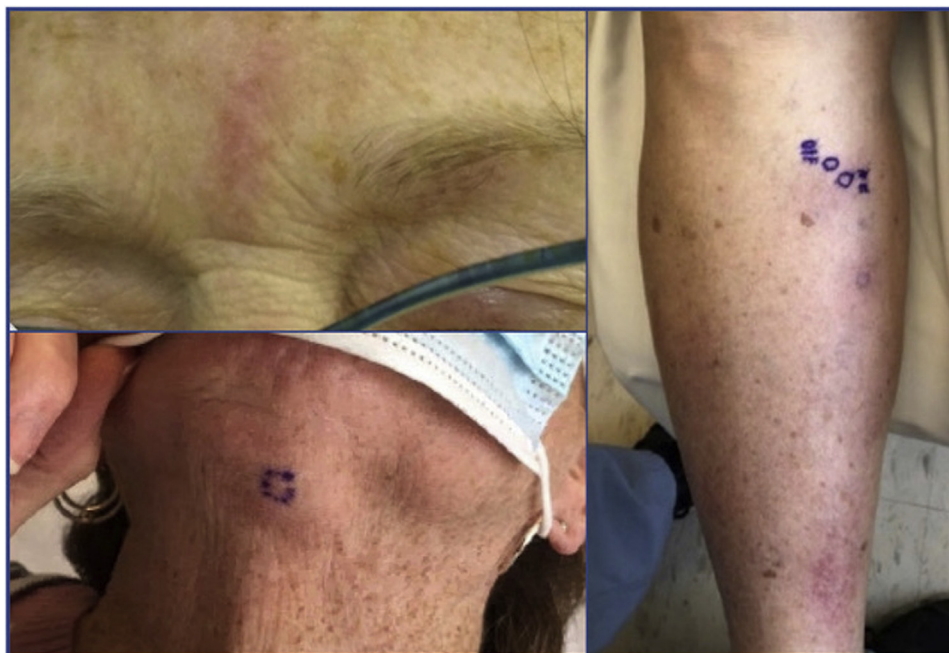
Correspondence to: Julia O. Baltz, MD, Department of Dermatology, University of Massachusetts Memorial Medical Center, 281 Lincoln Street, Worcester, MA 01605. E-mail: [Julia.baltz@umassmemorial.org](mailto:Julia.baltz@umassmemorial.org).

JAAD Case Reports 2020;6:915-7.

2352-5126

© 2020 by the American Academy of Dermatology, Inc. Published by Elsevier, Inc. This is an open access article under the CC BY-NC-ND license (<http://creativecommons.org/licenses/by-nc-nd/4.0/>).

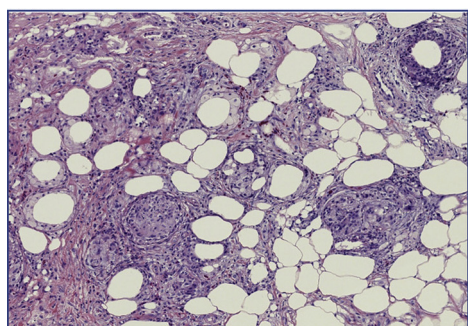
<https://doi.org/10.1016/j.jidcr.2020.07.026>



**Fig 1.** Indurated violaceous nodules on the glabella, submental chin, and anterior shin.

histologically indistinguishable.<sup>2</sup> Although the etiology of sarcoidosis is largely unknown, cross-reaction to an infectious antigen has been proposed as an initiating factor.<sup>3</sup> Sarcoid-like immune reactions are an immunologic response to immunogenic antigens from certain infectious or noninfectious processes and have been documented in patients with occupational exposures to beryllium, zirconium, and aluminum; on immunotherapy for cancer treatment; and in reaction to viral and bacterial infections.<sup>2,4</sup> To our knowledge, no COVID-induced sarcoid-like reactions have been reported.

Because of the close temporal relationship between her eruption and the infection, we propose that the noncaseating granulomas in this case are a



**Fig 2.** Subcutaneous fat notable for well-formed non-caseating sarcoidal granulomas in a predominantly lobular distribution with some spillover into the septae and deep dermis. (Hematoxylin-eosin stain; original magnification:  $\times 20$ .)

sarcoid-like immune reaction to SARS-CoV-2.<sup>2</sup> ACE levels are often elevated in sarcoidosis and sarcoid-like reactions, as ACE is produced by epithelioid cells within granulomas.<sup>5</sup> The ACE2 receptor has been implicated as the entry point for SARS-CoV-2, and expression of this receptor is inversely related to ACE levels; increased ACE levels suppress ACE2 expression and vice versa.<sup>6</sup> It has been theorized that COVID-19 infection leads to downregulation of the ACE2 receptor, thus increasing ACE2 levels.<sup>6</sup> We postulate that, in the case of pulmonary involvement, the ACE-producing noncaseating granulomas in a sarcoid-like immune reaction could act to decrease additional viral induction into cells by further downregulating ACE2 receptor expression. Therefore, sarcoid-like reactions in COVID-19 patients could be a sign of convalescence rather than a sign of acute infection itself, as evidenced by the onset of our patient's cutaneous findings as her disease waned. Although primary sarcoidosis can occur at any age, it is more common in young and middle-aged adults and would be unusual in a patient in her 70s without a history.<sup>7</sup> The rapidly resolving nature of the lesions and negative systemic workup further support COVID-induced sarcoid-like reaction rather than a diagnosis of primary sarcoidosis.

#### REFERENCES

1. Ghazal S, Litvinov IV, Aljahani N, Jfri A, Netchiporouk E. Cutaneous manifestations of coronavirus disease 2019 (COVID-19) infection-what do we know so far? *J Cutan Med Surg.* 2020;24(4):416-417.

2. Mehta AC, Ali SR. Mnemonic for the differential diagnosis of noncaseating granulomas. *Sarcoidosis Vasc Diffuse Lung Dis.* 2017;34(2):200.
3. Celada LJ, Hawkins C, Drake WP. The etiologic role of infectious antigens in sarcoidosis pathogenesis. *Clin Chest Med.* 2015;36(4):561-568.
4. Tchernev G, Tana C, Schiavone C, Cardoso JC, Ananiev J, Wollina U. Sarcoidosis vs. Sarcoid-like reactions: the two sides of the same coin? *Wien Med Wochenschr.* 2014;164(13-14):247-259.
5. Kahkouee S, Samadi K, Alai A, Abedini A, Rezaian L. Serum ace level in sarcoidosis patients with typical and atypical HRCT manifestation. *Pol J Radiol.* 2016;81:458-461.
6. Verdecchia P, Cavallini C, Spanevello A, Angeli F. The pivotal link between ACE2 deficiency and SARS-CoV-2 infection. *Eur J Intern Med.* 2020;76:14-20.
7. Iannuzzi MC, Rybicki BA, Teirstein AS. Sarcoidosis. *N Engl J Med.* 2007;357(21):2153-2165.