

Washington University School of Medicine

Digital Commons@Becker

Open Access Publications

10-1-2020

Does the presence of chondral lesions negatively affect patient-determined outcomes after arthroscopic rotator cuff repair?

Keith M Baumgarten

Peter S Chang

Will E Schweinle

Follow this and additional works at: https://digitalcommons.wustl.edu/open_access_pubs

Does the Presence of Chondral Lesions Negatively Affect Patient-Determined Outcomes After Arthroscopic Rotator Cuff Repair?

Keith M. Baumgarten,^{*†‡} MD, Peter S. Chang,[§] MD, and Will E. Schweinle III,^{||} PhD

Investigation performed at the Orthopedic Institute in Sioux Falls, South Dakota, USA

Background: There are limited data available to guide patients to their prognosis when glenohumeral chondral lesions are found during arthroscopic rotator cuff repair.

Hypothesis: The primary hypothesis was that patients with glenohumeral chondral lesions will have inferior outcomes after arthroscopic rotator cuff repair compared with patients without chondral lesions. The secondary hypothesis was that patients with concomitant chondral lesions will have more severe preoperative symptoms compared with those without chondral lesions.

Study Design: Cohort study; Level of evidence, 3.

Methods: A retrospective analysis was performed of patients who underwent arthroscopic rotator cuff repair between 2008 and 2012. We examined the effects of chondral lesions on patient-determined outcomes, which included the Western Ontario Rotator Cuff Index (WORC), American Shoulder and Elbow Surgeons (ASES) score, Simple Shoulder Test (SST), Single Assessment Numeric Evaluation (SANE), and the Shoulder Activity Level (SAL). Shoulders without chondral lesions were compared with shoulders with chondral lesions to determine whether differences in severity of preoperative symptoms as well as postoperative improvements were statistically significant.

Results: A total of 281 shoulders were included from 273 patients, with a mean follow-up of 3.7 years. In total, 90 shoulders (32%) had concomitant chondral lesions in the glenohumeral joint. The presence and degree of chondral damage were not associated with the severity of preoperative symptoms or the amount of improvement after arthroscopic rotator cuff repair, as determined by patient outcome scores. Shoulders with bipolar chondral lesions had less postoperative improvement in their outcome scores compared with shoulders with unipolar lesions, with significant differences found in the SST ($P = .0005$), the SANE ($P = .005$), and the SAL ($P = .04$). Regardless of this, the majority of shoulders with bipolar chondral lesions (80%-92%) had postoperative improvements that superseded the minimal clinically important difference of the ASES, WORC, and SANE.

Conclusion: At a mean 3.7-year follow-up, the presence of chondral damage did not appear to negatively affect the improvement in patient-determined outcomes after arthroscopic rotator cuff repair. However, improvement in outcomes was negatively affected by the presence of bipolar chondral lesions.

Keywords: arthroscopic rotator cuff repair; glenohumeral chondral lesions; patient-determined outcomes

Arthroscopic rotator cuff repair has become a commonly performed procedure. It is not rare to find concomitant chondral lesions during arthroscopic procedures to treat rotator cuff pathology. Studies^{5,12} have suggested the prevalence of chondral damage and/or osteoarthritis found during arthroscopic rotator cuff repair ranges from 13% to 46%. Currently, there are limited data available to guide patients to their prognosis when concomitant glenohumeral chondral lesions are discovered during arthroscopic

rotator cuff repair.^{5,9,12} Gartsman and Taverna⁵ found that 13% of the patients had concomitant chondral pathology during arthroscopic rotator cuff repair, but they were unable to show the effect of these lesions on patient outcome. The authors believed that “the presence of major cartilage abnormalities might adversely affect the end result” and suggested that further research was required.⁵

The purpose of this study was to evaluate the theory of Gartsman and Taverna⁵ and therefore determine if chondral damage affects both preoperative and postoperative outcomes of arthroscopic rotator cuff repair. The primary hypothesis was that patients with glenohumeral chondral lesions would have inferior outcomes after arthroscopic

The Orthopaedic Journal of Sports Medicine, 8(10), 2325967120957993

DOI: 10.1177/2325967120957993

© The Author(s) 2020

This open-access article is published and distributed under the Creative Commons Attribution - NonCommercial - No Derivatives License (<https://creativecommons.org/licenses/by-nc-nd/4.0/>), which permits the noncommercial use, distribution, and reproduction of the article in any medium, provided the original author and source are credited. You may not alter, transform, or build upon this article without the permission of the Author(s). For article reuse guidelines, please visit SAGE's website at <http://www.sagepub.com/journals-permissions>.

rotator cuff repair compared with patients without chondral damage. The secondary hypothesis was that patients with concomitant chondral lesions and a rotator cuff tear would have more severe preoperative symptoms compared with patients who had rotator cuff tears without glenohumeral chondral lesions. The additional aims of this study were as follows: (1) to determine if the severity of chondral damage, as determined by the Outerbridge classification,^{16,17} would affect the severity of preoperative symptoms or the amount of postoperative improvement in patient-determined outcomes; (2) to determine if the presence of bipolar compared with unipolar chondral lesions would affect postoperative improvement in patient-determined outcomes; and (3) to determine if the surgeon's decision for treatment of the chondral damage would affect postoperative outcomes.

METHODS

Prospective collection of preoperative patient-determined outcome scores on all patients undergoing arthroscopic rotator cuff repair by a single senior surgeon (K.M.B.) began in December 2008. Quality-of-life outcome scores that were collected included the Western Ontario Rotator Cuff Index (WORC)¹¹ (a disease-specific outcome score that has been recommended for assessing the results of rotator cuff repair treatment²⁶), the American Shoulder and Elbow Surgeons (ASES) score,¹⁸ the Simple Shoulder Test (SST)¹³ (a joint-specific outcome measure), and the Single Assessment Numeric Evaluation (SANE)²⁵ (a general health measure). In addition, the Shoulder Activity Level (SAL) was used as the primary activity-level outcome score, as it is a validated measure of a patient's activity level.¹

Patients who underwent primary arthroscopic rotator cuff repair with a concomitant subacromial decompression and who had completed preoperative patient outcome forms were eligible for inclusion in this study. Patients who underwent concomitant acromioclavicular joint resection, biceps tenodesis, and/or labral repair were included to increase the generalizability of the study, as they are often performed clinically along with rotator cuff repairs. Treatment of chondral lesions was determined by the senior author (K.M.B.). Chondroplasty was indicated if there were unstable cartilaginous flaps that might contribute to mechanical symptoms or potentially result in the formation of loose bodies. Microfracture was indicated if there were focal grade 4 chondral defects. Global or diffuse grade 4 changes were left in situ if the senior author determined it to be unlikely that

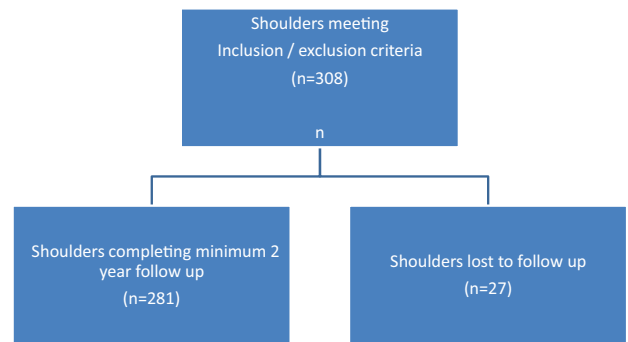


Figure 1. Flowchart of patients lost to follow-up.

microfracture would improve symptoms or change the natural history of the chondral damage. Exclusion criteria were patients with radiographically apparent osteoarthritis (defined as joint-space narrowing, subchondral sclerosis, subchondral cysts, and/or osteophytes); patients undergoing revision rotator cuff repair; patients with rotator cuff arthropathy or irreparable rotator cuff tears; non-English speaking patients; and patients with concomitant cervical radiculopathy, adhesive capsulitis, proximal humerus fracture, or a diagnosis of inflammatory arthritis. Patients with less than 2 years of follow-up were excluded from the patient-determined outcome assessment.

After institutional review board approval was obtained in 2014, a total of 308 shoulders that had arthroscopic rotator cuff repair surgery between 2008 and 2012 and that met inclusion/exclusion criteria were identified. Next, follow-up outcome measures were sent by mail, and each patient was asked to complete the identical outcome scores that were recorded preoperatively to determine the effect of the presence of chondral lesions and the severity of chondral damage, as determined by either the Outerbridge classification^{16,17} or the polarity of the chondral lesions (unipolar vs bipolar) on outcomes before and after rotator cuff repair surgery.

Postoperative patient-determined outcome scores could not be obtained for 27 (9%) of the shoulders (either we were unable to identify an appropriate address to mail the questionnaires, or the patients received but did not return their questionnaires) (Figure 1). Therefore, 281 shoulders were included from 273 patients at a mean follow-up of 3.7 years (range, 2.01-7.47 years). Of these shoulders, 90 (32%) had concomitant chondral lesions of the glenohumeral joint: 37 (41.1%) had chondral lesions isolated to the humeral head; 26 (28.9%) had chondral lesions isolated to the glenoid; and

*Address correspondence to Keith M. Baumgarten, MD, Orthopedic Institute, 810 E 23rd Street, Sioux Falls, SD 57117, USA (email: kbaumga@yahoo.com) (Twitter: @DrBaumgarten).

†Orthopedic Institute, Sioux Falls, South Dakota, USA.

‡University of South Dakota Sanford School of Medicine, Sioux Falls, South Dakota, USA.

§Washington University School of Medicine, St. Louis, Missouri, USA.

||University of South Dakota, Vermillion, South Dakota, USA.

Final revision submitted March 20, 2020; accepted April 7, 2020.

One or more of the authors has declared the following potential conflict of interest or source of funding: K.M.B. has received consulting fees from Wright Medical and speaking fees from Arthrex and Wright Medical. P.S.C. has received educational support from Elite Orthopedics. AOSSM checks author disclosures against the Open Payments Database (OPD). AOSSM has not conducted an independent investigation on the OPD and disclaims any liability or responsibility relating thereto.

Ethical approval for this study was obtained from the University of South Dakota Institutional Review Board (study No. 2014.115).

27 (30%) had chondral lesions on both the humeral head and the glenoid. The highest grade of chondral damage was grade 1 in 25 shoulders, grade 2 in 32 shoulders, grade 3 in 16 shoulders, and grade 4 in 17 shoulders. The mean Outerbridge grade among shoulders with chondral damage was 2.28.

To determine clinically meaningful improvements from the arthroscopic rotator cuff repair, the percentage of shoulders that had improvements equal to or greater than the minimal clinically important difference (MCID) for the WORC, the ASES, and the SANE was reported. According to previous studies,^{14,20,21,26} the MCID for the WORC was an 11.7% change in score, the MCID for the SANE was a 15% change in score, and the MCID for the ASES ranged from a 6.4- to 17-point change in score (100-point scale).

Magnetic resonance imaging was utilized to measure tear size in both the coronal and sagittal planes. The modified Goutallier scale was utilized to measure the presence and degree of atrophy of the rotator cuff musculature.^{4,6}

Statistical analysis was performed using Microsoft Excel 2010 and SAS 9.4 (SAS Institute, 2018). The paired-samples *t* test was conducted on all pre- and posttest scores to determine statistically significant improvements in the quality-of-life scales and the SAL. The Shapiro-Wilk test was performed to determine if the data sets were normally distributed. For data that were not normally distributed, the Mann-Whitney *U* test was performed to confirm that the results of the *t* tests were accurate. Multiple comparisons were analyzed utilizing a 1-way analysis of variance. If a difference among means was determined, a post hoc Student *t* test with Bonferroni correction was performed. Chi-square testing was used to analyze discrete variables. The level of significance was determined to be .05.

RESULTS

Characteristics

Patients with chondral lesions were significantly older than patients without chondral lesions (62.0 vs 57.4 years; $P < .0001$). However, there was no difference in patient age when stratifying the severity of chondral damage by Outerbridge classification among those patients with chondral lesions ($P = .86$). There were no sex-based differences in those who had chondral lesions (34 females; 38%) and those who did not (63 females; 33%; $P = .43$). The length of follow-up was not statistically different between groups (3.8 years [no chondral lesions] vs 3.6 years [chondral lesions]; $P = .35$).

Tendons Affected

Shoulders with chondral lesions were more likely to have a subscapularis tear requiring repair than shoulders without chondral lesions (45.6% vs 33.2%; $P = .04$). Otherwise, there was no difference between the groups regarding percentage requiring a supraspinatus repair (93.3% vs 91.9%; $P = .52$) or an infraspinatus repair (14.4% vs 11.1%; $P =$

.41). Shoulders with chondral lesions had a greater number of tendons requiring repair than shoulders without chondral lesions (1.54 vs 1.35 tendons; $P = .009$).

Tear Size

Shoulders with chondral lesions had larger supraspinatus and/or infraspinatus tears (coronal plane = 24 ± 11 vs 21 ± 11 mm; $P = .01$; sagittal plane = 20 ± 9 vs 19 ± 9 mm; $P = .15$; area = 554 ± 445 vs 462 ± 450 mm²; $P = .02$) and required more anchors for the repair compared with shoulders without chondral lesions (4.62 vs 4.29 anchors; $P = .04$).

Atrophy

Shoulders with chondral lesions were more likely to have atrophy (Goutallier stage 1-4) found in the supraspinatus, infraspinatus, and/or subscapularis versus shoulders without chondral lesions (42.7% vs 26.9%; $P = .008$), and the average Goutallier score was higher in the chondral lesion group (supraspinatus: 0.4 ± 0.7 vs 0.3 ± 0.7 ; $P = .44$; infraspinatus: 0.4 ± 0.8 vs 0.3 ± 0.7 ; $P = .24$; subscapularis: 0.3 ± 0.8 vs 0.2 ± 0.6 ; $P = .03$).

Concomitant Procedures

Overall, 17 shoulders with chondral damage underwent chondroplasty (grade 2 = 5; grade 3 = 10; grade 4 = 2). Nine grade 4 shoulders underwent a microfracture procedure. When comparing shoulders with and without chondral lesions, respectively, there was no difference in the percentage of shoulders undergoing concomitant labral repair (13.3% vs 10.5%; $P = .48$), biceps tenodesis (50% vs 44.7%; $P = .39$), or acromioclavicular joint resection (57.8% vs 56.5%; $P = .85$).

Effect of Chondral Lesions on Preoperative Outcome Scores

The presence of chondral lesions and the degree of chondral damage was not associated with severity of preoperative symptoms as determined by patient outcome scores. No statistically significant differences were found in preoperative outcome scores in shoulders with versus without chondral lesions (Table 1). In addition, there was no statistically significant difference in preoperative outcome scores among shoulders with varying degrees of chondral damage as determined by the Outerbridge score (Table 2).

Effect of Chondral Damage on Postoperative Improvement in Outcome Scores

There was statistically significant pre- to postoperative improvement in all quality-of-life scores for both groups ($P < .0001$). However, there was a decrease in the SAL in both the chondral lesion group (mean pre- to postoperative difference, -1.1 ; $P = .1$) and the no chondral lesion

TABLE 1

Mean Preoperative Patient-Determined Outcome Scores^a

	No Chondral Lesions	Chondral Lesions	<i>P</i>
WORC	41.9	42.8	.66
ASES	40.9	42.5	.38
SST	4.5	4.7	.59
SANE	37.0	37.4	.91
SAL	11.9	11.1	.21

^aASES, American Shoulder and Elbow Surgeons; SAL, Shoulder Activity Level; SANE, Single Assessment Numeric Evaluation; SST, Simple Shoulder Test; WORC, Western Ontario Rotator Cuff Index.

TABLE 2

Mean Preoperative Patient-Determined Outcome Scores Stratified by Outerbridge Grade of Chondral Damage^a

	Grade 0	Grade 1	Grade 2	Grade 3	Grade 4	<i>P</i>
WORC	41.9	46.9	41.5	39.9	41.4	.60
ASES	40.9	45.7	41.1	38.4	44.2	.59
SST	4.5	4.6	4.9	4.0	4.9	.83
SANE	36.8	34	41.7	30.5	40.4	.43
SAL	11.9	10.5	12.6	9.5	10.9	.11

^aASES, American Shoulder and Elbow Surgeons; SAL, Shoulder Activity Level; SANE, Single Assessment Numeric Evaluation; SST, Simple Shoulder Test; WORC, Western Ontario Rotator Cuff Index.

TABLE 3

Mean Postoperative Improvement in Patient-Determined Outcome Scores^a

	No Chondral Lesions	Chondral Lesions	<i>P</i>
WORC	46.5	45.6	.77
ASES	47.2	45.3	.34
SST	5.8	5.1	.29
SANE	52.0	50.8	.88
SAL	-1.4	-1.1	.64

^aASES, American Shoulder and Elbow Surgeons; SAL, Shoulder Activity Level; SANE, Single Assessment Numeric Evaluation; SST, Simple Shoulder Test; WORC, Western Ontario Rotator Cuff Index.

group (mean difference, -1.4; *P* = .001). The presence and degree of chondral damage were not associated with the amount of improvement as determined by patient-determined outcome scores. When comparing shoulders with versus without chondral lesions, we found no statistically significant differences regarding postoperative improvement (Table 3) and no differences regarding percentage of shoulders that achieved at least the MCID in postoperative improvement (Table 4) for any of the patient outcome scores. In addition, there were no statistically significant differences in postoperative improvement between shoulders with varying degrees of chondral damage (Table 5).

TABLE 4

Percentage of Patients Achieving at Least the MCID in Postoperative Improvement After Rotator Cuff Repair With or Without Concomitant Chondral Lesions^a

	No Chondral Lesions, %	Chondral Lesions, %	<i>P</i>
WORC (MCID, 11.7%)	94.9	96.5	.55
ASES (MCID, 6.4)	95.2	95.5	.93
ASES (MCID, 17)	90.7	92.0	.72
SANE (MCID, 15%)	93.2	91.4	.61

^aASES, American Shoulder and Elbow Surgeons; MCID, minimal clinically important difference; SANE, Single Assessment Numeric Evaluation; WORC, Western Ontario Rotator Cuff Index.

TABLE 5

Mean Postoperative Improvement in Patient-Determined Outcome Scores Stratified by Outerbridge Grade of Chondral Damage^a

	Grade 0	Grade 1	Grade 2	Grade 3	Grade 4	<i>P</i>
WORC	46.5	42.1	48.4	47.5	44.5	.80
ASES	47.2	42.2	50.3	42.3	43.6	.56
SST	5.8	5.9	5.7	4.5	4.4	.28
SANE	52.0	54.7	49.5	54.2	44.3	.70
SAL	-1.4	-0.2	-0.8	-2.1	-1.1	.74

^aASES, American Shoulder and Elbow Surgeons; SAL, Shoulder Activity Level; SANE, Single Assessment Numeric Evaluation; SST, Simple Shoulder Test; WORC, Western Ontario Rotator Cuff Index.

Effect of the Treatment of Chondral Lesions on Postoperative Outcome Scores

When examining the postoperative improvement in outcome scores for the different treatment interventions specific to the chondral damage, we found no differences between the cartilage lesions treated with chondroplasty versus microfracture versus no treatment (Table 6).

Unipolar Versus Bipolar Chondral Lesions

On average, shoulders with bipolar chondral lesions had more severe chondral damage, as determined by mean Outerbridge classification scores, compared with shoulders with unipolar chondral lesions (2.9 vs 2.0; *P* = .001). Shoulders with bipolar lesions had less postoperative improvement in outcome scores compared with shoulders with unipolar lesions, with statistically significant differences found in the SST (*P* = .0005), the SANE (*P* = .005), and the SAL (*P* = .04) (Table 7). Shoulders with bipolar lesions were less likely to meet the MCID for the SANE compared with those with unipolar lesions (80.8% vs 98.4%; *P* = .003) (Table 8).

There was a trend for the senior surgeon to perform treatment for chondral defects in patients with bipolar chondral lesions compared with patients with unipolar lesions

TABLE 6
Mean Postoperative Improvement in Patient-Determined Outcome Scores in Shoulders With and Without Treatment for Chondral Damage^a

	No treatment	Chondroplasty	Microfracture	P
WORC	45.2	45.7	48	.93
ASES	47.1	39.9	42.4	.41
SST	5.6	5.1	5	.83
SANE	51.9	51.0	42.6	.61
SAL	-1.0	-2.4	1	.31

^aASES, American Shoulder and Elbow Surgeons; SAL, Shoulder Activity Level; SANE, Single Assessment Numeric Evaluation; SST, Simple Shoulder Test; WORC, Western Ontario Rotator Cuff Index.

TABLE 7
Mean Postoperative Improvement in Patient-Determined Outcome Scores in Shoulders With Unipolar and Bipolar Chondral Lesions^a

	Unipolar Chondral Lesions	Bipolar Chondral Lesions	P
WORC	48.1	39.7	.05
ASES	48.0	39.2	.06
SST	6.2	3.6	.0005
SANE	55.7	39	.005
SAL	-0.3	-2.9	.04

^aASES, American Shoulder and Elbow Surgeons; SAL, Shoulder Activity Level; SANE, Single Assessment Numeric Evaluation; SST, Simple Shoulder Test; WORC, Western Ontario Rotator Cuff Index.

TABLE 8
Percentage of Patients Achieving at Least the MCID in Postoperative Improvement After Arthroscopic Rotator Cuff Repair With Unipolar and Bipolar Chondral Lesions^a

	Unipolar Chondral Lesions, %	Bipolar Chondral Lesions, %	P
WORC (MCID, 11.7%)	98.3	92.3	.16
ASES (MCID, 6.4)	98.4	88.9	.049
ASES (MCID, 17)	93.3	84.6	.20
SANE (MCID, 15%)	98.4	80.8	.003

^aASES, American Shoulder and Elbow Surgeons; MCID, minimal clinically important difference; SANE, Single Assessment Numeric Evaluation; WORC, Western Ontario Rotator Cuff Index.

(chondroplasty = 22.2% vs 17.5%; microfracture = 14.8% vs 7.9%); however, this was not statistically significant ($P = .48$). There was no statistically significant difference found in rotator cuff tear size in patients with bipolar chondral lesions compared with unipolar chondral lesions (coronal, 26 ± 11 vs 23 ± 11 mm; $P = .40$) (sagittal, 22 ± 8 vs 20 ± 9 mm; $P = .21$) (area, 620 ± 432 vs 528 ± 452 mm²; $P = .25$). However, shoulders with bipolar chondral lesions were more

likely to have atrophy (Goutallier stage 1-4) found in the supraspinatus, infraspinatus, and/or subscapularis (58% vs 37%; $P = .07$). For infraspinatus atrophy, the average Goutallier scores were significantly higher in the bipolar chondral lesions group compared with the unipolar chondral lesion group (0.8 ± 1.2 vs 0.2 ± 0.5 ; $P = .01$), but there were no significant differences in the mean Goutallier score for the supraspinatus (0.5 ± 0.9 vs 0.3 ± 0.6 ; $P = .45$) or the subscapularis (0.3 ± 0.7 vs 0.4 ± 0.8 ; $P = .48$) between groups.

DISCUSSION

The primary hypothesis of this study was not supported by the analysis of our data. In general, patients with chondral lesions did not have inferior postoperative patient-determined outcomes compared with patients without concomitant chondral lesions undergoing arthroscopic rotator cuff repair. However, we did find that the presence of bipolar chondral lesions was a risk factor for having inferior postoperative outcomes compared with patients with unipolar lesions. This finding is supported by previous studies^{10,15,22} that have shown that, in patients without rotator cuff tears, those with bipolar chondral lesions had worse outcomes versus those with unipolar lesions. In the current study, although the results of patients with bipolar chondral lesions were inferior to patients with unipolar or no chondral damage, the majority of patients (80%-92%) with bipolar chondral lesions did achieve postoperative improvements that met the MCID for the patient-determined outcome scores. Thus, this study suggests that even in the presence of bipolar chondral lesions, most patients achieved clinically significant improvement after undergoing arthroscopic rotator cuff repair.

The secondary hypothesis was not supported as well. Patients with chondral damage who underwent arthroscopic rotator cuff repair did not have more severe symptoms preoperatively versus patients without chondral damage, as determined by patient-determined outcome scores.

There are few other studies that have examined the effect of glenohumeral chondral damage on the outcomes of arthroscopic rotator cuff repair. In a study examining arthroscopic and open repair of large to massive rotator cuff tears, Jeong et al⁹ did not find any difference in clinical outcomes in patients with and without radiographically apparent osteoarthritis. That study⁹ differed from our study in that arthroscopic assessment for chondral damage was not performed, and small- and medium-sized rotator cuff tears were excluded. Kukkonen et al¹² performed a study on 85 shoulders that underwent arthroscopic rotator cuff repair with 1-year follow-up and found that 27% of patients had radiographically apparent arthritis preoperatively, and 46% had Outerbridge changes that were apparent arthroscopically. Unlike our study, intraoperative detection of osteoarthritis was associated with a lower Constant score both preoperatively and postoperatively.

A limitation of our study is that the Outerbridge classification is a qualitative and not quantitative classification. Currently, there is not a validated or reliable method to determine the surface area affected by the chondral

damage, thus we were unable to determine if outcomes in patients undergoing rotator cuff repair with grade 2 chondral lesions with a large surface area have worse outcomes versus patients with grade 4 chondral lesions with a small surface area. Regardless of the limitations of the Outerbridge classification, we were able to investigate the hypotheses of this study, and we believe that this study provides the best available evidence to date of the effects of chondral damage on rotator cuff repair outcomes.

Our study did not demonstrate improved outcomes in patients undergoing concomitant operative treatment of their chondral lesions (chondroplasty and/or microfracture) compared with chondral lesions that were left untreated. However, the methodology of our study was not designed to determine if operative treatment of chondral lesions was effective, as it was limited by selection bias (subjective decision making by the surgeon to perform cartilage treatment) and small sample size (17 chondroplasties, 9 microfractures). Regardless of this, multiple studies^{2,3,7,8,19,22-24} have demonstrated the effectiveness of both chondroplasty and microfracture in the treatment of chondral damage. Similar to our study, Kerr and McCarty¹⁰ demonstrated that when treating chondral injuries without rotator cuff tears, outcomes were similar regardless of whether the Outerbridge classification was grade 2-3 or grade 4.

One further limitation of this study was that patients did not return to the clinic for a physical examination or radiographs to determine if there was any progression of the chondral lesions to radiographically apparent osteoarthritis. Although this would have made our study more comprehensive, it did not limit our ability to investigate the study hypotheses.

CONCLUSION

This study provides clinicians with valuable information they may use to educate their patients as to the expected outcomes of arthroscopic rotator cuff repair when chondral damage is found intraoperatively. At a mean 3.7-year follow-up, the presence of chondral lesions found intraoperatively did not negatively affect the improvement in patient-determined outcome scores after arthroscopic rotator cuff repair. However, outcome improvement was negatively affected by the presence of bipolar chondral lesions compared with unipolar lesions. Regardless of this, most of the patients with bipolar chondral lesions maintained postoperative improvements that superseded the MCID for the patient-determined outcome scores at final follow-up.

REFERENCES

- Brophy RH, Beauvais RL, Jones EC, Cordasco FA, Marx RG. Measurement of shoulder activity level. *Clin Orthop Relat Res*. 2005;439:101-108.
- Cameron BD, Galatz LM, Ramsey ML, Williams GR, Iannotti JP. Nonprosthetic management of grade IV osteochondral lesions of the glenohumeral joint. *J Shoulder Elbow Surg*. 2002;11(1):25-32.
- Frank RM, Van Thiel GS, Slabaugh MA, Romeo AA, Cole BJ, Verma NN. Clinical outcomes after microfracture of the glenohumeral joint. *Am J Sports Med*. 2010;38(4):772-781.
- Fuchs B, Weishaupt D, Zanetti M, Hodler J, Gerber C. Fatty degeneration of the muscles of the rotator cuff: assessment by computed tomography versus magnetic resonance imaging. *J Shoulder Elbow Surg*. 1999;8(6):599-605.
- Gartsman GM, Taverna E. The incidence of glenohumeral joint abnormalities associated with full-thickness, reparable rotator cuff tears. *Arthroscopy*. 1997;13(4):450-455.
- Goutallier D, Postel JM, Bernageau J, Lavau L, Voisin MC. Fatty muscle degeneration in cuff ruptures. Pre- and postoperative evaluation by CT scan. *Clin Orthop Relat Res*. 1994;304:78-83.
- Gross CE, Chalmers PN, Chahal J, et al. Operative treatment of chondral defects in the glenohumeral joint. *Arthroscopy*. 2012;28(12):1889-1901.
- Hunnebeck SM, Magosch P, Habermeyer P, Loew M, Lichtenberg S. Chondral defects of the glenohumeral joint: long-term outcome after microfracturing of the shoulder. *Obere Extremit*. 2017;12(3):165-170.
- Jeong HY, Jeon YS, Lee DK, Rhee YG. Rotator cuff tear with early osteoarthritis: how does it affect clinical outcome after large to massive rotator cuff repair? *J Shoulder Elbow Surg*. 2019;28(2):237-243.
- Kerr BJ, McCarty EC. Outcome of arthroscopic debridement is worse for patients with glenohumeral arthritis of both sides of the joint. *Clin Orthop Relat Res*. 2008;466(3):634-638.
- Kirkley A, Alvarez C, Griffin S. The development and evaluation of a disease-specific quality-of-life questionnaire for disorders of the rotator cuff: The Western Ontario Rotator Cuff Index. *Clin J Sport Med*. 2003;13(2):84-92.
- Kukkonen J, Joukainen A, Lehtinen J, Aarimaa V. The effect of glenohumeral osteoarthritis on the outcome of isolated operatively treated supraspinatus tears. *J Orthop Sci*. 2013;18(3):405-409.
- Matsen FA 3rd, Ziegler DW, DeBartolo SE. Patient self-assessment of health status and function in glenohumeral degenerative joint disease. *J Shoulder Elbow Surg*. 1995;4(5):345-351.
- Michener LA, McClure PW, Sennett BJ. American Shoulder and Elbow Surgeons Standardized Shoulder Assessment Form, patient self-report section: reliability, validity, and responsiveness. *J Shoulder Elbow Surg*. 2002;11(6):587-594.
- Millett PJ, Huffard BH, Horan MP, Hawkins RJ, Steadman JR. Outcomes of full-thickness articular cartilage injuries of the shoulder treated with microfracture. *Arthroscopy*. 2009;25(8):856-863.
- Outerbridge RE. The etiology of chondromalacia patellae. *J Bone Joint Surg Br*. 1961;43-B:752-757.
- Outerbridge RE. Further studies on the etiology of chondromalacia patellae. *J Bone Joint Surg Br*. 1964;46:179-190.
- Richards RR, An KN, Bigliani LU, et al. A standardized method for the assessment of shoulder function. *J Shoulder Elbow Surg*. 1994;3(6):347-352.
- Snow M, Funk L. Microfracture of chondral lesions of the glenohumeral joint. *Int J Shoulder Surg*. 2008;2(4):72-76.
- Tashjian RZ, Deloach J, Green A, Porucznik CA, Powell AP. Minimal clinically important differences in ASES and simple shoulder test scores after nonoperative treatment of rotator cuff disease. *J Bone Joint Surg Am*. 2010;92(2):296-303.
- Thigpen CA, Shanley E, Momaya AM, et al. Validity and responsiveness of the single alpha-numeric evaluation for shoulder patients. *Am J Sports Med*. 2018;46(14):3480-3485.
- Van Thiel GS, Sheehan S, Frank RM, et al. Retrospective analysis of arthroscopic management of glenohumeral degenerative disease. *Arthroscopy*. 2010;26(11):1451-1455.
- Wang KC, Frank RM, Cotter EJ, et al. Long-term clinical outcomes after microfracture of the glenohumeral joint: average 10-year follow-up. *Am J Sports Med*. 2018;46(4):786-794.
- Weinstein DM, Bucchieri JS, Pollock RG, Flatow EL, Bigliani LU. Arthroscopic debridement of the shoulder for osteoarthritis. *Arthroscopy*. 2000;16(5):471-476.
- Williams GN, Gangel TJ, Arciero RA, Uhorchak JM, Taylor DC. Comparison of the single assessment numeric evaluation method and two shoulder rating scales. Outcomes measures after shoulder surgery. *Am J Sports Med*. 1999;27(2):214-221.
- Wright RW, Baumgarten KM. Shoulder outcomes measures. *J Am Acad Orthop Surg*. 2010;18(7):436-444.