

Washington University School of Medicine

Digital Commons@Becker

---

Open Access Publications

---

2020

**Interleukin-15 superagonist (N-803) treatment of PML and JCV in a post-allogeneic hematopoietic stem cell transplant patient**

Aabha Oza

Michael P. Rettig

Phil Powell

Kathryn O'Brien

David B. Clifford

*See next page for additional authors*

Follow this and additional works at: [https://digitalcommons.wustl.edu/open\\_access\\_pubs](https://digitalcommons.wustl.edu/open_access_pubs)

---

---

**Authors**

Aabha Oza, Michael P. Rettig, Phil Powell, Kathryn O'Brien, David B. Clifford, Julie Ritchey, Leah Gehrs, Julia Hollaway, Eugene Major, Todd A. Fehniger, Christopher A. Miller, Patrick Soon-Shiong, Amy Rock, and John F. DiPersio

---

# Interleukin-15 superagonist (N-803) treatment of PML and JCV in a post-allogeneic hematopoietic stem cell transplant patient

Aabha Oza,<sup>1,\*</sup> Michael P. Rettig,<sup>1,\*</sup> Phil Powell,<sup>1</sup> Kathryn O'Brien,<sup>1</sup> David B. Clifford,<sup>2</sup> Julie Ritchey,<sup>1</sup> Leah Gehrs,<sup>1</sup> Julia Hollaway,<sup>1</sup> Eugene Major,<sup>3</sup> Todd A. Fehniger,<sup>1</sup> Christopher A. Miller,<sup>4</sup> Patrick Soon-Shiong,<sup>5</sup> Amy Rock,<sup>5</sup> and John F. DiPersio<sup>1</sup>

<sup>1</sup>Division of Oncology and <sup>2</sup>Department of Neurology, Washington University in St. Louis, St. Louis, MO; <sup>3</sup>Laboratory of Molecular Medicine and Neuroscience, National Institute of Neurological Disorders and Stroke, National Institutes of Health, Bethesda, MD; <sup>4</sup>McDonnell Genome Institute, Washington University in St. Louis, St. Louis, MO; and <sup>5</sup>ImmunityBio, Inc., Culver City, CA

## Key Points

- Therapy with an IL-15 superagonist resulted in immune and clinical responses in a transplant recipient with PML.

## Introduction

Progressive multifocal leukoencephalopathy (PML) is a rare demyelinating disease of the central nervous system caused by reactivation of the John Cunningham virus (JCV). JCV is common; however, most infected patients will remain asymptomatic.<sup>1</sup> In the setting of immunosuppression, including after allogeneic hematopoietic cell transplant (HCT), the virus is transformed and may infect oligodendrocytes, causing a course of progressive neurologic decline. PML is generally rapidly fatal. There is no effective antiviral treatment of JCV or PML, but immune reconstitution is essential. In the post-HCT setting, the risk of developing PML does not appear to have an end point, and time to development of symptoms can range from weeks to decades.

Interleukin-15 (IL-15) is critical for the proliferation and activation of natural killer (NK) cells and CD8<sup>+</sup> memory T cells. N-803, a novel IL-15 superagonist, contains a mutant form of IL-15 (N72D), in complex with the soluble domain of the IL-15 receptor (IL-15R $\alpha$ ), resulting in a prolonged serum half-life and increased biologic activity compared with wild-type IL-15.<sup>2</sup> Here, we report a case of PML following allogeneic HCT in which neurological improvement occurred following treatment with N-803.

## Case description

A 27-year-old HIV-negative male with no significant medical history was diagnosed with T-cell acute lymphoblastic leukemia in January 2016. The patient was treated according to Cancer and Leukemia Group B 10403. Cerebrospinal fluid (CSF) cytology was negative at diagnosis and remained negative throughout therapy. Following a 10/10 matched-unrelated donor allogeneic HCT in May 2016, the patient achieved minimal residual disease negativity with complete donor engraftment. All immunosuppression was tapered off by February 2017. CD4 count at this time was 458. The patient was free of any neurologic deficits and was able to return to work full time.

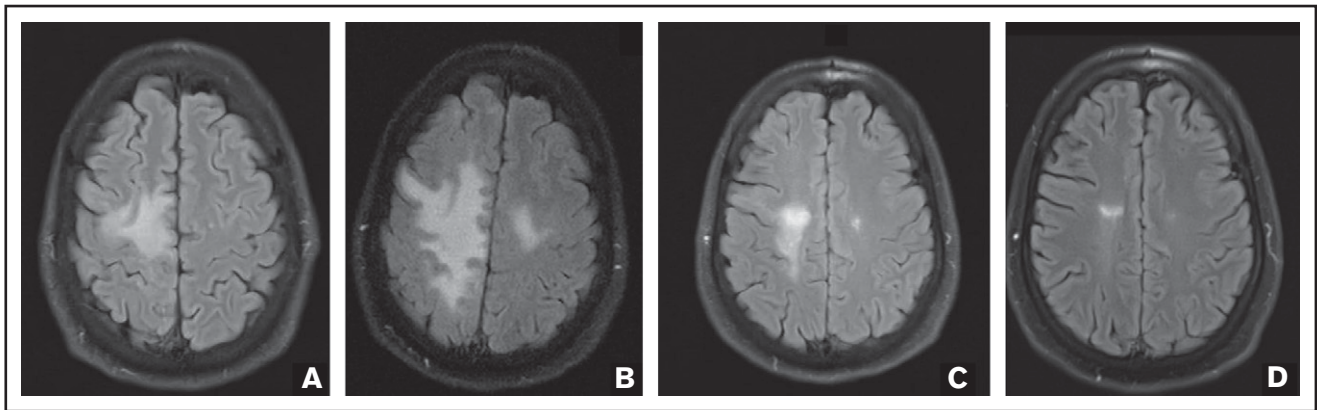
On 14 July 2017, 460 days posttransplant, the patient presented with left shoulder pain, left arm heaviness, and asymmetric left shoulder fullness but no weakness or neurologic deficits. There was no history of injuries or trauma. Cervical spine magnetic resonance imaging (MRI) was unremarkable, and CSF analysis showed no evidence of leukemia. Ten days later, he developed new weakness in the left lower and upper extremities, with loss of fine motor skills in the left hand and diminished deep tendon reflexes in the left upper and lower extremities but no numbness or sensory deficits. A short course of prednisone (2 mg/kg  $\times$  7 days) was administered, with no improvement.

Over the next week, the patient's weakness progressed to paralysis, and he was no longer able to ambulate, requiring a wheelchair. Brain MRI showed a posterior right frontal subcortical white matter lesion, hyperintense on T2/fluid-attenuated inversion recovery (FLAIR) without enhancement or diffuse restriction, concerning for PML. A repeat lumbar puncture was performed, and qualitative polymerase chain reaction (PCR) was positive for JCV, confirming the diagnosis. Mefloquine (250 mg daily  $\times$  3 days, then 250 mg weekly) and mirtazapine 30 mg daily were initiated on 7 August 2017. Due to lack of

Submitted 8 July 2019; accepted 2 April 2020; published online 2 June 2020. DOI 10.1182/bloodadvances.2019000664.

\*A.O. and M.P.R. contributed equally to this study.

For data sharing, e-mail the corresponding author, John F. DiPersio (jdispersio@wustl.edu).



**Figure 1. FLAIR MRI images.** Axial FLAIR MRI images were obtained before initiation of N-803 (A), after 2 cycles (B) and 8 cycles (C) of N-803, and 759 days after initiation of N-803 (D), demonstrating improvement in the posterior right frontal subcortical white matter lesion.

improvement and progression of weakness after 14 days, N-803, an IL-15 superagonist, (6  $\mu\text{g}/\text{kg}$  subcutaneously on days 1, 8, 15, and 22 of a 28-day cycle) was added under compassionate use (single-patient IND #136501) from the US Food and Drug Administration on 21 August 2017.

## Methods

### Flow cytometry

Cryopreserved peripheral blood mononuclear cells (PBMCs) were analyzed by flow cytometry as previously described.<sup>3</sup>

VP1-specific CD8<sup>+</sup> T cells (peptides VP1<sub>69</sub>-ESDSPNRDMLPCY, VP1<sub>183</sub>-NTEHKAYLDKNKAY, and VP1<sub>329</sub>-GTEELPGDPDMMRY from New England Peptide, Gardner, MA) were loaded into HLA-A\*01 monomers by UV-mediated exchange and multimers were generated using streptavidin-conjugated phycoerythrin or allophycocyanin (Invitrogen, Carlsbad, CA).<sup>4</sup> PBMCs were cultured with peptides for 12 days (primary stimulation) or 19 days (secondary stimulation with peptides on day 12), dual stained with tetramers, and analyzed by flow cytometry.

## Results and discussion

Repeat brain MRI after 2 N-803 cycles on 16 October 2017 showed a worsening extent of the FLAIR abnormality (Figure 1). However, the patient's strength was improving, and treatment was continued. Subsequent brain MRIs demonstrated marked improvement in the T2/FLAIR white matter lesions, and the most recent brain MRI, 759 days after initiation of N-803, continued to demonstrate response. Qualitative CSF JCV PCR has remained undetected since December 2017. CSF specimens were sent to the National Institutes of Health (NIH) for ultrasensitive quantitative JCV PCR, and the DNA copy number decreased from 31 copies/mL in December 2017 to 16 copies/mL in February 2018 and 11 copies/mL in April 2018. Identification of the JCV DNA variant as prototype was performed at the NIH using the Multiplex qPCR assay. N-803 was stopped after 8 total cycles, and the patient continues to take mefloquine and mirtazapine. His neurologic deficits continue to improve, and he is now able to ambulate with a cane. His last follow-up examination was April 2020 (+926 days after initiation of N-803 therapy), and he remains stable with slow and steady neurologic improvement and no evidence of graft-versus-host disease or acute myeloid leukemia.

While the absolute number of circulating T and B cells decreased during N-803 treatment, we observed a more than threefold increase in the number of circulating CD56<sup>bright</sup> and CD56<sup>dim</sup> NK cells (Figure 2A). Phenotyping of peripheral blood T cell subsets revealed little to no changes within the CD3<sup>+</sup>CD4<sup>+</sup> T cell subsets (Figure 2B-F). In contrast, there was a decrease in the relative percentage of naive CD3<sup>+</sup>CD8<sup>+</sup> T cells with a concomitant increase in effector memory and effector memory RA cells during N-803 treatment. This shift in the CD3<sup>+</sup>CD8<sup>+</sup> T cell population toward an effector phenotype was accompanied by an increase in the number of CXCR3-expressing cells as well as evidence of cell activation as determined by increased expression of CD38, HLA-DR, perforin, granzyme B, and the proliferation marker Ki-67 (Figure 2B-F). These findings are consistent with previously reported data.<sup>5,6</sup>

Using the Immune Epitope Database major histocompatibility complex class I peptide-binding prediction algorithm, we found 3 putative antigens from the JCV major capsid protein VP1 with predicted binding (50% inhibitory concentration <500 nM) to the patient's HLA-A\*01:01 allele. We stimulated PBMCs obtained before and after N-803 treatment with the VP1-derived peptides and stained cultures with peptide-specific HLA-A\*01:01 tetramers. No JCV VP1 peptide-specific CD8<sup>+</sup> T cells were detected (data not shown).

This report further suggests that N-803 may enhance the clearance and resolution of a viral illness in humans. A preclinical study in monkeys showed that N-803 leads to suppressed replication of an HIV-like virus.<sup>7</sup> Preliminary data in HIV-positive patients demonstrated increased numbers of CD4<sup>+</sup> and CD8<sup>+</sup> T cells, increased NK cells, and increased HIV transcription following N-803.<sup>8</sup> In the post-HCT setting, N-803 administration significantly increased NK and CD8<sup>+</sup> T cells numbers and function. This phenotype was associated with temporary cytomegalovirus clearance<sup>9</sup> and may enhance the clearance of relapsed/refractory acute myeloid leukemia, without increasing rates of immunosuppression-requiring graft-versus-host disease.<sup>5</sup> Thus, N-803 may augment antitumor and antiviral immunity in humans.

Novel therapeutic approaches for PML have included immunotherapy, and case reports supporting the use of IL-2,<sup>10-13</sup> IL-7,<sup>14-20</sup> vaccination,<sup>20,21</sup> PD-1 inhibitors,<sup>22-26</sup> and adoptive T cell therapy<sup>27,28</sup> have been published. Lymphopenia is the main risk factor for PML, and the lesions typically lack a lymphocytic infiltrate. Upon immune





12. Przepiorka D, Jaeckle KA, Birdwell RR, et al. Successful treatment of progressive multifocal leukoencephalopathy with low-dose interleukin-2. *Bone Marrow Transplant.* 1997;20(11):983-987.
13. Re D, Bamborschke S, Feiden W, et al. Progressive multifocal leukoencephalopathy after autologous bone marrow transplantation and alpha-interferon immunotherapy. *Bone Marrow Transplant.* 1999;23(3):295-298.
14. Alstadhaug KB, Crougts T, Henriksen S, et al. Treatment of progressive multifocal leukoencephalopathy with interleukin 7. *JAMA Neurol.* 2014;71(8):1030-1035.
15. Gasnault J, de Goër de Herve MG, Michot JM, et al. Efficacy of recombinant human interleukin 7 in a patient with severe lymphopenia-related progressive multifocal leukoencephalopathy. *Open Forum Infect Dis.* 2014;1(2):ofu074.
16. Guille M, Rousset S, Bonneville F, et al. IL-7 immunotherapy for progressive multifocal leukoencephalopathy in a patient with already controlled HIV-1 infection on antiretroviral therapy. *AIDS.* 2019;33(12):1954-1956.
17. Harel A, Horng S, Gustafson T, Ramineni A, Farber RS, Fabian M. Successful treatment of progressive multifocal leukoencephalopathy with recombinant interleukin-7 and maraviroc in a patient with idiopathic CD4 lymphocytopenia. *J Neurovirol.* 2018;24(5):652-655.
18. Miskin DP, Chalkias SG, Dang X, Bord E, Batson S, Koranik IJ. Interleukin-7 treatment of PML in a patient with idiopathic lymphocytopenia. *Neurol Neuroimmunol Neuroinflamm.* 2016;3(2):e213.
19. Patel A, Patel J, Ikwuagwu J. A case of progressive multifocal leukoencephalopathy and idiopathic CD4+ lymphocytopenia. *J Antimicrob Chemother.* 2010;65(12):2697-2698.
20. Sospedra M, Schippling S, Yousef S, et al. Treating progressive multifocal leukoencephalopathy with interleukin 7 and vaccination with JC virus capsid protein VP1. *Clin Infect Dis.* 2014;59(11):1588-1592.
21. Ray U, Cinque P, Gerevini S, et al. JC polyomavirus mutants escape antibody-mediated neutralization. *Sci Transl Med.* 2015;7(306):306ra151.
22. Audemard-Verger A, Gasnault J, Faisant M, et al. Sustained response and rationale of programmed cell death-1-Targeting for progressive multifocal leukoencephalopathy. *Open Forum Infect Dis.* 2019;6(10):ofz374.
23. Cortese I, Muranski P, Enose-Akahata Y, et al. Pembrolizumab treatment for progressive multifocal leukoencephalopathy. *N Engl J Med.* 2019;380(17):1597-1605.
24. Hoang E, Bartlett NL, Goyal MS, Schmidt RE, Clifford DB. Progressive multifocal leukoencephalopathy treated with nivolumab. *J Neurovirol.* 2019;25(2):284-287.
25. Rauer S, Marks R, Urbach H, et al. Treatment of progressive multifocal leukoencephalopathy with pembrolizumab. *N Engl J Med.* 2019;380(17):1676-1677.
26. Walter O, Treiner E, Bonneville F, et al; Immune Checkpoint Inhibitors in PML Study Group. Treatment of progressive multifocal leukoencephalopathy with nivolumab. *N Engl J Med.* 2019;380(17):1674-1676.
27. Balduzzi A, Lucchini G, Hirsch HH, et al. Polyomavirus JC-targeted T-cell therapy for progressive multiple leukoencephalopathy in a hematopoietic cell transplantation recipient. *Bone Marrow Transplant.* 2011;46(7):987-992.
28. Muftuoglu M, Olson A, Marin D, et al. Allogeneic BK Virus-Specific T Cells for Progressive Multifocal Leukoencephalopathy. *N Engl J Med.* 2018;379(15):1443-1451.
29. Ferenczy MW, Marshall LJ, Nelson CD, et al. Molecular biology, epidemiology, and pathogenesis of progressive multifocal leukoencephalopathy, the JC virus-induced demyelinating disease of the human brain. *Clin Microbiol Rev.* 2012;25(3):471-506.
30. Clifford DB. Progressive multifocal leukoencephalopathy therapy. *J Neurovirol.* 2015;21(6):632-636.
31. Martin-Blondel G, Bauer J, Cuvinciu V, et al. In situ evidence of JC virus control by CD8+ T cells in PML-IRIS during HIV infection. *Neurology.* 2013;81(11):964-970.
32. Wüthrich C, Kesari S, Kim WK, et al. Characterization of lymphocytic infiltrates in progressive multifocal leukoencephalopathy: co-localization of CD8(+) T cells with JCV-infected glial cells. *J Neurovirol.* 2006;12(2):116-128.
33. Du Pasquier RA, Kuroda MJ, Schmitz JE, et al. Low frequency of cytotoxic T lymphocytes against the novel HLA-A\*0201-restricted JC virus epitope VP1(p36) in patients with proven or possible progressive multifocal leukoencephalopathy. *J Virol.* 2003;77(22):11918-11926.
34. Koranik IJ, Du Pasquier RA, Kuroda MJ, et al. Association of prolonged survival in HLA-A2+ progressive multifocal leukoencephalopathy patients with a CTL response specific for a commonly recognized JC virus epitope. *J Immunol.* 2002;168(1):499-504.
35. Mani J, Wang L, Hüchelhoven AG, et al. Definition and characterization of novel HLA-A\*02-restricted CD8+ T cell epitopes derived from JCV polyomavirus with clinical relevance. *Oncotarget.* 2017;8(2):2485-2500.
36. Aly L, Yousef S, Schippling S, et al. Central role of JC virus-specific CD4+ lymphocytes in progressive multi-focal leukoencephalopathy-immune reconstitution inflammatory syndrome. *Brain.* 2011;134(Pt 9):2687-2702.
37. Jelcic I, Jelcic I, Kempf C, et al. Mechanisms of immune escape in central nervous system infection with neurotropic JC virus variant. *Ann Neurol.* 2016;79(3):404-418.