


Accepted Manuscript

Title: Disrupting effect of androgens in postnatal female domestic cats

Author: Lucía Demaldé Mariana Lopez Merlo Rosario
Vercellini Claudio G. Barbeito Patricia Fernandez Cristina
Gobello



PII: S0378-4320(16)30250-0
DOI: <http://dx.doi.org/doi:10.1016/j.anireprosci.2016.05.015>
Reference: ANIREP 5430

To appear in: *Animal Reproduction Science*

Received date: 21-3-2016
Revised date: 26-5-2016
Accepted date: 31-5-2016

Please cite this article as: Demaldé, Lucía, Merlo, Mariana Lopez, Vercellini, Rosario, Barbeito, Claudio G., Fernandez, Patricia, Gobello, Cristina, Disrupting effect of androgens in postnatal female domestic cats. *Animal Reproduction Science* <http://dx.doi.org/10.1016/j.anireprosci.2016.05.015>

This is a PDF file of an unedited manuscript that has been accepted for publication. As a service to our customers we are providing this early version of the manuscript. The manuscript will undergo copyediting, typesetting, and review of the resulting proof before it is published in its final form. Please note that during the production process errors may be discovered which could affect the content, and all legal disclaimers that apply to the journal pertain.

1

2

3 **Disrupting effect of androgens in postnatal female domestic cats**

4 Lucía Demaldé, Mariana Lopez Merlo, Rosario Vercellini, Claudio G. Barbeito,

5 Patricia Fernandez, Cristina Gobello*

6

7 Laboratory of Reproductive Physiology, Faculty of Veterinary Medicine, National

8 University of La Plata- CONICET, Argentina

9

10

11

12

13

14

15

16

17

18

19 *Corresponding Author: Cristina Gobello. Laboratory of Reproductive Physiology, Faculty of

20 Veterinary Medicine, National University of La Plata. 60 & 118, La Plata CC 296 (B 1900

21 AVW) Argentina. Phone: 54-221-4825372; Fax: 54-221-425-7980 (Attn Dr Gobello);

22 Email: cgobello@fcv.unlp.edu.ar- cristinagobello@gmail.com

23

24

25 **ABSTRACT**

26 To test the hypothesis that in domestic cats, postnatal androgens induce sterility, the
27 aims of this study were to describe the reproductive effects and the clinical safety of a
28 postnatal administration of a long term release androgen in this species. Thirteen newborn
29 littermate female kittens were randomly assigned to one of the following treatment groups
30 within the first 24 hours of birth: testosterone enanthate 12.5 mg sc (TE; $n = 8$) or Placebo
31 (PL; $n = 5$). The animals were subsequently assessed for fecal sexual hormones until
32 puberty was attained and subsequently when matings occurred. After 21 days, ovulation
33 and gestation were diagnosed. All queens were subsequently ovario-hysterectomized. Fecal
34 testosterone concentrations differed between the treatment groups throughout the study
35 period ($P < 0.05$) being greater during the first 2 postnatal weeks in those of the TE group
36 ($P < 0.01$). Fecal estradiol was not affected by treatment ($P > 0.1$). While all the females
37 were receptive during the pubertal estrus ($P > 0.1$), two TE (2/8) compared with all (5/5)
38 females of the PL group had ovulations ($P < 0.05$). Only one (1/2) compared with three
39 (3/5) of the queens of the TE and PL groups, respectively became pregnant. All kittens of
40 the TE group had transient clitoral enlargement. Anovulatory TE-treated cats had no corpus
41 luteum, and a significant diminution of the endometrial glands as well as of the height of
42 the uterine epithelium. It is concluded that, in domestic cats, a single postnatal supra-
43 physiological dose of testosterone caused a large proportion of queens to be anovulatory
44 and there were also histological endometrial abnormalities that also occurred with this
45 treatment that were accompanied by mild and transient side effects.

46

47 *Keywords:* Postnatal; Testosterone; Anovulation; Endocrine disruption; Felid

48

49

50 **1. Introduction**

51 Domestic cat (*Felis catus*) overpopulation is an insurmountable problem in almost all
52 the countries of the world. Female cats are extremely prolific breeders and can reproduce
53 from early puberty (e.g. 4 month) until death (Johnston et al., 2001). Furthermore, from the
54 equator to areas with temperate photoperiods domestic felids breed throughout the year
55 (Faya et al., 2011). In developing countries, unwanted kittens are simply abandoned to
56 suffer and die on the streets being problematic to both the animals themselves and humans.
57 Safe, efficient and practical pharmaceutical protocols are still needed to manage the feline
58 overpopulation problem.

59 Sex steroids have organizational actions during late gestation and early postnatal life in
60 both altricial and precocial species such as mice, rats and sheep (Jackson et al., 2013).
61 Specifically, during the early postnatal period the developing central nervous system is
62 sensitive to the organizing effects of androgens. In this respect, both genders normally
63 differ in pattern of pituitary gonadotropin secretion and the male non-cyclic pattern of
64 gonadotropin secretion is induced by the action of testicular androgens on the anterior
65 hypothalamus during the postnatal period (Jackson et al. 2013).

66 In female rats, there exists a critical postnatal period when there is greater tissue
67 differentiation sensitivity during which a single androgen administration permanently alters
68 both the hypothalamic mechanisms which underlie “cyclic” gonadotropin release patterns
69 and the target tissue response to estrogens (Gorski, 1971; Harris, 1970; Lobl et al., 1975,
70 Lobl and Gorski, 1974, Mena et al., 1992). Androgenization of developmental tissues in
71 neonatal pigs also resulted in anovulatory infertility (Ventanas et al., 1992). As a result,
72 androgenized females are anovulatory, anestrous, and have altered uterine morphology and

73 function as well as greater male behavioral expression than untreated females (Barraclough
74 and Gorski, 1961; Lobl and Maenza, 1977). When female dogs were injected postnatally
75 with an androgen for 3 months, there was delayed puberty, anovulatory syndrome and
76 complete lack of receptivity to males (Beach et al., 1983). Furthermore, rats injected on the
77 first days of life with testosterone had ovarian atrophy (Pinilla et al., 1993).

78 Thus, androgen treatment early in life prevents ovulation as well as normal uterine
79 function and sexual behavior and may have implications for development of this
80 methodology as a contraceptive strategy for felids. To the best of the authors' knowledge
81 the effect of postnatal androgenization has never been assessed in domestic cats.

82 To test the hypothesis that in domestic cats, similar to other mammals (Barraclough and
83 Gorski, 1961; Beach et al., 1983; Ventanas et al., 1992) exogenous androgens induce
84 sterility if administered during the postnatal critical reproductive developmental period, the
85 aims of the present study were to describe the clinical and histological reproductive effects
86 of the postnatal administration of an androgen. Secondly, the clinical safety of the treatment
87 was also assessed. For this purpose, testosterone enanthate, a potent, long term effective
88 androgen (Plumb, 2015) which is inexpensive and available worldwide was selected as the
89 endocrine disruptor for this experiment.

90

91

92 **2. Materials and methods**

93 *2.2. Animals and pharmacological protocols*

94 Thirteen (five litters) newborn littermate female kittens from the National
95 University of La Plata institutional cat colony were included in this study. The animals
96 were sexed according to anogenital distance and identified at birth, reared under 14 hours

97 of light per day, weaned at the age of 40 days and fed premium commercial food and water
98 *ad libitum*. This study was reviewed and approved by the Animal Care and Use Committee
99 of the Veterinary School of the National University of La Plata and all experiments were
100 conducted under the guidelines established in The Guide for The Care and Use of
101 Laboratory Animals, USA.

102 The kittens of the same litters were randomly assigned to one of the following
103 treatment groups within the first 24 hours of birth: Testosterone enanthate 12.5 mg total
104 dose (Testoviron Depot 250, Bayer, Argentina) subcutaneously (TE; $n = 8$) or Placebo:
105 0.05 ml corn oil subcutaneously injection (PL; $n = 5$). The dose was selected according to
106 previous pilot studies in cats based on a classical animal model (Barraclough and Gorski,
107 1961).

108

109 *2.3. Physiological and anatomical assessments*

110 All the animals were subsequently assessed for specific anatomical, behavioral, and
111 physiological characteristics until the first indications of puberty occurred. During this
112 assessment period, the animals were observed 1.5 hours twice a day for evaluating sexual
113 behavior and were physically examined and weighed once a week. Eventual appearance of
114 clinical side effects was also recoded. Vaginal cytology (Mills et al., 1979) assessments
115 were conducted three times per week after the third month of age. Puberty was defined by
116 the finding of more than 80% superficial keratinized cells and a clean background in the
117 vaginal smears accompanied by the typical estrous behavior (Johnston et al., 2001).

118

119 *2.4. Fecal collection, extraction and hormone determinations*

120 Fecal samples were collected weekly until the time of puberty and frozen for
121 testosterone (T) and estradiol-17 β (E2) determinations. Fecal collection was initiated at the
122 end of the first postnatal week. For this purpose, each cat was confined in an individual
123 cage with clean sanitary litter one night per week. During the first 4 weeks of age, the
124 neonates had to be rectally stimulated by a thin plastic suppository attached to a string to
125 obtain the sample. Fecal steroids were extracted using the methods described by Brown et
126 al. (2008) and T (ng/ml) and E2 (pg/ml) were determined using electrochemiluminescence
127 immunoassays (Elecsys Testo II and Estradiol II, Roche Diagnostics, Mannheim,
128 Germany). Inter- and intra-assay coefficients of variation of the assays were <10% and
129 sensitivity were 0.025 ng/mL and 12 pg/mL for T and E₂ kits, respectively. All fecal data
130 were expressed on a wet-weight basis (Faya et al., 2013).

131

132 *2.5. In vivo fertility test, ovulation and pregnancy diagnosis*

133 As the female cats attained puberty, there was exposure to a fertile tomcat during the
134 estrous period. Matings were observed and/or diagnosed by the presence of spermatozoa in
135 the vaginal smears. Twenty-one days after the end of estrus, blood samples were taken for
136 ovulation assessment by electrochemiluminescence immunoassay determination of serum
137 progesterone (Elecsys Progesterone II, Roche Diagnostics, Mannheim, Germany; P₄ > 5
138 ng/mL) and gestation was diagnosed by ultrasonic examination in all the females (Mattoon
139 and Nyland, 1995).

140

141 *2.6. Ovariohysterectomies*

142 Following assessments for pregnancy status, all queens were ovariohysterectomized and
143 the ovaries and uteri were subjected to histological study. For the surgery, the animals were

144 pre-medicated with atropine sulfate, (Atropine Sulfate, John Martin; 0.04 mg/kg,
145 subcutaneously), acepromazine maleate (Acedan, Holiday; 0.03 mg/ kg subcutaneously),
146 and butorphanol (Torbutol Plus, Fort Dodge; 0.2 mg/kg, intramuscularly). Anesthesia was
147 induced with sodium thiopental (Pentovet TM, Richmond; 8 mg/kg, intravenous). After the
148 females were endotracheally intubated, anesthesia was maintained with isoflurane and
149 oxygen in a closed system. A mid-line laparotomy was performed to excise the ovaries and
150 uteri (Arnold, 2002). After surgery ketoprofen (Ketofen®, Fort Dodge; 1 mg/kg) was
151 injected subcutaneously (once) and then orally every 24 hours for 4 additional days. All the
152 queens were then placed for adoption.

153

154 *2.7. Gross and histomorphometrical examination*

155

156 Immediately after surgery genital tracks were excised and ovaries and uteri were
157 macroscopically examined and weighed. The ovaries were sectioned longitudinally, placed
158 in Bouin's fixative for 12 h and placed in 70% alcohol and processed routinely with
159 paraffin embedding. After processing, 5 µm serial sections were cut, mounted on slides,
160 dyed, deparaffinized in xylene, rehydrated in graded ethanol solutions and stained with
161 hematoxylin and eosin.

162 Follicles were classified as primordial (small oocyte surrounded by a single layer of
163 squamous granulosa cells), primary (oocyte surrounded by a single layer of cuboidal cells),
164 secondary (two or more layers of granulosa cells and a theca cell layer), antral (fluid-filled
165 antrum, mural and cumulus granulosa cells and two or more layers of thecal cells) or atretic
166 (degenerated granulosa cells and follicular fluid containing cellular debris as previously
167 described; Bristol-Gould and Woodruff, 2006). The number of primordial, primary,

168 secondary and antral follicles, corpora lutea, and atretic follicles per square millimeter was
169 determined on a computer screen using 20 captured images (X20) per animal obtained from
170 two, 3 mm- sections.

171 Uteri were sectioned longitudinally for internal inspection. Cross-sections
172 (approximately 0.5-1 cm) were collected from a point midway between the external
173 bifurcation and the tip of each uterine horn and processed as described for the ovaries. The
174 uteri were examined for the presence or absence of endometrial glands. The area occupied
175 by uterine glands per mm² of endometrium over the total area of each microscope field was
176 measured by planimetry. The height of the glandular and luminal uterine epithelium was
177 assessed counting 100 cells in a total of 10 images per uterus taken with a 10X objective
178 while myometrial thickness was examined in a total of four images per uterus taken with a
179 4X objective.

180 All histological images were obtained from a microscope (Olympus BX50, Tokyo,
181 Japan; 10X through an attached digital RGB video camera (Evolution VF Color, Q
182 Imaging, USA) and digitalized in a 24 bit true color TIFF format. These images were
183 analyzed using Image Pro Plus v6.0-Media Cybernetics (Silver Spring, MA, USA).

184

185 2.8. *Statistical analysis*

186 Quantitative and qualitative differences between TE and PL groups were conducted by
187 Fisher Exact and Student's t tests, respectively. Fecal T and E₂ concentrations were
188 analyzed by repeated measures ANOVA followed by Tukey comparison test. Data were
189 expressed as (mean ±SEM) and the level of significance was set at $P < 0.05$ (SPSS 17.0,
190 SPSS, Chicago, IL, USA).

191

192 3. Results

193 Age (34 ± 2.6 compared with 33.0 ± 2.3 weeks; $P > 0.1$) and body weight (2.92 ± 0.7
194 compared with 2.76 ± 0.9 kg; $P > 0.1$) at puberty attainment did not differ between TE and
195 PL groups. Fecal T concentrations differed between the treatments throughout the weeks of
196 the study ($P < 0.05$) being greater in the TE than in PL groups during the first 2 postnatal
197 weeks ($P < 0.01$; **Fig. 1A**). Conversely, fecal $E_2-17\beta$ concentrations varied during the study
198 without differences between treatments ($P > 0.1$). Thus, in both groups, E_2 was elevated
199 during the first 5 postnatal weeks ($P < 0.01$). The E_2 remained basal until 3 to 4 weeks
200 before puberty when concentrations began to increase (Fig. 1B).

201 All TE-treated kittens had vulva and clitoris enlargement during postnatal weeks 3 to 13
202 and were of typical developmental size, thereafter. There was also one case (1/8) of
203 transient mammary nodules in an animal of the TE-treatment group. In this case two 1.8 cm
204 diameter nodules appeared in the pectoral and inguinal left mammary glands on week 27
205 and gradually decreased in size to week 39 at the time of spaying.

206 One kitten of the TE group displayed mounting behavior preceding puberty. All the
207 females had normal estrous behavior, were receptive to males ($P > 0.1$) and were, therefore,
208 repeatedly mated during the pubertal estrus. While all the cats of the PL group (5/5) had
209 ovulations and three were pregnant when assessments occurred, ovulation occurred in two
210 of eight females of the TE group ($P < 0.05$) and one of the females was pregnant at the time
211 of assessment. In both groups, gestations progressed normally until the time of
212 ovariectomies when the examination of the excised uteri revealed four to five
213 conceptuses.

214 Ovarian weight did not differ between animals in the TE and PL (0.17 ± 0.0 compared
215 with 0.16 ± 0.0 g; $P > 0.1$) groups. Gross ovarian examination revealed follicles and

216 corpora lutea in the animals that failed to and those that had ovulations, respectively. No
217 further gross nor microscopical differences were detected between treatment groups for the
218 ovarian variables that were studied (Table 1).

219 Gross external and internal uterine observations were normal in all but one queen in the
220 TE group which was in estrus again at the time of surgery and had generalized abdominal
221 hyperemia and a slightly increased bleeding. In this queen the entirety of the uterine horns
222 and endometrium were also thicker than in the other cats.

223 Microscopic assessment of the uteri revealed that the area occupied by uterine glands
224 per mm² of endometrium was smaller in the TE than in the PL group (0.34 ± 0.01
225 compared with 0.49 ± 0.03 ; $P < 0.01$). Conversely, the area occupied by stroma per mm²
226 was larger in the TE queens (0.64 ± 0.01 compared with 0.50 ± 0.03 ; $P < 0.01$). The height
227 of the glandular (μm ; 13.89 ± 0.29 compared with 21.43 ± 1.10 ; $P < 0.01$) and luminal (μm ;
228 8.09 ± 0.39 compared with 9.44 ± 0.42 ; $P < 0.05$) uterine epithelium were shorter in the TE
229 than in the PL group (Fig. 2). Myometrial thickness did not differ between the two groups
230 (μm ; 286.43 ± 8.23 vs. 298.36 ± 8.62 ; $P < 0.05$).

231

232 4. Discussion

233 Although, postnatal androgenization effects have been reported in several mammalian
234 species including dogs (Barraclough and Gorski, 1961; Beach et al., 1983; Jackson et al.,
235 2013; Lobl and Gorski, 1974; Ventanas et al., 1992), to the authors' knowledge, this is the
236 first study that describes the effect of a single postnatal supra-physiological dose of a
237 potent, time-released androgen on female cat reproduction. In the kittens of the present
238 study, androgen treatment did not alter growth rate, age at puberty attainment nor estrous

239 behavior and receptivity. Similarly, in postnatally androgenized rats, body weight did not
240 differ from that of control animals (Almirón et al., 1984).

241 It is generally accepted that testosterone, when present for a period after birth, can
242 permanently suppress development of female reproductive behavior but this premise is not
243 consistent with findings in a previous study where sexual receptivity was not affected by
244 testosterone treatment of female pigs early in life (Ford and Christenson, 1987).
245 Conversely, normal sexual behavior was abolished in neonatally-androgenized rodents and
246 bitches (Beach et al. 1983, Gogan et al. 1980, Thomas et al. 1983). These inconsistencies in
247 results may be due to dose and species differences in the behavioral response to postnatal
248 testosterone.

249 The increased fecal T during the first 2 postnatal weeks in the kittens of the TE group in
250 the present study clearly indicates the exogenous effects of the hormonal treatment on
251 anatomical and behavioral characteristics in cats and defines the time period of the “the
252 critical period” to permanently differentiate sexual reproductive function in this species.
253 Conversely, fecal E₂ does not seem to be affected by androgen treatment. Furthermore, the
254 augmented E₂ concentrations during the first 5 postnatal weeks could be due to an
255 endogenous origin (Faya et al., 2013).

256 The transient vulvar and clitoris abnormalities and the mounting behavior observed in
257 all and one the TE-treated cats, respectively, are evidence of the peripheral effects of
258 testosterone. Furthermore, these changes were expected according to previous reports in
259 other postnatally androgenized species (Brown et al., 1999, Morali et al., 1985).

260 Consistent with findings in the present study with what has been extensively described
261 for other mammals (Jackson et al., 2013), the hypothalamic-pituitary-ovarian axis
262 functionality was probably affected in most of these queens as 75% of the TE-treated

263 animals were anovulatory. It is assumed that anovulation resulted from an androgen-
264 induced disorder of the postnatal hypothalamus and the subsequent change in the release
265 pattern of luteinizing hormone from the pituitary gland (Barraclough, 1961; Wagner et al.,
266 1966). This supports the hypothesis that the hypothalamus is sensitive, at least in part, to
267 programming by postnatal steroids in this altricial species. Both the absence of luteal tissue
268 and ovarian abnormalities in the testosterone-treated cats that were anovulatory suggest the
269 central origin of the infertility in these cats. It could also be possible that postnatal
270 testosterone might alter target tissue receptor sensitivity and, therefore, response to
271 hormones.

272 Similarly to what has been described for other endocrine disruptors in postnatal cats
273 (Carranza et al., 2014), differences in individual response may have also accounted for the
274 findings in the present study. It is worth noting that a dose effect has been previously
275 described for aromatizable and non-aromatizable androgens in the induction of anovulatory
276 syndrome in rats (Arai et al., 1981, Gorski and Barraclough, 1963). Although a larger
277 testosterone dose may have decreased or eliminated the variability of anovulation in the
278 present study, the possibility of use of a larger dose for this purpose does not appear to be
279 feasible as there would likely be an increase in the prevalence and severity of side effects.

280 The follicles from which ovulation did not occur might have functioned to increase
281 estrogens in the bloodstream and may have led to the notable inflammation, hemorrhages,
282 and hyperplasia in the endometrium in the testosterone-treated queen of the present study
283 which was spayed while in estrus. These abdominal findings were similar, in some aspects
284 to those described for human ovarian hyper-stimulation syndrome which is characterized
285 by multiple ovarian cysts and subsequent hyper-estrogenemia (Jones et al., 1987).

286 The mammary nodules in the TE-group of the present study were not histologically
287 examined and the transient existence suggests a non-neoplastic etiology. Similarly,
288 postnatal dihydrotestosterone treatment resulted in the stimulation of mammary
289 development at advanced ages in female mice (Yanai et al., 1981). Importantly, it should
290 also be taken into account that the eventual long term undesired effects should not be
291 discarded for the treatments used in the present study as these were not studied in the time
292 frame of present trial.

293 Postnatal testosterone treatment, in the felids of the present study, reduced
294 the area occupied by endometrial glands and cell development in both glandular and
295 luminal epithelial tissues. Similar findings have been described in postnatal
296 androgenized rats (Arutiunian et al., 1987) and also in progesterone-treated postnatal
297 dogs (Wilborn et al., 2014). As normal endometrial glands are required for establishment
298 and maintenance of pregnancy the question about a concomitant uterine infertility arises
299 and remains to be unveiled in most of these anovulated testosterone treated females.
300 Normal uterine functionality could only be ascertained in the pregnant androgenized female
301 of the present study. Inconsistent with what has been found in postnatal androgenized rats
302 (Lobl and Maenza, 1977), no variations in myometrium thickness was found in the present
303 feline study.

304 It is concluded that a single postnatal supra-physiological dose of testosterone
305 enanthate caused a large proportion of queens to be infertile due to anovulation and
306 histological endometrial abnormalities were prevalent in these cats. Furthermore, this

307 pharmacological protocol seemed to predispose queens to mild reversible physical side
308 effects. More knowledge is necessary before these pharmacological protocols could be
309 widely recommended as a contraceptive strategy in female cats.

310

311

312 **Acknowledgments**

313 This study was partially funded by the National Agency of Research and Technology,
314 Argentina (PICT 2014 0426), Argentina. MLP and RV are Research Fellows and CB, and
315 CG are Career Scientists of CONICET, Argentina.

316

317

318 **Conflict of interest**

319 None of the authors of this article has a financial or personal relationship with other people
320 or organizations that could inappropriately influence or bias the content of the paper.

321

322

323

324

325 **References**

326

327 Almirón, I., Domené, H., Chemes, H.E., 1984. Hormonal regulation of premeiotic steps of
328 spermatogenesis in the newborn rat. *J. Androl.* 5, 235-242.

329 Arai, Y., Yamanouchi, K., Mizukami, S., Yanai, R., Shibata, K., Nagasawa, H., 1981.

330 Induction of anovulatory sterility by neonatal treatment with 5 beta-
331 dihydrotestosterone in female rats. *Acta. Endocrinol. (Copenh.)* 96, 439-443.

332 Arnold E., 2002. Ovary and Uterus. In: Slatter, D. (Ed) *Textbook of small animal surgery*
333 3rd ed., Saunders, R.W., Philadelphia, pp 1496-1498.

334 Arutiunian, N.A., Prořmina, F.I., Savchenko, O.N., Skopichev, V.G., Sekretareva, E.N.,
335 1987. [Morphological characteristics of the uterine reaction of androgenized rats in
336 the neonatal period to the administration of sex steroids]. *Probl. Endokrinol.*
337 (Mosk). 33, 59-61.

338 Barraclough, C.A., 1961. Production of anovulatory, sterile rats by single injections of
339 testosterone propionate. *Endocrinology.* 68, 62-67.

340 Barraclough, C.A., Gorski, R.A., 1961. Evidence that the hypothalamus is responsible for
341 androgen-induced sterility in the female rat, *Endocrinology.* 68, 68–79.

342 Beach, F.A., Buehler, M.G., Dunbar, I.F., 1983. Sexual cycles in female dogs treated with
343 androgen during development. *Behav. Neural. Biol.* 38, 1-31.

344 Bristol-Gould, S., Woodruff, T.K., 2006. Folliculogenesis in the domestic cat (*Felis catus*.
345 *Theriogenology.* 66, 5-13.

- 346 Brown, G.R., Nevison, C.M., Fraser, H.M., Dixon, A.F., 1999. Manipulation of postnatal
347 testosterone levels affects phallic and clitoral development in infant rhesus monkeys.
348 *Int. J. Androl.* 22,119-128.
- 349 Brown, J., Walkter, S., Steinaman, K., 2008. Endocrine manual for reproductive assessment
350 of domestic and non domestic species. Conservation and Research Center,
351 Smithsonian's National Zoological Park VA, Pp 62.
- 352 Carranza, A., Faya, M., Merlo, M.L., Batista, P., Gobello, C., 2014. Effect of GnRH
353 analogs in postnatal domestic cats. *Theriogenology.* 1;82, 138-143.
- 354 Faya, M., Carranza, A., Miotti, R., Ponchón, T., Furlan, P., Gobello, C., 2013.
355 Fecal estradiol-17 β and testosterone in prepubertal domestic cats. *Theriogenology.* 80, 584-
356 586.
- 357 Faya, M., Carranza, A., Priotto, M., Abeya, M., Díaz, J.D., **Gobello, C.**, 2011. Domestic
358 queens under natural temperate photoperiod do not manifest seasonality. *Anim.*
359 *Reprod. Sci.* 129, 78-81.
- 360 Ford, J.J., Christenson, R.K., 1987. Influences of pre- and postnatal testosterone treatment
361 on defeminization of sexual receptivity in pigs. *Biol. Reprod.* 36, 581-587.
- 362 Gogan, F., Beattie, I.A., Hery, M., Laplante, E., Kordon, D., 1980. Effect of neonatal
363 administration of steroids or gonadectomy upon oestradiol-induced luteinizing
364 hormone release in rats of both sexes. *J. Endocrinol.* 85, 69-74.
- 365 Gorski, R.A., 1971. Lesion effects on hypothalamohypophyseal function. *Neurosci. Res.*
366 *Program. Bull.* 9, 263-268.
- 367 Gorski, R.A., Barraclough, C.A., 1963. Effects of low dosages of androgen on the
368 differentiation of hypothalamic regulatory control of ovulation in the rat.
369 *Endocrinology.* 73, 210-216.

- 370 Harris, G.W., Naftolin, F., 1970. The hypothalamus and control of ovulation. *Br. Med.*
371 *Bull.* 26, 3-9.
- 372 Jackson, L.M., Mytinger, A., Roberts, E.K., Lee, T.M., Foster, D.L., Padmanabhan, V.,
373 Jansen, H.T., 2013. Developmental Programming: Postnatal steroids complete
374 prenatal steroid actions to differentially organize the GnRH surge mechanism and
375 reproductive behavior in female sheep. *Endocrinology.* 154, 1612-1623.
- 376 Johnston, S.D., Root-Kustritz, M.V., Olson, P.N.S., 2001. Canine and feline
377 theriogenology. Saunders, W.B., Philadelphia, Pp 592.
- 378 Lobl, R.T., 1975. Androgenization: alterations in the mechanism of oestrogen action. *J.*
379 *Endocrinol.* 66, 79-84.
- 380 Lobl, R.T., Gorski, R.A., 1974. Neonatal intrahypothalamic androgen administration: the
381 influence of dose and age on androgenization of female rats. *Endocrinology.* 94,
382 1325-1330.
- 383 Lobl, R.T., Maenza, R.M., 1977. The ontogeny of uterine pathology and pathophysiology
384 following neonatal androgen administration. *Biol Reprod.* 16, 182-189.
- 385 Mattoon, J.S., Nyland, T.G., 1995. Ultrasonography of the genital system. In: Nyland, J.S.,
386 Mattoon, T.G. (Eds). *Veterinary diagnostic ultrasound.* Saunders, W.B., Philadelphia,
387 pp 141-164.
- 388 Mena, M.A., Arriaza, C.A., Tchernitchin, A.N., 1992. Early postnatal androgenization
389 imprints selective changes in the action of estrogens in the rat uterus. *Biol. Reprod.*
390 46, 1080-1085.
- 391 Mills, J.N., Valli, V.E, Lumsden, J.H., 1979. Cyclical changes of vaginal cytology in the
392 cat. *Can. Vet. J.* 20, 95-101.

- 393 Moralí, G., Carrillo, L., Beyer, C., 1985. Neonatal androgen influences sexual motivation
394 but not the masculine copulatory motor pattern in the rat. *Physiol. Behav.* 34, 267-
395 275.
- 396 Pinilla, L., Trimiño, E., Garnelo, P., Bellido, C., Aguilar, R., Gaytán, F., Aguilar, E., 1993.
397 Changes in pituitary secretion during the early postnatal period and anovulatory
398 syndrome induced by neonatal oestrogen or androgen in rats. *J. Reprod. Fertil.* 97,
399 13-20.
- 400 Plumb DC., 2015. *Plumb's veterinary drug handbook*. 8th ed. Wiley-Blackwell, Pp 1296.
- 401 Thomas, D.A., Howard, S.B., Barfield, R.J., 1983. Influence of androgen on the
402 development of sexual behavior in the rat. II. Time and dosage of androgen
403 administration during the neonatal period and masculine and feminine copulatory
404 behavior in females. *Horm. Behav.* 17, 308-315.
- 405 Ventanas, J., López-Bote, C.J., García, C., 1992. Further signs of postnatal sexual
406 differentiation in pigs. *Exp. Clin. Endocrinol.* 99, 119-122.
- 407 Wagner, J.W., Erwin, W., Critchlow, V., 1966. Androgen sterilization produced by
408 intracerebral implants of testosterone in neonatal female rats. *Endocrinology.* 79,
409 1135-1142.
- 410 Wilborn, R.R., Wiley, A.A., Brennan, K.I., Johnson, A.K., Fraser, N.S., Dujovne, G.A.,
411 Cooke, P.S., Bartol, F.F., 2014. Neonatal exposure to medroxyprogesterone acetate
412 alters canine uterine development. *Clinical Theriogenology.* 6, 344.
- 413 Yanai, R., Nagasawa, H., Mori, T., Nakajima, Y., 1981. Long-term effects of perinatal
414 exposure to 5 alpha-dihydrotestosterone on normal and neoplastic mammary
415 development in mice. *Endocrinol. Jpn.* 28, 231-234.

419 **Figure legends**

420

421 **Fig. 1.** Fecal testosterone (A; $P < 0.05$) and estradiol-17 β (B; $P > 0.1$) concentrations (mean
422 \pm SEM) of 13 female kittens treated postnatally with testosterone enanthate 12.5mg (solid
423 symbols) or a placebo (open symbols) and subsequently assessed until the first pubertal
424 signs appeared for anatomical and behaviorally characteristics; Asteriks over the symbols
425 indicate selected differences ($P < 0.01$) between groups

426

427 **Fig. 2.** Ovaries (hematoxylin and eosin, 4X) of female cats; Animals treated with
428 testosterone enanthate (A) or placebo (B); No significant differences ($P > 0.05$) were
429 detected between groups for any ovarian structure except for the presence of luteal cells
430 (LC) in the testosterone- treated cats

431

432 **Fig 3.** Uteri (hematoxylin and eosin, 4X and 20X) of 13 female cats; Animals treated with
433 testosterone enanthate (A and A') or placebo (B and B'); Notice fewer ($P < 0.01$)
434 endometrial uterine glands in the testosterone-treated cats (A and A')

435

436

437 **Table 1.** Ovarian gross and histologic variables (mean \pm SD) of female cats; No
 438 differences ($P > 0.05$) were detected between groups

Parameter	TE	Placebo
Length (cm)	1.02 \pm 0.0	0.95 \pm 0.0
Height (cm)	0.58 \pm 0.0	0.65 \pm 0.0
Weight (g)	0.16 \pm 0.0	0.17 \pm 0.0
Volume (cm ³)	0.17 \pm 0.0	0.20 \pm 0.0
Primordial follicles/mm ²	35.13 \pm 15.0	38.67 \pm 7.7
Primary follicles/mm ²	6.80 \pm 1.4	10.62 \pm 1.8
Secondary follicles/mm ²	0.95 \pm 0.2	1.91 \pm 0.7
Antral follicles/mm ²	0.24 \pm 0.0	0.08 \pm 0.0
Atretic follicles/mm ²	3.80 \pm 0.6	3.64 \pm 0.7

439

440

441

442

443

444

445

446

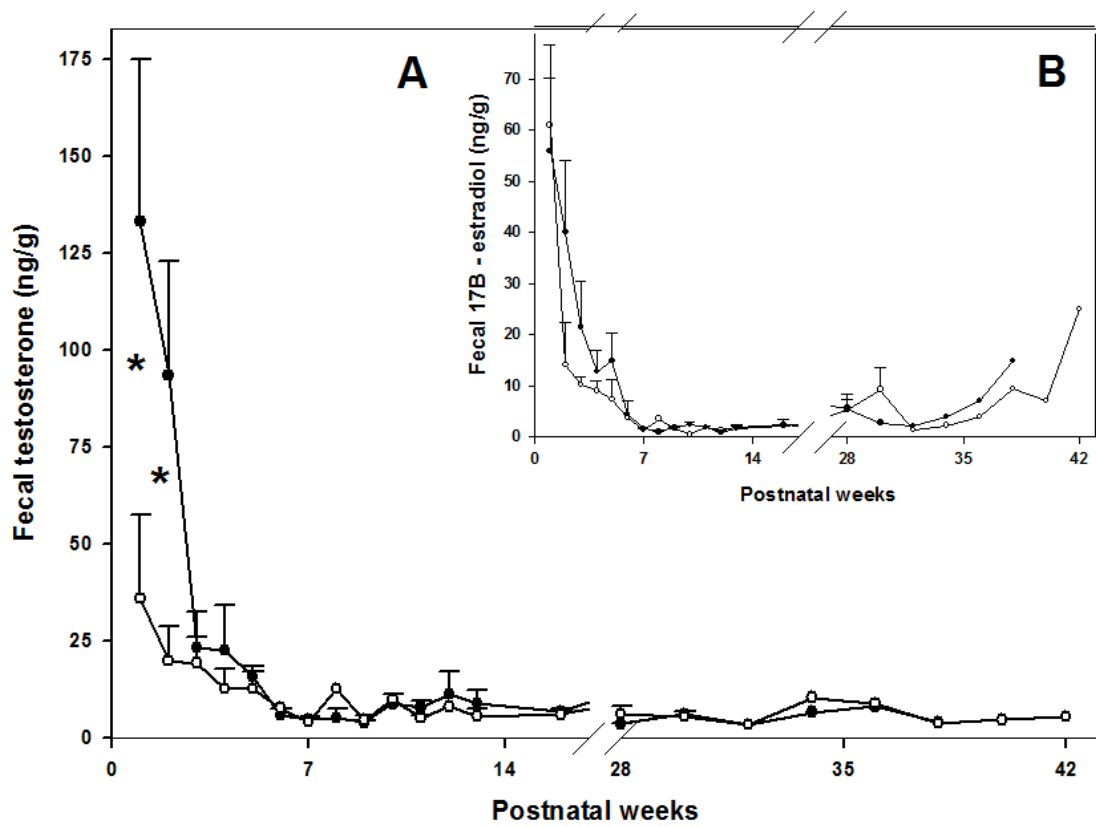


Fig 2 A

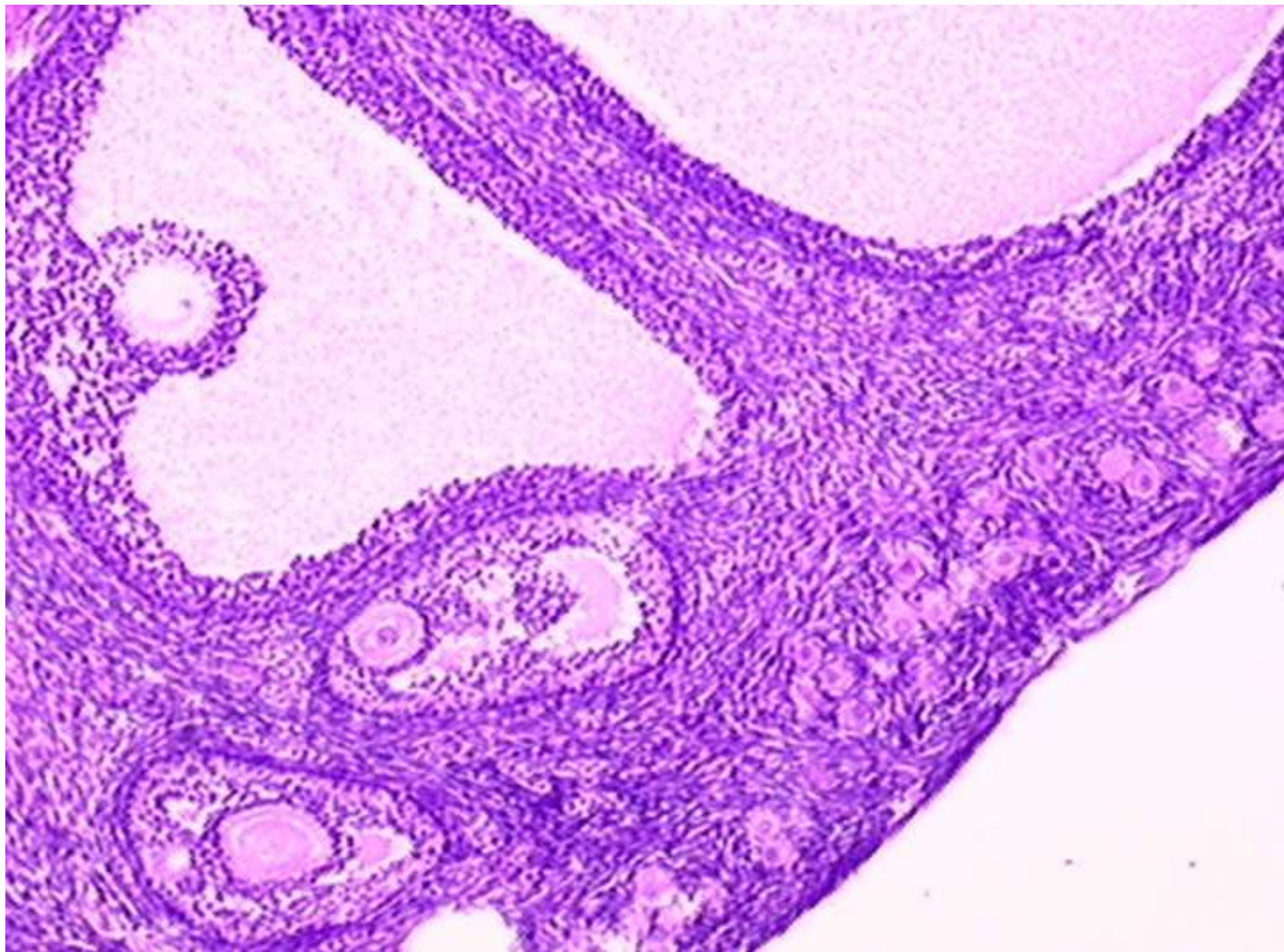


Fig 3A

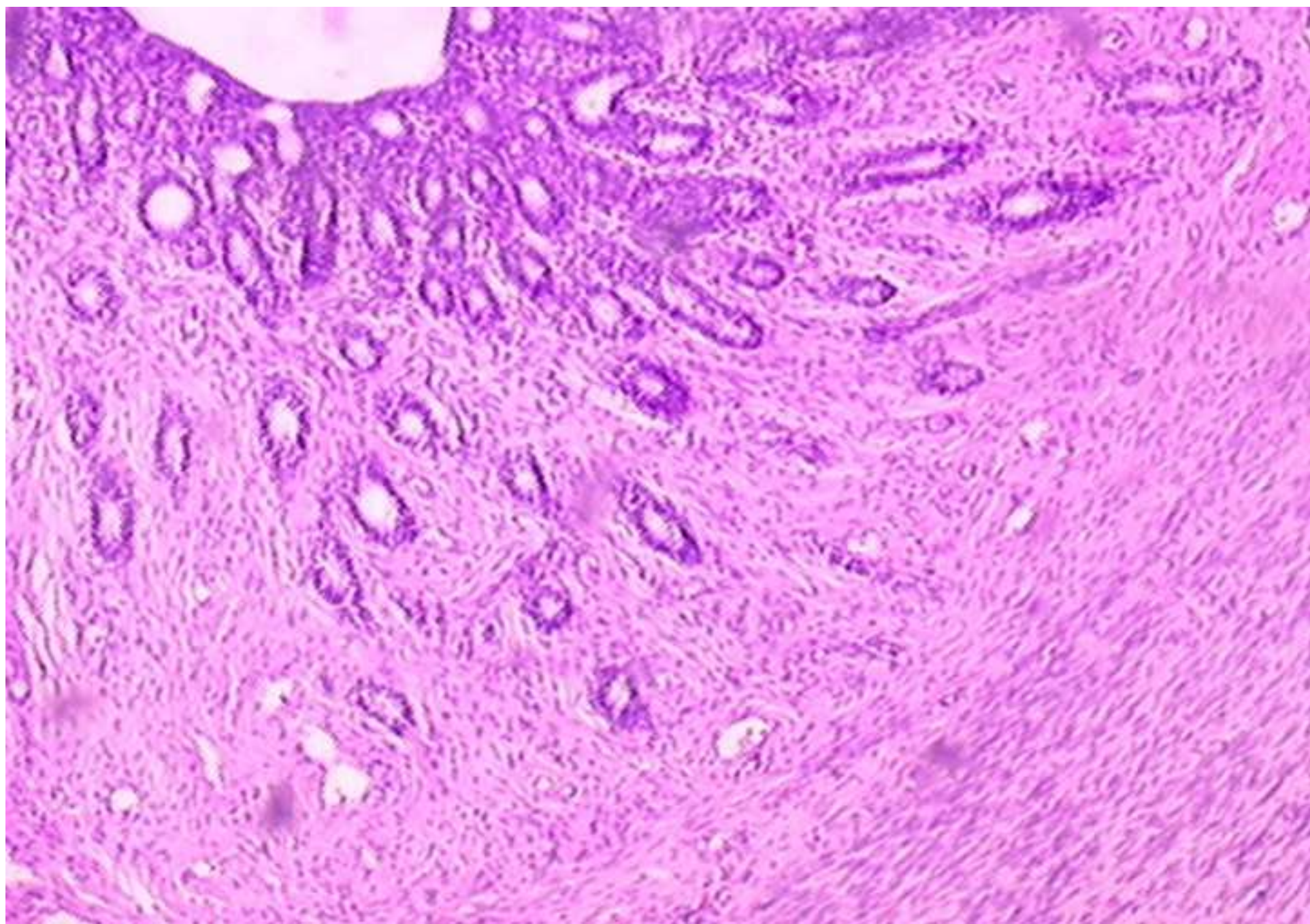


Fig 3B

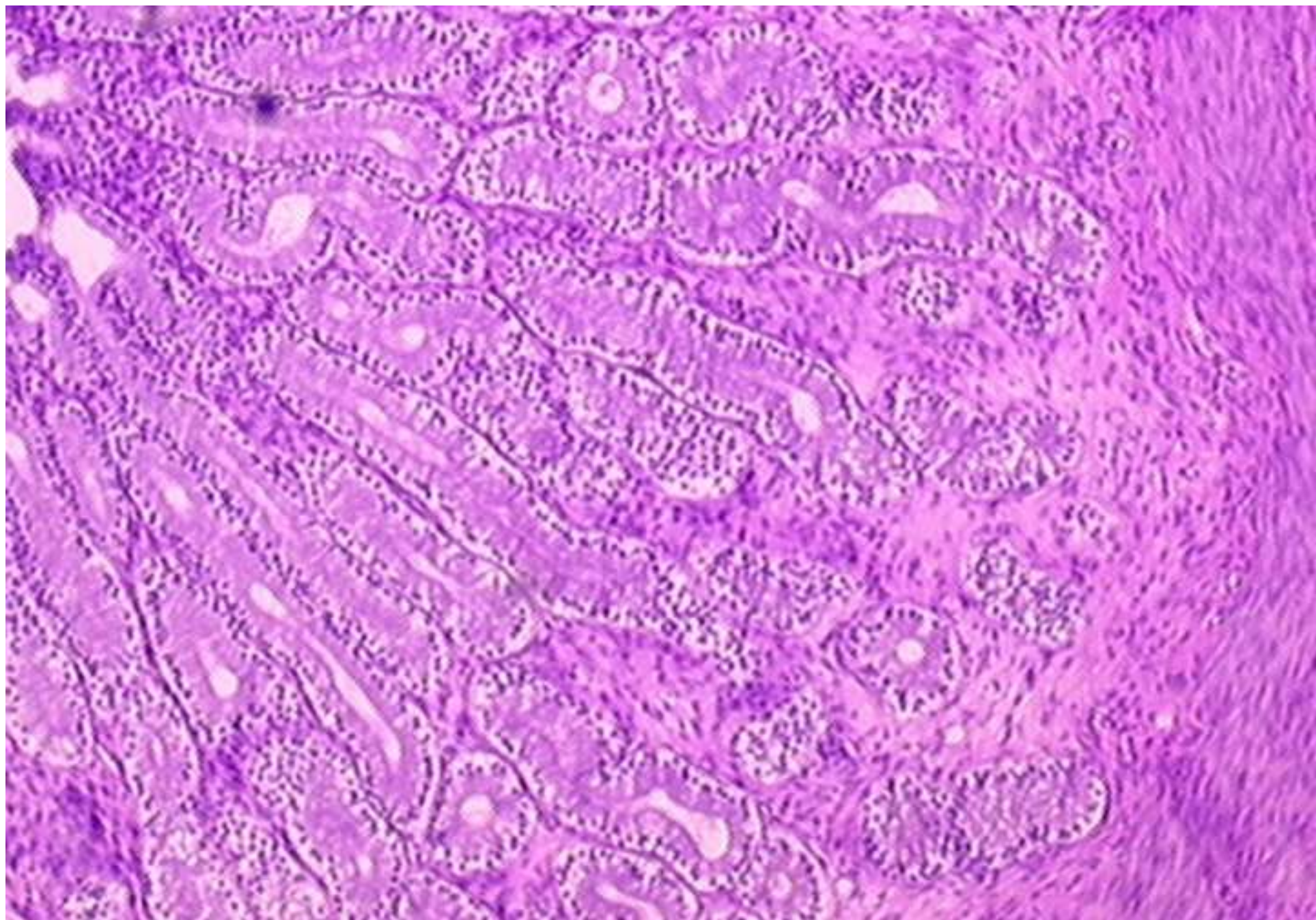


Fig A

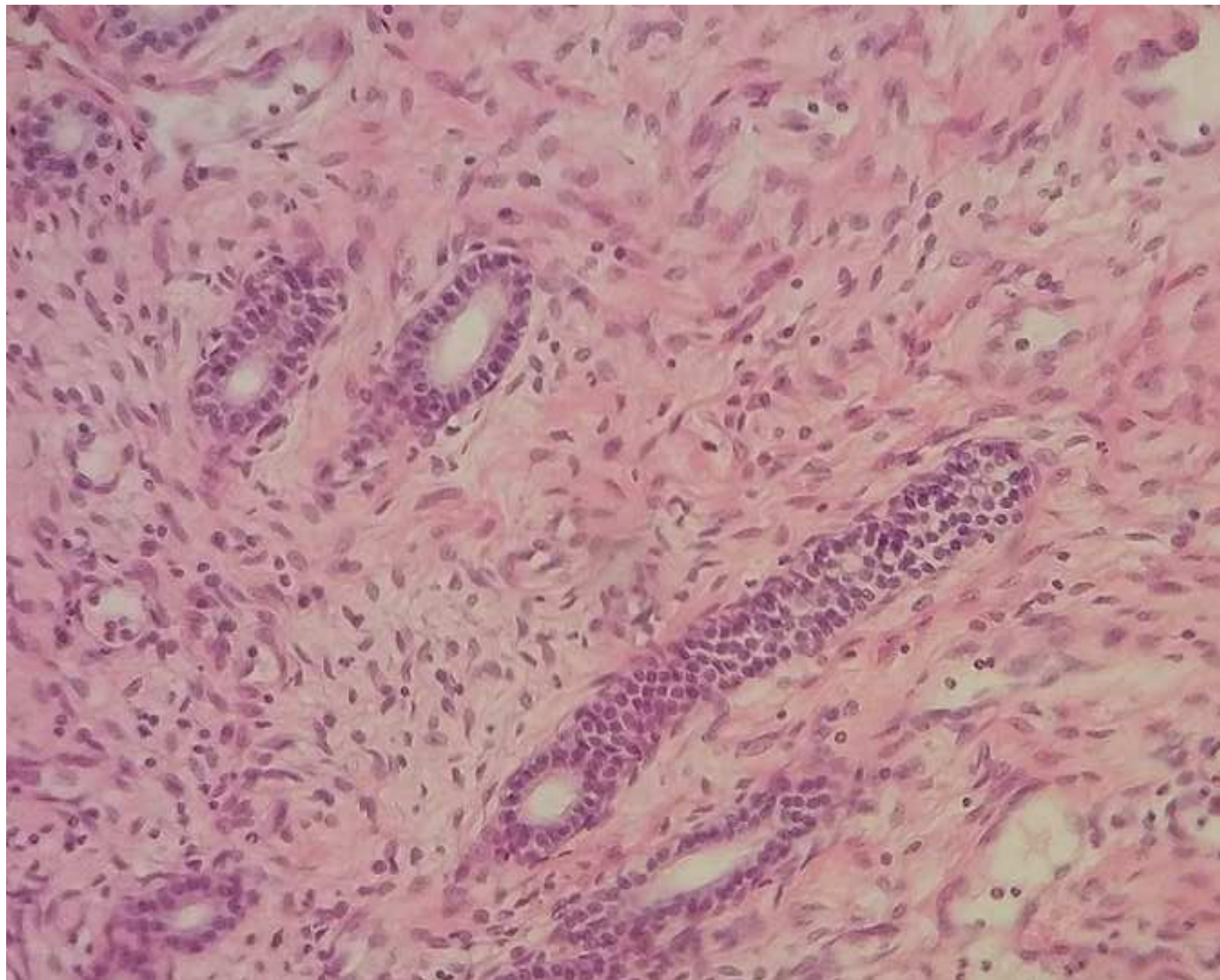


Fig B

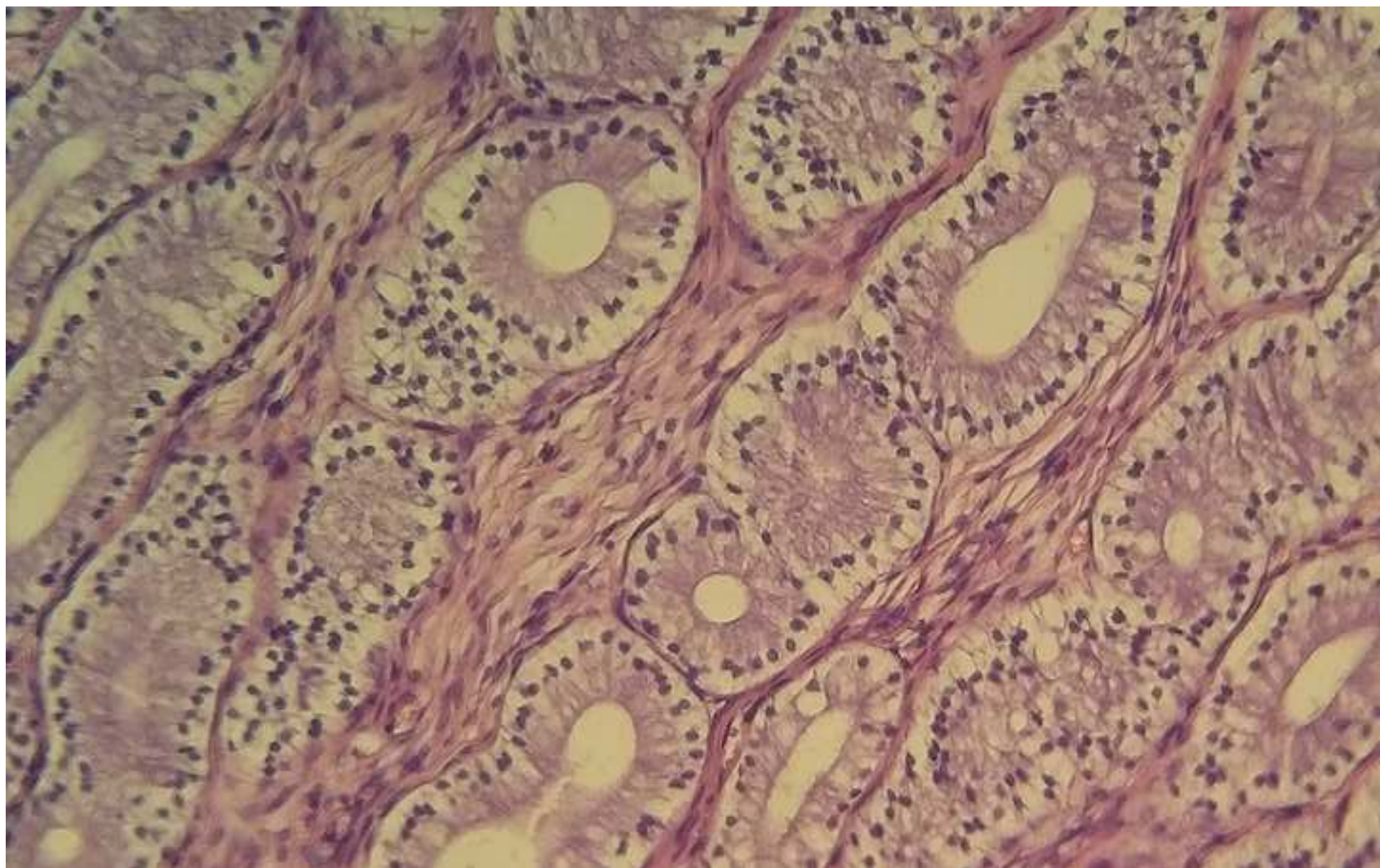


Fig 2B

