



2020

Iatrogenic pulmonary artery dissection in patient with ostium secundum interatrial septum defect

Follow this and additional works at: <https://www.j-saudi-heart.com/jsha>



Part of the [Cardiology Commons](#)



This work is licensed under a [Creative Commons Attribution-Noncommercial-No Derivative Works 4.0 License](#).

Recommended Citation

Di Lisi, Daniela; Aquaro, Giovanni D.; Macaione, Francesca; Novo, Salvatore; and Novo, Giuseppina (2020) "Iatrogenic pulmonary artery dissection in patient with ostium secundum interatrial septum defect," *Journal of the Saudi Heart Association*: Vol. 32 : Iss. 1 , Article 23.
Available at: <https://doi.org/10.37616/2212-5043.1022>

This Case Report is brought to you for free and open access by Journal of the Saudi Heart Association. It has been accepted for inclusion in Journal of the Saudi Heart Association by an authorized editor of Journal of the Saudi Heart Association.

Iatrogenic pulmonary artery dissection in patient with ostium secundum interatrial septum defect

Daniela Di Lisi ^{a,*}, Giovanni Donato Aquaro ^b, Francesca Macaione ^a, Salvatore Novo ^a, Giuseppina Novo ^a

^a Cardiology Division, University Hospital “P. Giaccone”, Palermo, Italy

^b Fondazione G. Monasterio CNR, Regione Toscana, Pisa, Italy

Abstract

Pulmonary artery dissection is a rare and lethal condition. Few cases are reported in the literature, and most are derived from autopsies. In most cases, pulmonary artery dissection is a complication of chronic pulmonary hypertension leading to pulmonary artery aneurysm but there are other causes. We describe a case of iatrogenic pulmonary artery dissection in an elderly patient with ostium secundum defect. In particular, we describe the role of cardiac magnetic resonance in making this diagnosis and guiding future therapeutic decisions.

Keywords: Cardiac magnetic resonance, Ostium secundum defect, Pulmonary dissection, Pulmonary hypertension

1. Introduction

Pulmonary artery (PA) dissection is a rare and lethal condition. Few cases are reported in the literature, and most are discovered from autopsies. In most cases, PA dissection is a complication from chronic pulmonary hypertension leading to a PA aneurysm [1–3]. Other cases of reported PA dissection are caused by an extension of a chronic type A aortic dissection through a patent ductus arteriosus or such as a Takayasu’s arteritis complication without pulmonary arterial hypertension (PAH) [4,5]. In effect, PA dissection can also occur rarely in the absence of PAH [6]. Cases of PA dissection are also reported in patients with congenital heart disease such as patent ductus arteriosus and Eisenmenger’s syndrome [7,8].

Liu et al. [9] reported a case of a full-length PA dissection in a young patient with idiopathic PAH who requested conservative treatment with PAH-

specific therapy after refusing heart–lung transplantation, the treatment recommended in extended PA dissection.

However, currently there are no management guidelines for PA dissection, despite the fact that PA dissection has a mortality rate of 80% within a few hours of diagnosis.

Senbaklavaci et al. [3] reported that patients with PA dissection should undergo surgery, including patients with chronic PA dissection without PAH. Li et al. [10] reported that for stable, asymptomatic patients, conservative treatment and follow-up are necessary and that further dilatation of the PA is an indication for surgery.

It is probable that, given the high risk of mortality associated with PA dissection, the treatment with the best results is surgical repair, but in patients who refuse surgical treatment or when a comorbidity implies high surgical risk, conservative medical treatment should be considered. The experience with conservative medical management using vasodilator therapy is limited to a very small number of patients, reporting favorable results [11].

Received 29 October 2019; revised 10 December 2019; accepted 12 December 2019.
Available online 17 April 2020

* Corresponding author at: Cardiology Division, University Hospital “P. Giaccone”, Palermo, Italy.
E-mail address: danydilis@hotmail.it (D. Di Lisi).



Diagnosis of PA dissection is not always easy. Patients can have dyspnea or oppressive retro-sternal chest pain. Echocardiography, computed tomography (CT), and cardiac magnetic resonance (CMR) can help facilitate a correct diagnosis.

In this case, we describe an iatrogenic PA dissection that was discovered 2 days after a right heart catheterization in a patient with ostium secundum interatrial septum defect (ISD) and PAH. However, regardless of etiology, PA dissection predisposes to sudden cardiac death and cardiogenic shock, and it requires an immediate diagnosis and treatment. Management of this condition is not always easy.

2. Case report

An 81-year-old man with progressive dyspnea and recent diagnosis of ostium secundum ISD with PAH was admitted to our hospital for assessment of PAH and evaluation of the possibility of percutaneous closure of ISD. At hospital admission, the patient presented with a blood pressure of 100/70 mmHg, arrhythmic heart auscultation, and mild cyanosis with arterial oxygen saturation of 86% without oxygen therapy. His electrocardiogram (ECG) showed known atrial fibrillation and right bundle branch block. A transthoracic echocardiography performed at admission showed severe right ventricle enlargement with reduced indices of longitudinal systolic contraction [tricuspid annular plane systolic excursion (TAPSE), 15 mm], severe tricuspid regurgitation with PAH (arterial pulmonary systolic pressure (PAPS) 80 mmHg), dilated inferior cava vein, dilated PA trunk (30 mm) and main branches, dilated right atrium, large ISD with left–right shunt, normal dimensions of left ventricle with a cardiac ejection fraction of 50% by biplane modified Simpson's method, and no other significant pathology.

No enzymatic movement was observed, but high values of pro-B-type natriuretic peptide (pro-BNP) were noted (pro-BNP, 10,000 pg/mL).

The patient's chest X-ray result showed slight accentuation of the bronchial texture and enlargement of the mediastinal shadow.

Three days after hospital admission, after hemodynamic stabilization, Swan–Ganz catheterization was performed. It indicated a systolic PA pressure of 97 mmHg and mean PA pressure of 47 mmHg with increased vascular pulmonary resistances (irreversible pulmonary hypertension). Swan–Ganz catheterization also showed left–right shunt because of a large ISD with a significant Qp/Qs ratio of 2.5. Two days after the right heart catheterization, a new onset of dyspnea and oppressive chest pain was

noted. Diuretic therapy was increased with mild benefit, and therapy with sildenafil was started. Therefore, considering the persistence of dyspnea and chest pain in the absence of new ECG anomalies or new left ventricle kinesis anomalies and low risk of pulmonary embolism in the patient with anticoagulant treatment for atrial fibrillation, CMR was performed to assess ISD anatomy, cardiac volumes, cardiac function, and stroke volume, and to assist in identifying other possible causes of dyspnea and chest pain. CMR scan revealed a large thrombosed dissection of right PA. Steady-state free precession (SSFP) images showed main and right PA dilatation, right PA lumen reduction that is compressed by hypodense mass and a thrombosed false lumen (Fig. 1a). Contrast enhanced-magnetic resonance angiography (CE-MRA) showed a right PA perfusion defect (Fig. 1b).

Chest CT was performed to confirm the data. The CT scan showed thrombosed right PA dissection (Fig. 1c). CT images demonstrated hypodense formation at the right PA bifurcation, and this formation was not enhanced in the angiography and venous phase images (Fig. 1d). For the most part, during the venous phase, a small flap appeared in the lumen vessel at the interlobar tract level.

Upon confirmation of the presence of PA dissection, a surgery consultation was requested. Considering the comorbidity, high surgical risk, and hemodynamic stability, the determined appropriate course of action was regular follow-up and medical therapy. Thus, the patient continued his therapy with diuretic and sildenafil for pulmonary hypertension, beta-blockers and heparin for atrial fibrillation, and oxygen therapy with subsequent mild improvement of dyspnea. The patient improved and was discharged; he was clinically stable and asymptomatic 1 month after the optimized medical treatment. CT was repeated after 1 month and showed that the right PA filling defect had slightly increased. Three months after discharge, the patient died at home because of comorbidity.

3. Discussion

In our case, the pre-existent PAH and PA dilatation facilitated iatrogenic dissection (a rare complication of PAH and pulmonary dilation in association with rupture of the vessel). It is probable that balloon inflation during Swan–Ganz catheterization caused PA dissection in a dilated and frail vessel, which led to the development of a future acute event. In effect, the majority of PA dissections occur

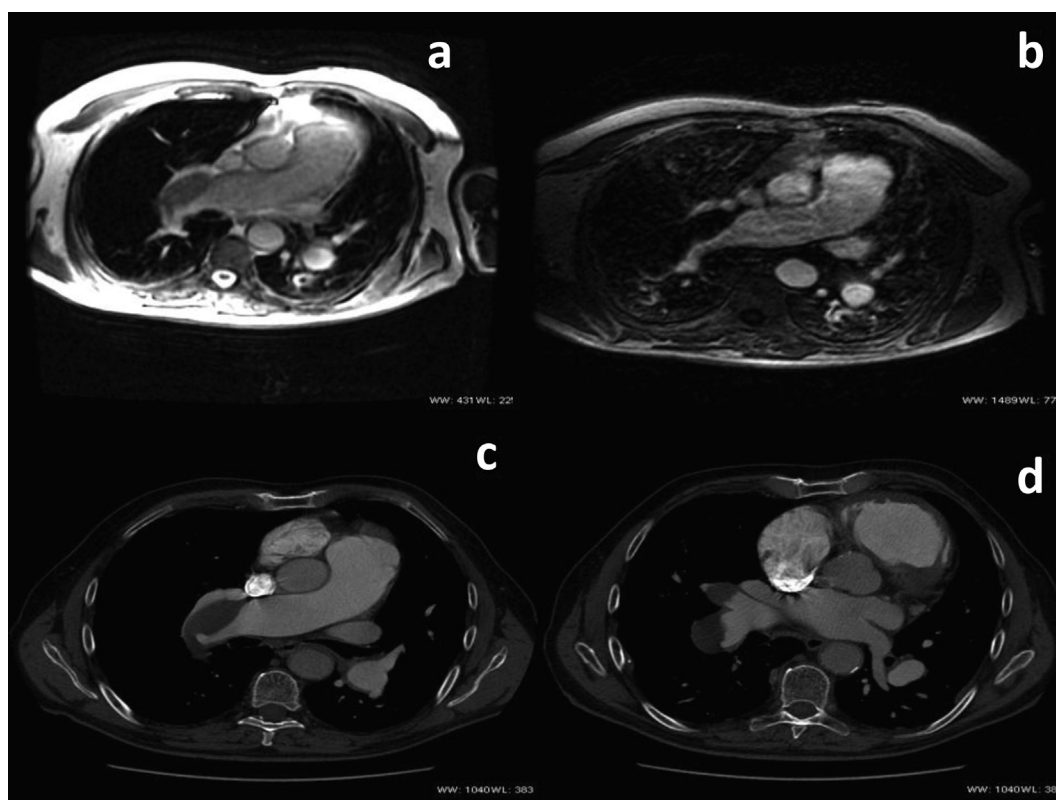


Fig. 1. Imaging results. (a) Steady-state free precession (SSFP) images showing main and right pulmonary artery dilatation and a right pulmonary artery lumen reduction that is compressed by hypodense mass (thrombosed false lumen). (b) Contrast enhanced-magnetic resonance angiography (CE-MRA) showing main and right pulmonary artery dilatation with right pulmonary artery perfusion defect. (c) Angio-computed tomography (CT) images showing main and right pulmonary artery dilatation with right pulmonary artery dissection; a true and a thrombosed false lumen are visualized. (d) Angio-CT images showing a hypodense formation at the right pulmonary artery bifurcation; this formation was not enhanced during angiography and venous phase images.

in the presence of medial degeneration with fragmentation of elastic fibers and generalized dilatation of the pulmonary arterial tree caused by chronic PAH. PA dissection is not predictable. Perhaps, as suggested in reviews, severe dilatation of the PA, high PA pressure, or a rapid change in diameter (2.0 and 2.5 cm/y) and pressure (40 mmHg/y) should warrant further evaluation or management to preclude a catastrophic event [12].

In addition, in consideration of the high surgery risk and the patient's comorbidity, conservative medical treatment was performed. The patient's death after 3 months confirmed the difficult therapeutic decision in an elderly patient with multiple comorbidity and high-risk surgery.

Chest CT and CMR have more advantages in the diagnosis of PA dissection compared with echocardiography. Echocardiography is unable to show PA dissection if the dissection is not proximal and if the acoustic window is not good. Chest CT with pulmonary angiography allows a better definition of the presence and extension of dissection in the main

pulmonary trunk and the main branch. Moreover, although CMR allows an accurate diagnosis of PA dissection, CT with pulmonary angiography is superior to CMR in the evaluation of the peripheral pulmonary circulation.

4. Conclusion

Management of PA dissection is not always easy even if it requires immediate diagnosis and surgical repair. Chest CT is the gold standard in the diagnosis of PA dissection even though multimodality CMR can be used to make the diagnosis by providing important data. In this patient, considering the cause and characteristics of dissection, hemodynamic stability, and high surgical risk, the appropriate decision was to use conservative medical therapy and proceed with regular follow-up using chest CT. In addition, for immediate diagnosis and treatment of patients with PAH, gravescent dyspnea, and chest pain, clinicians should consider PA dissection.

Conflict of interest

The authors have no conflict of interest to declare.

References

- [1] Perrotta S, Lentini S. Pulmonary artery dissection. *J Card Surg* 2015;30:442–7.
- [2] Malm CJ, Ternström L, Jörgensen K, Dellgren G. Pulmonary artery dissection in a patient with undiagnosed pulmonary hypertension—a case report and review of literature. *Heart Lung* 2015;44:453–7.
- [3] Senbaklavaci O, Kaneko Y, Bartunek A, Brunner C, Kurkciyan E, Wunderbaldinger P, et al. Rupture and dissection in pulmonary artery aneurysm. *J Thorac Cardiovasc Surg* 2001;121:1006–8.
- [4] Hong H, Dong NG, Liu JP, Li F. Pulmonary artery dissection caused by extension of a chronic type A aortic dissection through a patent ductus arteriosus. *Circulation* 2015;131:2023–5.
- [5] Sumi M, Hashizume K, Miura T, Tanigawa K, Matsukuma S, Eishi K, et al. Surgical repair of pulmonary artery dissection in a patient with 10-year history of Takayasu's arteritis. *Gen Thorac Cardiovasc Surg* 2016;64:745–8.
- [6] Inayama Y, Nakatani Y, Kitamura H. Pulmonary artery dissection in patients without underlying pulmonary hypertension. *Histopathology* 2001;38:435–42.
- [7] Yan T, Lu H, Yu H, Zhang WD. Pulmonary artery dissection. *Eur J Cardiothorac Surg* 2014;46:1040.
- [8] Westaby S, Evans BJ, Ormerod O. Pulmonary-artery dissection in patients with Eisenmenger's syndrome. *N Engl J Med* 2007;356:2110–2.
- [9] Liu C, Xia L, Pu Q, Liu L. A full-length pulmonary artery dissection. *Am J Respir Crit Care Med* 2018;197:1344–5.
- [10] Li Q, Wang A, Li D, Dou C, Zhang H, Wang Z, et al. Dissecting aneurysm of the main pulmonary artery a rare complication of pulmonary balloon valvuloplasty diagnosed 1 month after the procedure. *Circulation* 2009;119:761–3.
- [11] Navas Lobato MA, Martín Reyes R, flurueña Lobo P, Maté Benito I, Guzmán Hernández G, et al. Pulmonary artery dissection and conservative medical management. *Int J Cardiol* 2007;119:e25–6.
- [12] Jung LY. Is pulmonary artery dissection predictable? *Heart Lung* 2016;45:79–80.