

Hepatitis C virus- related cryoglobulinemic vasculitis: A review of the role of the new direct antiviral agents (DAAs) therapy

Cesare Mazzaro^{a,*}, Luigino Dal Maso^{b,**}, Endri Mauro^c, Marcella Visentini^d, Maurizio Tonizzo^e, Valter Gattei^a, Pietro Andreone^f, Gabriele Pozzato^g

^a *Clinical of Experimental Onco-Haematology Unit, Centro di Riferimento Oncologico di Aviano (CRO) IRCCS, Aviano, PN, Italy*

^b *Cancer Epidemiology Unit, Centro di Riferimento Oncologico di Aviano (CRO) IRCCS, Aviano, PN, Italy*

^c *Dipartimento di medicina interna, unità di ematologia, Ospedale Cà Foncello Treviso, Italy*

^d *Department of Clinical Medicine, Laboratory affiliated to Istituto Pasteur Italia-Fondazione Cenci Bolognetti, Roma, Italy*

^e *Department of Internal Medicine, Pordenone General Hospital, Pordenone, Italy*

^f *Department of SMECHIMAI, University of Modena and Reggio Emilia, Modena, Italy*

^g *Clinical and Surgical Sciences, University of Trieste, Trieste, Italy*

ARTICLE INFO

Keywords:

Cryoglobulinemia

Direct antiviral agents (DAAs)

Hepatitis C virus

Purpura

Arthralgia

ABSTRACT

Hepatitis C virus (HCV) infection affects about 70 million people worldwide. HCV is responsible for both hepatitis and extra-hepatic manifestations. Chronic infection has been shown to develop in about 70% of cases and can progress to cirrhosis or hepatocellular carcinoma. Ten percent of HCV patients may develop extra-hepatic manifestations, including mixed cryoglobulinemia (MC) and non-Hodgkin lymphomas. Many studies have demonstrated that, after antiviral therapy, MC can disappear along with HCV eradication. After the introduction of the new direct antiviral agents (DAAs), the combination of pegylated interferon and ribavirin has been abandoned. Several studies on new DAAs have reported remarkable 90% to 100% eradication rates, regardless of HCV genotype. Treatment with DAAs has comparable efficacy on viral eradication in patients with MC, but definite clinical improvements of vasculitis can be observed only in half the patients. On the contrary, the regression of renal disease and lympho-proliferative disorders, induced by HCV, appears to have a lower remission rate after viral eradication with DAAs and most cases need immunosuppressive treatments. In HCV related CV, the main clinical goal must be early eradication of HCV, to avoid organ complication and manifestation of lympho-proliferative diseases. This review focuses on the role of DAAs in treatment of HCV-related cryoglobulinemic vasculitis.

1. Introduction

Seventy million people are estimated to have been infected with Hepatitis C virus (HCV), which is responsible for both hepatitis and extra-hepatic manifestations. Chronic infection has been shown to develop in about 70% of cases [1], and it can progress to cirrhosis or hepatocellular carcinoma (HCC). HCV can determine not only acute and chronic hepatitis but also several extra-hepatic manifestations, including autoimmune diseases, mixed cryoglobulinemia (MC) and non-Hodgkin lymphomas (NHL) [2,3]. A large body of clinical, epidemiological, biological, and molecular data suggest the association between

HCV and monoclonal lympho-proliferative disorders and supports a causal relationship [4–8]. Many authors have demonstrated that both MC and NHL could disappear together with HCV after antiviral therapy, though with a largely unsatisfactory response rate as compared to HCV cases without extra-hepatic manifestations [9–12].

Antiviral therapies have significantly improved in recent years; the combination of pegylated interferon (Peg-IFN) and ribavirin (RBV), also combined with boceprevir or telaprevir, has been abandoned after the introduction of the new direct antiviral agents (DAAs) [13–15]. Several studies on these new DAAs have reported a remarkable eradication rate, ranging from 90% to 100% regardless of HCV genotype [16,17].

Abbreviations: CV, cryoglobulinemic vasculitis;; DAAs, direct antiviral agents;; HCC, hepatocellular carcinoma;; HCV, hepatitis C virus;; MC, mixed cryoglobulinemia;; NHL, non-Hodgkin lymphomas;; RF, rheumatoid factor;; RBV, ribavirin;; RTX, rituximab;; SOF, sofosbuvir;; SVR, sustained virological response.

* Corresponding author at: Clinical of Experimental Onco-Haematology Unit, Centro di Riferimento Oncologico di Aviano (CRO) IRCCS, Via Franco Gallini 2, 33081 Aviano, PN, Italy.

** Corresponding author at: Cancer Epidemiology Unit, Centro di Riferimento Oncologico di Aviano (CRO) IRCCS, Via Franco Gallini 2, 33081 Aviano, PN, Italy.

E-mail addresses: cesare.mazzaro@gmail.com (C. Mazzaro), epidemiology@cro.it (L. Dal Maso).

Accepted 2 March 2020

Presently, few published reports have documented novel DAAs regimens, showing a comparable efficacy in patients with MC concerning viral eradication, while a definite clinical improvement has been observed only in a fraction of patients who obtained a sustained virological response (SVR) [18–28].

A clinical assessment of MC patients is difficult because a fraction of them continues to assume steroids or other immunosuppressive agents and because of the considerable clinical heterogeneity of the disease. MC shows several pathological conditions and multi-organ involvement within the same patient; therefore, follow-up becomes challenging as it involves several specialists, and each haematology or hepatology center enrolls only few cases, precluding the execution of randomized trials. The American Association for the Study of Liver Diseases (AASLD) as well as the European Association for the Study of the Liver (EASL) suggest the use of the new DAAs for treatment of patients affected by symptomatic MC even in absence of a chronic liver disease [29,30].

This review focuses on the role of DAAs in the treatment of HCV-related cryoglobulinemic vasculitis (CV), taking into account that the contribution of cryoglobulins to MC development of clinical symptoms or the clinical recommendations for the management of MC-associated life-threatening manifestations were comprehensively addressed in recent reviews [31,32].

1.1. Main studies utilizing DAAs in HCV-related CV

Sadoun et al. [33] conducted a prospective study treating 24 HCV-RNA positive CV patients (12 with cirrhosis) with sofosbuvir (SOF) plus RBV for 24 weeks, 12 of them were genotype (Gt) 1. In this study, only 17/24 cases (71%) obtained a SVR (Table 1). Concurrently with SVR, they observed purpura disappearance in 16 cases (100%), ulcer disappearance in 3 cases (100%), and arthralgias disappearance in 14 cases (100%). Improvement of nephropathy was reported in 4 cases (80%) while improvement of peripheral neuropathy was seen in 8 out of 16 cases (50%). A reduction of cryocrit levels was reported in all cases but disappearance of cryoglobulins only in 46% of cases. The C4 serum levels increased in 20 patients. The ALT became normal in all patients (Table 2). Main side effects of DAAs were mild fatigue (25%), anemia (25%), insomnia (21%), and infection (17%). Grades 3 and 4 anemia was observed in 3 patients (12.5%). Thirteen patients (54%) received erythropoietin and 3 (12.5%) received blood transfusion. Antiviral therapy was discontinued in 2 patients due to hallucination and irritability and to a grade 4 anemia.

In a retrospective study, Sise et al. [19] have reported the experience obtained in 12 patients (6 with cirrhosis and 7 with Gt1). Eight patients received SOF plus simeprevir and 4 received SOF plus RBV for 12 or 24 weeks. All patients (100%) were HCV-RNA negative after 1 month of therapy. SVR at 12 weeks (SVR12) was achieved in 10 cases (83%) (Table 1). After SVR12, they observed purpura disappearance in 83% of cases, arthralgias disappearance in 67%, neuropathy disappearance in 75%, and nephropathy improvement in 43% of cases. Six, out of 7 patients with nephropathy, received a combination of rituximab (RTX), corticosteroids and plasmapheresis before of DAAs therapy. A cryocrit reduction was reported in 9 patients (75%) but cryoglobulins disappearance was observed only in 4 cases (33%) after treatment. The rheumatoid factor (RF) level was normal in 3 patients (50%) and C4 serum levels increased from 11 to 16 mg/dl at 12 weeks. ALT level became normal in all cases (Table 2). Mild side effects were common during treatment, and 8 patients (67%) reported one adverse event during therapy. Antiviral therapy was discontinued in 2 cases (17%) for iperkalemia and for severe anxiety and insomnia. In a historical control group, 10 patients received Peg-IFN plus RBV, and only 1 achieved SVR, and they observed clinical remission without immune response.

Gagnani et al. [21] have conducted a prospective study on 44 HCV-related CV patients (23 were Gt1) of whom, 27 had chronic hepatitis and 17 had cirrhosis. The majority of these patients (57%) failed

Table 1 Main studies of DAA therapy in patients with hepatitis C virus-related cryoglobulinemic vasculitis.

Study (year)	Patients N.	SVR %	Immunological Response (Cryocrit disappearance) (%)	Clinical response		Relapse N.		Follow-up months after DAAs therapy
				Complete %	Partial %	None %	Weeks	
Sadoun et al. (2015) [33]	24	74	(46)	87	12	4	12	
Sise et al. (2016) [19]	12	83	(44)	83	8	2	12–24	
Gagnani et al. (2016) [21]	44	100	(40)	77	23	7	6	
Sollima et al. (2016) [34]	7	100	(14)	14	14	1	8	
Bonacci et al. (2017) [24]	35	94	(45)	71	14	3	8	
Sadoun et al. (2017) [22]	41	100	(50)	90	10	4	104	
Emery et al. (2017) [23]	18	89	(29)	29	47	5	20	
Lauletta et al. (2017) [25]	22	100	(59)	64	23	3	48	
Sollima et al. (2017) [35]	17	100	(41)	29	35	1	6	
Mazzaro et al. (2018) [27]	22	95	(5)	75	0	1	48	
Bonacci et al. (2018) [36]	46	100	(48)	80	11	5	96	
Cacoub et al. (2019) [28]	148	97	(53)	73	22	0	64	
Visentini et al. (2019) [37]	45	100	(38)	78	18	4	75	

Table 2
Main studies on DAA therapy in patients (n) with hepatitis C virus-related cryoglobulinemic vasculitis.

Study, year	N	MEN, median age (years)	Antiviral agent		Duration, weeks (w)	After DAA therapy	
			At enrolment	At follow-up		Disappearance/clinical manifestations after DAAs therapy (%)	Other
Sadooun et al., 2015 [33]	24	13, 56.5 (50-67)	HCV-RNA (genotype) (%)	Cryoglobulins (cryocrit) (%)	Clinical manifestations N. (%)	Liver status (%)	HCV-RNA (IU/ml) Cryocrit (%) RF (0-25 IU/ml) C4 (10-40 mg/dl) ALT ((6-78 U/l)
			1a: 6 (25) 1b: 6 (25) 2: 2 (8) 3: 6 (25) 4: 3 (13) 5: 1 (4)	Median cryoglobulin (g/L) 0.4 (0.2-0.8) Median RF: 26 (6-84) Median C4 (g/L): 0.1 (0.2-0.8) Median ALT: 49 (28-68)			
Sise et al., 2016 [19]	12	7, 61 (37-73)	HCV-RNA (genotype) (%)	Cryoglobulins (cryocrit) (%)	Clinical manifestations N. (%)	Liver status (%)	HCV-RNA: neg 10 (83) Cryoglobulin median: 0.15 (0.05-0.45) Median RF: 63 (12-859) Median C4: 0.17 (0.09-0.23) Median ALT:15 (12-20)
			1a: 5 (42) 1b: 2 (17) 1 untypeable: 1(8) 2b: 2 (17) 3: 1 (8) 4: 1 (8)	Median Cryocrit 1.5%(0.5-5) Positive RF: 9/10 Median C4: 11 (2-29) Median ALT: 41 (18-207)			
Gragani et al., 2016 [21]	44	16, 65 ± 10 (37-73)	HCV-RNA (genotype) (%)	Cryoglobulins (cryocrit) (%)	Clinical manifestations N. (%)	Liver status (%)	HCV-RNA: neg: 44 (100) Median Cryocrit 1.8 ± 5.1% RF: 39 ± 29 C4: normal:9,low:5 ALT: 27.3 ± 10.3
			1a: 2 (5) 1b: 21 (48) 2: 13 (30) 3: 5 (11) 4: 3 (7)	RF: 7.2 ± 15.4% RF: 131.2 ± 252.9 Reduced C4:14/24 ALT: 77.7 ± 77.2 Raynaud Phen.:14 (32) Nephropathy: 4 (9) Sicca syndrome:18 (41) Skin ulcers: 6 (14) NHL: 2 (5)			
Sollima et al., 2016 [34]	7	4, 62 (46-71)	HCV-RNA (genotype) (%)	Cryoglobulins (cryocrit) (%)	Clinical manifestations N. (%)	Liver status (%)	HCV-RNA:neg: 7 (100) Mean Cryocrit level: 4.4(0-10)
			1a: 1 (14) 1b: 2 (28) 2: 3 (43) 3: - 4: 1(14)	Mean Cryocrit level: 3.7 (2-9)			
Bonacci et al., 2017 [24]	35	7, 61 (53-70)	HCV-RNA (genotype) (%)	Cryoglobulins (cryocrit) (%)	Clinical manifestations N. (%)	Liver status (%)	HCV-RNA: neg: 33 (94) Cryocrit: 0.5 (0-1.4) RF: 20(10-95) C4: 0.12 (0.05-0.16) ALT: 24 (17-28) PegIFN + DAAs: 5 (14) Other: 3 (8)
			1a: 5 (14) 1b: 28 (80) 2: - 3: - 4: 2 (6)	Cryocrit: 3.2 (1.5-5.7) RF: 80 (10-200) C4: 0.02(0.01-0.11) ALT: 64 (34-115)			
Saadon et al., 2017 [22]	41	19, 56 (50-62)	HCV-RNA (genotype) (%)	Cryoglobulins (cryocrit) (%)	Clinical manifestations N. (%)	Liver status (%)	HCV-RNA:neg: 41 (100) Mean Cryoglobulin: 0.21 ± 0.14 Median RF: - Mean C4 (g/L) 0.14 ± 0.02 Mean ALT: 55.3 ± 6.4 Mean creatinine: 116 ± 23 Mean Proteinuria: 0.9 ± 0.4
			1: 25 (61) 2: 2 (5) 3: 9 (22) 4: 3 (7) 5: 3 (5)	Mean cryoglobulin (g/l): 0.56 ± 0.18 Median RF: 47 ± 17 Mean C4 (g/l): 0.08 ± (0.02) Mean ALT: 55.3 ± 6.4 Mean creatinine: 116 ± 23 Mean Proteinuria: 0.9 ± 0.4			

(continued on next page)

Table 2 (continued)

Study, year	N	MEN, median age (years)	At enrolment	Antiviral agent		Duration, weeks (w)	After DAA therapy		
				HCV-RNA (genotype) (%)	Cryoglobulins (cryocrit) (%)		Clinical manifestations N. (%)	Liver status (%)	HCV-RNA (IU/ml)
Emery et al., 2017 [23]	7, 58 (53-61)		1a: 4 (22) 1b: 5 (28) 2: 4 (22) 3: 5 (28) 4: -	Mean Cryocrit: 3.1 (2-9) Median creatinine: 104 (90-159) Median proteinuria: 3 (0-3)	Purpura: 15 (83.3) Neuropathy: 6 (33) Nephropathy: 10 (55) NHL: 6 (17)	Cirrhosis: 12 (67)	IFN/RBV/DAA: 7 (39)	HCV-RNA neg: 16 (91)	Purpura: 8 (44) Neurological: 4 (22) Nephropathy: 7 (70) Hematol. response NHL: 3 (50)
							IFN-free: 11 (61)	Median Cryocrit: 0.5 (0-2)	
							SOF + RBV: 5 (28)	Median creatinine: 95 (85-108)	
							SOF + SIM: 3 (16)	Median Proteinuria: 0.5 (0.0-1.0)	
Lauletta et al., 2017 [25]	22, 8, 6 (46-84)		1: 14 (64) 2: 7 (32) 3: 1 (5)	Mean Cryocrit: 1.8% (0.5-4) Mean RF: 69.3 (0-530) Median C4: 9.6 (0-24) Mean ALT : 104.8 (13-668) Mean Cryocrit: 3 (0.5-9)	Purpura: 22(100) Weakness: 22(100) Arthralgias: 22 (100) Neuropathy: 2(9) Glomerulonephritis: 4 (18) NHL: 3 (14) Purpura: 14 (82) Neuropathy: 9 (53) Nephropathy: 5 (29)	Chronic hepatitis: 16 (73) Cirrhosis: 6(27)	3D: 3 (14)	HCV-RNA:neg = 22 (100)	Purpura: 22 (100) Weakness:22 (100) Arthralgia:22 (100) Neuropathy improv.: 2 (100) Glomerulonephritis: 3 (75) Hematol. response NHL: 0 (0) Purpura: 5 (29) Neurophathy: 3 (33) Nephropathy: 1 (20)
							SOF + RBV: 14 (64)	Mean Cryocrit: 0.8 (0-4.6)	
							SOF + LED: 4 (18)	Mean RF: 40 (0-224)	
							SOF + DCV: 1 (5)	Mean C4: 14(2-40) Mean ALT: 21 (6-32)	
Sollima et al., 2017 [35]	17		-	Mean Cryocrit: 3 (0.5-9)	Purpura: 14 (82) Neuropathy: 9 (53) Nephropathy: 5 (29)	Follow-up: 17 (3-33) months	SOF based regimen	HCV-RNA: neg:17(100) Cryocrit undetectable: 7 (41)	Purpura: 8 (67) Arthralgias: 9 (75) Neuropathy: 7 (70) Hematol. response B-cell NHL: 0 (0)
							3D: 3 (14)	HCV-RNA:neg: 21 (95)	
							SOF + RBV: 10 (45)	Median Cryocrit: 2 (0-6)	
							SOF + SIM ± RBV: 4 (18)	Median RF: 63 (12-859)	
Mazzaro et al., 2018 [27]	22, 69 (39-22)		1a: 1 (5) 1b:11 (50) 2: 6 (27) 3: 2 (9) 4: 2 (9)	Median Cryocrit: 3% (1-20) Median RF: 111 (20-1120) Median C4: 7 (1-17) Median ALT: 72 (12-173) Cryocrit: 2.8 (1.3-5.7) RF: 50 (12-230) C4: 0.04(0.01-0.10) ALT: 65 (34-115) Creatinine: 0.78 (0.62-1.04)	Purpura: 12 (55) Arthralgias: 12 (55) Neuropathy: 10 (45) Raynaud phen.: 4 (18) Sicca syndrome: 2(9) B-cell NHL: 2 (9) Purpura: 29 (63) Weakness: 28 (61) Arthralgias: 16(35) Neuropathy: 19 (41) Nephropathy: 9 (20) Sicca syndrome: 3 (7) Purpura: 85 (57), Arthralgias: 94 (64) Skin necrosis: 15(10) Neuropathy: 86 (58) Nephropathy: 25(17) Hypertension: 44 (30) Severe vasculitis*: 43 (29) B cell-NHL: 13 (9)	Chronic hepatitis: 9 (41) Cirrhosis: 13 (59)	SOF + RBV: 10 (45)	HCV-RNA:neg: 21 (95)	Purpura: 14 (61) Weakness: 12 (52) Arthralgias: 5 (22) Neuropathy: 16 (84) Nephropathy: 6 (66) Sicca syndrome: 0 (0) Purpura: 65 (76) Arthralgias: 73 (66) Skin necrosis: 11 (10) Neuropathy: 63 (54) Nephropathy improv.: 15 (60) Hypertension control: 29 (25) Severe form of vasculitis*: 28 (65) Clinical response NHL: 10 (77) Purpura: 35 (78) Arthralgias: 16 (76) Neuropathy: 14 (41) Nephropathy: 1 (11) Hematol. response NHL: 1 (12)
							SOF + LED ± RBV: 5 (23)	Median C4:9 (3-22) Median ALT:27 (29-95)	
							SOF based regimen: 21 (46)	HCV-RNA neg: 46 (100)	
							3D regimen: 13 (28)	Cryocrit: 2.2 (1.2-5.3)	
Bonacci et al., 2018 [36]	46, 61 (53-61)		1a: 6 (13) 1b: 34 (74) 2: 1(2) 3: 2(4) 4: 3 (7)	Weakness: 28 (61) Arthralgias: 16(35) Neuropathy: 19 (41) Nephropathy: 9 (20) Sicca syndrome: 3 (7) Purpura: 85 (57), Arthralgias: 94 (64) Skin necrosis: 15(10) Neuropathy: 86 (58) Nephropathy: 25(17) Hypertension: 44 (30) Severe vasculitis*: 43 (29) B cell-NHL: 13 (9)	Chronic hepatitis: 18 (39) Cirrhosis: 28 (61)	SOF + DAC: 4 (9)	RF: 15 (11-28)	Purpura: 14 (61) Weakness: 12 (52) Arthralgias: 5 (22) Neuropathy: 16 (84) Nephropathy: 6 (66) Sicca syndrome: 0 (0) Purpura: 65 (76) Arthralgias: 73 (66) Skin necrosis: 11 (10) Neuropathy: 63 (54) Nephropathy improv.: 15 (60) Hypertension control: 29 (25) Severe form of vasculitis*: 28 (65) Clinical response NHL: 10 (77) Purpura: 35 (78) Arthralgias: 16 (76) Neuropathy: 14 (41) Nephropathy: 1 (11) Hematol. response NHL: 1 (12)	
						GZB + EBR: 3 (6)	C4: 0.06 (0.01-0.15)		
						PegIFN + DAAs: 4 (9)	ALT: 67 (53-70)		
						FDP + DLR: 1 (2)	Creatinine: 0.79 (0.7-0.9)		
Cacoub et al., 2019 [28]	148, 58, 57 (51-67)		1: 79 (53) 2:19 (13) 3: 16 (11) 4: 28 (19) 5: 5 (3) 6: 1 (1)	Cryoglobulinemia level (mg/l): 168 (50-447) Low C4 level: 61 (70) Median ALT: 45 (24-77) Creatinine: 70 (60-84)	Purpura: 85 (57), Arthralgias: 94 (64) Skin necrosis: 15(10) Neuropathy: 86 (58) Nephropathy: 25(17) Hypertension: 44 (30) Severe vasculitis*: 43 (29) B cell-NHL: 13 (9)	Chronic hepatitis: 59 (46) Cirrhosis: 70 (54)	SOF + RBV: 51 (34)	HCV-RNA:neg: 141 (97)	Purpura: 65 (76) Arthralgias: 73 (66) Skin necrosis: 11 (10) Neuropathy: 63 (54) Nephropathy improv.: 15 (60) Hypertension control: 29 (25) Severe form of vasculitis*: 28 (65) Clinical response NHL: 10 (77) Purpura: 35 (78) Arthralgias: 16 (76) Neuropathy: 14 (41) Nephropathy: 1 (11) Hematol. response NHL: 1 (12)
							SOF + DACLA: 53 (36)	Cryoglobulinemia level: 196 mg/L (72-577)	
							SOF + LED: 23 (16)	Low C4 level: 47 (70)	
							SOF + SIM: 18 (123)	Median ALT: 47 (24-79) Creatinine: 69 * (61-82)	
Visentini et al., 2019 [37]	45, 69 (40-84)		1a: 4 (9) 1b: 24 (53) 2: 10 (22) 3: 4 (9) 4: 3 (7)	Cryocrit: 7.2 ± 15.4% RF: 131.2 ± 252.9 Reduced C4:1.4/24 ALT: 77.7 ± 77.2	Purpura: 37 (82) Ulcers: 4 (9) Arthralgias: 21 (47) Neuropaty: 34 (76) Sicca syndrome: 15 (33) Nephropathy: 9 (20) NHL: 8 (18)	Cirrhosis: 18 (40)	SOF based regimen: 45 (100)	HCV-RNA: neg: 45 (100) cryocrit undetectable: 17 (38) C4 normal: 17 (38)	Purpura: 35 (78) Arthralgias: 16 (76) Neuropathy: 14 (41) Nephropathy: 1 (11) Hematol. response NHL: 1 (12)

previous treatments with IFN-based regimens. Forty four patients were treated with different SOF-based DAAs therapy. All patients (100%) had undetectable HCV-RNA viremia after one month of therapy, which remained undetectable until the 12th week (SVR12) and 24th week after therapy in all cases. After 24 weeks from therapy, all patients had CV clinical response; 41% were clinically complete responders (disappearance of all clinical signs of disease), and 23% were partial responders (improvement of the clinical symptoms; reduction of the purpura score > 50% and reduction of at least half of the baseline arthralgias and weakness), and 7% were non responders (clinical improvements less than half of baseline symptoms or stable disease) (Table 1). Purpura disappeared in 87% of cases, arthralgias in 46%, Raynaud phenomenon in 79%, Sicca syndrome in 44%, and relief of peripheral neuropathy in 50% (Table 2). Among 4 patients with renal involvement, the one with membrano-proliferative glomerulonephritis had a reduction of proteinuria and normalization of blood pressure, another had complete remission of the nephrotic syndrome, and two showed a marked improvement of the glomerular filtration rate with normalization of proteinuria (Table 2). Two patients, one with chronic skin ulcers and one with kidney disease, were treated with RTX, in combination with DAAs. In the first patient ulcers completely healed at week 8 and in the other complete remission of the nephrotic syndrome was observed at week 4 of treatment. Two cases with MC and indolent NHL (B-cell lymphocytosis and marginal zone lymphoma) showed partial regression of vasculitis and a decrease of cryocrit; neither cases had regression of either vasculitis or of monoclonal lymphocytosis. A reduction of cryocrit and RF levels were reported in the majority of cases 24 weeks after therapy. Forty percent of patients showed normal C4 levels 24 weeks after therapy (Table 2). A slight decrease of the model for End-Stage Liver Disease score was observed in 17 patients with F4 fibrosis after 24 weeks. Main side effects of DAAs were mild, and no case interrupted treatment. Anemia occurred in 13 patients (29%), all receiving RBV, eight (61%) of them required reduction of RBV dose, one suspension of RBV, and three were treated with erythropoietin. One patient required blood transfusion.

In another prospective study, Sollima et al. [34] recruited 7 patients (1 with cirrhosis; 1 Gt1a; 2 Gt1b) who were treated with different DAA combination according to Gt (Table 2). All patients (100%) achieved SVR12. Serum cryoglobulins were undetectable in 4 patients at the end of treatment but reversed to detectable during follow-up (Table 2). A clinical response at SVR12 was observed only in two patients. However, 8 weeks later one patient had a recurrence of CV despite the HCV-RNA clearance (Table 1).

Bonacci et al. [24], in a prospective study, enrolled 64 patients (35 with CV and 29 without CV) for antiviral treatment. Ten patients (16%) received IFN plus DAA combination treatment while the remaining 54 received IFN-free therapy. In CV patients, 15 (44%) had cirrhosis and 5(14%) Gt 1a, and 28 (80%) Gt 1b. Five (71%), out of 7 patients with renal involvement, had a renal biopsy confirming a membrane-proliferative glomerulonephritis (Table 2). In the overall population, 94% of patients achieved SVR12; no significant differences in SVR12 rates were observed in patients with or without CV (93 and 94%, respectively). Among CV affected patients, 71% achieved complete clinical response and 14% had partial response while 15% had no response. Overall, antiviral treatment tolerance was excellent. Anemia occurred in 11 cases (31%). Four patients treated with RBV received erythropoietin. None discontinued antiviral therapy. Renal involvement was achieved in 5 cases (71%) along with disappearance of purpura, arthralgias and weakness with a significant improvement in GFR, decrease of proteinuria and disappearance of hematuria. Peripheral neuropathy improved in 13 cases (72%). All immunological parameters improved in both groups at SVR12. Circulating cryoglobulins became undetectable in 45% and 62% in patients with or without CV, respectively (Table 2). Normalization of C4 and RF was reported in 42%, and 29% subjects with CV or without CV, respectively.

In an open-label, prospective multicenter study, Sadoon et al. [22]

enrolled 41 patients HCV-related CV (18 with cirrhosis; 25 Gt1). All patients received therapy with SOF plus delectasvir for 12 months or 24 weeks. All patients (100%) had undetectable HCV-RNA viremia after one month of therapy that remained undetectable at the end of therapy. At SVR12 and 24 weeks after therapy, 90% of patients had complete clinical response, and 10% had partial clinical response (Table 1). They observed disappearance of the purpura, arthralgias and skin ulcers in 100% of patients at the end of therapy, which remained unchanged at the 36th week in all cases. (Table 2). The disappearance of peripheral neuropathy was observed in 38% of patients at 36th week after therapy. Nephropathy improvement was observed in all five patients, of whom 3 had complete response of renal function (Table 2). One patient with stage 4, marginal zone, B-cell lymphoma with villous lymphocytes was considered in complete remission of lymphoma and in partial remission of vasculitis at the end of antiviral therapy (Table 2).

Emery et al. [23], in a retrospective study, compared 18 patients with HCV and CV with 65 with HCV without CV. In CV patients, 12 had cirrhosis and 9 were Gt1. In patients without CV, 41 had cirrhosis and 40 were Gt 1. Eleven patients (79%) with CV and 55 (85%) without CV received IFN-free therapy, while 7 cases (20%) with CV and 10 (15%) without CV received Peg-IFN-based regimes. Overall, virological response rates were similar in the two with or without CV groups (89% vs 91%, respectively). IFN-free regimens had similar success rates, 91% in CV patients and 93% without CV. Virological response with Peg-IFN-based regimens were 82% in CV and 91% in patients without CV. In CV patients, complete clinical response at SVR12 was obtained in 29% of cases with 47% of partial response and 23% of no response (Table 1). Specifically, 44% of patients with skin manifestation, 22% with neuropathy, and also 39% of patients with nephropathy who had complete symptom resolution. Median creatinine at baseline and median proteinuria was reduced after therapy in 7 (70%) patients with nephropathy (Table 2). Safety and tolerability were excellent in the patients treated with DAAs. Patients administered IFN-based regimens had significantly more adverse events. Importantly, in patients with renal insufficiency, IFN-free regimens were well tolerated without negative impact on renal function, even in those who received SOF with creatinine clearance below 30 ml/min.

In a prospective study, Lauletta et al. [25] recruited 22 HCV-related CV patients, of whom 6 (27%) had cirrhosis without signs of hepatic decompensation, 14 (64%) were Gt 1. Three patients were treated with other DAAs therapy and 19 with different SOF-based therapy plus RBV (Table 2). All 22 patients (100%) obtained SVR12. Furthermore, they observed disappearance of the Meltz's triad symptoms in 100% of patients at SVR12. Two (100%) patients with peripheral neuropathy had a partial benefit during antiviral treatment and showed progressive improvement after the end of treatment. Three (75%) patients with nephropathy improved after therapy but 1 (25%) patient experienced a worsening of renal function at SVR12. Three cases with B-cell NHL, one with stage 4 small lymphocytic lymphoma (SLL) who received SOF/RBV therapy for 24 months, despite clearance virus, followed by four RTX infusions. One marginal zone B-NHL, previously treated with Peg-IFN- α + RBV + RTX, and one with diffuse centrocyte B-cell NHL who had received chemotherapy 2 years before, resulted in CR. In this patient treated with DAAs SVR12 was reported.

One patient with SLL treated with DAAs, despite viral clearance, experienced a tumor progression that required chemotherapy in addition to RTX. Two patients who had previously received diagnosis of HCC were treated with loco-regional ablation therapies, treated with DAAs, obtained SVR12, no recurrence of disease progression was recorded. The treatment induced a reduction of cryocrit levels and RF in the majority of cases, but only 18% showed undetectable levels of cryoglobulins at the end of treatment and at SVR12. The C4 serum level increased in 13 (59%) patients at SVR12 (Table 2). Complete response was obtained in 14 (64%) patients and partial clinical response in 5 (23%) (Table 1). After few weeks of treatment, DAAs induced normalization of the ALT serum levels at SVR12. During therapy, no severe

adverse events related to DAAs therapy were observed. Two (1%) patients presented anemia secondary to RBV treatment that required dosage reduction and erythropoietin administration, but no patient interrupted treatment.

Sollima et al. [35] recruited 17 HCV-related CV patients treated with SOF-based DAAs therapy, all achieved SVR12. At post treatment follow-up (i.e., 17 months), a complete clinical response was observed in 5 (29%) cases and a partial response in 6 (35%) cases. Serum cryoglobulins were undetectable in 7 (41%) patients (Table 1). However, one patient with purpura, nephrotic syndrome and chronic kidney disease, who had achieved complete clinical and immunological response, had a relapsed of vasculitis after influenza immunization. One patient with nephrotic syndrome had obtained improvement of renal function during follow-up. Three (18%) patients, who were non responders, showed clinical and immunological improvement after RTX therapy.

A previous study [27] recruited 22 HCV-related CV patients of whom 13 (59%) had cirrhosis: 12 (54%) GT1. Nineteen (86%) patients were treated with different SOF-based therapy and 3 (14%) patients received other DAAs (Table 2). All patients (100%) achieved SVR12 but 1 (5%) who relapsed four months after the end of treatment with HCV-RNA positive, cryocrit increase, purpura and arthralgias recurrence (Table 1). This patient had genotype 1b and was affected by cirrhosis. Disappearance of the purpura in 8 (67%) patients and arthralgias in 9 (75%) were observed at week 48 of follow-up, in all cases. Symptoms relief of peripheral neuropathy was observed in 7 (70%) patients at end therapy and remained in complete response at week 48, while three cases did not show any improvement of neuropathic pain and paresthesias. Two patients with indolent NHL (marginal zone) did not show any clinical response (purpura and arthralgia) and any radiological improvement in number and size of nodes (Table 2). Complete clinical response was achieved in 75% of cases and no response in 25% of cases (Table 1). The treatment induced a reduction of cryocrit levels in 15 (68%) cases, but only 1 (5%) showed undetectable levels of cryoglobulins 48 weeks after therapy. The RF levels decreased in 16 (72%) patients, but a normal RF level was observed in only 1 (5%). A normalization of the C4 levels was not observed in any case at week 24. Only one patient (5%) obtained the complete immunological response, while 10 (45%) patients obtained a partial response. ALT became normal at end of therapy, in all 10 (100%) patients with elevated ALT that remained normal after 48 weeks of therapy (Table 2). Main side effects of DAAs were mild, with no case of therapy interruption. Six (27%) patients presented anemia secondary to RBV treatment. Four of them required reduction of RBV dose and they completed the treatment.

In a prospective, study Bonacci et al. [36] assessed the long term outcomes of HCV eradication with DAA in 46 patients with HCV-related CV and in 42 without CV. All (100%) patients achieved SVR12; no significant differences in SVR12 rates were observed in patients with CV or without CV. Most baseline features were similar between groups, including treatment regimen and duration (data not shown). At 24 months from therapy, the last follow-up evaluation, complete clinical response increased from 70% to 80% and partial clinical response from 9 to 11%. Only 4 (9%) patients were non responders at the last follow-up. In patients with CV, disappearance of purpura was observed in 14 (61%) cases, weakness in 12 (52%), and arthralgias in 5 (22%). Among patients with peripheral neuropathy, symptoms improved in 16 out of 19 patients at SVR12. Among patients with nephropathy, 6 out of 9 experienced a complete recovery at SVR12 (Table 2). At immunologic level, cryoglobulins persisted in 59% patients with CV and 45% without CV at SVR 12 (Table 2). RF values also improved in both CV and without CV in the most cases at SVR12 (Table 2). Five patients with CV relapsed during follow-up and 4 with underlying cirrhosis (Table 1). Three patients had transient episodes of purpura, one patient developed nephrotic syndrome, and another died of acute mesenteric ischemia 1 year after SVR12. None of the patients without CV developed an overt

CV during the study. Three patients received RTX, but the last cycle was administrated more than 36 months before DAAs. Overall clinical and immunologic responses were similar between patients who received immunosuppressive therapy concomitant DAA and those who did not.

Cacoub et al. [28], in a prospective multicentre study, recruited 148 consecutive patients with HCV-associated CV, of whom 70 had Child-Pugh class A cirrhosis and 79GT1. Antiviral therapy included different SOF-based DAAs therapy. SVR12 was obtained in 141 (97%) of patients. One hundred six (73%) patients showed a complete clinical response, 33 (22%) a partial response, and 7 (5%) had no response of their CV manifestations (Table 1). They observed disappearance of purpura in 65(76%) of cases, arthralgias in 73 (66%), skin necrosis in 11 (10%), and symptoms relief of peripheral neuropathy in 63 (54%) patients. Among patients with B-cell lymphoma, 10/13 (77%) cases showed a complete clinical response and 2 (15%) partial response of cryoglobulinemic manifestations (Table 1). Moreover, improvements of nephropathy, in 15/25 (60%) patients and of a severe form of vasculitis in 28/43 (65%) were observed. The treatment reduced cryoglobulinemia levels in complete response and in partial response. They did observe an increase of the mean C4 level in 47(44%) patients in complete response. Normalization of the ALT serum levels was observed at 24 weeks. During therapy, adverse events related to DAAs were observed in 20% of cases. Main side effects of DAAs were mild, and no case interrupted the therapy. Nineteen patients presented anemia secondary to RBV treatment.

Visentini et al. [37] investigated 45 HCV-related CV patients treated with guideline-tailored DAAs and followed-up for a median time of 18.5 (9–38) months. A complete clinical response was observed in 78% of cases, a partial response in 18% of cases and only 4% of patients were non-responders (Table 1). Thirty-eight percent of patients showed a complete laboratory response with negativization of cryoglobulins and normalization of C4 levels and 42% of patients still had detectable cryoglobulins at the end of follow-up (Table 1). The authors described the behavior of circulating B-cell clones, detected at baseline in 40% of the patients, until the end of follow-up and found that their size remained substantially unchanged and did not correlate with the persistence of cryoglobulins or vasculitis manifestations. In this cohort of patients three cases experienced a clinical relapse, characterized in all cases by purpura and in one case by progression of neuropathy.

1.2. Relapses of mixed cryoglobulinemic vasculitis after DAAs

In the era of antivirals, interferon-based treatments, relapses of mixed cryoglobulinemic vasculitis despite viral eradication have been described and usually associated with the development of NHL [38]. The main studies reported in this review, in particular those with longer follow-up, have found several cases of vasculitis relapses, and additional small case series or case reports have described the recurrence of MC after viral eradication with DAAs [35–37,39,40]. Relapses seemed not to be limited to a determined time-space after DAA treatment, as they were observed 3 and 25 months after therapy. The majority of patients who relapsed had mainly a genotype 1 and were affected by cirrhosis. All patients relapsed with a positive cryocrit and vasculitis manifestations ranged from single and transient episodes of purpura to severe and life threatening manifestations (Table 1). Visentini et al. [37] and other authors [41] showed that clonal RF positive B cells expanded in MC patients, persisting in peripheral blood long after the eradication of chronic antigen stimulation provided by HCV. In addition, it has been suggested that vasculitis recurrence might be related to the activation of these persisting clonal B-lymphocytes [42]. Concomitant diseases, as infections and cancers, might contribute to the pathogenic mechanisms involved in vasculitis relapses through the production of high amounts of immune complexes that activate RF positive clonal B cells [40].

2. Discussion

The association of Peg-IFN plus RBV has been considered for many years the best antiviral therapy in HCV infections and in HCV related CV [13,14]. This therapy showed a virological response rate lower than that found in patients with HCV without CV. Since 2015, Peg-IFN therapy has been substituted by the new DAAs therapy, which have shown a nearly 100% virological response rate. Several study have reported that virological response in CV patients is similar to those without CV. In all these studies, no serious side effects causing treatment suspension were observed. The most common adverse reactions were mild fatigue, insomnia, and anemia in patients receiving RBV [19,21,27,43,44].

Today RBV-associated anemia is overcome by the new approved DAAs, such as glecaprevir/pibrentasvir [45] or SOF/velpatasvir [46] or grazoprevir/elbasvir [47] combinations, no longer including RBV. The clinical and immunological responses seem less satisfactory than the virological response. In fact, despite the viral eradication, the cryoglobulins in the serum and RF persisted in half the patients. Also C4 level resulted unchanged in most cases. In almost 50% of the patients, immunological response was associated with clinical response. These findings have indicated that production of cryoglobulins and RF had become independent of virus replication, as previously suggested by Artemova et al. [48]. This means that several independent clones of B-cells, which continue to produce both cryoglobulins and auto-reactive immunoglobulins, are present even in absence of the B-cell-receptor or CD81 stimulation by the viral proteins.

In the studies included in this review, the disappearance or improvement of the vasculitis symptoms such as purpura and arthralgias, became evident in 265/313 (84%) cases, after the end therapy and during follow-up (Figure 1). In our historical series of patients affected by CV treated with Peg-IFN, we observed a relief from purpura and arthralgias symptoms in 59% of cases, even in patients with still detectable HCV-RNA [13]. In these studies, improvement of peripheral neuropathy after few months of DAAs therapy emerged in 110 out of 240 (42%) of patients (Fig. 1). Few cases achieved improved prevalent motor peripheral neuropathy after DAAs therapy.

The patients affected by sensory motor peripheral neuropathy treated with DAA who achieved virus clearance, but remained clinically non responders, during follow-up were treated with RTX, achieving clinical and immunological improvement. Rituximab can be considered in patients with severe sensory motor peripheral neuropathy prior to induction of antiviral therapy, to obtain a reasonable and timely therapeutic response [49].

In our historical series of patients treated with Peg-IFN plus RBV, we observed improvement of symptoms of prevalent sensory neuropathy in 32% of cases [13].

In the majority of the analyzed studies, the improvement of HCV-related CV with nephropathy became evident at the end of DAA therapy or, during follow-up in 46/95 (48%) cases (Table 1, Fig. 1). This data is relevant since renal involvement in CV is associated with poor prognosis [50]. The patients affected by CV with nephropathy treated with DAA, but without clinical response, were treated during follow-up with RTX or apheresis, achieving immunological and kidney function improvement [33,35,51]. Rituximab is currently the first-line immunosuppressive agent for HCV-related glomerulonephritis [52].

The failure of the DAAs treatment on the B lymphocyte alterations induced by HCV is even more evident in the observations of the hematological responses. In fact, among patients with an overt indolent NHL B-cells, a complete or partial hematological response was observed in these studies at the end DAA therapy or at follow-up in 5/22 (23%) of patients (Table 1). However, in one center among patients with NHL, 10 showed a complete clinical response and 2 patients showed a partial response of cryoglobulinemia manifestation [28]. A fraction of these patients required conventional chemotherapy or monotherapy with anti-CD20 antibodies some months after the antiviral treatment for progressive disease [28,33]. Even most cases with clonal B-cells in peripheral blood without overt lymphoma did not show a disappearance of neoplastic cells from peripheral blood [27]. These findings pose the question about a relationship between HCV and NHL. In fact, previous studies had observed the efficacy of antiviral treatment with IFN-based regimens in HCV-related B-cell NHL [53–55]. Therefore, it has been demonstrated that HCV-positive lympho-proliferative diseases are associated with HCV replications and that the viral eradication is associated with the disappearing of the clonal B cells. It is likely that the previous satisfactory results on HCV-positive NHL were more correlated to the anti-proliferative activity of alfa-IFN than to its antiviral properties. Alfa-IFN, given its powerful anti-proliferative activities, has been used for decades in treatment of several chronic lymphoproliferative syndromes such as myeloma. A review of clinical studies on alfa-IFN in the management of multiple myeloma [56], hairy cell leukemia [57], indolent NHL [58], chronic lymphocytic leukemia [59,60], and it continues to be proposed for treatment of primary thrombocythemia [61]. Alfa-IFN, together with the clearance of HCV-RNA, could counteract the clonal expansion of B-lymphocytes and the cryoglobulin production. The DAAs are able to eliminate viral replication very efficiently; nevertheless, they have less efficient anti-proliferative properties and are less able to prevent B-cell monoclonal proliferation and cryoglobulins production. These observations are also in contrast with the theory of the pathogenesis of the HCV-NHL, always thought as driven by the chronic antigen stimulation [62,63], although the possibility of other mechanisms can be supposed.

Arcaini et al. [64] described the efficacy of the DAAs therapy in a significant number of indolent NHL patients. In this study, the

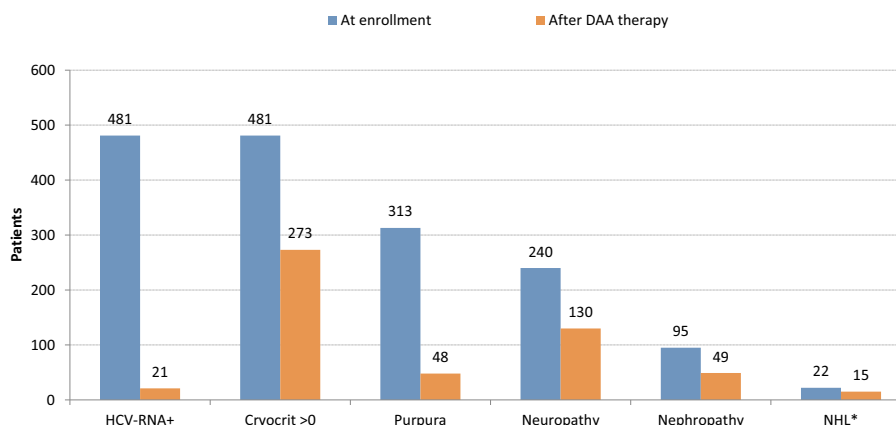


Fig. 1. Summary of hepatitis C virus (HCV) positivity, cryocrit positivity, purpura, peripheral neuropathy, nephropathy, and NHL at enrollment and after DAA therapy.

hematological responses were not satisfactory, since only a small fraction of cases (21%) obtained complete NHL remission, while most cases, after a partial remission, relapsed or had a disease progression and they had to be treated with immunotherapy and chemotherapy. Our previous paper [12], as well as other authors [65], has shown that IFN-based treatments were efficient in HCV-positive indolent NHL. In those cases, the anti-proliferative feature of alfa-IFN had a possibility in the cure of lympho-proliferative diseases, rather than its antiviral properties. It has been reported that RTX can be effective in various clinical manifestations of CV, including purpura, skin ulcers, arthralgias, glomerulonephritis, and peripheral neuropathy, in addition to inducing a complete hematological response in a large fraction of low-tumor-burden follicular lymphoma [66–68] (Table 1).

3. Conclusion

The studies included in this review demonstrated that IFN-free DAAs therapy in HCV-CV reported high virological responses, while immunological and clinical responses were less satisfactory. On the contrary, the nephropathy and lympho-proliferative disorders alterations induced by HCV seemed to respond poorly to DAAs, and most cases needed immunotherapy or chemotherapy. In case of a lack of clinical response, more often in severe CV (in case of nephropathy progressive or peripheral neuropathy motor progressive or NHL non responder a DAAs) a second line treatment with RTX might be used. In HCV related CV, the main clinical goal must be early eradication of HCV, to avoid organ complication and manifestation of lympho-proliferative disease.

Funding

This research is supported by the Italian Ministry of Health (Ricerca Corrente 2019).

Declaration of Competing Interest

The authors have no conflict of interests to declare.

Acknowledgements

The authors thank Luigina Mei for editorial assistance.

References

- [1] Lavanchy D. The global burden of hepatitis C. *Liver Int* 2009;29:74–8.
- [2] Ferri C, Zignego AL, Giuggioli D, Sebastiani M, Cazzato M, Antonelli A, et al. HCV and cryoglobulinemic vasculitis. *Clin J Med* 2002;69(Suppl. 2):S1120–3.
- [3] Agnello V, Chung RT, Kaplan LM. A role for hepatitis C virus infection in type II cryoglobulinemia. *N Engl J Med* 1992;327:1490–5.
- [4] Andreone P, Zignego AL, Cursaro C, Gramenzi A, Gherlinzoni F, Fiorino S, et al. Prevalence of monoclonal gammopathies in patients with hepatitis C virus infection. *Ann Intern Med* 1998;129:294–8.
- [5] Dal Maso L, Franceschi S. Hepatitis C virus and risk of lymphoma and other lymphoid neoplasms: a meta-analysis of epidemiologic studies. *Cancer Epidemiol Biomarkers Prev* 2006;15:2078–85.
- [6] IARC. Monographs on the evaluation of carcinogenic risks to humans volume 100 part B: A review of human carcinogens: Biological agents. Lyon: IARC Press; 2012 Available from: <http://monographs.iarc.fr/ENG/Monographs/vol100B/mono100B.pdf>.
- [7] Cacoub P, Gragnani L, Comarmond C, Zignego AL. Extrahepatic manifestations associated with hepatitis C virus infection. *Dig Liver Dis* 2014;46:S165–73.
- [8] Monti G, Pioltelli P, Saccardo F, Campanini M, Candela M, Cavallero G, et al. Incidence and characteristics of non-Hodgkin lymphomas in a multicenter case file of patients with hepatitis C virus-related symptomatic mixed cryoglobulinemias. *Arch Intern Med* 2005;165:101–5.
- [9] Pozzato G, Mazzaro C, Dal Maso L, Mauro E, Zorat F, Moratelli G, et al. Hepatitis C virus and non-Hodgkin's lymphomas: metanalysis od epidemiology data and therapy options. *World J Hepatol* 2016;8:107–16.
- [10] Arcaini L, Vallisa D, Rattotti S, Ferretti VV, Ferreri AJ, Bernuzzi P, et al. Antiviral treatment in patients with indolent B-cell lymphomas associated with HCV infection: a study of the fondazione Italiana Linfomi. *Ann Oncol* 2014;25:1404–10.
- [11] Hermine O, Lefrere F, Browicki JP, Mariette X, Jondeau K, Eclache-Saudreau V, et al. Regression of splenic lymphoma with villous lymphocytes after treatment of hepatitis C virus infection. *N Engl J Med* 2002;347:89–94.
- [12] Mazzaro C, De Re V, Spina M, Dal Maso L, Festini G, Comar C, et al. Pegylated-interferon plus ribavirin for HCV-positive indolent non-Hodgkin lymphomas. *Br J Haematol* 2009;145:255–7.
- [13] Mazzaro C, Monti G, Saccardo F, Zignego AL, Ferri C, De Vita S, et al. Efficacy and safety of peginterferon alfa-2b plus ribavirin for HCV-positive mixed cryoglobulinemia: a multicentre open-label study. *Clin Exp Rheumatol* 2011;29:933–41.
- [14] Pietrogrogrande M, De Vita S, Zignego AL, Pioltelli P, Sansonno D, Sollima S, et al. Recommendations for the management of mixed cryoglobulinemia syndrome in hepatitis C virus-infected patients. *Autoimmunity Rev* 2011;10:444–54.
- [15] Gragnani L, Fognani E, Piluso A, Boldrini B, Urraro T, Fabbrizzi A, et al. Long-term effect of HCV eradication in patients with mixed cryoglobulinemia: a prospective, controlled, open-label, cohort study. *Hepatology* 2015;61:1145–53.
- [16] Lawitz E, Sulkowski MS, Ghalib R, Rodriguez-Torres M, Younossi ZM, Corregidor A, et al. Simeprevir plus sofosbuvir, with or without ribavirin, to treat chronic infection with hepatitis C virus genotype 1 in non-responders to pegylated interferon and ribavirin and treatment-naïve patients: the COSMOS randomised study. *Lancet* 2014;384(9956). (1756–65. Erratum in: *Lancet* 2014; 384(9956): 1748).
- [17] Webster DP, Klenerman P, Dusheiko GM. Hepatitis C. *Lancet* 2015;385(9973):1124–35.
- [18] Saadoun D, Thibault V, Si Ahmed SN, Alric L, Mallet M, Guillaud C, et al. Sofosbuvir plus ribavirin for hepatitis C virus-associated cryoglobulinemia vasculitis: VASCULVALDIC study. *Ann Rheum Dis* 2016;75:1777–82.
- [19] Sise ME, Bloom AK, Wisocky J, Lin MV, Gustafson JL, Lundquist AL, et al. Treatment of hepatitis C virus-associated mixed cryoglobulinemia with direct-acting antiviral agents. *Hepatology* 2016;63:408–17.
- [20] Gragnani L, Piluso A, Urraro T, Fabbrizzi A, Fognani E, Petracchia L, et al. Virological and clinical response to interferon-free regimens in patients with HCV-related mixed cryoglobulinemia: preliminary results of a prospective pilot study. *Curr Drug Targets* 2017;18:772–85.
- [21] Gragnani L, Visentini M, Fognani E, Urraro T, De Santis A, Petracchia L, et al. Prospective study of guideline-tailored therapy with direct-acting antivirals for hepatitis C virus-associated mixed cryoglobulinemia. *Hepatology* 2016;64:1473–82.
- [22] Saadoun D, Pol S, Ferfar Y, Alric L, Hezode C, Si Ahmed SN, et al. Efficacy and safety of sofosbuvir plus daclatasvir for treatment of HCV-associated cryoglobulinemia vasculitis. *Gastroenterology* 2017;153:49–52.
- [23] Emery JS, Kuczynski M, La D, Almarzooqi S, Kowgier M, Shah H, et al. Efficacy and safety of direct acting antivirals for the treatment of mixed cryoglobulinemia. *Am J Gastroenterol* 2017;112:1298–308.
- [24] Bonacci M, Lens S, Londoño MC, Marino Z, Cid MC, Ramos-Casals M, et al. Virologic, clinical, and immune response outcomes of patients with hepatitis C virus-associated Cryoglobulinemia treated with direct-acting antivirals. *Clin Gastroenterol Hepatol* 2017;15:575–83.
- [25] Lauletta G, Russi S, Pavone F, Vacca A, Dammacco F. Direct-acting agents in the therapy of hepatitis C virus related mixed cryoglobulinemia: a single Centre experience. *Arthr Res Ther* 2017;19:74.
- [26] Sollima S, Milazzo L, Vassalini P, Antinori S, Galli M. Recurrence of mixed cryoglobulinemia vasculitis following influenza vaccination despite clearance of hepatitis C virus infection. *Clin Exp Rheumatol* 2018;36(Suppl. 111):161–2.
- [27] Mazzaro C, Dal Maso L, Quartuccio L, Ghersetti M, Lenzi M, Maruro E, et al. Long-term effects of the new direct antiviral agents (DAAs) therapy for HCV-related mixed cryoglobulinemia: a multicentre open-label study. *Clin Exp Rheumatol* 2018;36(Suppl. 111):107–14.
- [28] Cacoub P, Si Ahmed SN, Ferfar Y, Pol S, Thabut D, Hezode C, et al. Long-term efficacy of interferon-free antiviral treatment regimens in patients with hepatitis C virus-associated Cryoglobulinemia Vasculitis. *Clin Gastroenterol Hepatol* 2019;17:518–26.
- [29] American Association for the study of the liver Disease (AASLD). HCV Guidance: Recommendations for Testing, Managing, and Treating Hepatitis C. <http://www.hcvguidelines.org>. (Last access August 2019).
- [30] European Association for the study of the liver. EASL recommendations on treatment of hepatitis C 2015. *J Hepatol* 2015;63:199–236.
- [31] Kolopp-Sarda MN, Miossec P. Cryoglobulins: an update on detection, mechanisms and clinical contribution. *Autoimmun Rev* 2018;17:457–64.
- [32] Galli M, Monti G, Marson P, Scaini P, Pietrogrogrande M, Candela M, et al. Recommendations for managing the manifestations of severe and life-threatening mixed cryoglobulinemia syndrome. *Autoimmun Rev* 2019;18:778–85.
- [33] Saadoun D, Resche RM, Pol S, Thibault V, Blanc F, PIALoux G, et al. PegIFN/ribavirin/protease inhibitor combination in severe hepatitis C virus-associated mixed cryoglobulinemia vasculitis. *J Hepatol* 2015;62:24–30.
- [34] Sollima S, Milazzo L, Peri AM, Torre A, Antinori S, Galli M. Persistent mixed cryoglobulinemia vasculitis despite hepatitis C virus eradication after interferon-free antiviral therapy. *Rheumatology (Oxford)* 2016;55:2084–5.
- [35] Sollima S, Milazzo L, Antinori S, Galli M. Direct-acting antivirals and mixed cryoglobulinemia Vasculitis: long-term outcome of patients achieving HCV eradication. *Am J Gastroenterol* 2017;112:1753–4.
- [36] Bonacci M, Lens S, Mariño Z, et al. Long-term outcomes of patients with HCV-associated cryoglobulinemic Vasculitis after virologic cure. *Gastroenterology* 2018;155:311–5.
- [37] Visentini M, Del Padre M, Colantuono S, Yang B, Minafo YA, Antonini S, et al. Long-lasting persistence of large B-cell clones in hepatitis C virus-cured patients with complete response of mixed cryoglobulinemia vasculitis. *Liver Int* 2019;39:628–32.
- [38] Landau DA, Saadoun D, Halfon P, Martinot-Peignoux M, Marcellin P, Fois E, et al.

- Relapse of hepatitis C virus-associated mixed cryoglobulinemia vasculitis in patients with sustained viral response. *Arthritis Rheum* 2008;58:604–11.
- [39] Chowdhury R, Tsen A. Recurrent mixed Cryoglobulinemia despite sustained Virologic response to treatment: a case report. *Am J Kidney Dis* 2017;70:301–4.
- [40] Visentini M, Quartuccio L, Del Padre M, Colantuono S, Minafo YA, Fiorilli M, et al. Late relapses of hepatitis C virus-cured mixed cryoglobulinaemia associated with infection or cancer. *Rheumatology (Oxford)* 2018;57:1870–1.
- [41] Del Padre M, Todi L, Mitrevski M, Marrapodi R, Colantuono S, Fiorilli M, et al. Reversion of anergy signatures in clonal CD21 low B cells of mixed cryoglobulinemia after clearance of HCV viremia. *Blood* 2017;130:35–8.
- [42] Kaplan DE. Persistence of exhaustion in cured hep C. *Blood* 2017;130:4. <https://doi.org/10.1182/blood-2017-05-786368>.
- [43] Passerini M, Schiavini M, Magni CF, Landonio S, Niero F, Passerini S, et al. Are direct-acting antivirals safe and effective in hepatitis C virus-cryoglobulinemia? Virological, immunological, and clinical data from a real-life experience. *Eur J Gastroenterol Hepatol* 2018;30:1208–15.
- [44] Fuentes A, Mardones C, Burgos PJ. Understanding the Cryoglobulinemias. *Understanding the cryoglobulinemia Curr Rheum TOL Rep* 2019;21:60.
- [45] Hubbard H, Lawitz E. Glecaprevir + pibrentasvir (ABT493 + ABT-530) for the treatment of hepatitis C. *Expert Rev Gastroenterol Hepatol* 2018;12:9–17.
- [46] Weisberg IS, Jacobson IM. A pangenotypic, single tablet regimen of sofosbuvir/velpatasvir or the treatment of chronic hepatitis C infection. *Expert Opin Pharmacother* 2017;18. 535–4.
- [47] Vallet-Pichard A, Pol S. Grazoprevir/elbasvir combination therapy for HCV infection. *Therap Adv Gastroenterol* 2017;10:155–67.
- [48] Artemova M, Abdurakhmanov D, Ignatova T, Mukhin N. Persistent hepatitis C virus-associated cryoglobulinemic vasculitis following virus eradication after direct-acting antiviral therapy. *Hepatology* 2017;65:1770–1.
- [49] Scarpato S, Galassi G, Monti G, Mazzaro C, Mascia M, Scaini P, et al. Peripheral neuropathy in Mixed Cryoglobulinaemia: clinical assessment and therapeutic approach. *Clin Exper Rheumatol* 2020 ((in Press) article code: CER13359 revision (20200414220423–15529)).
- [50] Mazzaro C, Panarello G, Tesio F, Santini G, Crovatto M, Mazzi G, et al. Hepatitis C virus risk: a hepatitis C virus related syndrome. *J Intern Med* 2000;247:535–45.
- [51] Fabrizio F, Cerutti R, Porata G, Messa P, Ridruejo E. Direct-acting antiviral agents for HCV-associated glomerular disease and the current evidence. *Pathogens* 2019;8:176.
- [52] Kidney Disease Improving Global Outcomes (KDIGO), Hepatitis C Work Group. Clinical Practice Guideline for the prevention, diagnosis, evaluation, and treatment of hepatitis C chronic kidney disease. *Kidney Int* 2018;8(Suppl):91–165.
- [53] Mazzaro C, Franzin F, Tulissi P, Pussini E, Crovatto M, Carniello GS, et al. Regression of monoclonal B-cell expansion in patients affected by mixed cryoglobulinemia responsive to alpha-interferon therapy. *Cancer* 1996;77:2604–13.
- [54] Patriarca F, Silvestri F, Fanin R, Zaja F, Sperotto A, Baccarani M. Long-lasting complete remission of hepatitis C virus (HCV) infection and HCV-associated immunocytoma with alpha-interferon treatment. *Br J Haematol* 2001;112:370–2.
- [55] Vallisa D, Bernuzzi P, Arcaini L, Sacchi S, Callea V, Marasca R, et al. Role of anti-hepatitis C virus (HCV) treatment in HCV-related, low-grade, B-cell, non-Hodgkin's lymphoma: a multicenter Italian experience. *J Clin Oncol* 2005;23:468–73.
- [56] Cooper MR. A review of the clinical studies of alpha-interferon in the management of multiple myeloma. *Semin Oncol* 1991;18(5 Suppl 7):18–29.
- [57] Golomb HM, Ratain MJ, Mick R, Daly K. The treatment of hairy cell leukemia: an update. *Leukemia* 1992;6(Suppl. 2):24–7.
- [58] Foon KA, Roth MS, Bunn Jr. PA. Alpha interferon treatment of low-grade B-cell non-Hodgkin's lymphomas, cutaneous T-cell lymphomas, and chronic lymphocytic leukemia. *Semin Oncol* 1986;13(3 Suppl 2):35–42.
- [59] Jewell AP. Interferon-alpha, Bcl-2 expression and apoptosis in B-cell chronic lymphocytic leukemia. *Leuk Lymphoma* 1996;21:43–7.
- [60] Pozzato G, Franzin F, Moretti M, Tulissi P, Pecorari P, Melato M, et al. Low-dose “natural” alpha-interferon in B-cell derived chronic lymphocytic leukemia. *Haematologica* 1992;77:413–7.
- [61] Gisslinger H, Zagrijtschuk O, Buxhofer-Ausch V, Thaler J, Schloegl E, Gastl GA, et al. Rpeginterferon alfa-2b, a novel IFN α -2b, induces high response rates with low toxicity in patients with polycythemia vera. *Blood* 2015;126:1762–9.
- [62] Rosa D, Saletti G, De Gregorio E, Zorat F, Comar C, D'Oro U, et al. Activation of naïve B lymphocytes via CD81, a pathogenetic mechanism for hepatitis C virus-associated B lymphocyte disorders. *Proc Natl Acad Sci U S A* 2005;102:18544–9.
- [63] Bachy E, Besson C, Suarez F, Hermine O. Hepatitis C virus infection and lymphoma. *Mediterr J Hematol Infect Dis* 2010;2:e2010004.
- [64] Arcaini L, Besson C, Frigeni M, Fontaine H, Goldaniga M, Casato M, et al. Interferon-free antiviral treatment in B-cell lymphoproliferative disorders associated with hepatitis C virus infection. *Blood* 2016;128:2527–32.
- [65] Mihăilă RG. Hepatitis C virus-associated B cell non-Hodgkin's lymphoma. *World J Gastroenterol* 2016;22:6214–23.
- [66] Quartuccio L, Soardo G, Romano G, Zaja F, Scott CA, De Marchi G, et al. Rituximab treatment for glomerulonephritis in HCV-associated mixed cryoglobulinaemia: efficacy and safety in the absence of steroids. *Rheumatology* 2006;45:842–6.
- [67] Auzeurie V, Chiali A, Bussel A, Brouet JC, Fermanand JP, Dubertret L, et al. Leg ulcers associated with cryoglobulinemia: clinical study of 15 patients and response to treatment. *Arch Dermatol* 2003;139:391–3.
- [68] Colombat P, Brousse N, Salles G, Morschhauser F, Brice P, Soubeyran P, et al. Rituximab induction immunotherapy for first-line low-tumor-burden follicular lymphoma: survival analyses with 7-year follow-up. *Ann Oncol* 2012;23:2380–5.