

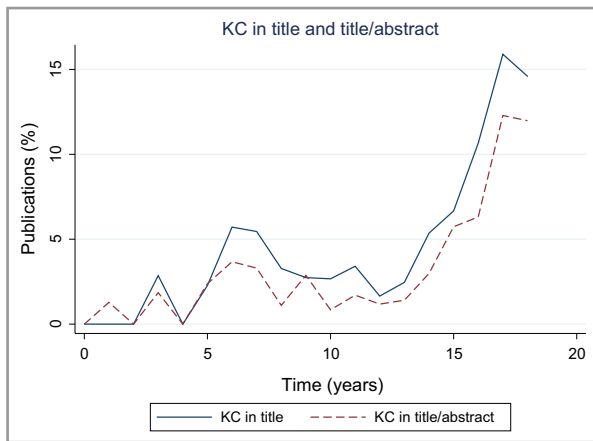Fig 1. Graph of annual trends in usage of the medical terms keratinocyte carcinoma(s) and keratinocyte cancer(s) (KC) from 2000 to 2018.

under the title of NMSC. Let us abandon the outdated, ambiguous term NMSC.

We are seeing substantial evidence of early success in using language that is more appropriate for referring to the most common skin cancers in the U.S.A.

## Acknowledgments

The opinions expressed in this manuscript are those of the authors, not the Department of Veterans Affairs or the United States Government.

M. Beatson<sup>1,2,3</sup> , A. Misitzis<sup>1,2</sup>, R.A. Lew<sup>4</sup> and M.A. Weinstock<sup>1,2</sup> 

<sup>1</sup>Center for Dermatopidemiology-111D, Veterans Affairs Medical Center, Providence, Rhode Island, U.S.A.; <sup>2</sup>Department of Dermatology, Alpert Medical School of Brown University, Providence, Rhode Island, U.S.A.; <sup>3</sup>George Washington University School of Medicine, Washington, D.C., USA.; and <sup>4</sup>VA Healthcare System, Boston, Massachusetts, U.S.A.  
 E-mail: mbeatson@gwu.edu

## References

- Rogers HW, Weinstock MA, Feldman SR, Coldiron BM. Incidence estimate of nonmelanoma skin cancer (keratinocyte carcinomas) in the U.S. population, 2012. *JAMA Dermatol* 2015; **151**:1081–6.
- Karimkhani C, Boyers L, Dellavalle RP, Weinstock MA. It's time for "keratinocyte carcinoma" to replace the term "nonmelanoma skin cancer". *J Am Acad Dermatol* 2015; **72**:186–7.

Funding sources: none.

Conflicts of interest: none to declare.

## The detection rate of human papillomavirus in well-differentiated squamous cell carcinoma and keratoacanthoma: is there new evidence for a viral pathogenesis of keratoacanthoma?

DEAR EDITOR, The 'keratinocyte skin cancer' term stands as a sort of umbrella covering different stages within the progression of cutaneous squamous cell carcinoma (cSCC).<sup>1</sup> The invasive forms are further classified on the basis of histopathological differentiation grade as well-differentiated, moderate and poorly-differentiated cSCC. Whether or not keratoacanthoma (KA) represents a form of well-differentiated tumour currently remains a matter of debate.

About 80% of cSCC arise on the head/neck area, mainly in the context of field cancerization, whereas KA may develop in other body sites suggesting a different pathogenesis of KA. In 1986, Gassenmaier et al. found a positivity for human papilloma virus (HPV) DNA in 12 of 32 (38%) samples of solitary KAs.<sup>2</sup> Thereafter, Forslund et al. detected cutaneous HPV DNA in 51% (37 of 72) of KAs. However, the authors concluded that the role of HPV in KAs remained elusive.<sup>3</sup> More recently, Arroyo Mühr et al. found that alpha and beta HPV can be sequenced from most skin disease specimens (including cSCC and KA).<sup>4</sup>

In order to better define whether KA is a well-differentiated cSCC or not, we conducted a pilot study investigating the presence of HPV in a series of KA and well-differentiated SCC. For this study, we defined tumours arising within a field of cancerization in association with actinic keratoses as well-differentiated SCC, whereas those developing in the absence of actinic keratosis were considered KA. We selected only cases that allowed the assessment of field cancerization signs from our database for clinical images collected between 2015 and 2018.

After this retrospective selection, DNA and RNA were extracted from paraffin embedded samples of the selected cSCC and KAs. The presence of HPV DNA was detected by nested polymerase chain reaction (PCR) with CP65/CP70 outer-CP66/CP69 inner, and MY09/MY11 outer-GP5<sup>+</sup>/GP6<sup>+</sup> inner primers to amplify a wide spectrum of HPV, according to standardized procedures.<sup>5</sup> Amplified products were subjected to direct sequencing using automated apparatus that allows the detection of the most dominant type. HPV type 16 positive samples were analysed for the presence of E6 viral oncoprotein mRNA by reverse-transcription (RT) real-time PCR using specific Taqman primers. The other HPV-positive samples were analysed by RT PCR for the presence of L1 (capsid protein) viral mRNA with CP primers. Each single sample was matched with a sample where no reverse-transcriptase was added; absence of amplified products indicated that no

**Table 1** Characteristics of the keratoacanthoma (n = 19) and squamous cell carcinoma (n = 22) samples

Type and sample ID	Age (years)	Sex	Location	HPV type
<b>Keratoacanthoma</b>				
1	68	M	Abdomen	16
2	69	M	Sternum	19
3	75	M	Leg	113
4	66	F	Leg	16
5	77	M	Arm	18
6	86	M	Leg	104
7	59	F	Leg	24
8	76	M	Abdomen	–
9	52	F	Leg	209
10	76	F	Leg	–
11	76	F	Leg	16
12	76	F	Leg	164
13	81	M	Leg	16
14	70	F	Leg	–
15	68	M	Arm	20
16	77	M	Back	113
17	62	F	Arm	174
18	76	F	Arm	16
19	64	F	Sternum	16
<b>Squamous cell carcinoma</b>				
1	86	M	Hand	–
2	82	M	Leg	105
3	93	M	Leg	174
4	71	M	Ear	99
5	75	M	Ear	16
6	85	M	Ear	16
7	67	F	Leg	16
8	88	M	Head	38
9	89	M	Ear	–
10	93	F	Hand	–
11	83	M	Face	107
12	85	M	Head	–
13	85	M	Face	–
14	69	M	Arm	–
15	65	F	Leg	–
16	84	M	Face	–
17	85	M	Head	–
18	81	M	Head	18
19	68	M	Head	–
20	80	M	Head	151
21	83	M	Head	–
22	92	M	Head	104

HPV, human papilloma virus; M, male; F, female.



contaminating DNA was present. Unfortunately, RT PCR with specific L1 primers cannot be performed for the limited quantity of extracted RNA.

In total, 22 cases of well-differentiated SCC and 22 of KA were analysed and those with available DNA are reported in Table 1. HPV DNA was detected in 84% (16 out of 19 samples) and 50% (11 out of 22 samples) of KA and cSCC, respectively. This difference was statistically significant (two-

tailed Fisher's exact test,  $P = 0.046$ ) and beta HPVs were more frequent than alpha HPV in both KA and sSCC. Sequence analysis revealed several different HPV genotypes (Table 1). SCC scored positive for HPV type 16 (27%), 18 (9%), 38 (9%), 99 (9%), 104 (9%), 105 (9%), 107 (9%), 151 (9%) and 174 (9%); whereas KA scored positive for HPV type 16 (38%), 18 (6%), 19 (6%), 20 (6%), 24 (6%), 104 (6%), 113 (13%), 164 (6%), 174 (6%) and 209 (6%). RT real-time PCR showed that 50% (three out of six samples) of HPV type 16 positive KA expressed the E6 gene, whereas no expression of HPV16 E6 was seen in the cSCC samples. Overall, RT PCR for the L1 gene revealed presence of L1 transcripts in 27% (three out of 11 samples) of HPV-positive cSCC samples, whereas no KA samples showed their presence.

In conclusion, our pilot study revealed differences with regard to the rate of HPV detection between cSCC and KA. HPV is carried in 84% of KAs, but their role with regards carcinogenesis remains to be determined. RNA analysis suggested that KA samples have no L1 production but 50% showed the presence of E6, whereas 27% of SCC samples showed L1 expression and none showed E6. This would imply that in KA there is latent (episomal) or integrated HPV but no productive infections, which in contrast seems to be present in SCC.

On the basis of data reported here, a causality link between HPV and skin cancer cannot be definitively ascertained. However, results of this pilot study will be useful for the interpretation of future interventional or mechanistic studies, with the aim of better understanding the role of HPV in keratinocyte skin tumours and to assess if HPV detection could be a tool to better define a diagnosis of KA, as we showed the highest positivity of HPV in these lesions.

C. Conforti<sup>1</sup> , F. Paolini<sup>2</sup>, A. Venuti<sup>2</sup> , C. Dianzani<sup>3</sup> and I. Zalaudek<sup>1</sup>

<sup>1</sup>Dermatology Clinic, Maggiore Hospital, Piazza dell'Ospitale 1, University of Trieste, Trieste, Italy; <sup>2</sup>HPV-Unit, Unità Operativa Semplice Dipartimentale (UOSD) Tumor Immunology and Immunotherapy, IRCCS Regina Elena National Cancer Institute, Rome, Italy; and <sup>3</sup>Department of Plastic, Reconstructive and Cosmetic Surgery, Campus Bio-Medico University Hospital, Rome, Italy  
E-mail: claudioconforti@yahoo.com

C.C. and F.P. contributed equally as first authors.

## References

- 1 Fernandez Figueras MT. From actinic keratosis to squamous cell carcinoma: pathophysiology revisited. *J Eur Acad Dermatol Venerol* 2017; **31** (Suppl. 2):5–7.
- 2 Gassenmaier A, Pfister H, Hornstein OP. Human papillomavirus 25-related DNA in solitary keratoacanthoma. *Arch Dermatol Res* 1986; **279**:73–6.
- 3 Forslund O, DeAngelis PM, Beigi M et al. Identification of human papillomavirus in keratoacanthomas. *J Cutan Pathol* 2003; **30**:423–9.

- 4 Arroyo Mühr LS, Hultin E, Bzhalava D et al. Human papillomavirus type 197 is commonly present in skin tumors. *Int J Cancer* 2015; **136**:2546–55.
- 5 Dianzani C, Paolini F, Conforti C et al. Human papilloma virus expression in immuno-competent patients with actinic keratosis: a case series. *J Am Acad Dermatol* 2017; **77**:770–2.

Funding sources: this work was partially supported by research project 'Regione Lazio-Lazio-Innova', funded under the L.R. 13/08 and by an IRE internal grant.

Conflicts of interest: none to declare.

## Use of dupilumab in patients who are HIV-positive: report of four cases

DEAR EDITOR, Atopic dermatitis (AD) and prurigo nodularis (PN) are defined by the drive to itch. Indeed, AD is so intensely pruritic, it is described as the itch that rashes. Incidences of AD and PN are higher in patients with HIV, with a prevalence of 30–50% in patients who are HIV-positive, in contrast to a prevalence of 2–5% in seronegative adults.<sup>1</sup> Additionally, approximately 39% of patients with HIV have PN, supporting PN as the most frequent skin disorder in patients who are HIV-positive.<sup>1</sup>

Dupilumab, a novel monoclonal interleukin (IL)-4/IL-13 antagonist, is the first biologic approved for the treatment of moderate-to-severe AD. Recent reports have described that dupilumab provides improvement in patients with PN.<sup>2</sup> Unfortunately, the effects of dupilumab in patients who are HIV-positive are unknown, as these patients were excluded from clinical trials. Herein, we describe four patients with HIV, two with concomitant AD and two with concomitant

PN, that were treated safely and successfully with dupilumab. All patients reported an improvement in the severity of itch as measured by the numerical rating scale for itch intensity (NRSi). Clinical improvement was noted for all patients as measured by the Investigator's Global Assessment (IGA). NRSi, IGA and HIV laboratory values are summarized in Table 1.

Superpotent topical steroids and topical calcineurin inhibitors failed to provide benefit in all patients. Narrowband ultraviolet B failed in patients with schedules that allowed for regular phototherapy sessions. Treatment with dupilumab was initiated using standard dosing regimen of a 600-mg induction dose followed by 300 mg every 2 weeks. No adverse events were reported.

Patient 1 was a man in his 60s with severe PN. The pre-dupilumab viral load was 168 copies mL<sup>-1</sup>, the absolute CD4 count was 229 cells µL<sup>-1</sup> and the CD4/CD8 ratio was 0.16. An initial NRSi of 7/10 was reported by the patient. After 2 weeks of dupilumab, NRSi improved to 4/10. At 1-, 4-, 6- and 9-month follow-ups the patient reported an NRSi of 0/10. Stepwise clinical improvement was noted with dupilumab.

Patient 2 was a man in his 60s with severe PN. The pre-dupilumab viral load was undetectable, the absolute CD4 count was 1058 cells µL<sup>-1</sup> and the CD4/CD8 ratio was 0.77. With an initial patient reported NRSi of 10/10, this patient desired more aggressive treatment but also wanted to avoid all frankly immunosuppressive medications, such as prednisone, despite well-controlled HIV. At 1-month follow-up, the patient-reported NRSi improved to 5/10. At 2-, 3- and 6-month follow-ups the NRSi was 0/10.

Patient 3 was a woman in her 20s with severe AD. Pre-dupilumab, the viral load was undetectable, the absolute CD4 count was 860 cells µL<sup>-1</sup> and the CD4/CD8 ratio was 2.1. At 2- and 4-month follow-ups, the patient reported an NRSi of 0/10.

Patient 4 was a woman in her 40s with severe AD. As a result of poorly controlled HIV disease, topicals and narrow-band ultraviolet B were attempted for an extended period. After failure to improve and the patient's desire for aggressive

Table 1 HIV disease activity during treatment with dupilumab

	Patient 1	Patient 2	Patient 3	Patient 4
Indication	Prurigo nodularis	Prurigo nodularis	Atopic dermatitis	Atopic dermatitis
Pre-dupilumab				
Viral load, copies mL <sup>-1</sup>	168	Undetectable	Undetectable	276 000
Absolute CD4 count, cells µL <sup>-1</sup>	229	1058	860	77
CD4/CD8 ratio	0.16	0.77	2.1	0.06
IGA	4/4	4/4	4/4	4/4
NRSi	7/10	10/10	Unreported	10/10
Post-dupilumab				
Length of follow-up, months	9	6	4	4
Viral load, copies mL <sup>-1</sup>	Undetectable	Undetectable	Undetectable	121 000
Absolute CD4 count, cells µL <sup>-1</sup>	188	1206	1012	92
CD4/CD8 ratio	0.22	0.74	2.3	0.07
IGA	1/4	1/4	1/4	1/4
Final NRSi	0/10	0/10	0/10	2/10

IGA, Investigator's Global Assessment; NRSi, numerical rating scale for itch intensity.