

Accepted: 11 April 2020

Secukinumab-induced subacute cutaneous lupus erythematosus

Dear Editor,

Drug-induced lupus erythematosus (DILE) is a well-known entity first described as an adverse effect of hydrochlorothiazide, terbinafine, and TNF- α inhibitors. Among the possible drugs associated with DILE, recently an association with IL-17 inhibitors has been reported, highlighting new and little-known side effects of biological therapies.^{1,2}

We present a case of a 62-year-old man with a history of plaque psoriasis, previously treated with methotrexate, acitretin and anti-TNF- α , switched on treatment with secukinumab 300 mg due to a loss of efficacy of other drugs. After the fourth dose at week 4, he developed a generalized itchy rash with multiple scaly erythematous plaques localized on his trunk, neck, and back; in addition, a widespread desquamation associated with severe blepharitis and mild

ectropium, not present at the beginning of therapy, was observed on the face (Figure 1A,B). Lesions were first interpreted as an early onset of erythrodermic psoriasis; photosensitive dermatitis and drug reaction were also considered in the differential diagnosis.

The dermoscopic examination (DermLite3G, 20 \times) showed telangiectatic vessels, with erythematous background, some yellowish areas and minimal desquamation, contrary to classical dermoscopic psoriatic criteria (Figure 1C).

Therefore, either a severe seborrheic dermatitis or a subacute lupus was considered in differential diagnosis. Two punch biopsies of 4 mm on two patches of the back, skin swab, and microbiological research of fungi were performed, with blood tests analysis and complete study of autoimmunity. Results showed positivity of antinuclear

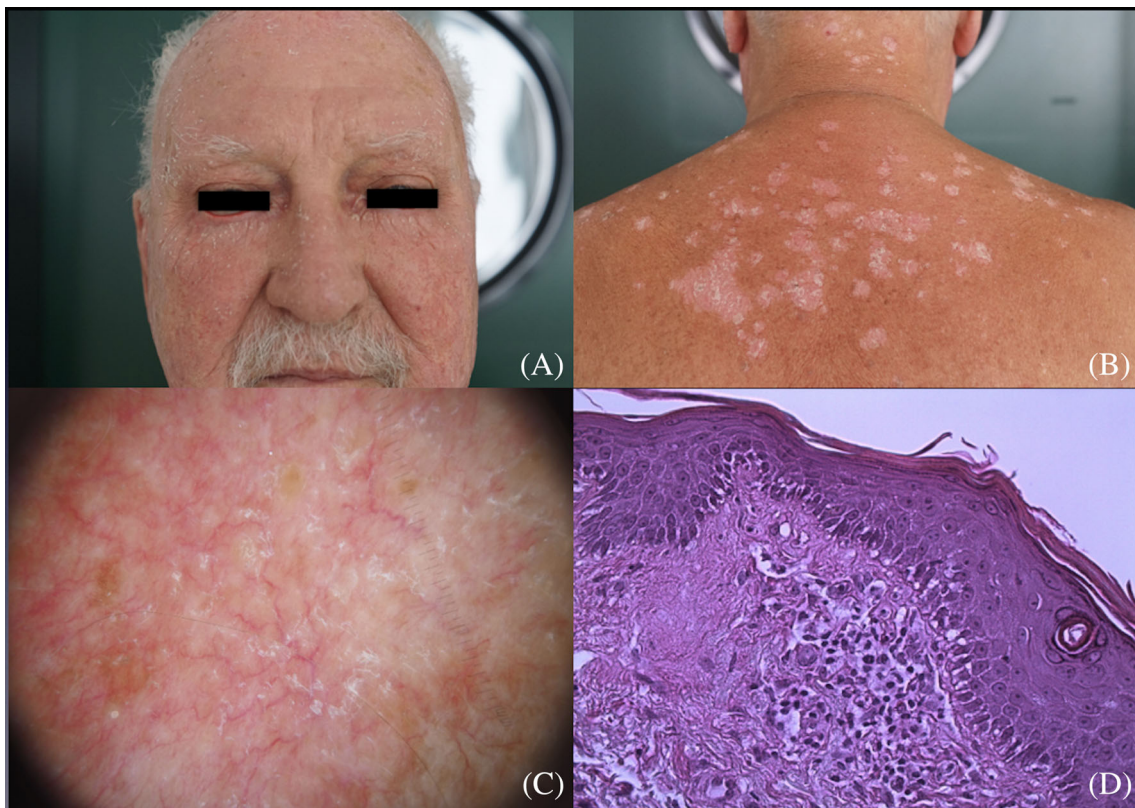

FIGURE 1 Diffuse facial erythema with bilateral mild ectropion and severe blepharitis, A, and finely flaky psoriasis-like plaques on the back, B. Dermoscopy of the back lesions showed an erythematous background with linear vessels and fine whitish scales, C. Histology shows evident vacuolization of the keratinocytes of the basal layer of the epidermis, perivascular infiltrate of lymphocytes, normal granular layer, and necrotic keratinocytes, D

antibodies (1:160) with speckled pattern, anti-SSA/Ro and antihistone antibodies, while the skin swab and research for fungi were negative. Histological examination showed perivascular infiltrate of lymphocytes, parabasal vacuolization, normal granular layer and necrotic keratinocytes (Figure 1D), features suggestive of subacute cutaneous lupus. Thus, a conclusive diagnosis of secukinumab-induced subacute cutaneous lupus erythematosus (SCLE) was made. Secukinumab was discontinued and treatment with hydroxychloroquine and topical clobetasol propionate 0.05% was started, with gradual improvement of the rash in about 45 days.



SCLE is a nonscarring dermatosis, typically located on the face, chest, back, and the extensor surface of the upper limbs. Sometimes it can be associated with blepharitis and ectropion, as observed in our patient.³ Drugs such as spironolactone, hydrochlorothiazide, naproxen, ace-inhibitors, interferon, terbinafine, and anti-TNF-alfa are well recognized triggers of SCLE. Recently a correlation with the anti IL12/23 ustekinumab has been reported.⁴

Few reports in literature described secukinumab or ustekinumab-induced SCLE and its pathogenesis is poorly understood. Data available suggest that inhibiting interleukin-12 and/or -23, T cell differentiation is diverted to the production of T cell 22 with an increase production of TNF-alfa, a cytokine involved in the pathogenesis of various inflammatory and autoimmune diseases. TNF-alfa can lead to a translocation of Ro/SSA and La/SSB autoantigens on the keratinocytes surface, attracting immunoglobulins, and complement in the dermoepidermal junction and causing the typical injury at this level of SCLE.⁵

Naranjo et al proposed a tool to evaluate the probability of true adverse drug reaction. It consists of 10 questions on the relationship between drug and adverse reaction giving an estimate of the possibility, probability or certainty of the correlation.⁶ In our case, the overall score was 5, suggesting the probability of secukinumab-induced SCLE.

CONFLICT OF INTEREST

The authors declare no potential conflict of interests.

Claudio Conforti¹ 
 Chiara Retrosi¹
 Roberta Giuffrida² 
 Roberta Vezzoni¹
 Damiano Currado³
 Luca Navarini³

Eleonora Farinazzo¹
 Carmen Dell'Aquila⁴
 Katuscia Nan¹
 Nicola Di Meo¹
 Iris Zalaudek¹

¹Dermatology and Venereology Department, University of Trieste, Ospedale Maggiore di Trieste, Italy

²Department of Clinical and Experimental Medicine, Dermatology, University of Messina, Messina, Italy

³Unit of Allergology, Immunology, Rheumatology, Department of Medicine, University of Campus Bio-Medico of Rome, Rome, Italy

⁴Department of Medical, Surgical Sciences and Health, Eye Clinic, University of Trieste, Trieste, Italy

Correspondence

Roberta Giuffrida, Department of Clinical and Experimental Medicine, Dermatology, University of Messina, via Consolare Valeria n°1, 98125 Messina, Italy.

Email: roberta_giuffrida@hotmail.it

ORCID

Claudio Conforti  <https://orcid.org/0000-0001-5126-8873>

Roberta Giuffrida  <https://orcid.org/0000-0002-5492-3033>

REFERENCES

- Conforti C, Currado D, Vezzoni R, et al. Erythema multiforme induced by secukinumab: clinical, dermoscopic, and histological features. *J Clin Rheumatol*. 2020; <https://doi.org/10.1097/RHU.0000000000001315> [Epub ahead of print].
- Currado D, Margiotta D, Conforti C, et al. New onset of psoriasis induced by secukinumab in a patient with ankylosing spondylitis: a case report. *Scand J Rheumatol*. 2020;49:75-76.
- Kopsachilis N, Tsaousis KT, Tourtas T, Tsinouopoulos IT. Severe chronic blepharitis and scarring ectropion associated with discoid lupus erythematosus. *Clin Exp Optom*. 2013;96:124-125.
- Goh SW, Jamil A, Nor NM, Cader RA, Shaharir SS. Exacerbation of systemic lupus erythematosus in a patient with concomitant chronic plaque psoriasis treated with ustekinumab. *Indian J Dermatol Venereol Leprol*. 2020;86:68-70.
- Tierney E, Kirthi S, Ramsay B, Ahmad K. Ustekinumab-induced subacute cutaneous lupus. *JAAD Case Rep*. 2019;5:271-273.
- Naranjo CA, Busto U, Sellers EM, et al. A method for estimating the probability of adverse drug reactions. *Clin Pharmacol Ther*. 1981;30:239-245.