



# Anti-EGFR Therapy in Metastatic Small Bowel Adenocarcinoma: Myth or Reality?

Emanuela Dell'Aquila<sup>1\*</sup>, Tea Zeppola<sup>1\*</sup>, Marco Stellato<sup>1</sup> , Francesco Pantano<sup>1</sup>, Mario Scartozzi<sup>2</sup>, Cristina Madaudo<sup>1</sup>, Filippo Pietrantonio<sup>3</sup>, Chiara Cremolini<sup>4</sup>, Giuseppe Aprile<sup>5</sup>, Bruno Vincenzi<sup>1</sup>, Roberto Moretto<sup>4</sup>, Marco Puzzone<sup>2</sup>, Silvio Ken Garattini<sup>6</sup>, Riccardo Lobefaro<sup>3</sup> , Giuseppe Tonini<sup>1</sup> and Daniele Santini<sup>1</sup>

<sup>1</sup>Department of Medical Oncology, Campus Bio-Medico University of Rome, Rome, Italy.

<sup>2</sup>Medical Oncology, University Hospital and University of Cagliari, Cagliari, Italy. <sup>3</sup>Medical Oncology Department, Fondazione IRCCS Istituto Nazionale dei Tumori, Milano, Italy. <sup>4</sup>Unit of Medical Oncology 2, Department of Translational Research and New Technologies in Medicine and Surgery, Azienda Ospedaliera Universitaria Pisana, Pisa, Italy. <sup>5</sup>Department of Oncology, San Bortolo General Hospital, Vicenza, Italy. <sup>6</sup>Department of Oncology, University Hospital of Udine, Udine, Italy.

Clinical Medicine Insights: Oncology

Volume 14: 1–5

© The Author(s) 2020

Article reuse guidelines:

[sagepub.com/journals-permissions](https://sagepub.com/journals-permissions)

DOI: 10.1177/1179554920946693



## ABSTRACT

**BACKGROUND:** Due to the relative rarity of small bowel adenocarcinoma (SBA), prospective trials, helping to guide therapeutic decisions, are lacking and the optimal therapy for advanced SBA is unknown. The role of targeted agents, such as anti-epidermal growth factor receptor (EGFR) and anti-vascular endothelial growth factor (VEGF), is unknown.

**PATIENTS AND METHODS:** This is a retrospective multicenter observational study that included patients with metastatic SBA treated with anti-EGFR antibodies (cetuximab or panitumumab) ± chemotherapy in the first (I) or second (II) line.

**RESULTS:** Thirteen patients with metastatic SBA, recruited from 5 Italian referral institutions, were included in the present retrospective analysis. All patients received anti-EGFR inhibitors as a single agent or in association with chemotherapy. More common G2 treatment-related side effects were skin reaction (8 patients, 53.8%), hypomagnesemia (6 patients, 46.2%), and diarrhea (8 patients, 61.5%). Grade 3 diarrhea was observed in only 1 patient. Conjunctivitis was not reported in any patients. Grade 4 toxicity was not reported. In the overall population, median progression-free survival was 5.526 months (95% confidence interval [CI]: 3.684–12.467). Median overall survival was 15.86 months (95% CI: 14.43–24.30). Complete response was observed in 15% of patients, partial response in 39% of patients, stable disease in 23% of patients, and progression disease in 15% of patients.

**CONCLUSIONS:** In this retrospective analysis, anti-EGFR inhibitors showed to be a suitable addendum to chemotherapy in the I and II line, with an excellent tolerance and safety profile both in I and II line.

**KEYWORDS:** Small bowel adenocarcinoma, anti-EGFR inhibitors, chemotherapy, toxicity, cetuximab, panitumumab

**RECEIVED:** March 4, 2020. **ACCEPTED:** July 2, 2020.

**TYPE:** Original Article

**FUNDING:** The author(s) received no financial support for the research, authorship, and/or publication of this article.

**DECLARATION OF CONFLICTING INTERESTS:** The author(s) declared no potential conflicts of interest with respect to the research, authorship, and/or publication of this article.

**CORRESPONDING AUTHOR:** Marco Stellato, Department of Medical Oncology, Campus Bio-Medico University of Rome, Via Alvaro del Portillo 200, 00128 Rome, Italy. Email: [m.stellato@unicampus.it](mailto:m.stellato@unicampus.it)

## Background

Malignant small bowel tumors are very rare, and they account for 0.1% to 0.3% of all malignancies.<sup>1</sup>

The most common histologic subtype of carcinoma of the small bowel is adenocarcinoma (small bowel adenocarcinoma [SBA]); it makes up 40% of all small intestine malignant tumors.<sup>2</sup>

In the last few years, improvements in imaging and endoscopic techniques have led to improved detection of small bowel tumors, but most SBA is still diagnosed only at an advanced stage.<sup>3</sup>

Due to its relative rarity, the clinical characteristics, the treatment modalities, and prognosis of SBA are not well known and prospective trials specific to this disease are lacking. The

survival of patients with advanced SBA is poor, with a median overall 5-year survival rate of 3% to 5%.<sup>4,5</sup>

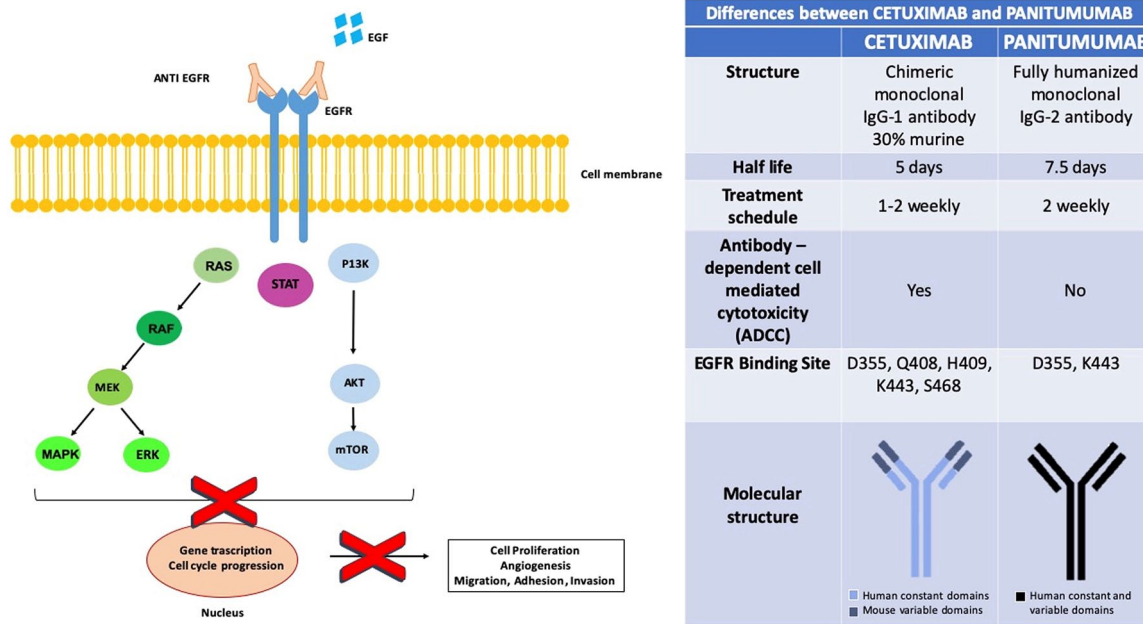
Surgery is the gold standard for localized disease,<sup>6</sup> but no clinical trials evaluated the benefit of surgical resection in metastatic SBA.

In advanced or metastatic disease, retrospective studies show that chemotherapy can improve the survival of patients compared with no treatment,<sup>7</sup> but prospective trials are absent so the optimal therapy for advanced or metastatic SBA is unknown.

The most effective agents include 5-fluorouracil, irinotecan, oxaliplatin, platinum agents, and gemcitabine, with median overall survival (OS) ranging between 8.1 and 22.2 months.<sup>8–10</sup>

\*The two authors contributed equally.





**Figure 1.** Association between anti-EGFR inhibitors. EGFR indicates epidermal growth factor receptor.

The role of targeted agents routinely used in the treatment of colorectal cancer (CRC; anti-epidermal growth factor receptor [EGFR] and anti-vascular endothelial growth factor inhibitors) is unidentified.

The use of bevacizumab and anti-EGFRs has been reported in individual patients but further evaluation is warranted.<sup>11,12</sup> These results, along with findings from the genomic characterization of SBA, suggest that SBA represents a unique intestinal malignancy, and treatments should not be habitually extrapolated from CRC.

Gulhati et al<sup>13</sup> showed that monotherapy with panitumumab has no clinical activity in metastatic RAS wild-type SBA and ampullary adenocarcinoma (AAC)

In this retrospective multicenter study, we proposed to describe for the first time the feasibility of the association between anti-EGFR inhibitors (cetuximab and panitumumab) and chemotherapy in patients with metastatic SBA, independently from *RAS* status (Figure 1).

## Patients and Methods

This retrospective observational multicenter study included patients with metastatic SBA treated with anti-EGFR monoclonal antibodies (cetuximab or panitumumab) ± chemotherapy and was conducted in 5 Italian hospital centers (Campus Bio-Medico University of Rome, Rome; University and General Hospital, Udine; Fondazione IRCCS Istituto Nazionale dei Tumori, Milan; University of Cagliari, Cagliari; and Azienda Ospedaliera Universitaria Pisana, Unit of Medical Oncology 2, Pisa).

Patients received their diagnosis and treatment from 2002 to 2016.

Inclusion criteria were histologically proven SBA, Eastern Cooperative Oncology Group Performance Status (PS)=0 to 2,

measurable disease according to Response Evaluation Criteria in Solid Tumors (RECIST) 1.1 criteria, and adequate bone marrow function and renal and hepatic functions.

Patients with poor PS or patients who received more than 1 line of therapy before anti-EGFR-based treatment were excluded. RAS status was not considered an inclusion criterion.

Variables assessed included sex, histotype, site of the tumor (duodenum, jejunum, ileum), grading, number of metastasis (single/multiple), site of metastasis, toxicities (conjunctivitis, diarrhea, hypomagnesemia, skin toxicity), resected primary tumor (yes or no), and Köhne prognostic score.

## Statistical methods

Descriptive statistics were used for patient demographics and clinical response parameters. Time-to-progression intervals were determined by the Kaplan-Meier method. Toxicity assessment was used to describe treatment-related side effects.

The ethics committee of the coordination center has approved this multicenter retrospective observational study.

Furthermore, the ethics committee deemed unnecessary written consent in consideration of the fact that the data the study was built on were related to patients already dead by the time it was conducted, and therefore, their treatment was in no way impacted or influenced by it. The methods were performed by following the approved guidelines.

## Results

Thirteen patients with metastatic SBA were included in the present retrospective analysis. Patients' characteristics are summarized in Table 1.

**Table 1.** Patients' characteristics.

CHARACTERISTICS	OVERALL POPULATION N = 13 (%)
Age	
Range	48-80
Median	67
Sex (%)	
Male	11 (84.6)
Female	2 (15.4)
Site of primary tumor (%)	
Duodenum	4 (30.8)
Jejunum	4 (30.8)
Ileum	5 (38.5)
Grading	
G1	1 (7.7)
G2	4 (30.8)
G3	8 (61.5)
Resected primitive tumor	
No	3 (23.1)
Yes	10 (76.9)
Köhne score (%)	
High risk	5 (38.5)
Intermediate risk	3 (23.1)
Low risk	4 (30.8)
Not assessable	1 (7.7)
Number of metastasis	
Single	1 (7.7)
Multiple	12 (92.3)
Metastases (%)	
Liver	
No	5 (38.5)
Yes	8 (61.5)
Bone	
No	11 (84.6)
Yes	2 (15.4)
Lung	
No	8 (61.5)
Yes	5 (38.5)

**Table 2.** Anti-EGFR-based treatment.

LINE	TREATMENT	OVERALL POPULATION N = 13 (%)
I line	CET Folfiri	5 (38.5)
	CET	1 (7.7)
II line	CET Folfiri	3 (23.1)
	CET CPT11	3 (23.1)
	CET Folfox	1 (7.7)
Total		13 (100)

Abbreviations: CET, cetuximab; EGFR, epidermal growth factor receptor.

All patients received anti-EGFR inhibitors in association with chemotherapy, just 1 patient received anti-EGFR as a single agent.

Six patients (46.2 %) received anti-EGFRs in the first (I) line setting and 7 patients (53.8%) in the second (II) line setting. Patients did not receive the same chemotherapy backbone in I and II line (see Table 2).

According to RECIST 1.1 criteria, complete response (CR) was observed in 2 patients (15%), partial response (PR) in 5 patients (39%), progression disease (PD) in 2 patients (15%), and stable disease (SD) was described in 3 patients (23%).

In I line setting, PD was observed in 33% of patients (2 patients), PR in 33% of patients (2 patients), and 1 patient reached SD. In 1 patient, CR was described.

In the II line setting, 3 patients reached PR (42%), 2 patients reached SD (28%). In 1 patient, CR was observed. The median duration of response was 6.23 months (95% confidence interval [CI]: 2.87-13.42).

In the overall population, median progression-free survival (PFS) was 5.526 months (95% CI: 3.684-12.467), calculated from the date of diagnosis to the date of radiological progression or death if it ever occurred first. Median OS was 15.86 months (95% CI: 14.43-24.30), calculated as the length of time from the date of diagnosis or the start of treatment in which half of the diagnosed patients are still alive.

The patient treated with anti-EGFR monotherapy progressed after 1 month of therapy with an OS of 1.7 months.

More common G2 treatment-related side effects were skin reaction (8 patients, 53.8%), hypomagnesemia (6 patients, 46.2%), and diarrhea (8 patients, 61.5%). Grade 3 diarrhea was observed in only 1 patient who required a 25% reduction of anti-EGFR dose. Conjunctivitis was not reported in any patients. Grade 4 toxicity was not reported (see Table 3).

## Discussion

Small bowel adenocarcinoma is a rare and aggressive disease with limited therapeutic options. The choice of treatment is

**Table 3.** Patients' side effects.

SIDE EFFECTS	GRADE	OVERALL POPULATION N = 13 (%)
Skin reaction	G2	8 (61.5)
Hypomagnesemia	G2	6 (46.2)
Diarrhea	G2	8 (61.5)
Diarrhea	G3	1 (7.7)
Conjunctivitis	G2	Not reported

often a challenge and, due to its relative rarity, limited evidence is available to guide clinicians in diagnosis and treatment.

The molecular pathology of SBA is not yet well known as in CRC; to find a molecular target to reach the goal of personalized therapy, several studies put their efforts to better understand biology and genetics of this disease.

There are biological differences between CRC and SBA, which may be due not only to the different embryological origins but also to the higher levels of lymphoid aggregates and IgA levels in the small intestine compared with the colon.

This difference could increase tumor immunity and subsequent different biological behavior.<sup>1,14</sup> Despite multiple differences, the 2 tumors share some characteristics, and therefore, the oncologists usually tend to treat SBA as CRC, as suggested by guidelines.

The role of anti-EGFR inhibitors has been investigated in patients with SBA in single cases and more recently in a Phase II trial by Gulhati et al.<sup>13</sup> In this trial, the authors meant to show the activity of panitumumab in metastatic RAS wild-type SBA (8 patients) and AAC (1 patient) patients with refractory disease to I line chemotherapy. The primary end point was response rate. Two patients achieved SD and 7 patients had progressive disease. The median PFS was 2.4 months and the median OS was 5.7 months. This clinical trial was originally designed to evaluate the addition of panitumumab to CAPOX in patients with SBA and AAC. The study was modified due to the toxicities developed in the first 3 patients.<sup>13</sup> Even if the trial did not meet the primary end point, the reported results and the findings from genomic characterization of SBA should be taken into account because they suggest that SBA is a different intestinal malignancy and treatment should not be extrapolated from metastatic colorectal cancer (mCRC). Moreover, authors state that further trials are warranted to evaluate the benefit of target therapies only in patients with metastatic small bowel adenocarcinoma (mSBA).

In our retrospective analysis, anti-EGFR inhibitors showed to be a feasible addendum to chemotherapy. The safety and tolerability profile was satisfactory both in I and II line, with skin reaction and diarrhea as the most common side effects. Only 1 patient reported G3 toxicity which consisted of diarrhea.

In our study, the association of an anti-EGFR with chemotherapy like oxaliplatin or irinotecan did not demonstrate increased toxicity and reported toxicity profile was consistent with the toxicities showed in mCRC.<sup>15</sup>

So far, we cannot define the activity of anti-EGFRs in our population, but we can affirm that the use of anti-EGFR in association with different schedules of chemotherapies is feasible and safe and showed manageable toxicities and promising results even in a small sample size.

Although it is the most numerous in the literature, the number of patients enrolled is limited and this is mostly due to the low incidence of SBA.

Even if the rarity of the disease makes difficult to design and conduct prospective clinical trials, further prospective randomized trials are expected to confirm the efficacy of anti-EGFR in mSBA to validate anti-EGFR as a standard of care.

## Conclusions

In conclusion, anti-EGFR treatment in association with chemotherapy showed interesting results of feasibility and safety profile both in I and II line settings.

There are very few data available for this treatment for SBA, and this series is the largest one. Nevertheless, further studies in a larger and prospective setting are needed to validate the use of these agents in this specific setting.

## Author Contributions

All authors contributed equally to this article.

## ORCID iDs

Marco Stellato  <https://orcid.org/0000-0002-0993-7540>

Riccardo Lobefaro  <https://orcid.org/0000-0003-3484-9718>

## REFERENCES

- Lowenfels AB. Why are small-bowel tumours so rare? *Lancet*. 1973;1:24-26.
- Chow JS, Chen CC, Ahsan H, Neugut AI. A population-based study of the incidence of malignant small bowel tumours: SEER, 1973-1990. *Int J Epidemiol*. 1996;25:722-728.
- Overman MJ, Hu CY, Kopetz S, Abbruzzese JL, Wolff RA, Chang GJ. A population-based comparison of adenocarcinoma of the large and small intestine: insights into a rare disease. *Ann Surg Oncol*. 2012;19:1439-1445.
- Aparicio T, Zaanan A, Svrcek M, et al. Small bowel adenocarcinoma: epidemiology, risk factors, diagnosis, and treatment. *Dig Liver Dis*. 2014;46:97-104.
- Raghav K, Overman MJ. Small bowel adenocarcinomas: existing evidence and evolving paradigms. *Nat Rev Clin Oncol*. 2013;10:534-544.
- Tran TB, Qadan M, Dua MM, Norton JA, Poultsides GA, Visser BC. Prognostic relevance of lymph node ratio and total lymph node count for small bowel adenocarcinoma. *Surgery*. 2015;158:486-493.
- Halfdanarson TR, McWilliams RR, Donohue JH, Quevedo JF. A single-institution experience with 491 cases of small bowel adenocarcinoma. *Am J Surg*. 2010;199:797-803.
- Fishman PN, Pond GR, Moore MJ, et al. Natural history and chemotherapy effectiveness for advanced adenocarcinoma of the small bowel: a retrospective review of 113 cases. *Am J Clin Oncol*. 2006;29:225-231.
- Speranza G, Doroshov JH, Kummar S. Adenocarcinoma of the small bowel: changes in the landscape? *Curr Opin Oncol*. 2010;22:387-393.
- Tsushima T, Taguri M, Honma Y, et al. Multicenter retrospective study of 132 patients with unresectable small bowel adenocarcinoma treated with chemotherapy. *Oncologist*. 2012;17:1163-1170.
- Tsang H, Yau T, Khong PL, Epstein RJ. Bevacizumab-based therapy for advanced small bowel adenocarcinoma. *Gut*. 2008;57:1631-1632.

12. Santini D, Fratto ME, Spoto C, et al. Cetuximab in small bowel adenocarcinoma: a new friend? *Br J Cancer*. 2010;103:1305.
13. Gulhati P, Raghav K, Shroff R, et al. Phase II study of panitumumab in RAS wild-type metastatic adenocarcinoma of small bowel or ampulla of Vater. *Oncologist*. 2018;23:277-278.
14. Neugut AI, Jacobson JS, Suh S, et al. The epidemiology of cancer of the small bowel. *Cancer Epidemiol Biomarkers*. 1998;7:243-251.
15. Petrelli F, Ardito R, Ghidini A, et al. Different toxicity of cetuximab and panitumumab in metastatic colorectal cancer treatment: a systematic review and meta-analysis. *Oncology*. 2018;94:191-199.