




Causality in COVID-19-associated stroke: a uniform case definition for use in clinical research

Alberto Vogrig¹  · Daniele Bagatto² · Gian Luigi Gigli^{1,3,4} · Milena Cobelli⁵ · Serena D'Agostini² · Claudio Bnà⁶ · Mauro Morassi⁵

Received: 17 July 2020 / Accepted: 21 July 2020
© Springer-Verlag GmbH Germany, part of Springer Nature 2020

Keywords SARS-CoV-2 · COVID-19 · Ischemic stroke · Hemorrhagic stroke · Neurological complications · Cerebrovascular disease

Dear Sirs,

Increasing evidence supports the association between the novel severe acute respiratory syndrome coronavirus 2 (SARS-CoV-2), the etiologic agent of the coronavirus disease 2019 (COVID-19), and neurological complications, including encephalopathy, encephalitis, Guillain–Barré syndrome, and cerebrovascular disease [1, 2]. In particular, both ischemic and hemorrhagic strokes have been linked to COVID-19 [3–5]. Since a substantial proportion of these reported patients had associated vascular risk factors, it is crucial to determine whether this association is causal or coincidental [1, 3, 6]. In an effort to systematically assess this issue, Shtaya et al. proposed to classify cases of COVID-19-related stroke in three major groups:

(1) hospital acquired; (2) community acquired; (3) stroke as direct complications of COVID-19 [7]. Most of the cases of our report [3] and other series [4, 5] fulfill the criteria for the latter group as defined by the authors. Conversely, we did not encounter hospital-acquired COVID-19 infections in patients hospitalized for stroke, since protective measures were readily implemented in our institutions. Although we believe that this proposed classification is valuable in highlighting a relevant clinical problem, these definitions are based on both epidemiological data (location of infection, as for pneumonia, difficult to ascertain in real-life settings) and pathogenetic aspects (as in group 3, for which few information is available at the moment), making their use impractical. Moreover, we believe that it is possible that some patients can fit two of the proposed categories (e.g., patients with community-acquired COVID-19 can develop stroke as direct complication of SARS-CoV-2). Ellul et al. suggested an alternative classification, subdividing cases with “probable” (SARS-CoV-2 identified, lack of vascular risk factors) and “possible” (when vascular risk factors are present) association [1]. We suggest some adaptations of the latter case definition as emerging data have shown distinct stroke patterns in COVID-19 infection [3–5, 8]. These features (clinical, laboratory, and pathological characteristics, shown in the Table 1) can provide supporting evidence in favor of a link in doubtful cases.

We propose a revised definition of CAS, with three degrees of certainty (possible, probable, and confirmed, as illustrated in the Table 1). Even if the World Health Organization (WHO) has provided definition for suspected, probable, and confirmed COVID-19 cases, we believe that only patients with laboratory-confirmed SARS-CoV-2 should enter in the classification, in addition to clinic-radiological evidence of acute stroke (ischemic

✉ Alberto Vogrig
alberto.vogrig@gmail.com

- ¹ Clinical Neurology Unit, Azienda Sanitaria Universitaria Friuli Centrale, Presidio Ospedaliero Santa Maria della Misericordia, Piazzale Santa Maria della Misericordia, 15, Udine 33010, Italy
- ² Unit of Neuroradiology, Department of Diagnostic Imaging, Azienda Sanitaria Universitaria Friuli Centrale, Presidio Ospedaliero Santa Maria della Misericordia, Udine, Italy
- ³ Department of Medicine (DAME), University of Udine Medical School, Udine, Italy
- ⁴ Department of Mathematics, Informatics and Physics (DMIF), University of Udine, Udine, Italy
- ⁵ Unit of Neuroradiology, Department of Diagnostic Imaging, Istituto Ospedaliero Fondazione Poliambulanza, Brescia, Italy
- ⁶ Unit of Radiology, Department of Diagnostic Imaging, Istituto Ospedaliero Fondazione Poliambulanza, Brescia, Italy

Table 1 Proposed case definition of COVID-19-associated stroke (CAS)

Case definition
Major criteria
1. Clinical and neuroradiological evidence of acute stroke (ischemic or hemorrhagic)
2. SARS-CoV-2 detection by PCR testing OR detection of SARS-CoV-2-specific antibody in serum indicating acute infection
Minor criteria
1. Timing of onset (from few days to 3 weeks after COVID-19 symptoms)
2. Lack of cardiovascular risk factors
3. D-dimer and/or LDH elevation
Possible CAS: 2 major criteria and 1 minor criterion
Probable CAS: 2 major criteria and ≥ 2 minor criteria
Confirmed CAS: criteria for probable CAS and consistent pathologic findings*
Note: the absence of the typical clinical patterns of CAS** should question the diagnosis
Clinical supporting features**
1. Large vessel occlusion
2. Vertebrobasilar location
3. Multi-territory involvement
4. Onset with seizures
5. Extra-cranial dissection
6. PRES or laminar cortical damage
Pathologic supporting features*
Evidence of endothelial disruption
<i>COVID-19</i> coronavirus disease 2019, <i>CSF</i> cerebrospinal fluid, <i>LDH</i> lactate dehydrogenase, <i>PCR</i> polymerase chain reaction, <i>PRES</i> posterior reversible encephalopathy syndrome, <i>SARS-CoV-2</i> severe acute respiratory syndrome coronavirus 2

or hemorrhagic). These two represent the major criteria of this revised definition. Minor criteria were designed to capture additional evidence of a causal and biologically plausible association: (1) onset of stroke few days to 3 weeks after COVID-19 symptoms [3–5], (2) lack of cardiovascular risk factors [1, 8], (3) D-dimer and/or lactate dehydrogenase elevation [3–5]. The presence of at least one of these features is required for “possible CAS”, and two for “probable CAS”, while confirmed CAS requires pathological evidence of disappearance of endothelial cells in the affected arterioles, capillaries and venules. These findings reflect the pathogenesis of CAS, which involves a thrombotic microangiopathy caused by endotheliopathy [4, 9]. Some additional features, such as the detection of SARS-CoV-2 in the cerebrospinal fluid (CSF), can possibly provide additional evidence of a causal association, although cases with negative CSF have been described [10]. Therefore, we do not believe that this represents a necessary feature.

It is important to notice that the absence of the typical clinical patterns of CAS should question the diagnosis. Typical clinical features of COVID-19-related stroke include large vessel occlusion, multi-territory involvement, and posterior circulation predisposition (Fig. 1a–g) [3–5, 8]. In addition, less frequent presentations were also observed: onset with seizures and/or encephalopathy [3, 4], extra-cranial dissection [4, 11, 12], including bilateral carotid artery

dissection [12] (Fig. 1h–j), and posterior reversible encephalopathy (PRES) [4] or laminar cortical damage [13].

Interestingly, if we retrospectively apply the CAS criteria to the 12 patients with community-acquired COVID-19 reported by Shtaya et al. [7], 3 of their cases do not fulfill the major criteria (neuroimaging not performed). Among the other nine patients, stroke developed few days to 3 weeks later in all cases (criteria for possible CAS fulfilled) and in two, there were no known vascular risk factors (criteria for probable CAS fulfilled). In particular, case 12 was a previously healthy 50-year-old man who developed a posterior circulation stroke 3 days after the onset of COVID-19 symptoms in the context of vertebral artery dissection [7], consistent with our proposed definition. This example suggests that the CAS criteria can be useful in identifying stroke cases more likely to be causally linked to COVID-19, irrespective of where the infection was acquired.

Development of a standardized case definition for stroke of presumed infectious etiology related to SARS-CoV-2 is important for epidemiological surveillance, clinical research, outbreak investigations, as well as for allocation of health-care resources. As the understanding of this novel disease is expanding rapidly, the proposed definition will likely need refining as more data emerge. Nevertheless, this proposal represents a first step into harmonization of research studies into the topic of CAS.

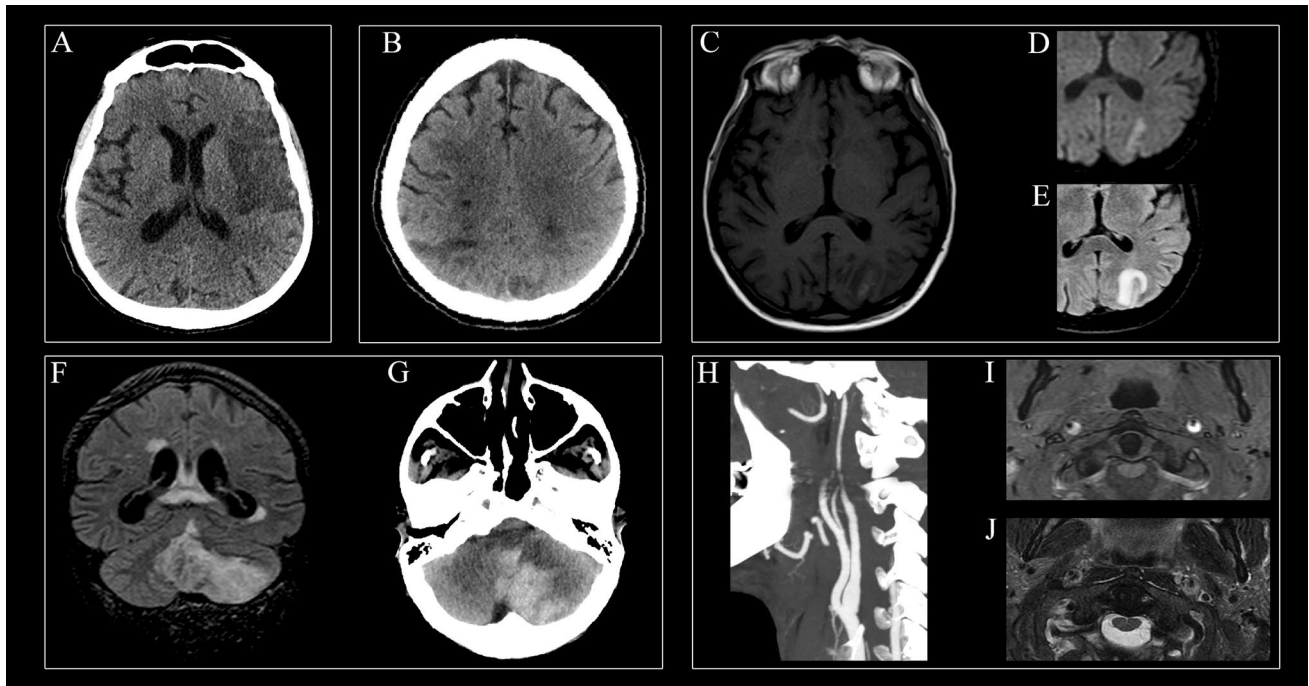


Fig.1 Neuroimaging features of COVID-19-associated stroke. **a** A 70-year-old man with critical COVID-19-related ARDS developed acute right-sided weakness. Brain CT showed a large fronto-insular ischemic lesion within the vascular territory of the left middle cerebral artery. **b** A 64-year-old man with COVID-19 infection developed multi-organ failure. Brain CT showed multiple recent ischemic lesions involving cortical-subcortical regions of both parietal lobes and centrum semiovale. **c–e** A 67-year-old man with COVID-19 and critical ARDS presented myocardial infarction 2 days after hospitalization. On day 14, he developed a tetraparesis. Brain and spine MRI were requested. As an incidental finding (given the final diagnosis of critical illness neuropathy), brain MRI showed a left parieto-occipital infarction, hyperintense on T1-weighted images (**c**) and bright on DWI (**d**) along the cortex, with subcortical white matter perilesional edema on FLAIR sequence (**e**). **f–g** A 72-year-old man diagnosed with COVID-19 presented with ataxia and vomiting. MRI showed

infarction of the postero-inferior part of the left cerebellar hemisphere and the inferior part of the vermis in the territory of PICA (**f**, coronal FLAIR). Areas of hypointensity within the vermis, corresponding to blood degradation products, were also noted. The lesion underwent extensive hemorrhagic transformation with large parenchymal hematoma (**g**, axial CT). **h–j** A 58-year-old man with moderate COVID-19 presented with intense headache and neck pain. **h** CT angiography showed a long stenosis of the distal part of internal carotid artery bilaterally. MRI axial T1-weighted images obtained with fat saturation (**i**) and T2-weighted images (**j**) showed a narrowed eccentric flow void surrounded by a crescent-shaped subacute mural hematoma. This case of bilateral carotid dissection was previously reported by our group [12]. *ARDS* acute respiratory distress syndrome, *CT* computed tomography, *DWI* diffusion-weighted imaging, *FLAIR* fluid-attenuated inversion recovery, *MRI* magnetic resonance imaging, *PICA* posterior inferior cerebellar artery

Author contributions Study concept and design: AV, DB, and MM. Drafting of the manuscript: AV. Critical revision of the manuscript for important intellectual content: AV, DB, GLG, MC, SDA, CB, and MM. Study supervision: AV, DB, and MM. All authors read and approved the final manuscript.

Funding No targeted funding reported.

Data availability The corresponding author had full access to all the data in the study and takes responsibility for the integrity of the data and the accuracy of the data analysis.

Compliance with ethical standards

Conflicts of interest None reported.

Ethical standards All procedures were performed in accordance with the institutional ethics committee and the Declaration of Helsinki.

References

1. Ellul MA, Benjamin L, Singh B et al (2020) Neurological associations of COVID-19. *Lancet Neurol.* [https://doi.org/10.1016/S1474-4422\(20\)30221-0](https://doi.org/10.1016/S1474-4422(20)30221-0)

2. Paterson RW, Brown RL, Benjamin L et al (2020) The emerging spectrum of COVID-19 neurology: clinical, radiological and laboratory findings. *Brain*. <https://doi.org/10.1093/brain/awaa240>
3. Morassi M, Bagatto D, Cobelli M et al (2020) Stroke in patients with SARS-CoV-2 infection: case series. *J Neurol*. <https://doi.org/10.1007/s00415-020-09885-2>
4. Hernández-Fernández F, Valencia HS, Barbella-Aponte RA et al (2020) Cerebrovascular disease in patients with COVID-19: neuroimaging, histological and clinical description. *Brain*. <https://doi.org/10.1093/brain/awaa239>
5. Beyrouiti R, Adams ME, Benjamin L et al (2020) Characteristics of ischaemic stroke associated with COVID-19. *J Neurol Neurosurg Psychiatry*. <https://doi.org/10.1136/jnnp-2020-323586>
6. Ellul M, Varatharaj A, Nicholson TR et al (2020) Defining causality in COVID-19 and neurological disorders. *J Neurol Neurosurg Psychiatry*. <https://doi.org/10.1136/jnnp-2020-323667>
7. Shtaya A, Trippier S, Ghatala R et al (2020) Comment on “Stroke in patients with SARS-CoV-2 infection: case series” from a London hospital experience. *J Neurol*. <https://doi.org/10.1007/s00415-020-10105-0>
8. Oxley TJ, Mocco J, Majidi S et al (2020) Large-vessel stroke as a presenting feature of Covid-19 in the young. *N Engl J Med* 382:e60. <https://doi.org/10.1056/NEJMc2009787>
9. Varga Z, Flammer AJ, Steiger P et al (2020) Endothelial cell infection and endotheliitis in COVID-19. *Lancet* 395:1417–1418. [https://doi.org/10.1016/S0140-6736\(20\)30937-5](https://doi.org/10.1016/S0140-6736(20)30937-5)
10. Al Saiegh F, Ghosh R, Leibold A et al (2020) Status of SARS-CoV-2 in cerebrospinal fluid of patients with COVID-19 and stroke. *J Neurol Neurosurg Psychiatry*. <https://doi.org/10.1136/jnnp-2020-323522>
11. Patel P, Khandelwal P, Gupta G, Singla A (2020) COVID-19 and cervical artery dissection: a causative association? *J Stroke Cerebrovasc Dis*. <https://doi.org/10.1016/j.jstrokecerebrovasdis.2020.105047>
12. Morassi M, Bigni B, Cobelli M et al (2020) Bilateral carotid artery dissection in a SARS-CoV-2 infected patient: causality or coincidence? *J Neurol*. <https://doi.org/10.1007/s00415-020-09984-0>
13. Anzalone N, Castellano A, Scotti R et al (2020) Multifocal laminar cortical brain lesions: a consistent MRI finding in neuro-COVID-19 patients. *J Neurol*. <https://doi.org/10.1007/s00415-020-09966-2>