

## КЛИНИЧКИ ИСТРАЖУВАЊА

## ВРЕДНОСТА НА МАГНЕТНАТА РЕЗОНАНЦА ВО МУЛТИМОДАЛНИОТ ТРЕТМАН НА ЛОКАЛНО НАПРЕДНАТ РЕКТАЛЕН КАРЦИНОМ

Ана Лазарова<sup>1,3</sup>, Андреј Николовски<sup>2</sup>, Виолета Василевска-Никодиновска<sup>1,3</sup><sup>1</sup> Универзитетска клиника по хируршки болести „Св. Наум Охридски“ Скопје, Оддел за радиологија,<sup>2</sup> Универзитетска клиника по хируршки болести „Св. Наум Охридски“ Скопје, Оддел за абдоминална хирургија<sup>3</sup> Медицински факултет, Универзитет „Св. Кирил и Методиј“, Скопје, Македонија

## Извадок

**Цитирање:** Лазарова А, Николовски А, Василевска-Никодиновска В. Вредноста на магнетната резонанца во мултимодалниот третман на локално напреднат ректален карцином. *Арх Ј Здравје* 2020;12(2):25-31 DOI: <https://doi.org/10.3889/aph.2020.5197>

**Клучни зборови:** ректален карцином, предоперативен стадиум, магнетна резонанца, неoadjuвант третман

**\*Кореспонденција:** Ана Лазарова, Универзитетска клиника по хируршки болести „Св. Наум Охридски“, Скопје, Република Северна Македонија. E-mail: [anidnamita@gmail.com](mailto:anidnamita@gmail.com)

**Примено:** 15-мај-2020; **Ревидирано:** 30-мај-2020; **Прифатено:** 5-јун-2020; **Објавено:** 15-јун-2020

**Печатарски права:** ©2020 Ана Лазарова. Оваа статија е со отворен пристап дистрибуирана под условите на нелокализирана лиценца, која овозможува неограничена употреба, дистрибуција и репродукција на било кој медиум, доколку се цитираат оригиналниот(ите) автор(и) и изворот.

**Конкурентски интереси:** Авторот изјавува дека нема конкурентски интереси.

Магнетната резонанца е основен дијагностички метод за селекција на пациенти со докажан ректален карцином кои имаат потреба од предоперативна хеморадиотерапија со цел намалување на стадиумот на болеста. Целта на овој труд беше да се направи евалуација на ефектите од хеморадиотерапијата во напреднат стадиум на ректален карцином, со споредба на МР прегледот пред и по третманот. Материјал и методи: Проспективно, беа евалуирани МР наоди на 15 пациенти со ректален карцином потврдени на колоноскопија. Кај сите пациенти беше направен предоперативен неoadjuвант третман и беше направен контролен МР преглед по 6 до 8 недели. МР прегледот беше направен на 1.5T магнет, во пулс секвенци: сагитален T2WI, аксијален T1WI, T2WI и DWI. На МР беше утврден T стадиумот, нодалниот стадиум, присуство на екстрамурална васкуларна инвазија (ЕМВИ), локализација на тумор во ректумот (низок, среден, висок ректум, ректосигмоиден спој). Компјутерска томографија беше направена кај сите пациенти за утврдување на далечни метастази. Резултати: Од 15 пациенти, 12 беа мажи (66,7%), а 3 (33,3%) беа жени, на возраст од 50 до 80 години. Локализација на ректален карцином: кај 6 пациенти во низок ректум, кај 6 пациенти во среден ректум и кај 3 пациенти на ректосигмоиден спој. На првичниот МР преглед, 7 (46,6%) пациенти беа во T3 стадиум, 8 (53,3%) во T4 стадиум. Споредбата на резултатите од МР прегледот пред и по хеморадиотерапијата покажа намалување на стадиумот во 5 (33,3%) од T4 во T3 фаза. Кај 11 пациенти (73,7%), ЕМВИ по терапијата стана негативна со статистички значајна разлика пред и по хеморадиотерапијата. Сите пациенти пред терапијата имаа различен број на метастатски лимфни јазли во мезоректум, со намалување на бројот во сите случаи по терапијата, а двајца пациенти беа без метастатски лимфни јазли. Заклучок: МР има значајна вредност во проценката на ефектите од хеморадиотерапијата. Ова е важно за оперативна планирање со цел да се избегне широка ресекција со хируршки техники кои го зачувуваат аналниот сфинктер.

## CLINICAL SCIENCE

## VALUE OF MRI IN MULTIMODAL TREATMENT OF LOCALLY ADVANCED RECTAL CARCINOMA

Ана Лазарова<sup>1,3</sup>, Андреј Николовски<sup>2</sup>, Виолета Василевска-Никодиновска<sup>1,3</sup><sup>1</sup> University Clinic for surgical diseases „St Naum Ohridski“ Skopje, Department for radiology, Skopje, Republic of North Macedonia<sup>2</sup> University Clinic for surgical diseases „St Naum Ohridski“ Skopje, Department for abdominal surgery, Skopje, Republic of North Macedonia<sup>3</sup> Faculty of medicine, Ss Cyril and Methodius University, Skopje, Republic of North Macedonia

## Abstract

**Citation:** Georgievska J, Samardziski I, Daneva A, Kocoski G. Successfully delayed delivery of second twin after early second trimester rupture of membranes of the first twin: a case report. *Arch Pub Health* 2020; 12 (2): 25-31 (English) DOI: <https://doi.org/10.3889/aph.2020.5197>

**Key words:** preterm delivery, preterm premature rupture of the membranes, twin pregnancy.

**\*Correspondence:** Jadranka Georgievska, University Clinic for gynecology and obstetrics, Skopje, Republic of North Macedonia. E-mail: [jadrangageo@yahoo.com](mailto:jadrangageo@yahoo.com)

**Received:** 28-Mar-2020; **Revised:** 16-May-2020;

**Accepted:** 20-May-2020; **Published:** 15-Jun-2020

**Copyright:** ©2020, Jadranka Georgievska. This is an open-access article distributed under the terms of the Creative Commons Attribution License, which permits unrestricted use, distribution, and reproduction in any medium, provided the original author(s) and source are credited.

**Competing Interests:** The author have declared that no competing interests

MRI is a basic tool in patient selection for preoperative neoadjuvant treatment of rectal carcinoma, with assessment of stage reduction. The aim of the paper was to evaluate chemoradiotherapy effects in advanced stage rectal carcinoma by comparison of MRI findings before and after chemoradiotherapy. Material and methods: Prospectively, MRI findings of 15 patients with rectal carcinoma confirmed at colonoscopy, were evaluated. In all patients preoperative neoadjuvant treatment was done and MRI restaging was performed after 6 to 8 weeks. MRI standard protocol was done on 1.5T machine, sagittal T2WI, axial T1WI, T2WI and DWI. On MRI was assessed tumor and nodal stage, presence of extramural vascular invasion (EMVI), tumor localization within the rectum (low, medium, high rectum, recto-sigmoid junction). Computer tomography was performed in all patients for distant metastases assessment. Results: Out of 15 patients, 12 (66.7%) were male, and 3 (33.3%) were female, with a mean age of 65 years (range 50 to 80years). Six cases had middle rectum localization, 6 cases in low rectum, and 3 patients had recto-sigmoid localization. At initial MRI, 7 cases (46.6%) had MR signs for T3 stage, and 8 cases (53.3%) had T4 stage. Comparison of MRI results before and after chemoradiotherapy showed stage decreasing in 5(33.3%), from T4 to T3 stage. In 11 patients (73.7%), EMVI after therapy became negative with a statistically significant difference before and after chemoradiotherapy. All patients before therapy had different numbers of metastatic lymph nodes in mesorectum, with number reduction in all cases after therapy and two patients were without metastatic lymph nodes. Conclusion: MRI has a significant value in pre- and post-neoadjuvant therapy assessment of resection margins involved by tumor, positive extramural vascular invasion, and metastatic lymph node around resection margins. This is important for operative planning in order to avoid extensive resection with surgery techniques that preserve the anal sphincter.

## Introduction

Rectal cancer is the third most common malignant disease worldwide after prostate cancer and lung cancer in men, and breast and lung cancer in the female population in the developed countries<sup>1</sup>.

Preoperative staging of rectal cancer with magnetic resonance imaging (MRI) is very important for the decision in further treatment of the disease, whether it would be chemoradiotherapy alone (neoadjuvant) or simple surgical treatment. This is aimed at achieving reduced recurrence rate and increasing of the 5-year survival rate<sup>2,3</sup>.

Preoperative chemoradiotherapy is very important because it can reduce the stage of advanced rectal cancer in some patients with good answer to the therapy. Also, the neoadjuvant therapy is used to minimize the risk of distant metastases, and if possible to perform less extensive surgical techniques. If the tumor is localized in low rectum, it is very important to use sphincter preservation technique instead of permanent colostomy<sup>4,5</sup>.

The multimodal approach includes a short cycle of radiotherapy, combined with chemotherapy. The key point is whether patients are candidates only for surgical treatment or chemoradiotherapy before the surgical treatment<sup>6</sup>. Besides other radiology diagnostic modalities, MRI is the best choice for rectal cancer staging, offering multiplanar projection, great resolution and good soft tissue contrast<sup>7,8</sup>. MRI is also performed after chemoradiotherapy, before definitive surgery, to enable its planning, with restaging due to the expected reduction of the stage and size of the tumor after the neoadjuvant treatment<sup>9,10</sup>.

The aim of this study was to evaluate chemoradiotherapy effects in advanced stage rectal carcinoma by comparison of MRI findings before and after chemoradiotherapy.

## Material and methods

Prospectively were evaluated pelvic MRIs in 15 patients with an advanced stage of rectal cancer proven at colonoscopy with age range from 50 to 80 years, and an average age of  $65 \pm 10.2$  years.

Inclusion criteria were: patients with proven rectal cancer by colonoscopy in whom pre-operative staging with MRI was indicated. Patients with metal implant or with claustrophobia were excluded.

In all patients a preoperative MRI staging was performed in order to determine tumor (T) and nodal (N) stage, presence of extra-mural vascular invasion (EMVI), with assessment of the level of tumor localization within the rectum (low, medium, high rectum, and recto-sigmoid junction). Computer tomography (CT) was performed in all patients to assess presence of distant metastases. The pelvic MRI was done on 1.5 T machine, with the standard protocol: sagittal T2WI, axial T1 WI, T2 WI and DWI. Initial MRI was without contrast media. After neoadjuvant treatment, pelvic MRI and restaging was done with intravenous administration of gadolinium in order to assess the effects of chemoradiotherapy.

According to the level of tumor localization, it was divided into three groups: within low rectum when its localization was up to 5 cm from the anorectal junction, in the mid-rectum from 5 to 10 cm from the anorectal junction, and 10 cm above the anorectal junction was a high rectal localization of the tumor.

T3 stage is when the tumor penetrates the rectal wall and grows into the mesorectal adipose tissue. If the tumor is less than 2 mm from the mesorectal fascia nearby or is infiltrated, then it is a potential seizure that requires preoperative neoadjuvant treatment. T4 stage is when the tumor grows in neighboring organs or they are infiltrated by the tumor (vagina, uterus in women, prostate in men as well as in muscular and pelvic organs). If the tumor infiltrates the vagina or the prostate the organ loses its normal morphology and structure locally, then, fat line between tumor and the organ cannot be visualized and the infiltrated part of the organ becomes with heterogenic signal intensity and has the same characteristics like the tumor itself witch is in continuity.<sup>12</sup>

Local nodal staging determines the number of MRI suspected positive lymph nodes. Although metastatic altered LNs are larger than benign ones, metastatic deposits (MS) may also be present in small LNs. Most often the size of LN with MS-deposits is 5 - 8 mm, with irregular contours and mixed signal intensity. When evaluating mesorectal nodules, the distance to the mesorectal fascia should be taken into account. Distance less

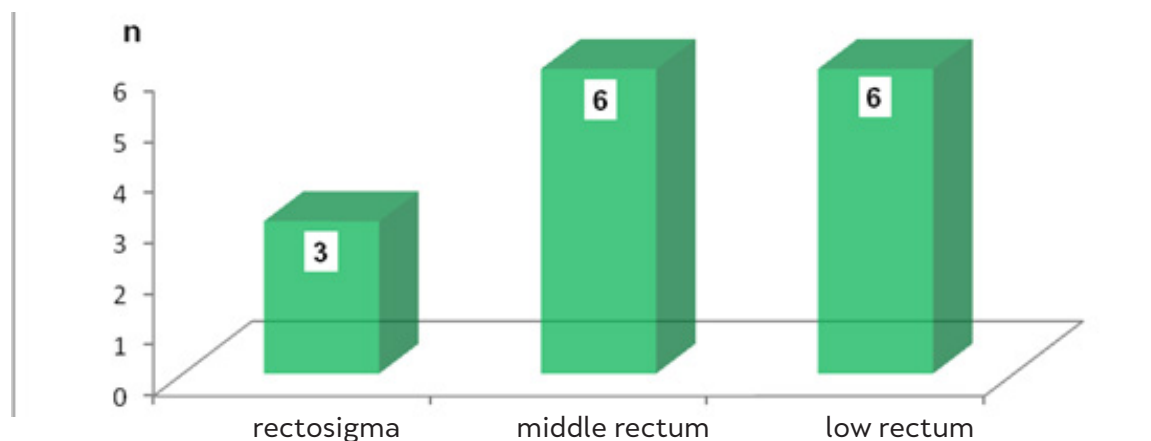
than 2 mm is a sign for local recidive.<sup>20</sup>

Extramural vascular invasion (EMVI) is accounted as positive on MRI when the small blood vessels within mesorectum and under muscularis propria, are thickened, with irregular contours, and with heterosignal intensity with large size and diameter which makes it visible for MRI detection. This is a MR sign of existence of MS deposits in intramural blood vessels. It is best visualized at axial T2WI and DWI. After neoadjuvant treatment there are changes in the presentation of EMVI. This effect was visualized by MRI signs of formation a fibrosis, which has hyposignal characteristics on T1WI and T2 WI, has flat margins and is at the places of previous with metastatic embolus changed EMVI.

The obtained data were analyzed with the statistical computer program SPSS 23.0 for Windows.

## Results

Out of 15 patients, 12 (66.7%) were male, and 3 (33.3%) were female, with a mean age of  $65 \pm 10.2$  years (age range 50 to 80 years). Rectal cancer was localized in the middle rectum in 6 cases, as well as in the low rectum,



**Figure 1.** Localization of rectal cancer

and in 3 patients the recto sigmoid part was affected by the malignant process.

Five (33.3%) had metastatic deposits at the initial MRI examination. Four of them (80%) had liver metastases, and one patient had both liver and lung metastases.

At initial MRI, 7 cases (46.6%) had MR signs for T3 stage of rectal cancer, and in 8 cases (53.3%) the stage of rectal cancer was T4.

Comparison of MRI results before and after chemo radiotherapy treatment showed that in 5 patients there

was a change in the findings in relation to T-staging. Of the 15 patients, in 5 patients (33.3%) T stage decreased from T4 to T3 stage. In the remaining 10 patients (66.67%) there were no changes in the T stage.

In 11 patients (73.7 %), the change in EMVI status was seen after MR therapy (Table 1). All 11 patients who had positive EMVI, after therapy became EMVI negative. The other 4 patients had still positive EMVI. Statistically significant was the difference in EMVI status determined by MR, before and after chemoradiotherapy ( $p = 0.0026$ ).

**Table 1.** EMVI status before /after therapy

EMVI status /changes	n (%)
no	4 (26.67)
yes	11 (73.33)

**Table 2.** Number of LNs before and after therapy

Number of lymph nodes per patient	Before therapy n (%)	After therapy n (%)	p = level
0		2 (13.33)	$p=0.00065$ sig
1		7 (46.67)	
2	1 (6.67)	5 (33.33)	
3	5 (33.33)	1 (6.67)	
4	5 (33.33)		
5	3 (20)		
7	1 (6.67)		

Wilcoxon Matched Pairs Test = 3.4  $p=0.000655$



All patients before therapy had metastatic lymph nodes in the mesorectum, and after therapy the number was reduced in all patients, and two patients (13.3%) had no metastatic lymph nodes (Table 2).

The patient, who had 2 MS changed LNs on MR before therapy, after therapy was negative.

Of five patients, who had 3 MS changed LNs before therapy, one had no MS LNs and 4 had only one MS LN after therapy. Of five patients, who had 4 MS LNs before therapy, 3 patients had only one MS LN, and 2 patients had only 2 MS LNs after therapy. Of three patients, who had 5 MS LNs before therapy, 3 patients had 2 MS LNs after therapy. One patient who had 7 MS LNs before therapy, had only 3 metastatic changed LNs after therapy.

## Discussion

The preoperative chemoradiotherapy or neoadjuvant treatment increases the 5-year survival rate while achieving negative circulatory resection margins. It can also provide sphincter-saving techniques in patients with low rectal tumors by reducing the stage of the locally advanced tumor process.

Post-chemoradiotherapy MRI restaging is performed in order to determine the condition after the neoadjuvant treatment, which would also affect the choice of surgical technique<sup>18</sup>.

Rectal cancer restaging is a comparison of all MR parameters before and after neoadjuvant treatment by using the same MRI protocol<sup>19</sup>.

Initial MRI was without contrast media administration due to partial volume effect given by the contrast medium that can interpret the more

advanced stages of rectal cancer at the primary MRI staging before neoadjuvant treatment. After neoadjuvant treatment, pelvic MRI and restaging was done with intravenous administration of gadolinium, in order to assess the effects of chemoradiotherapy: desmoplastic reaction which has to be differentiated from viable tumor, and changes in the extramural vascular invasion (EMVI). Also, administration of contrast medium provides better insight into the metastatic changes of lymph nodes.

When it comes to changes of T4 to T3 stages at MRI contrast administration gives adequate view of the fibrotic changes where viable tumor was first present, showing chemoradiotherapy effects, with decreasing of the tumor size which leads to down-stage of the rectal carcinoma<sup>12</sup>.

The anatomical localization of the rectum, its fixation on the pelvic floor and fat tissue, as well as the absence of peristalsis, which avoids moving artifacts, makes it an ideal organ for recording with the MRI imaging method.

Candidates for preoperative neoadjuvant treatment are patients in advanced stage (T3b and T4 stage) disease, patients with involved resection margins, patients in stage T3 and T4 with positive LNs, and positive extramural vascular induction, also tumors localized in a low rectum where a reduction of extensibility of the process is required in order to approach sphincter preservation techniques<sup>5</sup>.

In our study, a comparison of MRI results before and after chemoradiotherapy treatment showed that in 33.3% of the cases there were MRI signs of change from T4 to T3 stage. Change of EMVI status after therapy was found in 73.3% of the cases. Prior

to neoadjuvant treatment, the MRI finding in all patients presented with positive lymphatic status. After the therapy, the MRI finding showed a significant regression of metastatic lymph nodes.

All patients before therapy had metastatic lymph nodes in the mesorectum, and after therapy the number was reduced in all patients and two patients (13.3%) had no metastatic lymph nodes (Table 2).

EMVI is an independent prognostic indicator in the treatment of rectal cancer, but has recently been taken as an important indicator in making the decision to start neoadjuvant treatment<sup>13,16</sup>.

Positive EMVI affects the increase in the number of postoperative relapses and is therefore taken into account when deciding to start preoperative neoadjuvant treatment<sup>17</sup>.

In this study, 73.7% of the cases showed statistically significant changes in EMVI status after MR therapy from positive to negative EMVI.

Although this group of 15 patients is small for more significant statistical analysis, it is a sufficient indicator of the direction in the treatment of rectal cancer. It confirms the importance of multimodal treatment of rectal cancer, especially in reducing tumor size, allowing for negative resection margins, reducing nodal status, and altering the positive extramural vascular invasion.

Opportunities are opened for its greater application in the future, bringing it closer to world standards in that field in order to improve the overall treatment of rectal cancer, which would increase the 5-year survival rate, reduce recurrence rate or overall benefit of the patient in the struggle and victory of the disease.

## Conclusion

Magnetic resonance imaging has a significant value in evaluating of all T4 stages of rectal cancers and T3 stages in which resection margins are involved by the tumor, tumors in which there is a finding of a positive extramural vascular invasion, and malignant lymph node around the resection margin. This is very important in making decision for preoperative chemoradiotherapy, as well as in the assessment of the post-neoadjuvant treatment. In the case of tumor growth near the mesorectal fascia, this would mean less extensive resection and application of surgical techniques to preserve the anal sphincter. This is especially important for surgeons to prevent the development of permanent colostomy, which will significantly improve the patient quality of life.

## References

1. Thorat MA, Cuzick J. Role of aspirin in cancer prevention. *Curr Oncol Rep* 2013;15(6) 533-540
2. Del Vescovo R, Trodella LE, Sansoni I, et al. MR imaging of rectal cancer before and after chemoradiation therapy. *Radiol Med (Torino)* 2012; 117:1125-1138
3. Jung SH, Heo SH, Kim JW, et al. Predicting response to neoadjuvant chemoradiation therapy in locally advanced rectal cancer: diffusion-weighted 3 Tesla MR imaging. *J Magn Reson Imaging* 2012; 35:110-116
4. DeVries AF, Piringer G, Kremser C, et al. Pre-treatment evaluation of microcirculation by dynamic contrast-enhanced magnetic resonance imaging predicts survival in primary rectal cancer patients. *Int J Radiat Oncol Biol Phys* 2014; 90:1161-1167
5. Gollub MJ, Gultekin DH, Akin

- O, et al. Dynamic contrast enhanced-MRI for the detection of pathological complete response to neoadjuvant chemotherapy for locally advanced rectal cancer. *Eur Radiol* 2012;22:821
6. Kapiteijn E, Marijnen CAM, Nagtegaal ID, et al. Preoperative radiotherapy combined with total mesorectal excision for resectable rectal cancer. *N Engl J Med* 2001; 345(9):638-646
  7. Harrison JC, Dean PJ, el-Zeky F, Vander Zwaag R. From Dukes through Jass: pathological prognostic indicators in rectal cancer. *Hum Pathol* 1994; 25:498-505
  8. Mannaerts GHH, Martijn H, Crommelin MA, et al. Intraoperative electron beam radiation therapy for locally recurrent rectal carcinoma. *Int J Radiat Oncol Biol Phys* 1999;45(2):297-308.
  9. Beets-Tan RG, Lambregts DM, Maas M, et al. Magnetic resonance imaging for the clinical management of rectal cancer patients: recommendations from the 2012 European Society of Gastrointestinal and Abdominal Radiology (ESGAR) consensus meeting. *Eur Radiol* 2013; 23:2522-2531
  10. Slater A, Halligan S, Taylor SA, Marshall M. Distance between the rectal wall and mesorectal fascia measured by MRI: effect of rectal distension and implications for preoperative prediction of a tumour-free circumferential resection margin. *Clin Radiol* 2006; 61:65-70
  11. Furey E, Jhaveri KS. Magnetic resonance imaging in rectal cancer. *Magn Reson Imaging Clin N Am* 2014; 22:165-190, v-vi
  12. Suzuki C, Torkzad MR, Tanaka S, et al. The importance of rectal cancer MRI protocols on interpretation accuracy. *World J Surg Oncol* 2008; 6:89
  13. Hahnloser D, Nelson H, Gundersen LL, et al. Curative potential of multimodality therapy for locally recurrent rectal cancer. *Annals of Surgery* 2003;237(4):502-508.
  14. Maas M, Lambregts DM, Lahaye MJ, et al. T-staging of rectal cancer: accuracy of 3.0 Tesla MRI compared with 1.5 Tesla. *Abdom Imaging* 2012; 37:475-481
  15. Donmez FY, Tunaci M, Yekeler E, Balik E, Tunaci A, Acunas G. Effect of using endorectal coil in pre-operative staging of rectal carcinomas by pelvic MR imaging. *Eur J Radiol* 2008; 67:139-145
  16. Slater A, Halligan S, Taylor SA, Marshall M. Distance between the rectal wall and mesorectal fascia measured by MRI: effect of rectal distension and implications for preoperative prediction of a tumour-free circumferential resection margin. *Clin Radiol* 2006; 61:65-70
  17. Furey E, Jhaveri KS. Magnetic resonance imaging in rectal cancer. *Magn Reson Imaging Clin N Am* 2014; 22:165-190, v-vi
  18. Roh MS, Colangelo LH, O'Connell MJ, et al. Preoperative multimodality therapy improves disease-free survival in patients with carcinoma of the rectum: NSABP R-03. *J Clin Oncol* 2009; 27:5124-5130
  19. Park JH, Kim JH, Ahn SD, et al. Prospective phase II study of preoperative chemoradiation with capecitabine in locally advanced rectal cancer. *Cancer Res Treat* 2004; 36:354-359
  20. Engelen SM, Beets-Tan RG, Lahaye MJ, Kessels AG, Beets GL. Location of involved mesorectal and extramesorectal lymph nodes in patients with primary rectal cancer: preoperative assessment with MR imaging. *Eur J Surg Oncol* 2008 ;34:776-781