

## Case report

data, citation and similar papers at [core.ac.uk](http://core.ac.uk)

brought to you by

provided by Bern Open Repository and Information Service

# with situs inversus, single atrium and ventricle after total cavo-pulmonary connection

Pascal A. Berdat<sup>a</sup>, Paul Mohacsi<sup>b</sup>, Ulrich Althaus<sup>a</sup>, Thierry Carrel<sup>a,\*</sup>

<sup>a</sup>*Clinic for Thoracic and Cardiovascular Surgery, University Hospital, CH-3010 Berne, Switzerland*

<sup>b</sup>*Division of Cardiology, University Hospital, Berne, Switzerland*

Received 17 August 1998; accepted 30 September 1998

### Abstract

Heart transplantation represents a valuable therapeutical option for patients with congenital heart disease and end-stage heart failure. We report the case of a young adult patient with a situs inversus and additional complex congenital malformations of the heart who underwent several prior palliative interventions, a biventricular repair being impossible. Orthotopic cardiac transplantation with several technical modifications was performed successfully at the age of 19 years. © 1998 Elsevier Science B.V. All rights reserved

**Keywords:** Situs inversus; Orthotopic cardiac transplantation; Congenital heart disease

### 1. Introduction

End-stage heart failure patients suffering from congenital heart disease accounts for less than 5% of the overall number of cardiac transplant candidates. There may be a slightly increasing incidence in future years due to an expected rising of patients with failure of Fontan circulation and of patients with late systemic ventricular failure following atrial repair because of transposition of the great arteries.

Ivemark syndrome is a multiple organ syndrome associated with splenic abnormalities, complex cardiac pathology and abnormality of the abdominal organs. The incidence of Ivemark syndrome is thought to be approximately 1/6000 deliveries and the cause is unknown. The prognosis depends mainly on the degree of malformation of the heart [1].

We present a patient with complex cardiac malformation and situs inversus associated to Ivemark syndrome. He

underwent successful orthotopic heart transplantation after several previous palliative interventions, despite an accidentally transplanted ABO-incompatible cardiac allograft.

### 2. Case report

A 19-year-old patient presented with Ivemark syndrome and end-stage heart failure. The cardiac malformation included a situs inversus totalis with single atrium, single ventricle, transposition of the great arteries, persistent right superior vena cava and a fistula between the right coronary artery and the pulmonary artery. Main symptoms were dyspnea NYHA functional class III and pre-synopes. Treatment of heart failure included digoxin, diuretics, a CE-inhibitor and a  $\beta$ -blocker at low dosage.

#### 2.1. Previous surgical history

At the age of 11 years (in 1989), the patient presented with increasing cyanosis and a modified Blalock–Taussig shunt was constructed between the right subclavian artery

\* Corresponding author. Tel.: +41-31-632-9268; fax: +41-31-382-0279; e-mail: [thierry.carrel@insel.ch](mailto:thierry.carrel@insel.ch)

and the right pulmonary artery, using a Gore-Tex shunt of 5 mm in diameter. The child recovered well until 3 years later, when cyanosis returned because of shunt occlusion. At that time, cardiac catheterism showed still normal pulmonary pressure and resistance, a normal function of the single ventricle with absent regurgitation of the atrio-ventricular valve. Therefore, a Fontan-like palliation was considered. A two-stage total cavo-pulmonary connection was performed in 1992 included a bilateral, bidirectional cavo-pulmonary anastomosis and a connection between the inferior vena cava and the main pulmonary artery using a 18 mm Gore-Tex fenestrated (4 mm) tube graft lying within the single atrium (Fig. 1).

## 2.2. Present history

After uneventful recovery, medication could be stopped until increasing dyspnoea and rapidly progressive heart failure occurred in 1997. Echocardiography showed severe systemic atrio-ventricular valve regurgitation and severely impaired left ventricular function (ejection fraction 30%). Since any additional drug treatment nor surgical approach could have improved intractable heart failure, the patient was considered a cardiac transplant candidate and underwent transplantation in May 1997.

## 2.3. Surgical technique

The ascending aorta, both superior venae cavae and the right iliac vein were cannulated and cardiopulmonary bypass conducted in mild hypothermia (28°C). Extended cardiectomy was performed, removing the prior bilateral superior cavo-pulmonary anastomosis. The single atrium was opened and the intraatrial Gore-Tex graft was completely excised.

Donor cardiectomy was modified in order to include complete inflow and outflow tissue in the explant. Transplantation started with a running suture connecting the single, systemic atrium of the recipient with the left atrium of the donor heart; this suture was performed in a way to exteriorize the left-sided inferior vena cava out of the single atrium. Due to exceeding tissue, the inferior vena cava could be anastomosed end-to-end without tension. Two separate pulmonary artery anastomoses were performed rather peripherally with running suture of 5.0 polypropylene. Then, both superior venae cavae were anastomosed, the innominate vein of the donor heart assuming restoration of the continuity to the left recipient superior vena cava. Since the innominate donor vein was lying between the aorta and the main pulmonary artery, a short ring-reinforced Gore-Tex graft was interposed to avoid compression. Finally end-to-end aortic anastomosis was performed and warm blood reperfusion cardioplegia was instilled before aortic declamping (total cold ischemic time was 85 minutes). Fig. 2 summarizes the most important steps of cardiac grafting. Sinus rhythm appeared rapidly during

reperfusion and weaning from extracorporeal circulation was realized under minimal inotropic support (epinephrine 5 mg/kg per min).

## 2.4. ABO-Mismatch

Before starting reperfusion, we received information from the transplant coordinator that ABO-mismatch had happened accidentally, the transplant candidate (O-group) receiving a B-group graft. The following precautions were taken: in vivo absorption of the preformed anti-B antibodies by transfusion of a B-blood group red cells concentrate followed by intraoperative exchange plasmapheresis. Early postoperatively specific immunoabsorption was performed combined to intravenous infusions of IgG and IgM immunoglobulins and C1-inhibitor infusions. Anti-B titers were assessed isotype-specifically by ELISA throughout the treatment.

## 2.5. Present status

One and a half years after transplantation, the systolic and diastolic ventricular function are excellent, coronary angiography and endovascular ultrasound shows absence of graft atherosclerosis and the coronary flow reserve is fully normal. The anti-B antibody titer remains constant at 130–150% of the pre-transplant value. The patient continues to receive a triple immunosuppressive therapy and enjoys a normal life quality.

## 3. Discussion

Increased use of the Fontan's principle has permitted the correction of anomalies previously thought to be inoperable, like various forms of univentricular hearts, tricuspid atresia and double inlet left ventricle. Recent series suggest that a modified Fontan operation (so called total cavo-pulmonary connection) can be performed with a low mortality and that the early results are encouraging in the majority of patients [2,3]. Careful attention to operation indication and complete preoperative assessment have contributed to better early and long-term results. Nevertheless, late failure of the Fontan circulation is still difficult to predict and will happen in a substantial number of patients.

Adolescents and adult patients undergoing cardiac transplantation for congenital heart disease remain exceptional cases. In several series published, this subset of patients represent a very small group of candidates for transplantation [4–8]. Obviously, the perioperative risk may be increased by several factors in this patient's group, such as laborious dissection, increased bleeding, correction of congenital anomalies or re-establishment of a normal anatomy to fit with the cardiac allograft, as well as modifications of the transplantation technique that may extend the operative time and the graft ischemic period.

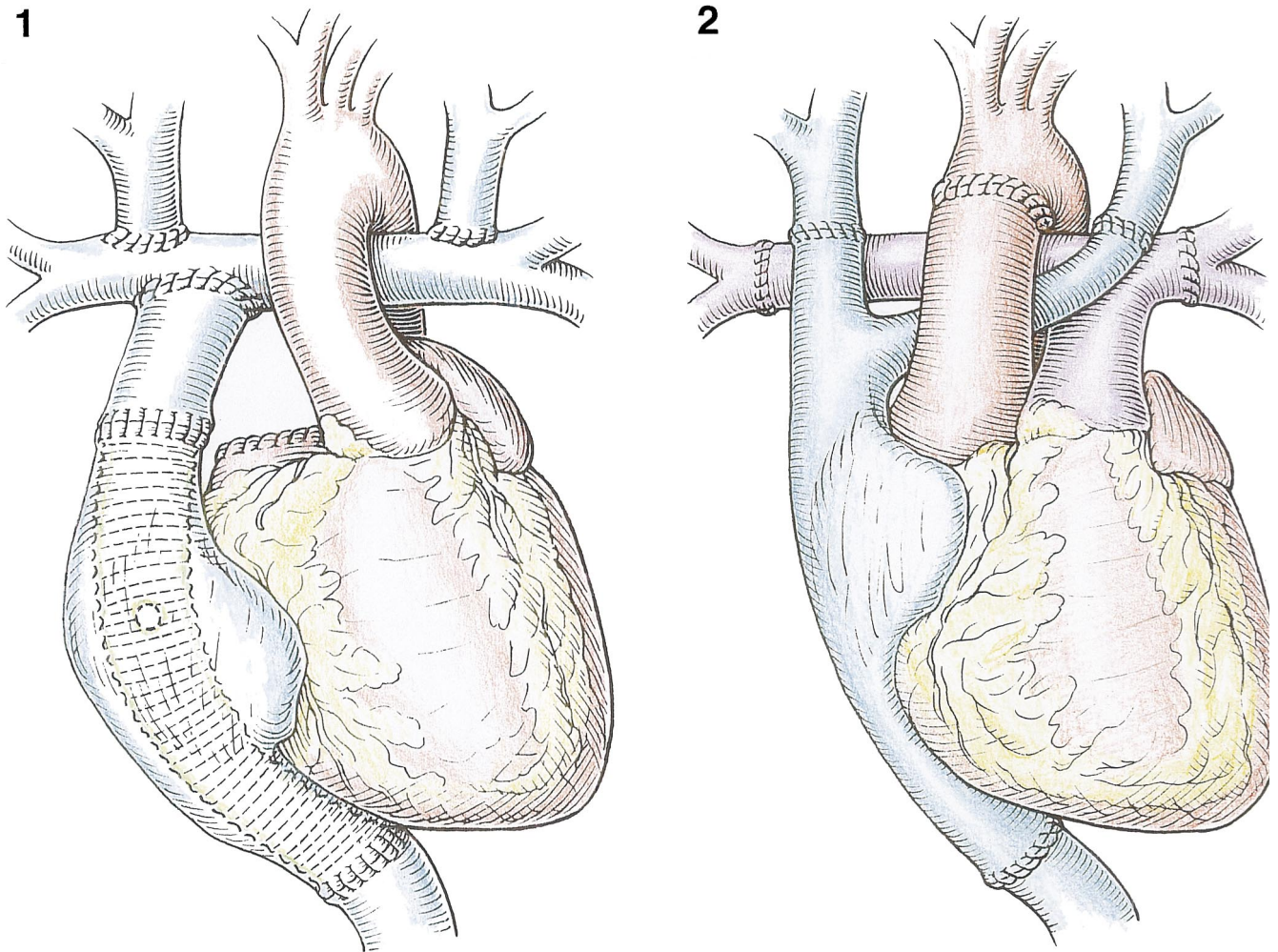


Fig. 1. The artist's drawing demonstrates the pre-transplant operative situs with the total cavo-pulmonary connection including a bilateral, bidirectional Glenn shunt and the intra-atrial Gore-Tex tube graft to connect the inferior vena cava to the pulmonary circulation. The proximal segment of the main pulmonary artery has been sutured just above the pulmonary valve.

Fig. 2. Schematic representation of the modified orthotopic heart transplantation technique. Exceeding donor tissue allowed a tension-free anastomosis to the recipient inferior vena cava which was lying on the left side. The superior left vena cava was reconstructed using the innominate vein of the donor and the persistent superior right vena cava was anastomosed with the donor superior vena cava. Note the separate rather distal reconstruction of the pulmonary arteries.

This case demonstrates that cardiac transplantation can be performed with excellent anatomical and functional results and with a low surgical risk, even in presence of most complex anomalies of venous and pulmonary inflow and outflow and multiple previous surgical palliations. The operative technique must be adapted to the malformation and includes usually bicaval anastomosis as well as extensive reconstruction of the pulmonary arteries [9].

The present observation shows also that accidental ABO-mismatch can be rescued by comprehensive application of modern immunological methods, including selective binding of the anti-donor antibodies, extracorporeal immunoabsorption and selective blockade of the complement system. In this case, ABO-mismatch did fortunately not compromise early and mid-term result of the complex surgical procedure.

## References

- [1] Roth P, Agnani G, Arbez F, Roux C, Martin A, Colette C. Ivemark-syndrome: 2 case reports and a review of the literature. *J Gynecol Obstet Biol* 1993;22:771–775.
- [2] Malm T, Pawada A, Karl T, Mee RB. Recent results with the modified Fontan operation. *Scand J Thorac Cardiovasc Surg* 1993;27:65–70.
- [3] Driscoll DJ, Offord KP, Feldt RH, Schaff HV, Puga FJ, Danielson GK. Five- to fifteen-year follow-up after Fontan operation. *Circulation* 1992;85:469–496.
- [4] Carrel T, Neth J, Pasic M. et al. Should cardiac transplantation for congenital heart disease be delayed until adult age. *Eur J Cardio-thorac Surg* 1994;8:462–469.
- [5] Chartrand C, Guerin R, Kanagh R, Stanley P. Pediatric heart transplantation: surgical considerations for congenital heart disease. *J Heart Transplant* 1990;9:608–617.
- [6] Cooper MM, Fuzesi L, Addonizio LJ, Hsu DT, Smith CR, Rose EA. Pediatric heart transplantation after operations involving the pulmonary arteries. *J Thorac Cardiovasc Surg* 1991;102:386–395.

- [7] Menkis AH, McKenzie FN, Novick RJ. et al. Expanding applicability of transplantation after multiple prior palliative procedures. *Ann Thorac Surg* 1991;52:722–726.
- [8] Hsu DT, Quaegebeur JM, Michler RE. et al. Heart transplantation in children with congenital heart disease. *J Am Coll Cardiol* 1995;26:743–749.
- [9] Bailey LL. Heart transplantation techniques in complex congenital heart disease. *J Heart Lung Transplant* 1993;12:168–175.