

Assessment of cardiac rejection by MR-imaging and MR-spectroscopy¹

data, citation and similar papers at core.ac.uk

brought to you by

provided by Bern Open Repository and Information Service

Beat H. Walpoth*, Markus F. Müller, Bülent Celik, Beatrice Nicolaus,
Nazan Walpoth, Thomas Schaffner, Ulrich Althaus, Thierry Carrel

*Thoracic and Cardiovascular Surgery, Cardiology, Radiology and Pathology,
University Hospital, Insel, CH-3010 Berne, Switzerland*

Received 27 October 1997; revised version received 27 May 1998; accepted 8 July 1998

Abstract

Background: Detection of cardiac rejection is a major problem in cardiac transplantation. The gold standard is, and remains, endomyocardial biopsy. **Purpose:** Evaluation of MR-imaging and MR-spectroscopy for detection of cardiac rejection. **Methods:** Orthotopic cardiac transplantation (HTX) was performed in 13 pigs (body weight 30 kg). All animals obtained immunosuppressive (triple) therapy for 1 week after the operation. Thereafter immunosuppression was stopped to induce cardiac rejection. MRI and MRS (1.5 Tesla General Electrics Signa) were performed pre- and post-operatively on days 10, 17, 24 and 31. The degree of rejection was determined post-operatively using endomyocardial biopsy (Texas grading score). **Results:** (1) MR-imaging: LV function remained unchanged after HTX. LV mass increased (+42%; $P < 0.05$) with cardiac rejection. (2) MR-spectroscopy: a marked reduction in the ratio of phosphocreatine and adenosine triphosphate, respectively, to inorganic phosphate was observed in the rejecting hearts. (3) Histologic grading confirmed cardiac rejection after stopping immunosuppression. The Texas score was 5.7 ± 0.8 at autopsy. **Conclusions:** MR-imaging and MR-spectroscopy allow the detection of changes associated with cardiac rejection. Both techniques are correlated with histologic rejection. However, endomyocardial biopsy remains the gold standard for reliable detection of cardiac rejection. © 1998 Elsevier Science B.V. All rights reserved

Keywords: Cardiac rejection; MR-imaging; MR-spectroscopy; Histologic grading

1. Introduction

Rejection episodes constitute the major problems after heart transplantation; moreover differentiation between rejection and infection may be difficult [1,2]. So far, only endomyocardial biopsy with histological evaluation has been established for accurate diagnosis of rejection [3]. Several non-invasive methods have been investigated and some of them are currently used in clinical trials [1,4–10]. However, until now, no method has been accepted to replace endomyocardial biopsy.

Like other groups, we have been able to demonstrate some significant correlations between phosphorous MR-spectroscopy (MRS) and the severity of histologic rejection [11–19]. The main finding consists of a reduction of PCr/Pi and/or β ATP/Pi by MRS with a concomitant increase in wall thickness, ventricular muscle mass and increased T2 relaxation time by MR-imaging (MRI) [20,21]. However, to our knowledge, no other groups have used the combination of MR-imaging and MR-spectroscopy to diagnose acute rejection. The aim of the present investigation was the consecutive assessment of both MR-imaging and MR-spectroscopy changes before and after orthotopic cardiac transplantation with and without immunosuppression.

* Corresponding author. Tel.: +41 31 6322375; fax: +41 31 6329766;
e-mail: beat.walpoth@insel.ch

¹ Presented at the 11th Annual Meeting of the European Association for Cardio-thoracic Surgery, Copenhagen, Denmark, September 28 – October 1, 1997.

2. Methods

Orthotopic cardiac transplantation was performed in

anesthetized (balanced narcosis) pigs (30 kg). Donors and recipients were not from the same litter but were blood typed and size matched. In addition a blood donor from the same litter as the recipient was necessary to prevent post-operative anaemia. The mean cold ischemic time was 26 min and the aortic crossclamp time 68 min. Cardiopulmonary bypass was conducted at high flow rate (>100 ml/kg per min) in mild hypothermia after aortic and bicaval cannulation. Animals were kept intubated during the first night after transplantation and treated under ICU conditions for 3 days to improve monitoring. Echocardiography assessment was repeated several times during the early post-operative period. Animals received immunosuppression starting at the day of transplantation, and including a triple therapy (cyclosporine with serum trough levels around 200–250 ng/ml, azathioprin and prednisolon). One week post-operatively, immunosuppression was tapered in order to provoke cardiac rejection. All animals were kept according to the European Convention on Animal Care. Thirteen animals were operated on, of which six survived more than 10 days and one up to 31 days.

2.1. MR examinations

MR-imaging and MR-spectroscopy examinations were repeatedly performed under general anesthesia before and after heart transplantation on days 10, 17, 24, and 31 using a 1.5 Tesla whole body scanner (Signa, General Electrics, USA) with a dual tuned flexible surface coil (Medical Advances, USA). Pre-operatively the donor heart was examined.

2.2. MR-imaging

A gradient echo sequence (16 phases) was used in a long (four chamber view) and short axis view to assess LV dimensions and cardiac function at end-diastole and end-systole. ECG-triggering was carried out to reduce motion artefacts. From these measurements, left ventricular septal and posterior wall thickness, left ventricular short and long axes, left ventricular volume (area length method) and left ventricular muscle mass were calculated. Mass was determined from the outer LV volume minus the intracavitary volume calculated by the area length method. Additionally, T2 relaxation time was calculated in the septal region at signal intensities of echo time 30 and echo time 90 ms, respectively.

2.3. MR-spectroscopy

³¹P phosphorous spectra were obtained with a 2D-CSI pulse sequence, 16 × 16 voxels, abadiatic pulse, relaxation time 2 s. Signals were obtained from the apical part of the left ventricle including some blood within the left ventricle. Acquisition time was 17 min. The following parameters

were calculated using conjugated gradient fitting routines: 2,3-diphospho-glycerol (2,3 DPG), inorganic phosphate (Pi), phosphocreatine (PCr) and adenosine triphosphate (γ , α , β ATP) (Fig. 1). Since no absolute values were obtained, PCr/Pi, β -ATP/Pi and PCr/ β -ATP ratios were determined before and after heart transplantation.

2.4. Histologic assessment of rejection

Myocardial biopsy specimens were obtained pre-operatively from endomyocardial biopsies of the right ventricle, post-operatively during MR examinations and, at the conclusion of the study, from autopsy samples of the right and left ventricle. The grade of rejection was classified according to the Texas grading system (semi-quantitative score from 0–10).

2.5. Statistics

Data are expressed as the mean \pm SD. Correlations were calculated using a regression analysis. *P*-Values smaller than 0.05 were considered to be significant. Pre- and post-operative data were compared either with a non-parametric Mann–Whitney Rank-Sum test or the paired *t*-test using Stata 5.0, Stata Santa Monica, CA.

3. Results

Six animals survived beyond day 10, three survived up to post-operative day 17 and one to 31 days after transplantation. Endomyocardial biopsies showed mild rejection during the first week post-operatively, while animals were still immunosuppressed (Texas grade 0–2, mean: 0.5 ± 0.9). Subsequent histologic evaluation revealed moderate to severe rejection with a significant increase in the Texas grade to 4–6, mean: 5.7 ± 0.8 at autopsy (*P* < 0.05).

3.1. Baseline hemodynamics (Table 1)

Heart rate increased significantly after heart transplantation, whereas mean arterial and pulmonary pressures did not change significantly.

3.2. MR-imaging (Table 1)

Septal and posterior wall thickness, as well as muscle mass, showed a significant increase after transplantation when compared to pre-operative values (baseline: 8.6 ± 0.5 and 7.2 ± 1.8 mm, and at conclusion of the study: 12.6 ± 1.9 and 10.9 ± 2.0 mm, respectively; *P* < 0.05). Left ventricular mass increased from 43 ± 16 g at baseline to 74 ± 13 g at the end of the study (*P* < 0.05). T2-relaxation time of the lateral and septal wall increased from 47 ± 6 at baseline to 50 ± 6 at the end of the study.

Table 1

Baseline hemodynamics and MRI data

	Pre-operative	Post-operative (>10 days)	P-value
<i>Baseline hemodynamics (n = 6)</i>			
Heart rate (beats/min.)	107 ± 16	142 ± 6	<0.05
Mean arterial pressure (mmHg)	102 ± 23	89 ± 7	n.s.
Mean pulmonary artery pressure (mmHg)	17 ± 5	20 ± 6	n.s.
<i>MRI data (n = 6)</i>			
Septal thickness (mm)	8.6 ± 0.5	12.6 ± 1.9	<0.05
Posterior wall thickness (mm)	7.2 ± 1.8	10.9 ± 2.0	<0.05
LV muscle mass (g)	43 ± 16	74 ± 13	<0.05
T2-relaxation time (ms)	47 ± 6	50 ± 6	n.s.

3.3. MR-spectroscopy (Table 2 and Fig. 1)

The PCr/Pi ratio decreased from 9.8 ± 3.4 to 4.0 ± 0.9 at the conclusion of the study. Similarly the β ATP/Pi ratio decreased from 4.4 ± 1.7 at baseline to 1.6 ± 0.8 during rejection ($P < 0.05$); on the other hand PCr/ β ATP remained essentially unchanged.

3.4. Correlations between MRI and MRS data, respectively, and histologic rejection (Table 3)

Muscle mass, septal wall thickness, stroke volume, inorganic phosphate, T2-relaxation time and ejection fraction show a significant correlation with the histologic grade of rejection ($P < 0.05$).

4. Discussion

Non-invasive detection of cardiac rejection is still a subject of intensive research. Various methods have been used experimentally and clinically for detection of acute rejection after cardiac transplantation. So far no reliable parameter has been found, although several methods such as electrocardiography, echocardiography, blood serum tests, and nuclear scintigraphy have been used [1,4–10]. Likewise, the role of magnetic resonance imaging and spectro-

scopy remains unclear, although these techniques have been evaluated both experimentally and clinically for diagnosis of cardiac rejection [11–21].

4.1. MR-imaging for detection of rejection

The MRI criteria for assessing myocardial rejection are similar to those used for echocardiography. Changes like an increase in wall thickness or muscle mass have been reported but were not found to be sensitive enough to detect rejection [4,15,20,21]. The increase in mass has been explained by myocardial edema. A prolongation of T2-relaxation time of the interventricular septum has been reported with rejection but has been found not to be sensitive enough to prove, or rule out, cardiac rejection [21].

Table 2

MRS data

	Pre-operative	Post-operative (>10 days)	P-value
<i>MRS data (n = 6)</i>			
Pi	10 ± 9	25 ± 12	<0.05
PCr	98 ± 34	99 ± 25	n.s.
β ATP	44 ± 12	41 ± 12	n.s.
PCr/ β ATP	2.2 ± 0.3	2.4 ± 0.3	n.s.
PCr/Pi	9.8 ± 3.4	4.0 ± 0.9	n.s.
β ATP/Pi	4.4 ± 1.7	1.6 ± 0.8	<0.05

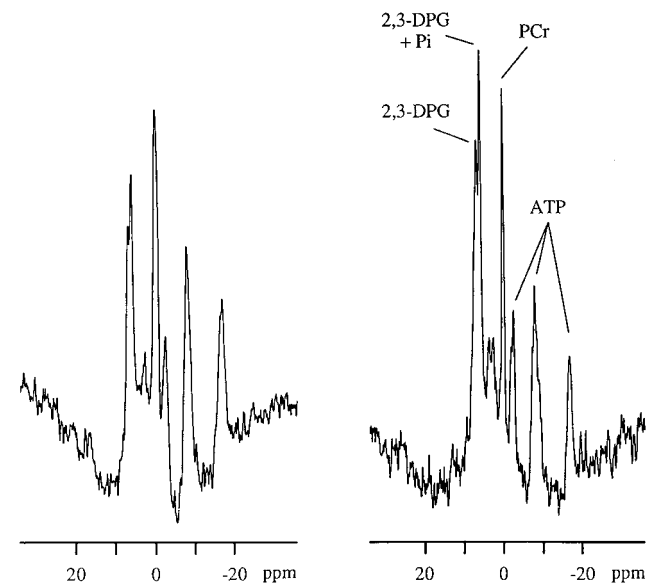


Fig. 1. Phosphorous spectra of a heart (anteroseptal region) before (left) and 24 days after transplantation (right). Peaks from left to right show 2,3 diphospho-glycerol (2,3 DPG), inorganic phosphate (Pi), phosphocreatine (PCr), adenosine triphosphate (γ , α , β ATP). The spectrum on the right shows an increase in inorganic phosphate (Pi) and a decrease in phosphocreatine ATP values, respectively, when compared to the spectrum at baseline. These data are compatible with acute myocardial rejection.

Table 3

Correlations between MRI and MRS data and histologic rejection

Rejection score versus:	R	P-value
Muscle mass	0.80	<0.0001
Septal wall thickness	0.73	<0.0001
Stroke volume	0.61	<0.005
Inorganic phosphate (Pi)	0.57	<0.01
T2-relaxation time	0.53	<0.01
Ejection fraction	0.49	<0.03

These data are, however, not specific for detection of cardiac rejection. Wall thickening has been reported after myocardial cardioplegia, etc. An increase in wall thickness or left ventricular muscle mass is relatively insensitive with regard to cardiac rejection and represents usually a 'late' stage of cardiac rejection when myocardial edema is severe and cardiac function depressed [1,14]. Therefore, these parameters provide only limited information on rejection and can be detected by MRI only when the process is advanced with moderate to severe rejection.

4.2. MR-spectroscopy for detection of cardiac rejection

Severe biochemical changes of the cardiac cells are found in the presence of myocardial rejection. Histologically two different types of rejection have been described, namely a vascular and a cellular rejection type. Biochemical changes can however, only be detected when myocardial or interstitial tissue is affected. Under these circumstances a reduction in the energy-rich phosphates has been described with a decrease in phosphocreatine and an increase in inorganic phosphate [11–13]. Therefore, several authors have recommended the use of magnetic resonance spectroscopy with a decrease in the ratio of PCr to β -ATP or PCr/Pi as well as β -ATP/Pi to detect changes associated with myocardial rejection [16–18].

In the present study a decrease in two of the three ratios (PCr/Pi and β -ATP/Pi) was observed during acute rejection, whereas the third ratio PCr/ β -ATP did not change significantly. These data show that changes in the energy-rich phosphates can be detected with MR-spectroscopy. However, these ratios show relatively large variations and, thus, are only of limited value for detection of rejection (Table 2). Previously, Bottomley et al. [18] reported a sensitivity of 50% and a specificity of 73% for detection of cardiac rejection by MR-spectroscopy. These authors followed 14 patients with MR-spectroscopy and used each patient as its own control. These authors showed clearly that sensitivity and specificity for detection of cardiac rejection are probably low and provide only limited information for non-invasive detection of cardiac rejection.

Correlations between histologic rejection and MRI/MRS (Table 3) showed significant regressions for muscle mass, septal wall thickness, stroke volume, ejection fraction and

T2-relaxation time (MRI), inorganic phosphate (MRS) and histologic rejection.

4.3. Limitations of MR assessment for cardiac rejection

(1) MR-imaging: dimensional data and T2 relaxation times give only limited information on the histologic changes of the myocardium associated with cardiac rejection. Similar data can be obtained with other imaging modalities such as echocardiography or CT scanning. Furthermore, the availability of MR-imaging systems is limited and the systems are costly.

(2) MR-spectroscopy: temporal and spatial resolution is limited with the technique used (surface coil) and only apical regions of the myocardium can be studied reliably. Contamination by blood (cavity), motion artefacts and skeletal muscle may be a major problem for MR-spectroscopy and increase variability.

5. Conclusions

Detection of cardiac rejection is feasible with MR-imaging and MR-spectroscopy although correlations with histologic grading are low to moderate. Variability and reproducibility of MR-spectroscopy for detection of cardiac rejection are not yet defined and their clinical value for assessing cardiac rejection remains to be confirmed.

Acknowledgements

The authors would like to thank the following people for their collaboration in this project: G. Sigurdsson, V. Krejci, L. Hildebrand, B. Aeschbacher, P. Mohacsi, H. Slotboom, C. Boesch, M. Lanz and the staff of the MR Center 1 and surgical research unit. The study was supported by a grant from the Swiss National Foundation (No. 3200–032565) and the Swiss Heart Foundation.

References

- [1] Kemkes BM, Schutz A, Engelhardt M, Brandl U, Breuer M. Non-invasive methods of rejection diagnosis after heart transplantation. *J Heart Lung Transplant* 1992;11:221–231.
- [2] Hosenpud JD, Novick RJ, Bennett LE, Keck BM, Fiore B, Daily OP. The Registry of the International Society for Heart and Lung Transplantation: thirteenth official report – 1996. *J Heart Lung Transplant* 1996;15 (7):655–674.
- [3] Billingham ME, Cary NR, Hammond ME, Kemnitz J, Marboe C, McCallister HA, Snovar DC, Winters GL, Zerbe A. A working formulation for the standardization of nomenclature in the diagnosis of heart and lung rejection: heart rejection study group. *J Heart Transplant* 1990;9 (6):587–593.
- [4] Wear KA, Schnittger I, Director BA, Dawkins KD, Haverich A, Billingham ME, Jamieson SW, Popp RL. Ultrasonic characterization of acute cardiac rejection from temporal evolution of echo-cardiograms. *J Heart Transplant* 1986;5 (6):425–429.

- [5] Ertel W, Reichenspurner H, Lersch C, Hammer C, Plahl M, Lehmann M, Kemkes BM, Osterholzer G, Reble B, Reichart B. Cytoimmunological monitoring in acute rejection and viral, bacterial or fungal infection following transplantation. *J Heart Transplant* 1985;4 (4):390–394.
- [6] Ladowski JS, Sullivan M, Schatzlein MH, Peterson AC, Underhill DJ, Scheeringa RH. Cardiac isoenzymes following heart transplantation. *Chest* 1992;102 (5):1520–1521.
- [7] Warnecke H, Schueler S, Goetze HJ, Matheis G, Suthoff U, Muller J, Tietze U, Hetzer R. Noninvasive monitoring of cardiac allograft rejection by intramyocardial electrogram recordings. *Circulation* 1986;74:72–76.
- [8] Walpoth BH, Tschopp A, Peheim E, Schaffner T, Althaus U. Assessment of Troponin-T for detection of cardiac rejection in a rat model. *Transplant Proc* 1995;27 (3):2084–2087.
- [9] Wang CW, Steinhubl SR, Castellani WJ, Van Lente F, Miller DP, James KB, Young JB. Inability of serum myocyte death markers to predict acute cardiac allograft rejection. *Transplantation* 1996;62 (12):1938–1941.
- [10] Zimmermann R, Baki S, Dengler TJ, Ring GH, Remppis A, Lange R, Hagl S, Kubler W, Katus HA. Troponin-T release after heart transplantation. *Br Heart J* 1993;69 (5):395–398.
- [11] Walpoth BH, Tschopp A, Lazeyras F, Galdikas J, Tschudi J, Altermatt H, Schaffner T, Aue WP, Althaus U. Magnetic resonance spectroscopy for assessing myocardial rejection in the transplanted rat heart. *J Heart Lung Transplant* 1993;12 (2):271–282.
- [12] Walpoth BH, Galdikas J, Tschopp A, Vorburger T, Lazeyras F, Schaffner T, Althaus U. Differentiation of cardiac ischemia and rejection by nuclear magnetic spectroscopy. *Thorac Cardiovasc Surgeon* 1991;39:217–220.
- [13] Walpoth BH, McGregor CG, Aziz S, Billingham ME, Jardetzky NW, Jardetzky O, Jamieson SW, Shumway NE. Assessment of myocardial rejection by nuclear magnetic resonance (P-31 NMR). *Circulation* 1984;70:165.
- [14] Walpoth BH, Lazeyras F, Tschopp A, Schaffner T, Althaus U, Billingham ME, Morris R. Assessment of cardiac rejection and immunosuppression by magnetic resonance imaging and spectroscopy. *Transplant Proc* 1995;27 (3):2088–2091.
- [15] Aherne T, Tscholakoff D, Finkbeiner W, Sechtem U, Derugin N, Yee E, Higgins CB. Magnetic resonance imaging of cardiac transplants: the evaluation of rejection of cardiac allografts with and without immunosuppression. *Circulation* 1986;74:145–156.
- [16] Canby RC, Evanochko WT, Barrett LV, Kirklin JK, McGiffin DC, Sakai TT, Brown ME, Foster RE, Reeves RC, Pohost GM. Monitoring the bioenergetics of cardiac allograft rejection using in vivo P-31 nuclear magnetic resonance spectroscopy. *J Am Coll Cardiol* 1987;9 (5):1067–1074.
- [17] Fraser Jr CD, Chacko VP, Jacobus WE, Mueller P, Soulen RL, Hutchins GM, Reitz BA, Baumgartner WA. Early phosphorus 31 nuclear magnetic resonance bioenergetic changes potentially predict rejection in heterotopic cardiac allografts. *J Heart Transplant* 1990;9:197–204.
- [18] Bottomley PA, Weiss RG, Hardy CJ, Baumgartner WA. Myocardial high-energy phosphate metabolism and allograft rejection in patients with heart transplant. *Radiology* 1991;181:344–350.
- [19] Vion-Dury J, Mouly-Bandini A, Viout P, Sciaky M, Confort-Gouny S, Monties JR, Cozzone P. Early detection of heart transplant rejection using cardiac echography combined with the assay of glycosylated residues in plasma by proton NMR spectroscopy. *C R Acad Sci III* 1992;315 (12):479–484.
- [20] Revel D, Chapelon C, Mathieu D, Cochet P, Ninet J, Chuzel M, Champsaur G, Dureau G, Amiel M, Helenon O. Magnetic resonance imaging of human orthotopic heart transplantation: correlation with endomyocardial biopsy. *J Heart Transplant* 1989;8 (2):139–146.
- [21] Doornbos J, Verwey H, Essed CE, Balk AH, de Roos A. MR-imaging in assessment of cardiac transplant rejection in humans. *J Comput Assist Tomogr* 1990;14 (1):77–81.

Appendix A. Conference discussion

Dr A. Murday (London, UK): I think from the data that you have presented there needs to be an extra control in there. There needs to be a control of a pig having a transplant and being immunosuppressed throughout, because although it is antilogical, it may be that your changes are just due to the time after transplantation rather than rejection because they are all rejecting.

Dr Walpoth: I think that is the reason why we have immunosuppressed the animals for 1 week with cyclosporine levels, with the triple therapy, like in patients. In all animals at the end of 1 week of treatment we have had endomyocardial biopsy results. They showed that only in two animals there is a Texas 2, which is a low rejection grade which would not be treated in patients. It is only thereafter that we stopped immunosuppression to allow the animals to go into rejection, where most of them showed moderate rejection. So each animal serves as its own control.

Dr Murday: I appreciate that that control exists, but I still think that it is just feasible that the changes you see in MRI could be argued to be just the consequence of time. In other words, if you wait 4 weeks, you have the MRI changes. It is not very likely, but it is possible.

Dr Walpoth: I do not think so, because what you are alluding to is the change you would see during the operation, which is the transplant trauma, the reperfusion of the ischemic heart which, of course, will induce some changes, such as edema, very early after surgery. You can measure that and several groups have shown that this is very transient, and that it is reversed after a couple of days. That is why we elected to treat them for 1 week before stopping immunosuppression, so that they could serve as their own control.