

Scientific Foundation SPIROSKI, Skopje, Republic of Macedonia  
 Open Access Macedonian Journal of Medical Sciences. 2020 May 15; 8(A):354-359.  
<https://doi.org/10.3889/oamjms.2020.4676>  
 eISSN: 1857-9655  
 Category: A - Basic Sciences  
 Section: Pathology



# Expression of “Connexin 43” in Colorectal Carcinomas: Histopathological and Immunohistochemical Study

Essam Ayad, Ahmed Naeem Eesa, Rabab Radi\*, Lubna Omar El Farouk Abdel-Salam

Department of Pathology, Faculty of Medicine, Cairo University, Giza, Egypt

## Abstract

**Edited by:** Sinisa Stojanowski  
**Citation:** Ayad E, Eesa AN, Radi R, Abdel-Salam LOE. Expression of “Connexin 43” in Colorectal Carcinomas: Histopathological and Immunohistochemical Study. Open-Access Maced J Med Sci. 2020 May 15; 8(A):354-359. <https://doi.org/10.3889/oamjms.2020.4676>  
**Keywords:** Colorectal cancer; Gap junction; Immunohistochemistry; Cx 43  
**\*Correspondence:** Rabab Radi, Department of Pathology, Faculty of Medicine, Cairo University, Giza, Egypt. E-mail: [r.radi.wael@gmail.com](mailto:r.radi.wael@gmail.com)  
**Received:** 26-Mar-2020  
**Revised:** 14-Apr-2020  
**Accepted:** 15-Apr-2020  
**Copyright:** © 2020 Essam Ayad, Ahmed Naeem Eesa, Rabab Radi, Lubna Omar El Farouk Abdel-Salam  
**Funding:** This research did not receive any financial support  
**Competing Interests:** The authors have declared that no competing interests exist  
**Open Access:** This is an open-access article distributed under the terms of the Creative Commons Attribution-NonCommercial 4.0 International License (CC BY-NC 4.0)

**BACKGROUND:** Colorectal cancer is one of the most common cancers worldwide and leading cause of cancer related deaths. Connexins are integral membrane proteins that form channels between adjacent cells. Gap junction intercellular communication plays essential roles in tissue homeostasis and regulation of cell growth and differentiation. Connexins can act as either tumor suppressors or tumor promoters. The human connexin protein family contains 21 members, of which the most widely studied is connexin 43 (Cx 43).

**OBJECTIVES:** Investigation of immunohistochemical expression of Cx 43 in cases of colorectal adenoma and carcinoma and correlation of this expression with the clinico-pathological aspects of the tumors.

**MATERIALS AND METHODS:** Seventy formalin fixed paraffin embedded BC tissue sections were randomly collected. All the available data were collected from the patients' reports. The paraffin blocks were sectioned and stained with hematoxylin and eosin stains for histologic evaluation. Additional sections were immunostained with Cx 43.

**RESULTS:** Cx 43 expression was negative in all studied cases.

**CONCLUSION:** Cx 43 is a tumor suppressor that is lost early in colorectal carcinogenesis and can be considered as potential target for cancer chemoprevention and chemotherapy aiming at restoration of normal connexin expression and functional gap junctions.

## Introduction

Colorectal cancer (CRC) is one of the most common cancers worldwide. More than 1 million new cases were reported annually resulting in about 600,000 deaths worldwide per year [1]. Worldwide, CRC is the second most common cancer in women and the third most common in men [2].

In Egypt, colorectal carcinoma accounts for 6.48% of all cancers according to the National Cancer Institute Cairo University [3].

Loewenstein and Kanno were the first to propose the idea that gap junction intercellular communication (GJIC) regulates tumor growth more than 50 years ago in a study, in which they demonstrated the loss of electrical coupling occurring in rat liver tumors [4]. Connexins are integral membrane proteins that form channels between adjacent cells. GJIC plays essential roles in tissue homeostasis and regulation of cell growth and differentiation [5]. In addition, connexins form functional channels at the non-junctional areas of the plasma membrane, these so-called hemichannels provide a communication pathway between the intracellular and extracellular milieu that is an important in autocrine and paracrine signaling [6].

Connexins can act as either tumor suppressors or tumor promoters depending on the isoform, cancer stage, and tissue. In addition to the emerging prognostic value of connexins in cancer, several studies indicate that connexin targeting might have considerable therapeutic implications [7], [8]. Cancer cells often display a loss of GJIC due to the dysregulation of connexin expression at multiple levels [9].

The human connexin protein family contains 21 members, of which the most widely studied is connexin 43 (Cx 43) [5].

Several studies reported that Cx 43 acts as tumor suppressor that is downregulated in colorectal carcinoma they are considered as potential targets for cancer chemoprevention and chemotherapy [10], [11], [12], [13], [14].

## Materials and Methods

A total of 70 formalin fixed, paraffin embedded tissue sections; divided as follow: 20 cases of colorectal adenoma and 50 cases of carcinoma were randomly collected from endoscopic and colectomy

specimens, blind of their clinico-pathological, and immunohistochemical data. The cases were collected from the Pathology Department at the Kasr El-Aini hospital in the time period between May 2018 and February 2019.

The data collected from the pathology reports of the cases included age and sex of patient, tumor size, type, and the degree of dysplasia as regard cases of adenoma. Regarding carcinoma cases, data collected included age and sex of patient, size of tumor, as well as the lymph node status.

The paraffin blocks of the tumor tissue were serially sectioned at 4  $\mu$ m thickness, stained with routine hematoxylin and eosin stains for pathological examination. The tumors were histologically typed according to the latest available World Health Organization recommendations [15].

Tumors histological grading was performed according to the World Health Organization recommendations [2]. Tumors staging was performed using the TNM staging system and the cases were further divided into prognostic stages [16]. Modified Duke's staging was also performed [17].

The tumor sections were also examined for the presence of lymphovascular invasion and perineural invasion.

For immunostaining, additional serial sections were prepared from the paraffin blocks and mounted on charged slides. Heat mediated antigen retrieval was performed with citrate buffer pH 6 in automated water bath (Dako PT link, PT101). Sections were stained for anti-connexin 43 antibody (Rabbit Polyclonal Anti-Connexin 43/GJA1 antibody [EPR21153] ab217676) obtained from Abcam and used at a dilution of 1:250. Immunohistochemical staining was performed in an autostainer (Dako Autostainer Link 48) using a polymer-based detection system (Dako EnVision™ FLEX, K8000). Diaminobenzidine was used as chromogen and hematoxylin as counterstain. Sections of normal human prostate tissue were used as positive control according to the manufacturer's recommendation.

The immunohistochemical staining was analyzed. The percentage of positively stained cells in normal, adenomatous, and cancerous tissues was assessed according to a 3-point scale: 0 (<10% positively stained cells), 1+ (10–50% positively stained cells), and 2+ (>50% positively stained cells). The results of Cx 43 immunostaining were expressed as Cx 43-positive (level of expression 1+ and 2+) and Cx 43-negative (level of expression 0) [18].

A substrate of cases was also stained immunohistochemically against  $\beta$ -catenin and Cyclin D1 using the same above methods.

Microsoft Excel 2010 was used for data entry and the Statistical Package for the Social Sciences (SPSS version 21) was used for data analysis. Simple

descriptive statistics (arithmetic mean and standard deviation) used for summary of quantitative data and frequencies used for qualitative data.

Finally, microscopic photos were captured using a digital camera attached to an Olympus microscope model BX 51.

## Results

This study is a retrospective study including 70 randomly selected cases; 20 cases of colorectal adenoma and 50 cases of carcinoma obtained from endoscopic and colectomy specimens. The cases were collected from the Kasr Al-Aini Hospital in the time period between May 2018 and February 2019. The clinico-pathological data, histological examination, and immunohistochemical results are summarized in Table 1.

In the present study, connexin 43 (Cx 43) was evaluated in colorectal adenoma and carcinoma cases. Sections from normal prostate gland were stained in the same runs with our colorectal adenoma and carcinoma cases, as positive control as instructed by the primary antibody's manufacturer. It was strongly and consistently expressed in the basal cells of normal human prostate glands. However, it was not expressed in all of colorectal adenoma and carcinoma cases.

## Discussion

In the present study, connexin 43 (Cx 43) was evaluated in colorectal adenoma and carcinoma cases. Sections from normal prostate gland were stained in the same runs with our colorectal adenoma and carcinoma cases, as positive control as instructed by the primary antibody's manufacturer. It was strongly and consistently expressed in the basal cells of normal human prostate glands (Figure 1c). However, it was not expressed in all of colorectal adenoma and carcinoma cases (Figure 1d and e). Hence, we suggest that Cx 43 may act as tumor suppressor gene and its expression is lost early in colorectal carcinogenesis.

It was only expressed focally in normal mucosa adjacent to adenocarcinoma (Figure 1a and b) that was in concordance with Nemeth *et al.* [19], Dubina *et al.* [20] and Kanczuga-Koda *et al.* [21] where Cx 43 was sparsely distributed in the human colonic epithelial cells. The notion that connexins are able to form gap junctions in normal colonic mucosa is further supported by Western blot analysis of protein extracts from normal colon tissue [22].

**Table 1: Clinico-pathologic features and Cx 43 expression**

Parameter	n (%)	Cx 43 (positive expression)	Cx 43 (negative expression)
Adenoma cases	20 (28.6)	0 (0)	20 (28.6)
Age (27–76 years, mean 59.8±11.83)			
Sex			
Male	14 (70)		
Female	6 (30)		
Site			
Left colon	11 (55)		
Right colon	4 (20)		
Rectum	5 (25)		
Size			
<2 cm	17 (85)		
>2 cm	3 (15)		
Histologic grade			
Low grade dysplasia	14 (70)		
High grade dysplasia	6 (30)		
Type			
Tubular	11 (55)		
Tubulovillous	4 (20)		
Serrated	5 (25)		
Carcinoma cases	50 (71.4)	0 (0)	0 (71.4)
Age (30–75 years, mean 54±11.62)			
Sex			
Male	22 (44)		
Female	28 (56)		
Site			
Left colon	19 (38)		
Right colon	19 (38)		
Rectum	12 (24)		
Size (3–12 cm, mean 5.7±1.97)			
Histologic types			
Adenocarcinoma	41 (82)		
Mucoid carcinoma	9 (18)		
Histologic grade of adenocarcinoma			
Grade I	0 (0)		
Grade II	30 (73)		
Grade III	11 (27)		
T stage			
T1	0 (0)		
T2	4 (8)		
T3	36 (72)		
T4	10 (20)		
N stage			
N1	18 (36)		
N2	16 (32)		
N3	16 (32)		
M stage			
M0	49 (98)		
M1	1 (2)		
Stage			
Stage I	3 (6)		
Stage II	15 (30)		
Stage III	31 (62)		
Stage IV	1 (2)		
Modified Duke's class			
A	0 (0)		
B1	3 (6)		
B2	15 (30)		
C1	23 (46)		
C2	8 (16)		
D	1 (2)		
Lymphovascular invasion			
Positive	16 (32)		
Negative	34 (68)		
Perineural invasion			
Positive	18 (36)		
Negative	32 (64)		

In concordance to our results, Sirmes *et al.* have shown that Cx 43 is either absent or aberrantly localized in colon cancer cell lines and colorectal carcinomas, which is associated with loss of GJIC. They studied a cohort of 674 colorectal carcinoma patients. About 63% of patients had weak or no expression of Cx 43 in tumors [22]. Although some colon cancer cell lines express Cx 43 at the protein level *in vitro*, they usually do not form gap junctions, probably because of aberrant regulation of the intracellular trafficking of Cx 43. The mechanisms underlying such impaired Cx 43 trafficking remain to be elucidated, but may involve dysregulation of the signaling pathways involved in

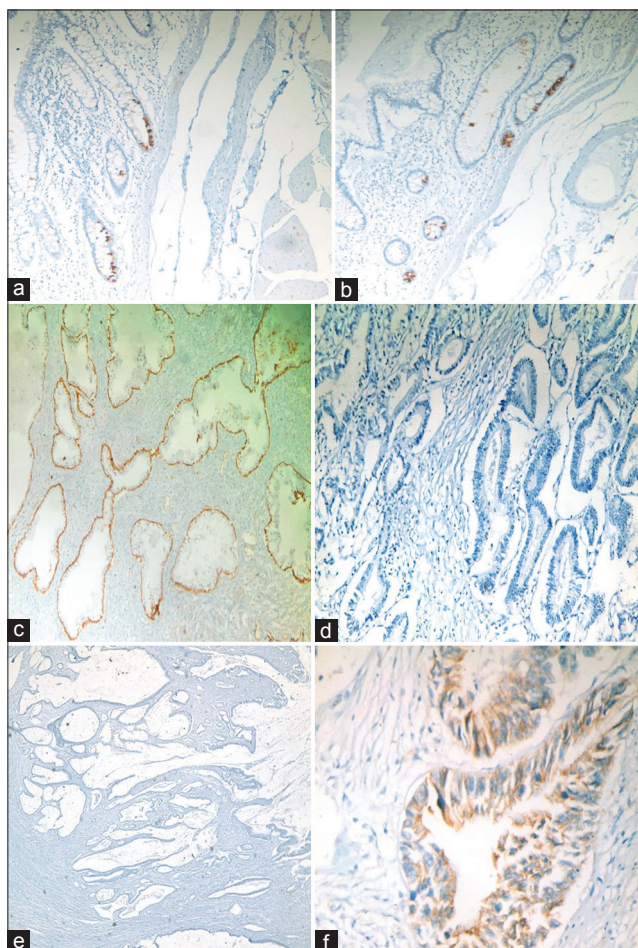


Figure 1: (a and b) Cx 43 expression in normal colonic mucosa, (c) Cx 43 expression in basal cell layer of prostatic glands "positive control," (d) negative Cx 43 expression in colonic adenocarcinoma, (e) negative Cx 43 expression in mucoid carcinoma, (f) positive  $\beta$ -catenin membranous staining in adenocarcinoma

regulating the assembly of Cx 43 into gap junctions or Cx 43 endocytosis and postendocytic sorting [13]. Furthermore, loss of Cx 43 expression was significantly correlated with shorter relapse-free survival and overall survival. Loss of Cx 43 further identified among Stage I and Stage II patients with reduced relapse-free and overall survival. However, this study was carried on cell lines and they combine both immunohistochemistry and Western blot techniques. They concluded that Cx 43 acts as a CRC tumor suppressor and that loss of Cx 43 expression during CRC development is associated with reduced patient survival [22].

Furthermore, Ismail *et al.* demonstrated that Western blotting using anti-Cx 43 antibody indicated that the expression of Cx 43 was significantly downregulated in 75% of colon cancer samples and immunohistochemical analysis of the tissue samples confirmed the downregulation of the Cx 43. Cx 43 downregulation showed significant association ( $p < 0.05$ ) with the histological type and tumor invasion properties of the cancer. They suggested that loss of Cx 43 may be an important event in colon carcinogenesis and tumor progression, providing significant insights about

the tumor suppressive properties of the Cx 43 and its potential as a diagnostic marker for colon cancer [14].

Dubina *et al.* also considered that Cx 43 acts as tumor suppressor since their function or expression is frequently aberrant in tumor cells. They have demonstrated that connexin 43 is specifically and quite frequently mutated in human colon sporadic adenocarcinomas. All tumor-associated mutations led to a shift of reading frame causing premature stop codons and truncation of the multifunctional carboxyl-terminal domain of the protein. Expression of mutated connexin 43 proteins was restricted to invasive structures of tumors. These findings suggest that mutational alterations of connexin 43 are involved in advanced stages of progression of human colon cancer toward malignancy [20].

Since the interaction between connexins of adjacent cells is not strong enough to maintain the cytoplasmic membranes of the neighboring cells together and to form the canal, the formation and maintenance of gap junctions require the presence of cell adhesion molecules [23], [24]. So substrate of cases was immunohistochemically stained with the adhesion molecule  $\beta$ -catenin. The majority of cases were negative apart from a focal positive area where focal membranous staining was noted between the tumor cells (Figure 1f). The correlation between Cx 43 and  $\beta$ -catenin; being both were downregulated in our work strengthen our conclusion that Cx 43 has tumor suppressor properties being lost in our cases. This finding was similar to Kanczuga-Koda *et al.* who found a statistically significant positive correlation between  $\beta$ -catenin and Cx 43 in colorectal carcinoma cases [21].

Cx 43 was also shown to participate in cell cycle regulation [25], [26]. Cyclin D1 is a protein required for progression through the G1 phase of the cell cycle. During the G1 phase, it is synthesized rapidly and accumulates in the nucleus and is degraded as the cell enters the S phase [27]. A substrate of cases was stained with Cyclin D1 and they found to be negative, this finding was approximate to Qi *et al.* who found significant correlation between the protein expression rates of Cyclin D1 and Cx 43 ( $p < 0.05$ ) in rectal cancer specimens [28].

Decreased gap junctional communication and reduced connexin expression were subsequently observed in several cancer types. Moreover, many growth factors, oncogenes and tumor promoters are potent inhibitors of GJIC [13].

Strengthening our results, several lines of experimental evidence indicate that connexins may act as tumor suppressors. First, restoration of GJIC by transfection of connexin genes into tumorigenic cells has been shown to normalize growth *in vitro* and *in vivo* [29], [30], [31], [32]. Second, downregulation of connexins by small interfering RNA has been found to result in more aggressive growth of cancer cells [32].

Third, knock-out of connexin genes in mice results in increased susceptibility to chemical or radiation-induced tumor formation [33], [34], [35]. Collectively, these observations are in concordance with our results in which the connexins may act as tumor suppressors, and they are considered as potential targets for cancer chemoprevention and chemotherapy [10], [11], [12].

Although several studies have shown that connexins are downregulated in colorectal carcinomas, some studies; in contrast to, our results have observed enhanced connexin expression. Han *et al.* stated that Cx 43 cytoplasmic expression increased progressively in the colonic adenocarcinoma sequence in both the epithelial and stromal components. In the epithelial component, Cx 43 was expressed lower in Stage I adenocarcinomas compared to Stage III/IV. In addition, Cx 43 was relatively increased in the adenocarcinoma at the invasive tumor front in all stages. Cytoplasmic expression of Cx 43 was frequently observed in colonic cancer cells. In addition, we found that the level of Cx 43 expression was significantly associated with higher AJCC Stage III/IV but did not have impact on the histological grading [36].

Another study showed higher Cx 43 expression in adenomas compared to healthy colonic mucosa suggesting an active role of Cx 43 in the process of carcinogenesis. Moreover, higher Cx 43 expression was found in the colonic mucosa surrounding advanced colorectal adenoma [37]. Stromal Cx 43 expression in CRC was found to be higher in more advanced CRC showing that it is a possible indicator of metastatic potential of colorectal adenocarcinoma [18].

Regarding the role of Cx 43 in other different tumors, many studies also reported its tumor suppressor effects. Ableser *et al.* suggest that Cx 43 can act as a tumor suppressor during melanoma tumorigenesis [38]. Solan *et al.* who studied the role of Cx 43 in pancreatic adenocarcinoma cell lines show decreased or altered connexin expression and/or localization [39]. Silencing connexin 43 induces cell cycle entry and invasion in non-neoplastic mammary epithelial cells [40]. Connexin 43 also suppresses lung cancer stem cells [41]. Yet different organs but they stated that it has tumor suppressor properties.

Regarding role of other connexins in CRC, patients with high levels of Cx 26 in the primary tumor have been reported to have a higher probability of developing lung metastasis. Furthermore, lung metastases, but not lymph node or liver metastases, have a higher level of Cx 26 expression than the corresponding primary colorectal tumor. Cx 26 localizes both in intracellular compartments and at the plasma membrane in the metastatic cells, indicating a possible role for GJIC during metastasis. Thus, Cx 26 is a promising therapeutic target, particularly for CRC patients who develop lung metastasis [42].

The finding that several connexin isoforms are expressed in colonic tissue, along with the fact that they

function in a redundant manner, makes it challenging to understand the roles of the specific connexin isoform in the normal colonic mucosa and in CRC pathogenesis. It will also be important to define which isoforms are expressed at the protein level in the normal colonic epithelium and to obtain a better understanding of how their expression changes during CRC progression [13].

The fact that connexins may be involved in both tumor suppression and tumor progression should be carefully evaluated before connexins can be considered as targets in cancer therapy. On the one hand, restoration of connexin expression and functional gap junctions may result in reduced tumor growth; on the other hand, increasing connexin expression may in other circumstances leads to increased cancer cell invasion. A central step toward determining whether connexins could represent beneficial targets in CRC prevention and therapy will be to obtain a better understanding of the molecular basis underlying their dysregulation during disease development.

## Conclusion

Cx 43 is a tumor suppressor that is lost early in colorectal carcinogenesis and can be considered as potential target for cancer chemoprevention and chemotherapy aiming at restoration of normal connexin expression and functional gap junctions.

## References

- Enkhat T, Nishi M, Takasu C, Yoshikawa K, Jun H, Tokunaga T, *et al.* Programmed cell death ligand 1 expression is an independent prognostic factor in colorectal cancer. *Anticancer Res.* 2018;38(6):3367-73. <https://doi.org/10.21873/anticancer.12603>  
PMid:29848685
- Hamilton SR, Bosman FT, Boffetta P. In: Bosman FT, Carneiro F, Hruban RH and Theise ND, editors. *Carcinoma of the colon and rectum.* In: WHO Classification of Tumors of the Digestive System. 4<sup>th</sup> ed. Lyon: IARC Press; 2010. p. 132-46.
- Khorshed E. Gastrointestinal tract tumors. In: Mokhatr NM, MA Ghoneim, MH Hussein, editors. *Cancer Pathology Registry 2000-2011.* Bethesda, Maryland: National Cancer Institute; 2016. p. 32-48.
- Loewenstein WR, Kanno Y. Intercellular communication and the control of tissue growth: Lack of communication between cancer cells. *Nature.* 1966;209(5029):1248-9. <https://doi.org/10.21873/anticancer.12603>  
PMid:5956321
- Aasen T, Mesnil M, Naus CC, Lampe PD, Laird DW. Gap junctions and cancer: Communicating for 50 years. *Nat Rev Cancer.* 2016;16(12):775-88. <https://doi.org/10.1038/nrc.2016.105>  
PMid:27782134
- Saez JC, Leybaert L. Hunting for connexin hemichannels. *FEBS Lett.* 2014;588(8):1205-11. <https://doi.org/10.1016/j.febslet.2014.03.004>  
PMid:24631534
- Laird DW, Lampe PD. Therapeutic strategies targeting connexins. *Nat Rev Drug Discov.* 2018;17(12):905-21. <https://doi.org/10.1038/nrd.2018.138>  
PMid:30310236
- Delvaeye T, Vandenabeele P, Bultynck G, Leybaert L, Krysko DV. Therapeutic targeting of connexin channels: New views and challenges. *Trends Mol Med.* 2018;24(12):1036-53. <https://doi.org/10.1016/j.molmed.2018.10.005>  
PMid:30424929
- Tan LW, Bianco T, Dobrovic A. Variable promoter region CpG island methylation of the putative tumor suppressor gene connexin 26 in breast cancer. *Carcinogenesis.* 2002;23(2):231-6. <https://doi.org/10.1093/carcin/23.2.231>  
PMid:11872627
- Kandouz M, Batist G. Gap junctions and connexins as therapeutic targets in cancer. *Expert Opin Ther Targets.* 2010;14(7):681-92. <https://doi.org/10.1517/14728222.2010.487866>  
PMid:20446866
- King TJ, Bertram JS. Connexins as targets for cancer chemoprevention and chemotherapy. *Biochim Biophys Acta.* 2005;1719(1-2):146-60.  
PMid:16263076
- Naus CC, Laird DW. Implications and challenges of connexin connections to cancer. *Nat Rev Cancer.* 2010;10(6):435-41. <https://doi.org/10.1038/nrc2841>  
PMid:20495577
- Sirnes S, Lind GE, Bruun J, Fykerud TA, Mesnil M, Lothe RA, *et al.* Connexins in colorectal cancer pathogenesis. *Int J Cancer.* 2015;137(1):1-11. <https://doi.org/10.1002/ijc.28911>  
PMid:24752574
- Ismail R, Rashid R, Andrabi K, Parray FQ, Besina S, Shah MA, *et al.* Pathological implications of Cx43 down-regulation in human colon cancer. *Asian Pac J Cancer Prev.* 2014;15(7):2987-91. <https://doi.org/10.7314/apjcp.2014.15.7.2987>  
PMid:24815435
- Bosman F, Carneiro F, Hruban R, Theise N. Tumors of the colon and rectum. In: Kleihues P, Louis DN, editors. *WHO Classification of Tumours of the Digestive System.* 4<sup>th</sup> ed. Lyon: IARC Press; 2010. p. 132.
- Jessup JM, Goldberg RM, Asare EA, Benson AB 3<sup>rd</sup>, Brierley JD, Chang GJ, *et al.* Definitions of AJCC TNM. In: Amin MB, Edge SB, Greene FL., editors. *AJCC Cancer Staging Manual.* 8<sup>th</sup> ed. Berlin: Springer; 2017. p. 268-9.
- Bresalier RS. Colorectal Cancer. In: Feldman M, Friedman LS, Brandt LJ., editors. *Sleisenger and Fordtran's Gastrointestinal and Liver Disease: Pathophysiology, Diagnosis, Management.* 9<sup>th</sup> ed. Philadelphia, PA: Elsevier; 2010. p. 2191-238. <https://doi.org/10.1016/b978-1-4160-6189-2.00123-2>
- Radić J, Krušlin B, Šamija M, Ulamec M, Milošević M, Jazvić M, *et al.* Connexin 43 expression in primary colorectal carcinomas in patients with Stage III and IV disease. *Anticancer Res.* 2016;36(5):2189-96.  
PMid:27127122
- Nemeth L, Maddur S, Puri P. Immunolocalization of the gap junction protein connexin 43 in the interstitial cells of cajal in the normal and Hirschsprung's disease bowel. *J Pediatr Surg.* 2000;35(6):823-8. <https://doi.org/10.1053/jpsu.2000.6851>  
PMid:10873019
- Dubina MV, Iatckii NA, Popov DE, Vasil'ev SV, Krutovskikh VA. Connexin 43, but not connexin 32, is mutated at advanced stages of human sporadic colon cancer. *Oncogene.*

- 2002;21(32):4992-6. <https://doi.org/10.1038/sj.onc.1205630>  
PMid:12118378
21. Kanczuga-Koda L, Sulkowski S, Koda M, Sobaniec-Lotowska M, Sulkowska M. Expression of connexins 26, 32 and 43 in the human colon--an immunohistochemical study. *Folia Histochem Cytobiol.* 2004;42(4):203-7. <https://doi.org/10.5603/fhc.2013.0043>  
PMid:15704645
  22. Sirnes S, Bruun J, Kolberg M, Kjenseth A, Lind GE, Svindland A, et al. Connexin43 acts as a colorectal cancer tumor suppressor and predicts disease outcome. *Int J Cancer.* 2012;131(3):570-81. <https://doi.org/10.1002/ijc.26392>  
PMid:21866551
  23. Hsu M, Andl T, Li G, Meinkoth JL, Herlyn M. Cadherin repertoire determines partner-specific gap junctional communication during melanoma progression. *J Cell Sci.* 2000;113(Pt 9):1535-42.  
PMid:10751145
  24. Fujimoto K, Nagafuchi A, Tsukita S, Kuraoka A, Ohokuma A, Shibata Y. Dynamics of connexins, E-cadherin and alpha-catenin on cell membranes during gap junction formation. *J Cell Sci.* 1997;110(Pt 3):311-22.  
PMid:9057084
  25. Solan JL, Lampe PD. Connexin phosphorylation as a regulatory event link to gap junction channel assembly. *Biochim Biophys Acta.* 2005;1711(2):154-63. <https://doi.org/10.1016/j.bbame.2004.09.013>  
PMid:15955300
  26. Decrock E, De Vuyst E, Vinken M, Van Moorhem M, Vranckx K, Wang N, et al. Connexin43 hemichannels contribute to the propagation of apoptotic cell death in a rat C6 glioma cell model. *Cell Death Differ.* 2009;16(1):151-63. <https://doi.org/10.1038/cdd.2008.138>  
PMid:18820645
  27. Baldin V, Lukas J, Marcote MJ, Pagano M, Draetta G. Cyclin D1 is a nuclear protein required for cell cycle progression in G1. *Genes Dev.* 1993;7(5):812-21. <https://doi.org/10.1101/gad.7.5.812>  
PMid:8491378
  28. Qi F, Yuan Y, Zhi X, Huang Q, Chen Y, Zhuang W, et al. Synergistic effects of AKAP95, cyclin D1, cyclin E1, and Cx43 in the development of rectal cancer. *Int J Clin Exp Pathol.* 2015;8(2):1666-73.  
PMid:25973052
  29. King TJ, Fukushima LH, Yasui Y, Lampe PD, Bertram JS. Inducible expression of the gap junction protein connexin43 decreases the neoplastic potential of HT-1080 human fibrosarcoma cells *in vitro* and *in vivo*. *Mol Carcinog.* 2002;35(1):29-41. <https://doi.org/10.1002/mc.10071>  
PMid:12203365
  30. McLachlan E, Shao Q, Wang HL, Langlois S, Laird DW. Connexins act as tumor suppressors in three-dimensional mammary cell organoids by regulating differentiation and angiogenesis. *Cancer Res.* 2006;66(20):9886-94. <https://doi.org/10.1158/0008-5472.can-05-4302>  
PMid:17047050
  31. Zhang D, Chen C, Li Y, Fu X, Xie Y, Li Y, et al. Cx31.1 acts as a tumour suppressor in non-small cell lung cancer (NSCLC) cell lines through inhibition of cell proliferation and metastasis. *J Cell Mol Med.* 2012;16(5):1047-59. <https://doi.org/10.1111/j.1582-4934.2011.01389.x>  
PMid:21777377
  32. Shao Q, Wang H, McLachlan E, Veitch GI, Laird DW. Down-regulation of Cx43 by retroviral delivery of small interfering RNA promotes an aggressive breast cancer cell phenotype. *Cancer Res.* 2005;65(7):2705-11. <https://doi.org/10.1158/0008-5472.can-04-2367>  
PMid:15805269
  33. Avanzo JL, Mesnil M, Hernandez-Blazquez FJ, Mackowiak II, Mori CM, da Silva TC, et al. Increased susceptibility to urethane-induced lung tumors in mice with decreased expression of connexin43. *Carcinogenesis.* 2004;25(10):1973-82. <https://doi.org/10.1093/carcin/bgh193>  
PMid:15166089
  34. Dagli ML, Yamasaki H, Krutovskikh V, Omori Y. Delayed liver regeneration and increased susceptibility to chemical hepatocarcinogenesis in transgenic mice expressing a dominant-negative mutant of connexin32 only in the liver. *Carcinogenesis.* 2004;25:483-92. <https://doi.org/10.1093/carcin/bgh050>
  35. King TJ, Lampe PD. Mice deficient for the gap junction protein connexin32 exhibit increased radiation-induced tumorigenesis associated with elevated mitogen-activated protein kinase (p44/Erk1, p42/Erk2) activation. *Carcinogenesis.* 2004;25(5):669-80. <https://doi.org/10.1093/carcin/bgh071>  
PMid:14742325
  36. Han Y, Zhang PJ, Chen T, Yum SW, Pasha T, Furth EE. Connexin43 expression increases in the epithelium and stroma along the colonic neoplastic progression pathway: Implications for its oncogenic role. *Gastroenterol Res Pract* 2011;2011:561719. <https://doi.org/10.1155/2011/561719>  
PMid:21754925
  37. Bišćanin A, Ljubičić N, Boban M, Baličević D, Pavić I, Bišćanin MM, et al. CX43 Expression in colonic adenomas and surrounding mucosa is a marker of malignant potential. *Anticancer Res.* 2016;36(10):5437-42. <https://doi.org/10.21873/anticancer.11122>  
PMid:27798912
  38. Ableser MJ, Penuela S, Lee J, Shao Q, Laird DW. Connexin 43 reduces melanoma growth within a keratinocyte microenvironment and during tumorigenesis *in vivo*. *J Biol Chem.* 2014;289(3):1592-603. <https://doi.org/10.1158/1538-7445.am2014-2467>  
PMid:24297173
  39. Solan JL, Hingorani SR, Lampe PD. Changes in connexin43 expression and localization during pancreatic cancer progression. *J Membrane Biol.* 2012;245(5-6):255-62. <https://doi.org/10.1007/s00232-012-9446-2>  
PMid:22729649
  40. Fostok SF, Bazzoun D, Lelievre SA, El-Sibai M, Talhouk RS. Silencing connexin 43 induces cell cycle entry and invasion in non-neoplastic mammary epithelial cells. *Cancer Res.* 2018;78(13 Suppl):4505. <https://doi.org/10.1158/1538-7445.am2018-4505>
  41. Ruch RJ. Connexin43 suppresses lung cancer stem cells. *Cancers.* 2019;11(2):175. <https://doi.org/10.3390/cancers11020175>  
PMid:30717421
  42. Ezumi K, Yamamoto H, Murata K, Higashiyama M, Damdinsuren B, Nakamura Y, et al. Aberrant expression of connexin 26 is associated with lung metastasis of colorectal cancer. *Clin Cancer Res.* 2008;14(3):677-84. <https://doi.org/10.1158/1078-0432.ccr-07-1184>  
PMid:18245526