

Scientific Foundation SPIROSKI, Skopje, Republic of Macedonia  
 Open Access Macedonian Journal of Medical Sciences. 2020 Jul 28; 8(C):99-100.  
<https://doi.org/10.3889/oamjms.2020.3737>  
 eISSN: 1857-9655  
**Category:** C - Case Reports  
**Section:** Case Report in Dentistry



# Severe Root Resorption after Obturating a Primary Molar Using Zinc Oxide and Eugenol at Different Follow-up Periods – A Case Report

Mona Abdel Rehim Wahby<sup>1\*</sup>, Sherine Ezz Eldin Taha<sup>2</sup>, Eman Sayed El Masry<sup>2</sup>, Randa Youssef Abd Al Gawad<sup>2</sup>

<sup>1</sup>Department of Pediatric Dentistry and Dental Public Health, Faculty of Dentistry, Beni-Suef University, Beni Suef, Egypt;

<sup>2</sup>Department of Pediatric Dentistry and Dental Public Health, Faculty of Dentistry, Cairo University, Cairo, Egypt

## Abstract

**Edited by:** Slavica Hristomanova-Mitkovska  
**Citation:** Wahby MAR, Taha SEE, El Masry ES, Abd Al Gawad RY. Severe Root Resorption after Obturating a Primary Molar Using Zinc Oxide and Eugenol at Different Follow-up Periods – A Case Report. Open Access Maced J Med Sci. 2020 Jul 28; 8(C):99-100. <https://doi.org/10.3889/oamjms.2020.3737>.

**Keywords:** Pulpectomy; Primary molar; Zinc oxide eugenol; Root resorption

**\*Correspondence:** Mona Abdel Rehim Wahby, Department of Pediatric Dentistry and Dental Public Health, Faculty of Dentistry, Beni-Suef University, Beni Suef, Egypt. Email: [moonwahby@gmail.com](mailto:moonwahby@gmail.com)

**Received:** 17-Sep-2019,

**Revised:** 26-Mar-2020,

**Accepted:** 29-Mar-2020,

**Copyright:** © 2020 Mona Abdel Rehim Wahby, Sherine Ezz Eldin Taha, Eman Sayed El Masry, Randa Youssef Abd Al Gawad

**Funding:** This research did not receive any financial support

**Competing Interests:** The authors have declared that no competing interests exist

**Open Access:** This is an open-access article distributed under the terms of the Creative Commons Attribution-NonCommercial 4.0 International License (CC BY-NC 4.0)

**AIM:** The aim of this study is to present severe root resorption following obturation of the primary molar with zinc oxide eugenol (ZOE) at different follow-up periods.

**CASE REPORT:** We present the case of a 6-year-old boy with decayed lower primary molars. Pulpectomy for pulpally involved primary molars was performed. ZOE has been used as root canal filling material and follow-up was done at 3, 6, and 9 months.

**CONCLUSION:** External root resorption was detected at 3 months and the resorptive process continued till 9 months. This finding emphasizes the need for alternative filling material with less irritating properties.

## Introduction

Dentists providing restorative care for children will typically face situations where a primary tooth has irreversible pulpitis or necrotic pulp [1].

Zinc oxide eugenol (ZOE) is one of the most routinely used materials for root canal filling in deciduous teeth. However, animal studies with ZOE as an obturating material have reported inflammatory reactions [2].

This case report reveals severe root resorption in primary molars obturated with ZOE at different follow-up periods (3, 6, and 9 months).

## Case Report

### *Patient information and clinical findings*

A 6-year-old boy presented to the outpatient clinic of the Department of Pediatric Dentistry, Faculty

of Dentistry, Cairo University, with a chief complaint of pain related to the lower left molar area that continued when the cause was removed, and it was spontaneous in nature. The patient was medically healthy and had no previous dental history.

### *Diagnostic assessment*

Pain history was recorded. Clinical and radiographic examinations showed badly decayed lower first and second primary molars. The initial diagnosis was irreversible pulpitis of the lower primary molars.

### *Therapeutic intervention*

The case was managed by performing pulpectomy to the lower primary molars, where the first and the second primary molar were obturated with ZOE. The teeth were ultimately restored with stainless steel crowns, which were cemented by glass ionomers.

### Follow-up and outcomes

Follow-up was performed clinically and radiographically at 3, 6, and 9 months.

External root resorption was recorded in the second primary molar at 3, 6, and 9 months (Figures 1-4).

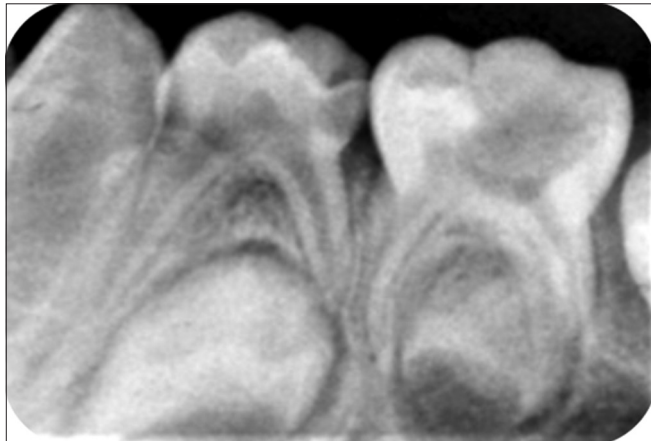


Figure 1: Pre-operative radiograph showing carious lower left first and second primary molars

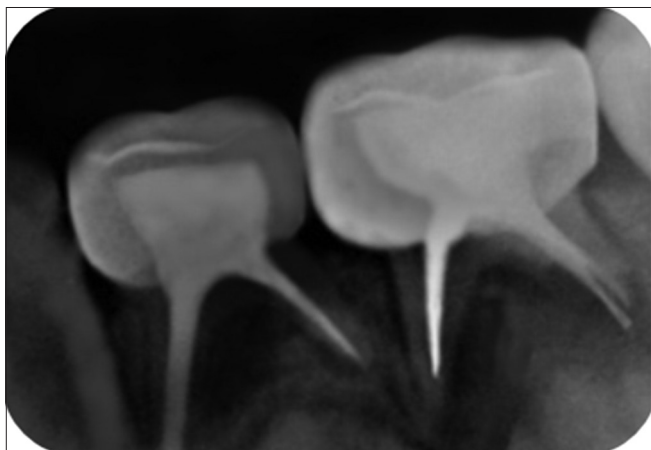


Figure 2: Periapical radiograph at the 1<sup>st</sup> follow-up (3 months)

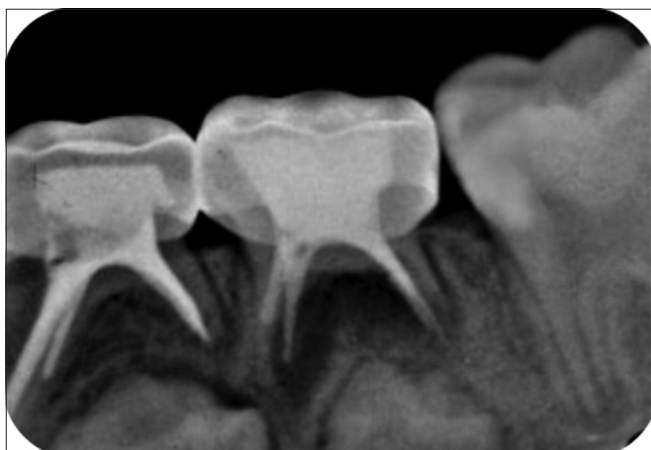


Figure 3: Periapical radiograph at the 2<sup>nd</sup> follow-up (6 months)

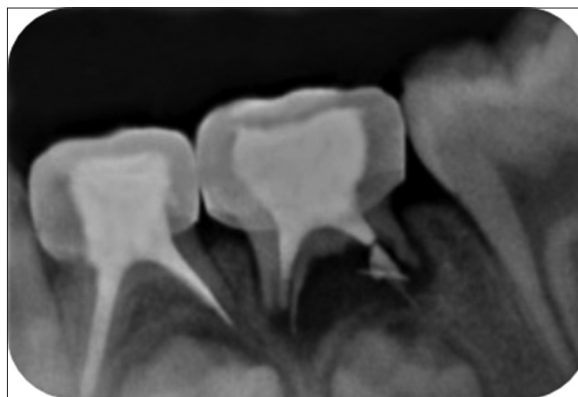

Figure 4: Periapical radiograph at the 3<sup>rd</sup> follow-up (9 months)

### Discussion

ZOE is periapical irritants, and the greatest care should be taken not to push the material past the apex [3]. As discussed by Markowitz *et al.* [4], the pharmacologic reactions of eugenol are likely to be complex and rely on the free eugenol concentration to which the tissue is susceptible. A high concentration appears to have cytotoxic effects, while a low concentration exerts anti-inflammatory activity. The amount of eugenol present in even a small amount of ZOE at the apex may be toxic to bacteria and host cells, causing periapical radiolucency and accelerating root resorption.

### Conclusion

Radiographic assessment of primary teeth obturated with ZOE is mandatory. The outcomes reported herein highlight the need for alternative filling material with less irritating properties.

### References

1. Dummett CO, Kopel HM. Pediatric endodontics. In: Ingle JI, Bakland LK. 5<sup>th</sup> ed. Endodontics. London: B.C. Decker Elsevier; 2002. p. 861-902.
2. Praveen P, Anantharaj. AA, Karthik V, Prathibha RS, Sudhir R, Jaya AR. A review of obturating materials for primary teeth. Streamdent J. 2011;2(1):42.
3. Rewal N, Thakur AS, Sachdev V, Mahajan N. Comparison of endoflas and zinc oxide eugenol as root canal filling materials in primary dentition. J Indian Soc Pedod Prev Dent. 2014;32(4):317-21. <https://doi.org/10.4103/0970-4388.140958> PMID:25231040
4. Markowitz K, Moynihan M, Liu M, Kim S. Biologic properties of eugenol and zinc oxide-eugenol. A clinically oriented review. Oral Surg Oral Med Oral Pathol. 1992;73(6):729-37. [https://doi.org/10.1016/0030-4220\(92\)90020-q](https://doi.org/10.1016/0030-4220(92)90020-q) PMID:1437045