



Bilateral Idiopathic Neuroretinitis

Muhammad Hidayat*

Department of Ophthalmology, Faculty of Medicine, Andalas University, Dr. M. Djamil Hospital, Padang, Indonesia

Abstract

BACKGROUND: Neuroretinitis is a clinical entity characterized by an acute loss of vision associated with disc edema and a star pattern of exudates in the macula. It can be divided into two, those with a specific infectious agent or idiopathic. Most infectious cases are due to cat-scratch disease caused by *Bartonella* species and other infectious agents. Case with a clear infectious is categorized as idiopathic. Most patients with idiopathic neuroretinitis recover excellent visual acuity with or without intervention. Although the presentation is most often unilateral, bilateral cases of neuroretinitis have been reported.

CASE REPORT: A 20-year-old woman with a 2-weeks history of sudden progressive visual loss both eyes (visual acuity: RE 3/60; LE 20/200). The optic disc was edema and the hard exudate on the macular area. Two weeks follow-up, funduscopy shows a macular star and the optic disc's edema was reduced. Perimetric test shows general depressed in both eyes. The blood tests and the brain computed tomography scan were normal. She received methyl prednisolone 48 mg for 2 weeks. Eight months follow-up, VA: RE 20/50, LE 20/40 with the pinhole 20/15 in both eyes. The funduscopy still showed edema and slight paling. There was an improvement in central visual acuity after steroid treatment but leave residual abnormal funduscopy.

CONCLUSION: Neuroretinitis is generally self-limited. The visual acuity recovers excellent with the steroid, but the abnormal disc in this case related to a vaso-occlusive mechanism of prelamin arterioles with subsequent disc infraction.

Edited by: Sasho Stoleski

Citation: Hidayat M. Bilateral Idiopathic Neuroretinitis. Open Access Maced J Med Sci. 2020 Jun 10; 8(C):89-93. <https://doi.org/10.3889/oamjms.2020.3596>

Keywords: Neuroretinitis; Ocular bartonellosis; Cat-scratch disease

***Correspondence:** Muhammad Hidayat, Department of Ophthalmology, Faculty of Medicine, Andalas University Dr. M. Djamil Hospital, Padang, Indonesia.

E-mail: muhammadhidayatspm@gmail.com

Received: 29-Aug-2019

Revised: 17-Apr-2020

Accepted: 20-Apr-2020

Copyright: © 2020 Muhammad Hidayat

Funding: This research did not receive any financial support

Competing Interests: The authors have declared that no competing interests exist

Open Access: This is an open-access article distributed under the terms of the Creative Commons Attribution-NonCommercial 4.0 International License (CC BY-NC 4.0)

Introduction

In 1916, Theodore Leber firstly described a condition where a patient has an acute unilateral vision loss that followed by the swelling of the optic nerve head and exudative maculopathy that formed a star pattern. The symptoms were then called stellate maculopathy because he thought the pathophysiology of the condition is in the retina. In 1977, Gass discovered that the symptom was started by the swelling of the optic nerve head and followed by exudates formed like stars in the macula. Using the fundus fluorescence angiography, he proved that the leakage was not from the perifoveal capillary but as a result of increased permeability in the optic nerve vessels. And because the condition affects both the optic nerve and the retina, the term neuroretinitis was implied [1], [2], [3], [4], [5].

In 1980, Sweeney and Drance reported a relationship between cat scratch disease (CSD) and neuroretinitis that is a self-limited disease affecting the lymphatic system. In 1994, Golnic *et al.* found a serologic prove of *Bartonella henselae* infection as a main infection agent of CSD in neuroretinitis. Since then, many publications reported cases of neuroretinitis that linked to CSD [3], [6], [7].

Neuroretinitis is a result of the inflammation process in the posterior segment of the eye with the

characteristic of optic disc swelling followed by macular star formation usually 7–10 days after the onset of optic disc swelling. Neuroretinitis is a special form of optic neuropathy, characterized by acute vision loss, in one or both eyes without any age or gender predilection, even though this condition is more common in the third or fourth decade of life. The pathophysiology of neuroretinitis is the inflammation of the optic nerve vessels that cause increased permeability of the vessels and as a result, exudation of the fatty liquid into subretinal space and outer plexiform layer of the retina. When the inflammation resolves, the liquid component is reabsorbed and leave the lipid component formed a star-like appearance in the macula [1], [8], [9], [10].

Neuroretinitis is classified by the etiology into infective and idiopathic. Idiopathic neuroretinitis is a diagnosis made when the etiology is not specific after physical and serologic examination [3], [7]. Two-third of neuroretinitis cases is caused by *B. henselae* which is the agent of CSD infection. Neuroretinitis also often confused with papillitis or papilledema if it appear bilateral. The funduscopy manifestation has some similar features and often caused misdiagnosis by ophthalmologists and neurologists [8], [10], [11].

In most cases, neuroretinitis is a self-limited disease, without any tendency of recurrency and has a good prognosis of visual acuity, and followed by the resolution of the optic nerve and the retina. Usually, the

optic nerve will heal in 6–8 weeks, with the manifestation of normal or a little pallor of the optic disc. Whereas, the exudates of the macula will heal more slowly, started in a couple to 6–12 weeks [2], [3], [11]. In this paper, reported a case where a patient has a history of bilateral neuroretinitis 8 months ago with a good central visual outcome and incomplete resolution of the optic nerve head and peripheral visual field.

Case Report

A 20-year-old female patient came to the Ophthalmology Clinic of M. Djamil Hospital with chief complaint decreased vision since 8 months ago. The decreased vision is persistent since 8 months ago. The patient first came for a spectacle prescription. From the medical record, we got the information that the patient has come 8 months ago to the clinic, with the complaint of the sudden loss of vision in both eyes, without any pain when moving the eyeballs, fever, pain in joints, and vomiting or nausea. There is no history of any medication.

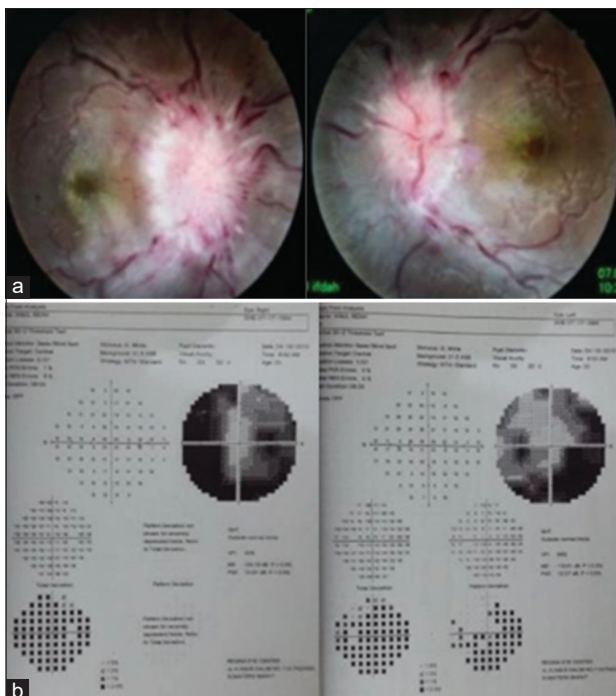


Figure 1: Fundus photograph (a) and perimetry (b) on the first visit

There is no history of hypertension and diabetes. There is no history of contact with felines. At the time, the visual acuity was 3/60 in the right eye, and 20/200 in the left eye. Funduscopy examination revealed that both of the optic disc were swollen. Blood work and brain computed tomography (CT) scan examination was in normal limit. The patient was given methylprednisolone 1 × 48 mg orally (0.8 mg/kg) for 2 weeks. In the follow-up, there was improvement of visual acuity, 20/200 in the right eye, and 20/100 in the left eye. In the funduscopy examination, the resolution of the optic

disc revealed swelling and macular star appearance of both eyes. The patient was then consulted to vitreo retina subdivision, with the result neuroretinitis, dd/hypertensive retinopathy KW IV. The patient also consulted to internal disease division, with the result no risk factor of systemic disease. The patient did not come for follow-up after that.

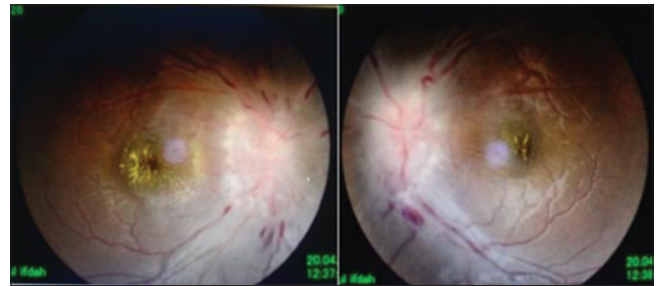


Figure 2: Fundus photograph after 2 weeks of oral steroid

Now, the visual acuity of the patient is 20/50 in the right eye and 20/40 of the left eye, and becomes 20/25 by pinhole. In the funduscopy examination, the optic discs appear slightly atrophy, with vague boundaries and decrease foveal reflex in both eyes. Perimetry examination reveals a peripheral scotoma in both eyes. Brain CT scan result is in normal limit. Figures 1-3 shows improvement of the case before and after therapy.

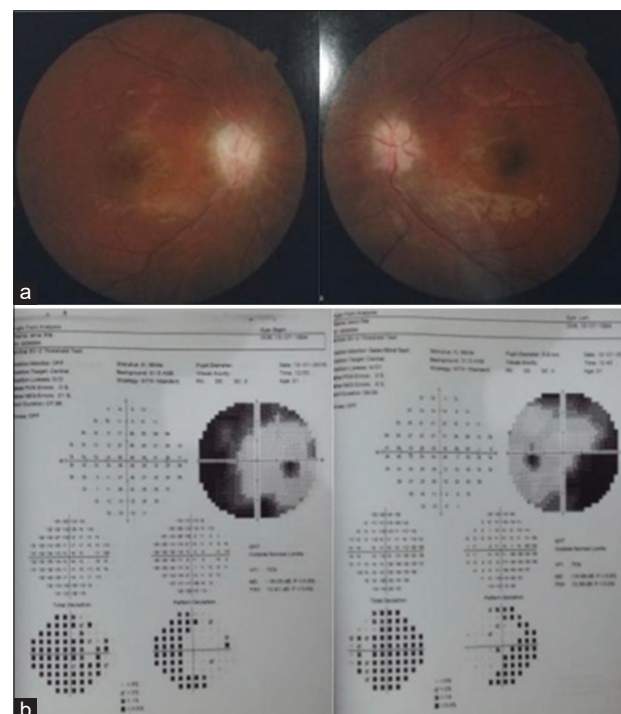


Figure 3: Latest fundus photograph (a) and perimetry (b)

Discussion

Neuroretinitis is a special form of optic neuropathy with the characteristic of acute visual loss, and swelling of optic nerve head with hard exudates

around the macula with the star-like appearance (macular star). In most cases, this condition occurs unilateral, but in 5–30% cases occur bilateral. Neuroretinitis can affect all individuals in all groups of age, but most commonly happen in the third and fourth decade of life, without any predilection of gender [2], [9], [10], [11], [12], [13].

Neuroretinitis is classified by the etiology into infective and idiopathic. Idiopathic neuroretinitis is then divided into single episode neuroretinitis and neuroretinitis with recurrence episodes, but there are no clear differences of the two classifications based on clinical appearance. The most commonly used classification is idiopathic neuroretinitis, infective neuroretinitis associated with CSD, and recurrent neuroretinitis [1], [14].

Two-third of all neuroretinitis cases reported are caused by *B. henselae* infection which is infective agent of CSD. The prevalence of CSD varies, affected by climate and geographic factor. The diagnosis of CSD requires a specific examination toward the *B. henselae* antibody. Neuroretinitis has also been linked to a viral infection such as herpes simplex, encephalitis, and hepatitis B virus. Other infections such as syphilis, Lyme disease, and toxoplasmosis are also associated to neuroretinitis (Table 1). Idiopathic neuroretinitis is diagnosed when there is no certain specific etiology found in the physical and serology examination [1], [11], [13], [15].

Table 1: Etiology of neuroretinitis [13]

Idiopathic: Leber stellate neuroretinitis (25%)
Infection:
1. <i>Bartonella henselae</i> (cat-scratch disease): most common (60% of all cases)
2. <i>Toxoplasma gondii</i> (toxoplasmosis)
3. <i>Treponema pallidum</i> (syphilis)
4. <i>Borrelia burgdorferi</i> (Lyme disease)
5. <i>Leptospira</i> spp. (leptospirosis)
6. <i>Mycobacterium tuberculosis</i> (tuberculosis)
7. <i>Histoplasma capsulatum</i> (histoplasmosis)
8. <i>Rickettsia typhi</i> (murine typhus)
9. <i>Brucella</i> spp. (brucellosis)
10. Viral: HIV, Varicella-zoster virus, herpes simplex virus, hepatitis B or C virus (rare)
11. Nematodes: Diffuse unilateral subacute neuroretinitis
Parainfection (immune mediated).

Some non-infection and non-inflammation conditions can manifest like neuroretinitis and with the sign of optic nerve head swelling followed by macular edema with the macular star appearance (Table 2). Those conditions are papilledema, anterior ischemic optic neuropathy (AION), and tumor infiltration to the optic nerve. Some retinal inflammation also has the neuroretinitis signs, such as idiopathic retinal vasculitis, aneurysm, and neuroretinitis syndrome and diffuse unilateral subacute neuroretinitis. Systemic hypertension can also give the manifestation of optic disc swelling and macular star that resolves after the blood pressure

Table 2: Differential diagnosis of optic nerve swelling with a macular star appearance

1. Hypertensive retinopathy
2. Papilledema
3. AION
4. Diabetic papillopathy
5. Branch retinal vein occlusion, central retinal vein occlusion, papillophlebitis
6. Optic disc tumor: Melanocytoma, juxtapapillary angioma
AION: Anterior ischemic optic neuropathy.

is controlled. The optic nerve swelling in a patient with a systemic vascular disease such as diabetes and hypertension can be distinguished by neuroretinitis because there are no sudden visual loss and history of a certain systemic condition. Spontaneous resolution of the optic nerve swelling followed by improvement in visual acuity after the systemic condition is controlled also distinguished neuroretinitis from this condition [3], [9], [13], [15].

Clinical manifestation of neuroretinitis is specific and different from other neuropathies. In most cases, there are no pains, but some patients can complain dullness when moving the eyeball like the patient with optic neuritis. The patient usually come with the sudden decrease of visual acuity, with the range of 20/20 to light perception, which commonly caused by the macular edema. If the neuroretinitis is caused by infection, signs of flu-like syndrome can occur, such as fever, malaise, or headache. Relative afferent pupillary defect (RAPD) is found except when it occurs bilateral. Visual field defects usually central or cecocentral scotoma, but arcuate and altitudinal scotoma can also occur [1], [8], [11].

In the funduscopy examination, the optic nerve head appears swollen. In severe cases, it can be accompanied by splinter hemorrhages. The degree of macular edema varies from mild to severe; depend on the time the patient firstly examined. Macular star, which is formed by lipid component (hard exudates), is usually not found in the first examination until 1–2 weeks after the patient complaint the vision loss worsens and the optic nerve head swelling is resolved [1], [8], [16].

The pathogenesis of neuroretinitis is the process of infection or inflammation that directly affects the optic nerve, causes the swelling and exudation of liquid from the inflammation area to the retina as a result of leakage in the peripapillary capillary vessels, with the distribution of leakage from the optic nerve papilla to the outer plexiform layer of the retina in the parafovea (Henle's layer). The serious component of the liquid in the Henle's layer will then reabsorbed, while the lipid component will sediment and form the macular star appearance. The macular star appearance usually appears after 1 until 2 weeks after the optic nerve swelling occurs or after the optic nerve swelling resolve. Hence, it is important that the patient with acute optic disc swelling with a normal macula to come for follow-up in 1–2 weeks to define if there is the macular star, because the macular star is essential for diagnostic and prognostic of the disease [4], [5], [16].

In this case report, the patient comes for a spectacle prescription. The vision of both eyes is blurry since months ago. From the medical record of 8 months ago, the patient has come to the clinic with the complaint of sudden vision loss without any pain when moving the eyeball, no fever, and at this moment, the vision has not worsened. From the ophthalmology examination, the visual acuity of the right eye is 3/60,

and left eye is 20/200, with the presentation of bilateral optic nerve head swelling which is thought as a result of increasing intracranial pressure or acute optic neuropathy in both eyes. Some diagnostic procedure is then performed. Perimetry examination reveals a wide scotoma (general depressed) and laboratory finding is within the normal limit as well as brain CT scan. The patient is given therapy of methylprednisolone 1 × 40 mg (0.8 mg/kg bw), as an anti-inflammation to protect the optic nerve. In 2 weeks follow-up after steroid therapy, the visual acuity is 20/200 OD and 20/100 OS, and in funduscopy examination, the optic nerve swelling is resolved and the macular star appears, so the diagnosis neuroretinitis was made. Antibiotics are not given to the patient because the laboratory finding is in normal limits and also because the patient did not come for follow-up after that. Eight months later, the patient comes to the clinic and the central visual acuity has improved, 20/50 right eye and 20/40 in the left eye and can be 20/25 by pinhole for both eyes.

Bilateral neuroretinitis is a rare case that can cause by misdiagnosis with other conditions such as malignant hypertension, increasing of intracranial pressure, or specific infection caused by *Bartonella*, Lyme disease, mumps, syphilis, toxoplasmosis dengue, and chikungunya [1], [10], [13]. In this case, some examinations were performed, laboratory of blood for infection and brain CT scan to exclude intracranial causes. The patients were also consulted to vitreo retina subdivision with the diagnosis of neuroretinitis bilateral and differential diagnose with hypertensive retinopathy KW IV. Then, the patient is consulted to the internal medicine division to search for any condition that related to this case, such as infection and high blood pressure. The result was that there is no abnormality in the internal medicine. The patient is better to undergo another advance examination like serology of *Bartonella* to find if this case is related to CSD infection or an idiopathic case.

The management of neuroretinitis is depending on the infection or inflammation as the main cause. There is no specific treatment in the idiopathic group because this condition is a self-limited disease, but some study suggests a steroid treatment. Some literatures said that the patient with bilateral neuroretinitis, young age, severe visual loss, and severe visual field defect can be considered given steroid to prevent recurrency. Other studies suggest that bilateral neuroretinitis can be given broad-spectrum antibiotics even when the serology examination of CSD is not out yet. The patient with neuroretinitis related to CSD is treated with a combination of antibiotics (clindamycin, ciprofloxacin, trimethoprim-sulfa, or tetracycline) and anti-inflammation (prednisolone and dexamethasone) and in most cases has a good prognosis of visual acuity. The newest study reports that doxycycline and rifampicin can shorten the course of the disease and accelerate the visual improvement [1], [5], [7], [8], [14], [17].

Neuroretinitis is a self-limited disease with a good prognosis of the visual acuity. The diffuse optic nerve head swelling resolve started in the 2nd week and will completely resolve in 2–3 months and the optic nerve will appear normal. In small cases, the optic nerve head will appear, such as peripapillary gliosis and atrophy. The exudates of the macula tend to resolve slower than the optic nerve head swelling, usually in several months after onset until a year later. After the resolution, the defect of the retinal pigment epithelium can be seen in the area where the lipid exudates previously appear in the macula. Dreyer *et al.* report that in 27 patients with neuroretinitis, 97% achieve a visual acuity better than 20/40 after 8 weeks after onset, while 3% suffer a severe decrease of vision (<20/400). Maitland and Miller report the final visual acuity of 12 patients with the range follow-up of 1 month to 2 years, where 13 eyes achieve visual acuity better than 20/50. However, in 3 eyes, the visual acuity is worse than 20/200. This means that a small percentage of patients with neuroretinitis will suffer from severe vision disability. In the first presentation, the patient usually comes with poor visual acuity and significant visual field defect, with relative afferent papillary defect if occur unilateral. However, patients with poor visual acuity still can achieve normal or near-normal visual acuity in the later follow-up.

In this case, the presentation in the 8 months after onset is different from most literature which is said that the optic nerve swelling will spontaneously heal. The patient did have a better central visual acuity which is 20/50 OD and 20/40 OS and can be 20/25 with pinhole even though the perimetry examination reveals peripheral visual field defect. In the funduscopy examination, the optic nerve head appears atrophy with vague boundary in both eyes and perfectly resolved macular star. The process of optic nerve head swelling related to neuroretinitis is the result of restrain of axoplasmic flow in the optic disc due to inflammation or infection and when the inflammation and infection are controlled, the optic disc will spontaneously resolve. However, in rare cases, the optic disc remains swollen, maybe because vaso-occlusive mechanism of prelaminar arterioles that are settle due to optic disc infarction or due to peripapillary gliosis formation or due to severe inflammation. After resolution, the retinal pigment epithelium defect can be seen in the area where the lipid exudate previously seen in macula [5], [8], [11], [18], [19].

Other visual function such as color vision and contrast sensitivity also reveals a normal result. This condition differs from neuritis optic cases wherein 75% to 93% can achieve a visual acuity better than 20/40, but the color vision deficiency usually persists in 56–84% patients and in the 67–100 patients, the contrast sensitivity remains abnormal [9], [19].

Most patients with neuroretinitis have a different clinical profile which characterized with permanent visual field defect linked to disc abnormality, RAPD, and pupil reflect abnormality and poor visual acuity.

These conditions can be caused by recurrent episodes in the same eye. The etiology of recurrent neuroretinitis is still not fully understood, but some researchers said that it from autoimmune factors [17]. In this patient, it is thought that the case is not a recurrent neuroretinitis, based on the history where she said that the vision is persistent since the onset. This patient undergoes a second brain CT scan examination to make sure; there are no systemic factors that underlie optic disc abnormality at the current moment.

Long-time prognosis of neuroretinitis is good, but in some individuals can suffer mild optic neuropathy post-infection. Patients with secondary neuroretinitis due to syphilis have to be treated with intravenous penicillin and patients with Lyme disease also have to be treated with proper antibiotics such as ceftriaxone, amoxicillin, or tetracycline. Even though optic neuritis is a risk factor for multiple sclerosis, neuroretinitis is not associated with multiple sclerosis, and the ratio of prevalence of multiple sclerosis in the neuroretinitis patients is the same as in the normal population, 6–80/100.000 [9], [15], [20].

References

- Purvin V, Sundaram S, Kawasaki A. Neuroretinitis: Review of the literature and new observations. *J Neuro Ophthalmol*. 2011;31:58-68. <https://doi.org/10.1097/wno.0b013e31820cf78a> PMID:21317731
- Lee AG, Brazis PW, Mughal M. Optic Disc Edema with a Macular Star Figure. *Emergencies in Neuroophthalmology*. Florida: Mayo Foundation for Medical Education and Research; 2010. p. 127-31.
- Narayan SK, Kaliaperumal S, Srinivasan R. Neuroretinitis, a great mimicker. *Ann Indian Acad Neurol*. 2008;11(2):109-13. <https://doi.org/10.4103/0972-2327.41879> PMID:19893649
- Lee AG, Brazis PW. Optic Disc Edema with a Macular Star and Neuroretinitis. *Clinical Pathways in Neuro Ophthalmology*. New York: Thieme; 2003. p. 63-70. <https://doi.org/10.1055/b-0034-50835>
- London NJ, Cunningham ET. *Neuroretinitis Intraocular Inflammation*. Berlin: Springer; 2016.
- Golnik K, Marotto M, Fanous M, Heitter D, King L. Ophthalmic manifestations of *Rochalimaea* species. *Am J Ophthalmol*. 1994;118(2):145-51. <https://doi.org/10.1097/00041327-199512000-00012> PMID:8053459
- Cunningham ET, Koehler JE. Ocular bartonellosis. *Am J Ophthalmol*. 2000;130(3):140-6. PMID:11020414
- Srinivasan R, Kaliaperumal S. Neuroretinitis review. *Kerala J Ophthalmol*. 2006;18(1):7-13.
- Cantor LB, Rapuano CJ, Cioffi GA. The Patient with Decreased Vision: Classification and Management. *Neuro ophthalmology*. San Francisco: American Academy of Ophthalmology; 2016-2017. p. 116-33.
- Gubianas V, Lopez R, Torres L, Garcia T, Penalver M. Neuroretinitis. *Clin Case Arch Soc Espanyola Ophthalmol*. 2009;84:389-94.
- Saatci AO, Oner FH, Kargi A, Kavukcu S. Unilateral neuroretinitis and per ipalillary serous retinal detachment in cat scratch disease. *Korean J Ophthalmol*. 2002;16:43-6. <https://doi.org/10.3341/kjo.2002.16.1.43> PMID:12162517
- Stewart MW, Brazis PW, Barrett KM, Eidelman BH, Mendez JC. Optical coherence tomography in a case of bilateral neuroretinitis. *J Neuroophthalmol*. 2005;25:113-31. <https://doi.org/10.1097/01.wno.0000165106.85989.1d>
- Kaliaperumal S, Narayan S. Neuroretinitis: Update on a visual emergency and role of technology in its diagnosis. *J Biomed Sci Eng*. 2013;6:15-9.
- Nartey A. Neuroretinitis: A case report of a 16-year old high school student. *Adv Ophthalmol Visual Syst*. 2017;7(4):1-3. <https://doi.org/10.15406/aovs.2017.07.00226>
- Kahloun R, Khairallah-Ksiaa I, Abroug N, Mahmoud A, Yahia SB, et al. Final Diagnosis in patients referred with a diagnosis of neuroretinitis. *Neuro Ophthalmol*. 2015;39(6):266-70. <https://doi.org/10.3109/01658107.2015.1092561> PMID:27928367
- Schiefer U, Wilhelm H, Hart W. Optic disc signs and optic neuropathies. In: *Clinical Neuro Ophthalmology, A Practical Guide*. Germany: Springer; 2007. p. 115-6. https://doi.org/10.1007/978-3-540-32708-0_8
- Purvin V, Ranson N, Kawasaki A. Idiopathic recurrent neuroretinitis. *Arch Ophthalmol*. 2003;121:65-7.
- Liu GT, Volpe NJ, Galetta SL. Optic disc swelling: Papilledema and other causes. *Neuro Ophthalmol*. 2010;1:198-299.
- Chan JW. Papilledema. In: *Optic Nerve Disorders, Diagnosis and Management*. USA: Springer; 2007. p. 62-80.
- Williams K, Johnson L. Neuroretinitis in patients with multiple sclerosis. *Ophthalmology*. 2010;111(2):335-40. PMID:15019385