

Outcomes of Intravitreal Methotrexate to Salvage Eyes with Relapsed Primary Intraocular Lymphoma.

Mona Mohammad,^{1,2} Richard M. Andrews,^{3,4} P. Nicholas Plowman,⁵ Gordon Hay,^{1,4} Amit K. Arora,^{1,4} Victoria M.L. Cohen,^{1,4} Mandeep S. Sagoo,^{1,3,4,6}

1. Ocular Oncology Service, Moorfields Eye Hospital, London, UK
2. Ocular Oncology Service, King Hussein Cancer Center, Amman, Jordan
3. Medical Retina Service, Moorfields Eye Hospital, London, UK
4. NIHR Biomedical Research Centre for Ophthalmology at Moorfields Eye Hospital and UCL Institute of Ophthalmology, London, UK.
5. Department of Medical Oncology, St. Bartholomew's Hospital, London, UK
6. UCL Institute of Ophthalmology, London, UK.

Presented in part at the 52nd Annual Scientific Meeting of the Retina Society, London, UK, September 2019

Correspondence:

Prof Mandeep S. Sagoo

Moorfields Eye Hospital, City Road, London, EC1V 2PD, UK

Tel: 020 72533411

Email: m.sagoo@ucl.ac.uk

The research was supported by the National Institute for Health Research (NIHR) Biomedical Research Centre based at Moorfields Eye Hospital NHS Foundation Trust and UCL Institute of Ophthalmology. The views expressed are those of the authors and not necessarily those of the NHS, the NIHR or the Department of Health.

Keywords: primary intraocular lymphoma, vitreoretinal lymphoma, intravitreal methotrexate, radiotherapy

ABSTRACT

Purpose: To report the outcomes of intravitreal methotrexate (MTX) injections to rescue eyes with relapsed primary vitreoretinal intraocular lymphoma (PIOL).

Methods: Retrospective case series of patients with ocular relapse of PIOL who had initially received systemic chemotherapy (all 5 cases) and external beam radiotherapy (EBRT) to the brain and orbits (2 cases). Injections of MTX (400 µg/0.1ml) were given through the pars plana into vitreous cavity once weekly for one month, then every other week for 4 months, followed by a maintenance phase of one injection monthly for 8 months (total of 20 injections in a year).

Results: From April 2008 to February 2016, there were 9 eyes of 5 patients (3 males, 2 females; average age at first presentation 62 years, range 53-68 years) treated with our rescue protocol of intravitreal MTX injections. Ocular relapse occurred at a mean interval of 15 months (range 5-34 months) after the completion of initial systemic treatment. At mean follow-up of 31 months (range 5-104 months), tumour control was achieved in 8 out of 9 eyes (89%); 1 eye failed, with persistent retinal infiltrates despite of increasing the frequency of injections, resulting in severe keratopathy. The only other complication occurred in 1 eye, developing cystoid macular oedema from MTX injections that resolved with topical anti-inflammatory medications and reduced frequency MTX. There were no cases of reduced vision or ocular relapse, but 2 patients died (1 of CNS lymphoma).

Conclusions: Intravitreal methotrexate was found to be a safe and effective treatment modality for relapsed PIOL after systemic chemotherapy and radiotherapy, achieving local tumour control in 89%, and hence represents an optimal choice. However, given the rare nature of PIOL, larger collaborative studies with longer follow up are needed to corroborate this.

Introduction

Primary intraocular lymphoma (PIOL) is a subtype of primary central nervous system lymphoma (PCNSL). PCNSL is an aggressive high-grade non-Hodgkin's lymphoma (NHL) usually of B-cell type. Eye involvement, which is mainly vitreoretinal, is considered part of multi-focal nature of CNS disease.[1] Around one third of PIOL patients will have CNS disease at presentation, and more than half will develop CNS disease later during the course of the disease.[2 3] This close association between eye and CNS disease should alert the clinician to at least screen and possibly treat prophylactically, though variations in practice exist.

Diagnosis of PIOL needs a high index of suspicion as this disease often masquerades as infectious or inflammatory uveitis. [2 4] Newer imaging modalities, such as optical coherence tomography[5 6] and autofluorescence [7 8] are useful in differentiating lymphoma from the latter, but tissue sampling is necessary for substantiating the diagnosis. Aqueous fluid, cytology from a vitreous tap or vitreoretinal biopsy are utilised to make the diagnosis from pathological techniques such as interleukin (IL) IL10-IL6 ratio, cytology, polymerase chain reaction and flow cytometry. [9 10] There has been recent attention on MyD88 gene mutations, which have been found in PIOL. [11] [12]

Initial treatment at diagnosis can be with intravitreal methotrexate (MTX) if only the eyes are involved [13] or systemic MTX and cytarabine based chemotherapy to treat the affected organs and as prophylaxis against fellow eye and brain involvement [14] [14] with or without external beam radiotherapy. [15] Our approach is based on the latter, but despite this relapse can occur in the eyes, brain or both.

Systemic or neurological relapse prompts second line chemotherapy or even stem cell bone marrow rescue protocols, [16] but it is questionable whether ocular only relapse should prompt second line systemic therapy in favour of intravitreal treatments. Herein we describe our results for the management of a select group of patients to try to answer this. We report the outcomes of intravitreal methotrexate injections in cases where relapse occurred exclusively in one or both eyes after initial systemic treatment with chemotherapy +/- EBRT to the brain and orbits.

Methods

Patients presenting to the London Ocular Oncology Service between 1 April 2008 and 28 February 2016 were included. The study was registered and approved by the Research Department of Moorfields Eye Hospital and adhered to the tenets of the Declaration of Helsinki. Inclusion criteria were patients with known PIOL treated initially with methotrexate-based high dose systemic chemotherapy +/- external beam radiotherapy to brain and orbit inducing remission and who presented during follow up with ocular only relapse of PIOL.

All patients had systemic work-up at the time of relapse including brain magnetic resonance image (MRI), whole body positron emission topography computed topography (PET-CT scan) and bone marrow biopsy or lumbar puncture where indicated. If patients were found to have relapse outside of the eye they were excluded from the study. Patients ocular relapse but with ≤ 3 months of follow-up were also excluded. Five patients were found to fulfil the inclusion criteria for the study.

Comprehensive chart review of each patient allowed collection of the following data: patient age, sex, medical history, presenting ocular symptoms and signs, diagnosis by biopsy, first treatment(s) given, presence of PCNSL in relation to PIOL, PIOL recurrence and timing, intravitreal MTX injection details, changes in visual acuity, intraocular pressure readings, and clinical status at last follow-up visit.

Our rescue protocol for intraocular injections for ocular only relapse was intravitreal MTX 0.4mg in 0.1 ml injected through the pars plana using standard aseptic technique at a frequency of:

in the first month – one injection every week

in the subsequent 4 months – one injection every 2 weeks

and the final 8 months – one injection every 4 weeks.

The full course of treatment was a total of 20 injections over 13 months.

Results

Over an 8-year period there were 5 patients that met the inclusion criteria of ocular only relapse following systemic treatment of PIOL. **Table 1** summarizes the demographic, clinical features of the study patients at first presentation and during relapse, associated CNS disease, treatments given, and the state of the eye at last follow-up. The average age at first presentation was 62 years (range 53-68 years). Three patients were male, and two were female.

At first presentation 3 patients had bilateral PIOL and 2 patients unilateral (left eye in both). The main presenting symptoms included reduced vision in 2 patients, floaters in 1 patient and reduced vision and floaters in 2 patients. All patients had vitritis, and 2 patients had associated pale retinal infiltrates. Diagnosis was confirmed by vitreous biopsy through pars plana vitrectomy for 3 patients, 1 patient (# 5) was already known to have PCNSL 12 months before presenting with typical signs and symptoms of PIOL, and in the other patient (#3) diagnosis was confirmed from biopsy of nasopharyngeal lesion found on PET-CT scan. The lag time between first visit to clinic and obtaining definitive diagnosis was 1 day to 18 months. Systemic work-up included brain MRI and whole-body PET-CT scan.

CNS lymphoma was diagnosed 12 months before ocular diagnosis in 1 patient (#5), and subsequent to ocular diagnosis in 2 patients (#2 and 3); both patients had CNSL 17 months after PIOL. Two patients in our study did not develop CNSL during the course of their follow-up. Treatment after initial diagnosis was high dose cytarabine and MTX-based systemic chemotherapy as per the protocol of Ferrari et al.[17] (5 patients) +/- EBRT to brain 30 Gy and the orbits to 40 Gy, delivered in 2Gy daily fractions (2 patients: #1 and #2).

All patients were subsequently followed routinely for the clinical recurrence of brain and eye disease. The time to PIOL relapse after initial treatment was a mean of 15 months (range 5-34 months). On diagnosis of relapsed PIOL systemic re-staging was initiated to exclude systemic lymphoma. If the only affected organ was the eye, local therapy with intravitreal MTX injections was offered.

The pattern of ocular only relapse was bilateral in all 5 cases. However, one involved eye (patient # 3) had developed phthisis bulbi, so was observed rather than treated with intravitreal MTX injections. In total 9 eyes were given intravitreal MTX injections, with an induction phase (1 injection per eye every week for 4 weeks), followed by a consolidation phase (1 injection per eye every 2 weeks for 4 months) and a maintenance phase (1 injection per eye every 4 weeks for 8 months) giving a total of 20 injections during the 13 month treatment period.

Tumour control was achieved in 8 out of 9 eyes (89%) treated in this protocol. One patient (# 4) had responded well in the right eye but there was a poor response in the left eye during the course of intravitreal injections. New retinal infiltrates developed, and the frequency of injections was increased. Despite a total of 44 injections local tumour control could not be achieved and EBRT was added.

Another case (patient #2) developed new onset neurological symptoms after the fifth intravitreal MTX injection. Brain MRI showed new onset PCNSL. Despite the 5 intravitreal injections controlling the ocular relapse, the onset of PCNSL initiated second line high dose systemic chemotherapy with autologous stem cell rescue. No more injections were given for this patient and no further ocular relapses occurred during the 104 months follow up. The remaining 3 patients completed the full 20- injection protocol.

Examination at each visit included visual acuity, intraocular pressure measurement (IOP) pre- and post-injection and fundoscopy to assess response to treatment as evidenced by the disappearance of vitreous cells and regression of retinal infiltrates. **Figure 1**

The changes in visual acuity during relapse and the phases of induction, consolidation and maintenance with intravitreal MTX and at last follow up are charted in **Figure 2**. At last follow-up visit, there were no cases of loss of vision. In total, six out of nine treated eyes showed improvement in measured visual acuity, the remaining three eyes demonstrated stable visual acuity. In one case (#3), there was a reduction of vision after the 5th intravitreal methotrexate injection in the right eye due to development of cystoid macular oedema, clinically and on OCT scan. There were no other clinical signs of uveitis, but a course of topical steroids and non-steroidal anti-inflammatory eye drops regressed the oedema. The intravitreal MTX injections

were continued, the oedema subsided after injection number 15, and the vision improved.

Figure 3.

Due to the 0.1 ml injection volume a transient rise in IOP was noted after each injection, but usually within the normal range. Only 1 eye had a rise of IOP up to 29 mmHg and this rise was transient. None of the treated eyes had persistent increase in IOP. The only other side-effect was a severe keratopathy in one eye (patient #4, left eye). This eye was resistant to treatment so required increased frequency of injections. During the 44 injections her symptoms were controlled with topical lubricant eye drops. Other patients had very mild keratopathy symptoms, mainly during the weekly injection induction phase. There were no cases of endophthalmitis, vitreous haemorrhage, or retinal detachment.

After mean follow-up time of 31 months (range 5-104 months) 2 patients had died (one of PCNSL, the other had no CNS disease), 2 patients were alive with inactive PCNSL, and 1 was alive without development of PCNSL. All patients had no signs of ocular relapse at the final eye examination.

Discussion

There are many challenges in the management of PIOL. From initial diagnosis, due to its ability to masquerade, to primary treatment, local or systemic, this is a tumour shrouded in controversy. It is a rare cancer but has an increasing incidence. In this report we share our experience of our protocol of intravitreal methotrexate for ocular only relapse after primary systemic treatment.

Treatment of PIOL has evolved from enucleation, to radiotherapy alone, systemic chemotherapy alone, then a combination of both modalities. Berenborn et al reported their outcomes for 12 patients with PIOL, who were treated by either chemotherapy alone radiotherapy alone or a combination, they found that none of the patients who received radiotherapy had ocular relapse (30-35 Gy in 15 fractions) during a mean follow-up of 19 months, and they valued the role of external beam radiotherapy within first line treatments for PIOL.[15] As indications for radiotherapy for other eye tumours such as retinoblastoma[18] and circumscribed choroidal haemangiomas[19] wane, it is important that external beam

radiotherapy capabilities are maintained in linear accelerator facilities for tumours such as lymphoma.[20] [21]

Non-Hodgkin's large B cell lymphoma is a chemosensitive and radiosensitive tumour, but in the case of CNS and eye involvement there are limitations. One limitation is drug availability due to the blood brain-barrier (BBB) and blood retinal-barrier (BRB), requiring higher doses and multiple agents, with associated local and systemic toxicities. One combination of drugs can induce resistance, so that relapse requires a second line more toxic combination. [16] [22] The second limitation is that radiotherapy to the brain and eye is associated with CNS and ocular complications. Brain radiotherapy can cause neurotoxicity and cognitive impairment, especially in elderly patients. [23] Ocular complications of radiation include dry eyes, cataract, and radiation retinopathy. [15] In practical terms this means that radiotherapy can only be given once.

These limitations have spurred the development of local treatments. Intravitreal chemotherapy, mainly using methotrexate or rituximab, has been employed by many centres for first line management of PIOL.[24] In the largest series on the use of intravitreal MTX Frenkel and associates used intravitreal methotrexate as a primary treatment for PIOL of B- and T-cell types and some secondary lymphomas in 44 eyes of 26 patients. As a primary treatment their protocol involved more frequent injections: twice weekly for 4 weeks, weekly for 8 weeks, and then monthly for 9 months, a total of 25 injections. Remission was reached after a mean of 6.4 injections, with 95% of the treated eyes requiring 13 injections or fewer.[13] Side effects included corneal epitheliopathy, which subsided when the interval between injections increased. Given these encouraging results but mindful of the side effect profile, we modified their protocol to the one reported herein for relapsed PIOL, to judge its efficacy and complications.

For primary treatment of PIOL with intravitreal MTX, the tumour response was reported as favourable in 95% of the eyes needing fewer than 13 injections to clear malignant cells. [13] Use of intravitreal MTX for relapsed PIOL has been the subject of a few case reports. *De Smet et al reported a case of a 50-year old female with ocular and CNS lymphoma treated primarily with radiotherapy and systemic chemotherapy. Ocular only relapse occurred after 4 years, treated by repeated intravitreal injections of MTX and thiotepa, inducing remission for 18*

months after the last injection. [25] In other reports the disease-free period in this situation with intravitreal MTX alone has been 6-21 months. [26] [27] In the current study to salvage eyes with relapsed PIOL we found 8 out of 9 eyes (89%) responded. The duration of ocular remission was up to 104 months after the last injection (Table 1); however, the shortest follow-up time of 5 months was due to the death of the patient. We conclude therefore that after systemic treatment ocular only relapse cases should be offered intravitreal MTX. The response is sustained, but follow-up is necessary in case of relapse.

All patients treated with intravitreal MTX injections tolerated treatment well with no serious complications, in keeping with other reports. [24] [28] [13] Reversible keratopathy associated with increased frequency of injections was found in 1 case. In another case there was the unusual situation of cystoid macular oedema, which was treated with topical anti-inflammatory drops. Intravitreal MTX injections were continued and the oedema resolved with improvement in vision. Systemic chemotherapy with blood brain barrier disruption is associated with maculopathy, [29] a phenomenon that has also been found with systemic chemotherapy in primary CNSL. [30] In the latter report some patients received intravitreal MTX as well, but this was not associated with maculopathy. In our case, the cystoid macular oedema occurred when the lymphoma was responding and hence was likely to be induced by intravitreal MTX injections. Furthermore, the CMO was reversible with topical anti-inflammatory drops and therefore this complication should not discourage the ocular oncologist from continuing with the course of intravitreal MTX.

We note the lack of ocular toxicity for two patients who had received prior ocular radiotherapy. This is important as there have been reports of increased brain toxicity when high dose systemic methotrexate has been delivered after brain radiotherapy. [31] Whilst there were only two cases to observe for potential ocular toxicity, this is a topic that must be observed in a larger cohort of patients; our early results in this regard are reassuring. Similarly, there is enhanced brain co-toxicity with intrathecal methotrexate therapy and high dose systemic chemotherapy (of the same intensity as delivered for intraocular lymphoma). It is similarly reassuring from our observations reported here on the safety of intra-ocular methotrexate in patients who have had prior systemic high dose methotrexate.

In our cohort, visual acuity did not deteriorate in any eyes treated with intravitreal MTX. In fact, two-thirds of eyes experienced improved visual acuity. This is important information when counselling patients in this situation.

The limitations of our results relate to the mode of treatment and the small sample size. Delivery of frequent local therapy is challenging, with 20 injections over 13 months. This may limit its use in elderly patients or accessibility in some centres. It is quite possible that a regimen with even fewer injections could be suitably efficacious. In addition, local therapy is unlikely to influence CNS involvement so regular systemic evaluations become necessary to ensure that the ocular only relapse has not progressed. Study specific limitations are the small sample size and relatively short follow-up intervals. As this is a rare scenario of an uncommon tumour, only multicentre studies with standardized protocols will yield further clinical information.

Given these considerations and the rarity of this disease, there is no agreed modality for treatment between different institutions. Even experts in the treatment of PIOL have contrasting views as to the use of systemic versus intravitreal chemotherapy and the role and timing of irradiation, if any. A multimodality approach tailored to disease degree, severity, and performance status of the patient is optimal. In this paper we present our multidisciplinary approach for management of this challenging disease with an algorithm, based on UK guidelines for PCNSL and PIOL. [32] **(Figure 4)** Once the diagnosis is confirmed, a fast track staging process by a medical oncologist (PNP) delineates the extent of the disease by PET/CT scan and MRI scan of the brain and orbits. Our normal protocol is for four cycles of high-dose methotrexate and cytarabine based systemic chemotherapy with radiotherapy to both eyes and depending on the findings and risk of cognitive impairment, to the brain as well. In some cases, only ocular treatment is advised, either with intraocular chemotherapy or radiotherapy or a hybrid of both, depending on the systemic status of the patient. For most cases though, systemic treatment is completed, and then ocular and systemic surveillance occurs. If PIOL relapse occurs without CNS disease then it is our practice to treat with intravitreal MTX injections but if there is systemic involvement on restaging, then second line systemic chemotherapy with bone marrow rescue is the usual modality employed.

We conclude from this series of eyes with ocular only relapse of systemically treated PIOL, that salvage with intravitreal MTX can be achieved in 89%, with low complication rate and 66% chance of improvement in visual acuity.

Figure Legends

Figure 1. Colour fundus photographs of the right eye (patient #5): A. at the time of ocular only relapse showing active vitritis with retinal infiltrates, B. after 4th injection of intravitreal methotrexate demonstrating regression of vitritis and infiltrates and C. at last follow up with clear vitreous and inactive atrophic retinal scars.

Figure 2. Change in visual acuity (decimal visual acuity) for each eye of the 5 patients at time of PIOL relapse, after each phase of MTX injection and at last visit. RE – right eye; LE – left eye.

Figure 3. Optical coherence tomography scans demonstrating the development of cystoid macular oedema (patient #3) during the course of MTX injections (A) after the 5th intravitreal methotrexate injection; (B) response to topical anti-inflammatory medication; and (C) at final follow-up with total resolution of the oedema with improvement in visual acuity.

Figure 4. Algorithm for the management of primary intraocular lymphoma and the role of intravitreal methotrexate for ocular only relapse.

References

1. Sagoo MS, Mehta H, Swampillai AJ, et al. Primary intraocular lymphoma. *Surv Ophthalmol* 2014;**59**(5):503-16 doi: 10.1016/j.survophthal.2013.12.001
2. Cassoux N, Merle-Beral H, Leblond V, et al. Ocular and central nervous system lymphoma: clinical features and diagnosis. *Ocul Immunol Inflamm* 2000;**8**(4):243-50 doi: 10.1076/ocii.8.4.243.6463
3. Freeman LN, Schachat AP, Knox DL, Michels RG, Green WR. Clinical features, laboratory investigations, and survival in ocular reticulum cell sarcoma. *Ophthalmology* 1987;**94**(12):1631-9 doi: 10.1016/s0161-6420(87)33256-7
4. Karma A, von Willebrand EO, Tommila PV, Paetau AE, Oskala PS, Immonen IJ. Primary intraocular lymphoma: improving the diagnostic procedure. *Ophthalmology* 2007;**114**(7):1372-7 doi: 10.1016/j.ophtha.2006.11.009
5. Barry RJ, Tasiopoulou A, Murray PI, et al. Characteristic optical coherence tomography findings in patients with primary vitreoretinal lymphoma: a novel aid to early diagnosis. *Br J Ophthalmol* 2018;**102**(10):1362-66 doi: 10.1136/bjophthalmol-2017-311612
6. Deak GG, Goldstein DA, Zhou M, Fawzi AA, Jampol LM. Vertical Hyperreflective Lesions on Optical Coherence Tomography in Vitreoretinal Lymphoma. *JAMA Ophthalmol* 2019;**137**(2):194-98 doi: 10.1001/jamaophthalmol.2018.5835
7. Ishida T, Ohno-Matsui K, Kaneko Y, et al. Fundus autofluorescence patterns in eyes with primary intraocular lymphoma. *Retina* 2010;**30**(1):23-32 doi: 10.1097/IAE.0b013e3181b408a2
8. Casady M, Faia L, Nazemzadeh M, Nussenblatt R, Chan CC, Sen HN. Fundus autofluorescence patterns in primary intraocular lymphoma. *Retina* 2014;**34**(2):366-72 doi: 10.1097/IAE.0b013e31829977fa
9. Char DH, Kemnitz AE, Miller T. Intraocular biopsy. *Ophthalmol Clin North Am* 2005;**18**(1):177-85, x doi: 10.1016/j.ohc.2004.08.007
10. Whitcup SM, de Smet MD, Rubin BI, et al. Intraocular lymphoma. Clinical and histopathologic diagnosis. *Ophthalmology* 1993;**100**(9):1399-406 doi: 10.1016/s0161-6420(93)31469-7
11. Pulido JS, Salomao DR, Frederick LA, Viswanatha DS. MyD-88 L265P mutations are present in some cases of vitreoretinal lymphoma. *Retina* 2015;**35**(4):624-7 doi: 10.1097/IAE.0000000000000589
12. Cani AK, Hovelson DH, Demirci H, Johnson MW, Tomlins SA, Rao RC. Next generation sequencing of vitreoretinal lymphomas from small-volume intraocular liquid biopsies: new routes to targeted therapies. *Oncotarget* 2017;**8**(5):7989-98 doi: 10.18632/oncotarget.14008
13. Frenkel S, Hendler K, Siegal T, Shalom E, Pe'er J. Intravitreal methotrexate for treating vitreoretinal lymphoma: 10 years of experience. *Br J Ophthalmol* 2008;**92**(3):383-8 doi: 10.1136/bjo.2007.127928
14. Batchelor TT, Kolak G, Ciordia R, Foster CS, Henson JW. High-dose methotrexate for intraocular lymphoma. *Clin Cancer Res* 2003;**9**(2):711-5
15. Berenbom A, Davila RM, Lin HS, Harbour JW. Treatment outcomes for primary intraocular lymphoma: implications for external beam radiotherapy. *Eye (Lond)* 2007;**21**(9):1198-201 doi: 10.1038/sj.eye.6702437
16. Soussain C, Choquet S, Fourme E, et al. Intensive chemotherapy with thiotepa, busulfan and cyclophosphamide and hematopoietic stem cell rescue in relapsed or refractory primary central nervous system lymphoma and intraocular lymphoma: a retrospective study of 79 cases. *Haematologica* 2012;**97**(11):1751-6 doi: 10.3324/haematol.2011.060434
17. Ferreri AJ, Reni M, Foppoli M, et al. High-dose cytarabine plus high-dose methotrexate versus high-dose methotrexate alone in patients with primary CNS lymphoma: a randomised phase 2 trial. *Lancet* 2009;**374**(9700):1512-20 doi: 10.1016/S0140-6736(09)61416-1
18. Fabian ID, Onadim Z, Karaa E, et al. The management of retinoblastoma. *Oncogene* 2018;**37**(12):1551-60 doi: 10.1038/s41388-017-0050-x

19. Papastefanou VP, Plowman PN, Reich E, et al. Analysis of Long-term Outcomes of Radiotherapy and Verteporfin Photodynamic Therapy for Circumscribed Choroidal Hemangioma. *Ophthalmol Retina* 2018;**2**(8):842-57 doi: 10.1016/j.oret.2017.12.002
20. Plowman PN. Radiotherapy and ophthalmology: time for a friendly re-acquaintance. *Br J Ophthalmol* 1992;**76**(5):307-9 doi: 10.1136/bjo.76.5.307
21. Plowman PN, Taylor A, Jackson AS, Lightman S, Pavesio C. Optimal therapy of primary ocular lymphoma. *Clin Oncol (R Coll Radiol)* 2002;**14**(6):521 doi: 10.1053/clon.2002.0154
22. Bessell EM, Hoang-Xuan K, Ferreri AJ, Reni M. Primary central nervous system lymphoma: biological aspects and controversies in management. *Eur J Cancer* 2007;**43**(7):1141-52 doi: 10.1016/j.ejca.2006.12.011
23. Dark F. ECT in a patient receiving prophylactic CNS irradiation for an intraocular lymphoma. *Psychosomatics* 1996;**37**(4):396-8 doi: 10.1016/S0033-3182(96)71557-8
24. Fishburne BC, Wilson DJ, Rosenbaum JT, Neuwelt EA. Intravitreal methotrexate as an adjunctive treatment of intraocular lymphoma. *Arch Ophthalmol* 1997;**115**(9):1152-6 doi: 10.1001/archophth.1997.01100160322009
25. de Smet MD, Vancs VS, Kohler D, Solomon D, Chan CC. Intravitreal chemotherapy for the treatment of recurrent intraocular lymphoma. *Br J Ophthalmol* 1999;**83**(4):448-51 doi: 10.1136/bjo.83.4.448
26. Wang JK, Yang CM, Lin CP, Shan YD, Lo AY, Tien HF. An Asian patient with intraocular lymphoma treated by intravitreal methotrexate. *Jpn J Ophthalmol* 2006;**50**(5):474-78 doi: 10.1007/s10384-005-0327-4
27. Kim E, Kim C, Lee J, Cho Y. A case of primary intraocular lymphoma treated by intravitreal methotrexate. *Korean J Ophthalmol* 2009;**23**(3):210-4 doi: 10.3341/kjo.2009.23.3.210
28. Smith JR, Rosenbaum JT, Wilson DJ, et al. Role of intravitreal methotrexate in the management of primary central nervous system lymphoma with ocular involvement. *Ophthalmology* 2002;**109**(9):1709-16 doi: 10.1016/s0161-6420(02)01125-9
29. Millay RH, Klein ML, Shults WT, Dahlborg SA, Neuwelt EA. Maculopathy associated with combination chemotherapy and osmotic opening of the blood-brain barrier. *Am J Ophthalmol* 1986;**102**(5):626-32 doi: 10.1016/0002-9394(86)90536-2
30. Vicuna-Kojchen J, Frenkel S, Siegal T, Shalom E, Chowars I, Pe'er J. Maculopathy in patients with primary CNS lymphoma treated with chemotherapy in conjunction with blood-brain barrier disruption. *Br J Ophthalmol* 2008;**92**(2):231-5 doi: 10.1136/bjo.2007.130062
31. Abrey LE, DeAngelis LM, Yahalom J. Long-term survival in primary CNS lymphoma. *J Clin Oncol* 1998;**16**(3):859-63 doi: 10.1200/JCO.1998.16.3.859
32. Marcus R, Hodson D, Coupland S, Bessell E, Mead B, Pettitt AR. British Committee for Standards in Haematology. Guidelines on the diagnosis and management of adult patients with primary CNS lymphoma (PCNSL) and primary intra-ocular lymphoma (PIOL). Secondary British Committee for Standards in Haematology. Guidelines on the diagnosis and management of adult patients with primary CNS lymphoma (PCNSL) and primary intra-ocular lymphoma (PIOL). 2009.
<https://citeseerx.ist.psu.edu/viewdoc/download?doi=10.1.1.519.4786&rep=rep1&type=pdf>.

Patient	#1	#2	#3	#4	#5
Age (Years)	62	53	65	62	68
Sex	M	M	F	F	M
Medical History	BPH	Nil	HTN Asthma	HTN Thalassemia	WMD IBD AS
CNS lymphoma	No	Yes, 17 months after PIOL	Yes, 17 months after PIOL	No	Yes, 12 months before PIOL
First presentation	BE vitritis	LE vitritis + retinal infiltrates	LE vitritis and mass on ultrasound	BE vitritis	BE vitritis + RE retinal infiltrates
Vitrectomy	BE	LE	No	BE	No
Time presentation to PIOL diagnosis (months)	18	1	5	2	1 day
First Tx	MTX-based chemotherapy + EBRT brain and orbit	MTX-based chemotherapy + EBRT brain and orbit	MTX-based chemotherapy	MTX-based chemotherapy	MTX-based chemotherapy
Time to eye relapse after first Tx (months)	34	8	15	5	12
Intravitreal MTX	BE 20X	BE 5X	RE 20X LE Phthisis pulbi	RE 20X LE 44X	BE 20X
Follow-up duration after last injection (months)	5	104	20	11	15
Ocular relapse at last visit	No	No	No	No	No
Death	Yes	No	Yes	No	No
<p>AS: ankylosing spondylitis BE: both eyes HTN: hypertension LE: left eye MTX: methotrexate Tx: Treatment</p> <p>BPH: benign prostatic hypertrophy F: female IBD: inflammatory bowel disease M: male RE: right eye WMD: Waldenstrom macroglobulinemia</p>					

Table 1 Patient demographics and treatment of PIOL at first presentation and during ocular relapse in 5 patients

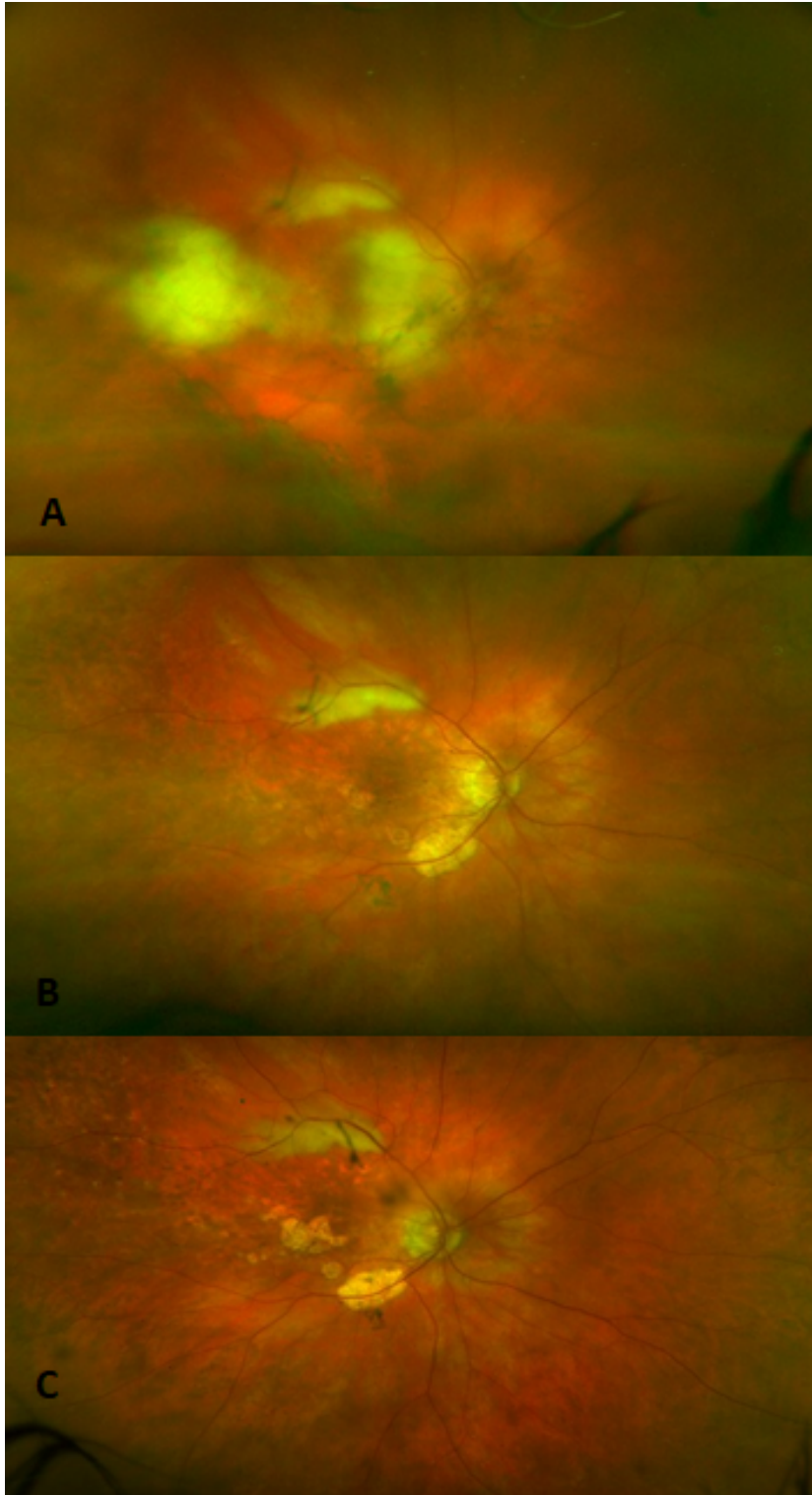


Figure 1. Colour fundus photographs of the right eye (patient #5): **A.** at the time of ocular only relapse showing active vitritis with retinal infiltrates, **B.** after 4th injection of intravitreal methotrexate demonstrating regression of vitritis and infiltrates and **C.** at last follow up with clear vitreous and inactive atrophic retinal scars.

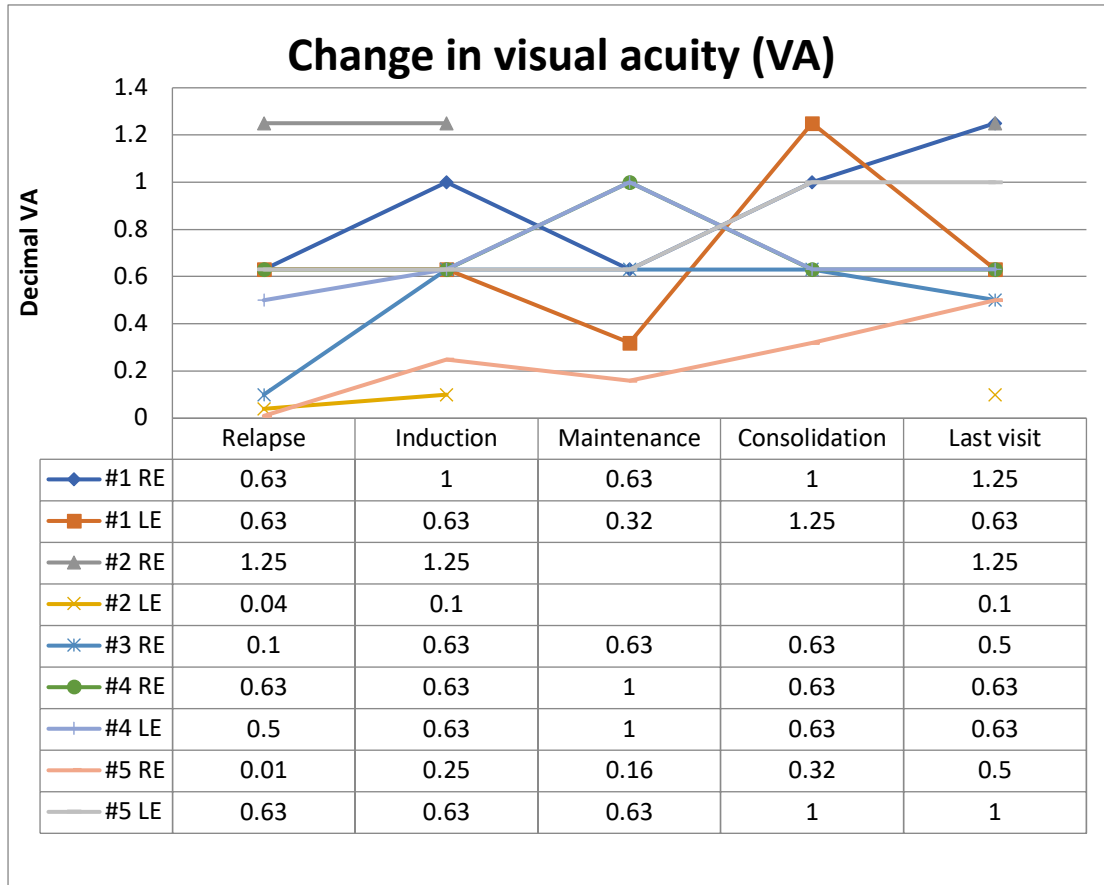


Figure 2. Change in visual acuity (decimal visual acuity) for each eye of the 5 patients at time of PIOL relapse, after each phase of MTX injection and at last visit. RE – right eye; LE – left eye.

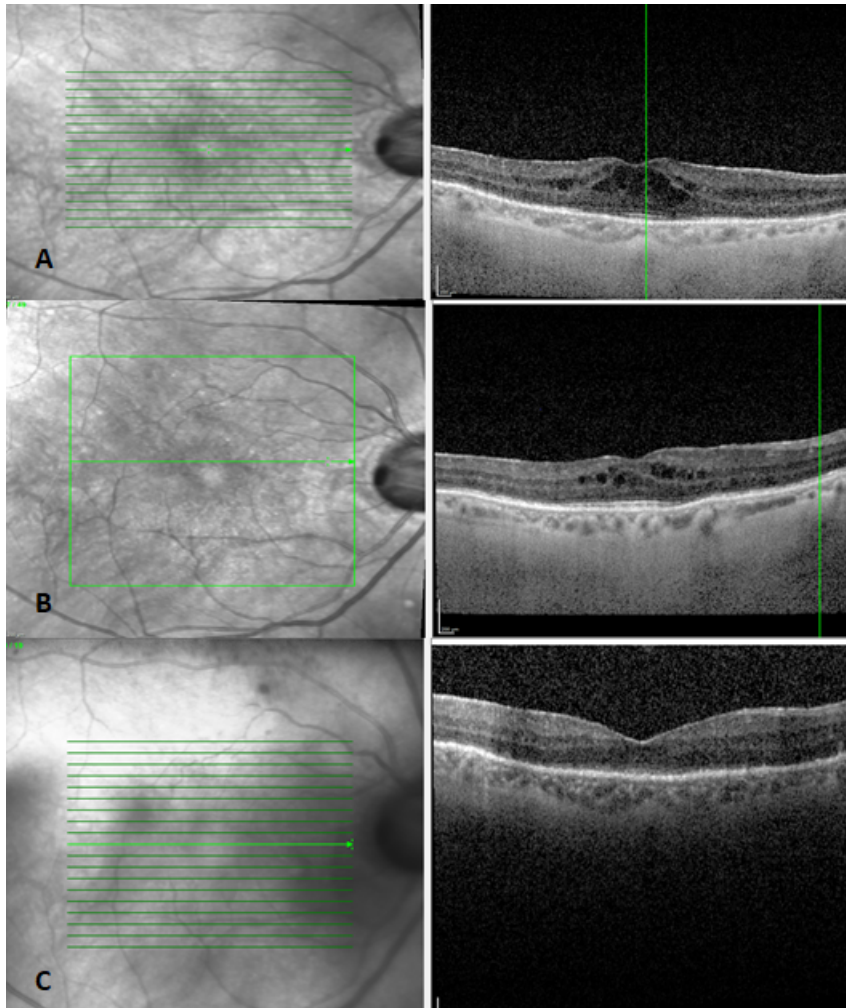


Figure 3. Optical coherence tomography scans demonstrating the development of cystoid macular oedema (patient #3) during the course of MTX injections **(A)** after the 5th intravitreal methotrexate injection; **(B)** response to topical anti-inflammatory medication; and **(C)** at final follow-up with total resolution of the oedema with improvement in visual acuity.

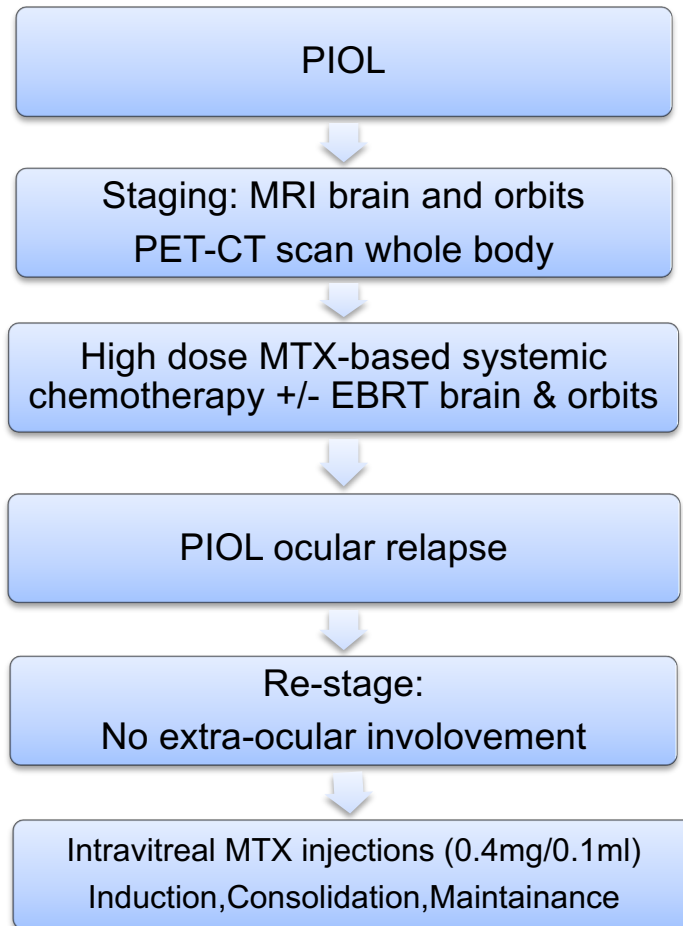


Figure 4. Algorithm for the management of primary intraocular lymphoma and the role of intravitreal methotrexate for ocular only relapse.